

Spinal Orthopedic Exam Manual
for the
Neuromusculoskeletal Service Line
National Naval Medical Center

Spinal Orthopedic Exam Manual

*for the
NeuroMusculoskeletal Service Line
National Naval Medical Center*

*Joanna K. Hudec, D.C.
NNMC Fellowship Integrated Medicine*

With contributions by

Captain Devol

NNMC Dept. of Chiropractic

Dr. Morgan

NNMC Dept. of Neurology

Dr. McKenna

NNMC Dept. of Neurosurgery

Dr. Mason and Dr. Mulligan

NNMC Dept. of Orthopedics

Dr. Phipps

NNMC Dept. of Physical Therapy

Editing and Formatting

Erika Warner

Table of Contents:

Spinal Ranges of motion 7

Space Occupying Lesion Tests

Valsalva 8

Dejerine's Sign 9

Swallowing Test 9

Fracture Tests

Rust's Sign 10

Spinal Percussion 10

Cervical Compression Tests

Cervical Compression Test 12

Jackson Compression Test 12

Maximum Cervical Compression Test 13

Spurling's Test 14

Cervical Orthopaedic Tests

Bakody's Sign 15

Cervical Distraction 16

L'hermitte's Sign 17

Shoulder Depression 17

Soto Hall Test 18

TOS & Brachial Plexus Tests

Roo's Test 19

Allen's Test 20

Adson's Test 21

Wright's Test 22

Brachial Plexus Stretch Test 23

Neural Tension Tests

Straight Leg Raise 25 -26

Neural Tension Tests Continued:

<i>Well Leg Raise</i>	27
<i>Bechterew's Test</i>	27
<i>Lasègue's Test</i>	28
<i>Braggard's Test</i>	29
<i>Sicard's Test</i>	29
<i>Tury'n's Sign</i>	30
<i>Femoral Nerve Traction Test</i>	30
<i>Slump Test</i>	31
<i>Lindler's</i>	32

Contracture Tests

<i>Ely's Sign</i>	33
<i>Thomas Test</i>	33
<i>Rectus Femoris Contracture Test</i>	34

Lumbar Orthopedic Test

<i>Axial Trunk-Loading</i>	35
<i>Heel/Toe Walk Test</i>	36
<i>Kemp's Test</i>	37
<i>Milgram's Test</i>	38
<i>Minor's Sign</i>	38
<i>Nachlas Test</i>	39

Pelvis, Sacroiliac, and Hip Joint Tests

<i>Gaenslen's Sign</i>	40
<i>Goldthwaith's Test</i>	41
<i>Iliac Compression Test</i>	41
<i>Hibb's Test</i>	42
<i>Gillis' Test</i>	42
<i>Patrick's Test</i>	43
<i>Trendelenburg Test</i>	44
<i>Yeoman's Test</i>	45

Neurologic Tests

<i>Hoffman's Sign</i>	46
-----------------------	----

Babinski's Sign 47

Heel to Shin Test 48

Romberg's Sign 49

Evaluation of Nerve Root Lesions

Upper Extremity 50-51

Lower Extremity 52

References 53

Preface

For several years the spine specialties at the National Naval Medical Center, Bethesda (NNMC) endeavored to create a spinal center of excellence, the Defense Spine Center. The model of this center has evolved from a stand-alone clinic to a more realistic virtual clinic.

One of the challenges that confronts anyone trying to integrate eight different specialties (neurosurgery, neurology, neuroradiology, orthopedic surgery, chiropractic, physical medicine and rehabilitation, physical therapy, and occupational therapy) is vocabulary and standardization of evaluation procedures. This guidebook represents an attempt to bridge this gap.

This manual was established through a modified Delphi process. Dr. Joanna Hudec interviewed representatives from the various specialties at Bethesda, asking them to describe which examination procedures were commonly employed. She then compiled these examinations and took the names used by each of the professions to label them. After consulting the literature, she described each procedure in detail. If more than one name was used to identify a procedure, she included also-known-as (AKA) names.

Dr. Hudec compiled the data into booklet form, and it was distributed to the various clinics for refining, approval and editing. Each specialty was allowed contribute to this consortium of information. Finally, when everyone agreed to its content, this booklet was completed.

There was varying consensus on the normal ranges of spinal motion by the various specialties, so we chose the ranges recognized by the 38 CFR Book C-Schedule for Rating Disabilities as our standard. These numbers represent the standards used in disability rating by military medical boards.

Photos were taken by Gill Fortin of the NNMC Medical Photo department to expand on the written descriptions. Diana Pino of the graphic arts department created schematic illustrations to simplify the concepts behind various findings.

I commend Dr. Hudec for her work on this project.

*William E. Morgan, D.C.
Neuromusculoskeletal Service Line
National Naval Medical Center, Bethesda*

Spinal Ranges of Motion

	CERVICAL	THORACIC	LUMBAR
FLEXION	60°	60°	90°
EXTENSION	60°	25°	30°
LATERAL FLEXION	45 °	35°	30°
ROTATION	80°	50°	30°

Space Occupying Lesions

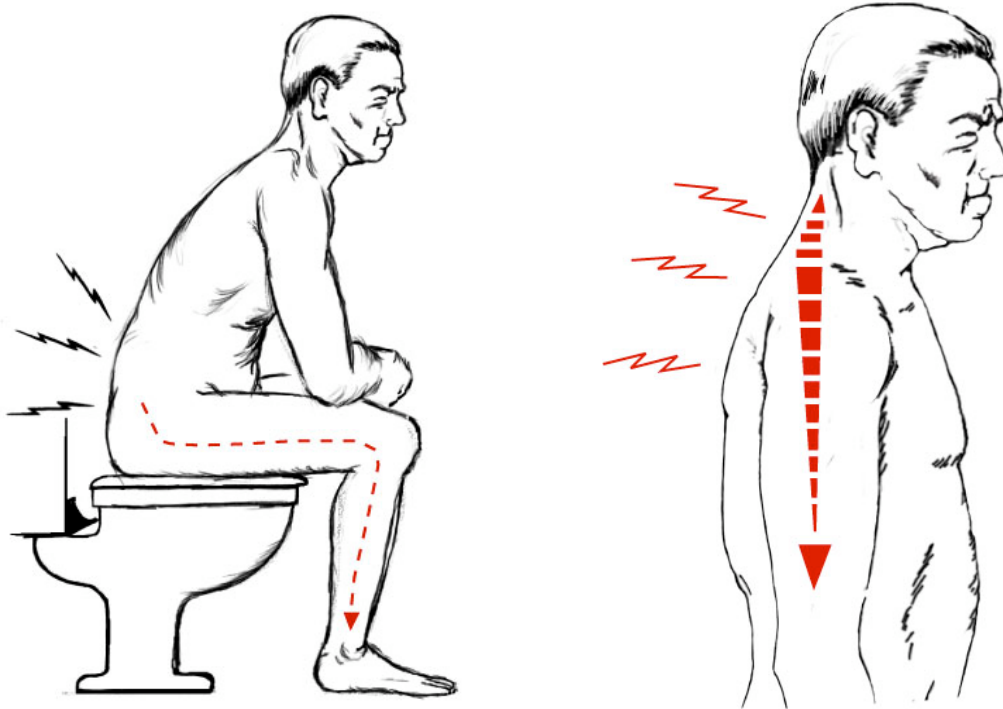
- Valsalva
- Dejerine's Sign
- Swallowing Test

Valsalva

Action: With the patient in a seated position, instruct the patient to take a deep breath and bear down (as if defecating). Ask the patient if there is any increased pain and if so, ask them to point to its location.

Significance: Local spinal or radiating extremity pain.

Indication: This test increases intrathecal pressure in the entire spine and may indicate a space-occupying lesion in the spinal cord or foraminal encroachment such as IVD or soft tissue growth.



Dejerine's Sign (Dejerine's Triad)

Action: With the patient seated, instruct the patient to:

1. cough
2. sneeze
3. bear down (Valsalva Maneuver)

Significance: Pain, either localized or radiating into the extremities after any of the above actions.

Indication: Indicates a space-occupying lesion.

Swallowing Test

Action: With the patient seated, have the patient drink a glass of water OR ask the patient if there is difficulty swallowing.

Positive: Patient has difficulty swallowing.

Indication: Swallowing difficulties can persist due to a space occupying lesion in the anterior cervical spine such as an osteophyte, tumor, DISH, Ankylosing Spondylitis, soft tissue swelling.



Fracture Tests

- *Rust's Sign*
- *Spinal Percussion*

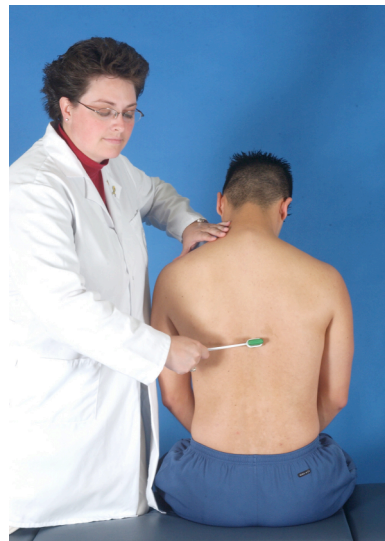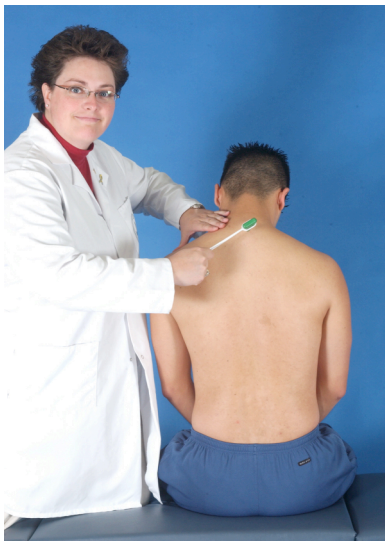Rust's Sign

Action: A sign in which the patient presents with both hands holding the head or when arising from a seated or lying position for support.

Indication: A patient with severe cervical spinal injuries (severe sprain/strain, Rheumatoid Arthritis, fracture, or severe cervical subluxation) is subject to stabilization of the head with slight traction. This action can help with pain reduction.



Spinal Percussion



Action: With the patient seated, instruct the patient to slightly flex their head forward. The examiner uses a reflex hammer to percuss the spinal musculature then the spinous processes of the **cervical, thoracic, and lumbar spine**.

Positive: Radicular pain or a significant increase in local pain.

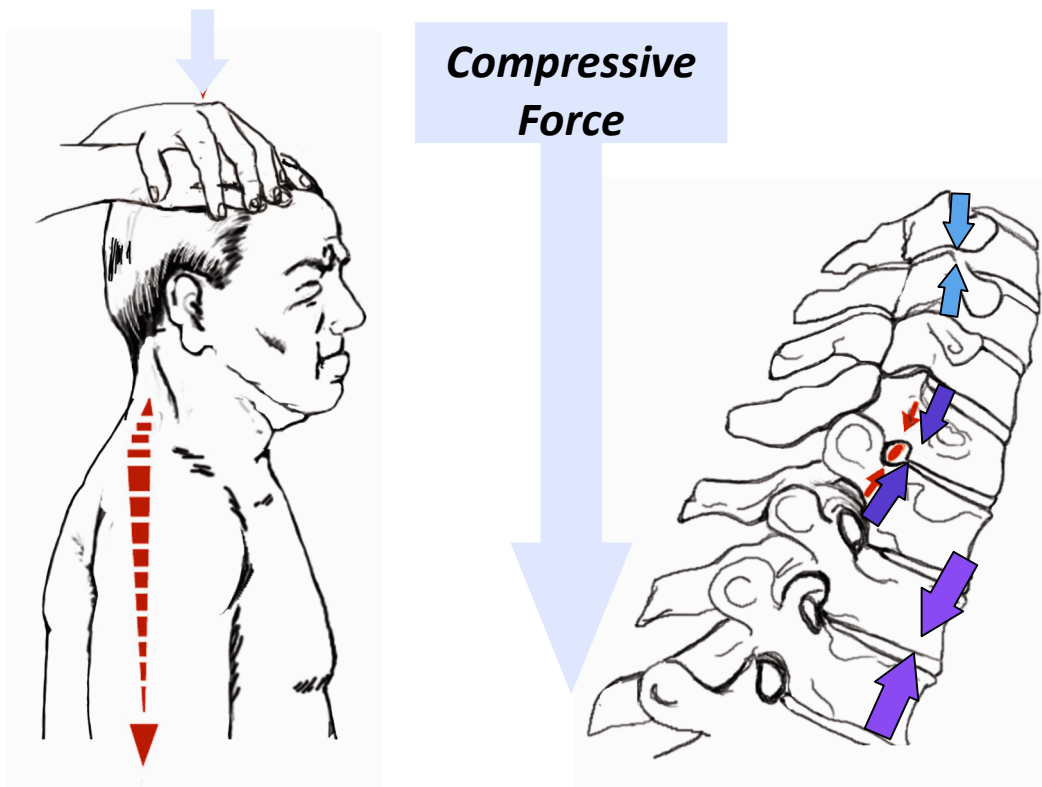
Indication: Pain in the musculature is suggestive of sprain/strain. Radicular pain is suggestive of disc lesions, and severe local pain is suggestive of osseous or cord damage.

Cervical Compression Tests

There are multiple named tests that utilize compressive force on the cervical spine. They all share the procedure of applying force through the top of the head but some further stress the integrity of the anatomy by placing the cervical spine in combined movement patterns.

When compression is applied to patient's head and neck, the following biomechanical considerations take place:

- 1) *Compression of the cervical intervertebral discs.*
- 2) *Narrowing of the cervical intervertebral foramina.*
- 3) *Compression of the cervical facet joints.*



Named compression tests:

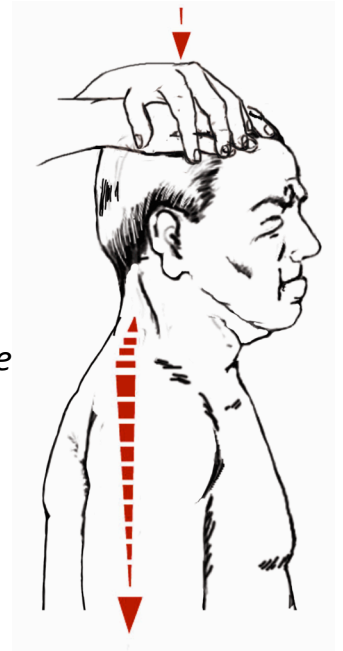
- *Cervical Compression*
- *Jackson Compression*
- *Maximum Cervical Compression*
- *Spurling's*

Cervical Compression Test

Action: The patient sits in a neutral position. The examiner gradually applies increasing axial pressure on the head and cervical spine.

Positive: Exacerbation or production of local or radicular pain.

Indication: An increase in local pain is indicative of facet or ligamentous damage. An increase in radicular pain is indicative of nerve root involvement, foraminal encroachment, or disc herniation.

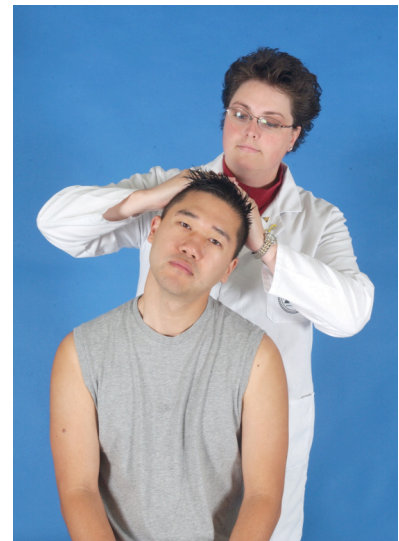

Jackson Compression Test

Action: With the patient seated, laterally flex the patient's head and apply downward pressure.

Positive: Exacerbation of local or radicular pain.

Indication: An increase in local pain is indicative of facet or ligamentous damage or muscle strain. An increase in radicular pain is indicative of nerve root involvement, foraminal encroachment, or disc herniation.



Maximum Cervical Compression Test

Action: Patient is seated and **actively** laterally flexes, rotates, and extends the head toward the side of pain. **If pain is positive STOP.** If no pain is elicited, the examiner then compresses the patient's head.

Positive: Exacerbation of local or radicular pain.

Indication: An increase in local pain is indicative of facet or ligamentous damage or muscle strain. An increase in radicular pain is indicative of nerve root involvement, foraminal encroachment, or disc herniation.



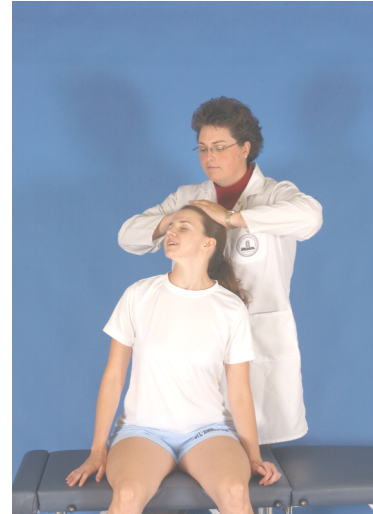Spurling's Test



Neutral Position



Rotation



Hyperextension

Action: With the patient seated follow the three steps of this test. If at any time symptoms are reproduced or exacerbated, do not continue to the next step and consider the test positive.

1. Examiner applies pressure on the patients head in neutral position.
2. Examiner rotates head to side of pain and applies downward pressure.
3. Examiner rotates and hyperextends the patients head and applies downward pressure.

Positive: Radicular pain into arm.

Indication: The biomechanical action of this test compresses the posterior elements of the vertebra indicating foraminal encroachment and nerve root irritation. If pain is positive on the opposite side of head rotation, then suspect sprain/strain (Reverse Spurling's Sign).

Cervical Orthopedic Tests

- *Bakody's Sign*
- *Cervical Distraction*
- *L'hermitte's Sign*
- *Shoulder Depression*
- *Soto Hall*

Bakody's Sign (Shoulder Abduction Test)

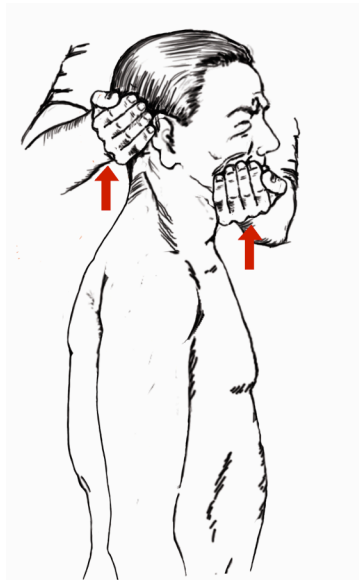
Action: Patient actively places the hand of the affected arm on his/her own head.

Positive: A **decrease** in the radicular symptoms.

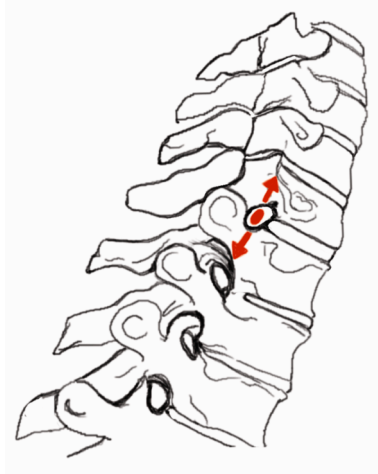
Indication: By abducting the shoulder in this manner, the suprascapular nerve and brachial plexus slack causing a decrease or cease in pain/radiculopathy. This is indicative of a cervical compression problem usually associated with the lower cervical spine (C4-C5, C5-C6) or scalene entrapment.



Cervical Distraction



Cervical Distraction



IVF Distraction, decreases encroachment

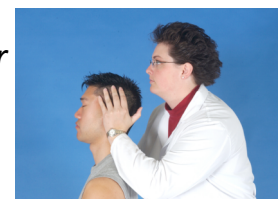Action: This test can be performed in two different ways. Both with the patient seated.

Technique 1

Examiner stands to the side of the patient with one hand under the mandible and the other hand under the occiput. The examiner lifts (distracts) the patients head up.

Technique 2

Examiner stands behind the patient with hands under the mastoids and lifts (distracts) patients head up.



Hold this position for 30-60 seconds.

NOTE: If the patient presents with TMJ symptomology use technique #2.

Positive: A decrease in pain and/or radiculopathy.

Indication: By distracting the cervical spine, this causes a decrease in pressure on the cervical spine. Emphasize in pain is indicative of foraminal encroachment and nerve root irritation. An increase in pain is indicative of muscle or ligament sprain/strain causing local pain.

L'hermitte's Test

Action: With the patient seated, actively flex the chin to the chest.

Positive: sharp radicular pain or paresthesia into the upper or lower extremities or down the spine.

Indication: Flexion of the cervical vertebra causes the spinal cord and surrounding tissues to be tractioned and the discs to be compressed. If the patient has a posterior disc lesion, this movement may exacerbate the defect resulting in spinal cord or nerve root compression. Cervical cord disease, meningitis, osteophytes, and masses may cause local and/or radicular pain into upper and/or lower extremities.

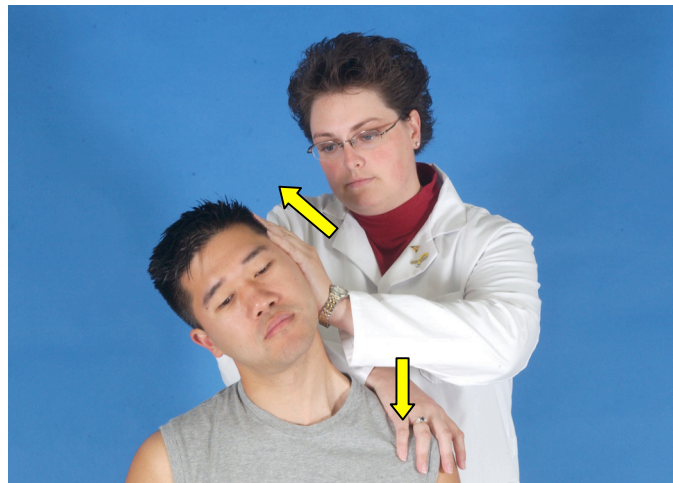

Shoulder Depression

Action: With patient sitting, doctor stands behind patient and passively flexes patient's head laterally away from the side being tested while simultaneously applying downward pressure onto the same side shoulder.

Positive: Exacerbation of pain and/or radicular pain.

Indication: Pain on the side being tested is an indication of adhesions of the nerve roots at the dural sheath and/or brachial plexus being impinged. If the pain is positive on the opposite side being tested it is an indication of IVF or disc compression.

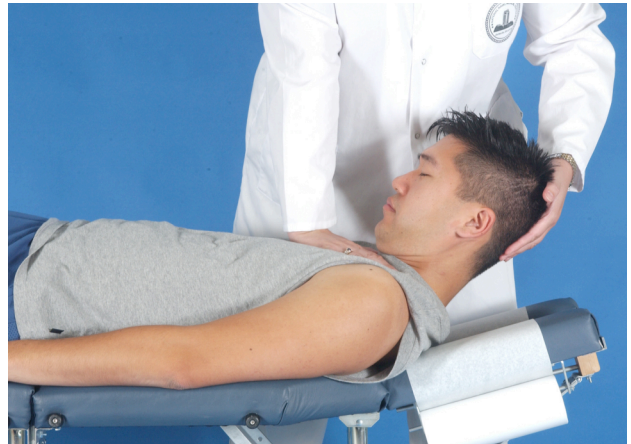

Soto Hall Test

Action: With the patient supine, the examiner stabilizes over the patient's sternum with one hand and flexes the patient's head and neck with the other.

Positive: Exacerbation of pain in cervical spine or radicular pain into upper or lower extremities.

Indication: Posterior neck pain indicates a lesion to posterior structures such as subluxation, sprain, strain, fracture. Anterior neck pain indicates a lesion to anterior neck structures such as vertebral body pathology or fracture, disc, exostosis, and sprain.



TOS & Brachial Plexus

- *Roo's*
- *Allen's*
- *Adson's*
- *Wright's*
- *Brachial Plexus Stretch Test*

Roo's Test (Provocation Elevation Test)



Action: Patient is seated with shoulders abducted to 90° and elbows flexed. The examiner then instructs the patient to open and close their fists tightly for up to 3 minutes.

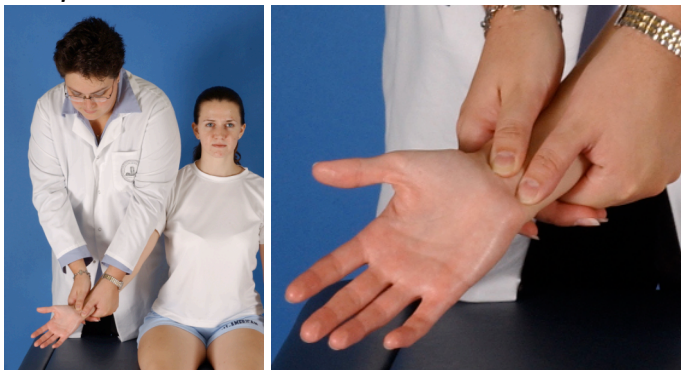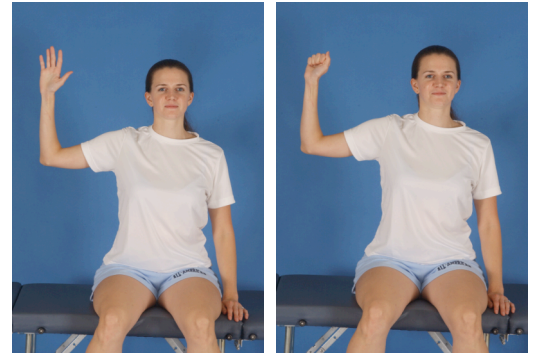
Positive: Unable to maintain the action due to weakness, numbness, or tingling in one or both extremities.

Indication: Thoracic Outlet Syndrome, peripheral vascular disease.

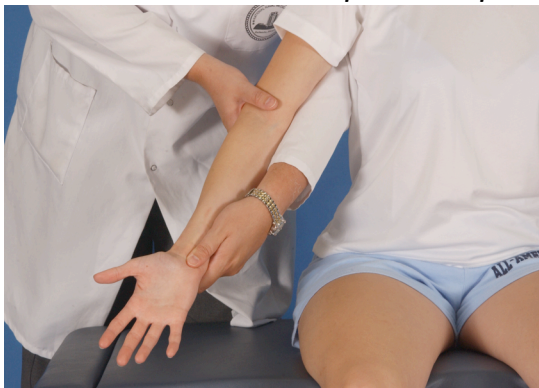Allen's Test

1st Action: Have the patient abduct the affected shoulder and flex the elbow to 90 degrees. Then have them pump their fist, this allows the blood to drain from the hand.

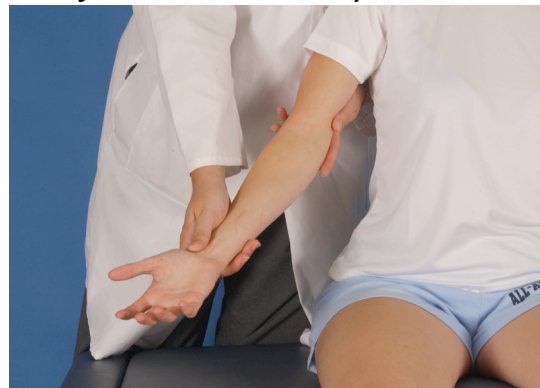2nd Action: Next, the examiner occludes the radial and ulnar arteries with the thumbs and drops the patients arm down.



3rd Action: The examiner then releases pressure off the radial artery and counts how many seconds it takes for the normal vascularization color to return to the hand. Repeat the procedure for the ulnar artery.



Radial

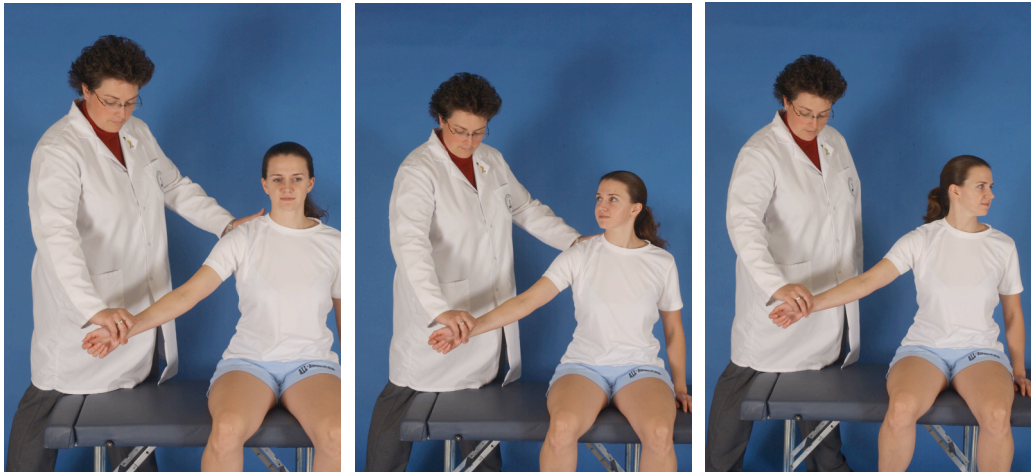

Ulnar

Positive: If skin remains blanched for more than 5 seconds.

Indication: Thoracic Outlet Syndrome, peripheral vascular disease.

Adson's Test



Scalenius Anticus

Scalenius Medius

This test is performed in two parts:

1st Action: (aka Scalenius Anticus Test) With the patient seated, the examiner takes a base line pulse. Then the examiner abducts the patient's affected arm. The patient is told to **rotate the head toward** the affected side and hyperextend the neck; then take a deep breath and hold it.

Positive: Decrease in amplitude or disappearance of the pulse. Patient can also have radicular pain into arms.

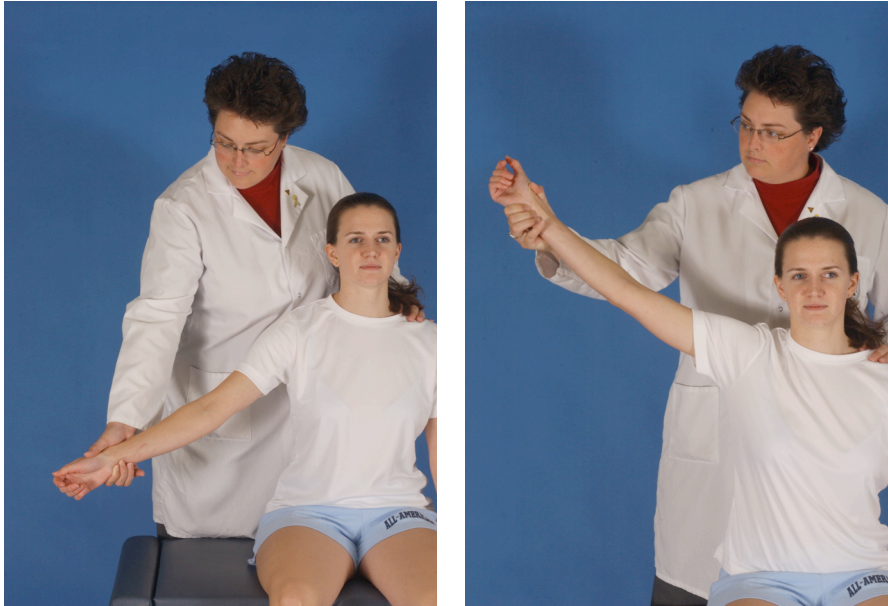Indication: Thoracic Outlet Syndrome (TOS) due to the compression of the Subclavian vessels by the cervical rib or Scalenius Anticus muscle.

2nd Action: (aka Reverse Adson's or Scalenius Medius Test) With the same arm abducted, the patient is then told to **rotate the head away** from the affected side and hyperextend the neck; then take a deep breath and hold it.

Positive: Decrease in amplitude or disappearance of the pulse. Patient can also have radicular pain into arms.

Indication: Upper extremity entrapment neuropathies due to the compression of the Subclavian vessels by the cervical rib or Scalenius Medius muscle.

Wright's Test (Hyperabduction Test)

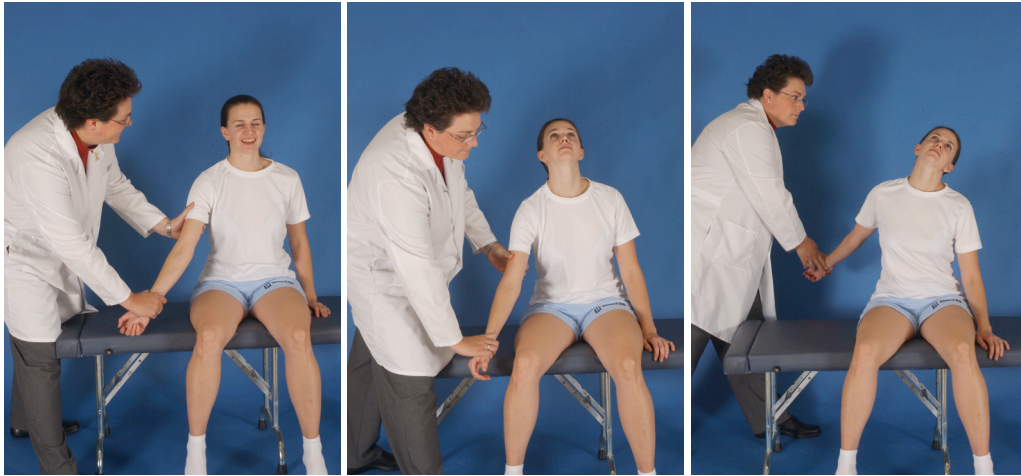

Action: With the patient seated or standing, the examiner takes a base line pulse. Then the examiner takes the pulse while passively abducting the patient's arm. Do this bilaterally.

Positive: Decrease in amplitude or disappearance of the pulse with possible radiating arm pain into the affected arm at an earlier angle than the unaffected arm.

Indication: Upper extremity entrapment neuropathies caused by compression of axillary vessels by the Pectoralis Minor muscle.

Brachial Plexus Stretch Test



Action: With the patient seated, the examiner supports the arm and slightly tractions. The examiner then instructs the patient to laterally flex their head away from the affected side and then the patient externally rotates and extends the shoulder back.

Positive: Radicular pain and/or paresthesia into the upper extremity.

Indication: This test has been described at the Straight leg raise test for the upper extremity. This test stretches the brachial plexus causing pain and/or paresthesia into the extremity opposite of lateral flexion if lesions are present, notably lower cervical disc herniations or direct brachial plexus damage. If pain occurs on the same side as lateral flexion, suspect cervical facet joint problems.

Lumbosacral Neural Tension Tests

Neural Tension Tests are described as tests that resolutely increase the tension of the lumbosacral nerve roots and sciatic nerve in order to assess nerve root irritation and disc involvement. This is done by flexion or extension of the hip along with various additional actions that increase nerve tension and therefore increasing sensitivity and/or specificity. A positive assessment would typically reproduce or aggravate lower limb pain or paresthesia.

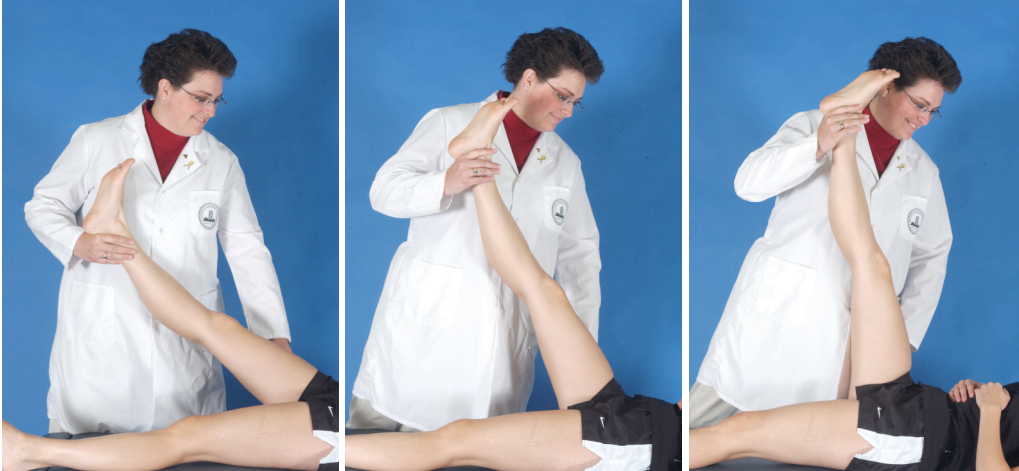Restriction of the hip and knee due to severe muscle tightness may adversely affect the validity of these tests. Additionally, these tests may stress the lumbopelvic and lower limb anatomy (musculature, hip, sacroiliac joint, facet joints) and consideration should be noted.

The Straight Leg Raise (elevation of the affected leg) is the most frequently performed neural tension test and has been shown to have reasonable validity to diagnose disc herniations. The validity of the diagnosis is increased with a positive Well Leg Raise (elevation of the unaffected leg) (1). Vroomen performed a systematic review of the literature from 1965 to 1994 and found the Straight Leg Raise to be the only test to be consistently sensitive and the Well Leg Raise to be the only test to be specific for sciatica caused by disc herniation (2,3). The Well Leg Raise has also been documented as a strong indicator of disc and nerve root involvement.

Neural Tension Tests:

- **Straight Leg Raise (SLR)**
- **Well Leg Raise**
- **Bechterew's**
- **Lasegue's**
- **Braggard's**
- **Sicard's**
- **Turyn's**
- **Femoral Nerve Traction Test**
- **Slump Test**
- **Lindler's**

Straight Leg Raise



Action: Patient is supine. The examiner lifts the affected leg keeping the knee straight to the point of pain or exasperation.

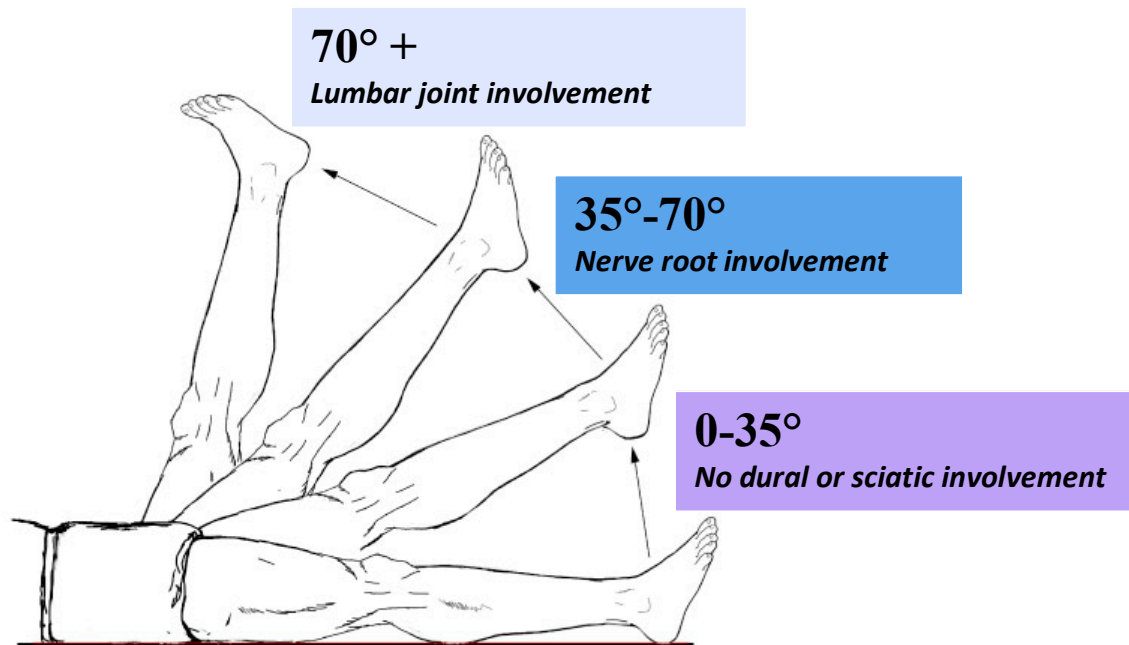
Positive: Paresthesia and/or Radicular pain into the leg.

Indication: Pain exacerbated only when leg is lifted indicates sciatic neuralgia. An increase in leg pain when the patient flexes the neck indicates intervertebral disc syndrome or nerve root irritation. Note: the test primarily stretches the sciatic nerve and spinal nerve roots of the lower lumbar and upper sacral levels (L5-S2).

0 to 35 degrees of flexion does not affect the spinal levels because there is no dural or sciatic involvement movement.

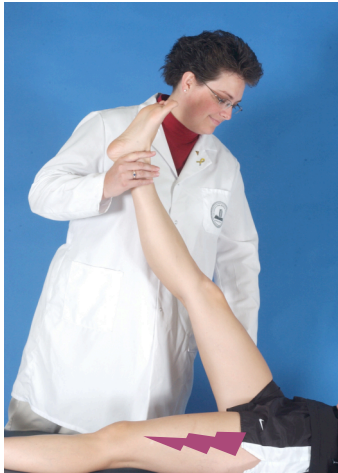35 to 70 degrees of flexion tenses the nerve roots over the intervertebral discs causing pain if disc pathology or intradural lesion is present.

70 to 90 degrees of hip flexion causes full stretching of the nerve roots and sciatic nerve. If pain is elicited lumbar joint pain is suspected.



Straight Leg Raise

Well Leg Raise (Fajersztajn's Test or Crossed Leg Test)

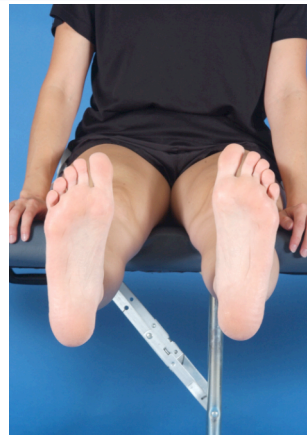
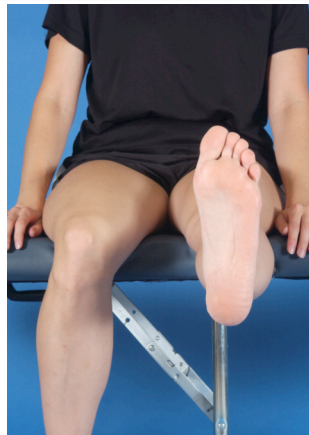
Action: The patient is supine. The examiner performs a straight leg raise test on the unaffected leg. When the leg is flexed to the point of pain, slightly lower the leg and dorsiflex the foot.

Positive: Significant increase or decrease of pain or paresthesia in the affected leg.

Indication: By flexing the unaffected leg at the hip, the nerve root on the affected side becomes tense and moves toward the midline. If a medial disc protrusion is present, this action will cause radicular pain down the affected leg. If a lateral disc protrusion is present, this action will cause a decrease in pain of the affected leg because the nerve root moves away from the lesion.

Seated Straight Leg Raise (Bechterew's Test)

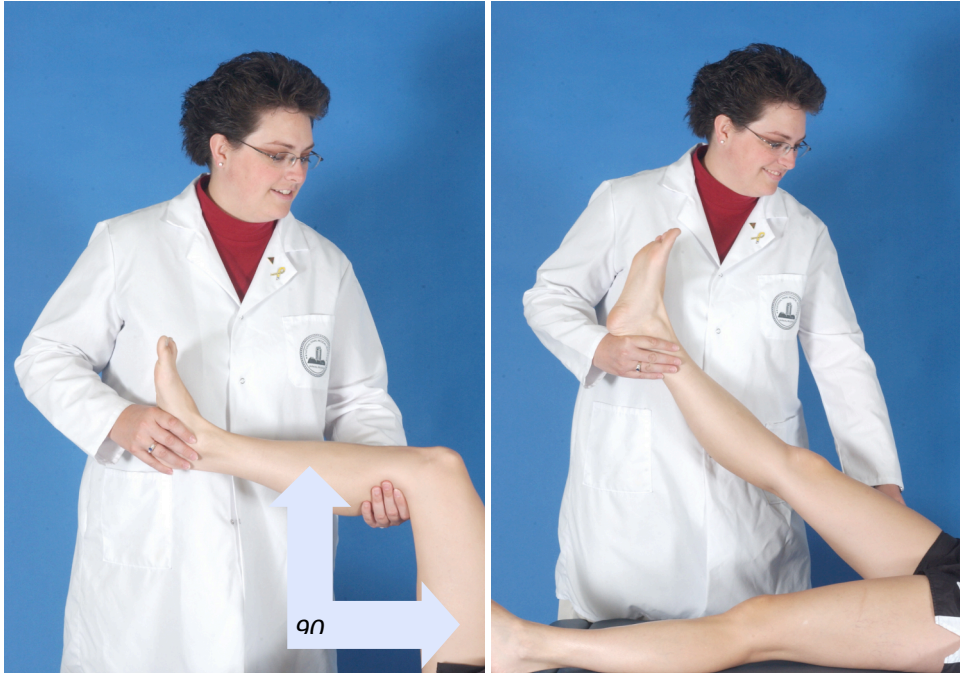

Action: Patient is in a seated position with legs hanging freely over the exam bench. Have the patient extend one leg at a time. If no pain is elicited, have the patient extend both legs at the same time.

Positive: Radicular pain into leg OR watch for the patient leaning back in order to perform the test.

Indication: When the leg is extended or both legs are extended, the sciatic nerve is tractioned causing pain if lesions are present.

Lasègue's Test (Lasègue's Differential Sign)



Bent Knee at 90°

Extended Knee

Action: With the patient supine, flex the hip keeping the knee bent at 90°. Note if the patient has pain. Then keeping the hip flexed, extend the knee so entire leg is straight. Note if the patient has pain.

Positive: The test is only positive if there is 1) *no pain with knee bent* **and** 2) *pain is elicited when knee is extended*.

Indication: By flexing the hip and knee, there is no tension of the sciatic nerve. Extending the knee to straighten the leg causes the sciatic nerve tension to increase and eliciting pain if sciatic lesions persist. Pain present with the knee bent indicates hip pathology.

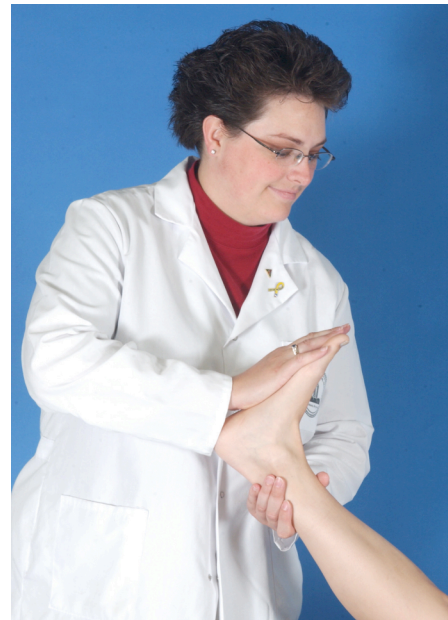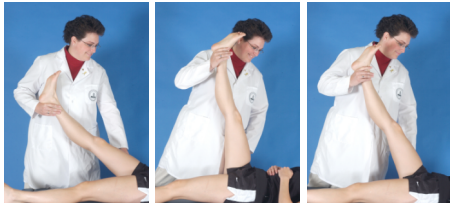Note: this test is performed in the 30-70 range of hip flexion otherwise the elicitation may be hamstring tightness and not sciatic irritation.

Braggard's Test

Action: The patient is supine. Raise the leg to the point of pain. Lower the leg 5-15 degrees and dorsiflex the foot.

Positive: Radicular pain into leg.

Indication: Flexing the hip and dorsiflexing the foot causes tension of the lower lumbar nerve roots and the sciatic nerve. This test is used for confirmation of SLR.

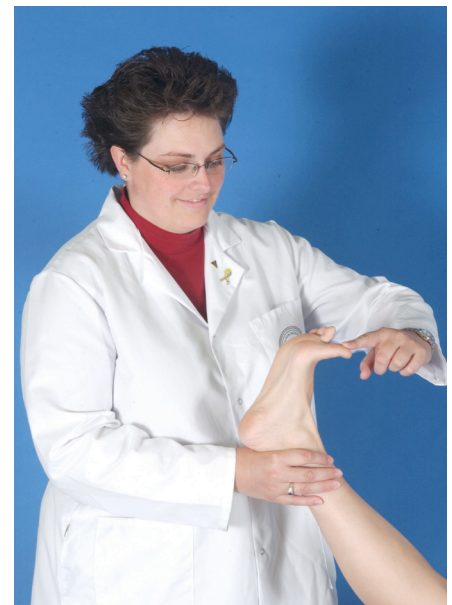

Sicard's Test

Action: The patient is supine. Raise the leg to the point of pain and then lower the leg 5 degrees. Dorsiflex the big toe.

Positive: Radicular pain into leg.

Indication: When raising the leg (flexion of the hip with a straight leg) and dorsiflexing the first toe causes tractioning of the sciatic nerve causing sciatic radiculopathy if a lesion is present. Confirmation of both SLR and Braggard's.

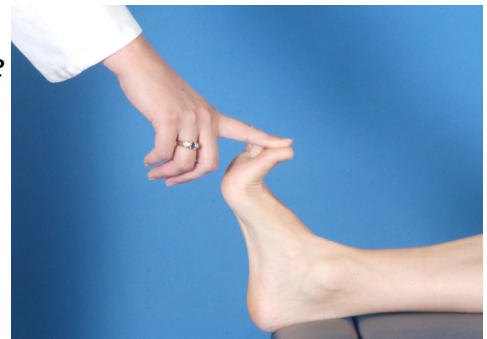

Tury'n's Sign

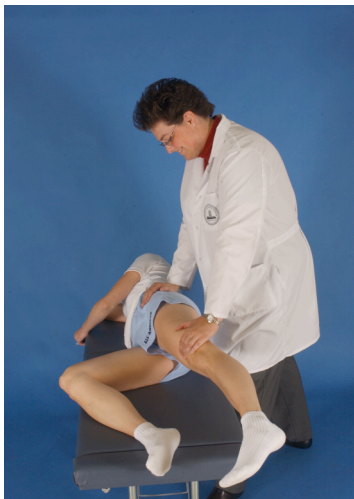Action: With patient lying supine on the exam table with legs flat (hip not flexed) the examiner dorsiflexes the first toe.

Positive: Radicular pain.

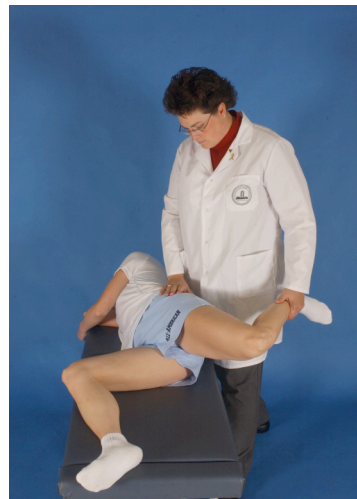Indication: Dorsiflexion of the first toe causes tractioning of the sciatic nerve causing sciatic radiculopathy if a lesion is present.



Femoral Nerve Traction Test



Straight leg



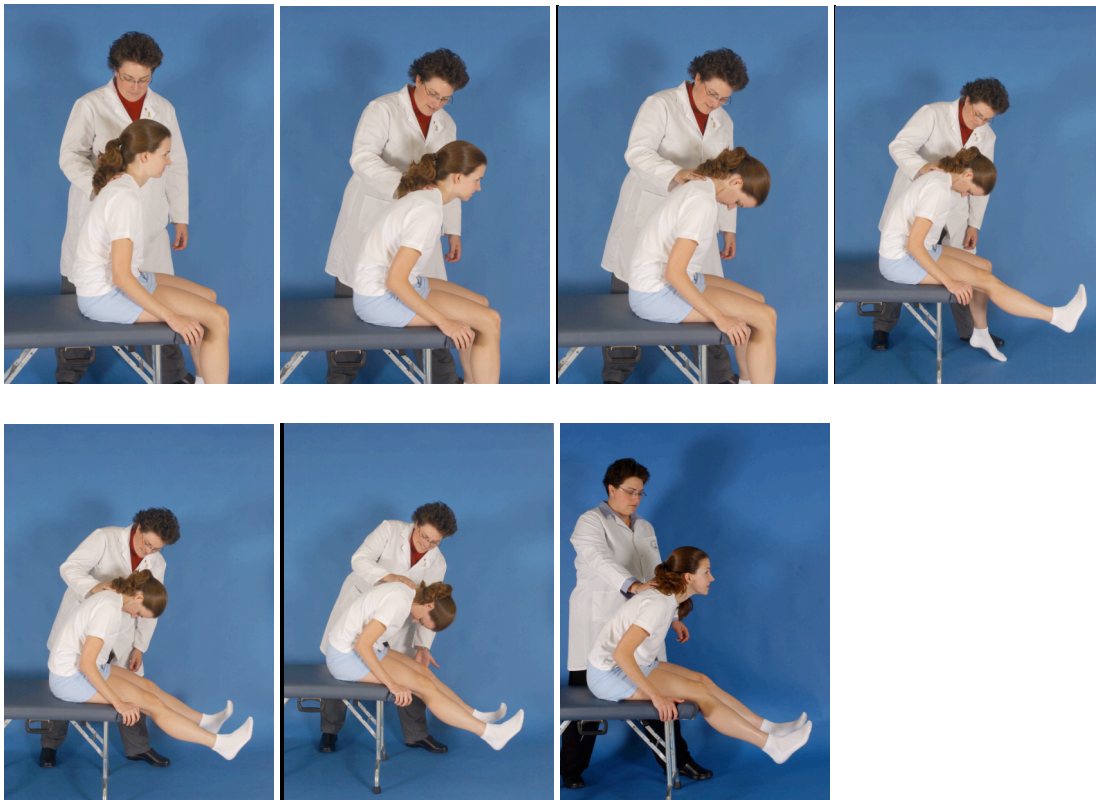knee flexed

Action: Patient lies with affected side up. Patient actively flexes unaffected hip (side toward the table) and knee. The examiner then passively extends the affected hip (side up) 15 degrees and flexes the knee.

Positive: Anterior thigh pain or radicular pain into the leg.

Indication: Extending the patient's hip and flexing the knee causes tractioning of the middle lumbar nerve roots (L2-L4) and the Femoral Nerve.

Slump Test

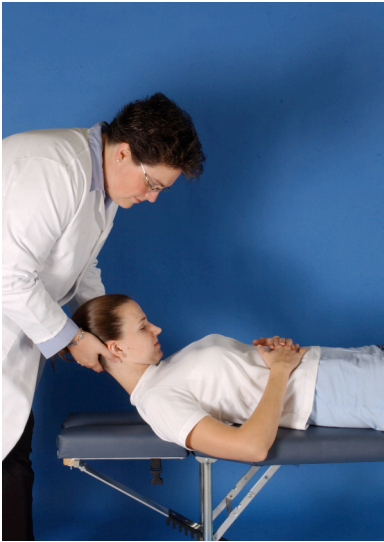

Action: This test is done in steps: With patient seated on end of exam table in a neutral position.

1. Have the patient “slump” the back so that they are in a flexed position of the lumbar and thoracic spine.
2. The examiner then applies pressure forward to maintain the flexed position and asks the patient to tuck the chin to the chest adding cervical flexion.
3. The examiner then applies pressure forward to maintain a flexed position in the lumbar, thoracic, and cervical spine.
4. Then the patient is asked to extend the knees one at a time and then both together.
5. If pain is elicited, release the cervical pressure and have the patient extend the neck back. This action should reduce pain. for increased tension of the neuromeningeal tract.

Positive: If pain is elicited with the actions above, release the cervical pressure and have the patient extend the neck back. This action should reduce the pain. Magee states this test would then be considered positive.

Linder's Test



Action: Patient is supine. The examiner flexes the patient's head to the chest and continues applying pressure until the shoulders come off the table and thoracic spine is in a flexed position.

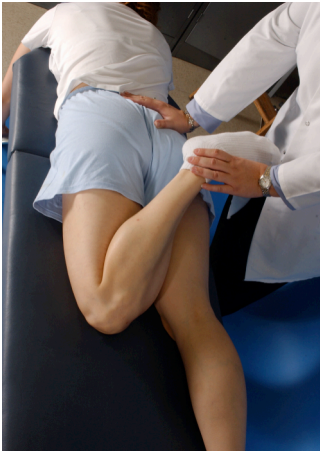Positive: Exacerbation of pain in lumbar spine and/or lower extremity radicular pain.

Indication: Flexion of the cervical and thoracic vertebra causes the spinal cord to be tractioned. If the patient has a lumbar disc lesion, this movement may exacerbate the defect.

Contracture Tests

- Ely's Test
- Rectus Femoris Contracture Test
- Thomas Test

Ely's Sign

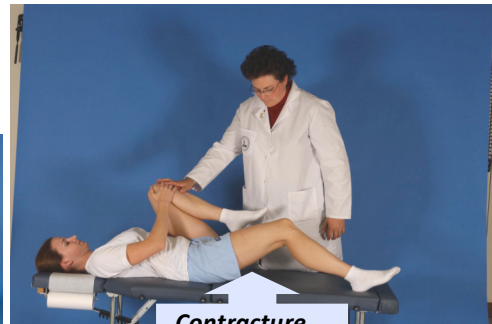
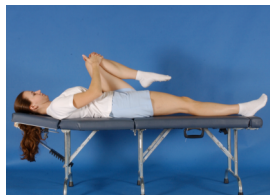
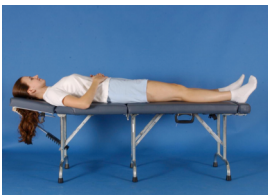Action: With the patient prone, the examiner flexes the knee until the heel touches the contralateral buttock while watching for hip flexion contracture of affected side.

Positive: The patient's hip spontaneously contracts, lifting the hip off the table.

Indication: If the patient has a tight Rectus Femoris or Iliopsoas muscle then the hip on the same side will flex causing the patient's hip to raise off the table.

Thomas Test



Action: Have the patient lie supine on the exam table with legs flat on table. Instruct the patient to flex one knee to their chest while keeping the opposite leg straight on the table. Examiner observes the opposite leg for hip flexion contracture.

Positive: If the opposite hip rises off the table.

Indication: Suspect a tight iliopsoas or rectus femoris muscle.

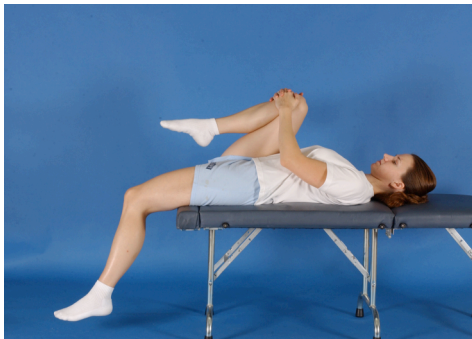
Note: if this is a positive test, continue with the Rectus Femoris Contracture Test.

Rectus Femoris Contracture Test

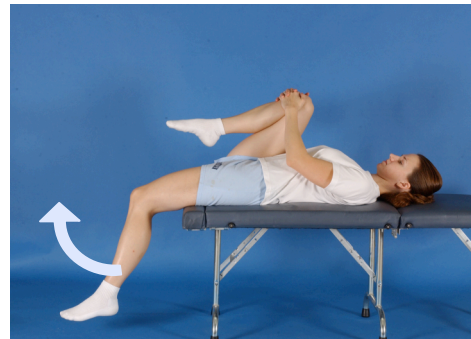
Action: Have the patient lie supine on the exam table with legs hanging off the end of the exam table at 90°. Instruct the patient to flex one knee to their chest while keeping the opposite leg hanging off the table. Examiner observes the opposite leg.

Positive: The opposite leg will straighten out.

Indication: This is suggestive of a tight rectus femoris muscle.



Negative

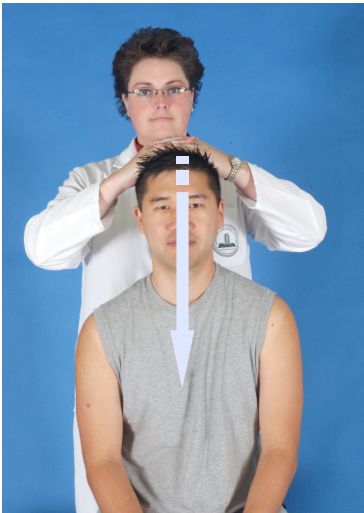

Positive

Lumbar Orthopedic Tests

- Axial Trunk-Loading
- Heel/Toe Walking Test
- Kemp's
- Milgram's
- Minor's Sign
- Nachlas

Axial Trunk-Loading

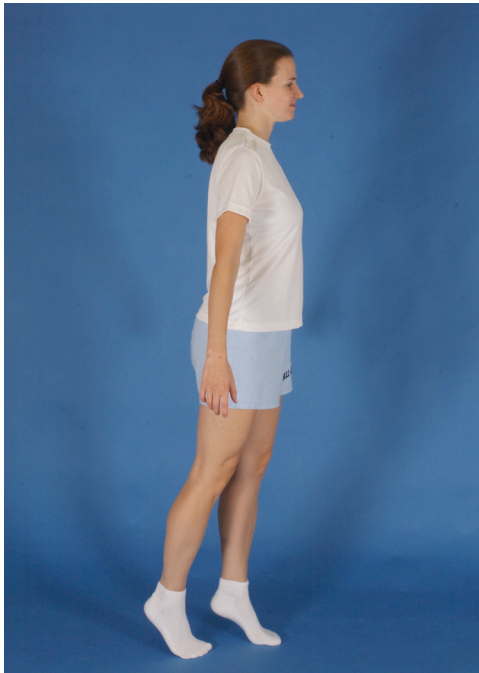

Action: This test can be performed either sitting or standing. Instruct the patient to stand or sit comfortably in an erect position. Apply strong downward pressure (axial pressure) to the top of the head.

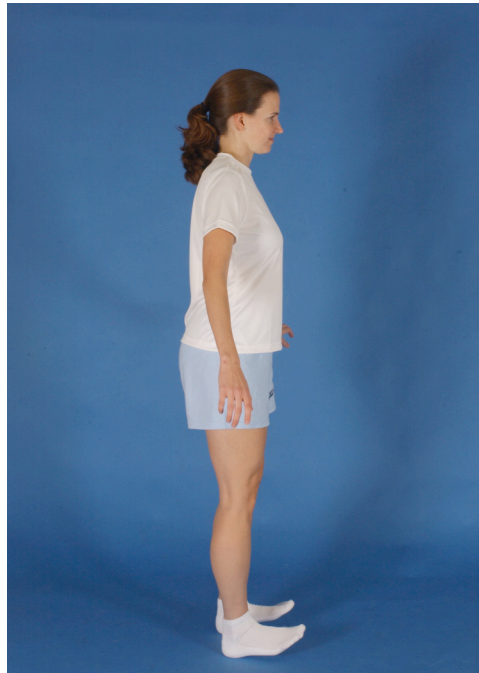Positive: Exacerbation of pain in the cervical spine only.

Indication: The axial pressure compresses the spinal components and reproduces pain in the cervical spine. Reproduction of pain in the lumbar spine is usually a nonorganic finding and the examiner would perform malingering tests.

Heel/Toe Walk Test



Toe walk



Heel walk

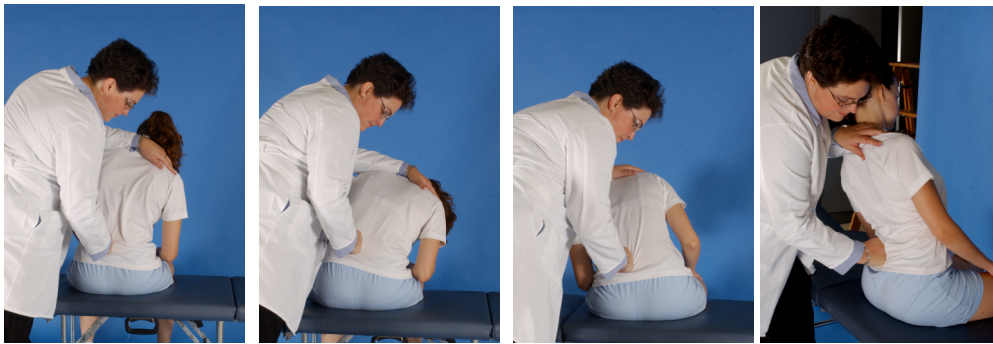Action: Ask the patient to walk on their toes. Then ask the patient to walk on their heels.

Positive: Patient can not perform the action.

Indication: Inability to walk on their toes indicates plantarflexion weakness (S1 neuropathy). Inability to walk on their heels indicates dorsiflexion weakness (L5 neuropathy).

Precaution: Have the patient near a wall or guardrail for stability.

Kemp's Test

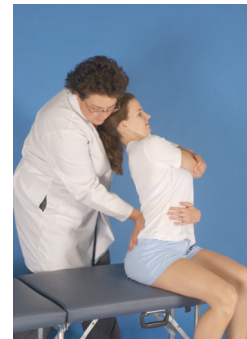

Away from pain.

To side of pain.

Obliquely extends into pain.

Action: *Instruct the patient to hug themselves or put their hands on the opposite shoulder. The examiner is behind the patient supporting the spine with one hand. The opposite hand supports upper back and shoulder region. The examiner then passively leans the patient obliquely forward away from the side of pain then rotates the patient to the side of pain and obliquely extends the patient into the side of pain.*



Positive: *exacerbation of pain.*

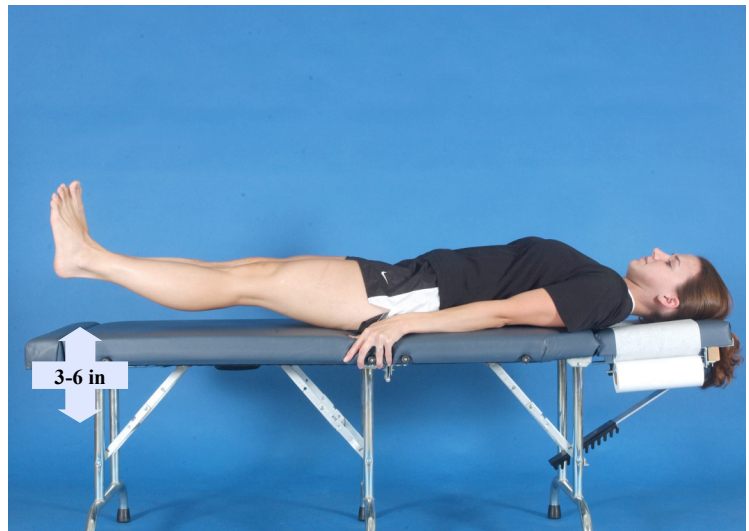Indication: *The oblique lumbar extension causes the dural sac on the side of bending to move laterally thus increasing nerve root tension over the disc. The presence of a lateral disc protrusion will cause local or radicular pain. Radicular pain will usually be on the side opposite of the oblique extension.*

Milgram's Test

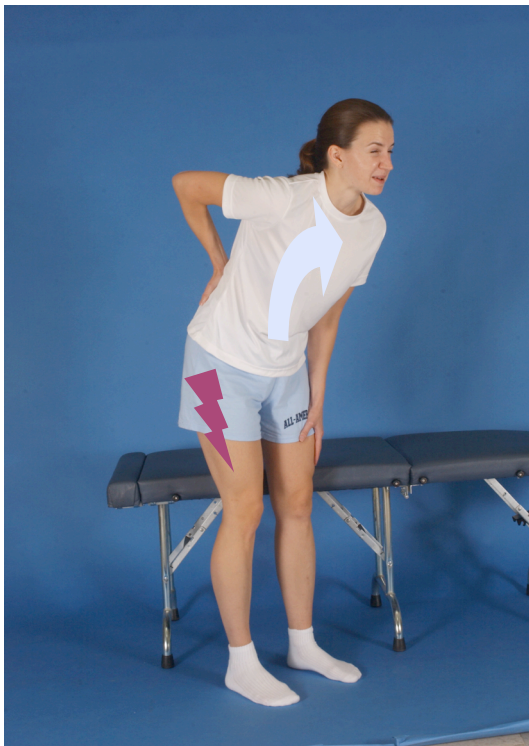Action: With the patient supine, ask the patient to lift both legs 3-6 inches above the exam table and hold them.

Positive: If the patient is unable to hold this position for 30 seconds.

Indication: The patient should be able to hold this position for 30 seconds without low back pain. If pain exacerbates, suspect a disc protrusion.



Minor's Sign



Action: Observe the patient or have the patient go from a seated to a standing position.

Positive: The patient will have an antalgic posture usually toward the unaffected side. They will use their arms to stabilize themselves and usually be slow to rise and stand.

Indication: A patient with radiculopathy will lean away from the pain and support themselves in that position. They will usually keep the affected leg slightly flexed to decrease the tractioning of the sciatic nerve.

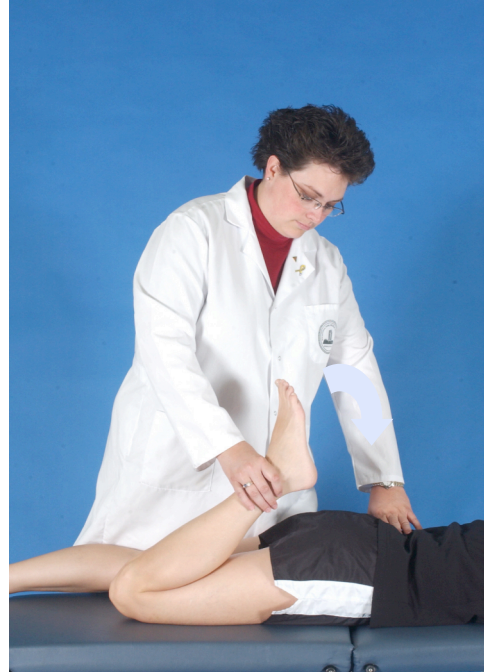Nachlas Test (Prone Knee Bending Test)

Action: With the patient prone, the examiner stabilizes the buttock with one hand and flexes the knee until the patient's heel touches the ipsilateral buttock.

Positive: Radicular pain into leg.

Indication: This action stretches the lumbar plexus and stresses the sacroiliac and lumbosacral joints.

- Pain in the SI region indicates a sacroiliac lesion.
- Pain in the lumbosacral region indicates a lumbosacral lesion.
- Pain in the anterior thigh indicates Femoral Nerve irritation (L2,L3) or pain from the Rectus Femoris muscle.
- Pain in the lateral thigh indicates Lateral Femoral Cutaneous Nerve irritation (L2,L3).



Pelvis, Sacroiliac, and Hip Joint Tests

- **Gaenslen's Sign**
- **Goldthwaith's**
- **Iliac Compression**
- **Hibb's**
- **Gillis's**
- **Patrick's FABER**
- **Trendelenburg**
- **Yeoman's**

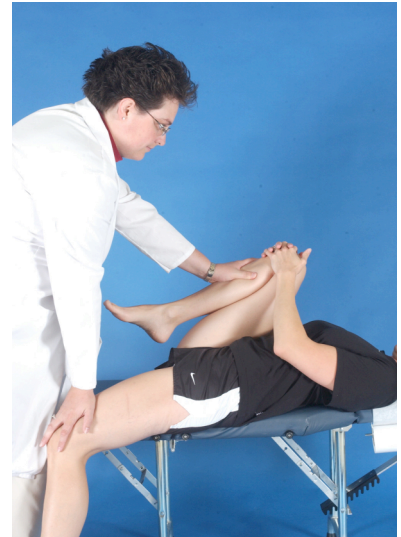Gaenslen's Sign

Action: Have the patient lie supine with affected side buttock extending over the edge of the table. The unaffected buttock remains on the table with the leg flexed to chest with the patient supporting it at the knee. Then the examiner passively hyperextends the hip with gradual pressure with one hand and the other hand stabilizes the flexed knee.

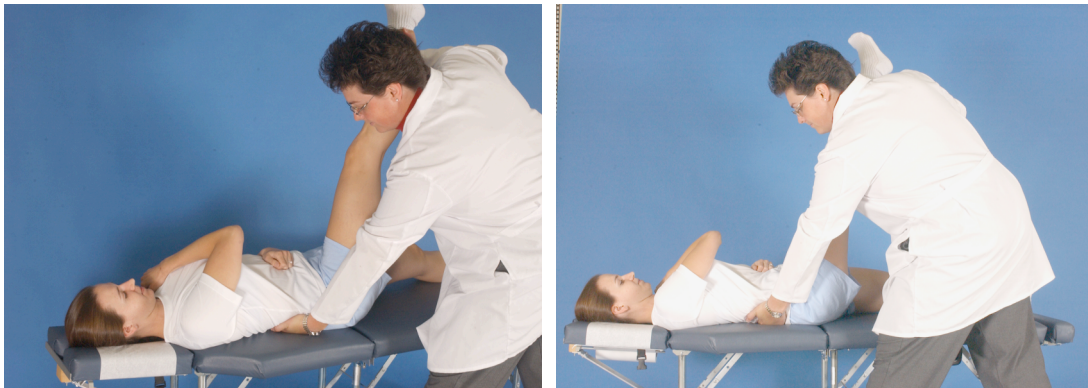Positive: Pain in the sacroiliac region or referred pain into the lower extremities.

Rationale: The hyperextension of the leg will cause torsion within the pelvis and pain in the sacroiliac region if a lesion is present.

Note: test not recommended on geriatrics.



Goldthwaith's Test

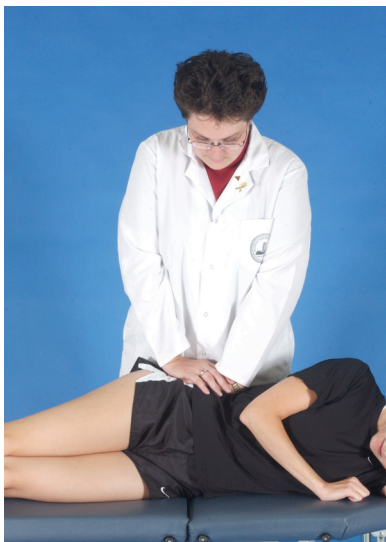

Action: The patient is supine. The examiner places one hand under the low back with fingers palpating the interspinous space. With the other hand, the examiner raises the leg (Straight Leg Raise). The examiner notes whether the pain is elicited *before, during, or after* the spinous processes gap.

Indication:

0 to 35 degrees: no lumbar spinous gapping indicates extradural lesion
35 to 70 degrees: lumbar spinous processes gap indicating intradural lesion.
70 to 90 degrees is after lumbar gapping which indicates posterior lumbar joint disorder.

Iliac Compression Test

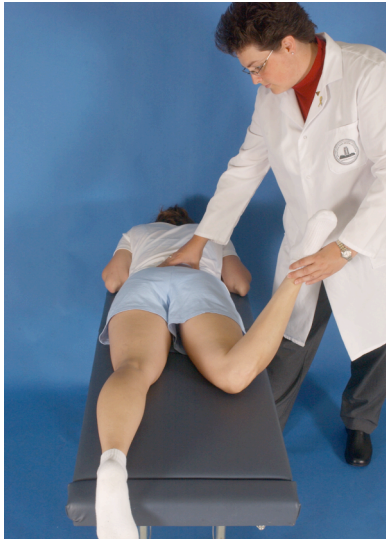

Action: Patient lies on the side with either SI joint up. The examiner compresses down over the SI joints. Note: avoid pressure over the femur head and greater trochanter.

Positive: Pain in either SI joint.

Indication: Sacroiliac lesion

Hibb's Test (Prone Gapping Test)



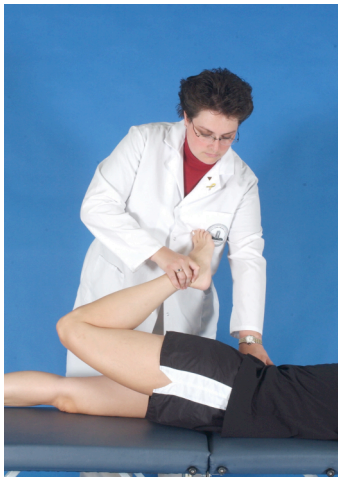Action: The patient is prone. The examiner stabilizes the affected SI with one hand and with the other hand holds the ankle and flexes the knee to ipsilateral buttock. Then the examiner moves the ankle laterally away from the buttock. This action internally rotates the femoral head stressing the acetabulum and externally rotates the ilium gapping the sacroiliac joint.

Positive: SI pain = SI lesion

Hip joint pain = hip joint pathology

Indication: Without pressure, this test stresses the SI joint and externally rotates the ilium. With pressure on hip internal rotation, the Piriformis muscle is stretched.

Gillis' Test



Action: The patient is prone. The examiner stands opposite the affected side and stabilizes the unaffected SI with the superior hand. Then hyperextends the affected thigh stressing the affected SI joint.

Positive: SI pain = SI lesion

Indication: Hyperextending the thigh stresses the SI joint indicative of a SI lesion.

Patrick's Test (FABER Sign)

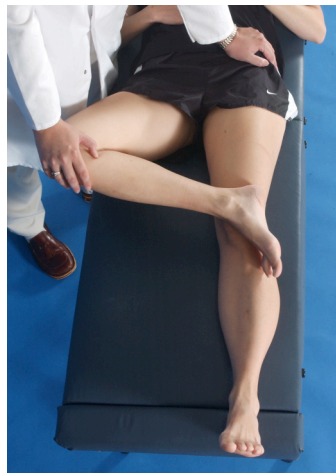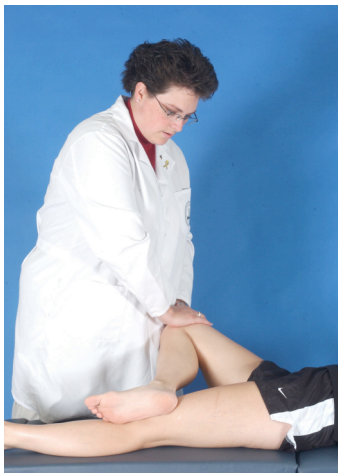Action: With the patient supine, the doctor places the heel of the affected leg over the opposite knee allowing the knee of the affected leg to drop to the table. Stabilize the pelvis with the opposite hand. This action results in the following position:

Flexion of the knee

ABduction of the hip

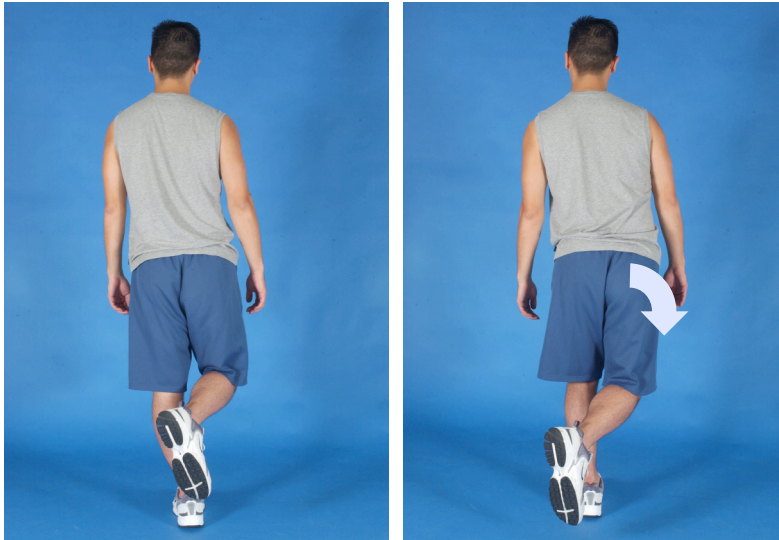Eternal **R**otation of the hip

The doctor then applies gentle pressure on the affected knee downward toward the table.



Positive: Pain in the hip.
Indication: Anterior hip joint lesion

Trendelenburg Test

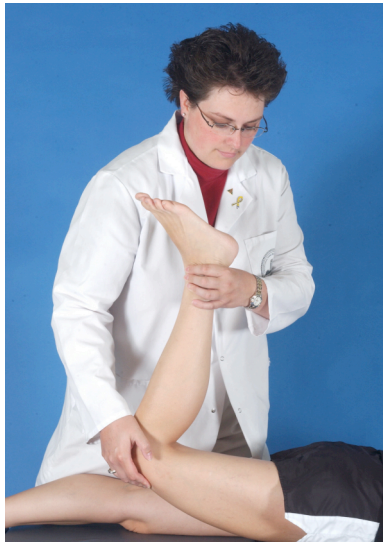
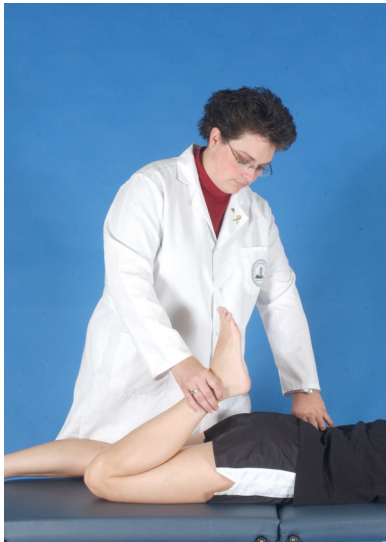
Action: Have the patient stand on the affected leg and then raise the unaffected leg off the floor. Have the patient hold the position for at least 30 seconds and watch for the hip to drop on side of flexed leg.

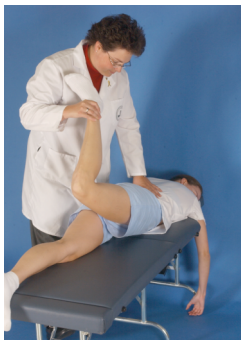Positive: The examiner observes for the pelvis to drop on the side of the leg being lifted OR the patient must hunch or lean over the leg he is standing on to maintain balance.

Indication: This indicates weak gluteus medius muscle opposite the side of hip flexion: weight bearing side.

Yeoman's Test



Action: With the patient prone. The examiner stabilizes the affected SI with one hand and with the other hand holds the ankle and flexes the heel to ipsilateral buttock. Then support the knee and hyperextend the hip. If the patient does not have knee problems, the procedure can be done in one motion.



Positive: Pain in SI joint.

Indication: This action puts stress on the anterior sacroiliac ligaments and is indicative of anterior SI sprain.

Neurologic Tests

- *Hoffman's Sign*
- *Babinski's Sign*
- *Heel to Shin Test*
- *Romberg's Sign*

Hoffman's Sign

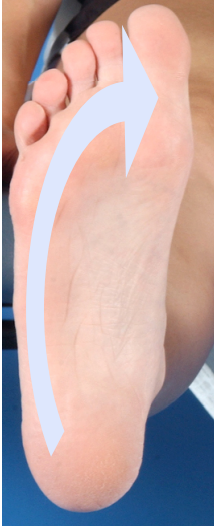

Action: Patient is seated with elbows bent and hands palm down. The examiner “flicks” the end of the patient’s middle finger and observes the thumb and fingers for motion.

Positive: The patient flexes his thumb and forefinger.

Indication: This sign is indicative of a hyperactive reflex and may be an indication of a pyramidal tract lesion (upper motor neuron lesion).

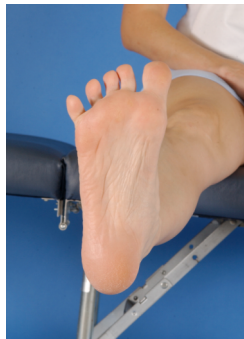Babinski's Sign



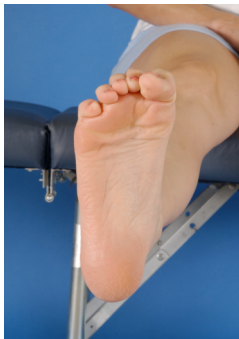Action: With the patient seated or supine on exam table with their feet at the end, stroke the sole of the foot with a blunt object like the end of a reflex hammer. Begin the stroke at the lateral aspect of the heel and move superior and medial to the first toe.

Positive: Dorsiflexion of the first toe and fanning of the other toes.

Indication: The sign is indicative of a pyramidal tract lesion (upper motor neuron lesion).

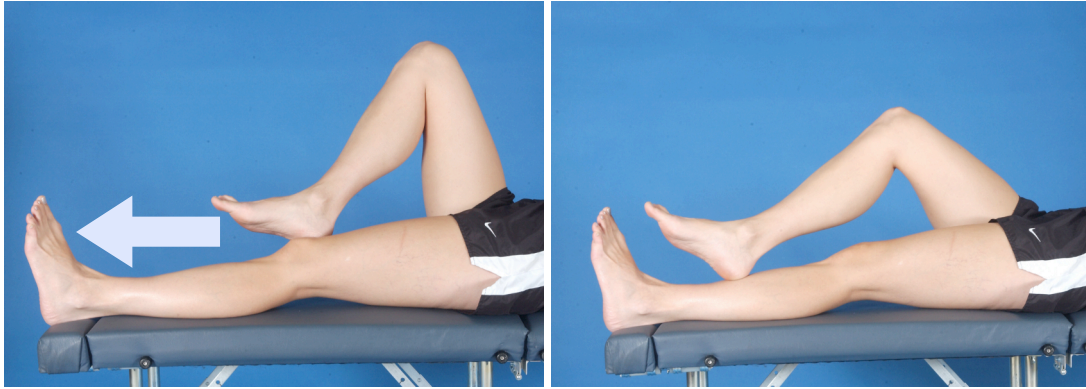


Positive



Normal

Heel to Shin Test (Heel to Knee Test)



Action: With the patient lying on table, ask the patient to place one foot on the opposite knee and slide the heel of the foot down the shin to the ankle.


Positive: This test is positive if the patient can not perform the procedure OR does so with a tremor or in a spastic manner.

Indication: Cerebellar dysfunction

Romberg's Sign



True sign: sways at ankles



False sign: sways at pelvis










Action: Patient stands with feet close together. Examiner stands behind or to the side for support but does not touch the patient. Ask the patient to close their eyes while staying in the same position. The examiner observes the patient looking for swaying.



Positive: With a true Romberg's sign, the patient will sway and lose balance from the ankles and will start to fall with the body in a straight stiff position. With a false sign or malingering sign, the patient will sway from the waist and hips and fall with a bent waist.

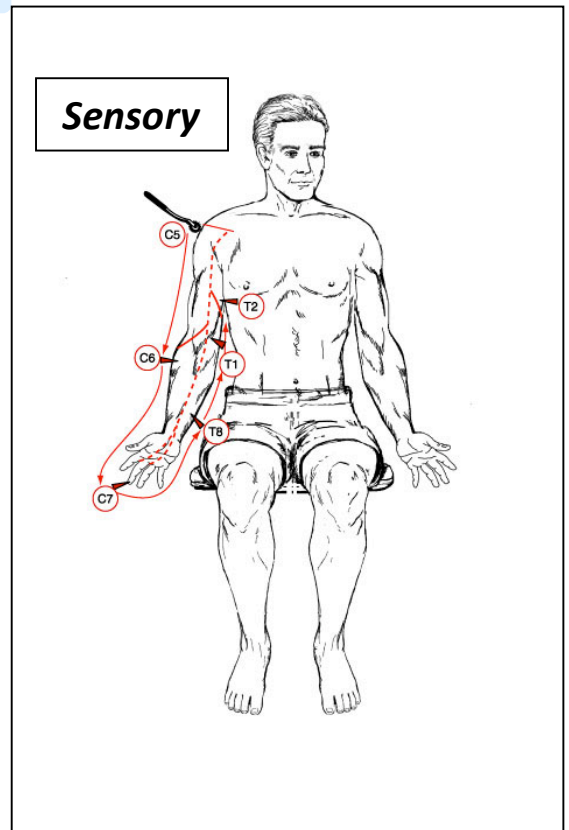
Indication: Romberg's sign tests the cerebellum/posterior column and results in a loss of proprioception. The patient with this problem will often present with an abnormal gait.

Note: Inner ear infections may mimic loss of balance.



Evaluation of Nerve Root Lesions – Upper Extremity

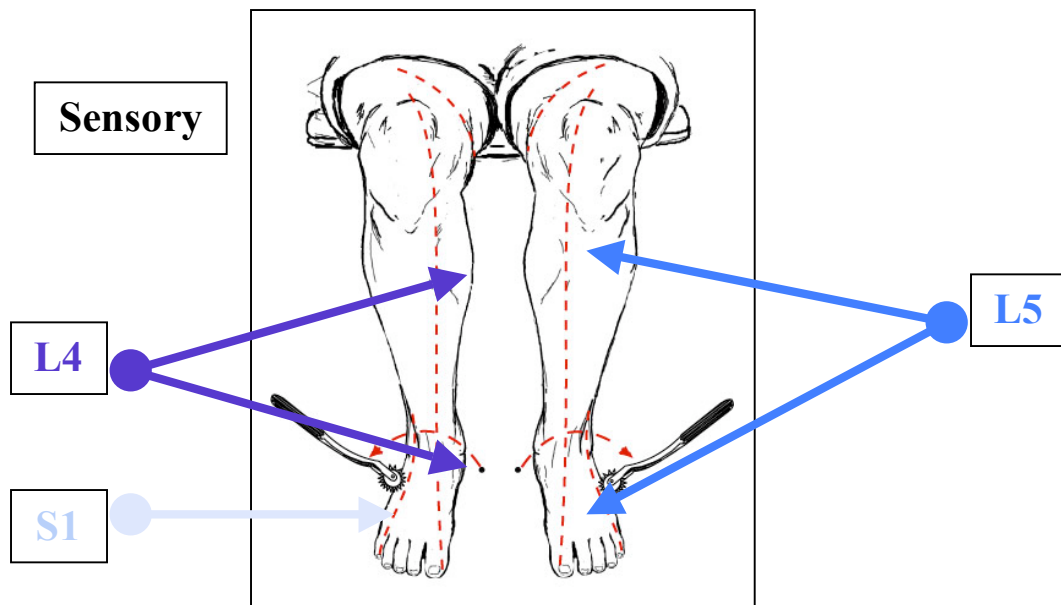
	Reflex	Motor		Sensation
<p>C5 C4-C5 disc</p>	<p>Biceps </p>	<p>Deltoid </p>	<p>Biceps </p>	<p>Lateral arm Axillary nerve</p>
<p>C6 C5-C6 disc</p>	<p>Brachioradialis </p>	<p>Biceps </p>	<p>Wrist Extensors </p>	<p>Lateral Forearm Musculocutaneous nerve</p>
<p>C7 C6-C7 disc</p>	<p>Triceps </p>	<p>Wrist Flexors </p>	<p>Finger Extensors </p>	<p>Middle finger</p>

	Motor	Sensation
<p>C8</p> <p>C7-T1 disc</p>	<p>Finger Flexors</p> 	<p>Medial forearm Ring & small finger</p> <p>Medial Antebranch of the Cutaneous Nerve</p>
<p>T1</p> <p>T1-T2 disc</p>	<p>Interossei</p> 	<p>Medial arm</p> <p>Medial branch of the Cutaneous Nerve</p>



Evaluation of Nerve Root Lesions – Lower Extremity

	Reflex	Motor	Sensation
L4 L3-L4 disc	Petellar 	Tibialis Anterior	Medial leg & Medial foot
L5 L4-L5 disc	Tibialis Posterior	Extensor hallucis longus	Lateral leg & Dorsum of foot
S1 L5-S1 disc	Achilles 	Peroneus longus & Peroneus brevis	Lateral foot



Key References

Bernstein J. *Musculoskeletal Medicine*. Rosemont: American Academy of Orthopedic Surgeons, 2003.

Cipriano JJ. *Regional Orthopaedic and Neurological Tests*. 3rd ed. Baltimore: Williams & Wilkins, 1997.

Donatelli RA. *Orthopaedic Physical Therapy*. 3rd ed. New York: Churchill Livingstone, 2001

Evens RC. *Illustrated Essentials in Orthopedic Physical Assessment*. St. Louis: Mosby, 1994:

Hoppenfeld S. *Orthopaedic Neurology: A Diagnostic Guide to Neurologic Levels*, Philadelphia: J.B. Lippincott Company, 1977:

Hoppenfeld S. *Physical Examination of the Spine and Extremities*. New York: Appleton Century-Crofts, 1976.

Magee DJ. *Orthopedic Physical Assessment*. 3rd ed.

Mazion JM. *Illustrated Reference Manual of Ortho/Neuro/Physil Clinical Diagnostic Techniques*. 4th ed. Arizona: Imperial Lithographics, 1980.

Snider RK. *Essentials of Musculoskeletal Care*. Rosemont: American Academy of Orthopaedic Surgeons, 1997.

References

1. Deville WL, van der Windt DA, Dzaferagic A, et al. The test of Lasègue: Systematic review of the accuracy in diagnosing herniated discs. *Spine* 2000; 25 (9):1140-1147.
2. Vroomen PCAJ, de Krom MCTFM, Knottnerus JA. Diagnostic value of history and physical examination in patients suspected of sciatica due to disc herniation: A systematic review. *J Neurology* 1999;264:899-906.
3. Walsh MJ. Evaluation of orthopedice testing of the low back for nonspecific lower back pain. *J Manipulative Physiol Ther* 1998;21(4):232-236.