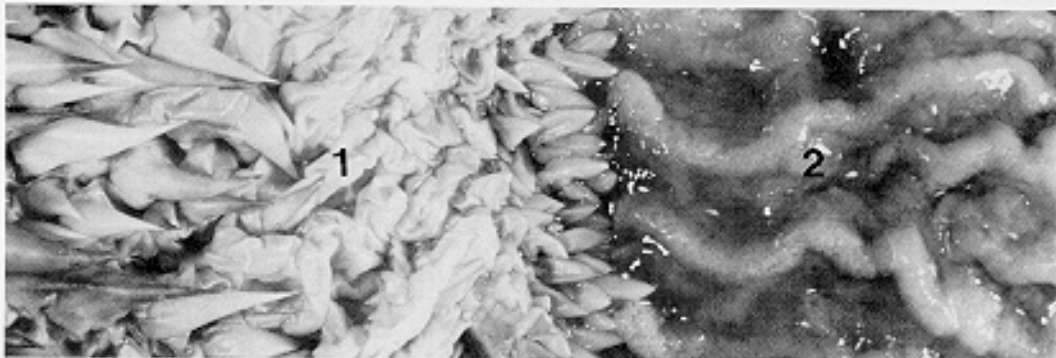

As the digestive tract has been removed and the lungs (2) have been inflated with air introduced through the trachea and bronchi (1), the lungs cover much of the medial lining of the carapace, extending from the base of the neck to the anterior tips of the kidneys (see fig. 22). In this specimen, there is no liver margin to the lungs as seen in the





Figure 19.