

# ANNEX 1

## Overview of Smallpox, Clinical Presentations, and Medical Care of Smallpox Patients

## **ANNEX 1 – Overview of Smallpox, Clinical Presentations, and Medical Care of Smallpox Patients**

This annex is intended to provide medical and public health personnel with information on smallpox and its etiological agent, variola virus.

### Introduction

Smallpox was declared globally eradicated by the WHO in 1980, following the last known naturally occurring case in Somalia in 1977. Routine vaccination against smallpox was discontinued in the United States in the early 1970s and worldwide in the early 1980s. Though protection by live vaccinia virus vaccination against smallpox is long lived and may prevent death from the illness in those who were vaccinated over two decades ago, all children and most adults are now considered susceptible to developing disease if exposed to variola virus. During the smallpox era, humans were the only known reservoirs of the virus but occasional laboratory acquired infections did occur.

### Transmission

Human-to-human transmission of variola virus normally occurs by inhalation of virus-containing large airborne droplets of saliva from an infected person with subsequent infection of the oropharyngeal region of the susceptible individual. Virus transmission occurs as the fever peaks and coincides with the onset of the skin rash. The rash occurs about 2-4 days after the onset of fever that begins 10-14 days following initial infection (range 7-19 days). Infectious virus particles are released by sloughing of oropharyngeal lesions, that continues for about a week. Patients are most infectious during this time. Transmissibility of the virus via large air-borne droplets decreases during the later stages of the disease as sloughing of the oropharyngeal lesions slows.

Transmission via contact with material from the smallpox pustules or crusted scabs can also occur, however, scabs are much less infectious than respiratory secretions presumably due to binding of the virions in the fibrin matrix of the scab. During the smallpox era, the disease had secondary household or close contact attack rates up to 80%. The higher attack rates were rare and were most often seen with hemorrhagic smallpox, an infrequent clinical manifestation that can be associated with higher transmission rates. Because of the lack of natural or vaccine-induced immunity currently, it is difficult to predict the exact attack rates in today's population.

### Pathogenesis

After smallpox virus infection of the respiratory tract or skin (percutaneous inoculation), the virus remains localized and replicates for up to three days. The

initial steps in viral dissemination in the body involve a primary viremia in which the virus moves to the draining lymph nodes, spleen and sometimes bone marrow. In smallpox the virus replicates further in lymphoid organs then migrates via the lymphatics to the bloodstream producing a secondary viremia followed by fever and toxemia. The secondary viremia carries the virus to the basal layer of the oropharyngeal region and epidermis by the 10th to 14th day after the initial infection. Just after the fever peaks, the development of oropharyngeal lesions begins (the enanthem), and is soon followed by the development of skin lesions (the exanthem). Lesions occur first on the mucous membranes of the mouth, tongue, pharynx, larynx, and upper part of the esophagus. Transmission by large-particle, airborne droplets is maximal at the time of the appearance of skin lesions. The disease can be spread by these large-particle, airborne droplets until the skin scabs fall off, however, droplet transmissibility decreases significantly after the 2<sup>nd</sup> week of disease as the oral lesions of the enanthem heal and viral titers in the saliva decrease.

The characteristic pathologic feature of smallpox is the skin rash. Initially, the capillaries in the dermal papillae dilate, followed by swelling of the endothelium and infiltration of lymphocytes and histiocytes (macrophages present in connective tissue). Polymorphonuclear leukocytes enter skin vesicles from the dermis to produce the pustular lesions. The pustular fluid eventually dries up as the disease disappears and the lesions become filled with granular tissue, which forms scabs consisting of degenerated epithelial cells and leukocytes. Virus particles can be present in large numbers in the scabs but are generally not highly infectious because they are enclosed within the hard, dry scab. Lesion scars or pockmarks are sequelae caused mainly by destruction of infected sebaceous glands and are most prominent on the face.

Cell-mediated immunity most likely plays the primary role in the recovery from smallpox infection. Antibodies play a secondary role in recovery, though they play a primary role in protecting against re-infection. The presence of viral neutralizing antibodies is considered a reasonable marker of immunity.

Small hemorrhages may occur in the heart and liver, but generally vital organs are not damaged enough to cause death. Death results from a profound toxemia, leading to respiratory and/or heart failure.

### Clinical Disease

Three clinical forms of smallpox; ordinary, flat, or hemorrhagic, may occur in unvaccinated individuals. An additional form, modified-type, is seen most often in individuals with previous vaccination. An early, vigorous cellular immune response in immune competent persons inhibits most virus growth. However, some virus survives the host immune defenses and produces ordinary smallpox, the most common form, in which characteristic skin lesions appear in a discrete centrifugal rash. Although the case-fatality rate varied with the different clinical

forms of smallpox, it was approximately 30% in unvaccinated individuals during the smallpox era.

**Ordinary smallpox (*Variola major*):**

The clinical course of smallpox begins with an asymptomatic incubation period, which may last from 12 to 14 days. After the incubation period, the first symptoms of the prodromal phase begin and include; fever, malaise, prostration, cough, headache, and backache. This phase lasts about 4 days. In pale-skinned subjects, the prodromal phase is sometimes accompanied by an erythematous rash, or rarely, a petechial rash. As the fever begins descending from its peak (38.5 to 40.5 °C), the eruptive phase begins with development of rash lesions. Lesions first appear on the buccal and pharyngeal mucosa, then the face, forearms, and hands. At this point the patient becomes infectious from viral shedding from the mucosal lesions. The rash spreads down, and within a day or so, the trunk and lower limbs are involved including the palms and soles. The back is typically more involved than the abdomen. Ultimately the distribution of the rash is centrifugal: most profuse on the face, more abundant on the forearms than the upper arms, on the lower legs than the thighs (Fig. 1). Prominent surfaces and areas exposed to irritation are more heavily involved by the rash, while protected surfaces, such as flexures and depressions are usually spared.

The eruptive lesions of the rash begin as macules, which are small, discolored skin patches. The macules progress to firm papules, then vesicles, which are usually multiloculated and soon become opaque and pustular. The vesicles are typically raised and firm to the touch, or “shotty,” as if filled with a lead bird shot. Approximately 8 to 9 days after onset of the rash, the pustules become pit-like and dimpled. Around day 14 the pustules dry up and become crusted. By about day 19 after infection most pustules begin to scab and separate, with those on the palms and soles separating last (Fig. 2).

Sequelae may follow recovery from smallpox. The most common are pockmarks, which may occur all over the body, but usually are most profuse on the face due to the large number of infected sebaceous glands. Blindness can occur occasionally, but generally occurs when malnutrition and/or an opportunistic bacterial infection are present. The virus itself does not cause corneal opacity. Encephalitis, osteomyelitis, stillbirths, and spontaneous abortions can also occur as complications of smallpox infection. Recovery results in prolonged immunity to re-infection with variola virus. Variola virus does not persist in the body after recovery.

When smallpox was endemic, the diagnosis of the vast majority of cases could be easily made from the distribution and evolution of the rash. Difficulties arose in outbreaks associated with importations into non-endemic areas, especially in cases of hemorrhagic smallpox (see below). These cases were sometimes confused with meningococcal septicemia or acute leukemia. In situations where smallpox was not expected, modified-type variola major or ordinary-type variola

minor were at times confused with chickenpox. In contrast to chickenpox, all lesions on any one part of the body are at the same stage of development with smallpox. Distribution of the rash in chickenpox is uniform or centripetal; there may be more lesions on the trunk than on face and distal limbs, and abdominal involvement is equivalent to back involvement. The rash of chickenpox manifests as uniloculated vesicles that do not umbilicate or dimple. The vesicles may also have irregular borders. There are usually no lesions on the palms and soles in chickenpox.

#### Modified-type smallpox:

This form of smallpox most often occurs in previously vaccinated individuals. The modification of this form of smallpox relates to the character and development of the rash with more rapid progression and resolution of the lesions. In general, the prodrome stage may still consist of severe headache, backache, and fever, and the duration may not be shortened. However, once the skin lesions appear, they generally evolve more quickly with crusting completed within 10 days. The lesions may be fewer in number and are more superficial than those seen in ordinary-type smallpox. Fever during the evolution of the rash is also usually absent during this modified clinical course.

#### Flat-type or malignant smallpox:

A deficient cellular immune response to variola virus is believed to be associated with a very rare manifestation of smallpox named flat-type smallpox. This form of disease is characterized by intense toxemia and occurs more frequently in children. The skin lesions develop slowly, become confluent, and remain flat and soft, never progressing to the pustular stage (Fig. 3). They have been described as “velvety” to the touch and sections of the skin may slough off. The majority of flat-type smallpox cases are fatal but if the patient survives, the lesions gradually disappear without forming scabs.

#### Hemorrhagic smallpox:

In patients with a highly compromised immune response, there is extensive multiplication of the virus in the spleen and bone marrow to produce a rare condition known as hemorrhagic smallpox. Megakaryocyte destruction in the bone marrow is believed to lead to defective blood coagulation. The rare hemorrhagic-type smallpox is associated with petechiae (minute hemorrhagic spots) in the skin and bleeding from the conjunctiva and mucous membranes (Fig. 4). A high level of viremia is maintained in this type of smallpox as opposed to the other clinical forms of the disease. Illness with severe prodromal symptoms that include high fever, severe headache, and abdominal pain begins after a shortened incubation period. Soon after illness onset, a dusky erythema develops which is followed by petechiae and skin and mucosal hemorrhages. Death usually occurs by the 5<sup>th</sup> or 6<sup>th</sup> day of rash, often before lesions more characteristic for smallpox rash develop. The two forms of hemorrhagic-type smallpox, early and late, are differentiated by the occurrence of hemorrhages after the appearance of the rash in the late form. Hemorrhagic-type smallpox occurs among all ages and

in both sexes but is more common in adults. Pregnant women also seem to be more susceptible to developing this form of smallpox than other adults. The underlying molecular biologic reasons for the toxemia and other effects are unclear.

#### Laboratory Diagnosis:

The usual preliminary method of diagnosis of orthopoxvirus infections is by observing the characteristic brick-shaped virions in negatively stained preparations of vesiculopustular fluid or homogenates of scab material viewed by electron microscopy. Species diagnosis was formerly made by observation of the morphology of pocks on the chorioallantoic membrane (CAM) three days after infection of 12-day-old chick embryos. However, a variety of relatively rapid PCR methods are now available at CDC and USAMRIID for genus and species identification. Orthopoxviruses are very closely related antigenically, thus genus-specific identification can be accomplished using hyperimmune antiserum against any species within the genus, most commonly vaccinia virus.

#### Treatment:

There are no proven treatments for clinical smallpox; medical care is generally supportive. Vaccination can prevent or lessen the severity of disease if given within 2-3 days of the initial exposure and decreases symptoms if given within the first week of exposure. Dehydration and electrolyte abnormalities can occur during the vesicular and pustular rash stages. Occasionally, bacterial superinfections may also occur and should be treated with appropriate antibiotic therapy.

*Multiple studies of antivirals during the smallpox eradication failed to show significant benefit in the treatment of smallpox. Evaluation of modern day antivirals at CDC is ongoing. One current antiviral, Cidofovir, has shown some in-vitro and in-vivo (animal studies) activity against orthopoxviruses. However, its effectiveness for treating clinical smallpox or vaccine adverse events is not known. This medication is labeled for the treatment of CMV retinitis and has been associated with renal failure. Were an outbreak of smallpox to occur, this medication would be made available through the CDC or NIH under an Investigational New Drug (IND) protocol for the potential treatment of smallpox or vaccine adverse events.*

#### Vaccination

Vaccination administered within 3-4 days postexposure can prevent disease or severe illness caused by variola virus. Presently, smallpox (vaccinia) vaccine is available in the U.S. only through the CDC. Vaccinia human immunoglobulin (VIG), which is licensed to treat certain postvaccinia-vaccination adverse effects, is also only available through the CDC. Vaccine administration and contraindications are included in the Guide B -Vaccination Guidelines located elsewhere in this manual.

Complications of vaccination are rare after primary vaccination and are even less likely in previously vaccinated persons. However, the following complications to vaccination can occur (see also Vaccination Complications in Guide B – Vaccination Guidelines):

- (a) ***Progressive vaccinia*** (*vaccinia gangrenosa*) can occur in persons with deficiencies of the cell-mediated immune system. Congenital or acquired immunodeficiency diseases or other forms of immunosuppression (e.g., by medications such as steroids or chemotherapeutics) are contraindications for vaccination. In a national survey conducted by CDC in the 1960s, five cases (including two deaths) of progressive vaccinia occurred among 6 million primary vaccinees (0.83 cases/million) and 6 cases (including two deaths) occurred among 8.6 million persons revaccinated with the licensed smallpox vaccines containing the New York Board of Health (NYBH) strain (0.7 cases/million). This strain was the only vaccine strain used in the United States at the time.
- (b) ***Eczema vaccinatum*** may occur in persons who suffer from eczema (either from primary vaccination or contact with a person who has a non-scabbed vaccination site that contains live vaccinia virus). Active eczema or a history of eczema is a contraindication to vaccination in non-contacts. However, the risk and seriousness of developing smallpox verses the risk of developing eczema vaccinatum should be considered in a true smallpox contact who has eczema or a history of eczema. In the national survey there were 66 cases (no deaths) among 14.5 million vaccinees (4.6 cases/million) and 60 cases (one death) among their several million contacts. Vaccination under cover of VIG or treatment of established cases with VIG diminished the severity of the disease.
- (c) ***Generalized vaccinia*** comprises a generalized skin rash, sometimes covering the whole body, that may occur 6 to 9 days post-vaccination. The course of the individual lesions resembles that of the lesion at the inoculation site, however, if the rash is profuse the lesions may vary greatly in size. Generalized vaccinia is not associated with the presence of immunodeficiency, and therefore has a good prognosis. In general, this complication of vaccination does not require the administration of VIG severe. In the national survey there were 141 cases (no deaths) among 14.5 million vaccinees (9.7 cases/million), and 2 cases (no deaths) among their several million contacts.
- (d) ***Post-vaccination encephalitis*** is an unpredictable complication that only occurs in primary vaccinees. The frequency of its occurrence differed widely from country to country. The incidence of encephalitis, which could not be predicted on the basis of pre-existing disease in the vaccinee, was influenced by the strain of vaccinia virus used for vaccination and was lower with the NYBH strain in the United States than with other strains used in Europe

before the mid-1960s. Infants age <1 year, occasionally developed a generalized encephalopathy associated with a high viremia. There were four cases with three deaths from this complication reported among the 614,000 vaccinees in this age group. In older persons, the principal lesions by pathology resembled those of other postinfectious encephalitides, perivenular inflammation, and demyelination. In the national survey, 12 cases with one death occurred among some 13 million vaccinees.

(e) ***Accidental infection*** of some part of the body distant from the inoculation site was a primary complication in the national survey and was probably much more common than the 156 cases (no deaths) among the 14 million vaccinees reported in that survey. Over the period 1963 to 1968, ocular vaccinia occurred in 348 persons (including 259 vaccinees and 66 contacts). In 22 of these cases, 11 persons suffered corneal complications, resulting in residual visual defects.

(f) ***Contact infection***. In the survey it was difficult to determine the incidence of contact infection; such cases were rarely severe unless the contact was suffering from eczema or an immunodeficiency disease.

*Additional descriptions of postvaccination complications along with recommendations for treatment of these complications are included in Guide B – Vaccination Guidelines.*



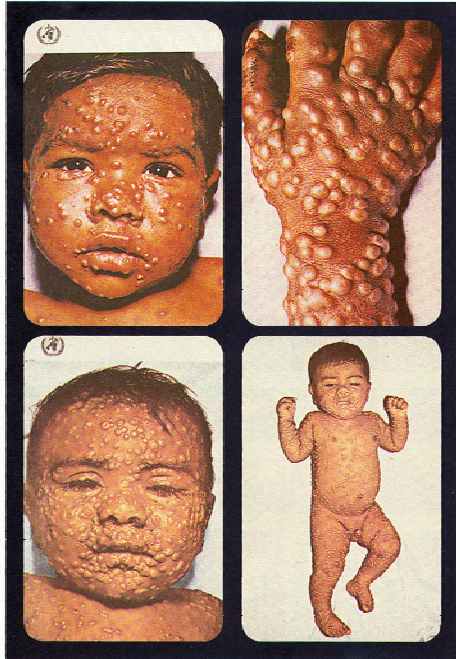
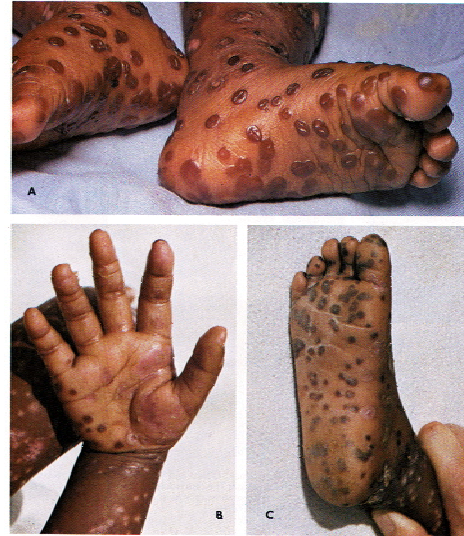
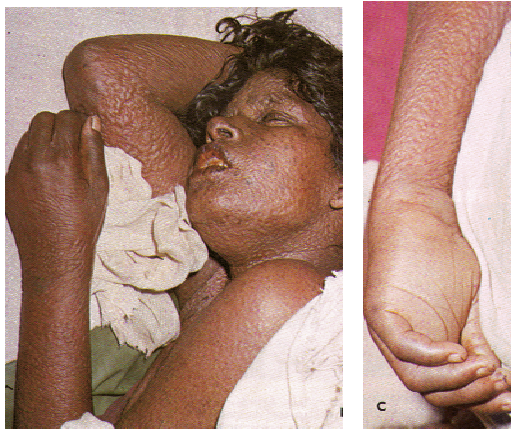
Plate 10.11. The front and back of two versions of the shirt-pocket-size WHO smallpox recognition card produced in 1972. They were first used in India, and tens of thousands were eventually distributed to search workers throughout the subcontinent. The first version (upper pictures) was selected to portray a patient with relatively mild smallpox; it is a reduced version of the larger card shown in Plates 10.29 and 10.30.

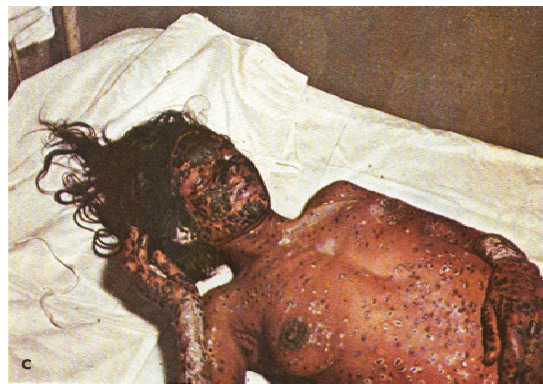**Fig. 1** – The front and back of two versions of the shirt-pocket-size WHO smallpox recognition card produced in 1972. Upper pictures represent a patient with relatively mild smallpox while the bottom version represented a patient with more severe disease. Note the prominence of pustules on the face and extremities and the similar stage of development of the lesions. (From Fenner F, Henderson DA, Arita I, Ježek Z, Ladnyi ID. *Smallpox and its eradication*. Geneva, Switzerland: World Health Organization; 1988.)



**Fig. 2** – Upper picture: lesions on the sole on 14<sup>th</sup> day of rash. Lower picture: lesions on palm and sole on 21<sup>st</sup> day of rash. Note, scabs on other visible areas of arm and leg have separated, however, lesions on palms and soles remained as dark disc-like scabs. (From Fenner F, Henderson DA, Arita I, Ježek Z, Ladnyi ID. *Smallpox and its eradication*. Geneva, Switzerland: World Health Organization; 1988.)



**Fig. 3** – Flat-type smallpox: Unvaccinated, young woman on the 6<sup>th</sup> day of rash; Note severe toxemia and extensive flat pustules (From Fenner F, Henderson DA, Arita I, Ježek Z, Ladnyi ID. *Smallpox and its eradication*. Geneva, Switzerland: World Health Organization; 1988.)



**Fig. 4** – Late hemorrhagic-type smallpox in a young woman, showing bleeding in base of pustules and development of a general hemorrhagic diathesis late in disease (From Herrlich A, Mayr A, Munz E, Rodenwaldt E. (1967). *Die Pocken; Erreger, Epidemiologie und klinisches Bild*, 2<sup>nd</sup> ed., Stuttgart, Thieme.)