

MASS STRANDING OF WEDGE-TAILED SHEARWATER CHICKS IN HAWAII

Thierry M. Work^{1,2} and Robert A. Rameyer¹

¹ U.S. Geological Survey, Biological Resources Division, National Wildlife Health Center, Honolulu Field Station, P.O. Box 50167, Honolulu, Hawaii 96850, USA

² Corresponding author (e-mail: thierry_work@usgs.gov)

ABSTRACT: Unusual numbers of wedge-tailed shearwater (*Puffinus pacificus*) chicks stranded on Oahu (Hawaii, USA) in 1994. Compared to healthy wedge-tailed shearwater (WTSW) chicks, stranded chicks were underweight, dehydrated, leukopenic, lymphopenic, eosinopenic, and heterophilic; some birds were toxemic and septic. Stranded chicks also were hypoglycemic and had elevated aspartate amino transferase levels. Most chicks apparently died from emaciation, dehydration, or bacteremia. Because many birds with bacteremia also had severe necrosis of the gastrointestinal (GI) mucosa associated with bacteria, we suspect the GI tract to be the source of disseminated bacterial infection. The identity of the bacteria was not confirmed. The daily number of chicks stranded was significantly related to average wind speeds, and the mortality coincided with the fledging period for WTSW. Strong southeasterly winds were a distinguishing meteorologic factor in 1994 and contributed to the distribution of stranded chicks on Oahu. More objective data on WTSW demographics would enhance future efforts to determine predisposing causes of WTSW wrecks and their effects on seabird colonies.

Key words: Hematology, mortality, pathology, *Puffinus pacificus*, serum chemistry, wedge-tailed shearwater.

INTRODUCTION

Mass strandings (wrecks) of seabirds involve large numbers of seabirds blowing or washing up on shore alive and dead. Wrecks in temperate zones have been documented in both hemispheres (Underwood and Stowe, 1984; Ryan and Avery, 1987). Wrecks of seabirds usually involve immatures and are attributed to starvation or severe weather (Hayashi, 1983; Oka et al., 1987; Jury, 1991; Piatt and Van Pelt, 1997). Toxicants (Scott et al., 1975) or biotoxins (Coulson et al., 1968) have occasionally been implicated, but actual confirmation of such causes are relatively rare.

Investigations of wrecks of seabirds usually emphasize the geographic extent of the mortality, beach counts of carcasses, age and gender distribution, and estimation of total mortalities (Bourne, 1976; Hayashi, 1983; Underwood and Stowe, 1984; Oka and Maruyama, 1986). Sometimes, body condition of stranded birds is assessed (Hope-Jones et al., 1984) or organs are analyzed for toxicants (Lloyd et al., 1974); however, complete clinical and pathologic examinations of specimens are less common (Nishigai et al., 1981; Jau-

niaux et al., 1996; Piatt and Van Pelt, 1997) in spite of guidelines that exist on the topic (Pionneau, 1987).

Wrecks have been documented for several species of shearwaters (Nishigai et al., 1981; Hayashi, 1983; Oka and Maruyama, 1986), but not wedge-tailed shearwaters (*Puffinus pacificus*). Powlesland and Pickard (1992) reported an unusual finding of 17 wedge-tailed shearwaters on the coast of New Zealand, but offered no additional information on why these birds stranded or circumstances surrounding the event. We report a wreck of WTSW on the island of Oahu (Hawaii, USA). To gain a better understanding of circumstances associated with such wrecks, we examined meteorology and available demographics, clinical signs, clinical, and microscopic pathology.

MATERIALS AND METHODS

Demographics

In late October 1994, large numbers of WTSW chicks stranded along roads and in yards on Oahu (Hawaii, USA; 21°15'–21°45'N to 158°15'–157°30'W). Stranded birds were reported to state and federal wildlife agencies and taken to a zoological park (Sea Life Park, Waimanalo, Hawaii) where date and location of stranding was recorded for each bird. While at

the park, birds were fed fish and released when possible. Because Sea Life Park (SLP) was the only facility that routinely admits stranded seabirds on Oahu, we could get a crude index of the magnitude of this stranding relative to the previous 2 yr by examining admission records from the park for 1992 and 1993. To assess geographic distribution of the wreck, we mapped out stranding locations of individual birds.

Laboratory diagnostics

We bled and weighed 69 live WTSW upon admission to SLP and evaluated hematology and serum chemistry (Work, 1996). Thirteen of these animals died an average of less than one day later (0–6 days). These 13 birds, plus 233 birds that died in captivity or upon arrival to SLP were individually wrapped in plastic bags, stored at 4 C, and necropsied within 24 hr of death. Necropsies entailed a complete external and internal examination. Each bird was weighed to the nearest 10 g with a spring scale (Pesola, Bern, Switzerland), and gender determined either on gross or histologic examination of gonads. Birds were classified as chicks if they had tufts of down on the plumage, large bursa on gross examination, or immature gonads on histological examination. We classified body condition as good (ample abdominal and subcutaneous fat, adequate breast muscles), fair (moderate fat, moderate breast muscle atrophy), or poor (little to no fat, severely atrophied breast muscles). Skeletal muscle, liver, kidney, spleen, adrenal, lung, brain, heart, gonad, small and large intestines, esophagus, and proventriculus were fixed in 10% neutral buffered formalin, sectioned at 5 μ m and stained with hematoxylin and eosin. Grams, Grocott's silver, and alcian blue-PAS were used to characterize bacteria, tissue-associated fungi, and sulfated mucosubstances, respectively (Prophet et al., 1992).

For bacteriology, swabs of heart blood or liver were streaked on 5% sheep blood and McConkey agar (Remel, Lenexa, Kansas USA) immediately after collection. Plates were allowed to incubate at 37 C for 48 hr, and individual colonies were subcultured in trypticase soy agar (Remel) and sent to the National Wildlife Health Center (Madison, Wisconsin, USA) for identification using API 20E, API NFP, and API Coryne strips (bioMerieux Vitek, Hazelwood, Missouri, USA).

Birds were placed into diagnostic categories according to the most severe gross and microscopic lesion. Birds dying from trauma included those with gross evidence of broken bones, severe bruising, and frank internal hemorrhage; bacteremic birds included those for which we

had microbiologic (pure culture from heart or liver) or microscopic evidence of disseminated bacterial infection; uncomplicated emaciation included birds with no evidence of infectious disease, lack of body fat, and microscopic evidence of hepatocellular atrophy, severe lymphoid depletion, or pancreatic zymogen granule depletion; dehydration included birds with microscopic evidence of moderate to severe nephrosis in absence of bacterial infection or trauma; and the remaining birds for which cause of death was uncertain were classified as unknown.

Climate

To assess the role of climate, we obtained the following data from the Kaneohe Marine Corps Base Hawaii Weather Station (NOAA—National Weather Service, Kaneohe, Hawaii, USA): Daily average wind speed (km/hr), peak wind speed (km/hr), and wind direction. Data were summarized for October–December, which is fledging season for WTSW on Oahu (Harrison, 1990).

Statistical analysis

From admission records at SLP, we calculated how many days birds were captive prior to death. Simple linear regression was used to assess the relationship between diagnostic category and duration in days of captivity. Multiple linear regression was used to assess the relationship between daily average and peak wind speed and numbers of birds recovered. Multiple comparison were done using one-way ANOVA (Daniel, 1987; Sigmapstat, San Rafael, California USA). Hematologic parameters of stranded and healthy chicks were compared as described in Work (1996). Alpha for all comparisons was 0.05.

RESULTS

Demographics and clinical signs

The number of WTSW submitted to Sea Life Park in 1994 was >10 times the total in either 1992 or 1993. Mortality started on the 44th week (October 30) of 1994, peaked on the 49th week, abated soon thereafter, and coincided with fledging period for WTSW on Oahu (Harrison, 1990) (Fig. 1). Birds were found mainly on southeastern Oahu with decreasing numbers towards the northwest (Fig. 2). Stranded birds were in poor condition and were weak but alert. Often, stranded birds appeared hypotensive and hemoconcentrated.

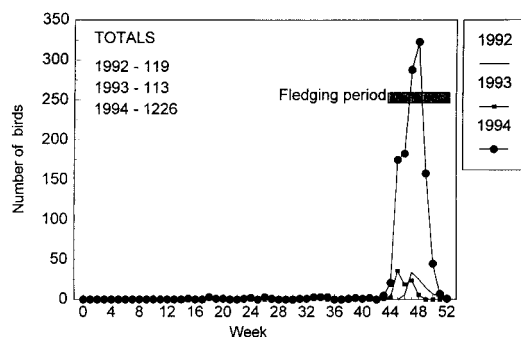


FIGURE 1. Weekly tally of wedge-tailed shearwaters submitted to Sea Life Park (Oahu Hawaii, USA) during 1992–94.

trated based on difficulty in visualizing peripheral veins and having overly viscous blood, respectively.

Laboratory investigations

Stranded chicks had significantly lower weight, lymphocyte, eosinophil and total white blood cell counts and glucose and albumin concentrations and significantly greater hematocrit, total solids, heterophil counts and aspartate amino transferase (AST) concentrations than healthy chicks (Work, 1996) sampled two months prior to fledging (Table 1). Of the 69 live birds that were bled, toxic heterophils, characterized by shrinkage of the nucleus, and clumped, rounded eosinophilic granules in a basophilic cytoplasm (Hawkey and Dennett, 1989) were observed in 24% of birds; 7% also had bacteria within cytoplasm of thrombocytes.

Of 13 birds that were bled while alive and subsequently necropsied, seven died from bacteremia, 2 from dehydration, 1 each from emaciation and trauma and the remainder were unknown. Intracytoplasmic bacteria in peripheral blood thrombocytes were seen only in birds (54%) dying from bacteremia.

Of birds necropsied ($n = 246$), including the 13 mentioned above, all were in poor body condition and had extensive fecal pasting on abdominal and breast feathers. Most (44%) of birds died from bacteremia, and diagnostic category was not

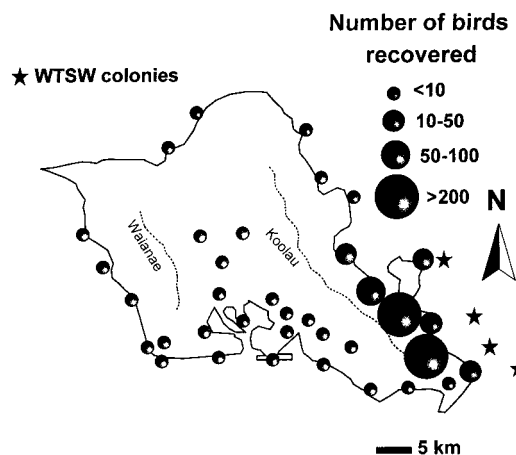


FIGURE 2. Distribution of wedge-tailed shearwater chicks stranded on Oahu in 1994.

significantly related to time in captivity prior to death. Emaciated birds weighed significantly ($H_3 = 34.7, P < 0.01$) less than bacteremic or dehydrated birds (Table 2).

Gross lesions in bacteremic birds were most often seen in the kidney, gastrointestinal tract, heart and liver. Bacteremic birds had pale tan kidneys with multiple pale spots or reticulations. The intestines had a thickened wall with petechiae, a rugose mucosa, and were distended with gas, urates or inspissated feces. The heart had numerous pale areas often accompanied by hemorrhage. Pale foci or amorphous areas in the liver were common as were petechiae in the adrenals. Many birds had marked vascular engorgement of the brain. Less commonly encountered lesions included soft tan nodules associated with hemorrhage in the lungs, subcutaneous edema of the neck and petechiae in the abdominal fat and muscle.

Gross lesions in dehydrated birds resembled those of bacteremic birds except that subcutaneous edema of the neck and shoulders was more common as was vascular engorgement of the brain, often giving the organ a purple hue. While intestines were often distended with urates, we did not see the mucosal thickening and widespread petechiae as in bacteremic

TABLE 1. Weights, hematology, and serum chemistry of stranded and healthy (n = 45) wedge-tailed shearwater chicks, 1994.

	Stranded chicks			Healthy chicks (Work, 1996)			
	Mean	SD	Range	n	Mean	SD	Range
Weight (g)	270 ^a	50	170-390	69	470	50	365-590
Hematology							
Hematocrit (%)	43 ^a	6	31-54	68	37	3	30-43
Total solids (g/dl)	4.2 ^a	0.8	2.2-6.2	68	3.7	0.3	3-4.4
Lymphocyte (103/μl)	5.36 ^a	4.32	0.45-21.2	67	26.04	13.49	7.61-70.05
Heterophil (103/μl)	8.38 ^a	5.38	2.08-32.89	67	2.49	0.95	0.91-5.05
Monocyte (103/μl)	0.36	0.61	0-3.36	67	0.15	0.19	0-0.77
Eosinophil (103/μl)	0.04 ^a	0.09	0-0.58	67	0.74	2.21	0-14.81
Basophil (103/μl)	0.15	0.14	0-0.48	67	0.34	0.44	0-2.68
Total white cells (103/μl)	14.29 ^a	8.41	3.02-54.37	67	29.75	13.93	9.45-76.56
Chemistry							
Glucose (mg/dl)	133 ^a	44	22-248	52	202	23	145-255
Calcium (mg/dl)	11.0	1.9	5.1-14	52	11.8	1.2	7.8-13.8
Phosphorus (mg/dl)	9.6	3.4	4.2-18.5	52	8.8	2.0	5.2-13.9
Uric acid (mg/dl)	7.3	5.5	1.4-24.7	53	6.2	4.3	1.2-15.8
Protein (g/dl)	3.2	0.6	2.1-4.4	51	3.2	0.4	2.6-4.2
Albumin (g/dl)	1.5 ^a	0.2	1.1-2	51	1.7	0.2	1.4-2.2
Globulin (g/dl)	1.6	0.4	1-2.4	51	1.5	0.2	1.2-2
Aspartate amino transferase (IU/L)	366 ^a	231	169-1,740	51	153	41	95-274
Creatinine phosphokinase (IU/L)	1,091	1,142	65-6,000	50	899	899	147-4,473

^a Means between healthy and stranded chicks are significantly different (P < 0.003).

TABLE 2. Physical characters and numbers of days in captivity for wedge-tailed shearwater chicks on Oahu in 1994 by diagnostic category.

	Bacteremia	Emaciation	Dehydration	Trauma
Number	108	35	75	13
Sex				
Female	60	13	39	6
Male	37	17	26	3
Unknown	11	5	10	4
Condition				
Good	21	0	13	6
Fair	17	0	19	3
Poor	70	35	43	4
Mean weight (g)	221	187 ^a	208	282 ^b
SD	44	22	32	54
Range	145–335	150–250	160–305	190–365
Number	108	34	75	13
Mean days captive	3.3	2	2.8	2.4
Standard deviation	1.9	2	2	3.2
Range	0–8	0–7	0–8	0–11

^a Numbers within a row with different letters are significantly different ($P < 0.05$).

birds. A few birds had numerous deposits of urates on the serosa of multiple organs.

The most common microscopic lesion in bacteremia birds was moderate to severe, multifocal acute necrosis associated with tiny gram negative rods which was most often seen in the liver, spleen, small intestinal mucosa and heart. In most cases, the necrosis in the intestines diffusely encompassed the mucosa and extended into the underlying muscularis. Inflammation and hemorrhage were occasionally associated with the necrosis. Intravascular bacteria and macrophages distended with bacteria were found in all organs examined but most commonly in the intestines, kidney, heart, liver, and adrenal. Moderate to severe atrophy of the spleen, liver, pancreas, and heart were common. Nephrosis was common and characterized by shrinkage and hypereosinophilia of tubular cells, distortion of tubular cells by variably sized intracytoplasmic vacuoles, or dilation of collecting ducts with cell debris, urates, or mucus concretions (Table 3).

Atrophy of the liver, spleen, and pancreas were the most common microscopic lesions in birds with dehydration followed by nephrosis. In some cases, deposits of blue-

grey feathery material or deposition of stellate crystals, compatible with urates (Ridell, 1987), surrounded by necrotic tissues was seen in the lung and heart. Acute mild to severe myocardial, hepatic and adrenal necrosis with little to no inflammation were prominent as was interrenal cell hypertrophy and hyperplasia. Pulmonary mycosis, characterized by septated hyphae accompanied by necrosis and chronic inflammation, was seen only in birds with dehydration. We did not culture the fungus (Table 3).

Multi-organ atrophy was the most common lesion in birds with emaciation followed by mild nephrosis, moderate to severe adrenal hypertrophy and mild to moderate acute myocardial and hepatic necrosis with little to no associated inflammation. Nephrosis was the most common lesion in birds with trauma followed by acute to subacute moderate periportal hepatitis or enteritis and splenic reticulo-endothelial hyperplasia (Table 3).

Seven of 31 cultures from bacteremic birds consisted of pure growth of *Escherichia coli* (6) or *Erysipelothrix rhusiopathiae* (1). Remaining cultures consisted of mixed growth of *E. coli*, *E. rhusiopathiae*,

TABLE 3. Percent of total microscopic lesions observed in stranded wedge-tailed shearwater chicks by diagnostic category.

	Bacteremia	Emaciation	Dehydration	Trauma
<i>n</i>	589	113	285	38
Multi-organ				
-Atrophy	14	53	32	10
-Hemorrhage	2	4	2	5
-Inflammation	1	4	0	15
-Intravascular bacteria	22	0	0	0
Multi-organ necrosis	8	8	11	8
-with hemorrhage	2	3	2	8
-with inflammation	3	0	2	5
-with mineralization	4	1	4	3
-with urates	1	0	1	0
-with bacteria	25	0	0	3
Nephrosis	12	14	29	18
Glomerulopathy	1	1	1	0
Adrenal hypertrophy	3	11	9	3
Splenic MPS cell hyperplasia	1	0	3	11
Pulmonary mycosis	0	0	2	0
Vacuolar hepatopathy	1	1	2	11

Proteus sp., *Vibrio alginolyticus*, *Enterococcus* sp., *Morganella morganii*, *Acinetobacter* sp., *Xanthomonas* sp., *Serratia marcescens*, *Edwardsiella* sp., and *P. multocida*. One of three cultures from birds with trauma revealed pure growth of *Proteus* sp., one of one culture from an emaciated bird revealed no growth and two of 13 cultures from a bird with nephrosis revealed mixed growth of *Citrobacter freundii*, *E. coli*, *Proteus* sp., *Xanthomonas* sp., or *Bacillus* sp.

Climate

Number of birds stranded daily was significantly related to average ($R_{50} = 0.38$, $P = 0.007$) wind speed. There was no significant difference in mean peak or average wind speeds between years. There were 20 days in 1994 where winds originated from the southeast (90–135°) vs. 3 and 8 days for 1993 and 1992, respectively (Fig. 3).

DISCUSSION

We suspect that winds from the southeast blew chicks from offshore colonies onto southeastern Oahu and funneled them between the Koolau and Waiiaie mountain ranges. This explains the high numbers of stranded birds on southeastern Oahu with a progressive decrease towards the northwest. Observer bias would not explain the distribution of birds because there are several large populated areas in central and western Oahu where, presumably, stranded birds would have been reported. Coincidence of stranding with the fledging period for WTSW explains the predominance of chicks in our necropsy survey. The number of days with winds

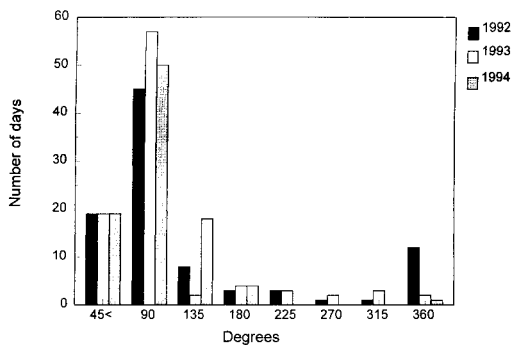


FIGURE 3. Number of days versus resultant wind direction at Oahu in 1994 during a wedge-tailed shearwater chick mortality event.

from the southeast in 1992 and 1993 were half of those in 1994 suggesting that if similar WTSW mortality occurred in those years, it could have been missed because northeast (0–90°) winds presumably blew birds out to sea.

Severe weather associated with seabird wrecks has been noted in several seabird species (Jury, 1991) including shearwaters (Hayashi, 1983). Oka et al. (1987) implied that inadequate food resources caused adults to abandon chicks prematurely leading to mortality and stranding of chicks. Harris and Wanless (1996) suggested that strong winds made prey harder to locate thus accounting for a wreck of Guillemots (*Uria aalga*) and shags (*Phalacrocorax aristotelis*). Lack of demographic data prior to the wreck preclude our concluding whether the poor condition of stranded chicks was the result of insufficient feeding by adults or poor availability of prey for newly fledged chicks due to strong winds.

Clinical presentation and weights indicated that stranded shearwaters were dehydrated and in poor body condition. Hematocrit and estimated total solids confirmed the dehydration (Quesenberry and Hillyer, 1994) while stress and inflammation secondary to bacterial infection contributed to heterophilia (Campbell, 1994). Based on clinical and pathologic findings, toxic heterophils in peripheral circulation were a response to bacterial toxemia (Campbell, 1994). Given the poor body condition of stranded birds, bone marrow exhaustion secondary to loss of nutritional reserves was a likely cause of leukopenia and lymphopenia (Campbell, 1994). Alternatively, excessive circulation of stress hormones such as cortisol could also cause lymphopenia (Campbell, 1994).

Poor body condition could explain the hypoglycemia in stranded birds (Hochleithner, 1994) while sepsis is another likely cause (Leifer, 1986). Prolonged contact of serum with red cells was probably not responsible for hypoglycemia since blood for healthy (Work, 1996) and stranded chicks was handled in an identical manner

(Hochleithner, 1994). Poor body condition and liver atrophy accounted for hypoalbuminemia although protein losing enteropathies or renal disease also are possible (Hochleithner, 1994). Increased AST in birds can indicate liver or muscle damage (Hochleithner, 1994), and would be compatible with pathologic findings of hepatocellular and myocardial necrosis in stranded birds that died.

Presence of intracytoplasmic bacteria in peripheral blood thrombocytes and macrophages in live and dead birds along with multifocal necrosis of multiple organs associated with bacteria was indicative of sepsis (Cheville, 1988; Randall and Reece, 1996). That many birds had severe necrosis of small intestinal mucosa suggested this was the primary source of bacterial infection; this is an accepted mechanism for establishment of systemic bacterial disease in birds (Barnes and Gross, 1997). Other than the causative bacteria being gram negative, however, their identity remains uncertain. Although some of the bacteria we cultured, such as *E. coli*, could be responsible for lesions seen here (Barnes and Gross, 1997), the variety of bacteria makes a definitive diagnosis uncertain. During the peak of the mortality, we often necropsied >20 birds/day that had heavy external fecal pasting thereby offering ample opportunity for contamination. Poor technique and consequent contamination of bacterial swabs with feces is a likely explanation for the variety of bacteria cultured.

Dehydration as a cause of the renal pathology was supported by lesions compatible with those of gout (Ridell, 1987) or of chickens deprived of water (Swayne and Radin, 1991). Renal pathology of dehydration in WTSW chicks with mucus or protein concretions or urates in distal tubules lined by necrotic epithelium was similar to that of Laysan albatross chicks (Work et al., 1998). Vacuolation of collecting duct epithelium is associated with dehydration in chickens experimentally deprived of water (Onderka, 1977). Some dehydrated birds were probably immunocompro-

mised, as evidenced by pulmonary mycosis, which typically affects immunosuppressed birds (Chute and Richard, 1997). The presence of birds with trauma was expected because many of the stranded WTSW chicks were found near roads, buildings and other urbanized areas.

The lack of mononuclear inflammation typically seen in viral infections argued against viruses such as infectious bronchitis as a cause of renal lesions (Cavanagh and Naqi, 1997). The lack of intracytoplasmic or intranuclear inclusions also argued against a viral cause for other lesions like the enteritis (Pierson and Dommert, 1997; Sandhu and Leibovitz, 1997). Natural marine toxins were not a likely cause of this stranding. Such events usually affect birds in good condition and of all ages; absence of neurological signs in live birds also argued against marine toxins (Work et al., 1993). Toxicants as the cause of the wreck also was unlikely because at the time, no chemical spills were detected on the Oahu coastline or in the vicinity of WTSW colonies, and no other species were affected. Furthermore, had adults fed toxicants in sufficient amounts to kill chicks, we should have observed adult mortality or morbidity.

Given that most stranded WTSW are probably dehydrated and immunosuppressed, future efforts to rehabilitate stranded chicks should focus on aggressive fluid therapy coupled with monitoring of weight, hematocrit, and estimated total solids. If birds are to be held captive for more than one day, they should be housed individually and strict hygiene observed to minimize spread of enteric organisms. Such events also point to the need for more systematic census of offshore WTSW colonies to better assess demographic conditions leading to wrecks and their effects on the population.

ACKNOWLEDGMENTS

The authors are very grateful to M. Breese from Sea Life Park and her staff for assistance in procuring specimens. R. Duncan at the Na-

tional Wildlife Health Center kindly provided identification of bacteria. We also thank the Hawaii Department of Agriculture for providing laboratory space that made this work possible. C. Brand, C. Franson, and anonymous reviewers kindly provided constructive comments on the manuscript.

LITERATURE CITED

- BARNES, H. J., AND W. B. GROSS. 1997. Colibacillosis. *In* Diseases of poultry, B. W. Calnek, H. J. Barnes, C. W. Beard, L. R. McDougald, and Y. M. Saif (eds.). Iowa State University Press, Ames, Iowa, pp. 131–142.
- BOURNE, W. R. P. 1976. The mass mortality of common murrelets in the Irish sea in 1969. *The Journal of Wildlife Management* 40: 789–792.
- CAMPBELL, T. W. 1994. Hematology. *In* Avian medicine: Principles and application, B. W. Ritchie, G. J. Harrison and L. R. Harrison (eds.). Wingers Press, Lake Worth, Florida, pp. 176–198.
- CAVANAGH, D., AND S. A. NAQI. 1997. Infectious bronchitis. *In* Diseases of poultry, B. W. Calnek, H. J. Barnes, C. W. Beard, L. R. McDougald, and Y. M. Saif (eds.). Iowa State University Press, Ames, Iowa, pp. 511–526.
- CHEVILLE, N. F. 1988. Introduction to veterinary pathology. Iowa State University Press, Ames, Iowa, 537 pp.
- CHUTE, H. L., AND J. L. RICHARD. 1997. Fungal infections. *In* Diseases of poultry, B. W. Calnek, H. J. Barnes, C. W. Beard, L. R. McDougald, and Y. M. Saif (eds.). Iowa State University Press, Ames, Iowa, pp. 351–365.
- COULSON, J. C., G. R. POTTS, I. R. DEANS, AND S. M. FRASER. 1968. Exceptional mortality of shags and other seabirds caused by paralytic shellfish poison. *British Birds* 61: 381–405.
- DANIEL, W. W. 1987. Biostatistics: A foundation for analysis in the health sciences. John Wiley and Sons, New York, New York, 734 pp.
- HARRIS, M. P., AND S. WANLESS. 1996. Differential responses of guillemot (*Uria aalge*) and shag (*Phalacrocorax aristotelis*) to a late winter wreck. *Bird Study* 43: 220–230.
- HARRISON, C. S. 1990. Seabirds of Hawaii. Cornell University Press, Ithaca, New York, 249 pp.
- HAWKEY, C. M., AND T. B. DENNETT. 1989. Color atlas of comparative veterinary hematology. Iowa State University Press, Ames, Iowa, 192 pp.
- HAYASHI, T. 1983. Straying of streaked shearwaters, *Calonectris leucomelas*, with special reference to seasonal winds. *Tori Bulletin of the Ornithological Society of Japan* 32: 21–29.
- HOCHLEITHNER, M. 1994. Biochemistries. *In* Avian medicine: Principles and application, B. W. Ritchie, G. J. Harrison, and L. R. Harrison (eds.). Wingers Press, Lake Worth, Florida, pp. 223–245.

- HOPE-JONES, P., C. F. BARRETT, G. P. MUDGE, AND M. P. HARRIS. 1984. Physical condition of auks beached in eastern Britain during the wreck of February 1984. *Bird Study* 31: 95–98.
- JAUNIAUX, T., L. BROSENS, F. FARNIR, C. MANTECA, B. LOSSON, J. TAVERNIER, H. VINDEVOGEL, AND F. COIGNOUL. 1996. Mortalite des oiseaux marins lors de l'hiver 1992–1993 le long du littoral belge. *Annales de Medicine Veterinaire* 140: 149–159.
- JURY, M. R. 1991. Anomalous winter weather in 1984 and a seabird irruption along the coast of South Africa. *Marine Ornithology* 19: 85–89.
- LEIFER, C. E. 1986. Hypoglycemia. *In* Current veterinary therapy IX, R. W. Kirk (ed.). W. B. Saunders Co., Philadelphia, Pennsylvania, pp. 982–987.
- LLOYD, C., J. A. BOGAN, W. R. P. BOURNE, P. DAWSON, J. L. PARSLow, AND A. G. STEWART. 1974. Seabird mortality in the north Irish Sea and Firth of Clyde early in 1974. *Marine Pollution Bulletin* 5: 136–140.
- NISHIGAI, M., Y. SAEKI, R. ISHITANI, F. SUGIMORI, Y. ISHIBASHI, N. OKA, AND A. NAKAMA. 1981. Pathological investigations on cause of death in slender-billed shearwater collected in Johga-shima area. *Journal of the Yamashina Institute for Ornithology* 13: 82–89.
- OKA, N., AND N. MARUYAMA. 1986. Mass mortality of short-tailed shearwaters along the Japanese coast. *Tori Bulletin of the Ornithological Society of Japan* 32: 97–104.
- , N. MARUYAMA, AND I. SKIRA. 1987. Chick growth and mortality of short-tailed shearwaters in comparison with sooty shearwaters as a possible index of fluctuations of Australian krill abundance. *Proceedings of the NIPR Symposium on Polar Biology* 1: 166–174.
- ONDERKA, D. K., J. A. HANSON, F. L. LEGGETT, AND L. D. ARMSTRONG. 1977. Renal pathology in chicks following water deprivation. *Avian Diseases* 31: 735–739.
- PIATT, J. F., AND T. I. VAN PELT. 1997. Mass mortality of guillemots (*Uria aalge*) in the Gulf of Alaska in 1993. *Marine Pollution Bulletin* 34: 656–662.
- PIERSON, F. W., AND C. W. DOMERMUTH. 1997. Hemorrhagic enteritis, marble spleen disease, and related infections. *In* Diseases of poultry, B. W. Calnek, H. J. Barnes, C. W. Beard, L. R. McDougald, and Y. M. Saif (eds.). Iowa State University Press, Ames, Iowa, pp. 624–632.
- PIONNEAU, F. 1987. Etude des oiseaux marin echoués. *Le Point Veterinaire* 19: 469–481.
- POWLESLAND, R. G., AND C. R. PICKARD. 1992. Seabirds found dead on New Zealand beaches in 1988, and a review of Puffinus species recoveries, 1943 to 1988. *Notornis* 39: 27–46.
- PROPHET, E. B., B. MILLS, J. B. ARRINGTON, AND L. H. SOBIN. 1992. Laboratory methods in histotechnology. Armed Forces Institute of Pathology, Washington, DC, 279 pp.
- QUESENBERRY, K. E., AND E. V. HILLYER. 1994. Supportive care and emergency therapy. *In* Avian medicine: Principles and application, B. W. Ritchie, G. J. Harrison and L. R. Harrison (eds.). Wingers Press, Lake Worth, Florida, pp. 383–416.
- RANDALL, C. J., AND R. L. REECE. 1996. Avian histopathology, Mosby-Wolfe, London, UK, 2332 pp.
- RIDDELL, C. 1987. Avian histopathology. American Association of Avian Pathologists, Kennett Square, Pennsylvania, 152 pp.
- RYAN, P. G., AND G. AVERY. 1987. Wreck of juvenile blackbrowed albatrosses on the west coast of South Africa during storm weather. *Ostrich* 58: 139–140.
- SANDHU, T. S., AND L. LEIBOWITZ. 1997. Duck virus enteritis (duck plague). *In* Diseases of poultry, B. W. Calnek, H. J. Barnes, C. W. Beard, L. R. McDougald, and Y. M. Saif (eds.). Iowa State University Press, Ames, Iowa, pp. 675–684.
- SCOTT, J. M., J. A. WIENS, AND R. R. CLAEYS. 1975. Organochlorine levels associated with a common murre die-off in Oregon. *The Journal of Wildlife Management* 39: 310–320.
- SWAYNE, D. E., AND M. J. RADIN. 1991. The pathophysiological effects of water and feed restriction in chickens. *Avian Pathology* 20: 649–661.
- UNDERWOOD, L. A., AND T. J. STOWE. 1984. Massive wreck of seabirds in eastern Britain, 1983. *Bird Study* 31: 79–88.
- WORK, T. M. 1996. Weights, hematology, and serum chemistry of seven species of free-ranging tropical pelagic seabirds. *Journal of Wildlife Diseases* 32: 643–657.
- , B. BARR, A. M. BEALE, L. FRITZ, M. A. QUILLIAM, AND J. L. C. WRIGHT. 1993. Epidemiology of domoic acid poisoning in brown pelicans (*Pelecanus occidentalis*) and Brandt's cormorants (*Phalacrocorax penicillatus*) in California. *Journal of Zoo and Wildlife Medicine* 24: 54–62.
- , M. R. SMITH, AND R. DUNCAN. 1998. Necrotizing enteritis as a cause of mortality in Laysan albatross, *Diomedea immutabilis*, chicks on Midway Atoll, Hawaii. *Avian Diseases* 42: 1–5.

Received for publication 15 June 1998.