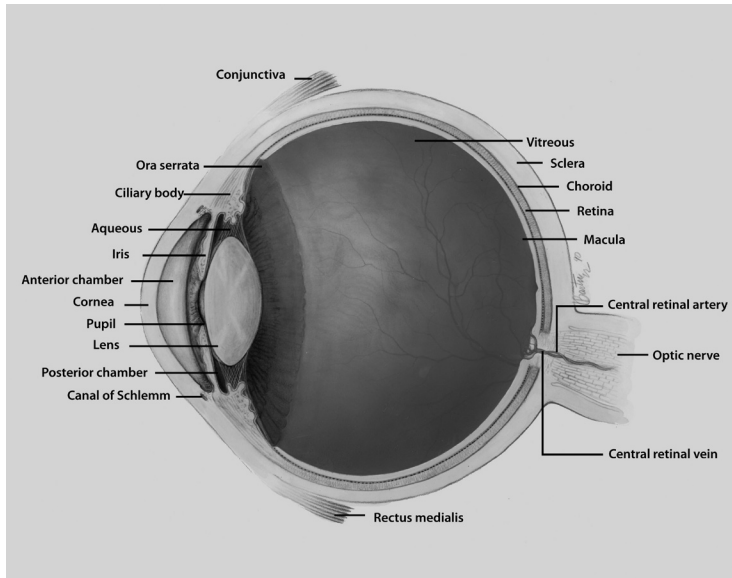


Coloboma



Coloboma describes conditions where normal tissue in or around the eye is missing from birth.

● What is a coloboma?

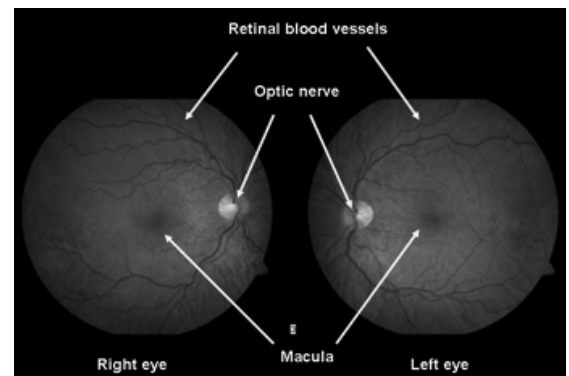
Coloboma comes from a Greek word which means “curtailed”. It is used to describe conditions where normal tissue in or around the eye is missing from birth.

To understand coloboma, it is useful to be familiar with the normal structure and appearance of the eye, and the terms related to the different parts of the eye. See diagram of the eye above.

● Normal fundus

There are different kinds of coloboma, depending on which part of the eye is missing. Coloboma can affect the:

- eyelid
- lens
- macula
- optic nerve
- uvea



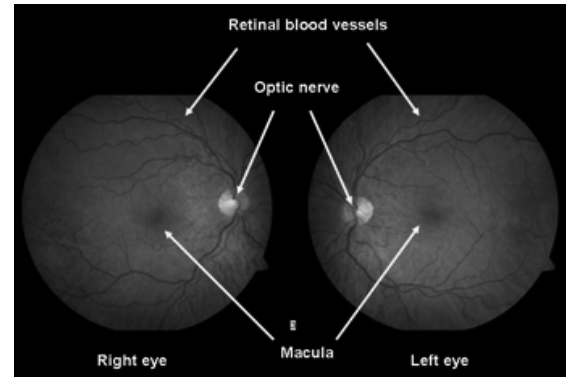
Normal fundus

● Eyelid Coloboma

In eyelid coloboma a piece of either the upper or lower eyelid is absent. Eyelid coloboma may be part of a genetic syndrome, or happen as a result of a disruption of eyelid development in a baby. A syndrome is a specific grouping of birth defects or symptoms present in one person. (www.genome.gov/glossary.cfm?key=syndrome)

● Lens Coloboma

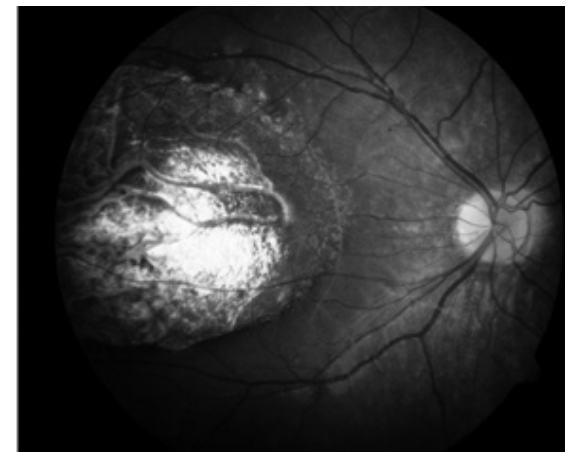
In this type of coloboma, a piece of the lens is absent. The lens, which helps focus light on the retina, will typically appear with a notch.



Lens Coloboma

● Macular Coloboma

This happens when the center of the retina, called the macula, does not develop normally. The macula is responsible for daylight, fine and color vision. Macular coloboma may be caused when normal eye development is interrupted or following an inflammation of the retina during development of the baby.



Macular Coloboma

● Optic Nerve Coloboma

Optic nerve coloboma refers to one of two distinct things:

1. An abnormal optic nerve that is deeply “excavated” or hollowed out. In some cases it can also be referred to as an optic nerve pit. The optic

nerve is the bundle of nerve fibers that relays the light signals from the eye to the brain.

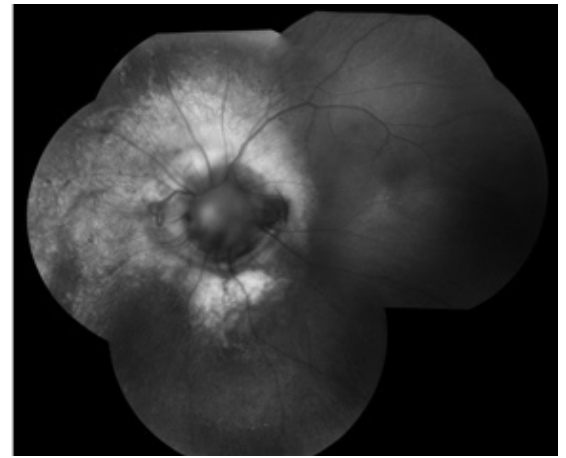
2. A uveal coloboma that is large enough to involve the optic nerve, either the inferior portion or the entire optic disc.

● **Uveal coloboma**

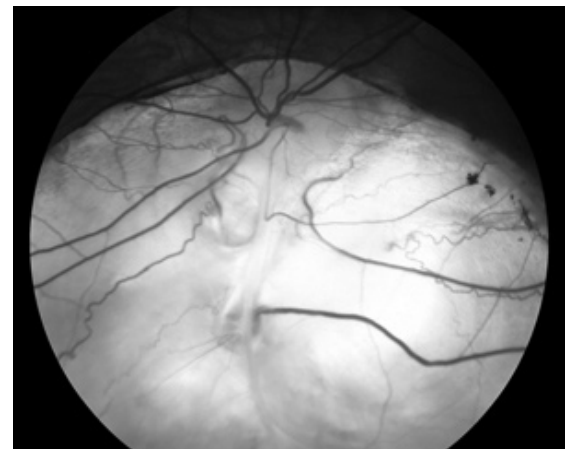
This coloboma can present as an iris coloboma (the iris is the colored part of the eye), with the traditional “keyhole” or “cat-eye” appearance to the iris, and/or as a chorio-retinal coloboma where the retina in the lower inside corner of the eye is missing.

● **How does uveal coloboma happen?**

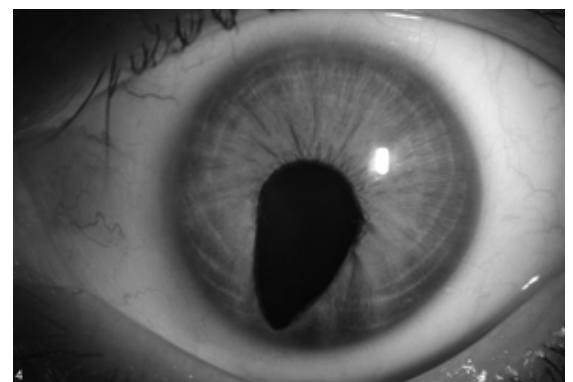
To understand how uveal coloboma happens, we first have to understand how the eye forms in the developing baby. The eyes start as stalks coming out of the brain. The tip of each stalk will become the eye itself, while the rest of the stalk will become the optic nerve linking the eye to the brain. There is a seam at the bottom of each stalk, where blood vessels originally run. This seam is known as the optic fissure, or the choroidal fissure, or the embryonic fissure. Starting at the fifth week of gestation (pregnancy), this seam must close. The closure starts roughly in the middle of the developing eye, and runs in both directions. This process is finished by the seventh week of



Optic Nerve Coloboma



Uveal Coloboma



Uveal coloboma affecting the iris

gestation. If, for some reason, the closure does not happen, a uveal coloboma is formed.

Depending on where the closure did not happen, the baby can have an iris coloboma (front of the fissure), a chorio-retinal coloboma (back of the fissure), or any combination of these. Uveal coloboma can affect one eye (unilateral) or both eyes (bilateral). The condition can be the same in both eyes (symmetric) or different in both eyes (asymmetric). A uveal coloboma may go from front to back (continuous) or have “skip lesions”. The fact that the seam runs at the bottom of the stalk is the reason why uveal coloboma is always located in the lower inside corner of the eye.

● What causes uveal coloboma?

It is believed that uveal coloboma is primarily genetic in origin. “Genetic” means that the coloboma was caused by a gene that was not working properly when the eye was forming. Sometimes coloboma is part of a specific genetic syndrome, for which the genetics are known. For instance, coloboma is one feature of CHARGE syndrome, which is associated with a change in, or a complete deletion of a gene called CHD7.

Researchers have found genes associated with coloboma in a few cases. To date, however, we still do not know which genes explain most cases of coloboma. For more information about what genes are and what a genetic condition is, please visit the National Library of Medicine’s Genetics Home Reference (<http://ghr.nlm.nih.gov/ghr/page/BrowseGenes>).

Some researchers have proposed that certain environmental factors may contribute to developing coloboma, either in humans or in animals. These findings have been published over time in the research literature, but there have been no systematic analysis of possible links. For instance, it is known that babies exposed to alcohol during pregnancy can develop coloboma - but they also have other anomalies. There are no known strong links between environmental exposures and isolated coloboma.

It is always possible that coloboma happens strictly by chance. In summary, there is little data to presently say why coloboma happened to a person in a family where no one else is affected.

● **How can uveal coloboma be inherited?**

Isolated coloboma can follow all possible patterns of single gene inheritance, namely autosomal dominant, autosomal recessive and X-linked. For more information on inheritance patterns, please visit the National Library of Medicine's Genetics Home Reference (<http://ghr.nlm.nih.gov/ghr/page/BrowseGenes>). In one family, however, coloboma will follow only one pattern. For instance, in case of an autosomal dominant pattern, a person with coloboma would have a 50/50 chance of passing on the coloboma to each of his or her offspring. In families with a single case of coloboma, it is not possible to say what pattern of inheritance is involved; therefore it is not possible to give an exact recurrence risk number. The recurrence risk of coloboma computed from averaging data across many families (empiric risk) is about 10 percent. This is an imperfect number, as it mixes information from families where this risk may be close to 0 percent with information from families where the actual risk may be 25 percent or even 50 percent.

The topic of inheritance of coloboma is complicated by several factors:

- Sometimes a person who is at risk for developing coloboma may not develop the condition, or it may be so minor that it goes unnoticed. This may appear in the family history as an inconsistent, non-interpretable pattern of inheritance.
- Knowing the pattern of inheritance of coloboma in a family does not give information on how severely an at-risk person will be affected (e.g., how good their visual acuity will be).
- There may be more than one gene involved in being at risk for coloboma, which makes predicting inheritance even more difficult.

For coloboma due to a known syndrome, such as CHARGE syndrome, inheritance is based on what is known about that particular syndrome. However, it is rarely, if ever, possible to say whether coloboma will be a feature of the syndrome in a person inheriting the genetic background responsible for this syndrome.

● **How common is uveal coloboma?**

Uveal coloboma is a rare condition that is not always well documented. Depending on the study and where the study was conducted, estimates range from 0.5 to 2.2 cases per 10,000 births. Some cases may go unnoticed because uveal coloboma does not always affect vision or the outside appearance of the eye.

Uveal coloboma is a significant cause of blindness. Studies estimate that 5 to 10 percent of blind European children have uveal coloboma or uveal coloboma-related malformations.

● **What are the symptoms of uveal coloboma?**

There may or may not be any symptoms related to coloboma; it all depends on the amount and location of the missing tissue. People with a coloboma affecting the macula and the optic nerve will likely have reduced vision. In general, it is difficult to exactly predict what level of vision a baby will have only by looking at how much of the retina is missing.

People with a coloboma affecting any part of the retina will have what is called a “field defect”. A field defect means that a person is missing vision in a specific location. Because coloboma is located in the lower part of the retina, vision in the upper part of the field of vision will be missing. This may or may not be noticeable to the affected person.

A person with a coloboma affecting the front of the eye only will not have any decreased vision from it. Some people, however, have reported being more sensitive to light.

● **Are there other diseases or conditions associated with coloboma?**

In the eye

Coloboma is sometimes found in association with other eye features. These may include:

- Difference in eye color between the two eyes (heterochromia)
- Small eye (microphthalmia)
- Increased thickness of the cornea. The cornea is the clear front part of the eye.
- Clouding of the lens (cataract)
- Elevated pressure in the eye (glaucoma)
- Retinal malformation (retinal dysplasia)
- Nearsightedness (myopia)
- Involuntary eye movements (nystagmus)

Protrusion of the back of the eyeball (posterior staphyloma)

In other parts of the body

Coloboma may be an isolated feature, or may be found with other features. Sometimes these other features may be few and minor, such as skin tags near the ear. Sometimes they may be more numerous and severe, such as a heart or a kidney defect. A few of these associations may be genetic syndromes. These include (but are not limited to):

- CHARGE syndrome
- Cat-Eye syndrome
- Kabuki syndrome
- 13q deletion syndrome
- Wolf-Hirshhorn syndrome

● **Can uveal coloboma be treated?**

Patients with uveal coloboma should have yearly follow-up exams by an eye care professional. However, there is currently no medication or surgery that can cure or reverse coloboma and make

the eye whole again. Treatment consists of helping patients adjust to vision problems and make the most of the vision they have by:

- Correcting any refractive error with glasses or contact lenses.
- Maximizing the vision of the most affected eye in asymmetric cases. This may involve patching or using drops to temporarily blur vision in the stronger eye for a limited period of time.
- Ensuring that amblyopia (lazy eye) does not develop in childhood in case of asymmetry. Sometimes amblyopia treatment (patching, glasses and/or drops) can improve vision in eyes even with severe colobomas.
- Treating any other eye condition that may be present with coloboma, such as cataracts.
- Treating any complications that might arise from a retinal coloboma later in life, such as the growth of new blood vessels at the back of the eye (neovascularization) and/or retinal detachment.
- Using low vision devices, as needed.
- Making use of rehabilitation services, such as early intervention programs.
- Offering genetic counseling to the patient and family members.

If the eye with the coloboma is very small (microphthalmia), other follow-ups may be needed. Conformers and expanders may be used to help support the face and encourage the eye socket to grow. Children may also be fitted for a prosthetic (artificial) eye to improve appearance. As the face develops, new conformers will need to be made.

For people who wish to alter the appearance of a coloboma affecting the front of the eye, two options are currently available:

- Colored contact lenses that make the black part of the eye (pupil) round.

- Surgery to make the pupil rounder. This procedure pulls and sutures together the lower edges of the iris.

● **Is genetic testing available for uveal coloboma?**

Testing may be available in cases where the coloboma is part of a specific genetic syndrome. This testing would look for the gene(s) causing whole syndrome and not just the coloboma. Genetic testing is done on a blood sample and may involve looking at the patient's chromosomes, or looking at a specific gene on one of the chromosomes. For definition and pictures of genes and chromosomes, please visit the National Library of Medicine's Genetics Home Reference (<http://ghr.nlm.nih.gov/ghr/page/BrowseGenes>).

There is no specific recommended testing for isolated coloboma. Testing for some of the genes that were reported in the medical literature might be performed as part of research projects. However, results from such testing will likely be negative, since these genes explain very few cases of uveal coloboma.

● **National Eye Institute Research**

Researchers at the National Eye Institute have been following individuals with uveal coloboma (Research protocols #04-EI-0039 for isolated cases of coloboma, and #06-EI-0230 for familial cases of coloboma). For an overview of this research, please go to <http://www.nei.nih.gov/intramural/pediatric.asp>. The above studies are available for patient examination and consultation. At a minimum, the vision of each patient and first-degree relatives is evaluated, and blood samples from each participant are collected to look for the genes involved in coloboma. Other clinical evaluations and tests may be offered, based on history and symptoms. Patients interested in participating in these research studies should contact:

Delphine Blain, ScM, MBA
Certified Genetic Counselor
National Eye Institute
(301) 496–1410
dblain@mail.nih.gov

● Resources

National Human Genome Research Institute Talking Glossary of Genetic Terms at *<http://www.genome.gov/10002096>*.

National Library of Medicine—Genetics Home Reference at *<http://ghr.nlm.nih.gov>*.

NEI Eye Health Organizations Database (Resources on Coloboma) at *<http://www.nei.nih.gov/health/resourceSearch.asp?Disp=1&strKey=Coloboma>*.

● Medical literature

For information on your topic, you may wish to conduct a search of the medical literature. The National Library of Medicine (NLM) coordinates PubMed, a computerized medical literature database. You can conduct your own free literature search by accessing PubMed through the Internet. For help on how to search PubMed and how to get journal articles, please see PubMed Help. You may also get assistance with a literature search at a local library.

Please keep in mind that articles in the medical literature are usually written in technical language. We encourage you to share articles with a health care professional who can help you understand them.

Below are citations for some sample articles:

- Chang L, Blain D, Bertuzzi S, Brooks BP. Uveal coloboma: clinical and basic science update. *Curr Opin Ophthalmol*. 2006 Oct;17(5):447-70. Review. PMID: 16932062
- Gregory-Evans CY, Williams MJ, Halford S, Gregory-Evans K. Ocular coloboma: a reassessment in the age of molecular neuroscience. *J Med Genet*. 2004 Dec;41(12):881-91. Review. PMID: 15591273
- Morrison D, Fitzpatrick D, Hanson I, Williamson K, van Heyningen V, Fleck B, Jones I, Chalmers J, Campbell H. National study of microphthalmia, anophthalmia, and coloboma (MAC) in Scotland: investigation of genetic aetiology. *J Med Genet*. 2002 Jan;39(1):16-22. PMID: 11826019
- Onwochei BC, Simon JW, Bateman JB, Couture KC, Mir E. Ocular colobomata. *Surv Ophthalmol*. 2000 Nov-Dec;45(3):175-94. Review. PMID: 11094243

This information was developed by the National Eye Institute to help patients and their families search for general information about coloboma. An eye care professional who has examined the patient's eyes and is familiar with his or her medical history is the best person to answer specific questions.

The National Eye Institute (NEI) is part of the National Institutes of Health (NIH) and is the Federal government's lead agency for vision research that leads to sight-saving treatments and plays a key role in reducing visual impairment and blindness.



National Eye Institute
National Institutes of Health
2020 Vision Place
Bethesda, MD 20892-3655
(301)496-5248
www.nei.nih.gov



Last Reviewed on 07/20/09