

Chapter 34

Nasal Leeches

Synonyms

Duck leeches

Cause

Bloodsucking leeches of the genus *Theromyzon* sp. are the only leeches in North America known to feed directly in the nasal passages, trachea, and beneath the nictitating membrane of the eyes of migratory birds. Three species of nasal leeches have been reported from North America, *T. rude*, *T. tessulatum*, and *T. biannulatum*. Other genera of leeches feed on the exposed surfaces of waterfowl.

Species Affected

Nasal leeches affect many aquatic bird species (Fig. 34.1). Affected waterfowl include northern pintail, teal, American wigeon, northern shoveler, ring-necked duck, canvasback, redhead, lesser scaup, bufflehead, gadwall, ruddy duck, white-winged scoter, surf scoter, trumpeter swan, and tundra swan. Geese may also be parasitized but they are parasitized less frequently than ducks and swans.

Distribution

Nasal leech infestations of waterfowl and other migratory birds have not been reported south of the 30th parallel and are most commonly observed in northern areas because these parasites are better adapted to cold-water lakes (Fig. 34.2).

Seasonality

Peak parasitism usually occurs during the spring and summer months when leeches are actively seeking potential hosts and reproducing. During the winter months, the ambient temperatures in frozen ponds and marshes considerably slow their metabolic rate and, thus, their activity. In wetlands kept free of ice during the winter, bird activity may stimulate opportunistic feeding by leeches.

Field Signs

Birds that have leeches protruding from the nares or attached externally to the mucous membranes of the eyes are easily recognized from a distance with the aid of binoculars (Fig. 34.3). Leeches may be so blood-engorged that they resemble small sacks of blood (Fig. 34.4). Infested birds may be seen vigorously shaking their heads, scratching at their bills with their feet, or sneezing in an effort to dislodge the leeches and to force air through blocked nasal passages. These efforts are usually unsuccessful. Nasal and respiratory tract

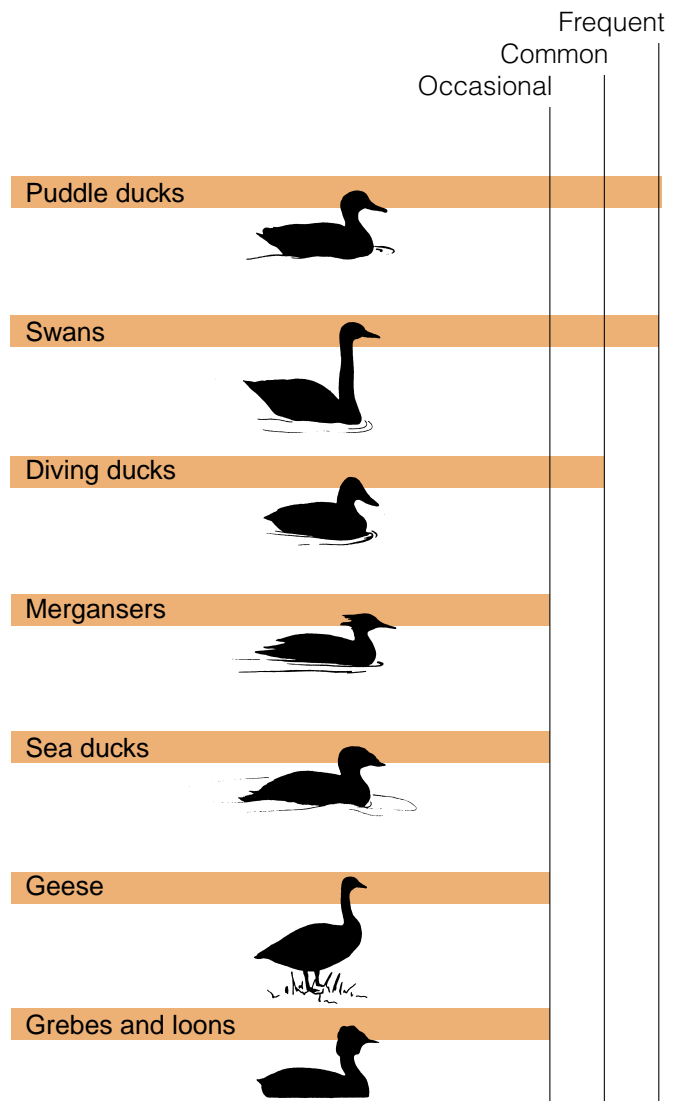






Figure 34.1 Relative frequency of nasal leech infestations in selected groups of migratory birds.

EXPLANATION

Frequency of occurrence of nasal leeches, by State and Province

-  Frequent
-  Common
-  Occasional
-  Rare or not reported

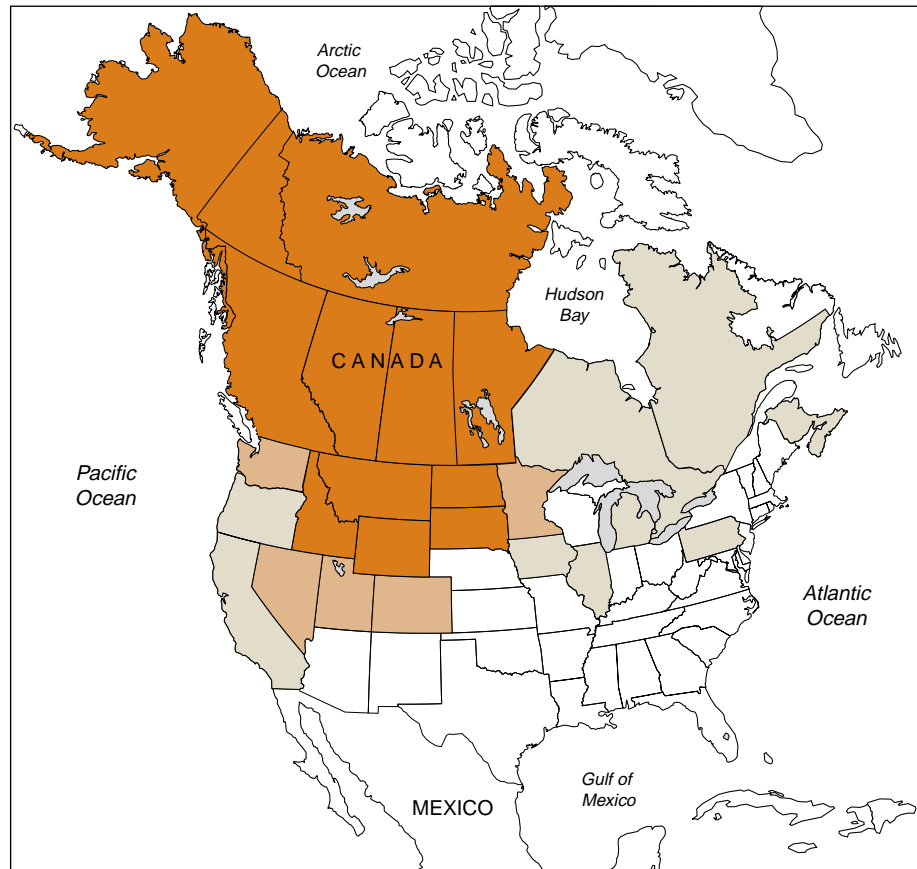

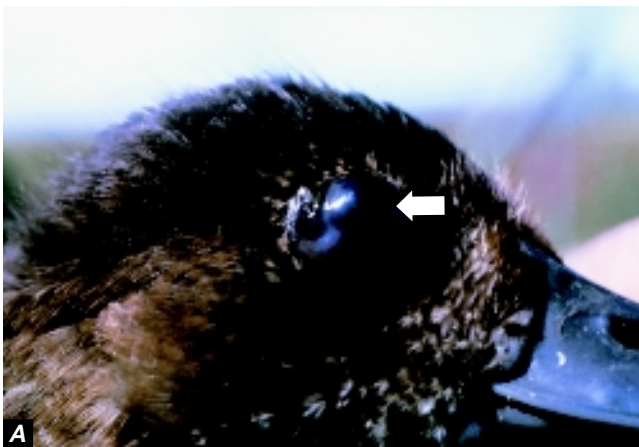


Figure 34.2 Reported distribution of nasal leeches in North America.



Photos by David Trauger, Biological Resources Division, USGS

Figure 34.3 External nasal passage infestations of nasal leeches on (A), the eyes and (B), on the nares of a female redhead duck.

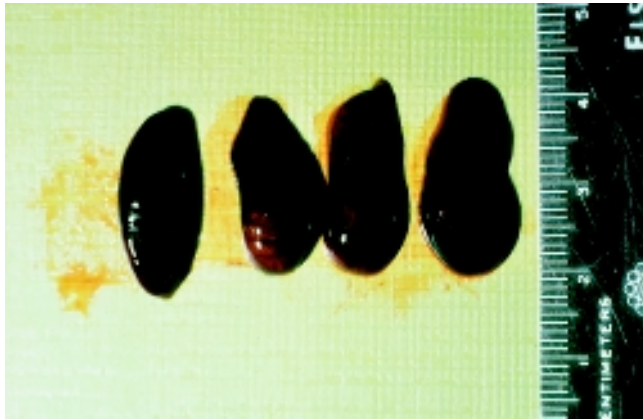

Photo by James Runnigen

Figure 34.4 Blood-engorged nasal leeches removed from the nares of a trumpeter swan.

leech infestations can cause labored breathing and gaping similar to that seen among birds suffering from aspergillosis.

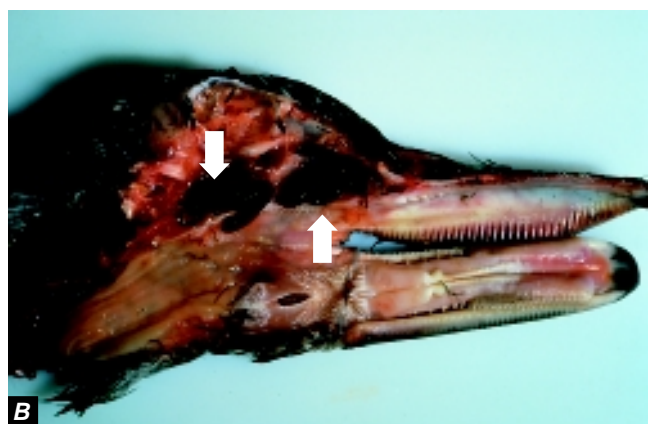
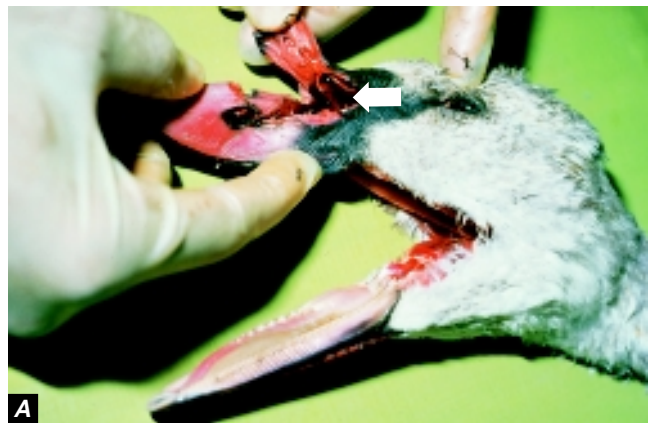
Gross Lesions

Severe leech infestations of the eye can result in temporary blindness. Eye damage may be seen as an accumulation of a stringy, cheeselike material beneath the nictitating membrane, as clouding of the cornea, and, in some instances, as collapse of the globe of the eye. Nasal passages (Fig. 34.5), throat, and trachea can become blocked by engorged leeches. The feeding action of *Theromyzon* sp. can cause inflammation and extensive damage to the lining of the nasal cavity.

Diagnosis

Nasal leeches are 10–45 millimeters long when they are blood-engorged, are amber or olive colored, and have four pairs of eyes. Those found in the free-living state are green, with variable patterns of spots on the top surface. Diagnosis of parasitism is usually made by seeing blood-engorged leeches protruding from the nares or attached to the eyes (Fig. 34.3), especially in birds that cannot be handled. Birds with internal leech infestations cannot be diagnosed by observation. In cases where the suspected cause of death is nasal leech parasitism, submit the entire carcass for examination. Leeches may depart a dead bird, making diagnosis difficult, or they may move to other areas of the body where they may be overlooked. Therefore, leeches found on carcasses should be collected and submitted with the carcass. They can be shipped alive in pond water and can be maintained in that condition for several months if they are kept refrigerated.

If leeches are to be killed before shipment, they must be preserved in a relaxed state so that species identification can be made. Straighten specimens between two glass slides (Fig. 34.6A) and flood them with a 10 percent formalin solution for 3–5 minutes while applying pressure to the top micro-



Photos by James Runnigen

Figure 34.5 (A), Nasal passages of trumpeter swan infested with blood-engorged *Theromyzon* sp. leeches. (B), Dissected nasal passages of a mallard showing leech infestation in sinus passages.

scope slide (Fig. 34.6B); then place them in a 10 percent formalin solution for about 12 hours to complete the fixation. Afterwards, transfer leeches to a 5 percent formalin solution for preservation (Fig. 34.6C).

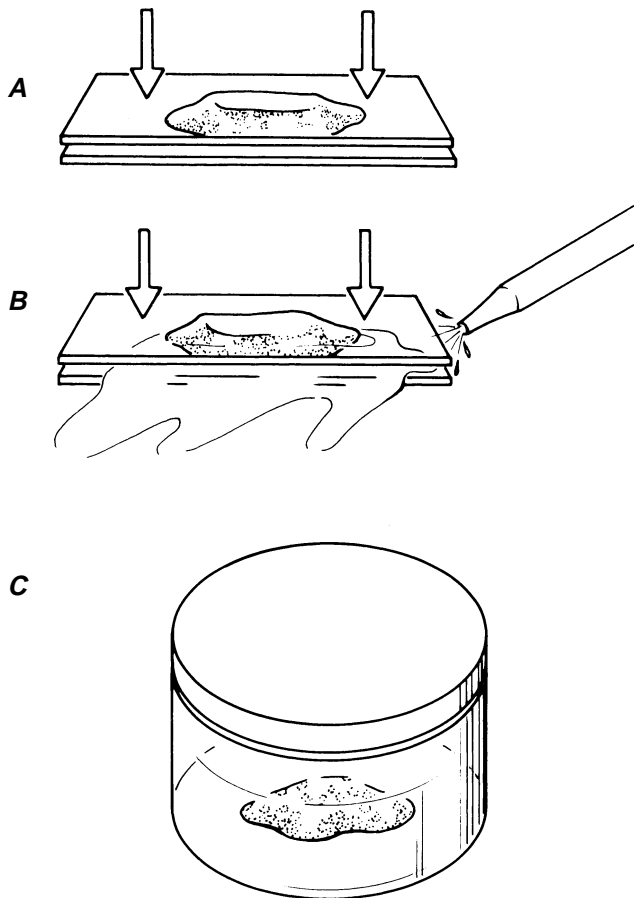


Figure 34.6 Leech fixation procedure. (A), Straighten (flatten) leech between two glass slides; (B), flood area between slides with 10 percent formalin for 3–5 minutes while maintaining downward pressure on top slide; and (C), transfer leech to container of 10 percent formalin (see text for additional details). (Illustration by Randy Stothard Kampen)

Control

Leech infestations in waterfowl are common and can be fatal, especially in cygnets and ducklings. Tissue damage resulting from heavy infestations can facilitate secondary bacterial infections. However, no preventive measures have been developed for combating infestations in wild birds. When they are not feeding on birds, nasal leeches occur as free-living organisms in aquatic environments. Control measures to reduce leech populations might be possible if nasal leeches could be selectively killed. However, leech control must be weighed against the value of leeches as an aquatic bird food item.

Leeches protruding externally from the nares or attached to eyes can be removed with forceps. Leeches in the nasal passages can be removed by submerging the bird's bill for 5–10 seconds in a 10–20 percent salt solution, and this can be repeated several times if necessary.

Human Health Considerations

Theromyzon sp. feed exclusively on avian hosts and are not considered a threat to humans.

Benjamin N. Tuggle

Supplementary Reading

- Davies, R.W., 1984, Sanguivory in leeches and its effects on growth, survivorship and reproduction of *Theromyzon rude*: *Journal of Canadian Zoology*, v. 62, p. 589–593.
- Trauger, D.L., and J.C. Bartonek, 1977, Leech parasitism of waterfowl in North America: *Wildfowl*, v. 28, p. 142–152.
- Tuggle, B.N., 1985, The occurrence of *Theromyzon rude* (Annelida:Hirudinea) In association with mortality of trumpeter swan cygnets (*Cygnus buccinator*): *Journal of Wildlife Diseases*, v. 22, p. 279–280.