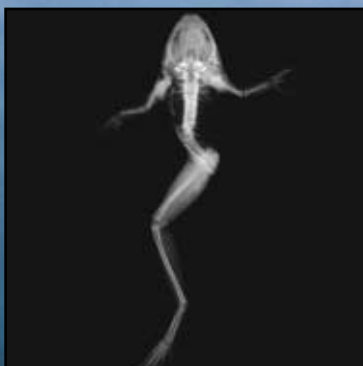
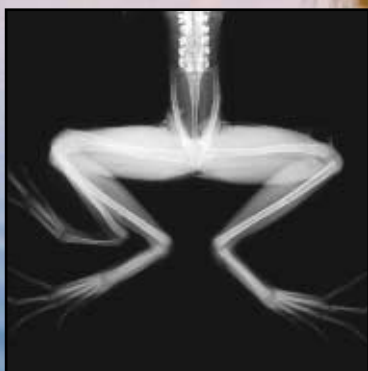


U.S. Department of the Interior,
U.S. Geological Survey

Field Guide to Malformations of Frogs and Toads

With Radiographic Interpretations

Biological Science Report
USGS/BRD/BSR-2000-0005





Acknowledgments

This field guide began as part of The Amphibian Health Examinations and Disease Monitoring workshop coordinated by U.S. Fish and Wildlife Service National Conservation Training Center (NCTC) in February 2000. The malformations presented here are not intended to be an exhaustive summary of all potential types of malformations. These malformations represent the major types of malformations found in approximately 200 recently metamorphosed frogs that were collected in Minnesota, Vermont, Wisconsin and Maine and examined at the USGS–National Wildlife Health Center in Madison, Wisconsin (NWHC). These studies focused on the northern leopard frog (*Rana pipiens*). The malformations and the method of their classification are reported in much greater detail in the publications from which this information was excerpted (Meteyer, C.U., et al., 2000).

Jewel Bennett, Karene Motivans, and Kelly Fike, NCTC, provided the final design, production and printing of the field guide. Denim Jochimsen and Harry Rihn, NWHC, provided assistance with the initial draft of the guide. Information on more training available through NCTC can be obtained at the NCTC homepage www.nctc.fws.gov.

Frogs in this field guide were collected during 1997–1998 survey efforts conducted in Minnesota by Judy C. Helgen, Dorothy Bower, and Susan Kersten, Minnesota Pollution Control Agency; Vermont by Richard Levey, Vermont Agency of Natural Resources, and Laura Eaton–Poole, U.S. Fish and Wildlife Service Ecological Services; and Maine by Kathryn A. Converse, NWHC. The technical staff of the NWHC Lab Investigations Branch provided photography, radiography, and necropsy support.

Scientific Review of this guide was provided by Dr. Doug Johnson, Dr. Doug Campbell, Dr. Ian Barker, Dr. D. Earl Green, Jeff Canfield, and Dottie Johnson.

Reporting Malformations

Malformations can be reported to the North American Reporting Center for Amphibian Malformations (NARCAM) on their website at www.npwrc.usgs.gov/narcam, or by phoning 1 800/238 9801. For results from more extensive surveys, information can also be submitted via mail by sending a spreadsheet or disk with the information on it to NARCAM, Northern Prairie Wildlife Research Center, 8711 37th St. SE, Jamestown, ND 58401. Basic information reported to NARCAM should include the date, species, numbers of both normal and malformed amphibians encountered, and a description of the malformation, along with the location of the malformation, including the state, county, and specific site.

Obtaining More Copies

Copies of the field guide may be obtained through: Publications Clearinghouse at NCTC at www.nctc.fws.gov/library/pubunit.html, or by calling 800/344 WILD, or the NWHC web site www.umesc.usgs.gov/http_data/nwhc/frog/frogmal.html.

Field Guide to Malformations of Frogs and Toads

With Radiographic Interpretations

Carol U. Meteyer

*USGS National Wildlife Health Center
Madison, WI 53711*

608/270 2462

<http://www.emtc.usgs.gov/nwhchome.html>

Funding for this project was provided in part by the USGS Biological Resource Division Eastern Region; the Northern Prairie Wildlife Research Center Grasslands Ecosystem Initiative; the National Institute for Environmental Health Science, Environmental Toxicology Program and U.S. Fish and Wildlife Service, National Conservation Training Center.

Suggested citation: Meteyer, C.U. 2000. Field guide to malformations of frogs and toads with radiographic interpretations. Biological Science Report USGS/BRD/BSR-2000-0005

Cover photo by: Ryan Hagerty



Introduction

In 1995, students found numerous malformed frogs on a field trip to a Minnesota pond. Since that time, reports of malformed frogs have increased dramatically. Malformed frogs have now been reported in 44 states in 38 species of frogs, and 19 species of toads. Estimates as high as 60% of the newly metamorphosed frog populations have had malformations at some ponds (NARCAM, '99). The wide geographic distribution of malformed frogs and the variety of malformations are a concern to resource managers, research scientists and public health officials. The potential for malformations to serve as a signal of ecosystem disruption, and the affect this potential disruption might have on other organisms that share those ecosystems, has not been resolved. Malformations represent an error that occurred early in development. The event that caused the developmental error is temporally distant from the malformation we see in the fully developed animal. Knowledge of normal developmental principles is necessary to design thoughtful investigations that will define the events involved in abnormal development in wild frog populations.

Development begins at the time an egg is fertilized and progresses by chemical communication between cells and cell layers. This communication is programmed through gene expression. Malformations represent primary errors in development, errors in chemical communication or translation of genetic information. Deformations arise later in development and usually result from the influence of mechanical factors (such as amputation) that alter shape or anatomy of a structure that has developed normally. The occurrence and the type of malformations are influenced by the type of error or insult as well as the timing of the error (the developmental stage at which the error occurred). The appearance of the malformation can therefore provide clues that suggest when the error may have occurred. If the malformation is an incomplete organ, such as an incomplete limb, the

factor or insult acted during a susceptible period prior to organ completion (Robbins S.L., et al., 1984). Although defining the anatomy of the malformed metamorphosed frog can give us an idea of the approximate window during which the developmental insult was initiated, and might even suggest the type of insult that may have occurred, **the morphology of the malformation does not define the cause.** To define causes and mechanisms of frog malformations we need to use well designed investigations that are different from traditional tests used in acute toxicity or disease pathogenicity studies. When investigating malformations in metamorphosed frogs, we are looking at the affect of exposure to an agent that occurred early in tadpole development. Therefore investigations to determine causes of malformations need to look at agents that are present in the tadpoles or their environments at these early developmental times. Laboratory experiments need to expose embryos and tadpoles to suspect agents at appropriate developmental stages and look at acute results, such as toxicity and death, as well as following the developmental process to completion to determine the impact of the agent on the developing tadpole and the fully developed frog. This means holding animals past metamorphic climax to assure that the anatomy and physiology of the adult have developed normally.

As we look at field collections of abnormal frogs, we need to keep in mind that these collections reflect survivors only. We are looking at malformations that were not fatal to tadpoles. We cannot assume that because we do not collect other malformations, they did not exist. More work needs to be done on the developing tadpole, in the field and in the laboratory, to better elucidate the range, frequency, character and causes of anuran malformations.



American toad
USFWS Photo by: K. Hollingsworth



Pickerel frog
USFWS Photo by: G. Atwell



Northern Leopard frog
USFWS Photo by: J. Rorabaugh

Glossary

Descriptions of frog malformations in this report are based on terminology used in human literature (Bolande, 1979; Robbins, et al., 1989), developmental biology (O’Rahilly, et al., 1996; Carlson, 1994; Gilbert, 1997), and teratology (Wise, et al., 1997). Many of these terms were originally used to describe abnormalities in the mammalian fetus at birth. However, application of common terminology may allow comparison of similar conditions in related specialties and across species and bring new interest and collaboration to the issues involving malformed frogs and toads.

Amelia: No evidence of a limb, the hip region is smooth and the pigment pattern is not disrupted.

Anophthalmia: Missing eye.

Aplasia (agenesis): Lack of development of an organ or tissue often resulting from failure of appearance of the primordium of an organ in embryonic development. For example, amelia is aplasia or agenesis of a limb.

Brachydactyly: Short toe; The normal number of metatarsal bones are present but the number of phalanges (bones in the toe) are reduced.

Brachygnathia: Abnormal shortness of lower jaw; same as mandibular micrognathia.

Bilaterally symmetrical rear limb malformations refer to the occurrence of the same type of malformation in both rear limbs.

Bilateral rear limb malformations refer to the occurrence of malformations of any type in both rear limbs.

Bone bridge: A bone structure that spans the space between two margins of bent bone. This bone structure appears radiographically as a plane of linear rays of bone that extend from the margins of bent bone and fill the angle between the bone margins.

Complete but malformed limb: All bones of the limb are present, but the limb is still abnormal e.g., rotation, bone bridge, skin web, micromelia.

Deformations: Deformations arise later in fetal life and represent alterations in form or structure resulting from

mechanical factors such as amputation. A deformation does not involve an intrinsic defect in morphogenesis and impacts a structure that otherwise developed normally.

Digits: Toes; identified by the number of phalanges and relative position on the foot or hand (Fig. 1C page 4).

Ectoderm: The embryonic layer from which epidermal tissues (skin, hair, etc.), mucous membranes, nervous tissue, and external sense organs (eye, ear, etc.) are derived.

Ectrodactyly: Missing toe; Distinguished from brachydactyly and refers to a completely missing digit including the metatarsal bone and phalanges.

Ectromelia: An incomplete limb with the lower portion of the leg missing. Types of ectromelia refer to the last identifiable bone e.g., ectromelia of the femur, ectromelia of the tibiafibula, and ectromelia of the tibiale and fibulare. Phocomelia and amelia are also considered types of ectromelia.

Hemimelia: Short bone; The affected bone is short but distal limb and foot are present, e.g., hemimelia of the tibiafibula, means the tibiafibula is short but the foot is present.

Hypoplasia: Incomplete development of an organ.

Hock joint: Ankle.

Kyphosis: Abnormally convex (hunchback) thoracic spine.

Malformations: Primary errors in any phase of morphogenesis including cell proliferation, cell migration, differentiation, programmed cell death or regression of larval structures.

Mesoderm: The embryonic layer from which connective tissue, bone, cartilage, muscle, blood, vasculature, notochord, pleura, pericardium, peritoneum, kidney, and gonads are derived.

Microcephaly: Small head, blunt snout.

Micromelia: Proportionally small or short limb.

Microphthalmia: Small eye.

Morphogenesis: The development

of highly organized and specialized tissues through cell division and proliferation, cell migration, cell differentiation, and programmed cell death all of which are orchestrated through chemical communication within and between cells.

Pathogenesis: Cellular events and tissue reactions that occur in the progression of disease.

Phocomelia: Absence of the proximal portion of a limb, with the foot attached very close to the body and proximal bones that cannot be identified.

Phalanges: Bones of the toe.

Polydactyly: More than the normal number of metatarsal bones are present with or without a complete set of phalanges.

Polymelia: More than two forelimbs or more than two rear limbs are present. The extra limb needs to have identifiable major segments (e.g. femur and tibiafibula) to be classified as a multiple limb.

Polyphalangy: The normal number of metatarsal bones are present at the tibiale-fibulare-metatarsal joint but with duplicate sets of phalanges.

Rotation: Distortion of the direction of bone growth in such a way that the orientation of the limb and foot is abnormal. **Primary** rotation is the misdirection of bone growth without a predisposing cause such as a fracture, a bone bridge or a skin web. A **secondary** rotation also has abnormal orientation of the foot, but it is due to the formation of a bone bridge, skin web or fracture.

Scoliosis: Lateral deviation (either left or right) in the normally straight line of the spine.

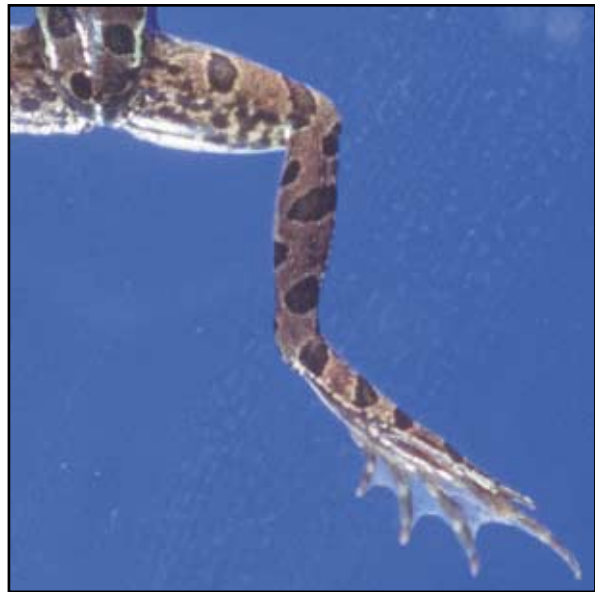Skin web: A band of skin crossing a joint and restricting motion of that limb.

Stifle joint: Knee.

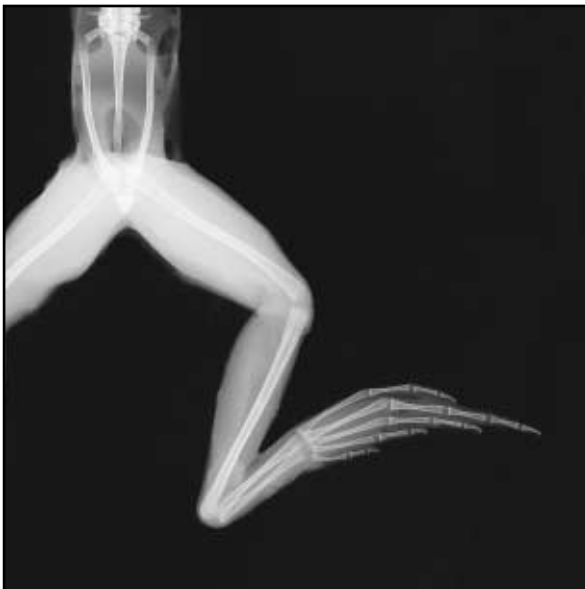Teratogen: An agent or factor that causes malformations.

Teratogenesis: Abnormal development that gives rise to malformations

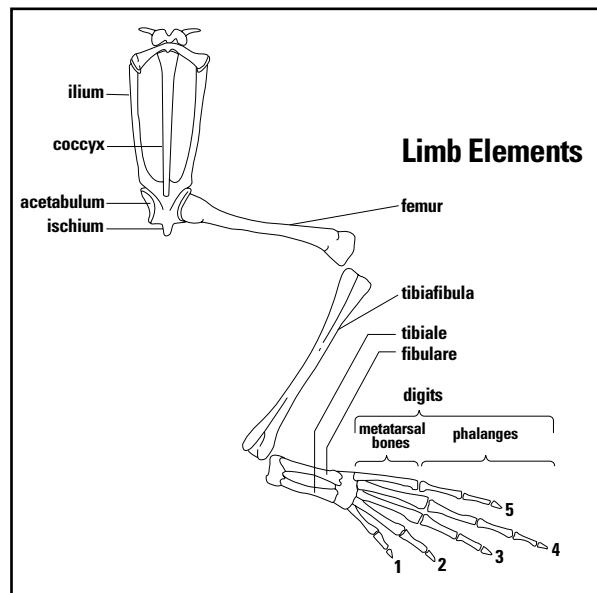
Anatomy and terminology describing the normal frog limb.



1A



1B



1C

Diagram is adapted from Duellman, et al., 1996.

General Classification System for Limb Malformations

I. No limb

A. Amelia 2A-B

II. Reduced limb segments

A. Ectromelia 2C-F, 3A-D
B. Phocomelia 3E-F

III. Complete but malformed limb

A. Skin web 4A-B
B. Bone bridge 4C-D
C. Rotation 4E-F, 5A-D, 6A-F
D. Hemimelia 5C-D, 6A-F
E. Micromelia 5E

IV. Reduced limb elements

A. Ectrodactyly
B. Brachydactyly 5C-D
C. Brachydactyly with Ectrodactyly 6A-F

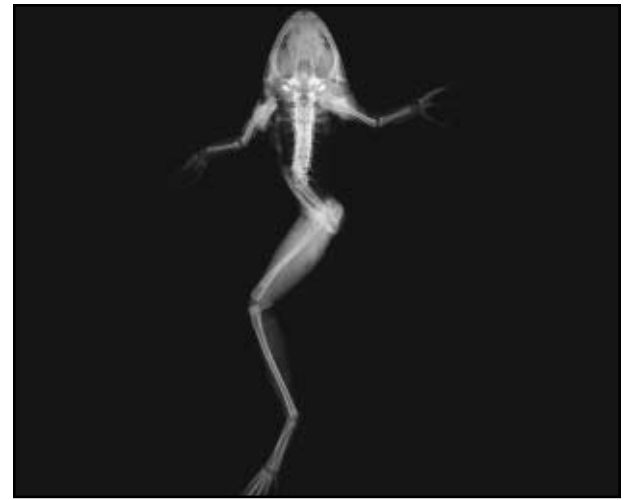

V. Multiple limb elements

A. Polydactyly
B. Polyphalangy 7A-F
C. Polydactyly and Polyphalangy 8A-B

VI. Multiple limb segments

A. Polymelia 8C-F, 9A-E

2A

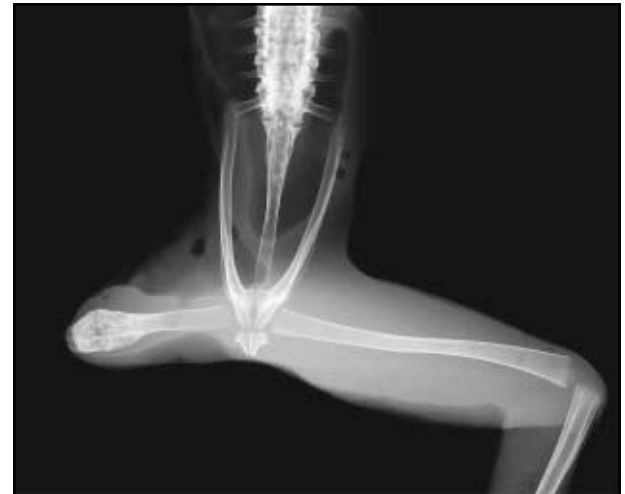
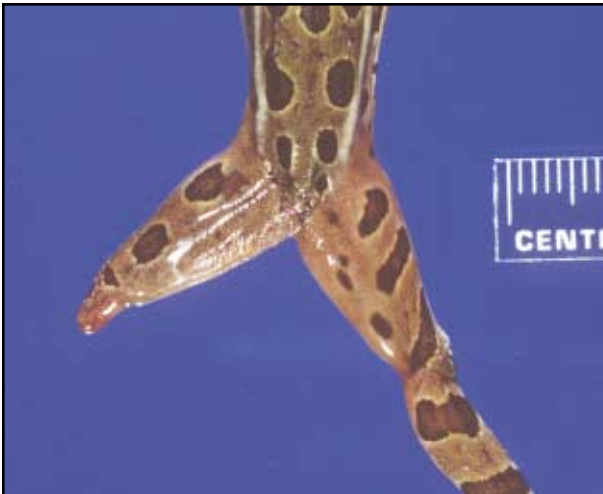
2B

Amelia

No bone has developed beyond the pelvis and the contour over the right hip is smooth. Displacement of the coccyx gives the appearance of scoliosis (curve to the right) although the vertebrae are properly aligned. The pelvis is usually abnormal in frogs with amelia. The frog in the images above is missing the right ilium.

2C



2D

Ectromelia of the femur

The femur is present but ends mid shaft. There is no evidence of a stifle (knee) joint.

2E



2F

Bilateral ectromelia of the femur

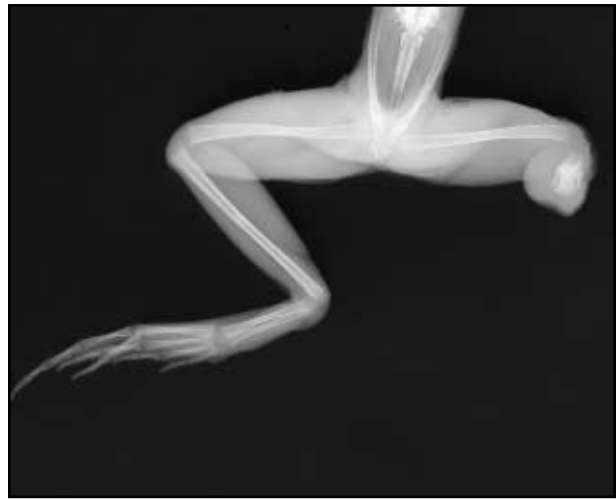The right femur is very short and difficult to discern, but as long as there is any bulge at the hip it can be assumed that a portion of the femur is present. Movement of the partial femur can often be seen under the skin.

Ectromelia of the femur with pigment malformation of the limb

Note the abnormal small reticular pattern of brown-black pigment over the right limb rather than the large spots of black-brown pigment which are normal for the leopard frog. At present, this is considered a malformation of skin pigment pattern. The melanophores that contain pigment are of ectodermal (neural crest) origin, and might be another form of inappropriate pattern determination in the malformation syndrome.



3A



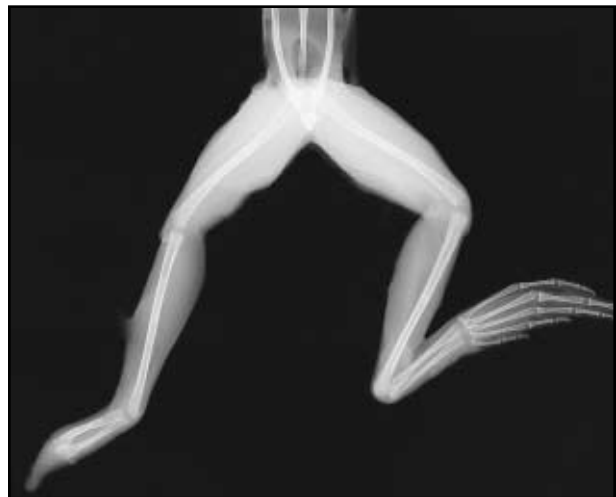
3B

Ectromelia of the tibiafibula

As long as the stifle (knee) is present, a portion of the tibiafibula must be present. In this frog, although the right tibiafibula is hard to identify without radiographs, we know that a portion of the bone must be there because the stifle is well defined.



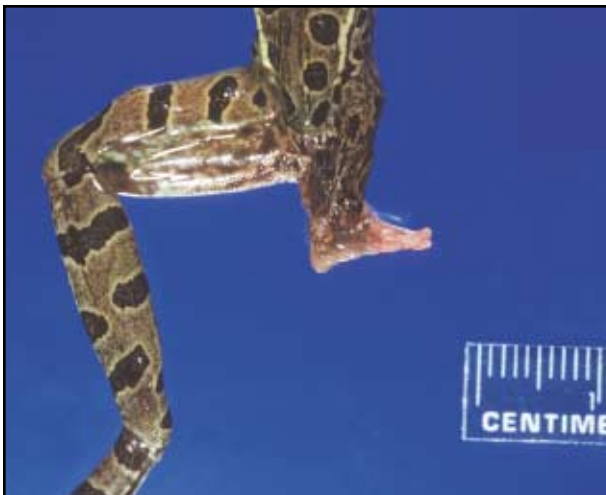3C



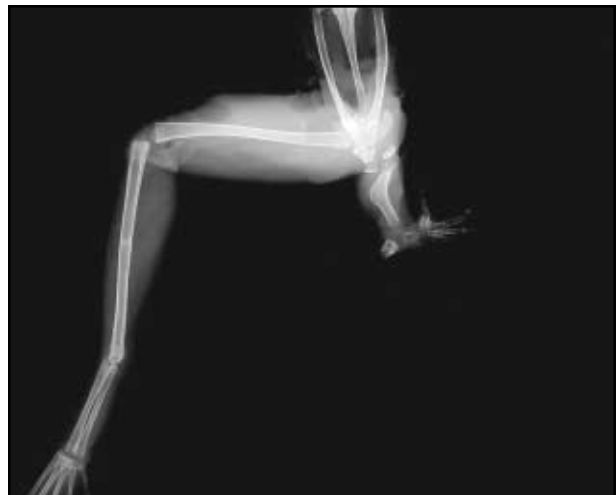3D

Ectromelia of the tibiale and fibulare

The left hock (ankle) joint is present, indicating that the tibiale and fibulare are present. The tibiale and fibulare are incomplete, however, and the digits are absent.



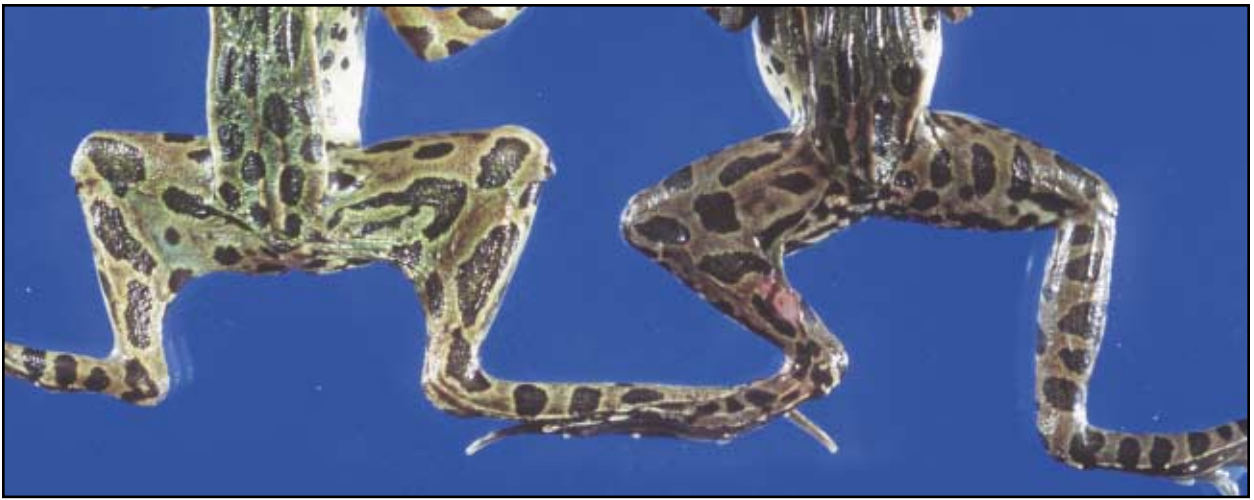3E



3F

Phocomelia

The right limb is very short with no distinct femur or tibiafibula. This is phocomelia and not ectromelia because a foot is present. This foot is very abnormal with only four metatarsal bones (ectrodactyly) associated with four terminal phalanges (brachydactyly).

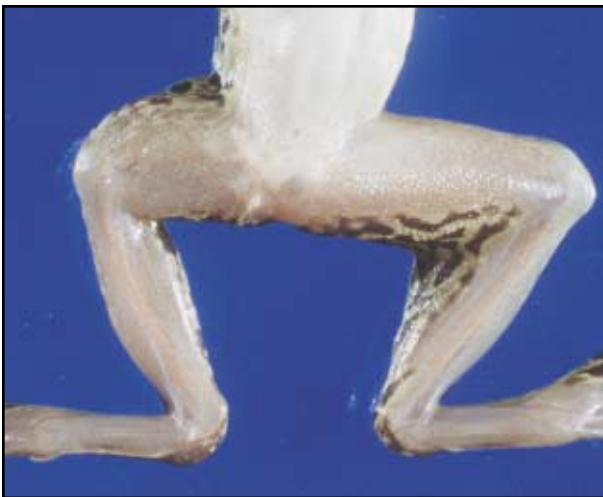

4A

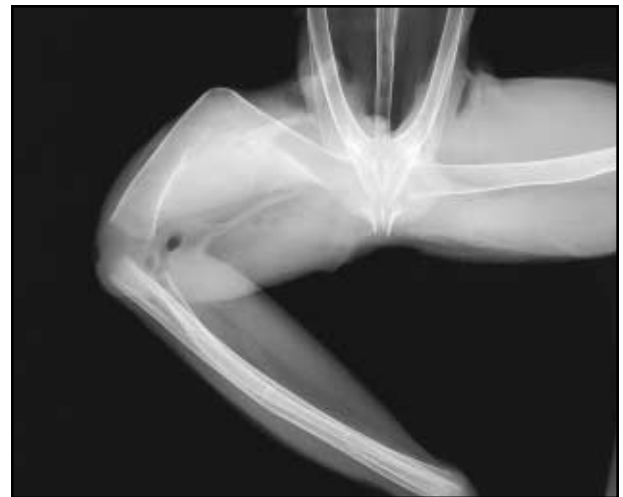4B

Bilateral skin webbing

Continuous bands of skin connect the hip to the hock. These webs of skin can be of various length and “tightness” but must cross a joint (usually stifle) to be a skin web. Skin webs are bilateral in frog (4A) and unilateral (left side) in frog (4B).



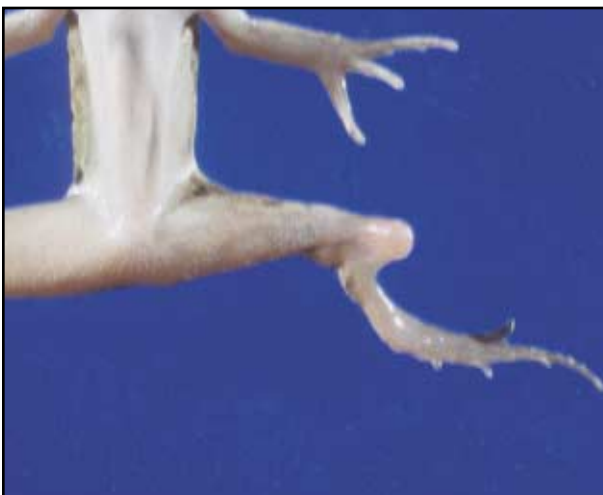4C



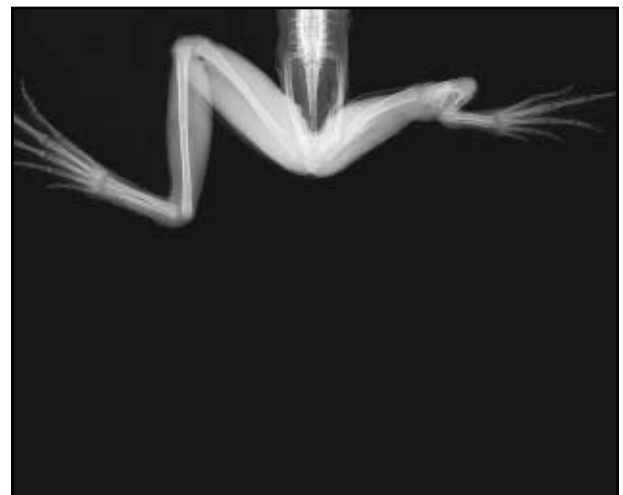
4D

Bone bridge of the femur

Bone bridging is difficult to discern in the live frog. The primary clues are a short, thick, bent long bone which may be palpable as a wide solid bone beneath the skin. Although skin webbing may be present with bone bridging, the skin web would again need to cross the stifle joint and not just “cover” a thickened bone. Radiographs show that these bone bridges form delicate rays of bone along the margins of bent long bone. Bone bridges may occur in any of the long bones including femur; tibiafibula and the tibiale and fibulare.



4E



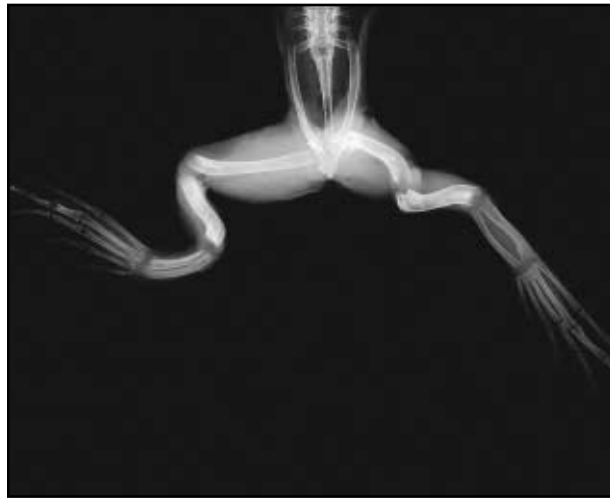4F

Bone bridge of the tibiafibula and “secondary” limb rotation

The left tibiafibula bends sharply at mid shaft and a bone bridge spans the angle of this bend. The tibiale and fibulare are short but the digits are relatively unremarkable. Although rotation is present, it is secondary to the bone bridge.



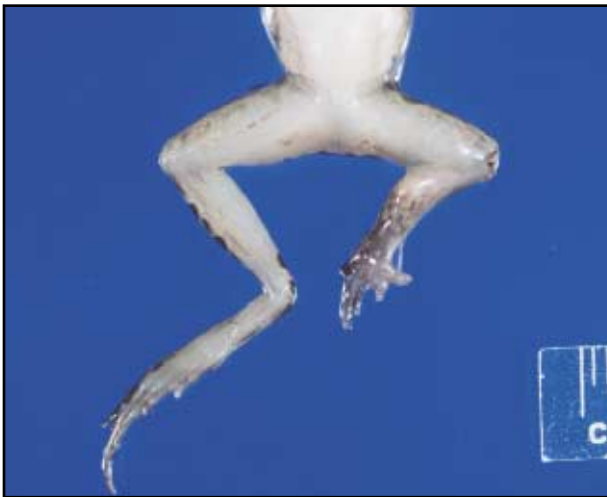5A



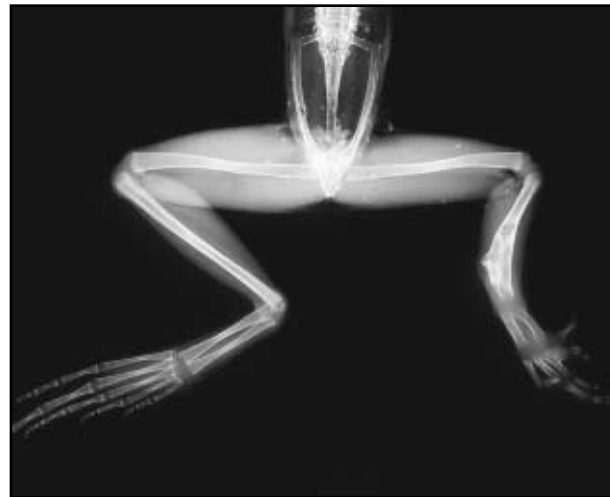
5B

Bilateral primary rotation

To classify a limb as a primary rotation, there should be no associated bone bridging or skin webbing. The distortion in these limbs is from intermittent bends in the long bones. This malformation is usually bilateral.



5C



5D

Brachydactyly, hemimelia of tibiafibula, and rotation

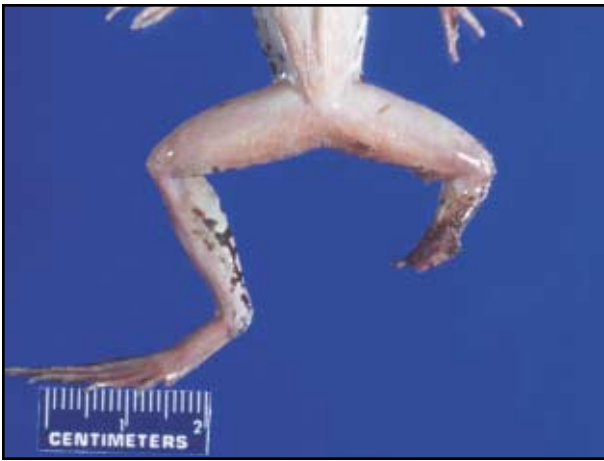Five digits (five metatarsal bones) are present but short, indicating missing phalanges (brachydactyly). Radiographs show the number of phalanges in the digits (medial to lateral) are 1, 3, 2, 2, 0. The tibiafibula is short, thick and rotated approximately 180 degrees because the longest toe (digit 4) is second from the midline suggesting a reversed digit order of 5, 4, 3, 2, 1. This is not phocomelia because a femur is present.



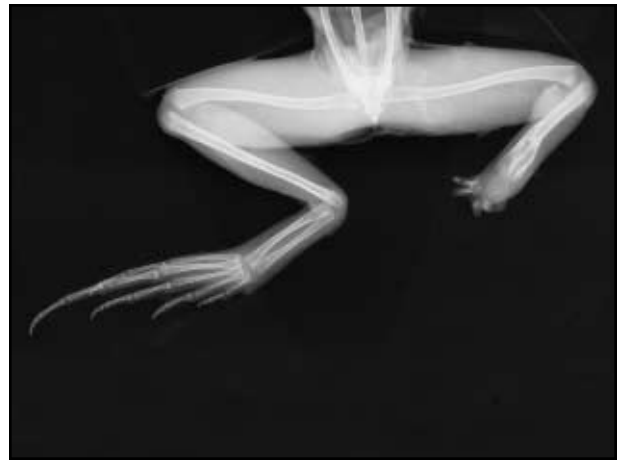5E

Micromelia

The right limb has all of its bones, but they are short with poorly developed muscle. The joints of these short limbs can be fused and immobile. This frog is also missing the right eye.



6A



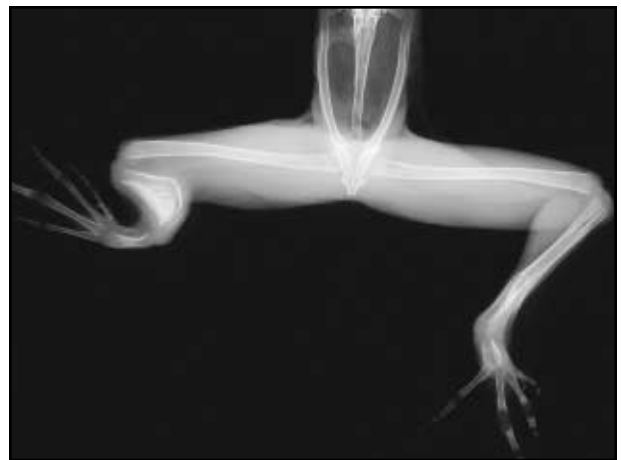6B

Ectrodactyly, brachydactyly, hemimelia of tibiafibula, and rotation

The tibiafibula is short, thick and rotated. However, this is not ectromelia of the tibiafibula because digits are present. The three digits (ectrodactyly) are very abnormal and short (brachydactyly). Although it cannot be seen in the live specimen, the tibiale and fibulare are absent.



6C



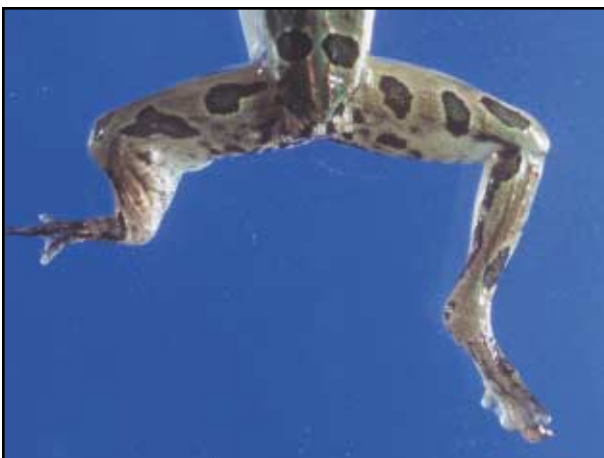6D

Left limb: Bone bridge, hemimelia of tibiafibula, rotation, ectrodactyly and brachydactyly

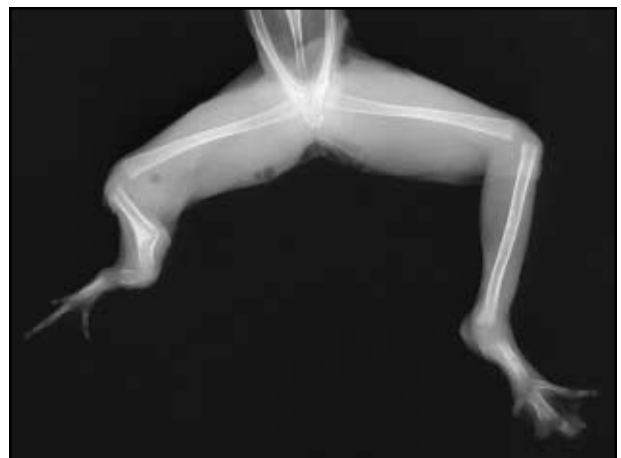
The tibiafibula is short, bent and a bone bridge fills the broad angle of the bend. There are four (ectrodactyly) short (brachydactyly) digits. The longest digit is in the second position suggesting 180 degrees rotation with digit order of 5,4,3,2,1. This is not skin webbing (skin does not cross a joint), the skin simply covers a very thick bone bridge.

Right limb: Rotation, ectrodactyly and brachydactyly

Only four digits are present (ectrodactyly) and all are short (brachydactyly). The distal tibiafibula is thick and rotated. The tibiale and fibulare are very small oval bones.



6E



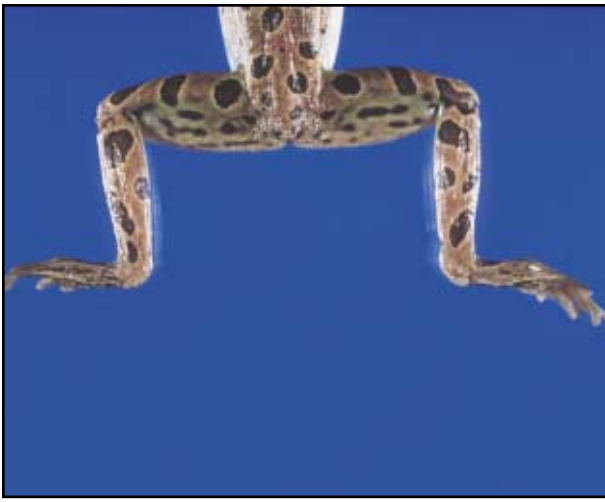6F

Left limb: Bone bridge, hemimelia of tibiafibula, skin web, rotation, ectrodactyly and brachydactyly

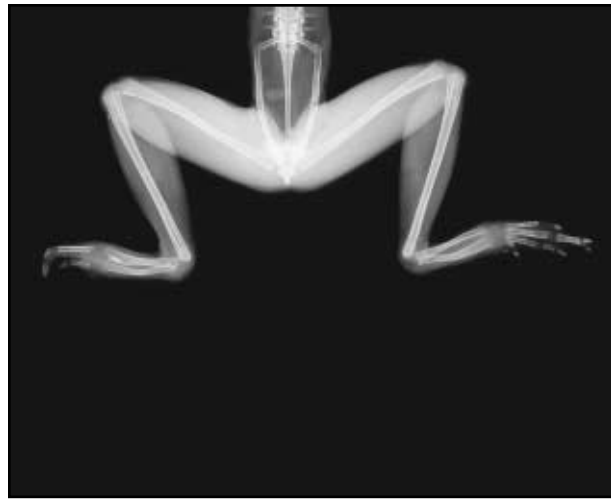
The tibiafibula is short, bent, and rotated. The bend is traversed by a bone bridge. A short skin web crosses the stifle. The tibiale or fibulare is missing and the remaining bone is short. Only three digits are present (ectrodactyly) and they are all short (brachydactyly).

Right limb: Ectrodactyly and brachydactyly

The tibiale and fibulare are rotated. There are only three digits (ectrodactyly) and they are all short (brachydactyly).



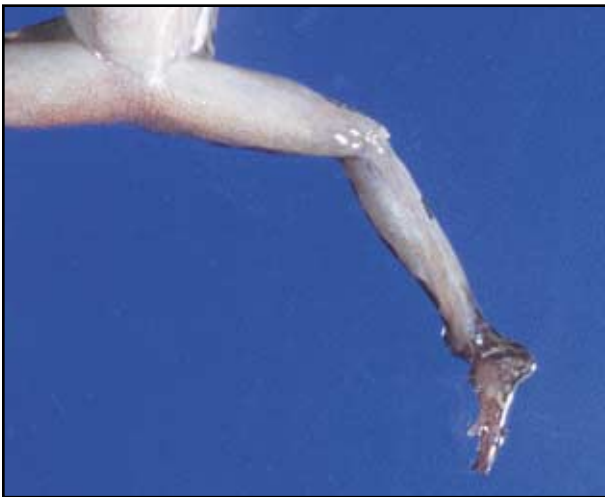7A



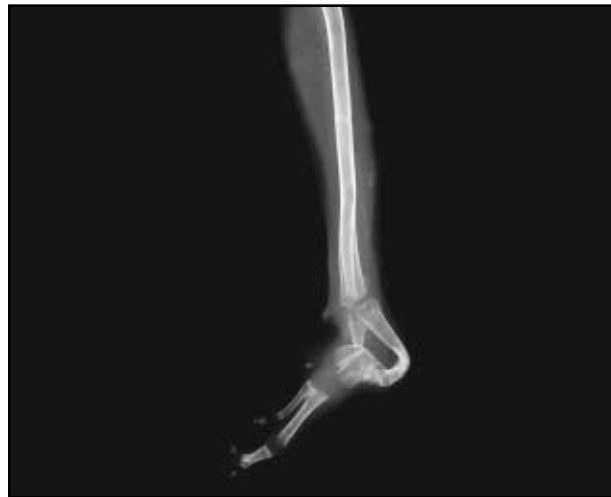7B

Ectrodactyly, brachydactyly, polyphalangy

The left foot has only two digits (ectrodactyly) and they are both short (brachydactyly). The right foot has four digits with 1, 2, 2, 1 phalanges respectively. The last phalanx of the longest digit on the right foot is duplicated (polyphalangy).



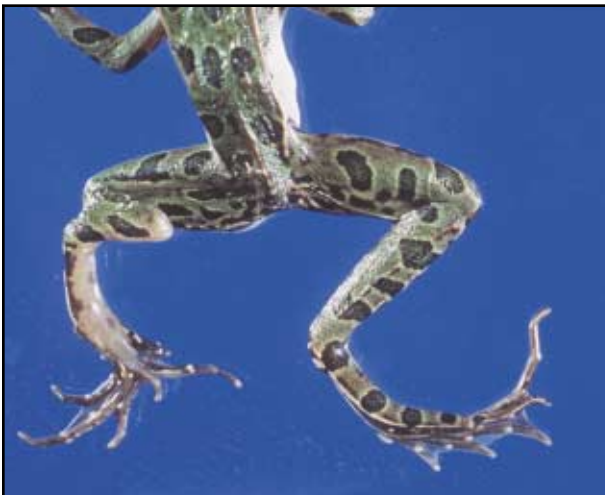7C



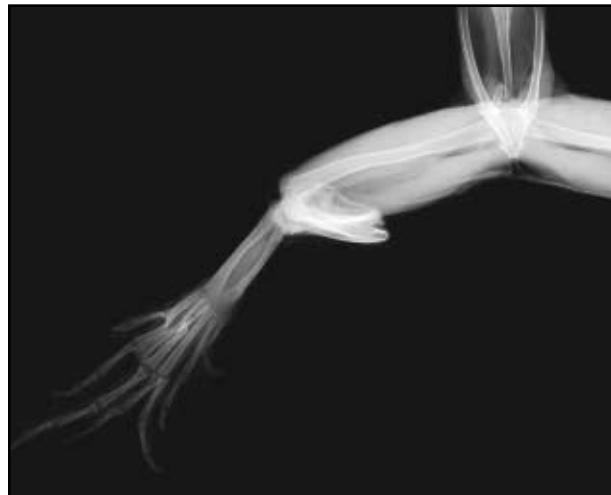
7D

Ectrodactyly, brachydactyly, polyphalangy with an unusual bone bridge

The left limb has a triangular-shaped tibiale-fibulare region, which is actually a long curved fibulare and a very short tibiale. This is not a skin web because it simply covers a bone structure and does not traverse a joint. Only three digits are present (ectrodactyly) and they are short (brachydactyly). The first phalanx of the longest digit splits and articulates with two terminal phalanges (polyphalangy).



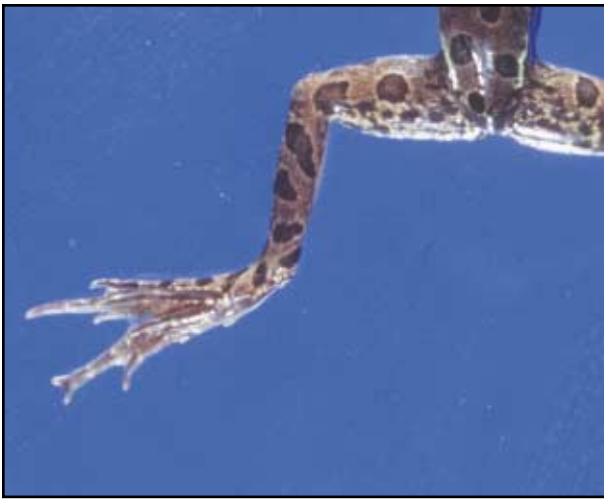
7E



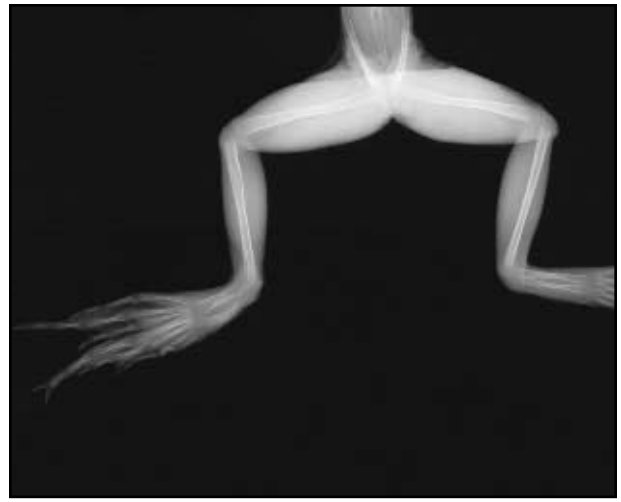
7F

Bone bridge, polyphalangy, and brachydactyly

The tibiafibula is folded on itself and the folded bone creates a bone bridge. The tibiale and fibulare are unremarkable. Eight digits can be counted but the left foot has a normal number of metatarsal bones. Metatarsal bones 4 and 5 are split midshaft resulting in polyphalangy. Digit 3 has duplication of the first phalanx at the metatarsal phalangeal joint, also resulting in polyphalangy. Two of the duplicated digits are short (brachydactyly).



8A



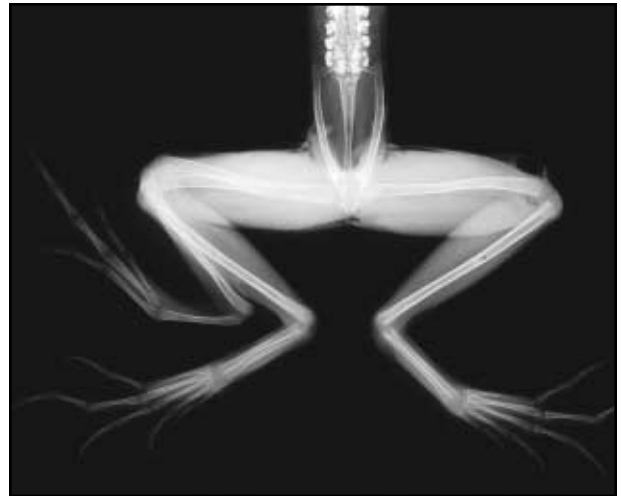
8B

Polydactyly and polyphalangy

There are eight digits (polydactyly), which are poorly separated in the image of the live frog. The radiograph shows digits as 1, 2, 3, 4 (3 or 5), 3, 4, 5. The long digit second from the mid line (digit 4) has a duplicated last phalanx (polyphalangy).



8C



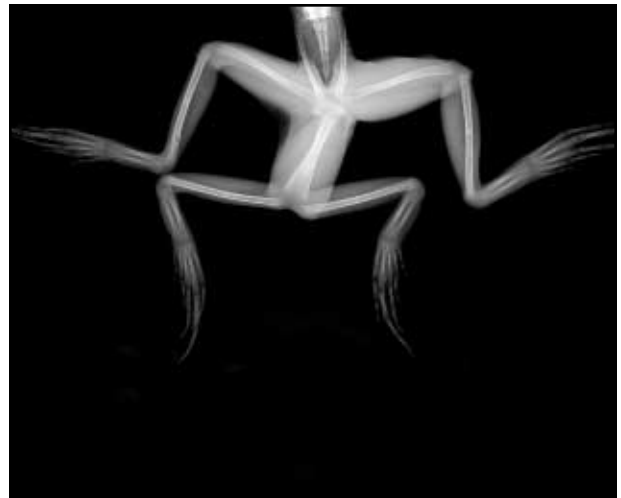
8D

Polymelia

The femur and tibiafibula are duplicated, therefore the classification is polymelia. The multiple femurs were not seen in this live specimen but the thickened bone at the end of the femur and stifle were palpable. A duplicate limb that becomes obvious at the stifle suggests that a portion of the femur is also duplicated.



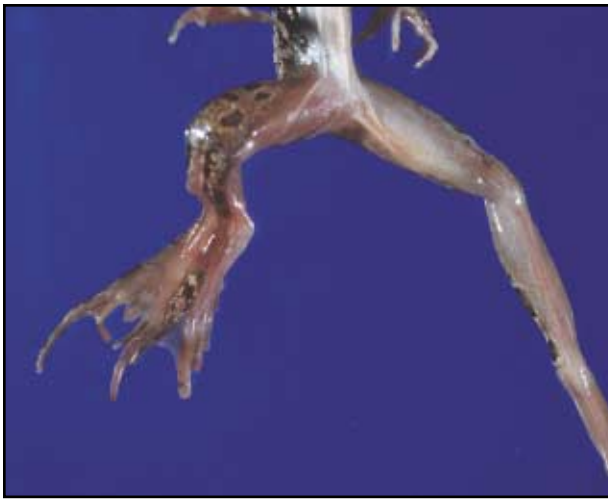8E



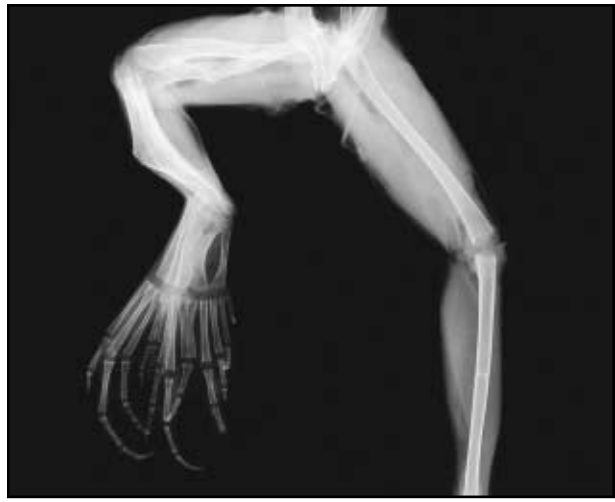8F

Polymelia

The fused femurs originate at multiple pelvic elements. The two duplicated limbs are present as “mirror images” of each other.



9A



9B

Polymelia

Although the multiple right limbs do not appear separated in the live specimen, the entire limb is very wide and there are 12 toes. This provides good evidence that the bones of the limb are duplicated. The radiograph shows two right femurs, five tibia/fibula bones and five tibiale/fibulare bones.



9C

Multiple forelimbs

The forelimbs of ranids do not emerge until metamorphosis and multiple forelimbs can remain under the skin.



9D

Multiple forelimbs

This bronze frog has almost identical and easily recognizable multiple forelimbs.



9E

Multiple forelimbs

This bullfrog has a mass of multiple limbs.

Photo by Dr. R.R. Dubielzig



9F

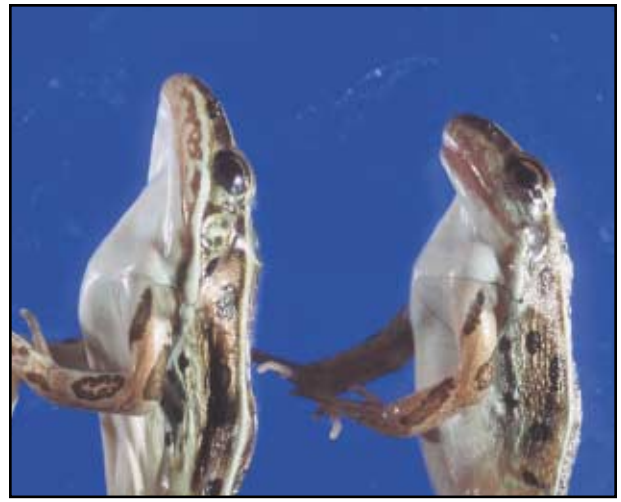Small bone projections

This late-stage tadpole has an abnormal structure projecting from the region of the tibia/fibula. This is not a multiple limb because no joint or identifiable segments are present.



10A

10B



10C

10D

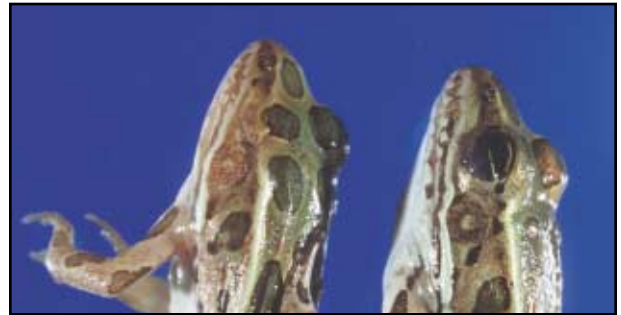
Microcephaly

The frogs on the far left and far right (10A, 10D) have small heads and their snout is blunt and curved. The heads of the frogs in the center (10B, 10C) are normal.



10E

10F



10G

10H

Eye abnormalities

10E Normal eye in a frog.

10F Small left eye in a frog (microphthalmia).

10G Frog missing left eye (anophthalmia).

10H The left eye has no iris and therefore appears uniformly black.

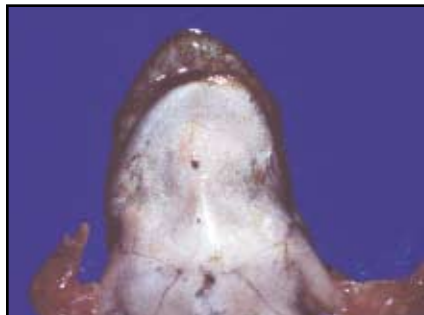10I Tadpole missing right eye (anophthalmia).



10I



10J



10K

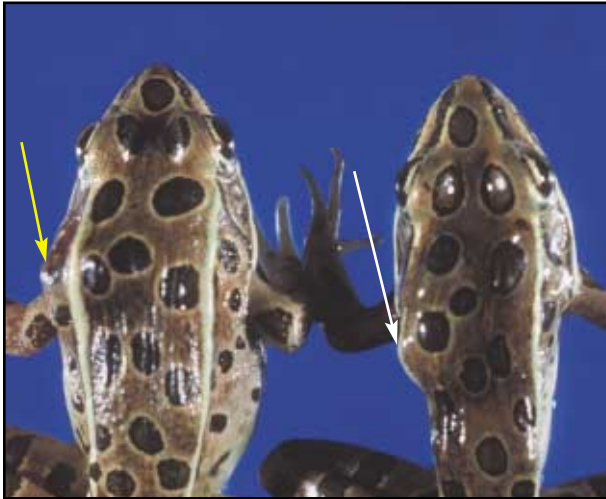

10L

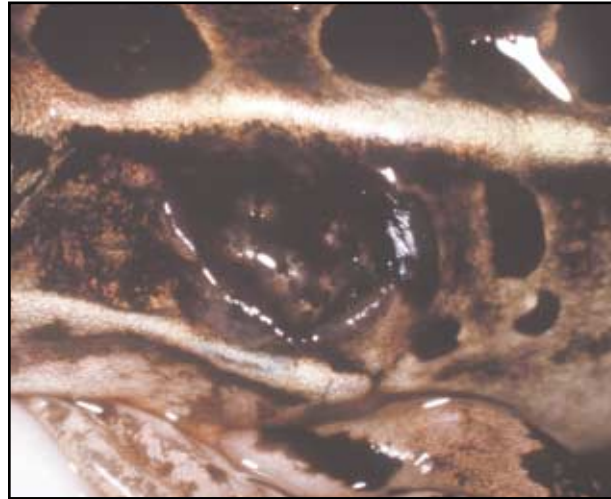Brachygnathia (mandibular micrognathia)

The first frog (10J) has a normal jaw with uniform closure of the margins of the mouth. The second frog (10K) has a short lower jaw (mild brachygnathia) that is curved to the left. The third frog (10L) has a severely distorted jaw with an irregular margin that does not meet the margins of the upper jaw (severe brachygnathia) leaving a large open gap that makes closure impossible.

Abnormalities, Not Malformations



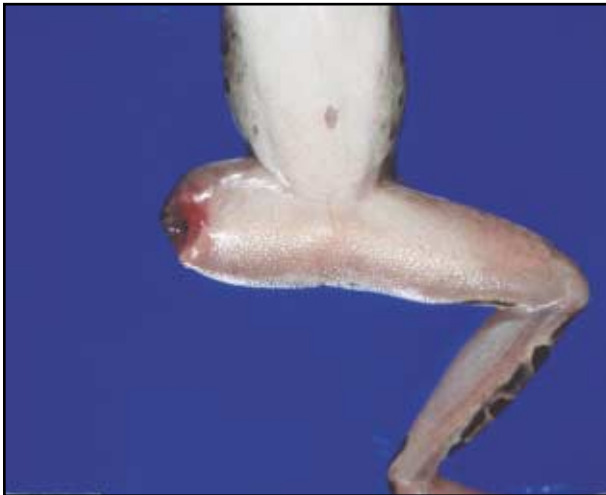11A



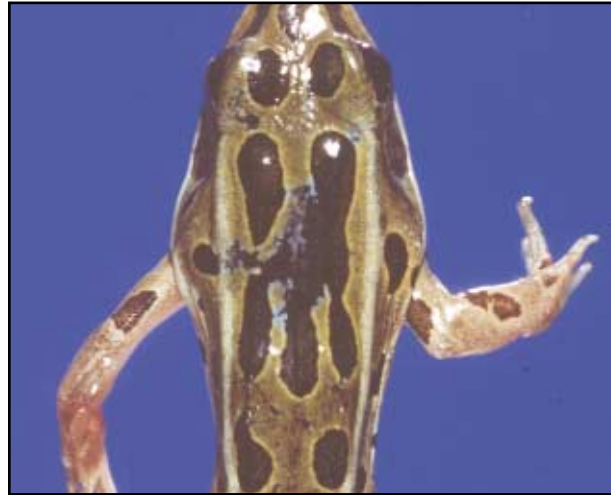11B

Not all irregular contours on the frog are malformations.

These frogs have a mass on the left side of their backs (arrows). When submerged in water, a pore opens and fly larvae (maggots) can be seen beneath the skin. Figure 11B is an enlargement of the area at the point of the yellow arrow in 11A.



11C



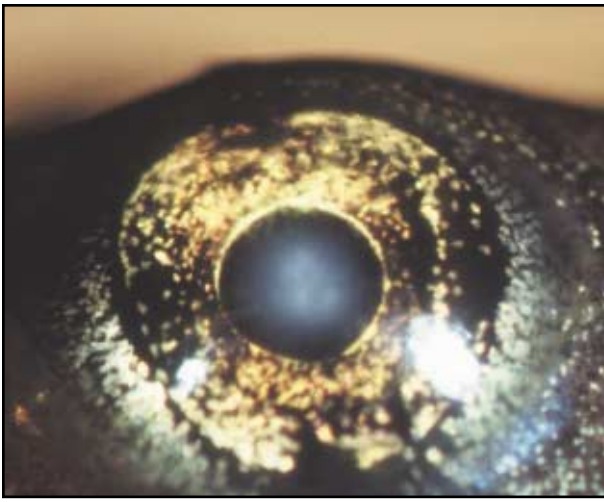
11D

Trauma—Limb amputation

The terminal margin of the right femur is blunt, irregular, red and swollen indicating trauma. Hemorrhage can be seen along the cut surface.

Trauma—Skin wound on back

There is irregular loss of pigment disrupting the skin color pattern over the back. The margins of this region are white, suggesting degeneration and scarring.



11E

Eye opacity due to intraocular infection with an immature fluke

The lens region of the eye in this late-stage tadpole is opaque and resembles a cataract. However, the opacity in this eye is actually a live immature fluke. The consequence of this infection on the post-metamorphic frog is not known, but one might assume that the frog's vision would be obstructed.



11F

Tuberculosis of the skin of a frog

This raised, tan, ulcerated skin mass resembles a tumor but is the consequence of infection with the species of mycobacteria which causes amphibian TB. The mass is composed of characteristic inflammatory cells that contain these bacteria.



11G

Emaciation and runtting

These newly metamorphosed leopard frogs have marked disparity in size. The center frog is within the normal size range for a newly metamorphosed frog (3.74 cm snout to vent length, 4.2 gm). The frogs on the left (2.15 cm snout to vent length, 0.7 gm) and right (2.45 cm snout to vent length, 1.0 gm) are extremely small and in poor body condition. The frog on the left is considered emaciated with a very narrow body silhouette along the abdomen and flank. The outline of the bones of shoulder, spine and pelvis can be easily defined through the skin and there is severe muscle wasting which is most obvious along the legs. This muscle wasting makes the legs look very thin and the head looks disproportionately large for the body size.

References

- Bolande, R. P. 1979. Developmental Pathology. *American Journal of Pathology* 94(3), pp. 627-638.
- Carlson, B. M. 1994. Human Embryology and Developmental Biology. Chapter 11, Limb Development, Mosby-Year Book, Inc. pp. 182-203.
- Duellman, E. and Trueb, L., 1996. *Biology of Amphibians*. The John Hopkins University Press, Baltimore, MD.
- Gilbert, S.F. (ed). 1997. Development of the tetrapod limb. In: *Developmental Biology*, pp. 701-731. Sinauer Associates, Inc., Sunderland, Massachusetts.
- O’Rahilly, R., Muller, F. 1996. *Human Embryology & Teratology*, Second Edition, Wiley-Liss, Inc. pp. 10-15.
- Meteyer, C.U., I. K. Loeffler, J. G. Burkhardt, K. A., Converse, E. Green, J. C. Helgen, S. Kersten, R. Levey, L. Eaton-Poole, and J. F. Fallon. 2000b. Hind limb malformations in free-living Northern leopard frogs (*Rana pipiens*) from Maine, Minnesota and Vermont suggest multiple etiologies. *Teratology* 60: 151–171.
- Robbins, S. L., R. S. Cotran, V. Kumar. 1984. Congenital malformation. In *Pathological Bases of Disease*, S. L. Robbins, R. S. Cotran, V. Kumar (eds), W.B. Saunders Company, Philadelphia, PA, pp. 479-482.
- Wise D. L., S. L. Beck, D. Beltrame, B. K. Beyer, I. Chahoud, R. L. Clark, R. Clark, A. M. Druga, M. H. Feuston, P. Guittin, S. M. Henwood, C. A. Kimmel, P. Lindstrom, A. K. Palmer, J. A. Petrere, H. M. Solomon, M. Yasuda, R. G. York. 1997. Terminology of developmental abnormalities in common laboratory mammals (Version 1). *Teratology* 55:249-292.

Key to Frog and Toad Malformations

C.U. Meteyer, 2000

L and R refer to animal's left and right

- Malformation** of limb see page 1;
Malformations of head, spine and skin, see page 2

- Abnormality** not malformation, see page 2

Limb Malformations

- Rear limb**
- Forelimb** (Forelimb nomenclature in parentheses)

L R

- No Limb:** Amelia
- Incomplete Limb:** (Ectromelia)
- No knee** (elbow): Ectromelia of femur (humerus)
- No foot** (hand) or hock (wrist): Ectromelia of tibiafibula (radius and ulna)
- Partial foot** (hand) Hock (wrist) joint but no toes: Ectromelia of tibiale/fibulare
- Foot attached "directly" to body** No identifiable proximal limb: Phocomelia

Complete Limb With Abnormal Long Bones

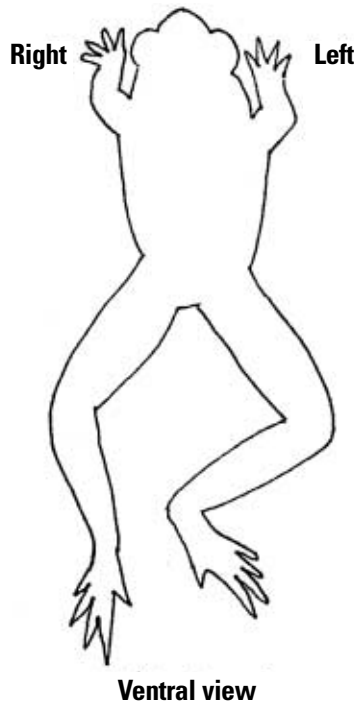
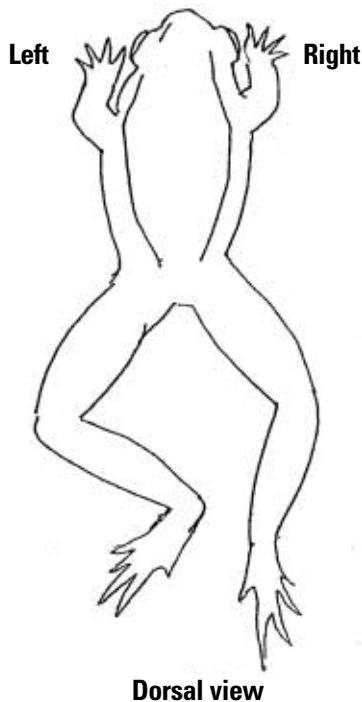
L R

- Skin Web**
Band of skin crosses joint
- Bone bridge**
Sharp bend in mid-shaft bone
- Rotation:**
- Primary rotation**
no bone bridge or skin web
- Secondary rotation**
Caused by bone bridge or skin web
- Long bone shortened**
Hemimelia of femur; tibiafibula or tibiale/fibulare
- Proportionately short limb**
Micromelia; short bones, often reduced muscle mass

Complete Limb; Digits Abnormal

L R

- Entire toe missing**
Ectrodactyly
- Short toes**
Brachydactyly
- Multiple toes:**
- Entire duplication**
Polydactyly
- Partial duplication**
Polyphalangy
- Mixed pattern same toe:**
Brachydactyly, and polyphalangy
- Multiple Limbs**
Polymelia; Sketch (label, e.g. A, B, C) describe these limbs (referring to labels) including site of limb origin, pairing, limb function, completeness, muscle development.
- Miscellaneous**
Small bone projection (sketch)
Other: Describe (sketch)



Malformation:

Abnormality not malformation

Head (Craniofacial) Malformations

Head Shape

- Small head microcephaly
- Domed head

Eye

- L R*
- Missing eye: anophthalmia
 - Small eye: microphthalmia
 - Iris abnormal color or shape
 - Iris absent
 - Malpositioned eye

Mouth or Jaw Abnormal

- No jaw: Agnathia**
- Lower (mandibular)
 - Upper (maxillary)
- Cleft jaw**
- Lower (mandibular)
 - Upper (maxillary)
- Small jaw: micrognathia**
- Lower (mandibular)
 - Upper (maxillary)
- Curved jaw
 - Absent tongue: Aglossia
 - Protruding tongue

L R

- Trauma** Describe fracture, laceration, amputation
-
-

- Infectious**
Viral, bacterial, parasitic
-

- Emaciation**
-

- Other**
-
-

- Unknown**
-
-

Spine Malformations

- Hunched back: Kyphosis
- Curvature: Scoliosis
- Extension of "spine" beyond rump

Skin Malformations

- Pigment/color:** Describe and sketch
- Pigment lacking, translucent
 - Pattern abnormal

