

***INCREASING UTILIZATION OF DECEASED DONOR LIVERS:
OPTIONAL RESOURCES FOR OPTN MEMBERS***

JUNE 2012

BACKGROUND

From 2010 to 2012, various OPTN committees worked together to develop a package of optional resources to help OPOs enhance the availability and utilization of deceased donor livers for transplantation. Members of the now-dissolved Organ Availability Committee, with assistance from the Organ Procurement Organization Committee and the Liver and Intestinal Organ Transplantation Committee, identified the following needs:

- Promote greater organ utilization of viable deceased donor livers, transplant centers considering offers need online access to the complete and reliable information about the organs
- Ensure local pathologists who provide histological information are aware of how to collect and report the specific data elements of most benefit to transplant centers considering the organ offer
- Enable transplant center staff to make better use of the reported biopsy information by helping them understand how to interpret what is most important in the reported data and any accompanying images

In June 2012, the OPTN Board of Directors approved a set of optional resources that were developed to address these needs. This document contains each resource, as described below, which can be printed and used separately or as a composite.

DONOR LIVER BIOPSY FORM

- This may be used by OPOs (a) to obtain appropriate and consistent biopsy information from their local pathologists, as well as (b) to easily upload this information for online access and consideration by transplant centers.
- Biopsy information routinely provided to centers using this standardized reporting and presentation format can promote more efficient and well-informed decision-making regarding organ offers.

PHOTO DOCUMENTATION RESOURCE GUIDE

- To assist liver organ placement, a few standardized photos in situ and on the back-bench can provide substantial information to augment (but not replace) clinical judgment and/or biopsy results. This guide describes when and how such photos can be made available for online access by the transplant centers. It also may assist center staff who must review and interpret any biopsy images provided by the OPO.

STEATOSIS GUIDE

- To assist pathologists in assessing % steatosis of deceased donor livers.

DONOR LIVER BIOPSY FORM

DONOR # _____

Type of Specimen: *Circle all that apply*

Wedge
Needle

Steatosis: **Large Vacuolar Macrovesicular Steatosis to nearest 10%:** _____
Small Vacuolar Macrovesicular Steatosis: *None Mild Moderate Severe*

Fibrosis:

Chronic Hepatitis-related (circle one)	Score
No fibrosis	0
Portal/periportal fibrosis involving a minority of portal tracts	1
Periportal fibrosis involving a majority of portal tracts	2
Definite/Bridging fibrosis	3
Cirrhosis	4

Necrosis:

Please circle one choice for location and percent involvement

Hepatocyte Necrosis (Location): *None Centrilobular Periportal Midzonal Random*

Percent of Biopsy Involved by Necrosis (estimate to nearest 10%) _____

Inflammation: Liver Inflammation Scoring (for HBV+ or HCV+ donors):

Portal and Lobular (circle one)	Score
None	0
Mild, some or all portal areas	1
Moderate, some or all portal areas	2
Moderate marked, all portal areas	3
Marked, all portal areas	4

Comments and Other findings:

The evaluation and diagnosis listed for the specimen(s) above are based on a 'frozen section', and are therefore preliminary and subject to change. A final diagnosis and report will be issued after review of the permanent sections at the time of signature of the Pathologist. This sign-out process and evaluation may require several days.

PATHOLOGIST NAME (PRINTED)

PATHOLOGIST SIGNATURE

DATE / TIME

PLEASE FAX TO: _____

PLEASE CALL _____ TO CONFIRM RECEIPT OF DOCUMENT @ PHONE # _____

This is an OPTIONAL form to assist OPTN members with placement of deceased donor kidneys.

Guide for Photo-Documentation of Deceased Donor Livers

Purpose and Summary

Photo documentation can be used to assist liver organ placement. A few standardized photographs *in situ* and on the back-bench will provide substantial information that can assist in decision-making regarding organ suitability by augmenting (but not replacing) clinical judgment and/or biopsy results. Organ procurement organizations and their representatives make no claims regarding the suitability of the organ based on photo-documentation. The final responsibility rests with the accepting program and/or their representatives.

Circumstances in which Livers May be Considered for Photo-Documentation

- Livers rejected by procuring and/or local surgeons
- Livers considered for export out of region
- Livers with significant (>30%) macrosteatosis on biopsy
- Livers with fibrosis on biopsy
- Livers from donors who are at the extremes of height or weight
- Livers from elderly donors (>70 years of age)
- Livers with lacerations or any trauma
- Livers with unusual appearance

Photograph Equipment Requirements

- Any high quality standard digital camera with a removable memory card or camera phone is permissible provided the photos are uploaded directly onto UNETSM using a USB or similar link via a web-based computer. Flash photography is not recommended.
- The maximum file size for a single photo is 50MB.
- Attachments can be in many different file formats including: PDF, XLS, DOC, TXT, JPG, AVI, TIF, BMP. All files (images) except standard image formats [BMP, JPG, etc] will be converted to PDFs for cross-platform portability.
- Transmission of images using email is strictly prohibited and may be considered a violation of the Health Insurance Portability and Accountability Act (HIPAA).

Photograph Image Requirements

All photographs must include the donor's assigned DONOR ID and a sterile ruler. The DONOR ID can be written on the back of a sterile ruler. OPO staff should entitle images to correspond to the specific view as suggested below:

- ***In situ* Surgeon's View of Open Abdomen and Liver**
- ***In situ* Close-up view of the Inferior Edge and Left Lateral Segment.**
- ***Back bench* Whole View of Liver, Front**
- ***Back bench* Whole View of Liver, Back**
- ***Back bench* Close up View of Inferior Edge and Left Lateral Segment**
- Optional ***back bench*** photos including abnormalities and other noticeable findings

In Situ Surgeon’s View of Open Abdomen and Liver

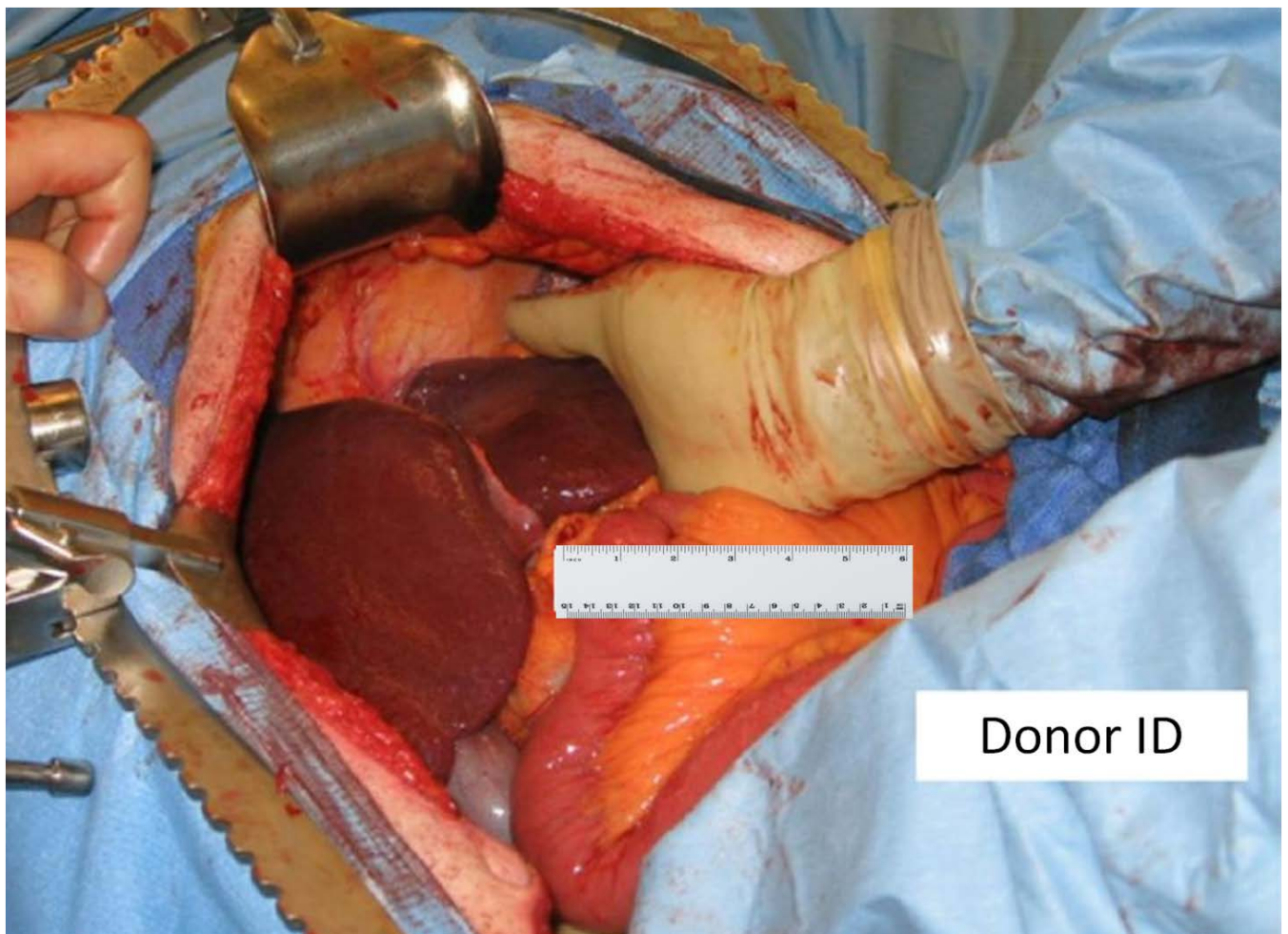
The first *in situ* photograph should provide a “surgeon’s view” of the liver from the donor’s right side. This should be obtained shortly after incision and placement of retractors.

Sterile ruler and DONOR ID should be in the photograph.

- If obtained by procuring surgeon: Surgeon should “over-glove” with sterile gloves.
- If obtained by OPO personnel: Request donor surgeon to step aside to allow closer; Take care to avoid contaminating the field.

If the donor is **UNstable**, OPO personnel should obtain photographs from the donor’s left side without interfering with procurement operation.

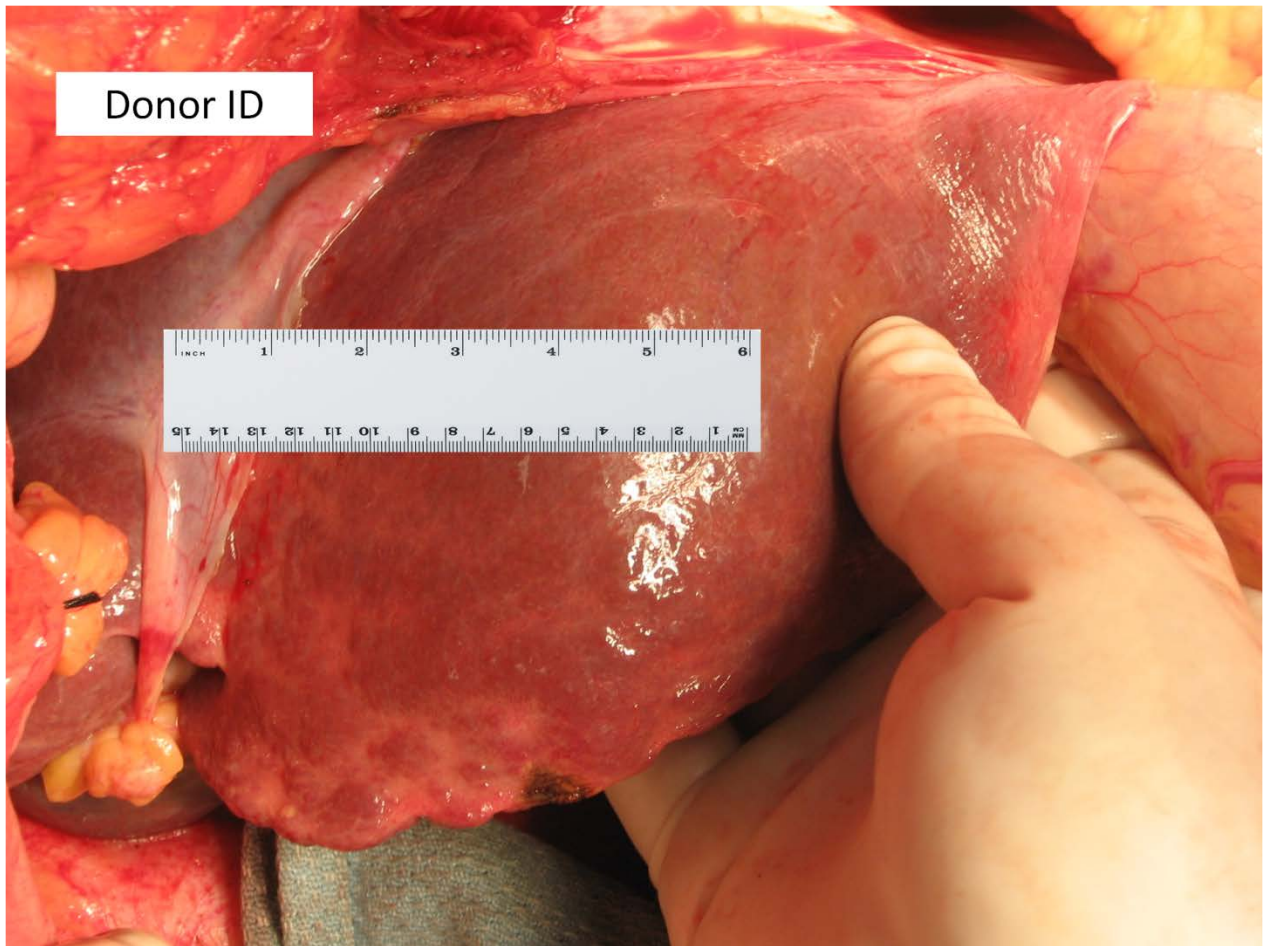
Picture 1: In Situ Surgeon’s View of Open Abdomen and Liver



In situ Close-up View of Inferior Edge and Left Lateral Segment

The second *in situ* photograph should provide a close-up view of the liver's inferior edge and include the left lateral segment. **Include sterile ruler and DONOR ID should be in the photograph.**

Picture 2: Close-up View of Inferior Edge and Left Lateral Segment

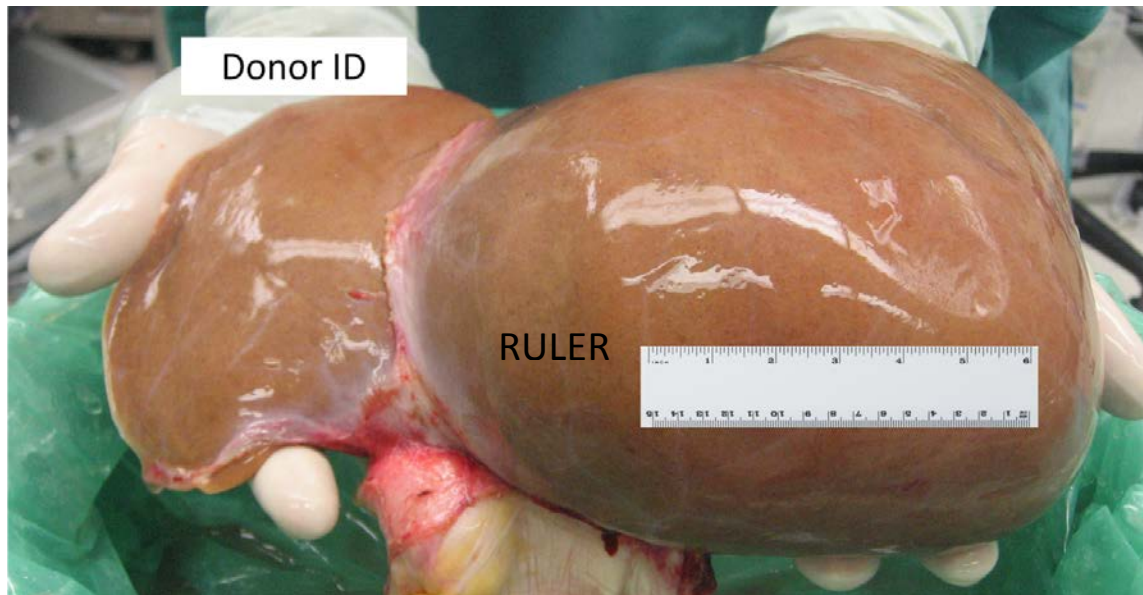


NOTE: OPO staff can UPLOAD *in situ* photographs as dissection proceeds

Back bench Whole View of Liver, Front

Once the liver is on the back-bench, two photographs of the entire liver should be quickly taken. Here is the FRONT VIEW. **Sterile ruler and DONOR ID should be in the photograph.**

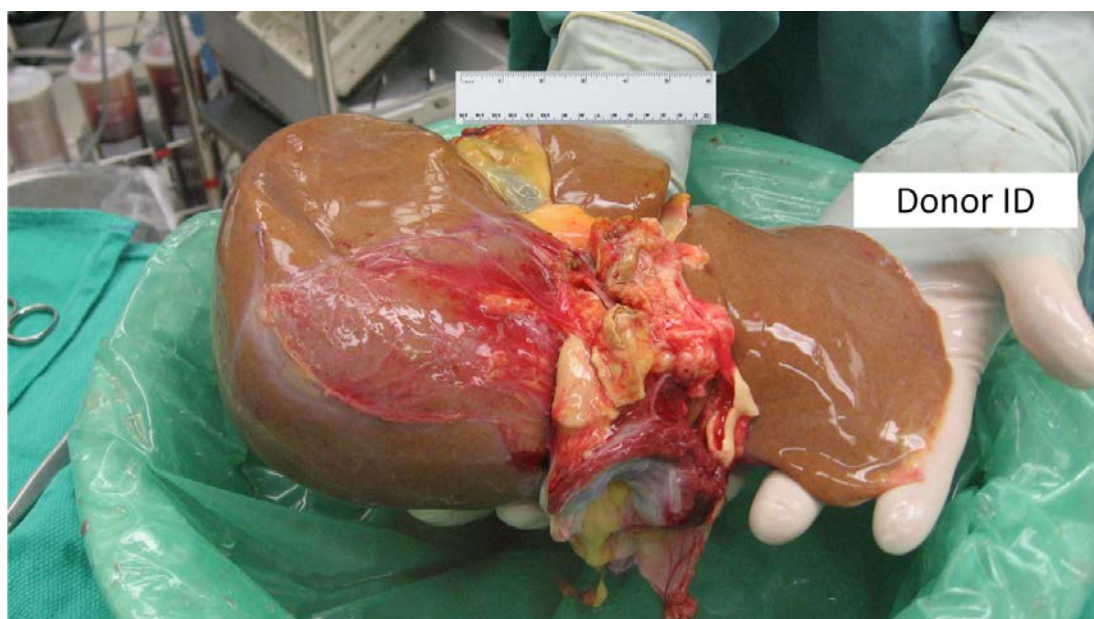
Picture 3: *Back bench Whole View of Liver, Front*



Back bench Whole View of Liver, Back

The next view should be a BACK view. **Include sterile ruler and donor DONOR ID.**

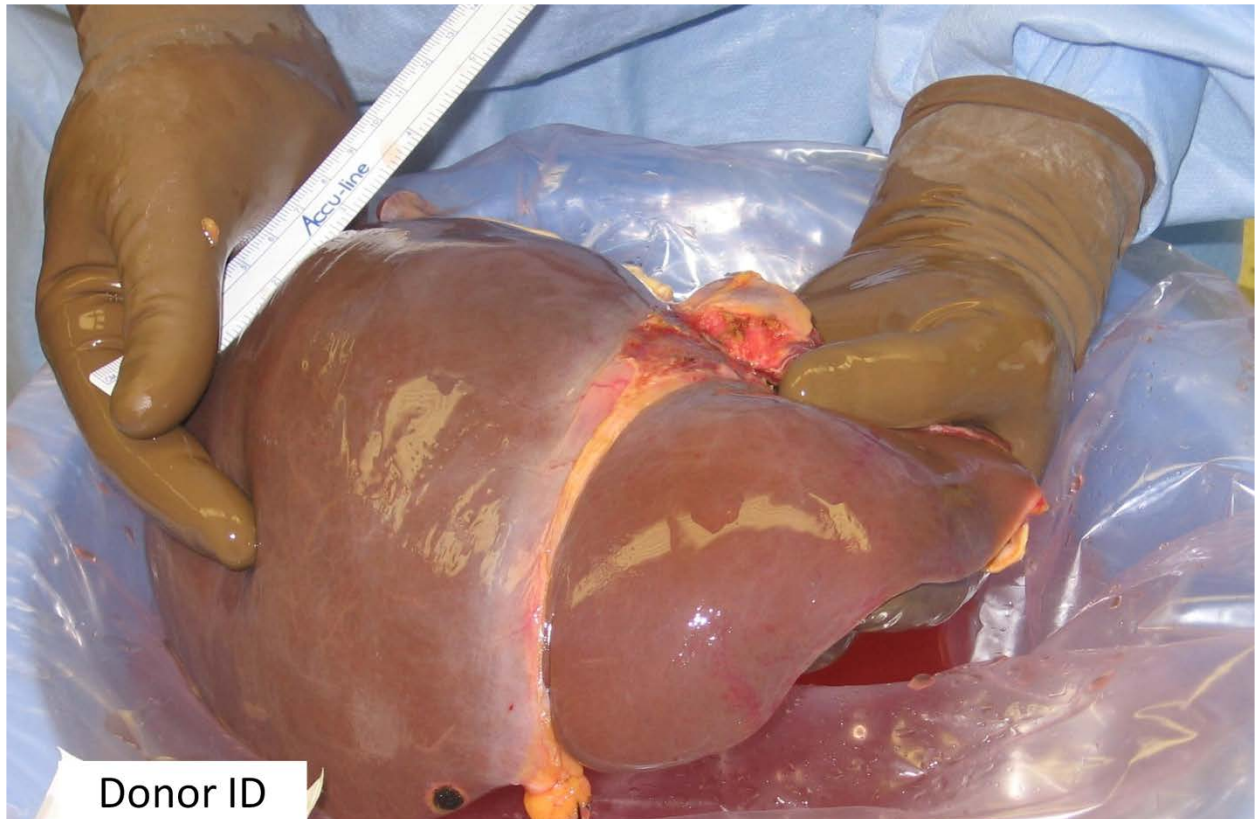
Picture 4: *Back bench Whole View of Liver, Back*



Back bench Close-up View of Inferior Edge and Left Lateral Segment

A close-up view of the liver's inferior edge, including the left lateral segment should be obtained. **Include sterile ruler and DONOR ID.**

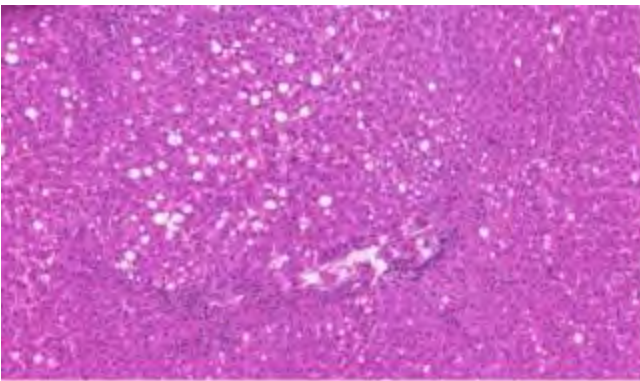
Picture 5: Back bench Close-up View of Inferior Edge and Left Lateral Segment



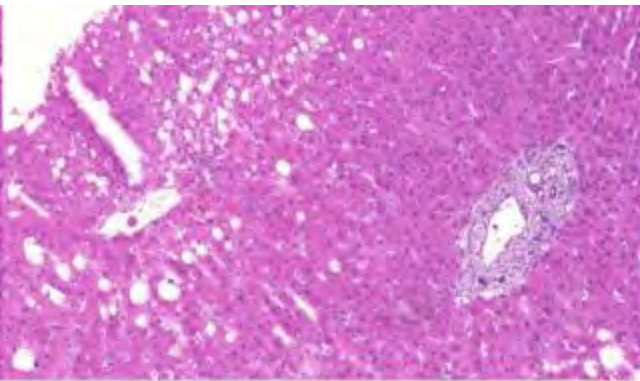
Optional Back bench Photos of abnormalities, trauma, and/or other noticeable findings.

Optional photographs are to be taken of any abnormal lesions, flush defects, traumatic or procurement injuries, severe atherosclerosis of the celiac axis or the SMA orifices, or other notable findings. **Sterile ruler and DONOR ID should be in the photograph.**

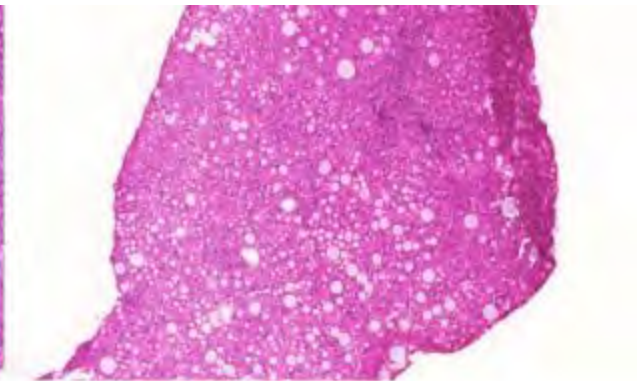
Donor Liver Steatosis Scale



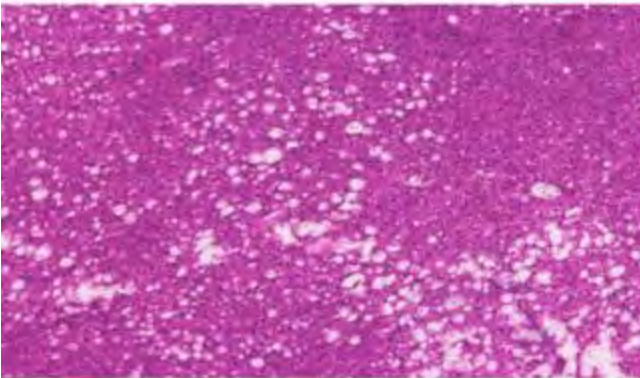
10



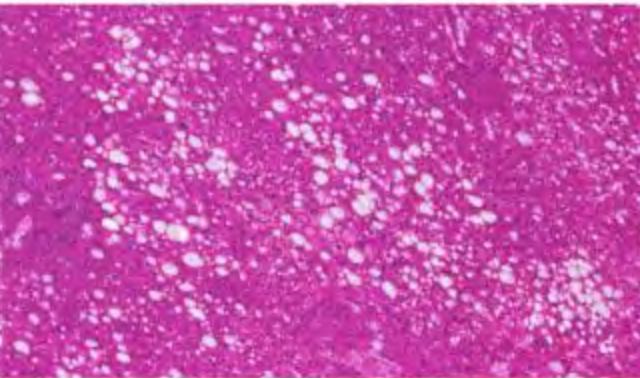
20



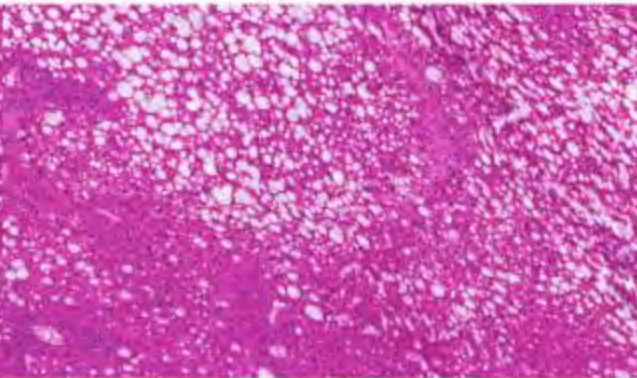
30



40



50



60