

CHAPTER




RECORDING LIVING AND POSTMORTEM FRICTION RIDGE EXEMPLARS

BRENT T. CUTRO, SR.

CONTENTS

3	4.1 Introduction	17	4.5 Summary
3	4.2 Equipment	18	4.6 Reviewers
5	4.3 Recording Fingerprints, Palmprints, and Footprints of Living Subjects	18	4.7 References
10	4.4 Recording Postmortem Friction Ridge Detail		





CHAPTER 4

RECORDING LIVING AND POSTMORTEM FRICTION RIDGE EXEMPLARS

BRENT T. CUTRO, SR.

4.1 Introduction

The skin is both the largest organ and the first line of protection in the human body. Completely covering the body from head to toe, the skin is primarily consistent in nature everywhere except for the areas covering the palmar surfaces of the fingers and hands and the plantar surfaces of the toes and feet. The skin on these areas is referred to as *friction ridge skin*. Obtaining legible recordings of these areas of skin is crucial for subsequent comparisons to latent impressions recovered from crime scenes, for comparison against previous records, or for input into automated fingerprint identification systems (AFIS).

Inked prints, record prints, standards, and exemplars are all terms that are used to describe the recording of these unique details.

4.2 Equipment

Various types of equipment, inks, scanning devices, and techniques are used to record friction ridge detail. Although the concept of recording friction ridge detail seems basic, care and determination should always be exercised in order to obtain the best quality recordings because complete and legible recordings are a necessity in latent print examinations.

The equipment that is needed to record friction ridge detail includes an ink roller, an inking plate (constructed of glass or a smooth metal, such as stainless steel), fingerprint or palmprint cards for recording the prints, and a quality black ink formulated for this purpose (Figure 4–1). These items can be obtained from various forensic or printing supply companies. Only inks formulated for forensic purposes should be used, because other types of inks (printer's ink, writing ink, or rubber stamp ink) are too light, too thin,

or do not dry quickly enough on the recording cards; this retained moisture could cause subsequent smearing of the prints. An alternative to the ink-and-roller method is the use of micro-reticulated thermoplastic resin pads or ceramic inking pads, both of which are impregnated with special permanent and nonfading inks. These products contain enough ink to record up to 50,000 fingerprints and should last approximately two years without replenishing. Cleanup is easy, and the ink dries quickly on recording cards (Olsen, 1978, pp 90–91). Advances in ink technology have improved certain characteristics of some of these inks, resulting in more user-friendly products.

A fingerprint stand is also useful. The fingerprint stand can be placed at a height that is necessary to comfortably record friction ridge detail while conveniently holding within its built-in storage bins all of the equipment needed for this purpose.

The standard cards that are used to record prints are 8" x 8". This size has space for two rows of five rolled fingerprints and space for plain or flat prints of the fingers under the rows of rolled prints. These cards are white and are usually lightweight cardboard or heavy paper stock. Fingerprint cards are handled countless times and may be stored in files for many years. For these reasons, the texture and strength of the card must be such that it will withstand frequent handling (Olsen, 1978, pp 59–60).

Figure 4–2 shows two rows of fingerprints (*rolled impressions*) in the center of the card. The blocks begin with the thumb of the right hand as #1, the right index finger as #2, and so on through the right little finger, #5. The left hand then begins with the thumb, designated #6, the left index finger is #7, and so on through the left little finger, #10. Another set of impressions would appear below these. They are referred to as *plain, flat, or simultaneous* impressions

FIGURE 4-1

Equipment and ink used to record friction ridge exemplars.



FIGURE 4-2

Two rows of rolled impressions in center of fingerprint card.

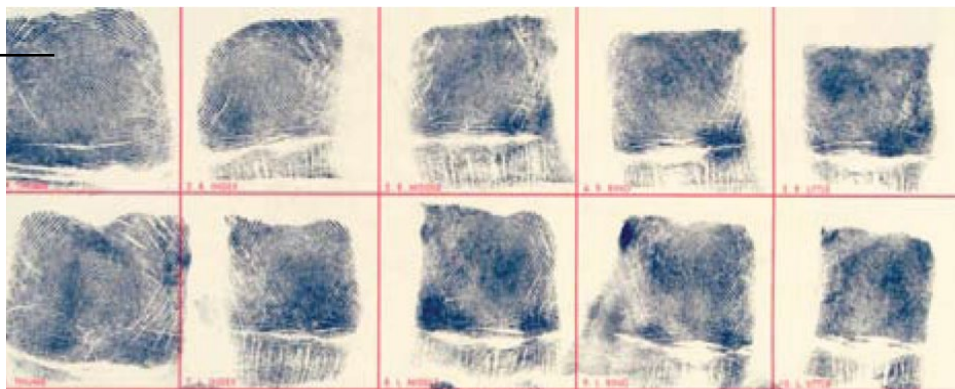



FIGURE 4-3

Completely recorded fingerprint card.

and serve as a verification of the finger sequence of the rolled impressions (Olsen, 1978, pp 60–62). See Figure 4–3.

In addition to the spaces for the fingerprint impressions, there is room on the card to record information about the person being printed (e.g., name, date of birth), information about the agency, and space for the date and signatures of the subject and technician.

Livescan technology replaces the process of using ink to record friction ridge detail. The friction ridge surfaces to be recorded are placed on a scanner that records the detail in a matter of seconds. High-resolution scanners can produce images that rival the quality of ink recordings, and the digital images are easily reproduced and distributed electronically. The process of rolling the finger impressions (and plain impressions) on the scanner platen is the same as for the actual recording of inked impressions on a card, but without the ink.

4.3 Recording Fingerprints, Palmprints, and Footprints of Living Subjects

Legible and completely recorded fingerprint cards, such as the one in Figure 4–3, are adequate for classification or comparison purposes and for scanning into AFIS.

4.3.1 Recording Fingerprints

The basic method of recording friction ridge detail on the hands or feet can be accomplished by applying a thin coat of black ink directly to the skin's surface using a roller or by coating an inking plate with the ink and rolling the fingers onto the plate. Next, the inked skin is pressed on a surface of contrasting color, such as a white piece of paper or a fingerprint card. The difference in elevation between the ridges and the furrows of the friction ridge skin leaves a print that is a recording of the unique detail of the friction ridge skin (Cowger, 1983, p 10).

To begin this process, if using the ink-and-roller method, a small amount of ink is deposited at the edge, center, and opposite edge of a thoroughly cleaned inking plate. The ink is then rolled and smoothed out. The ink should look black, not gray. A gray color means that there is not enough ink on the plate. The ink should not look wet. If the ink looks wet, too much ink has been placed on the plate, and this could result in a smearing of the print. After the proper amount of ink has been rolled onto the plate, the next step is to ink the fingers (Cowger, 1983, p 10).

Before any ink is applied to the fingers, the fingers must be inspected to ensure that they are clean and dry, because contaminants can interfere with proper recording. If the subject's fingers are too dry, a moisturizing hand lotion may be applied sparingly to soften the fingers. If the subject's fingers are too moist, they must be dried individually or,

in case of excess moisture, wiped with an alcohol wipe and then dried. Regardless of what method of recording is used (ink and roller, Porelon Pad, or scanning device), the fingers should be rolled away from the body, and the thumbs should be rolled toward the body (thumbs in, fingers out). This procedure allows the fingers and thumbs to be rolled from an awkward position to a more relaxed position and is less likely to produce smeared recordings. To completely roll each finger, with the subject standing in front of and facing the cardholder, the hand should be firmly grasped in such a manner that the finger is extended and the other fingers are out of the way. The inking plate and the cardholder should be side by side, with the cardholder nearest the operator (Olsen, 1978, p 66). The hand is then rotated so that the side of the finger can be placed on the inking plate. While one of the operator's hands grasps the hand of the subject, the operator's other hand holds the end of the finger or thumb being printed to keep it from slipping, to apply light pressure, and to guide the roll (Figure 4-4). Two key factors to remember are control and pressure (Cowger, 1983, p 11). For best results, the subject should not help with the process and should be asked to remain in a relaxed posture. The finger or thumb is then rotated 180° (i.e., nail edge to nail edge) and is immediately lifted from the plate and rolled in the same manner in the appropriate box on the fingerprint card that has been previously placed in the cardholder.

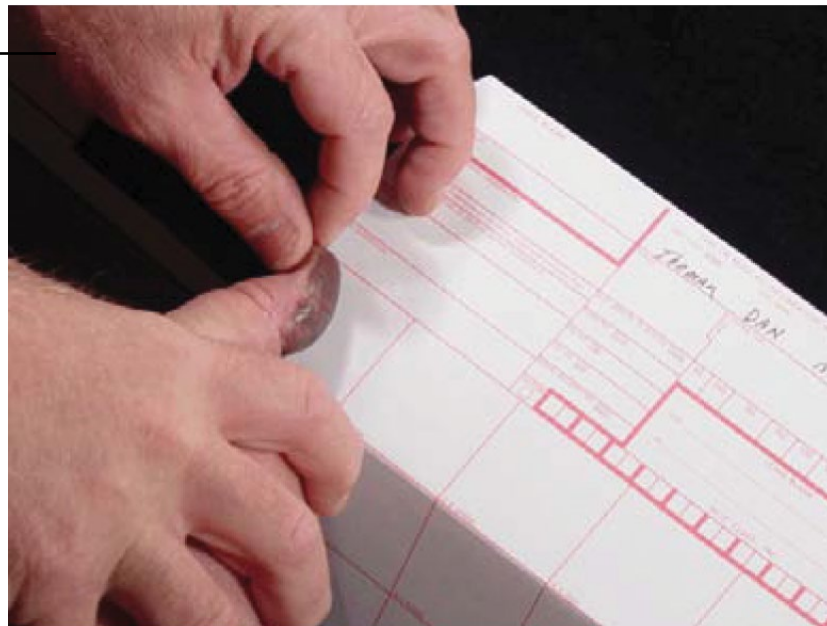
The fingers and thumbs should be rolled on the card or scanning device in the same sequence in which the spaces appear on the card, starting with the right thumb and ending with the left little finger (Olsen, 1978, p 66). The plain (i.e., flat or simultaneous) impressions are recorded by grouping the fingers from each hand and pressing them on the inking plate. The grouped fingers, numbers 2-5 and 7-10, are then pressed on the fingerprint card or scanning device in the appropriate boxes, taking care not to superimpose these impressions over the rolled impressions. The thumbs are inked and recorded separately in the same manner. The fingers and thumbs that are recorded in these boxes should not be rolled from side to side. As the fingers and thumbs are lifted from the card or scanning device, they should be rolled toward the tips of the fingers by keeping pressure on the fingers and lifting the subject's wrists so as to record as much friction ridge detail as possible toward the top of the pattern area.

4.3.2 Recording Palmprints

Palmprints are recorded in much the same manner as fingerprints; however, a cylindrical device is often used to facilitate the process to ensure complete recording of all friction ridge detail. The palms are not pressed on an inking plate. Rather, the roller is loaded with ink from the inking plate and the ink roller is used to apply a thin coat

FIGURE 4-4

Position of operator's hands.



**FIGURE 4-5**

Recording palmprint exemplars using a cylinder.

of ink directly to the hands from the base and edges of the palms to the tips of the fingers. Care must be exercised to ensure complete coverage of ink to all areas containing friction ridge detail.

To record palmprints, a standard 8" x 8" card or heavy plain white bond paper is attached to a cylinder approximately 3" in diameter. Removable adhesive tape or rubber bands may be used to attach the paper to the cylinder. (Some technicians prefer to let the paper "ride" across the cylinder without attaching it, taking care to prevent slippage.) The inked palm is then rolled either from the base of the palm toward the fingers or from the fingers to the base of the palm. Either way is acceptable and is generally left to the discretion of the technician. Most technicians prefer beginning at the base of the palm and rolling toward the fingers because this gives the technician more control over the subject and position of the print on the card (Olsen, 1978, p 74). The hand can simply be pulled rather than pushed across the surface, which also tends to help prevent lateral movement of the subject's hand. The palm must be recorded in one smooth, unceasing motion to prevent smudging or distortion (Figure 4-5). Light pressure should also be applied while rolling in order to maintain completeness and to adequately record the centers of the palms. (Extending the thumb to the side will also help eliminate voids in the center of the recorded palm.) The thumbs are recorded separately because of their position on the hand. The extreme side of the palm, opposite of the thumb, referred

to as the "writer's palm" (i.e., the edge of the hypothenar area), is also recorded separately on the palmprint card. The card is removed from the cylinder and placed on a hard flat surface. This area of the palm is then pressed on the palmprint card, with the little finger extended, to the right of the previously recorded palmprint for the right hand and to the left of the previously recorded palmprint for the left hand, if space allows. The thumb area of the palm (thenar area) is then recorded in the same manner and placed to the left side of the previously recorded right palmprint and to the right side of the previously recorded left palmprint, again, if space allows. If adequate space does not allow for the thenar and hypothenar areas to be recorded on the same card, separate cards should be used for these recordings.

An easy alternative method for recording palmprints is with the use of a white adhesive lifting material, such as Handiprint® (Kinderprint Co.), and black fingerprint powder. The fingerprint powder is lightly applied with a soft fingerprint brush to the entire surface of the palm. The adhesive material is separated from the backing and pressed onto the palm while smoothing from the center to the sides. The flexible adhesive conforms to the creases and crevices of the palm with minimal slippage, which aids in producing a high-contrast, completely recorded palmprint. The adhesive lifter is then peeled from the palm and placed onto a clear acetate cover, thus preserving the impression for subsequent comparisons.

4.3.3 Recording Major Case Prints

*Major case prints** (also referred to as *major criminal prints*) are a recording of all the friction ridge detail covering the hands. If necessary, this may also include a recording of all the friction ridge detail on the feet. In addition to legible and completely recorded fingerprints and palmprints, major case prints include a legible and completely recorded set of the tips of the fingers, from just below the nail to the center of the fingers, rolled from one side of the nail to the other, as well as completely recorded lower joints of the fingers, including the extreme sides. Major case prints are often required for comparison to unknown impressions that have been collected from crime scenes, and these impressions may include areas of friction ridge detail that are not routinely recorded.

To begin, a complete set of the subject's fingerprints should be recorded as previously described. Next, all of the remaining friction ridge detail on the phalangeal areas of the thumbs and fingers is recorded using 8" x 8" cards or white bond paper firmly attached to the edge of a table. Beginning with the right thumb, a thin coat of ink is applied to all of the friction ridge detail with an ink roller, from the base of the thumb to the tip, including the extreme sides

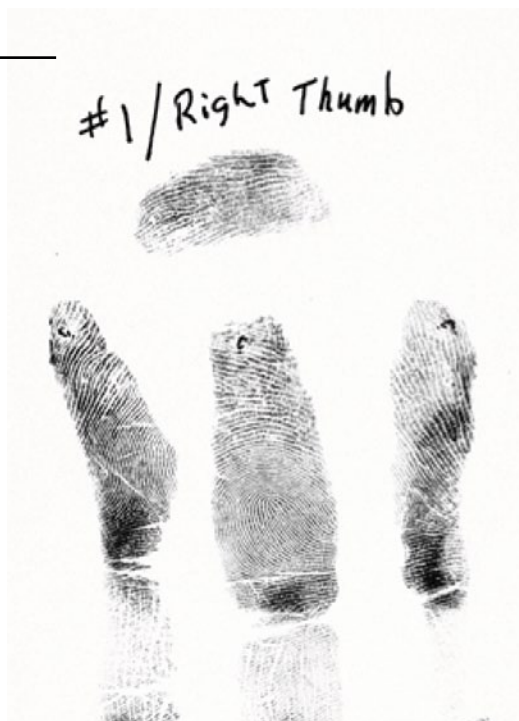of the finger. Usually beginning at the lower left corner of the paper, the extreme left side of the thumb is firmly pressed on the paper. The thumb is removed by lifting from the base of the thumb to the tip. This will record the extreme left side of the thumb and tip. Next to this impression, the center of the thumb is placed on the paper and is removed in the same manner, thus completely recording the friction ridge detail from the base of the thumb to the tip. The extreme right side of the thumb is then placed to the right of the center portion, thus recording the extreme right side of the thumb and tip. Lastly, above the three recorded areas of the thumb, the extreme left side of the tip of the thumb is placed on the paper and rolled to the extreme right side with one continuous motion. This group of recorded friction ridge details of the thumb should be labeled "#1," or "right thumb," above the rolled tip (Figure 4-6). This process should be repeated with the remaining four fingers of the right hand, moving counterclockwise around the paper.

Another method that is preferred by some latent print examiners is to roll the entire finger with one continuous motion from extreme side to extreme side, including the lower phalanges, to ensure continuity of the impression.

*The Scientific Working Group on Friction Ridge Analysis, Study and Technology (SWGFAST) has proposed a change in terminology from "major case prints" to "complete friction ridge exemplars" [SWGFAST, 2006, pp 619-627].

FIGURE 4-6

Friction ridge detail of right thumb from a set of major case prints.





The tip areas are also positioned and recorded above these impressions in the same manner.

This procedure is then repeated for the left hand. To complete the major case print process, a legible and completely recorded set of palmprints is then recorded in the previously described manner.

4.3.4 Recording Footprints

On occasion it may become necessary to record a subject's footprints. The same basic procedures as with recording palmprints are used; however, because of the large size of an adult foot, a larger cylinder and paper must be used.

The cylinder used for this process should be approximately 5" in diameter and should hold an 8.5" x 14" (legal size) sheet of heavy white bond paper attached to the cylinder, as previously described. The foot should be rolled across the paper in the same manner as the palmprints, in one smooth, continuous motion from the heel of the foot toward the toe, with the toes passing completely over the cylinder. Recordings of the feet may also be obtained by applying ink to the bottoms of the subject's feet with a roller and instructing the subject to walk across paper that has been laid out on the floor. This, however, requires cooperation from the subject and may not produce satisfactory recordings, because excessive pressure and movement of the feet may blur or smear the impressions. Another method (Olsen, 1978, p 75) is to mount a card or paper on a flat board. With the subject in a sitting position and with the leg elevated and supported, the paper is pressed against the subject's inked foot.

4.3.5 Unusual Circumstances

Problems ranging from temporary disabilities (e.g., wounds and blisters) to permanent disabilities (e.g., amputated fingers, extra fingers, webbed fingers, arthritis, or palsy) may be present when obtaining known standards. The occupation of the subject (e.g., brick layer) may also affect the ability to obtain legible recordings. In these cases, the friction ridge detail may be affected or worn to the point that a legible recording may be difficult. However, with patience, skill, and some ingenuity, it is possible to obtain satisfactory recordings.

Obtaining legible recordings from injured fingers or palms can be difficult, so a notation of any temporary disabilities (e.g., fresh cuts, wounds, bandaged fingers, or large blisters)

should be made in the corresponding block on the fingerprint or palmprint card. If classification or input into an AFIS database is necessary, however, it is advisable to defer recording the fingerprints of the subject, if possible, until after the temporary injury has healed.

Certain occupations can also pose problems to friction ridge skin, because people who consistently work with their hands tend to have worn, rough, dry, or damaged friction ridges on their fingers and palms, to the point that it is difficult to obtain legible recordings of their friction ridge detail. This problem may be overcome by applying skin-softening lotion to the hands and fingers prior to recording. In addition, applying a very small amount of ink to the inking plate (so as not to get ink into the furrows and to ensure that only the tops of the ridges will be covered) may improve the fine detail (FBI, 1979, p 127).

These same techniques are also useful when obtaining known standards from elderly individuals or small children with very fine ridge detail. The use of ice held against the friction ridge skin may also facilitate the recording of the fine detail (Olsen, 1978, p 83). On occasion, a subject's friction ridges may be so fine that the ink completely covers the ridges and furrows. In these cases, instead of using ink, using a brush to lightly dust the friction ridge skin with black fingerprint powder may be necessary to record the very fine friction ridge detail. White opaque lifting material (e.g., Handiprint®) with a transparent cover is then used to record the impressions directly from the fingers (Olsen, 1978, p 84). The finger numbers should be marked on the transparent covers to prevent any confusion and to ensure the correct orientation of the impressions. The lifts are then cut to fit inside the appropriate blocks on the fingerprint card and are secured with clear tape.

A notation of any permanent disabilities should be recorded in the appropriate block on the fingerprint card (e.g., "missing at birth" if the subject was born without certain fingers). In cases of amputation, a notation should be made in the appropriate block on the fingerprint card. If only a portion of the first joint of the finger is affected, it should be recorded as completely as possible and a notation should be made.

In cases of bent or disfigured fingers, the tools (e.g., special ink rollers or spatulas and a curved strip holder) that are used for obtaining prints from deceased individuals can be used to record the friction ridge detail.

If a subject has more than 10 fingers (polydactyly), the thumb and the 4 fingers next to the thumb should be recorded on the fingerprint card in the usual manner. Any remaining fingers should be recorded on the other side of the card, and a notation should be made. Webbed fingers (syndactyly) should be recorded as completely as possible, also with a notation on the card concerning this congenital abnormality (FBI, 1979, p 128).

4.4 Recording Postmortem Friction Ridge Detail

One of the most challenging, and also rewarding, aspects of latent print examination is the determination of the identity of deceased individuals. Various methods and techniques may be used to facilitate the successful recording and preservation of postmortem friction ridge detail. In circumstances involving unknown deceased infants, it is often necessary to obtain postmortem footprints, because hospital personnel usually record only footprint standards of newborn babies.

When decomposition, desiccation (dryness), or maceration (separation and softening of skin by soaking in liquid) of the friction ridge skin precludes satisfactory recordings with traditional methods, the hands, fingers, or feet of the deceased may be surgically removed by a medical examiner and submitted to a laboratory, where advanced procedures may be conducted.

Many techniques have been developed to effectively process postmortem friction ridge skin. It is important to

realize that successful development, recording, and individualization of an often small area of available friction ridge skin could be the most valuable lead in solving a homicide case or in providing closure to a grieving family. Therefore, the latent print examiner must have experience and knowledge in this area. The condition of the friction ridge skin will dictate the various methods and techniques that should be used to successfully record valuable friction ridge detail.

Recording the friction ridge detail from deceased individuals can, at times, present quite a challenge. Satisfactory recordings of recently deceased individuals can most often be performed much like recording the prints of live individuals, utilizing some specific tools to facilitate this process. Obtaining recordings of friction ridge detail from skin that is decomposed, mummified, charred, or macerated, however, may be much more difficult.

4.4.1 General Recording of Recently Deceased Subjects

If the hands are in reasonably good condition, obtaining satisfactory recordings of the friction ridge detail from the fingers is usually accomplished by straightening the fingers and flattening the palm. To facilitate this process, the deceased should be positioned with the face and palms down on a table (prone position) (FBI, 1979, p 136). The fingers and palms should be clean and dry. If rigor mortis (stiffening of the muscles) has set in, it is possible to break the rigor by forcibly straightening the digits, which can then be recorded by using equipment intended for this purpose (e.g., a spoon-shaped tool, as seen in Figure 4–7). As always, prior to handling any type of biohazardous material,

FIGURE 4–7

A spoon-shaped tool with fingerprint card used for postmortem friction ridge recording.





care should be taken to ensure that personal protective equipment (e.g., gloves, face mask, and eye protection) is worn at all times.

If only the fingers are of concern, it is possible to print them by pressing on the finger just above the knuckle. This will straighten the finger and separate it from the others, facilitating proper recording. The palm can be recorded by bending it forward at the wrist. It may be possible to obtain adequate recordings by recording various areas of the palm separately (Cowger, 1983, p 29). If rigor mortis is present, “It is better to take advantage of this condition than to try to overcome it, by bending the wrist still further toward the inner forearm and pressing the fingers one at a time toward the palm or wrist. In this position, they separate and straighten out in such a way that each finger can be printed without interference” (Olsen, 1978, p 85). “If breaking rigor is difficult or ineffective, or if the hand is so curled that the fingers or palm will not straighten sufficiently when pressed inward, it may be necessary to cut the tendons which cause the curling to occur” (Cowger, 1983, p 29). (It is advisable that only legally designated persons perform this activity, because there are restrictions in some jurisdictions concerning the dissection of human remains.)

There are many satisfactory methods of applying ink to the fingers of a deceased individual. One method is to use a spatula that contains a thin coat of ink that has been applied by an ink roller. The ink is then transferred to the fingers by manually rolling it around the fingers. A standard fingerprint card may then be cut into two strips of five blocks or into single blocks. A strip holder or spoon is used to hold the strip. The strip or block is then placed in the spoon with the top of the strip toward the handle of the spoon. The inked fingers are then rolled in their corresponding blocks from nail edge to nail edge, as previously described. This procedure is repeated on different strips until legible impressions are obtained. If individual cards are used, it is advisable to have more than 10 squares cut and ready in case some of them are ruined or the pattern area is not completely recorded (Olsen, 1978, p 86). Another method for extremely difficult cases is to use black fingerprint powder and white adhesive lifting material such as Handiprint®.

4.4.2 Recording Decomposed Friction Ridge Skin

Putrefied skin (skin that is in a state of decomposition or rotting) is fragile. Such putrefaction is usually a result of various biological factors such as bacteria, fungi, or fermentation. Parasites may have also infiltrated this necrotic tissue. Extreme care should be exercised when examining and handling this fragile friction ridge skin.

If, upon examination, friction ridge skin is present, discernible, and not badly damaged, it may be possible, using extreme care, to simply ink and record the friction ridge skin. However, if the friction ridge skin is rubbery and is separating from the underlying tissues or is too fragile for the technician to apply ink in the usual manner, the friction ridge skin may be removed from the underlying tissue. The skin must then be cleaned and dried and may be recorded by placing each finger, or friction ridge skin, over the technician’s gloved finger or palm to ink and record as if the friction ridge skin were the technician’s. As always, care in documenting which fingers are recorded is important. It is also recommended to photograph the visible ridge detail prior to any technique that may cause further deterioration of the friction skin.

A 10–15% soaking solution of formaldehyde may be used in extreme cases to firm up the skin to facilitate this process. Formaldehyde, however, can cause the skin to become very firm and brittle, causing the skin to split. The skin should soak for an hour or so until sufficiently firm. Once hardened, the friction ridge skin should be removed, patted dry, and recorded (FBI, 1979, pp 143–144). Another similar method suggests soaking the fingers or friction skin in 10% formaldehyde solution for several hours. The skin is then rinsed gently with running water, rinsed in laboratory-quality isopropanol to remove any excess moisture, patted dry, and recorded as previously described (Miller, 1995, p 603).

In many cases, especially if the decomposition is advanced, discernible friction ridge detail may not be present because the top layers of friction ridge skin may be completely decomposed or destroyed. In these instances, the bottom layers or underside of the friction ridge skin, as well as the dermis, may reveal discernible friction ridge detail and can be recorded successfully.

One method that is used to record the underside of friction ridge skin is lightly coating the underside of the epidermal layer of the friction ridge skin with fingerprint powder before applying ink. The underside of the friction ridge skin is then rolled on a section of the adhesive side of fingerprint lift tape (Rice, 1988a, p 100).

To proceed, the friction ridge skin must be completely dried by placing the skin between paper towels. With the underside of the epidermal layer of the skin exposed, it is lightly dusted with black fingerprint powder and positioned over the technician's own gloved finger. The skin is then coated using an ink roller in the usual manner or rolled on an inking slab that has been coated with ink to apply a thin, even coat of fingerprint ink. The fingerprint powder is necessary to facilitate removal of the skin from the tape. The skin is then rolled across the adhesive side of a section of transparent or frosted fingerprint tape. It is important to note that the impression resulting from this method on the adhesive side of the tape will be in the correct orientation for comparison when placed adhesive-side down in the appropriate block on the fingerprint card, or, if recording palms, on the palmprint card. The impressions will be tonally reversed (white ridges) because the furrows (valleys), as opposed to the ridges, will be inked and recorded. If necessary, tonal reversal can be corrected photographically (Rice, 1988a, pp 98–100).

If the friction ridge skin is too brittle to attempt the previously described methods, the underside of the friction ridge skin may be photographed. To accomplish this, "it may be advisable to trim the skin, flatten it out between two pieces of glass, and photograph it in that position" (FBI, 1979, p 144).

The skin is trimmed by carefully and meticulously removing the excess flesh by scraping, cutting, and trimming until only the friction ridge skin remains and can be flattened satisfactorily between two pieces of glass. Another method to further enhance friction ridge detail is to use transmitted lighting. This is accomplished by shining a light through the skin toward the lens of the camera when photographing. If the skin is still not transparent enough, soaking the skin in xylene for approximately five minutes before photographing or keeping the skin immersed in xylene while photographing is recommended. Once a suitable photograph is obtained, the negative may be printed as necessary to provide correct orientation

of the impression for subsequent comparison to known standards (FBI, 1979, pp 145–147).

4.4.3 Recording Macerated Friction Ridge Skin

Maceration occurs when friction ridge skin is immersed, usually in water, for an extended period of time. The epidermal layer absorbs water, often swells, and can loosen from the dermis within a few hours after immersion (FBI, 1979, p 151).

If the friction ridge skin is not too badly damaged, the skin should be carefully cleaned, wiped with alcohol, and recorded as previously described for recently deceased subjects. If the skin has separated from the dermal layer and is wrinkled, it may be possible to pull the skin from the back of the finger to smooth out the pattern area by pinching the skin tightly. This will facilitate inking and recording (FBI, 1979, p 151). Stretching of the friction ridge skin in this manner may also facilitate the recording of palmprints and footprints.

It is important to note that this type of process may enlarge the pattern area of the fingers, which may be significant when conducting an AFIS search with some systems. The epidermis from a "de-gloved" hand can be as much as 33% larger than the dermis. For this reason, if an AFIS search does not reveal an individualization using the original recording, the print should be searched again at 70% of its original size (Leas, 2006).

In such instances when the skin is wrinkled but not pliable, thus not allowing the skin to be stretched smoothly across the pattern area, tissue builder or glycerin may be injected into the bulb of the finger to round out the pattern area. A string tied just above the injection site will help prevent the fluid from escaping. Often, the skin may be loose and somewhat damaged yet have most of the pattern area still intact. If this is the case, the friction ridge skin should be carefully removed, cleaned, and placed in alcohol for about one minute. The skin is then carefully placed over the technician's gloved finger to facilitate inking and recording (FBI, 1979, p 151).

As always, friction ridge detail may also be photographed on the finger or cut and prepared, as previously described for decomposed friction ridge skin, to be placed between two pieces of glass and photographed with reflected or transmitted light. If no discernible friction ridge detail is present on the outer layers of the epidermis, it is possible

**FIGURE 4–8**

Photographs of macerated hand before (top hand) and after (bottom hand) “boiling” treatment.

(Photo courtesy of the FBI Disaster Squad.)

that the underside of the epidermis or the top of the dermis may be recorded or photographed, as described previously for decomposed friction ridge skin.

For situations in which the epidermis is missing or has been totally destroyed because of prolonged immersion in a liquid, a method known as osmotic rehydration (the boiling method) can produce very satisfactory results. This method produces the best results when used on hands or feet that are soft and pliable, with no epidermis present, and with the ridges of the dermis appearing flat. The hot water plumps the dermis, thus facilitating the recording of the ridges. To proceed, water is heated in a pot to just below boiling point (~200 °F) and maintained at this temperature. The friction ridge skin being processed is immersed in the heated water for 10 seconds. A shorter time is recommended for fine ridge detail (e.g., as children have) or where advanced decomposition is present. A longer time, up to 30 seconds, may be necessary at the examiner’s discretion. The raised friction ridge detail should be carefully cleaned, if necessary, with a soft-bristled toothbrush and water in the direction of the ridge flow, wiped with alcohol, and lightly dusted with black fingerprint powder. A white adhesive lifting material is then used to record and preserve the friction ridge detail (Leas, 2006) (Figure 4–8).

4.4.4 Recording Desiccated Friction Ridge Skin

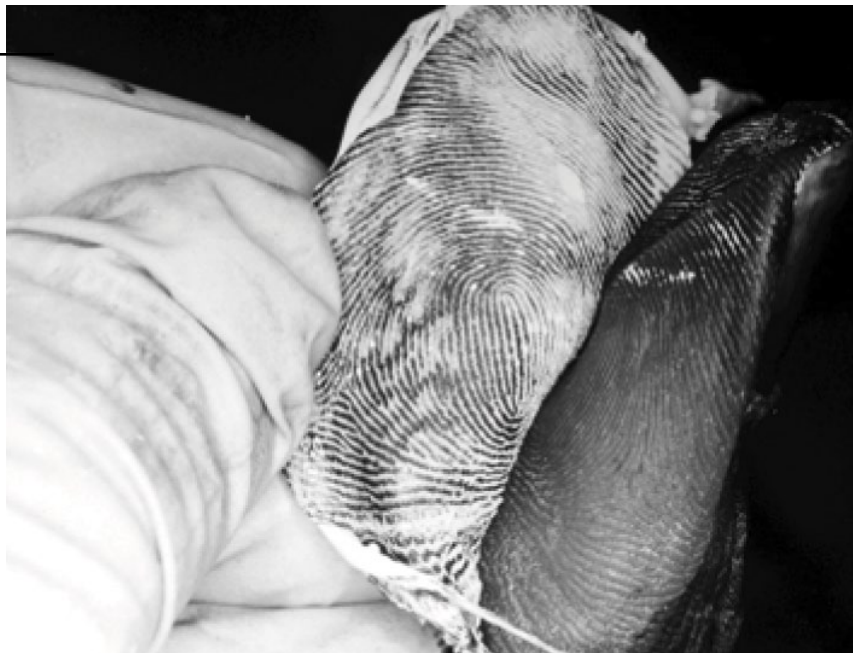Traditional methods to obtain recordings of friction ridge detail from desiccated skin usually involve removing the

hands or feet and subjecting the skin to many hours of potentially destructive chemical rehydration soaking and softening techniques. Although these methods work well to rehydrate the friction ridge skin, and will be discussed in further detail, a much less destructive and time-consuming method is available. This method involves the use of a silicone product (Mikrosil) to successfully record friction ridge detail that has been subjected to various types of destructive conditions such as desiccation, hardening, or wrinkling. Removal of the hands or feet is not always necessary, and this procedure may be accomplished at the mortuary or morgue.

To begin, the friction ridge skin must be cleaned and dried. The fingers should be separated to keep the silicone casts from sticking together. A light coat of black fingerprint powder is applied with a soft fingerprint brush to the friction ridges. The casting material is then mixed according to the included instructions and applied to each finger or other areas of friction ridge skin. After approximately 15 minutes, the casts are peeled off one at a time and marked accordingly, thus revealing a “high contrast, highly detailed, three-dimensional mold” (Tomboc and Schrader, 2005, p 473) (Figure 4–9). These silicone casts may then be photographed and preserved. When the casts are examined, the friction ridge details will be black and will be in the same orientation as if they had been recorded on a fingerprint or palmprint card. On severely damaged or decomposed friction ridge skin, Greenwop powder, which fluoresces under ultraviolet light, and black casting material may also be used. The resulting casts are then photographed using ultraviolet

FIGURE 4–9

Cast being removed from finger. (Reprinted from Tomboc and Schrader, 2005, p 478.)



light (Tomboc and Schrader, 2005, p 474). If this method should fail to produce discernible friction ridge detail, the traditional methods of rehydration and softening must be implemented. Once the skin is rehydrated and softened, the Mikrosil method may be used subsequent to the traditional methods to facilitate satisfactory recordings of any restored friction ridge detail.

4.4.5 Traditional Rehydration Method

This method is used primarily when extreme drying and dehydration of the friction ridge skin has caused excessive shriveling and wrinkling of the tissues, thus precluding sufficient recordings using less destructive methods. Individual fingers or toes should be placed in separate 75 mL capped bottles, nail-side down. The bottles should be labeled with the subject's name, case number, and the finger or toe number. Photographs should be taken of any friction ridge detail prior to the rehydration process, because this procedure is potentially destructive to the tissues.

It is advisable to start with one finger before processing the remaining fingers, in order to determine the degree of destruction caused by the process. The 75 mL capped bottles are filled with enough 1% to 3% sodium or potassium hydroxide (FBI, 1979, pp 147–148) solution to cover the friction ridge detail. The capped bottles are refrigerated for approximately 24 to 48 hours (Rice, 1988b, p 153). Each bottle should be checked every 4 to 6 hours for excessive destruction. The friction ridge detail is checked periodically

until the inner layers of skin are pliable such that the skin will give slightly under pressure. As previously mentioned, sodium and potassium hydroxide solutions are destructive to the tissues and will cause shedding of some of the outer layers of friction ridge skin. The outer layers of the friction ridge skin may be removed by gently brushing the skin (in the direction of the ridge flow) under warm running water with a soft-bristled toothbrush containing powdered hand cleaner. If the ridge detail is prominent, and the friction ridge skin is soft and pliable, the skin is then ready to be recorded. At this point, the epidermis should be white and soft. If, however, the friction ridge skin appears flat and stiff, it may then be soaked in a solution of dishwashing liquid and water in the same manner as with the hydroxide solution. (If this step is needed, one tablespoon of the dishwashing liquid should be placed in the 75 mL jar with enough warm water added to cover the friction ridge detail.) The friction ridge skin should soak at room temperature for approximately 24 to 48 hours, again being checked every 4 to 6 hours. This process may also cause further shedding of the tissues, which should be removed using a soft-bristled toothbrush, as described previously.

Once the friction ridge skin is soft and pliable with prominent and discernible friction ridge detail, the friction ridge skin is ready to be recorded. The length of time the skin should soak in these solutions depends on the extent of desiccation. However, if left too long, the friction ridge skin could potentially be destroyed (Rice, 1988b, pp 152–155).

**FIGURE 4–10**

Lifting sheet is placed on top of duct seal. (Photo courtesy of the FBI Latent Print Unit.)

4.4.6 Recording Rehydrated Friction Ridge Skin

Although the rehydration process should cause the friction ridge skin to become soft and pliable, the loose and wrinkled friction ridge skin may make recording difficult with some methods. As always, to avoid confusion, the fingers should be recorded one at a time. The previously described method of recording rehydrated friction skin (Tomboc and Schrader, 2005, pp 471–479) has been found to be successful after rehydrating with traditional methods. However, another procedure (Rice, 1988b, pp 152–155) involves the use of tissue builder or glycerin to “fill out” the friction ridge skin by carefully injecting the material into the tip of the finger, from the nail side toward the center of the finger, after the skin has been rehydrated.

To begin, the fingers should be tied with string around the distal phalangeal joint (first joint) to prevent the material to be injected from escaping. Enough material is injected into the finger to round out the friction ridge skin, enabling successful recording. A locking hemostat is then clamped to the finger as an extension of the finger to facilitate the recording process. The finger must now be completely dry for proper adhesion of the fingerprint ink. To accomplish this, the finger should be gently dried with paper towels and lightly dusted with fingerprint powder. Excess moisture and powder may be removed by rolling the finger on paper towels until the fingers are sufficiently dry. The friction ridge skin is then coated with a thin layer of fingerprint

ink, either by rolling on an inked plate or by rolling ink on the friction ridge skin with an ink roller. The finger is then recorded in the usual manner by applying light pressure to the nail side of the finger while rolling it on an index card or other suitable recording card. This process should be repeated until satisfactory results are obtained. The recorded prints are then placed in the appropriate blocks on a standard fingerprint card.

If satisfactory results cannot be obtained using this ink-and-roll method, it is possible to obtain satisfactory recordings using powder and lifting tape (Rice, 1988b, p 155). A light dusting of black fingerprint powder is applied to the friction ridge detail. A piece of lifting tape is then placed on the friction ridge detail at one side and lightly pressed over the friction ridge detail to the other side while smoothing. The tape is then removed and placed on a piece of clear Mylar-type plastic. One might also use white opaque lifting sheets with a transparent cover (Olsen, 1978, p 98).

Putty can serve as a cushion on which to roll the finger. Putty (i.e., duct seal) is moldable and nondrying. (It is used in plumbing and electrical work and is available in hardware stores.) A ball of duct seal is placed on the working surface and flattened. A piece of a lifting sheet is placed on top of the duct seal and the powdered finger is rolled onto the lifting sheet (Figures 4–10 and 4–11). The duct seal allows the lifting sheet to mold into the extreme wrinkles of the finger, creating a fingerprint impression of the entire area of the finger (Figure 4–12).

FIGURE 4–11

The powdered finger is rolled onto the lifting sheet. (Photo courtesy of the FBI Latent Print Unit.)



FIGURE 4–12

Postmortem fingerprint on lifting sheet. (Photo courtesy of the FBI Latent Print Unit.)



Regardless of the tape that is used, the recorded impression is now placed in the appropriate block (adhesive-side up) on the fingerprint card with the correct orientation. (When using transparent fingerprint tape, if the recorded impression were to be placed adhesive-side down on the fingerprint card, the fingerprint impression would be reversed.) The clear lift should then be marked directly on the lift with the correct orientation, finger number, and all other appropriate markings.

4.4.7 Recording Charred Friction Ridge Skin

On occasion, it may be necessary to obtain recordings of friction ridge detail that has been subjected to intense fire. Charring of the skin can occur, producing very brittle, often easily destroyed skin. Care must be exercised not to destroy the epidermal layer of friction ridge skin should removal of the hands or feet become necessary. As a worst-case scenario for severely charred skin, photography of any discernible friction ridge detail using oblique (side-to-side) lighting may be the only method that will produce satisfactory results (FBI, 1979, p 150).



The correct procedure to record friction ridge detail that has been subjected to desiccation and charring will be determined by the level of destruction to the friction ridge skin. Fortunately, in some cases, the friction ridge skin on the fingers and palms is somewhat protected by the tightening of the flexor muscles, ligaments, and tendons in the hands and arms which, as a result of intense heat, draw the fingers into a tightly clenched fist (pugilistic attitude). Intense heat also tends to cause a separation of the epidermal layer from the dermal layer of the friction ridge skin.

One method involves completing the separation of the epidermal layer from the dermal layer of the skin through refrigeration (Rice, 1992, pp 18–25). To facilitate inking and recording, an ink roller is used to deposit a thin coat of ink onto the pattern (ridge side) of the skin. The skin is then flipped over and rolled on the backside, recording the friction ridge detail on a standard card.

To begin this procedure, the hands (or feet) are removed by a medical examiner or pathologist and placed into separate containers labeled with appropriate markings. The containers are then refrigerated for approximately 5 to 7 days, checking each day for skin separation. When the skin separates, it is milky-white and looks “like a wrinkled latex glove that is one size too large for the wearer” (Rice, 1992, p 19). Subsequent to the removal of the skin, any loose, charred flesh or foreign material should be carefully removed by lightly brushing with a soft-bristled toothbrush to expose as much discernible friction ridge detail as possible. In addition, examinations should be conducted separately to prevent any mix-up of friction ridge skin. The friction ridge skin is then removed from the palms by carefully cutting along the outer edges with curved-tip scissors. Incisions are also made at the base of the palms, the base of the fingers, and at the base of the thumbs. Friction ridge skin from the feet is removed by making incisions along the outer edges of the feet, at the base of the heels, and at the base of the toes.

The connecting tissue between the epidermal and dermal layers is then carefully cut with scissors pointed away from the skin. The epidermal layer of the skin is then lifted away from the dermal layer. The separated friction ridge skin is then immersed in warm water for a few seconds and is laid flat to enable further gentle cleansing. A small amount of dishwashing liquid is applied to a very soft-bristled toothbrush,

which is then very carefully used to clean out any remaining debris by brushing in the direction of the ridge flow to prevent damage to the ridges. During this process, the skin should be rinsed frequently in clean, warm water. After the skin is sufficiently cleaned and rinsed, it should be carefully blotted dry with paper towels.

To record the friction ridge detail from this skin, an ink roller is lightly coated with ink using an inking plate in the same manner as when recording inked standards from a live person. The friction ridge skin to be recorded is then placed on a hard flat surface, ridge-side up. With gentle pressure, and while the skin is held in place, the ink is rolled onto the skin. The skin is then flipped over, ridge side down, onto a standard 8” x 8” recording card, and while the skin is held in place, the roller is then gently rolled across the skin, pressing the ink onto the card. This method should be repeated until a satisfactory recording is produced.

Fingers and toes can also be recorded in this manner, taking care to remove, label, and examine them separately to prevent confusion. To remove the friction ridge skin from toes and fingers, incisions at the base of the digits, along the extreme sides, and around the insides of the nail are recommended, being careful not to damage any of the pattern areas. The friction ridge skin is then removed by cutting the connecting tissue starting from the base, as with removal of the palm areas. Cleaning, drying, inking, and recording are performed in the same manner as previously described (Rice, 1992, pp 18–25).

4.5 Summary

The methods and techniques described in this chapter for recording living and postmortem friction ridge detail are appropriate for the vast majority of conditions and circumstances. However, it is possible that an unusual circumstance will arise that may require extra patience and skill to achieve the most desirable results. Quality recordings from live subjects are usually not too difficult to obtain, as long as the subject is cooperative. Recording postmortem friction ridge detail, however, may become more of a challenge because of the varying conditions of the friction ridge skin. There are also many levels of difficulty associated with this endeavor, which is why proper training, experience, and determination are essential.

4.6 Reviewers

The reviewers critiquing this chapter were Herman Bergman, Patti Blume, Mike Campbell, Sue Mancini Coppejans, Robert J. Garrett, Laura A. Hutchins, Bridget Lewis, Michelle L. Snyder, Lyla A. Thompson, Juliet H. Wood, and Rodolfo R. Zamora.

4.7 References

Cowger, J. F. *Friction Ridge Skin, Comparison and Identification of Fingerprints*; Elsevier Science Publishing Company: New York, 1983.

Federal Bureau of Investigation, U.S. Department of Justice. *The Science of Fingerprints*; U.S. Government Printing Office: Washington, DC, 1979.

Leas, R. L. Program Manager, FBI Disaster Squad—Victim Identification Unit, Quantico, VA. Personal communication, 2006.

Miller, R. D. Recovery of Usable Fingerprint Patterns from Damaged Postmortem Friction Ridge Skin. *J. Forensic Ident.* 1995, 45 (6), 602–605.

Olsen, Sr., R. D., *Scott's Fingerprint Mechanics*; Charles C Thomas: Springfield, 1978.

Rice, K. A. Printing of the Underside of the Epidermal Surface of Decomposed Fingers. *J. Forensic Ident.* 1988a, 38 (3), 98–100.

Rice, K. A. The Re-Hydration and Printing of Mummified Fingers. *J. Forensic Ident.* 1988b, 38 (4), 152–156.

Rice, K. A. Printing the Deceased Who Have Been Subjected to Fire. *J. Forensic Ident.* 1992, 42 (1), 18–25.

Scientific Working Group on Friction Ridge Analysis, Study and Technology. Special Notice—Name Change for Major Case Prints to Complete Friction Ridge Exemplars. *J. Forensic Ident.* 2006, 56 (4), 619–627.

Tomboc, R.; Schrader, M. Obtaining Fingerprint and Palmprint Impressions from Decomposed Bodies or Burn Victims Using the Mikrosil Casting Method. *J. Forensic Ident.* 2005, 55 (4), 471–479.