

# HEAD INJURY

STUDENT NAME: \_\_\_\_\_

WHEN, WHERE, HOW INJURY OCCURRED, COMPLAINTS REGARDING PAIN AND FUNCTION

TIME OF INCIDENT: \_\_\_\_\_

DATE: \_\_\_\_\_

ARRIVAL TIME IN HEALTH OFFICE: \_\_\_\_\_

DEPARTURE TIME AND DISPOSITION: \_\_\_\_\_

SIGNATURE: \_\_\_\_\_

Record assessments & interventions by circling Yes, No, & intervention done, plus filling in blanks.

GLASGOW COMA SCALE		INITIALS & SIGNATURE		DATE	
1. BEST EYE OPENING	Spontaneous	4			
	To voice	3			
	To pain	2			
	None	1			
2. BEST VERBAL RESPONSE	Oriented	5			
	Confused	4			
	Inappropriate words	3			
	Incomprehensible sounds	2			
3. BEST MOTOR RESPONSE	Obeys commands	6			
	Localizes pain	5			
	Withdraws to pain	4			
	Flexes to pain	3			
GLASGOW COMA SCALE TOTAL					
PUPILS		INITIALS & SIGNATURE		DATE	
RIGHT	SIZE				
	RESPONSE				
LEFT	SIZE				
	RESPONSE				

\* PRE-VERBAL  
 5 Smiles, coos, cries appropriately  
 4 Cries  
 3 Inappropriate crying and/or screaming  
 2 Grunts  
 1 None

PUPIL SIZE	PUPILARY RESPONSE
1 •	C Constricted
2 ●	D Dilated
3 ●	E Equal
4 ●	F Fixed
5 ●	G/R Nonreactive
6 ●	R Reactive
7 ●	S Sluggish
8 ●	U Unequal

A person with significant head injury is always at high risk for a spinal injury. Always take spinal precautions if a person is down with a head injury.

Time: \_\_\_\_\_

Airway obstructed? YES NO

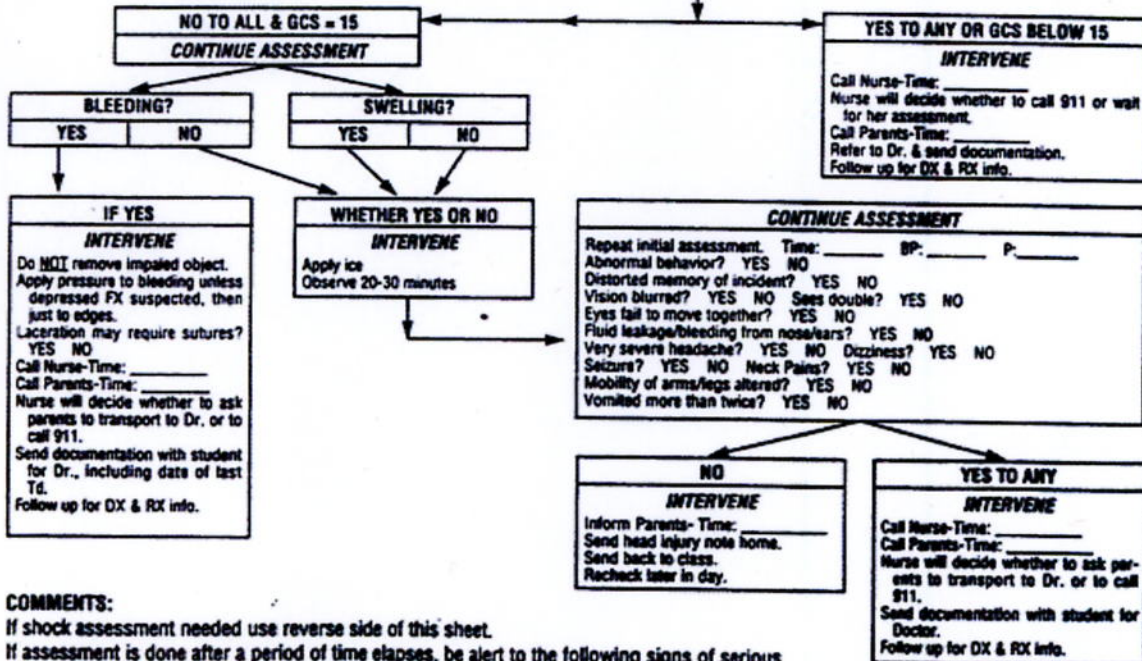
Abnormal breathing pattern/rate? YES NO R\_\_\_\_\_

Abnormal pulse? YES NO P\_\_\_\_\_

Abnormal skull contour? YES NO  
Describe: \_\_\_\_\_

Abnormal reflexes? YES NO  
Describe: \_\_\_\_\_

Hand grips unequal in strength? YES NO  
Describe: \_\_\_\_\_



**COMMENTS:**

If shock assessment needed use reverse side of this sheet.

If assessment is done after a period of time elapses, be alert to the following signs of serious head injury:

**CUSHING'S TRIAD** - Increased systolic BP, decreased heart rate, widened pulse pressure. Is a sign of increased intracranial pressure.

**RACCOON EYES** - Discoloration & swelling around both eyes. Suggests basilar skull FX or facial FX.

**BATTLE'S SIGN** - Discoloration & swelling behind one or both ears. Suggestive of basilar skull FX.