

**HIGHLIGHTS**

- Life-threatening effects on GI tract, kidney, liver, heart, other organs
- Pulmonary fibrosis is the usual cause of death in paraquat poisoning (but not diquat)

**Signs and Symptoms:**

- Paraquat and diquat (ingestion): burning pain in the mouth, throat, chest, upper abdomen; pulmonary edema, pancreatitis, other renal, CNS effects
- Paraquat (dermal): dry and fissured hands, horizontal ridging or loss of fingernails, ulceration and abrasion
- Diquat: neurologic toxicity

**Treatment:**

- Immediate GI decontamination with Bentonite, Fuller's Earth, or activated charcoal
- Maintain urinary output by administering IV, but monitor fluids in case of renal failure
- Decontaminate eyes and skin

**Contraindicated:**

- No supplemental oxygen unless patient develops severe hypoxemia

# Paraquat and Diquat

The dipyridyl compounds paraquat and diquat are non-selective contact herbicides that are relatively widely-used, primarily in agriculture and by government agencies and industries for control of weeds. While paraquat is a restricted-use pesticide in most forms for most uses in the United States, its wide usage leads to significant potential for misuse and accidental and intentional poisonings. In the past few decades, paraquat has been a popular agent for suicide, but recent experience indicates a decline in such intentional poisonings. Paraquat and diquat are highly toxic compounds and management of poisonings requires a great deal of skill and knowledge of proper management procedures.

## PARAQUAT

### Toxicology

When ingested in adequate dosage (see below), paraquat has life-threatening effects on the gastrointestinal tract, kidney, liver, heart, and other organs. The LD<sub>50</sub> in humans is approximately 3-5 mg/kg, which translates into as little as 10-15 mL of a 20% solution.<sup>1,2</sup>

The lung is the primary target organ of paraquat, and pulmonary effects represent the most lethal and least treatable manifestation of toxicity. However, toxicity from inhalation is rare. The primary mechanism is through the generation of free radicals with oxidative damage to lung tissue.<sup>1,2</sup> While acute pulmonary edema and early lung damage may occur within a few hours of severe acute exposures,<sup>3,4</sup> the delayed toxic damage of pulmonary fibrosis, the usual cause of death, most commonly occurs 7-14 days after the ingestion.<sup>5</sup> In patients who ingested a very large amount of concentrated solution (20%), some have died more rapidly (within 48 hours) from circulatory failure.<sup>5</sup>

Both types I and II pneumatocytes appear to selectively accumulate paraquat. Biotransformation of paraquat in these cells results in free-radical production with resulting lipid peroxidation and cell injury.<sup>1,2,4</sup> Hemorrhage proteinaceous edema fluid and leukocytes infiltrate the alveolar spaces, after which there is rapid proliferation of fibroblasts. There is a progressive decline in arterial oxygen tension and CO<sub>2</sub> diffusion capacity. Such a severe impairment of gas exchange causes progressive proliferation of fibrous connective tissue in the alveoli and eventual death from asphyxia and tissue anoxia.<sup>6</sup> One prospective study of survivors suggests

that some of the fibrous toxic damage may be reversible as evidence exists of markedly improved pulmonary function three months after survival.<sup>7</sup>

Local skin damage includes contact dermatitis. Prolonged contact will produce erythema, blistering, abrasion and ulceration, and fingernail changes.<sup>8,9</sup> Although absorption across intact skin is slow, abraded or eroded skin allows efficient absorption.

The gastrointestinal (GI) tract is the site of initial or phase I toxicity to the mucosal surfaces following ingestion of the substance. This toxicity is manifested by swelling, edema, and painful ulceration of the mouth, pharynx, esophagus, stomach, and intestine. With higher levels, other GI toxicity includes centrilobular hepatocellular injury which can cause elevated bilirubin, and hepatocellular enzymes such as AST, ALT, and LDH.

Damage to the proximal renal tubule is often more reversible than the destruction to lung tissue. However, impaired renal function may play a critical role in determining the outcome of paraquat poisoning. Normal tubule cells actively secrete paraquat into the urine, efficiently clearing it from the blood. However, high blood concentrations poison the secretory mechanism and may destroy the cells. Diquat poisoning typically results in greater renal injury compared to paraquat.

Focal necrosis of the myocardium and skeletal muscle are the main features of toxicity to any type of muscle tissue, and typically occur as a second phase. Ingestion has also been reported to cause cerebral edema and brain damage.<sup>10</sup>

Although much concern has been expressed about the effects of smoking paraquat-contaminated marijuana, toxic effects caused by this mechanism have been either very rare or nonexistent. Most paraquat that contaminates marijuana is pyrolyzed during smoking to dipyrindyl, which is a product of combustion of the leaf material itself (including marijuana) and presents little toxic hazard.

## Signs and Symptoms of Poisoning

Initial clinical signs depend upon the route of exposure. Early symptoms and signs of poisoning by ingestion are burning pain in the mouth, throat, chest, and upper abdomen, due to the corrosive effect of paraquat on the mucosal lining. Diarrhea, which is sometimes bloody, can also occur. Giddiness, headache, fever, myalgia, lethargy, and coma are other examples of CNS and systemic findings. Pancreatitis may cause severe abdominal pain. Proteinuria, hematuria, pyuria, and azotemia reflect renal injury. Oliguria/anuria indicate acute tubular necrosis.

Because the kidney is almost the exclusive route of paraquat elimination from body tissues, renal failure fosters a build-up of tissue concentrations, including those in the lung. Unfortunately, this pathogenic sequence may occur in the first several hours following paraquat ingestion, generating lethal concentrations of paraquat in lung tissue before therapeutic measures to limit absorption and enhance disposition have taken effect. It is probably for this reason

## Commercial Products

### Paraquat

#### *Liquid Concentrates:*

Cekuquat  
Crisquat  
Dextrone  
Esgram  
Goldquat  
Gramocil  
Gramonol  
Gramoxone

#### *In combination with other herbicides:*

##### With diquat:

Actor  
Preeglone  
Preglone  
Weedol (a 2.5% soluble granule formulation)

##### With diuron:

Dexuron  
Gramuron  
Para-col  
Tota-col

##### With monolinuron:

Gramonol

##### With simazine:

Pathclear  
Terraklene

### Diquat

Aquacide  
Dextrone  
Ortho Diquat  
Reglone

that methods for enhancing paraquat disposition several hours following ingestion have had little effect on mortality.

Cough, dyspnea, and tachypnea usually appear 2-4 days following paraquat ingestion, but may be delayed as long as 14 days. Progressive cyanosis and dyspnea reflect deteriorating gas exchange in the damaged lung. In some cases, the coughing up of frothy sputum (pulmonary edema) is the early and principal manifestation of paraquat lung injury.

Clinical experience has offered a rough dose-effect scale on which to base prognosis in cases of paraquat ingestion:<sup>9</sup>

- **Less than 20 mg** paraquat ion per kg body weight (less than 7.5 mL of 20% [w/v] paraquat concentrate): No symptoms or only gastrointestinal symptoms occur. Recovery is likely.
- **Twenty to 40 mg** paraquat ion per kg body weight (7.5-15.0 mL of 20% [w/v] paraquat concentrate): Pulmonary fibroplasia ensues. Death occurs in most cases, but may be delayed 2-3 weeks.
- **More than 40 mg** paraquat ion per kg body weight (more than 15.0 mL of 20% [w/v] paraquat concentrate): Multiple organ damage occurs as in class II, but is more rapidly progressive. Often characterized by marked ulceration of the oropharynx. Mortality is essentially 100% in 1-7 days.

Dermal signs are common among agriculture workers with acute paraquat toxicity. Particularly in concentrated form, paraquat causes localized injury to tissues with which it comes into contact. Fatal poisonings are reported to have occurred as a result of protracted dermal contamination by paraquat, but this is likely to occur only when the skin is abraded, eroded, or diseased, when more efficient systemic absorption can occur. With an intact dermal barrier, paraquat leaves the skin of the hands dry and fissured, can cause horizontal ridging of the fingernails, and may even result in the loss of fingernails. Prolonged contact with skin will create ulceration and abrasion, sufficient to allow systemic absorption.

In addition, some agriculture workers can be exposed through prolonged inhalation of spray droplets, and develop nosebleeds due to local damage. However, inhalation has not resulted in systemic toxicity, due to the low vapor pressure and lower concentration of paraquat field formulations. Eye contamination with diquat concentrate or stronger solutions results in severe conjunctivitis and sometimes protracted corneal opacification.

The hepatic injury from paraquat may be severe enough to cause jaundice, which signifies severe injury. However, hepatotoxicity is rarely a major determinant to clinical outcome. No other hepatic signs or symptoms are present other than the abnormal laboratory values mentioned in the Toxicology section.

## DIQUAT

### Toxicology

Diquat poisoning is much less common than paraquat poisoning, so that human reports and animal experimental data for diquat poisoning are less extensive than for paraquat. Systemically absorbed diquat is not selectively concentrated in lung tissue, as is paraquat, and pulmonary injury by diquat is less prominent. In animal studies, diquat causes mild, reversible injury to type I pneumocytes, but does not injure the type II cells. No progressive pulmonary fibrosis has been noted in diquat poisoning.<sup>11-13</sup>

However, diquat has severe toxic effects on the central nervous system that are not typical of paraquat poisoning.<sup>12,13</sup> While laboratory experimentation has suggested that diquat is not directly neurotoxic, there have been relatively consistent pathologic brain changes noted in reported fatal cases of diquat poisoning. These consist of brain stem infarction, particularly involving the pons.<sup>12</sup> It is not clear whether these post-mortem changes represent direct toxicity or secondary effects related to the systemic illness and therapy. (See Signs and Symptoms section for CNS clinical effects.)

There is probably significant absorption of diquat across abraded or ulcerated skin.

### Signs and Symptoms of Poisoning

In many human diquat poisoning cases, clinical signs of neurologic toxicity are the most important. These include nervousness, irritability, restlessness, combativeness, disorientation, nonsensical statements, inability to recognize friends or family members, and diminished reflexes. Neurologic effects may progress to coma, accompanied by tonic-clonic seizures, and result in the death of the patient.<sup>12,13</sup> Parkinsonism has also been reported following dermal exposure to diquat.<sup>14</sup>

Except for the CNS signs listed in the preceding paragraph, early symptoms of poisoning by ingested diquat are similar to those from paraquat, reflecting its corrosive effect on tissues. They include burning pain in the mouth, throat, chest, and abdomen, intense nausea and vomiting, and diarrhea. If the dosage was small, these symptoms may be delayed 1-2 days. Blood may appear in the vomitus and feces. Intestinal ileus, with pooling of fluid in the gut, has characterized several human poisonings by diquat.

The kidney is the principal excretory pathway for diquat absorbed into the body. Renal damage is therefore an important feature of poisonings. Proteinuria, hematuria, and pyuria may progress to renal failure and azotemia. Elevations of serum alkaline phosphatase, AST, ALT, and LDH reflect liver injury. Jaundice may develop.

If the patient survives several hours or days, circulatory function may fail due to dehydration. Hypotension and tachycardia can occur, with shock resulting in death. Other cardiorespiratory problems may develop, such as toxic cardiomyopathy or a secondary infection such as bronchopneumonia.

Diquat is somewhat less damaging to the skin than paraquat, but irritant effects may appear following dermal contamination with the concentrate. There is probably significant absorption of diquat across abraded or ulcerated skin.

The great majority of poisonings by paraquat and diquat (discussed below) have been caused by ingestion with suicidal intent in most cases, particularly in Japan<sup>11</sup> and many developing countries. Since 1987, there has been a decline in most countries in the total numbers of suicidal deaths attributed to paraquat and diquat. Nearly all of the few poisonings caused by occupational exposure have been survived, but the mortality rate among persons who have swallowed paraquat or diquat remains high.<sup>1,5</sup> Avoidance of this mortality will probably have to rely on preventive strategies or on stopping gastrointestinal absorption very soon after the toxicant has been ingested.

Even though intestinal absorption of dipyriddyis is relatively slow, lethal uptake by critical organs and tissues apparently occurs within 18 hours, and possibly within 6 hours, following ingestion of toxic quantities of paraquat or diquat. Bipyridyls have large volumes of distribution. Once distribution to tissues has occurred, measures to remove bipyridyls from the blood are very inefficient in reducing the total body burden.

Several strategies are being tested to reduce the frequency of these occurrences. These include the addition of emetics, stenching agents, gelling substances, and bittering agents such as sodim denatonium.

## Confirmation of Poisoning: Paraquat and Diquat

At some treatment facilities, a simple colorimetric test is used to identify paraquat and diquat in the urine, and to give a rough indication of the magnitude of absorbed dose. To one volume of urine, add 0.5 volume of freshly prepared 1% sodium dithionite (sodium hydrosulfite) in one normal sodium hydroxide (1.0 N NaOH). Observe color at the end of one minute. A blue color indicates the presence of paraquat in excess of 0.5 mg per liter. Both positive and negative controls should be run to ensure that the dithionite has not undergone oxidation in storage.

When urine collected within 24 hours of paraquat ingestion is tested, the dithionite test appears to have some prognostic value: concentrations less than one milligram per liter (no color to light blue) generally predict survival, while concentrations in excess of one milligram per liter (navy blue to dark blue) often foretell a fatal outcome.

Diquat in urine yields a green color with the dithionite test. Although there is less experience with this test in diquat poisonings, the association of bad prognosis with intense color is probably similar.

Paraquat and diquat can be measured in blood and urine by spectrophotometric, gas chromatographic, liquid chromatographic, and radioimmunoassay methods. These tests are available in numerous clinical reference laboratories and sometimes by the manufacturing company. Survival is likely if plasma concentrations do not exceed 2.0, 0.6, 0.3, 0.16, and 0.1 mg per liter at 4, 6, 10, 16, and 24 hours, respectively, after ingestion.<sup>15</sup>

## Treatment

**1. Skin and eye decontamination. Flush** skin immediately with copious amounts of water. Material splashed in the **eyes** must be removed by **prolonged irrigation** with clean water. Eye contamination should thereafter be treated by an ophthalmologist. Mild skin reactions usually respond if there is no further contact with the pesticide, but the irritation may take several weeks to resolve. Severe injuries with inflammation, cracking, secondary infection, or nail injury should be treated by a dermatologist.

**2. Gastrointestinal decontamination.** If paraquat or diquat have been ingested, **immediate administration of adsorbent** is the one therapeutic measure most likely to have a favorable effect. **Bentonite** (7.5% suspension) and **Fuller's Earth** (15% suspension) are highly effective, but sometimes not available.

### **Dosage of Bentonite and Fuller's Earth:**

- *Adults and children over 12 years:* 100-150 g.
- *Children under 12 years:* 2 gm/kg body weight.

**Caution:** Hypercalcemia and fecaliths have sometimes occurred following administration of Fuller's Earth.

Activated charcoal is nearly as effective, and is widely available. See Chapter 2 for dosage of charcoal and further information on gastric decontamination.

Lavage has not been shown to be effective and should not be performed unless the patient is seen within an hour of ingestion. Later lavage runs the risk of inducing bleeding, perforation, or scarring due to additional trauma to already traumatized tissues. Repeated administration of charcoal or other absorbent every 2-4 hours may be beneficial in both children and adults, but use of a cathartic such as sorbitol should be avoided after the first dose. Cathartics and repeat doses of activated charcoal should not be administered if the gut is atonic. **Check frequently for bowel sounds.** Ileus occurs commonly in diquat poisoning, less often in paraquat poisoning.

**3. Samples.** Secure a blood sample as soon as possible for paraquat analysis, and urine samples for either paraquat and/or diquat. Serial samples of urine for either agent and plasma for paraquat may be followed for prognostic information.

**4. Respiration. Do not administer supplemental oxygen** until the patient develops severe hypoxemia. High concentrations of oxygen in the lung increase the injury induced by paraquat, and possibly by diquat as well. There may be some advantage in placing the patient in a moderately hypoxic environment, i.e., 15%-16% oxygen, although the benefit of this treatment measure has not been established empirically in human poisonings. Inhalation of nitric oxide has been suggested as a method to maintain tissue oxygenation at low inspired oxygen concentrations, but its efficacy is unproven. When the lung injury is so far advanced that there is no expectation of recovery, oxygen may be given to relieve air hunger.

**5. Intensive care.** In serious poisonings, care should be provided in an intensive care setting, to allow proper monitoring of body functions and skilled performance of necessary invasive monitoring and procedures.

**6. Fluids.** It is essential to maintain adequate urinary output.<sup>4</sup> Administer intravenous fluids: isotonic saline, Ringer's solution, or 5% glucose in water. This is highly advantageous early in poisonings as a means of correcting dehydration, accelerating toxicant excretion, reducing tubular fluid concentrations of paraquat, and correcting any metabolic acidosis. However, fluid balance must be monitored carefully to forestall fluid overload if renal failure develops. Monitor the urine regularly for protein and cells, to warn of impending tubular necrosis. Intravenous infusions must be stopped if renal failure occurs, and extracorporeal hemodialysis is indicated. Hemodialysis is not effective in clearing paraquat or diquat from the blood and tissues.

**7. Hemoperfusion** over cellophane-coated activated charcoal may be considered. The procedure has been used in many paraquat poisonings because the adsorbent does efficiently remove paraquat from the perfused blood. However, recent reviews of effectiveness have failed to show any reduction in mortality as a result of hemoperfusion.<sup>1,4</sup> The apparent reason for this is the very small proportion of paraquat body burden carried in the circulating blood even when only a few hours have elapsed after ingestion. Theoretically, a patient who can be hemoperfused within 10 hours of paraquat ingestion may derive some marginal benefit, but this has not been demonstrated.

If hemoperfusion is attempted, blood calcium and platelet concentrations must be monitored. Calcium and platelets must be replenished if these constituents are depleted by the procedure.



**8. Seizure control.** Convulsions and psychotic behavior sometimes encountered in diquat poisoning may be best controlled by lorazepam, given slowly intravenously, as outlined in Chapter 2. Control convulsions as outlined in Chapter 2.

**9. Other drugs.** Many drugs have been tested in animals or given in human bipyridyl poisonings without clear evidence of benefit or harm: corticosteroids, superoxide dismutase, propranolol, cyclophosphamide, vitamin E, riboflavin, niacin, ascorbic acid, clofibrate, desferrioxamine, acetylcysteine, and terpin hydrate. However, recent evidence regarding the use of **cyclophosphamide** and **methylprednisolone** may be effective in reducing the mortality associated with moderate to severe paraquat poisoning. Two studies found a reduced mortality associated with the treatment, while one study found no difference.<sup>16</sup> The dosages used for cyclophosphamide and methylprednisolone were 1 gram daily for two days and 1 gram daily for three days respectively, and were given after hemoperfusion. Each drug was administered as a two hour infusion, and white cell counts, serum creatinine levels, chest radiography, and liver function tests were monitored.<sup>16</sup>

**10. Pain management.** Morphine sulfate is usually required to control the pain associated with deep mucosal erosions of the mouth, pharynx, and esophagus, as well as abdominal pain from pancreatitis and enteritis. Mouthwashes, cold fluids, ice cream, or anesthetic lozenges may also help to relieve pain in the mouth and throat.

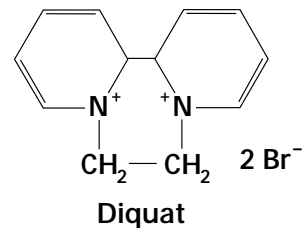
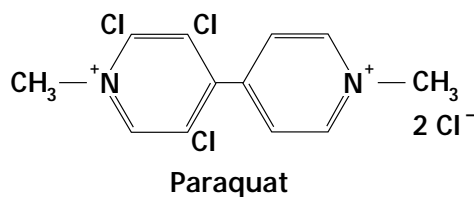
**Dosage of Morphine Sulfate:**

- *Adults and children over 12 years:* 10-15 mg subcutaneously every 4 hours.
- *Children under 12 years:* 0.1 - 0.2 mg /kg body weight every 4 hours.

**11. Transplantation.** With severe pulmonary toxicity, recovery of the patient may only be accomplished by lung transplantation. However, the transplanted lung is susceptible to subsequent damage due to redistribution of paraquat.<sup>17</sup>



## General Chemical Structures



## References

1. Pond SM. Manifestations and management of paraquat poisoning. *Med J Aust* 1990;152:256-9.
2. Giulivi C, Lavagno CC, Lucesoli F, et al. Lung damage in paraquat poisoning and hyperbaric oxygen exposure: superoxide-mediated inhibition of phospholipase A2. *Free Radic Biol Med* 1995;18:203-13.
3. Nordquist RE, Nguyen H, Poyer JL, et al. The role of free radicals in paraquat-induced corneal lesions. *Free Radic Res* 1995;23:61-71.
4. Honore P, Hantson P, Fauville JP, et al. Paraquat poisoning: State of the art. *Acta Clin Belg* 1994;49:220-8.
5. Bismuth C, Garnier R, Dally S, et al. Prognosis and treatment of paraquat poisoning: A review of 28 cases. *J Toxicol Clin Toxicol* 1982;19:461-74.
6. Harsanyi L, Nemeth A, and Lang A. Paraquat (gramoxone) poisoning in south-west Hungary, 1977-1984. *Am J Forensic Med Pathol* 1987;8:131-4.
7. Lee CC, Lin JL, and Liu L. Recovery of respiratory function in survivors with paraquat intoxication (abstract). *Ann Emerg Med* 1995;26:721-2.
8. Tungsanga K, Chusilp S, Israsena S, et al. Paraquat poisoning: Evidence of systemic toxicity after dermal exposure. *Postgrad Med J* 1983;59:338-9.
9. Vale JA, Meredith TJ, and Buckley BM. Paraquat poisoning: Clinical features and immediate general management. *Hum Toxicol* 1987;6:41-7.
10. Hughes JT. Brain damage due to paraquat poisoning: A fatal case with neuropathological examination of the brain. *Neurotoxicology* 1988;9:243-8.
11. Lam HF, Azawa J, Gupta BN, et al. A comparison of the effects of paraquat and diquat on lung compliance, lung volume, and single-breath diffusing capacity in the rat. *Toxicology* 1980;18:111-23.
12. Vanholder R, Colardyn F, DeReuck J, et al. Diquat intoxication: Report of two cases and review of the literature. *Am J Med* 1981;70:1267-71.
13. Olson KR. Paraquat and diquat. In: Olson KR et al. (eds), *Poisoning and Drug Overdose*, 2<sup>nd</sup> ed. Norwalk CT: Appelton and Lange, 1994, pp. 245-6.
14. Sechi GP, Agnetti V, Piredda M, et al. Acute and persistent Parkinsonism after use of diquat. *Neurology* 1992;42:261-3.
15. Proudfoot AT, Stewart MS, Levitt T, et al. Paraquat poisoning: Significance of plasma-paraquat concentrations. *Lancet* 1979;2:330-2.

16. Lin JL, Wei MC, and Liu YC. Pulse therapy with cyclophosphamide and methylprednisolone in patients with moderate to severe paraquat poisoning: A preliminary report. *Thorax* 1996;51:661-3.
17. Toronto Lung Transplant Group. Sequential bilateral lung transplantation for paraquat poisoning. A case report. *J Thoracic Cardiovas Surg* 1985;89:734-42.