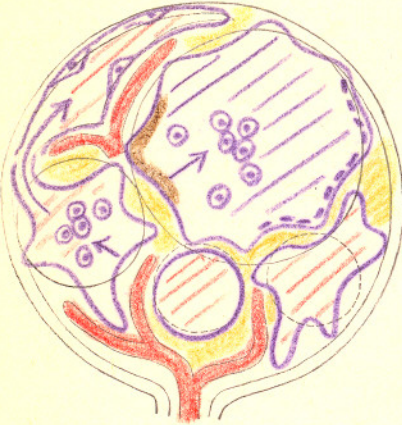

~~CONFIDENTIAL~~

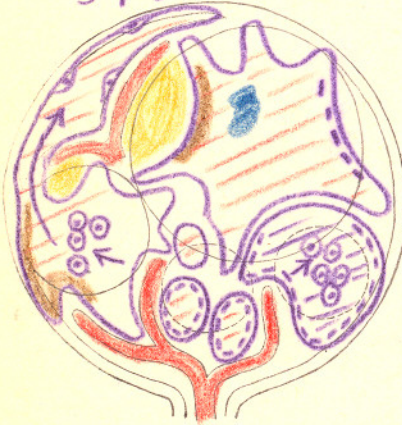393



393.

Acute disfiguring of thyroid in medium degree. Considerable congestion and degenerative processes of follicular epithelial cells (flattening, cloudy swelling, pycnosis, desquamation and some desolation of epithelial cells) with increased basophilic colloidal masses and collapse of follicles (fluidified colloidal masses). Without any proliferative changes. Colloidal masses in lymph-vessel and slight edematous swelling of peri-follicular connective tissues.

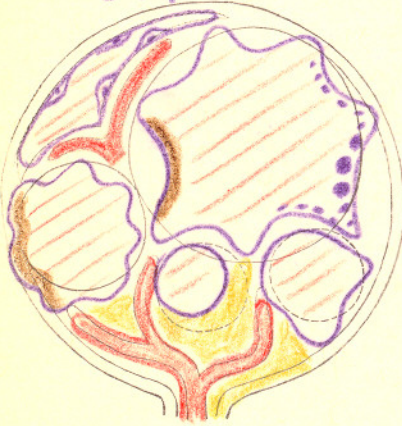
396



396. Acute disfiguring of thyroid in severe degree. Considerable congestion, more or less swelling of blood-vessel walls and slight edematous swelling of perivascular tissues.

Follicles in various forms: some macro- and some microfollicles, with some degenerative processes of follicular epithelial cells (flattening, pycnosis, remarkable desquamation and desolation of epithelial cells). Increase of basophilic colloidal masses and collapse of follicles in severe degree. Colloidal masses in lymph-vessels.

399



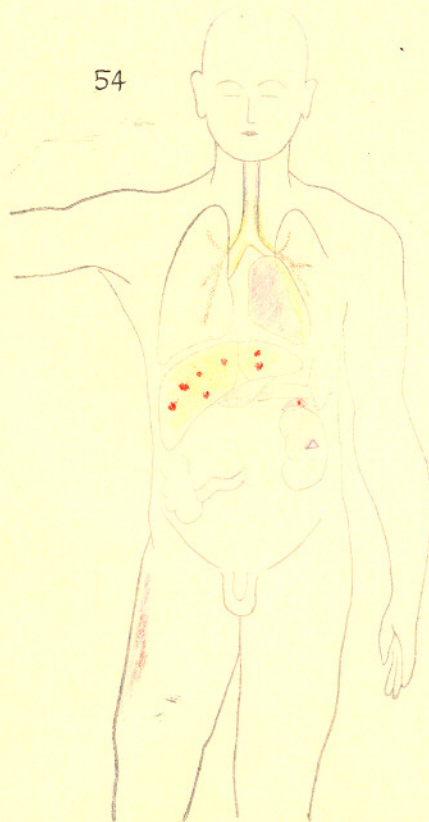
Bacterial masses in follicles without any proliferative changes.
399. Acute disfiguring of thyroids in slight degree. Considerable congestion and slight edema in perivascular tissues. Some degenerative processes of follicular epithelial cells in slight degree and slight

~~CONFIDENTIAL~~

~~TOP SECRET~~

~~CONFIDENTIAL~~

54



~~CONFIDENTIAL~~

~~TOP SECRET~~

2

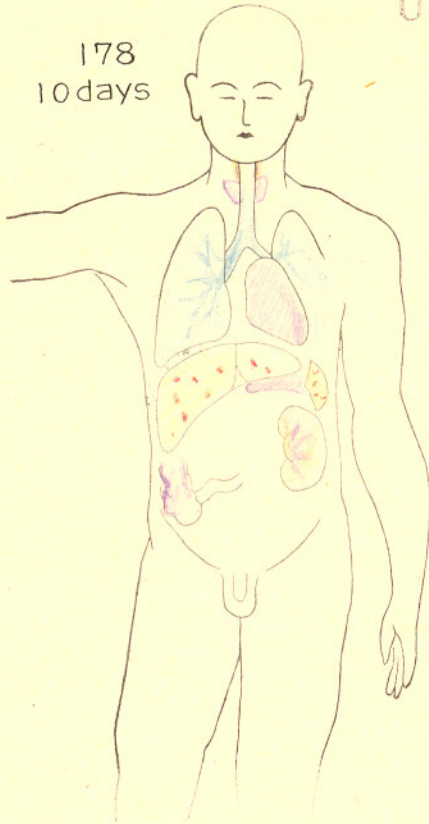
56-FDTS-

[REDACTED]

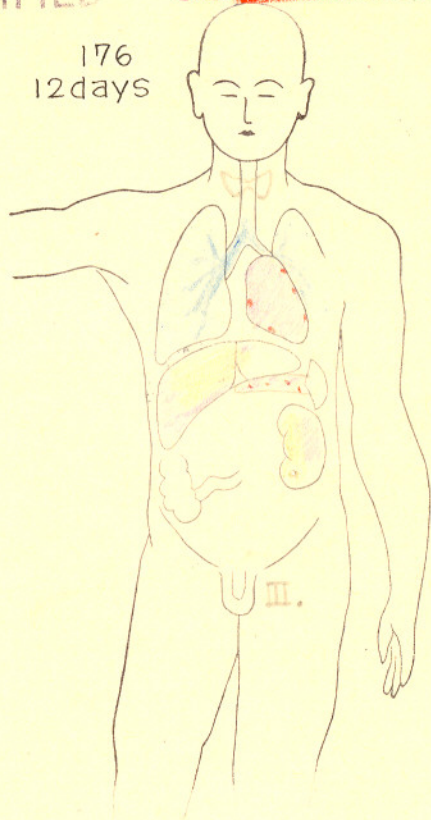
UNCLASSIFIED

[REDACTED]

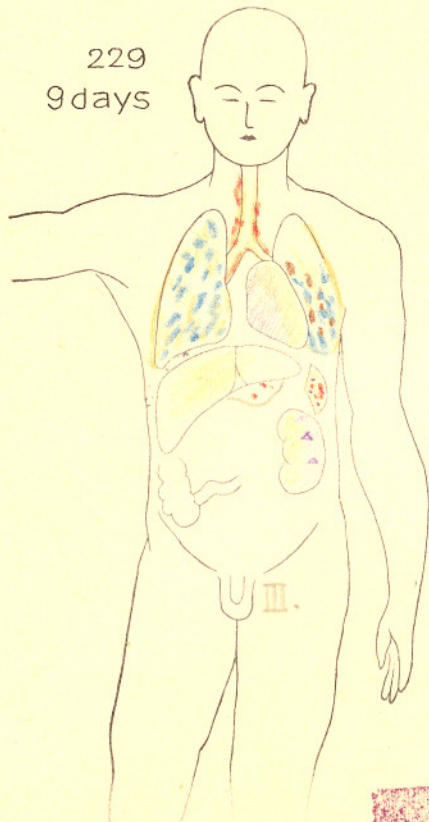
178
10 days



176
12 days



229
9 days



[REDACTED]

[REDACTED]

UNCLASSIFIED