

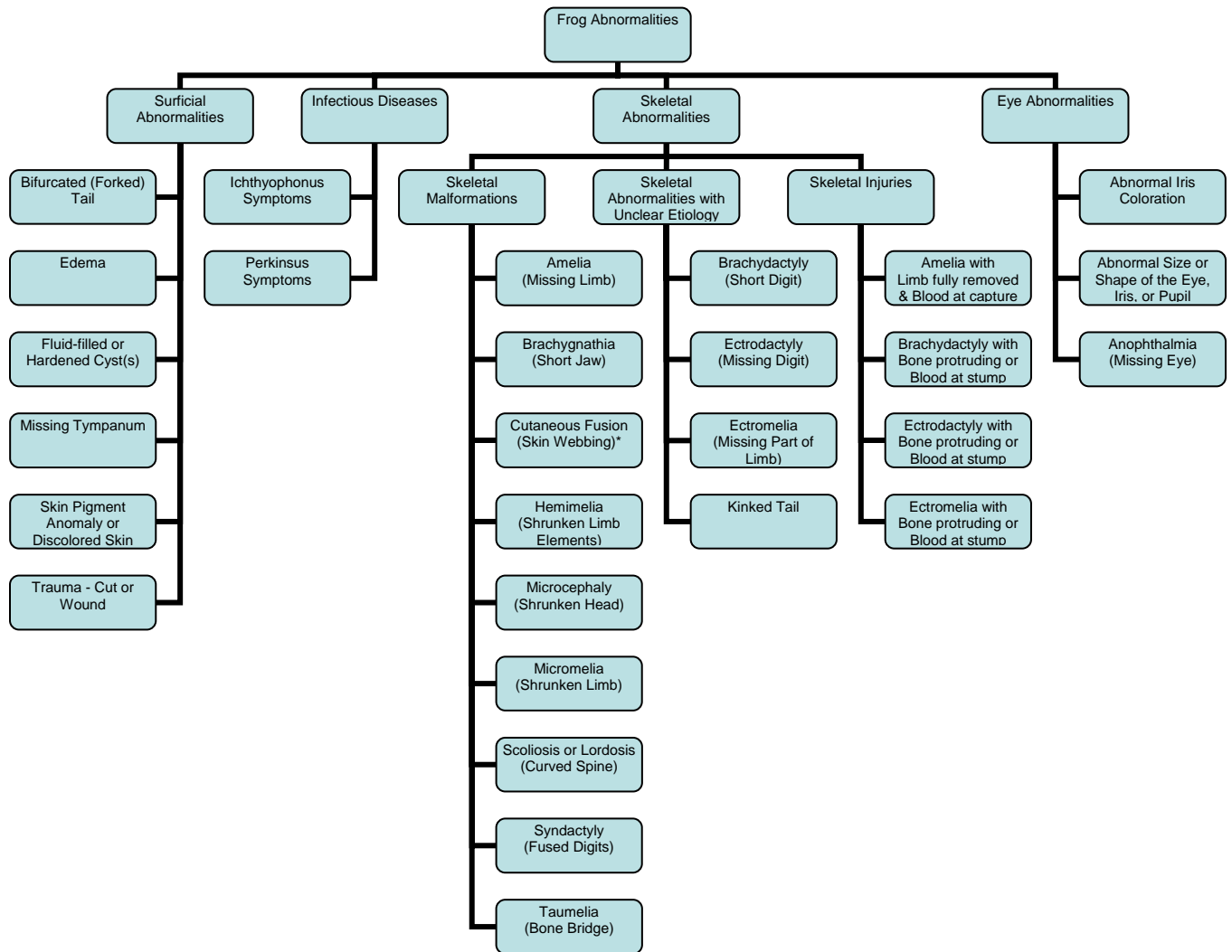


ABNORMALITY CLASSIFICATION SOP

- A. Objective:** To classify frog abnormalities for analysis.
- B. Background:** There is variability in what researchers term "abnormal" when reporting the prevalence of abnormal frogs. Researchers who focus on the prevalence of skeletal and eye abnormalities often exclude traumatic injuries, diseases, and surficial abnormalities or infections from their reports (Eaton et al. 2004; Helgen et al. 2000; Hoppe, 2000; Hoppe, 2005; Johnson et al. 2001; Levey 2003; Ouellet et al. 1997; Schoff et al. 2003, Taylor et al. 2005). Other researchers include abnormalities and diseases but not obvious injuries when reporting the prevalence of abnormal frogs (McCallum and Trauth 2003), and still others report all gross physical abnormalities (Dubois 1979; Johnson et al. 2002; Lannoo et al. 2003). Because of this variability, a decision was made in the USFWS Abnormal Amphibian surveys to categorize frogs with any gross physical abnormality as "abnormal" to ensure consistency in field data collection (USFWS 1999). Consequently, the results from our surveys include more abnormalities than are reported by most researchers studying abnormal frogs. We developed this abnormal classification standard operating procedure (SOP) to enable a more accurate comparison of our field data with published research. Regional amphibian coordinators will utilize this SOP to further refine our "abnormal" category and ensure consistency in our classification of abnormal frogs. The SOP combines abnormalities into categories and subcategories, which may stem from similar causes, and provides us with more power to detect relationships between environmental variables and certain types of abnormalities. The abnormality classification SOP has its origins in the *Field Guide to Malformations of Frogs and Toads with Radiographic Interpretations* (Meteyer, 2000), which describes malformations in detail with photographs and radiographs, and in the body of literature cited above. Additional support for this SOP comes from knowledge gained from a large subset of newly metamorphosed frogs radiographed and analyzed for parasites and diseases between 2000 and 2005 for the Abnormal Amphibian surveys. Those analyses provided insight into the gross appearance of certain injuries, malformations, infections, and diseases.
- C. Existing Definitions:** We recognize there are different definitions and classification schemes that have been used in published literature or by the public when describing the gross physical condition of an amphibian. For our purposes, we will use the following definitions from Johnson et al. (2001) as they are best suited to the goals of the USFWS Abnormal Amphibian surveys:
- i. **Abnormality:** Any gross deviation from the normal range in morphological variation, be it traumatic or developmental.
 - ii. **Malformation:** Permanent structural defect resulting from abnormal development.
 - iii. **Deformity:** Alteration in an organ or structure that originally formed correctly. Deformities result from mechanical factors, such as amputation.
- D. Existing Resources:** The USGS field guide to common malformations in frogs and toads:

Meteyer, C.U. 2000. *Field Guide to Malformations of Frogs and Toads with Radiographic Interpretations*, 2000. Biological Science Report USGS/BRD/BSR-2000-0005.

E. **Further Classification:** An analysis of project data from 2000-2006, and of the available literature, suggests that the initial USFWS “Abnormal” classification can be further subdivided into the following categories: Surficial Abnormality, Infectious Disease, Skeletal Abnormality, and Eye Abnormality, according to the flow chart below. Skeletal Abnormality is further divided into 3 subcategories: Skeletal Malformation, Skeletal Abnormality with Unclear Etiology, and Skeletal Injury. The flow chart is not exhaustive for all abnormalities, but rather shows abnormalities commonly encountered by USFWS employees. The text following the diagram has a more extensive list of abnormality types in each category, as does Table 1. The terminology for each abnormality is taken from Meteyer (2000). Photographs of some common abnormalities are included in the text. **NOTE: Every USFWS employee using this SOP should first use the Meteyer (2000) guide to identify the type of abnormality (or abnormalities) that a frog has before using this SOP to further classify the abnormal frog.**



*Although skin webbing is not technically a skeletal malformation, we have decided to include it under the skeletal malformation category for several reasons. First, skin webbing, along with other skeletal malformations such as polymelia, polydactyly, and taumelia, may be diagnostic of *Ribeiroia* infections. Second, skin webbing restricts the

movement of the skeletal system and, as such, could be viewed as a type of skeletal abnormality. Finally, skin webbing has been described in Meteyer (2000) as a malformation. For the purposes of this SOP and the USFWS Abnormal Amphibian surveys, skin webbing will be categorized as a skeletal malformation.

- F. Surficial Abnormalities:** Surficial Abnormalities include abnormal pigmentation, wounds, scars, cysts, infections, subcutaneous hemorrhaging, or edema. Wounds can be caused by predation or other trauma. These may leave hematomas (bruises) or scars, which disrupt the normal skin pigmentation and appear a different color than the rest of the animal (red, brown, black, or even bluish). Split or forked tails may be healed injuries and are therefore considered surficial abnormalities. Edema, or fluid-filled swelling under the skin, is considered a surficial abnormality for this SOP. Small, fluid-filled or hardened cysts not affecting the skeletal system also should be included in this category for the purposes of this SOP. Some species of trematodes and nematodes create rather distinctive cysts on the surface of the skin.
- G. Infectious Diseases:** Frogs exhibiting disease symptoms that manifest as physical abnormalities should be classified in the disease category. Two diseases encountered and diagnosed between 2000 and 2005 are a Perkinsus-like protozoan organism and Ichthyophonus. Perkinsus symptoms include severely swollen viscera that lead to a bloated body and an infected, swollen (enlarged) heart. The swollen heart is occasionally displaced to the throat area and is visible through the skin. Ichthyophonus symptoms include a swollen tail resorption site that matches the surrounding skin in color and translucency (i.e., not a cyst).
- H. Skeletal Abnormalities:** The Skeletal Abnormality category comprises three subcategories: Skeletal Malformations, Skeletal Abnormalities with Unclear Etiology, and Skeletal Injuries. If a frog has any of the abnormalities in these three subcategories, it should be placed in the Skeletal Abnormality category, and also in the appropriate subcategory.
- i. **Skeletal Malformations:** Frogs with skeletal malformations have skeletal systems that have grown in an abnormal way. Examples of skeletal malformations include:
 1. small head or blunt snout (microcephaly),
 2. shortened or malformed jaw (brachygnathia),
 3. curved spine in a lateral direction (scoliosis),
 4. curved spine in a dorsoventral direction (lordosis),
 5. completely missing limbs with no stump (amelia),
 6. shrunken limb (micromelia)
 7. shrunken limb elements, such as shortened tibiae, fibulae, or metatarsals (hemimelia),
 8. extra limb or limbs (polymelia),
 9. bone bridge (taumelia),
 10. extra digits (polydactyly),
 11. fused digits (syndactyly),
 12. digit bent at right angle to normal trajectory (clinodactyly),
 13. extra bones in a digit (polyphalangy),
 14. rotated long bones with reversed digit order (anteversion), or
 15. skin webbing that restricts skeletal movement (cutaneous fusion).
 - ii. **Skeletal Abnormalities of Unclear Etiology:** If a frog is missing part of a limb (ectromelia) or has a shortened or missing digit or digits (brachydactyly or ectrodactyly) yet there is no evidence of trauma (i.e., no blood visible at capture

and the bone is contained within the skin), it should be scored as a skeletal abnormality of unclear origin. If a leg stump is present, even if very small, the abnormality should be classified as ectromelia.

- iii. **Skeletal Injuries:** If a frog has a missing or broken limb (or part of a limb) where either blood is noted at capture or bone is protruding through the skin, the abnormality should be classified as a Skeletal Injury. *There must be evidence of trauma (e.g., blood or a broken bone) to qualify for this category.*

I. Eye Abnormalities: Any abnormality of the eye should be classified in this category. The most common eye abnormalities are anophthalmia, abnormal iris coloration, and abnormal eye, iris, or pupil sizes.

- i. **Anophthalmia:** The eye is not present, and skin is grown over where the eye should be.
- ii. **Abnormal Iris Coloration:** The eye is present, but something is unusual about the coloration. The most common eye color anomalies are heterochromia (the eyes are two different colors), reduced pigment in one or both eyes, and melanistic or “black” eye, where either one or both eyes are all black.
- iii. **Abnormal Size or Shape:** One eye, iris, or pupil is a different size or shape than the other, or both eyes deviate from the normal size range of the rest of the population.

Table 1. Abnormality descriptions for different classification categories and subcategories.

CATEGORY and SUBCATEGORY	ABNORMALITY DESCRIPTION
SURFICIAL ABNORMALITY	BLOOD POOLED IN LEGS OR ELSEWHERE
	CYST OR LUMP UNDER SKIN
	DISCOLORED SKIN - INDICATIVE OF SCARRING
	EDEMA
	FLESH CUT OR WOUND WITH BLOOD
	BIFURCATED OR FORKED TAIL
	INTESTINES PROTRUDING
	MISSING TYMPANUM
	OTHER PIGMENT ANOMALY
	SORE OR WOUND BUT NO BROKEN BONES, AND/OR NO DISLOCATIONS
INFECTIOUS DISEASE	ICHTHYOPHONUS SYMPTOMS
	PERKINSUS SYMPTOMS
SKELETAL ABNORMALITY	
Skeletal Malformation	AMELIA - MISSING LIMB
	ANTEVERSION - TOES CURLED INTO FIST OR FINGERS/TOES IN REVERSE ORDER WITH NO BLOOD
	BRACHYGNATHIA - SHORTENED OR MALFORMED JAW
	CLINODACTYLY - DIGIT BENT AT RIGHT ANGLE TO NORMAL TRAJECTORY
	CUTANEOUS FUSION - SKIN WEBBING THAT RESTRICTS SKELETAL MOVEMENT
	HEMIMELIA - SHRUNKEN LIMB ELEMENTS - SOME ELEMENTS ARE SHRUNKEN, BUT NOT ALL
	LORDOSIS - SPINAL CURVATURE IN A DORSOVENTRAL DIRECTION
	MICROCEPHALY - SMALL HEAD OR SHORTENED SNOOT
	MICROMELIA - SHRUNKEN LIMB - ALL LIMB ELEMENTS SHRUNKEN INCLUDING FOOT
	POLYDACTYLY - EXTRA DIGITS
	POLYMELIA - EXTRA LIMB
	POLYPHALANGY - EXTRA BONES IN A DIGIT
	SCOLIOSIS - SPINAL CURVATURE IN A LATERAL DIRECTION
	SYNDACTYLY - DIGITS FUSED TOGETHER
	TAUMELIA - BONE BRIDGES OR BONY TRIANGLES
Unclear Etiology	BRACHYDACTYLY - TOES SHORT OR MISSING PHALANGES WITH NO EVIDENCE OF TRAUMA
	ECTRODACTYLY - DIGIT OR DIGITS MISSING WITH NO EVIDENCE OF TRAUMA
	ECTROMELIA - MISSING PART OF LIMB - NO BLOOD OR BONE PROTRUDING (OR NOT MENTIONED)
	KINKED TAIL
	NON-FLEXIBLE LIMB
	ONE LEG THINNER THAN OTHERS
Skeletal Injury	AMELIA - LIMB FULLY REMOVED WITH BLOOD AT CAPTURE
	APPENDAGE DISLOCATED, DANGLING, OR HANGING OFF
	BRACHYDACTYLY - TOES MISSING PHALANGES WITH PROTRUDING BONES OR FLESH WOUND
	ECTRODACTYLY - DIGIT OR DIGITS MISSING WITH BLOOD OR PROTRUDING BONE
	ECTROMELIA - MISSING PART OF LIMB - WITH BLOOD OR PROTRUDING BONE
	TOES CURLED OR SMASHED WITH BLOOD
EYE ABNORMALITY	ABNORMAL IRIS COLORATION - HETEROCHROMIA (EYES TWO DIFFERENT COLORS), REDUCED PIGMENT IN IRIS, OR UNPIGMENTED IRIS (ONE OR BOTH EYES ALL BLACK)
	ABNORMAL SIZE OR SHAPE OF EYE, IRIS, OR PUPIL
	ANOPTHALMIA - MISSING EYE

References

- Dubois A. 1979. Anomalies and mutations of natural populations of the *Rana "esculenta"* complex (Amphibia, Anura). *Mitteilungen aus dem Zoologischen Museum in Berlin* 55(1): 59-87.
- Eaton BR, Eaves S, Stevens C, Puchniak A, Paszkowski CA. 2004. Deformity levels in wild populations of the wood frog *Rana sylvatica* in three ecoregions of Western Canada. *Journal of Herpetology* 38: 283-287.
- Helgen JC, Gernes MC, Kersten SM, Chirhart JW, Canfield JT, Bowers D, Haferman J, McKinnell G, Hoppe DM. 2000. Field investigations of malformed frogs in Minnesota 1993-1997. *Journal of the Iowa Academy of Science* 107: 96-112.
- Hoppe DM. 2000. History of Minnesota frog abnormalities: Do recent findings represent a new phenomenon? *Journal of the Iowa Academy of Science* 107(3): 86-89.
- Hoppe DM. 2005. Malformed frogs in Minnesota: History and interspecific differences. In: *Amphibian Declines: The Conservation Status of United States Species*, pp. 103-108. University of California Press, Berkeley, California.
- Johnson PTJ, Lunde KB, Ritchie EG, Reaser JK, Launer AE. 2001. Morphological abnormality patterns in a California amphibian community. *Herpetologica* 57(3): 336-352.
- Johnson PTJ, Lunde KB, Thurman EM, Ritchier EG, Wray SN, Sutherland DR. 2002. Parasite *Ribeiroia ondatrae* infection linked to amphibian malformations in the western United States. *Ecological Monographs* 72: 151-168.
- Lannoo MJ, Sutherland DR, Jones P, Rosenberry D, Klaver RW, Hoppe DM, Johnson PTJ, Lunde KB, Facemire C, Kapfer JM. 2003. Multiple causes for the malformed frog phenomenon. pp. 233-262. In: Linder G, Krest S, Sparling D, and Little, E. (Eds.), *Multiple Stressor Effects in Relation to Declining Amphibian Populations*. American Society for Testing Materials International, West Conshohocken, Pennsylvania.
- Levey R. 2003. Investigations into the causes of amphibian malformations in the Lake Champlain basin of New England. Vermont Department of Environmental Conservation, Waterbury, Vermont.
- McCallum ML, Trauth SE. 2003. A forty-three year museum study of northern cricket frog *Acris crepitans* abnormalities in Arkansas: Upward trends and distributions. *Journal of Wildlife Diseases* 39: 522-528.
- Meteyer CU. 2000. *Field guide to malformations of frogs and toads with radiographic interpretations*. Biological Science Report USGS/BRD/BSR-2000-0005. U.S. Geological Survey, Madison, Wisconsin.
- Meteyer CU, Loeffler IK, Fallon JF, Converse KA, Green E, Helgen JC, Kersten S, Levey R, Eaton-Poole L, Burkhart JG. 2000. Hind limb malformations in free-living northern leopard frogs (*Rana pipiens*) from Maine, Minnesota, and Vermont suggest multiple etiologies. *Teratology* 62: 151-171.
- Ouellet M, Bonin J, Rodrigue J, DesGranges J, Lair S. 1997. Hindlimb deformities ectromelia, ectrodactyly in free-living anurans from agricultural habitats. *Journal of Wildlife Diseases* 33: 95-104.
- Schoff PK, Johnson CM, Schotthoefer AM, Murphy JE, Lieske C, Cole RA, Johnson LB, Beasley VR. 2003. Prevalence of skeletal and eye malformations in frogs from north-central United States: Estimations based on collections from randomly selected sites. *Journal of Wildlife Diseases* 39: 510-521.

Taylor B, Skelly D, Demarchis LK, Slade MD, Galusha D, Rabinowitz PM. 2005. Proximity to pollution sources and risk of amphibian limb malformation. *Environmental Health Perspectives* 113: 1497-1501.

USFWS. 1999. Standard operating procedures for abnormal amphibian surveys. U.S. Fish and Wildlife Service, Annapolis, Maryland.