

# Technology Assessment



**Technology  
Assessment Program**

**Agency for Healthcare  
Research and Quality  
540 Gaither Road  
Rockville, Maryland 20850**

## **The Role of Bone Growth Stimulating Devices and Orthobiologics in Healing Nonunion Fractures**

**September 21, 2005**

# **The Role of Bone Growth Stimulating Devices and Orthobiologics in Healing Nonunion Fractures**

Prepared by:  
ECRI Evidence-based Practice Center

Karen Schoelles, M.D., S.M.  
David Snyder, Ph.D.  
Janice Kaczmarek, M.S.  
Evelyn Kuserk, M.L.S., M.A.  
Eileen Erinoff, B.A.  
Charles Turkelson, Ph.D.  
Vivian Coates, M.B.A.

# **The Role of Bone Growth Stimulating Devices and Orthobiologics in Healing Nonunion Fractures**

This report is based on research conducted by the ECRI Evidence-based Practice Center (EPC) under contract to the Agency for Healthcare Research and Quality (AHRQ), Rockville, MD (Contract No. 290-02-0019). The findings and conclusions in this document are those of the author(s) who are responsible for its contents; the findings and conclusions do not necessarily represent the views of AHRQ. Therefore, no statement in this report should be construed as an official position of the Agency for Healthcare Research and Quality or of the U.S. Department of Health and Human Services.

The information in this report is intended to help health care decision-makers; patients and clinicians, health system leaders, and policymakers, make well-informed decisions and thereby improve the quality of health care services. This report is not intended to be a substitute for the application of clinical judgment. Decisions concerning the provision of clinical care should consider this report in the same way as any medical reference and in conjunction with all other pertinent information, i.e., in the context of available resources and circumstances presented by individual patients.

This report may be used, in whole or in part, as the basis for development of clinical practice guidelines and other quality enhancement tools, or as a basis for reimbursement and coverage policies. AHRQ or U.S. Department of Health and Human Services endorsement of such derivative products may not be stated or implied.

**September 21, 2005**

**Prepared for:  
Agency for Healthcare Research and Quality  
540 Gaither Road  
Rockville, Maryland 20850**

## Table of Contents

Tables .....	iv
Figures .....	v
Executive Summary .....	1
Key Question 1: How is a nonunion fracture diagnosed? .....	2
Key Question 2: What are the risk factors for developing a nonunion fracture? .....	3
Key Question 3: What are the current standards of care for nonunion fractures? .....	4
a. What supportive measures are recommended?.....	4
b. What surgical therapies are currently recommended for treatment of nonunion? .....	4
c. What orthobiologics and external devices for stimulation of bone healing in nonunion fractures have been approved by the FDA and which have not been approved by the FDA? .....	5
Key Question 4: What are the intermediate and patient-reported outcomes of treatment for nonunions, and how are they defined?.....	6
Key Question 5: What is the evidence for variations in outcomes attributable to surgeon, procedure and institution characteristics? .....	6
Key Question 6: What is the evidence for benefits and harms of bone growth stimulating devices and orthobiologics for treatment of nonunion fractures?.....	6
Concluding Remarks .....	11
Scope of Report .....	13
Background .....	15
Fracture Healing and the Development of a Nonunion .....	15
Overview of Treatment Decisions for Nonunion.....	17
Anatomic Location of Nonunion Fractures .....	21
Relevance of Nonunion Fractures to the Medicare Population .....	22

Methods .....	24
Key Questions Addressed .....	24
Literature Searches.....	24
Inclusion/Exclusion Criteria.....	25
Data Extraction .....	27
Evaluation of the Quality of the Evidence Base .....	29
Evidence Synthesis.....	31
Key Question 1: How is a nonunion fracture diagnosed? .....	31
Key Question 2: What are the risk factors for developing a nonunion fracture? .....	33
Key Question 3: What are the current standards of care for nonunion fractures? ...	36
a. What supportive measures are recommended?.....	37
b. What surgical therapies are currently recommended for treatment of nonunion? .....	37
c. What orthobiologics and external devices for stimulation of bone healing in nonunion fractures have been approved by the FDA and which have not been approved by the FDA? .....	48
Key Question 4: What are the intermediate and patient-reported outcomes of treatment for nonunions, and how are they defined?.....	50
Key Question 5: What is the evidence for variations in outcomes attributable to surgeon, procedure and institution characteristics? .....	51
Key Question 6: What is the evidence for benefits and harms of bone growth stimulating devices and orthobiologics for treatment of nonunion fractures?.....	52
Proposed mechanisms of action.....	52
Evidence Base.....	57
Quality of Included Studies .....	59
Findings of Included Studies .....	61
Concluding Remarks .....	83

Bibliography .....	86
APPENDICES: Supporting Documentation, Summary Tables, and Evidence Tables .....	95
Appendix A. Literature Searches .....	96
Electronic Database Searches .....	97
Hand Searches of Journal and Nonjournal Literature.....	102
Appendix B. Orthobiologics and Bone Growth Stimulating Devices Used to Treat Nonunion Fractures .....	103
Appendix C. Evidence Tables for Key Question 4 .....	112
Appendix D. Evidence Tables for Key Question 6 .....	113
Appendix E. Additional Data Supplied by Reviewers .....	156

## TABLES

Table 1.	Hierarchy of Research Design (USPSTF) .....	29
Table 2.	Criteria for Grading the Internal Validity of Individual Studies (USPSTF) ...	30
Table 3.	Evidence Base for Key Question 6 .....	58
Table 4.	Included Studies with Control Groups Treated for Nonunion Fractures Addressing Key Question 6 .....	60
Table 5.	Pre-1990 Studies of PEMF Treatment of Nonunion Fractures .....	72
Table 6.	Pre-1990 Studies of Direct and Capacitive Treatment of Nonunion Fractures .....	76
Table B-1.	List of Orthobiologics Used to Treat Nonunion Fractures .....	103
Table B-2.	List of External Bone Growth Stimulating Devices Used to Treat Nonunion Fractures .....	106
Table C-1.	Intermediate and Patient-Reported Outcomes of Treatment for Nonunion Fractures .....	112
Table D-1.	Excluded Studies for Key Question 6 .....	113
Table D-2.	Included Studies of Ultrasound Treatment of Nonunion Fractures Addressing Key Question 6 .....	116
Table D-3.	Included Studies of Pulsed Electromagnetic Fields Treatment of Nonunion Fractures Addressing Key Question 6 .....	121
Table D-4.	Included Studies of Direct Current and Capacitive Coupling Treatment of Nonunion Fractures Addressing Key Question 6 .....	135
Table D-5.	Included Studies of Shock wave Treatment of Nonunion Fractures Addressing Key Question 6 .....	144
Table D-6.	Included Studies of Orthobiologics Treatment of Nonunion Fractures Addressing Key Question 6 .....	151

## FIGURES

Figure 1.	Overview of Treatment Decisions for Nonunion.....	19
Figure A-1.	Study Selection Algorithm.....	96



## **EXECUTIVE SUMMARY**

The Centers for Medicare and Medicaid Services (CMS) requested that AHRQ commission an evidence report to assist CMS and the Medicare Coverage Advisory Committee in considering treatments for nonunion fractures. On June 16th 2005, AHRQ issued a Statement of Work (SOW) contracting ECRI to prepare a report on the role of bone growth stimulating devices and orthobiologics in healing nonunion fractures. The SOW specified that ECRI perform a narrative review of background information and surgical therapy and a systematic review of bone growth stimulating devices and orthobiologics. For the systematic review, the tasks to be performed were the following:

1. Systematically search, review, and analyze the relevant scientific evidence for each question. Search MEDLINE and other suitable databases containing primary studies and review literature relevant to the questions to be addressed. Identify other sources of relevant literature, such as meeting abstracts and clinical trials currently in progress.
2. Retrieve and review full articles on eligible studies, assessing quality and extracting key data from each eligible study.
3. Prepare abbreviated evidence tables and summary of important findings.

In commissioning this report, AHRQ, in consultation with CMS and ECRI, developed six Key Questions to be addressed. Key Questions 1 through 5 were addressed by examining reviews, clinical practice guidelines, orthopedic textbooks and selected clinical studies published between 1990 and 2005. Key Question 6 was addressed by examining all eligible original clinical studies published between 1990 and 2005. The inclusion criteria for these studies are provided in the Methods section of this report. A draft report was submitted for review to a variety of interested parties, including representatives from orthopedic surgery, manufacturers of bone growth stimulating devices, AHRQ and CMS. This process resulted in a supplemental search for the period 1975 to 1990 to expand the information pertinent to electrical bone growth stimulating

devices. Additional articles were identified by reviewers, and in one case, a translation of a study of ultrasound therapy published in German was provided to us.(1) Abstracts presented for the past 2 years at the American Academy of Orthopedic Surgeons (AAOS), the Orthopedic Trauma Association (OTA) and the American Orthopedic Foot and Ankle Society (AOFAS) meetings were reviewed to identify studies relevant to Key Question 6. Studies identified from the supplemental search and the meeting abstracts are discussed in the body of this report, but are not included in the full evidence tables in the Appendices.

The findings of our assessment as they pertain to the six Key Questions are presented below.

### **Key Question 1: How is a nonunion fracture diagnosed?**

There is no uniformly accepted method of nonunion diagnosis applicable to all fractures, given variations in the bone tissue and fracture characteristics. Even for fractures in a given bone, there is a range of opinions regarding the time by which a fracture is expected to heal. The term “delayed union” describes a fracture which has not healed within the expected time frame. Epidemiologic studies of time to healing of acute fractures with specific characteristics (e.g., open vs. closed) for specific bones could provide benchmarks. A full search and review of such studies was beyond the scope of the current report, but would probably be helpful to clinicians in defining delayed union. Once an assessment is made that healing is delayed, most authors define nonunion as the absence of signs of healing for an additional 3 months. One survey of orthopedic surgeons published in 2002 found that the mean and standard deviation (SD) time from initial fracture of the tibia to diagnosis of nonunion was 6 months (SD: 2 months), with a range of 2 to 12 months.(2)

There are variations in the specific radiographic and clinical criteria used to diagnose nonunion. Bhandari et al.(2) found that 79% of surgeons use radiographic evidence of cortical continuity as their primary means of defining nonunion fracture healing, but that 42% also used weight-bearing and 37% also use pain on palpation of the fracture site.

Multiple projections or computerized tomography (CT) may be necessary to identify evidence for healing. Magnetic resonance imaging (MRI) is useful for diagnosing infection complicating nonunion if the presence of hardware does not contravene its use.

Clinical characteristics favoring a diagnosis of nonunion include inability to bear weight, pain on palpation of the fracture site or motion at the site. These clinical findings in the absence of radiographic evidence for healing may influence the timing of diagnosis.

Despite these imaging and clinical methods, determination of the presence of nonunion can be very difficult and is often dependent on clinical judgment. Court-Brown's discussion of the diagnosis of tibial nonunion is illustrative of the difficulty in diagnosis of nonunion.(3)

### **Key Question 2: What are the risk factors for developing a nonunion fracture?**

The principal reasons for fractures failing to unite are believed to be inadequate stabilization and failure of the biologic processes necessary for new bone formation. Both local and systemic factors may contribute to this breakdown in normal healing. Of the systemic risk factors, heavy smoking was mentioned in a number of reviews and studies as an important risk factor. Obesity, alcoholism, diabetes, peripheral vascular disease, and increasing age were also mentioned, although there is not agreement on the effect of age. Certain medications (e.g., corticosteroids) are also thought to increase risk for nonunion or infection, which in turn increases the risk for nonunion.

Certain characteristics of the fracture and the injury may predispose to nonunion. These include high-energy trauma, higher grade and open fractures, comminution of the fracture, vertical or oblique fracture pattern, and fracture displacement. Interposition of soft tissue between fragments impedes healing, and severe soft tissue trauma may interrupt vascular supply and may predispose to infection. Specific bones may have higher rates of nonunion than others because of limited normal blood supply or propensity to more severe fractures. Some techniques and hardware for fixation of acute fractures have been abandoned because of higher rates of nonunion, while new

developments in acute fracture management have reduced the likelihood of nonunion with certain fractures.

### **Key Question 3: What are the current standards of care for nonunion fractures?**

#### **a. What supportive measures are recommended?**

Reviews of surgical management of nonunion mentioned supportive measures in the care of patients infrequently. Recommendations included control of infection, improvement in nutrition and smoking cessation. Good clinical practice dictates stabilizing any comorbid conditions such as diabetes prior to elective procedures.

#### **b. What surgical therapies are currently recommended for treatment of nonunion?**

Nonunions are classified as either septic (infected) or aseptic (noninfected), by clinical examination as either stiff or mobile, and by radiographic appearance as hypertrophic, oligotrophic or atrophic. Once nonunion has been diagnosed, the presence or absence of infection is a key determinant of treatment. In general, implantation of new hardware for stabilization may need to be delayed until antibiotic therapy and surgical debridement bring the infection under control. In some cases, previously implanted hardware must be removed. An external fixation device is sometimes used for stabilization of the fracture site in this setting. The fracture site is reassessed when the infection is under control.

Hypertrophic nonunions have viable bone ends and an adequate blood supply, but excessive motion at the fracture site has disrupted the healing process. Therapy of this type of nonunion emphasizes improving stabilization of the fracture site. Atrophic nonunions are those with a “biological” problem, i.e., a failure of the normal stimuli or cellular responses necessary for bone formation. Oligotrophic nonunions are intermediate in character between the hypertrophic and atrophic types. Both inadequate stability of the fracture site and impairment of the biological response to fracture play a role in many nonunions. Inadequate stability is most frequently addressed by use of

fixation devices, either external or internal; biologic deficits are currently treated primarily by autogenous bone grafts. Autogenous bone grafts provide growth factors and cellular mechanisms for osteoinduction, but depend on adequate vascular supply at the nonunion site. In some instances, bone grafts are harvested with an intact vascular supply to overcome inadequate blood supply at the nonunion site, which is more likely with large defects. The iliac crest is the most commonly used donor site, although “local bone” may be obtained from a site close to the nonunion. Excessive morbidity, primarily related to the harvesting procedure, has led to a demand for alternative means of treatment. Patient preferences and values, as well as the assessment of higher levels of risk of complications from surgery, may also lead the orthopedic surgeon to consider less invasive methods of treatment.

**c. *What orthobiologics and external devices for stimulation of bone healing in nonunion fractures have been approved by the FDA and which have not been approved by the FDA?***

The FDA considers most orthobiologics to be Class II medical devices. Orthobiologics include resorbable calcium salt bone void fillers, some of which contain demineralized bone matrix (DBM). DBM is processed from human bone tissue and contains a variety of bone growth stimulators (osteoinductive agents such as bone morphogenetic proteins) and is used in a number of bone graft substitutes. Therefore, these products may be used in treating nonunion fractures as an FDA off-label use. One orthobiologic that is not classified as a Class II device is OP-1 Implant (Stryker Biotech). Stryker Biotech was granted a humanitarian device exemption (HDE) by the FDA for its use in treatment of recalcitrant long bone nonunions. Palacos E-Flow (Osteopal) Bone Cement (Biomet Merck) has FDA approval for femoral nonunions. Of note, autogenous bone graft and bone marrow aspirate, used to stimulate bone growth, are not regulated by the FDA.

Currently, a number of electrical stimulation devices and ultrasound devices have been approved by the FDA for treating nonunion fractures. Shock wave treatment has not

been approved by the FDA. Several studies performed in Europe have examined the efficacy of this treatment for nonunion fractures.

**Key Question 4: What are the intermediate and patient-reported outcomes of treatment for nonunions, and how are they defined?**

Three radiographic variables are most often used to determine nonunion fracture healing: callus size, cortical continuity, and progressive loss of fracture line. The ability of the patient to bear weight on the fractured limb and pain at the fracture site on palpation are additional nonradiographic methods often used to judge nonunion fracture healing. There is, however, a lack of consensus among surgeons as to which methods should be used to judge healing of fractures and to monitor response to treatment of nonunion. Cortical continuity is believed to be most directly related to return of original bone strength while callus size is the least related. However, cortical continuity may not be directly correlated with functional outcomes. Studies that use a combination of radiographic and clinical evidence of healing provide a more complete picture of the healing process than studies that use only radiographic evidence or only clinical evidence. A list of outcomes and measures used to assess them in the included studies is provided in Appendix C.

**Key Question 5: What is the evidence for variations in outcomes attributable to surgeon, procedure and institution characteristics?**

We identified no publications that directly addressed this question.

**Key Question 6: What is the evidence for benefits and harms of bone growth stimulating devices and orthobiologics for treatment of nonunion fractures?**

Fracture healing relies on a coordinated series of phases in which damaged nonfunctional tissue is replaced by tissue that restores the original structure and function of the bone. Each phase in the healing sequence relies on specific growth factors to ensure complete healing and bone restoration. Application of these growth

factors directly into the fracture has been proposed as a means of enhancing bone repair. In bone tissue, these growth factors stimulate the production of cells needed in the healing process.

Another element in the repair process is the type of stress applied to the bone during healing. Biophysical stimulation has been proposed as a key element in repairing, maintaining, and remodeling of bone to meet its functional demands. However, the direct link between biophysical stimulation and the cellular responses controlled by the various growth factors has not been fully elucidated. The biophysical stimulation needed to enhance fracture healing may be supplied through external energy sources such as ultrasound, pulsed electromagnetic field stimulation (PEMF), low power direct current, and extracorporeal shock wave stimulation. Although these are all forms of biophysical stimulation, whether these modalities produce different cellular responses or follow a similar osteogenic pathway is still controversial.(4)

We identified 24 studies published from 1990 to 2005 that examined the effectiveness of bone growth stimulating devices or orthobiologics that met our inclusion criteria. These studies consisted of three studies of ultrasound, seven studies of PEMF, four studies of direct current and capacitive coupling, six studies of shock wave, and four studies of orthobiologics. We identified only four randomized controlled trials (RCT), two for PEMF, one for capacitive coupling and one for orthobiologics. We included case series in this report based on the prevalent belief that nonunion fractures are not likely to heal without intervention (see discussion in the Background section). Some of the reviewers of the draft of this report preferred to describe these as “self-paired patient controlled” studies – with each patient serving as his or her own control.(5-8) For the purpose of this report, however, we have considered these studies with no separate comparison group to be case series rather than controlled trials.

Three cases series published since 1990 (two prospective(1,9) and one retrospective(10)) using the Exogen system to treat nonunion in 1446 patients consistently reported that a high percentage of nonunions healed during ultrasound therapy. While the results of these studies suggest that ultrasound promotes the healing

of nonunion fractures, they do not rule out a role for other concurrent treatment procedures, such as stabilization of the nonunion, contributing to the observed effects. The two studies reporting data for patients over 65 are not in agreement as to the effect of age on response to ultrasound treatment.

Seven studies published since 1990 with a total of 403 patients reported data concerning PEMF treatment of nonunions. Two of the included studies were double-blind RCTs using dummy devices and blinded assessment. One RCT examined longstanding tibial nonunions, comparing an active vs. dummy PEMF device in addition to treatment with a fibular osteotomy and unilateral external fixation. The healing rate was higher in the group receiving PEMF in addition to the other treatment, but was not statistically significantly different after adjustment for confounding by the greater proportion of smokers in the control group.(11) The second RCT compared an active vs. dummy PEMF device and full-leg plaster cast immobilization in patients with “delayed tibial union” (failure to heal within 16 – 32 weeks of initial injury while treated with cast immobilization).(12) While radiographic assessments demonstrated significantly greater progression toward healing in the active device group at the end of the 12 week study, analysis of the long-term follow-up data was confounded by early surgical and electrical device intervention in the control group; longer followup prior to further intervention may have altered the difference between the groups. Nonetheless, 17 of 20 patients treated with the active device from the beginning of the 12-week study had healed at long-term followup without the need for further surgical intervention.(13) One nonrandomized study with a concurrent control group demonstrated higher rates of healing in the PEMF group with infected nonunions, but no adjustments were made for differences in patient and fracture characteristics in the two groups.(14) One prospective case series which included patients with nonunions of long duration also reported healing in 57%. The remaining case series showed healing when PEMF therapy was combined with cast immobilization. Studies conducted prior to 1990 were consistent with the more recent studies in terms of healing rates. Overall, these results consistently indicate that nonunions heal in patients treated with PEMF, but the effect of PEMF cannot be separated from the effect of concomitant fracture site stabilization.



We identified four studies published since 1990 with a total of 351 patients treated with direct current or capacitive coupling treatment of nonunions. An RCT examined patients with established nonunions treated with an active capacitive coupling device (n = 10) or an inactive device (n = 11).(15) While 6 of 10 in the active treatment group healed in an average of 21 weeks compared to none of the control group, there were 5 tibial nonunions of 10 total nonunions in the active treatment group, vs. 10 tibial nonunions out of 11 total nonunions in the control group.(15) This may have negatively affected the healing rates in the control group. One retrospective comparative study examined tibial nonunions in separate groups of patients treated with direct current, capacitive coupling, and bone graft.(16) This study used logistic regression analysis to estimate better than 95% healing with all three treatments when the nonunions were of 10-month duration prior to treatment and no other risk factors for failure to respond to the treatments were present. Risk factors predicting slower healing rates included longer duration of nonunion prior to treatment, open fracture, comminuted fracture, prior failed bone graft or prior failed electrical therapy. Patient age was used as a continuous variable in the logistic regression analysis, but any influence of age on healing was not reported in the study. In the remaining two studies, one specifically examined patients with large nonunion gaps (>1 cm, which is wider than is typical for nonunions treated with electrical stimulation).(17) The other study reported on the 10-year followup of patients treated with an implanted bone growth stimulator, but forty-four percent of the original patients were not located, reducing the validity of the reported results.(18) An additional 6 case series published between 1975 and 1989 had reported healing rates between 40% and 90%. Overall, these studies consistently demonstrate healing during treatment with direct current and capacitive coupling but the effect of these therapies cannot be separated from the effect of concomitant immobilization of the fracture site.

Six case series published since 1990 with a total of 430 patients reported results of shock wave treatment of nonunions of multiple bone types.(19-22) Five of the studies were conducted in Europe and one was conducted in Taiwan; shock wave devices have not been approved by the FDA for use in treating nonunion fractures. These case series reported healing rates between 50% and 80%, but the effect of shock wave therapy cannot be separated from the effect of immobilization in these uncontrolled studies.

Four separate studies published since 1990 with a total of 214 patients reported data concerning the use of orthobiologics to treat nonunions. One study was an RCT comparing BMP-7, OP-1 Implant (Stryker Biotech) to fresh bone autograft in the treatment of tibial nonunions. Stryker Biotech was granted a humanitarian device exemption (HDE) by the FDA for the use of OP-1 Implant as an alternative to autograft in recalcitrant long bone nonunions where use of autograft is not feasible and alternative treatments have failed. Patients in both groups underwent intramedullary rod fixation in addition to the autograft or OP-1 grafting procedure.(23) The internal validity of this study was rated as “fair” only because autogenous bone grafting requires removal of bone from the patient’s pelvis; consequently, patients could not be blinded to treatment. However, radiographic assessment of bone bridging was blinded. The study found similar healing rates in the two groups. A noninferiority statistical analysis should be performed to determine whether OP-1 Implant in conjunction with internal fixation was not inferior to autogenous bone graft in the treatment of tibial nonunions. Assuming the analysis demonstrates noninferiority, this single study would need to be replicated by other investigators before OP-1 is considered an effective substitute for autogenous bone grafting. The absence of the morbidity associated with harvesting of autogenous bone for grafting is a distinct advantage; hence, additional studies would only need to demonstrate noninferiority as well.

The other three studies of orthobiologics were retrospective case series. One examined the use of AlloMatrix Injectable Putty (Wright Medical Technology) in nonunions in multiple bone types.(24) AlloMatrix Putty, which contains demineralized bone matrix (Allogro from AlloSource), carboxymethylcellulose, and OsteoSet (calcium sulfate), is cleared by the FDA only for “bony voids or gaps that are not intrinsic to the stability of bony structure” and is therefore not directly cleared for use in nonunion fractures. The publication did not report prior treatment or the duration of the nonunions prior to the AlloMatrix Putty treatment. Without this information, interpretation of the results is difficult. The remaining two studies were retrospective case series from a single laboratory that examined the use of a composite allograft with partially purified human bone morphogenetic protein (hBMP) to treat nonunions of the femur in one study, and multiple bone types in the other. As with other case series, the precise role of the

composite allograft in the healing process cannot be distinguished from the other procedures used to stabilize the limbs. Two recent meeting abstracts describing studies utilizing DBM indicated healing rates of 54% and 75%, respectively, but one found high rates of wound drainage and subsequent deep infection.(25,26) Additional studies are needed to understand the role of DBM in treating nonunions at this time.

### **Concluding Remarks**

What is the evidence for benefits and harms of bone growth stimulating devices and orthobiologics for treatment of nonunion fractures?

After searching the literature published since 1990, retrieving references, and applying our inclusion/exclusion criteria, we identified 24 published studies of bone growth stimulators and orthobiologics. Four of the studies were RCTs, two were retrospective comparison studies, seven were prospective case series, and the remaining 11 were retrospective case series. Thus, the overall quality of the evidence for each type of intervention is for the most part low, and few of the studies can actually be used to distinguish the effect of the device or orthobiologics agent from the additional treatments these patients received. While some view case series of patients treated for nonunion as “self-paired, patient controlled” studies, the occurrence of healing at late timepoints in some patients receiving other therapies (e.g., cast immobilization) made us hesitant to view the studies in this way. Two RCTs of PEMF therapy indicate that patients treated with PEMF had healing of nonunions, but the results from one study did not reach statistical significance after adjusting for confounding, and the other was only randomized for the initial 12 weeks of treatment and observation.(11,12) One prospective case series,(27) a retrospective series with a comparison group(14) and three retrospective case series also demonstrated healing with PEMF treatment, but the effect of PEMF could not be separated from the contribution of the immobilization procedures or casting.(11) The RCT of treatment with a capacitative coupling device demonstrated higher rate of healing in the active treatment group, although the number of tibial nonunions in the comparison group may have negatively affected the results in that group.(15) The remaining RCT, Friedlaender et al.,(23) indicates that OP-1 Implant

may substitute for autogenous bone graft in the treatment of tibial nonunions in patients also being treated with reamed intramedullary nail fixation, but a noninferiority statistical analysis is needed to show that OP-1 (along with internal fixation) is not inferior to autogenous bone graft and additional studies are needed to replicate the results. Case series studies of ultrasound and shock wave therapy report healing of nonunions with these therapies but individual study quality limits the strength of the evidence and the effects cannot be separated from those of concomitant treatments. There is some indication from case series that DBM preparations are also useful, but additional studies are needed to understand the role of DBM in treating nonunion.

The studies' generalizability to the Medicare population was poor with few studies either reporting results separately for individuals 65 years of age or older or analyzing results by age groups. It is commonly argued that there is no change in healing response with increasing age,(5-7) but whether this holds true across the lifespan (even in the absence of comorbid conditions that predispose to impaired healing) is not evident from the literature we examined. The higher prevalence of osteoporosis in older adults complicates the management of nonunion by reducing the likelihood of successful stabilization with internal fixation.(28,29) Whether the results of treatments in younger adults can be generalized to persons of advanced age is not entirely clear, but reporting of outcomes separately for older patients in studies of nonunion treatments would provide useful information.

## **SCOPE OF REPORT**

The Centers for Medicare and Medicaid Services (CMS) requested that AHRQ commission an evidence report to assist CMS and the Medicare Coverage Advisory Committee in considering treatments for nonunion fractures. On June 16th 2005, AHRQ issued a Statement of Work (SOW) contracting ECRI to prepare a report on the role of bone growth stimulating devices and orthobiologics in healing nonunion fractures. The SOW specified that ECRI perform a narrative review of background information and surgical therapy and a systematic review of bone growth stimulating devices and orthobiologics. In commissioning this report, AHRQ, in consultation with CMS and ECRI, developed six Key Questions to be addressed. These questions are as follows:

1. How is a nonunion fracture diagnosed?
2. What are the risk factors for developing a nonunion fracture?
3. What are the current standards of care for nonunion fractures?
  - a. What supportive measures are recommended?
  - b. What surgical therapies are currently recommended for treatment of nonunion?
  - c. What orthobiologics and external devices for stimulation of bone healing in nonunion fractures have been approved by the FDA and which have not been approved by the FDA?
4. What are the intermediate and patient-reported outcomes of treatment for nonunions, and how are they defined?
5. What is the evidence for variations in outcomes attributable to surgeon, procedure and institution characteristics?
6. What is the evidence for benefits and harms of bone growth stimulating devices and orthobiologics for treatment of nonunion fractures?

Nonunion fractures are defined by their failure to unite across the fracture gap in a prescribed time period.(30) The treatment options for nonunions are designed to restart the course of healing by enhancing the cellular processes that lead to fracture repair. Various surgical approaches, bone growth stimulating devices, and orthobiologics have been used separately or together in an effort to correct nonunion fractures and restore normal physical functioning. For Key Questions 1 through 5, this technology assessment addresses the diagnosis, risk factors, standard of care, important outcomes of treatment, and treatment outcomes for nonunion fractures by examining current reviews, clinical practice guidelines, orthopedic textbooks and selected clinical studies. For Key Question 6, this report systematically reviews clinical studies of bone growth stimulating devices and orthobiologics to assess their role in enhancing the healing process of nonunion fractures. We identified clinical studies relevant to Key Question 6 through electronic and manual searches of literature published between 1990 and 2005. In addition, we performed a supplemental search for the period 1975 to 1990 to expand the information pertinent to electrical bone growth stimulating devices. We also searched the most recent 2 years' worth of meeting abstracts from the American Academy of Orthopedic Surgeons (AAOS), the Orthopedic Trauma Association (OTA) and the American Orthopedic Foot and Ankle Society (AOFAS) for new clinical studies of bone growth stimulating devices and orthobiologics.

This report is intended to highlight, where possible, the relevance of nonunion fracture treatments and outcomes to the Medicare population. Where available, outcome data reported for patients 65 years and older were separately abstracted from included clinical studies and entered into the evidence tables.

The findings of our assessment as they pertain to the six Key Questions are presented below.

## **BACKGROUND**

### **Fracture Healing and the Development of a Nonunion**

Bone tissue is composed of a matrix of 25% water, 25% protein (mostly collagen), and 50% mineral salt (calcium and phosphorus salts and calcium hydroxyapatite) and a small number of bone cells spread throughout the matrix. The components of mature bone marrow, bone tissue and periosteum have distinct composition and function but are interdependent. Bone has three mature cell types that are responsible for the production and maintenance of bone matrix: osteoblasts, osteocytes, and osteoclasts. Osteoblasts are derived from stem cells and progenitors, some of which are capable of forming other mesenchymal tissues such as cartilage, fat, fibrous tissue and muscle under appropriate conditions.(31) Osteoblasts form new bone matrix by secreting collagen fibers and initiating the calcification process. This matrix contains the mineral which provides the tensile strength of bone, as well as type I collagen and other organic components which give bone flexibility.(32) As they mature, some of the osteoblasts survive within the new matrix and develop into osteocytes. Osteocytes maintain the cellular activity of the bone. Osteoclasts, which are derived from a stem cell population derived from hematopoietic stem cells, are responsible for removing old worn-out bone matrix.(31) Compact or dense bone (also called cortical bone) provides support and resists stress. Cancellous bone (also called trabecular or spongy bone) is found adjacent to the joint surfaces of bone and lining the cavity of long bones. Bone is a dynamic tissue that constantly replaces old bone matrix with new bone matrix.(33)

When a bone is fractured, the blood vessels across the break are ruptured. Blood clots around the site of the fracture and forms a fracture hematoma. Because of the disrupted blood supply, many of the bone cells in the fracture site die. The fracture hematoma becomes the center of an inflammatory response that removes cellular debris and prepares the tissue for healing. The inflammatory phase of healing, which constitutes approximately 10% of total healing time, is characterized by a proliferation of various cell types and the infiltration of new blood capillaries into the fracture site.(32)

Transforming growth factor-beta (TGF- $\beta$ ) seems to play a key role in initiating and stimulating the phases of fracture healing that occur after the formation of the fracture hematoma. TGF- $\beta$  is abundant in the bone matrix and in platelets. It controls the proliferation of osteoblasts that lay down collagen fibers in the fracture gap and of osteoclasts that remove the fractured bone particles. The rate at which repair proceeds and the composition of the tissue formed varies depending on the type of bone fractured (i.e., cancellous bone vs. cortical bone), the severity of injury to soft tissue and vascular supply, the stability of the fracture site, the degree of separation of the fracture surfaces, and a variety of host factors (both local and systemic).

Five to ten percent of all fractures do not heal (nonunion) or heal very slowly (delayed union).(34) Bones heal at different rates, leading to different standards for the time by which healing is expected. In addition, for a given anatomic location, the type of fracture is another factor in setting the expectation for time to healing. Court-Brown et al. evaluated several grades of closed and of open tibial fractures, finding a mean healing time of 12 weeks in the simplest closed fractures (n = 38) but a mean of 56 weeks in the most severe open fractures (n = 12).(3)

Initial trauma to the blood supply of the bone medulla and periosteum, a source of osteogenic cells, may be the cause of nonunion in the majority of cases.(30)

Several potential surgical and non-surgical causes for impaired healing may also be involved.(30,34,35) The surgical causes include inadequate stability of the fracture, an excessive residual fracture gap, infection introduced at the time of surgery, and excessive stripping and damage to the periosteum. Non-surgical causes include persistent contamination of the fracture site from the time of an open (compound) injury, an injury with bone loss leading to a lack of apposition of the fracture fragments, insufficient blood flow to the soft tissue at the fracture site, malnutrition, chronic illness, smoking, or use of medications (e.g., non-steroidal anti-inflammatory drugs and corticosteroids) that interfere with healing.

Many orthopedists consider nonunion to be a cessation of the healing process, which, if left untreated, will never heal. Our search did not identify long-term studies supporting



this assumption, but it appears to be based on extensive clinical experience. For example, Mayr et al. stated that “The orthopedic literature is quite clear in stating that all processes have stopped in a nonunion, and healing can only be initiated by another procedure since no spontaneous healing will take place.”(10) This study and another by Nolte et al. on ultrasound treatment of nonunion relied on the assumption that without intervention, a nonunion will not heal. Both studies used patients as their own controls.(9)

### **Overview of Treatment Decisions for Nonunion**

The treatment options for nonunions are designed to enhance the cellular processes that lead to fracture repair. The exact approach depends on the condition of the fracture, surrounding soft-tissue damage, the patient’s preferences and comorbid conditions and the physician’s preference and experience.(36)

The algorithm (Figure 1) illustrates an overall approach to choice of therapy for nonunion. The science of bone healing is still evolving, and the algorithm presented represents an oversimplification of the underlying biological processes.(4,32,37,38) Nonetheless, several reviews and texts organize the decision-making process around these basic principles.

Once nonunion has been diagnosed, the presence or absence of infection is a key determinant of treatment. In general, implantation of new hardware for stabilization may need to be delayed until antibiotic therapy and surgical debridement bring the infection under control (step 1). In some cases, previously implanted hardware must be removed. An external fixation device is sometimes used for stabilization of the fracture site in this setting. Once infection is quiescent, the fracture site is reassessed for nonunion and the subsequent steps followed.

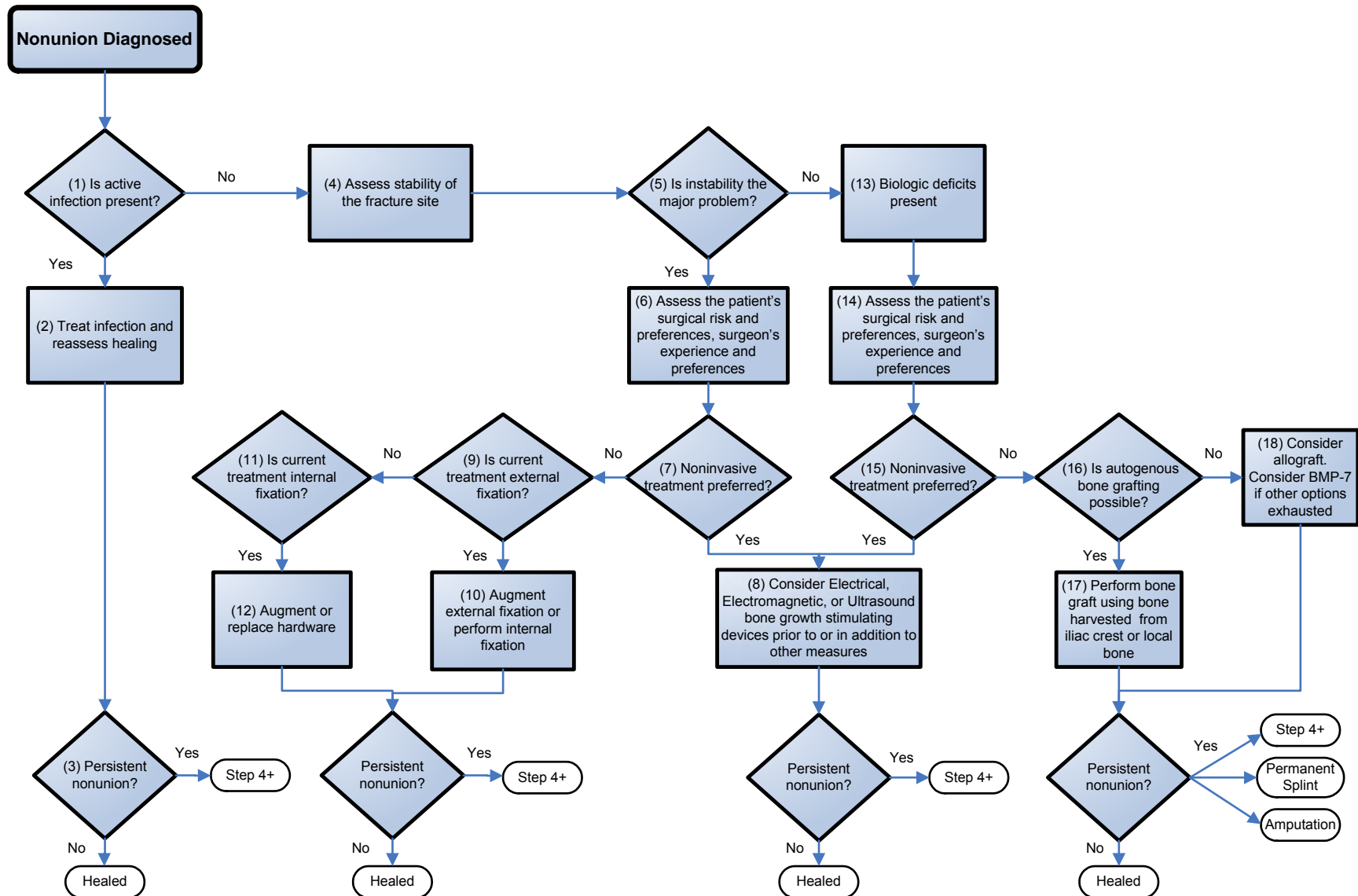
The stability of the fracture site (step 4) may range from none (as in the case of freely movable bone fragments) to fairly rigid (in the case of fragments with good interdigitation and stiff fibrous or cartilaginous tissue across the site).(31) For simplicity, the algorithm is divided into those noninfected nonunions in which lack of stability

appears to be the major problem (step 5) and those in which the biological processes necessary for bone formation have failed (step 13). In practice, both instability and biologic deficits frequently coexist, but one may be the dominant issue for initial nonunion treatment decisions.

The assessment of stability of the fracture site is partially based on the radiographic appearance of the fracture. If a nonunion is accompanied by exuberant callus formation, it is generally assumed that the biologic processes are intact, but that excessive motion or strain at the fracture site has disrupted the healing process. Breakage or loosening of hardware from the stress of motion at the fracture site may be seen on x-ray. Motion at the fracture site on clinical examination may be present.

If the acute fracture has been treated with closed reduction and external support (step) (e.g., cast, brace or external fixator), internal fixation may be necessary to achieve alignment and stability of the nonunion site (step 9). If internal fixation was used in prior fracture management but stability was not achieved (step 11), the hardware may be replaced or stabilization may be supplemented with either additional internal or external fixation (step 12). For example, an intramedullary nail used in the management of a tibial or femoral shaft fracture may be removed and replaced with a nail of greater diameter. A variety of devices and techniques are utilized to stabilize ununited fracture sites, with the choice of hardware and technique determined in large part by the characteristics of the fracture site, the patient, and the surgeon's experience.

Figure 1. Overview of Treatment Decisions for Nonunion



At the other end of the spectrum is the nonunion with good alignment and stability, but no visible callus and a persistent gap between fracture fragments on x-ray. In this situation, a defect in the biological processes is presumed (step 13). Bone resorption occurs at the bone ends and fibrous or fibrocartilaginous tissue may fill the gap, or a synovial capsule may form around the bone ends, creating a pseudoarthrosis.(32) It is often stated that such nonunions, referred to as atrophic nonunions, are relatively avascular, but a study by Reed et al. disputes this assertion. The authors used an antibody labeling technique to quantify vascularity in biopsies of hypertrophic and atrophic nonunions. The study was adequately powered to detect a 10% difference in vascularity at the  $p < 0.05$  level and it did not demonstrate a significant difference in median vessel counts.(39) Nonetheless, it is generally observed that disruption of the blood supply, either by the initial injury or by subsequent surgery, impairs fracture healing and increases the risk of nonunion. Although much has been learned in recent years about the biological processes involved in fracture healing, there are still gaps in understanding the reasons for failure of healing.(40) Clinical experience has shown that fresh bone autograft, which contains viable cells and growth factors, will stimulate fracture healing in the nonunion site (step 17). In current practice, bone graft obtained from the patient's iliac crest or from a bone site near the fracture (e.g., use of tibial bone in distal femur nonunion) is the most common treatment for failure of the healing process.(32) Unfortunately, retrieval of the autograft may cause significant morbidity in terms of blood loss, pain and risk of infection. In some cases, these risks may outweigh the potential benefits (steps 15 and 18). Bone marrow harvested by aspiration also contains osteogenic cells and has been used in the treatment of nonunion. It can be delivered by percutaneous or open routes to the nonunion site, with time to union and volume of callus formed related to the number and concentration of progenitor cells (measured as fibroblast colony-forming units) in the aspirate.(41) Comparisons of bone marrow grafting to standard surgical bone autografting and to the FDA-approved bone morphogenetic protein (BMP-7), OP-1, were beyond the scope of this report.

Untreated allografts are highly likely to provoke an immune response that leads to graft rejection (i.e., excessive local inflammation and subsequent resorption); therefore,

allografts are treated by freezing, freeze-drying or irradiation. Allografts of cancellous, cortical or corticocancellous bone are employed in specific situations, but the efficacy may vary depending on the processing, handling and preservation (step 18).

Given the morbidity associated with autogenous bone harvesting, an alternative treatment for atrophic nonunions with comparable rates of healing and comparable time to healing as bone grafting would provide patients with a valuable option, assuming the new treatment does not also have significant adverse effects. Proposed and current alternatives to bone autografts will be discussed thoroughly under Key Question 6 in the body of this report.

In practice, achieving stability of the fracture site is equally important when bone grafting is performed. Cancellous bone grafts, while rich in growth factors and inflammatory mediators, do not provide mechanical stability; additional measures are generally employed to stabilize the site. Corticocancellous grafts provide some additional support, but unless a graft with retained vasculature is used, the graft will be resorbed and remodeled, decreasing its strength for some time. Some authors refer to the process of reaming the marrow of a long bone (such as the femur or tibia) for placement of an intramedullary nail as an “internal cancellous bone graft.”(42,43) Rodriguez-Merchan notes that while reaming and nailing disrupt the vascular supply to the endosteum, a periosteal vascular reaction develops which stimulates bone formation.(38) Finally, amputation may be an acceptable alternative in some situations, particularly when associated injury to soft tissue and peripheral nerves would leave the limb nonfunctional or persistently painful even with bony union.

### **Anatomic Location of Nonunion Fractures**

The National Center for Health Statistics' National Health Interview Survey for 1992-1994 provides information on the frequency of fractures in the United States.(44) Of a total of 5,946,000 fractures per year, the average annual number of lower leg fractures (tibia, fibula, and ankle) in the United States was 581,000. Approximately 10% of tibial fractures result in nonunions.(30) The majority of nonunion fractures (62%)

occur in the tibia, while 23% occur in the femur, 7% in the humerus and 7% in the forearm.(36) Motor vehicle accidents are the most common cause of tibial shaft fractures, and are more likely to produce open high energy fractures.(3) Advances in fracture treatment in other bones have led to fewer healing problems while advances in emergency medicine have reduced the number of lower limbs that would have been amputated. However, the salvaged lower limbs are more likely to be severely injured and have a higher rate of nonunion than fractures at other sites.(36)

### **Relevance of Nonunion Fractures to the Medicare Population**

Data from the 2002 Health Care Utilization Project (HCUP) Nationwide Inpatient Sample (NIS) estimate that more than 13,000 individuals 65 years of age and older were hospitalized for the treatment of nonunion fractures.(45) This age group was 36% of the total patient population treated as inpatients for nonunion fractures. Medicare was the payer for 14,658 individuals, 38% of the total. Publicly-available HCUP data (HCUPnet) for nonunions are not subdivided by bone type, but data are available on the frequency of fractures in various bone types. Fractures of the humerus accounted for 32,623 discharges for individuals 65 years and older and this age group accounted for 49% of discharges with this diagnosis.(46) Likewise, the principal diagnosis of fracture of the shaft and distal portions of the femur was given in 23,061 discharges and fractures of the tibia/fibula in 13,953, with the older patients comprising 40% of discharges with the former and 20% of discharges in the latter instance. Fractures of the proximal femur (hip fractures) led to hospitalization of 273,161 individuals 65 years and older and this age group accounted for 89% of hip fractures.

Buckwalter et al. state that the rate of healing declines with increasing age only up to the point of skeletal maturity, then remains relatively constant.(32) As stated previously, epidemiologic studies of fracture healing rates would be useful for determining when an ununited fracture is evidence of delayed healing; such studies would also be useful for examining rates of healing with advanced age. While it is generally believed that fractures in older adults normally heal at the same rate as those in younger individuals, age-related changes in the bone tissue could theoretically affect fracture healing in the

elderly and increase the likelihood that nonunions will occur. Several mechanisms have been hypothesized. Osteoblasts and chondrocytes may not be able to fully synthesize matrix proteins because of a decline in protein synthesis capacity or the proteins produced may not be fully functional. The osteogenic stem cells may decline in number and reduce the capacity to produce new osteoblasts. The osteoblasts may have a shorter life span and produce less new bone matrix. The overall decline in cortical and cancellous bone mass and an increase in microarchitectural damage with age may contribute to fracture incidence and delay healing. The bone mass loss with age may be related to a diminished response of bone tissue to mechanical loading stress which would ordinarily stimulate the removal of old bone and the production of new bone. Diminished bone turnover may also be due to a disruption in the communication and coordination between osteoblasts and osteoclasts.(47-51)

It has also been postulated that trophic hormones, growth factors, and cytokine concentrations may decline in the circulation or these substances may not be produced in sufficient quantities during the inflammatory phase of fracture healing. Street et al. examined the effect of age on angiogenesis following fracture.(52) They measured concentrations of vascular endothelial growth factor (VEGF) and platelet-derived growth factor (PDGF) in fracture hematoma and systemic circulation in 16 patients under 40, and in 16 patients over 75 years of age who were undergoing open reduction internal fixation (ORIF) of isolated closed fractures. Serum levels of these cytokines were similarly elevated in both groups, although concentrations of PDGF were lower in the fracture hematoma of the older subjects. However, plasma from patients in both groups induced endothelial cell proliferation in vitro to a similar extent. These authors conclude that impairment of angiogenesis is unlikely to play a role in delayed healing with advanced age.(52)

The higher prevalence of osteoporosis in older adults complicates the management of nonunion by reducing the likelihood of successful stabilization with internal fixation.(28,29) Whether the results of treatments in younger adults can be generalized to persons of advanced age is not entirely clear, but reporting of outcomes separately for older patients in studies of nonunion treatments would provide useful information.

## **METHODS**

### **Key Questions Addressed**

In order to meet the objectives of this report, we address the following Key Questions:

1. How is a nonunion fracture diagnosed?
2. What are the risk factors for developing a nonunion fracture?
3. What are the current standards of care for nonunion fractures?
  - a. What supportive measures are recommended?
  - b. What surgical therapies are currently recommended for treatment of nonunion?
  - c. What orthobiologics and external devices for stimulation of bone healing in nonunion fractures have been approved by the FDA and which have not been approved by the FDA?
4. What are the intermediate and patient-reported outcomes of treatment for nonunions, and how are they defined?
5. What is the evidence for variations in outcomes attributable to surgeon, procedure and institution characteristics?
6. What is the evidence for benefits and harms of bone growth stimulating devices and orthobiologics for treatment of nonunion fractures?

### **Literature Searches**

Details of our search strategies used in searching 10 electronic databases, hand searches of the bibliographies of all retrieved articles, and searches of the gray literature are presented in Appendix A.



## **Inclusion/Exclusion Criteria**

For Key Questions 1, 2, 3a, 3b and 4, we included reviews, clinical practice guidelines, and orthopedic textbooks published between 1990 and 2005. Based on recommendations from our orthopedic consultant,(53) we relied heavily on chapters in the text, *Rockwood and Green's Fractures in Adults*.(54) A limited number of illustrative clinical studies are included as supplements to information in these sources. In addition, studies included for Key Question 6 were used as sources for the list of most frequently used outcome measures addressed in Key Question 4.

For Key Question 3c, we examined the U.S. Food and Drug Administration's pre-market approval (PMA) and 510(k) databases for approvals and marketing clearance for orthobiologics and external bone growth stimulating devices specifically indicated for the treatment of nonunion fractures. For non-FDA approved orthobiologics and external bone growth stimulating devices being used to treat nonunion fractures, we examined all of the included and excluded studies examined for Key Question 6, FDA News, Current Healthcare News, Medscape, the Web sites of AAOS, OTA and AOFAS, and Clinicaltrials.gov.

For Key Question 5, we included only publications from 1990 to 2005 that explicitly linked variations in practice with respect to surgeon, procedure, and institution characteristics to outcomes of treatment.

For Key Question 6, this report systematically reviews clinical studies of bone growth stimulating devices and orthobiologics to assess their role in enhancing the healing process of nonunion fractures. We identified clinical studies relevant to Key Question 6 through electronic and manual searches of literature published between 1990 and 2005. A draft report was submitted for external review to a variety of interested parties, including representatives from orthopedic surgery, manufacturers of bone growth stimulating devices, AHRQ and CMS. This process resulted in a supplemental search for the period 1975 to 1990 to expand the information pertinent to electrical bone growth stimulating devices. Additional articles were identified by reviewers, and in one case, a translation of a study of ultrasound therapy published in German was provided to us.(1)

Abstracts presented for the past 2 years at the American Academy of Orthopedic Surgeons (AAOS), the Orthopedic Trauma Association (OTA) and the American Orthopedic Foot and Ankle Society (AOFAS) meetings were reviewed to identify studies relevant to Key Question 6. Studies identified from the supplemental search and the meeting abstracts are discussed in the body of this report, but are not included in the full evidence tables in the Appendices.

We used the following criteria to determine which studies would be included in our analysis for Key Question 6:

1. Studies published in English. (A translated study provided to us is discussed to provide additional information on ultrasound technology.)
2. Articles published from 1990 to the present. (Studies of bone growth stimulating devices conducted prior to 1990 which otherwise meet our inclusion criteria are discussed to provide historical context for more recent publications included in the systematic review.)
3. Studies of adult humans. The developmental processes involved in bone growth prior to adulthood lead to additional complexities in the treatment of nonunions which are not relevant in the general Medicare population. We did not exclude studies which included a small number of individuals younger than 18 years of age.
4. Studies using controlled, cohort, and case series designs. Controlled studies are the preferred study design for sorting out the influence of the treatment under study from other potential influences. While we did not identify long-term studies to substantiate the belief that nonunions will not heal without further intervention, there appears to be consensus in the orthopedic community that this is the case. Therefore, carefully designed case series that reduce the potential that other aspects of treatment are responsible for healing may provide valid evidence of device or orthobiologic effectiveness. ECRI proposes a careful evaluation of uncontrolled studies in this systematic review to judge the quality and validity of their results.

5. Studies including 20 or more patients. The primary outcome of interest in the studies examined for this report is the percentage of treatment successes (healed nonunions) and failures (continued nonunions). We chose 20 patients as the minimum for inclusion given the predominance of case series. In order to be reasonably confident that reported success rates with treatment were not due to chance, we calculated 95% confidence intervals (using the Wilson Score Method(55,56)) for groups of varying sizes. The 95% confidence interval calculated for a success rate of 70% in a group of 10 patients is 40% to 90%. The confidence interval for the 30% failure rate in this group would be 11% to 60%. With 10 patients, there is considerable overlap in these estimates of success and failure, which are in the range of success and failure rates commonly reported. With 20 patients the confidence intervals narrow. For fifteen successes (75%) and five failures (25%) the 95% confidence intervals are 53% to 89% for the success rate and 11% to 47% for the failure rate. The confidence intervals will decrease further as patient numbers increase, but we considered 20 patients a reasonable minimum number for comparing these series to published success rates for other treatments of nonunion. We followed the commonly accepted practice of requiring at least 10 patients per group for controlled studies.
6. Studies published as full papers. We also reviewed recent abstracts to supplement our review, but did not assign them the same status as full papers.
7. Only the most recent publication of any study reported in multiple publications to avoid duplication of data.

Additional criteria specific to individual questions are presented in the Results section under each Key Question.

### **Data Extraction**

Information extracted from the included studies for Key Question 6 is presented in Evidence Tables in Appendix C. These tables describe study results, design details,

information on enrolled patients, information on the treatment procedures used in each study, and study results.

We have only extracted outcome data relevant to the Key Questions in this report. If relevant data were reported in figures but not in text, we estimated them from the figures. When study authors did not report dichotomous data as percentages, we computed percentages.

## **Evaluation of the Quality of the Evidence Base**

For Key Question 6, we rated evidence strength and internal validity using standard criteria as proposed by the U.S. Preventive Services Task Force (USPSTF). The first step in this process involves identifying the study design and labeling it according to the hierarchy shown in Table 1.(57)

**Table 1. Hierarchy of Research Design (USPSTF)**

<b>Level</b>	<b>Definition</b>
I	Evidence obtained from at least one properly randomized controlled trial.
II-1	Evidence obtained from well-designed controlled trials without randomization.
II-2	Evidence obtained from well-designed cohort or case-control analytic studies, preferably from more than one center or research group.
II-3	Evidence obtained from multiple time series with or without the intervention. Dramatic results in uncontrolled experiments (e.g., penicillin) also qualify.
III	Opinions of respected authorities, based on clinical experience, descriptive studies and case reports, or reports of expert committees.

In recent years USPSTF has recognized that this hierarchy by itself gives inadequate consideration of internal validity (how well a study was conducted). For example, a well-designed cohort study may be of higher quality than a poorly-conducted randomized controlled trial. Therefore, they adopted an additional system for ranking internal validity (“good”, “fair”, or “poor”). A “good” rating means that a study meets all criteria for that particular study design, a “fair” study does not meet all criteria but is judged to have no fatal flaw that invalidates its results, and a “poor” study contains a fatal flaw.(57)

Table 2 presents the criteria used by the USPSTF to judge internal validity. We gave each criteria a ‘yes’ if the study met that criteria and a ‘no’ if the study did not. A “good” study had all yeses, a “fair” study had one or two no’s. We have added an additional category called “low” if the study had three or more no’s, which describes a study that is borderline acceptable (not quite “fair”, but not necessarily fatally flawed). Any fatally flawed studies were excluded. We listed both the USPSTF hierarchy level and the validity results in each of the evidence tables in Appendix D for included studies addressing Key Question 6.

**Table 2. Criteria for Grading the Internal Validity of Individual Studies (USPSTF)**

<b>Criteria for Randomized controlled trials and cohort studies</b>
1. Initial assembly of comparable groups: For RCTs: adequate randomization, including concealment and whether potential confounders were distributed equally among groups. For cohort studies: consideration of potential confounders with either restriction or measurement for adjustment in the analysis; consideration of inception cohorts (We considered prospective case series reporting consecutive patients to be 'yes' and retrospective case series to be 'no' )
2. Maintenance of comparable groups, includes attrition, crossovers, adherence, and contamination. (We considered this to be 'no' if attrition or dropouts were not reported)
3. Important differential loss to followup or overall high loss to followup. (We considered this to be 'no' if attrition was over 20%)
4. Measurements: equal, reliable, and valid, includes masking of outcome assessment. (We considered this to be 'no' if outcome assessment was not blinded/masked)
5. Clear definition of interventions
6. All important outcomes considered. (Studies should report radiographic evidence of healing, pain, and weight-bearing to be considered a 'yes')
7. Analysis: adjustments for potential confounders for cohort studies, or intention-to-treat analysis for RCTs. (We considered this to be a 'no' if the study did not report statistical analysis.)

We estimated the generalizability of each study to the U.S. Medicare population using study enrollment criteria and the reported characteristics of the patients who were actually enrolled in the study. This information is presented in the Evidence Tables in Appendix D.

## **EVIDENCE SYNTHESIS**

Because each Key Question had a different evidence base, we describe each evidence base separately under the relevant Key Question.

### **Key Question 1: How is a nonunion fracture diagnosed?**

This question was addressed using reviews, clinical practice guidelines, orthopedic textbooks and selected clinical studies published between 1990 and 2005. Based on recommendations from our orthopedic consultant,(53) we also used chapters in the text, *Rockwood and Green's Fractures in Adults*.(54) Selected clinical studies are included as supplements to information in these sources.

Nonunion is the failure of a fracture to unite over an expected period of time. In a recent review, Smith et al.(58) stated that “clearly, a fracture that fails to show progressive evidence of healing over a 4- to 6-month period can be considered a nonunion.” However, in a cross-sectional survey of 444 orthopedists, Bhandari et al.(2) found that there was a range in time to declaration of nonunion in the tibial shaft of 2 – 12 months (mean of 6 months, SD 2 months), as well as variations in the use and weight given to radiographic and clinical characteristics.

Some variation in expected time to fracture union reflects different healing rates for different bones.(53) Bones and regions of bones with relatively more cancellous bone and greater vascularity heal more quickly than those with predominantly cortical bone. For a given anatomic location, characteristics of the fracture also determine expected healing rates. For example, Court-Brown et al. evaluated 438 patients with closed tibial fractures and 109 patients with open tibial fractures, finding a mean healing time of 12 weeks in the simplest closed fractures (n = 38) but a mean of 56 weeks in the most severe open fractures (n = 12).(3) A systematic review of epidemiologic studies of time to healing of acute fractures with specific characteristics (e.g., open vs. closed) for specific bones (and regions of those bones) was beyond the scope of this report, but

could be useful for clarifying criteria for delayed union. Once an assessment is made that healing is delayed, most authors define nonunion as the absence of signs of healing for an additional 3 months, although there is not unanimity on this definition.

The radiographic features used for diagnosis of nonunion include the size and shape of callus formation, the continuity of the cortex, the visibility of the fracture line, and the position and integrity of hardware used in the initial treatment.(2) In the survey conducted by Bhandari et al., roughly 40% of surgeons responding stated that they “always” used these features to diagnose nonunion.(2) Plain films of fracture sites are typically taken in orthogonal projections. Additional views to further assess the progress of healing may include oblique projections and stress views. Radiographic evidence of fracture healing lags behind actual healing, as mineralization of the new bone formed occurs late in the process. For example, Ring noted that fractures in the hand can heal uneventfully despite persistence of a fracture line for as long as a year following injury.(59) Other imaging studies may be used to supplement plain films. Standard tomography provides greater detail than plain films and may show persistent fracture lines more clearly.(60) Computerized tomography is a particularly useful imaging modality for more accurately assessing nonunion.(53) The shape of callus formed is described as “elephant’s foot type” (with abundant callus) or “horse-shoe” type in hypertrophic nonunions. Atrophic nonunions demonstrate minimal to no callus and resorption of the ends of the bone fragments. Oligotrophic nonunions are intermediate in character between hypertrophic and atrophic nonunions.(32,58)

MRI may be particularly helpful for determining whether infection is present with nonunion when the presence of hardware does not preclude its use. Radionuclide scans of various types may be used to determine whether there is osteonecrosis or infection, but tissue biopsy may be necessary in some instances. One case series we identified examined the use of ultrasound in addition to standard x-rays to follow fracture healing over a one-year follow-up period, and noted that ultrasound demonstrated multiple bone fragments or poor alignment, loss of a linear echogenic cortical border and absence of a bony bridge in nonunions.(61)



Clinical criteria for diagnosis of nonunion include pain on palpation of the fracture site, and for the lower extremity, pain on weight-bearing. In the survey by Bhandari et al., roughly 40% of orthopedists stated that they “always” used these criteria.(2) Motion at the fracture site may be detectable on physical examination when an unstable nonunion is present.(3) These clinical findings in the absence of radiographic evidence for healing may influence the timing of diagnosis.

Court-Brown’s discussion of the diagnosis of tibial nonunion is illustrative of the difficulty in diagnosis of nonunion.(3) He notes that confirmation of a clinical suspicion of nonunion may be “surprisingly difficult” and that “even after extensive investigations, neither the radiologist nor the surgeon may be completely sure about the diagnosis, and under these circumstances, the surgeon must rely on experience, and the decision as to whether treatment is required is based on clinical grounds.”

### **Key Question 2: What are the risk factors for developing a nonunion fracture?**

In the chapter, “Bone and Joint Healing” in *Rockwood and Green’s Fractures in Adults*, Buckwalter et al. point out that while nonunion may occur in the absence of identifiable risk factors, certain injury, patient and treatment characteristics appear to predispose to nonunion.(32) Injury variables include the severity of injury both to bone and surrounding soft tissue. Open fractures are more likely to be associated with disruption of blood supply, producing necrotic bone and soft tissue which may interfere with formation of the fracture hematoma and predispose to infection. Severely comminuted fractures, whether open or closed, are also associated with severe soft tissue damage, vascular disruption and an impaired bone healing response. Soft tissue may also become interposed between fracture fragments, interfering with reduction and alignment. In contrast, less severe injuries have an “internal splint” in the form of the intact soft tissue envelope and a fracture hematoma, which serves as a source of cells and mediators which promote healing. Intraarticular fractures may be difficult to properly align and stabilize. Segmental fractures may result in a section of bone without adequate periosteal and intramedullary blood supply. Vascular disruption may be a particularly important risk factor for nonunion in bones such as the femoral neck,

scaphoid and talus, which have a limited blood supply under normal circumstances. Areas with minimal surrounding soft tissue, such as the distal tibial region, also have a more limited blood supply and are at greater risk of nonunion following extensive trauma or after surgical procedures.(32)

Of the systemic risk factors, heavy smoking was mentioned in a number of reviews and case series as an important risk factor.(62-67) Obesity, alcoholism, diabetes and peripheral vascular disease were also mentioned.(68) Certain medications, including nonsteroidal anti-inflammatory drugs,(69) corticosteroids and anticoagulants are also thought to increase risk for nonunion or infection.(58) Buckwalter et al. noted that one experimental study found impaired fracture callus strength in the setting of protein deficiency.(32) Some case series describe higher rates of nonunion with increasing age,(70) but based on the study by Street et al.(52) and the discussion in the chapter by Buckwalter et al.(32) presented in the Background section on page 20 of this report, this may not be a generalizable finding. Osteoporosis does not directly interfere with fracture healing, but the decreased bone mass leaves less surface area for contact between fracture ends and the ultimate mechanical strength of the new bone formed will be less than that of nonosteoporotic bone.(32,53)

Certain aspects of fracture treatment interfere with healing, but may or may not be clinically significant. Open reduction or other surgical exposure of a fracture site disrupts the fracture hematoma and may damage the blood supply and surrounding soft tissue. Inadequate stabilization or excessive distraction of fracture fragments by internal or external fixation devices may interfere with healing. In the ideal situation, fracture fragments are in direct contact, in proper alignment and under compressive loads. However, if the periosteum and the soft tissue envelope are well-preserved, minimal separation of the fragments may not significantly deter healing. Buckwalter et al. referenced experimental studies indicating that early weight-bearing and micromotion at long bone fracture sites promotes fracture healing and that decreased loading across the fracture retards healing. Unfortunately, the optimal timing, pattern and intensity of loading is not known for individual fracture types, and could vary based on individual patient factors if it were known. Certainly, continuous and excessive motion at a fracture site is likely to cause nonunion, but the effect of instability is not consistent across

various bones. For instance, closed fractures of ribs, the clavicle, humeral shaft, metacarpals and metatarsals may heal despite persistent mobility on clinical examination. In contrast, fractures of the femoral neck and scaphoid are particularly sensitive to excessive motion, and require immobilization to heal.(32)

While internal fixation devices such as compression plates provide rigid stabilization (commonly referred to as “absolute stability”), they may cause regional bone loss due to transfer of load from the fractured bone to the implant. If an implant is utilized but stability is not achieved, motion at the fracture site may cause additional stress on the bone leading to resorption, as well as stress on the implant, causing device breakage. Inadequate stabilization or immobilization of fractures was cited by several authors as a significant risk factor for nonunion, but was not necessarily attributable to surgical technique, given the nature of the fractures and the need for patients to adhere to difficult treatment plans and intensive followup. When successful, however, rigid stabilization by internal fixation is particularly helpful for treatment of fractures of the radial and ulnar shafts and intraarticular fractures.(32)

As orthopedic techniques and equipment have evolved, certain hardware and techniques have been abandoned because of excessive rates of nonunion associated with their use. For example, transverse osteotomy of the olecranon (used to expose and repair the distal humerus) was associated with a 30% nonunion rate.(71)

Power reaming of the tibia and use of skeletal traction were thought to be risk factors for tibial nonunion by O’Dwyer et al.(72) Among 45 patients with tibial fractures randomized to intramedullary nailing with or without reaming, higher rates of tibial nonunions were found without reaming (3 patients) than with reaming (no patients).(73) Early intramedullary nails that did not provide adequate stability were prone to rotational and axial motion, as well as nail migration, making nonunion more likely.(74) Certain plating systems have caused vascular damage.(75)

Variations in surgical practice addressed in the articles we retrieved included the issue of time to initial surgical repair of an acute fracture. In a retrospective review of open fractures treated at the University of Alberta Hospital in Edmonton, Canada, Harley et al. found no increase in nonunion rates for 100 fractures treated more than 8 hours

following injury with the majority treated within 13 hours compared to 115 treated within 8 hours. In a multivariate logistic regression model, the strongest determinants of nonunion were infection and grade of injury.(76) Roolker stated that diagnosis and appropriate immobilization of scaphoid fractures within a week of injury reduced the risk of nonunion, noting that plain films are often insufficient for diagnosis. Use of a hanging cast was an important risk factor for proximal humeral nonunion in the study by Pugh et al.(74)

### **Key Question 3: What are the current standards of care for nonunion fractures?**

Treatment of nonunion fractures must be individualized as no single method of treatment is applicable in all situations.(30,38) Therefore, a variety of treatment approaches have been developed to treat nonunion fractures. These include surgical placement of internal and external fixation, bone grafting, bone growth stimulators (electrical stimulation, ultrasound stimulation, high-energy extracorporeal shock waves), and orthobiologics (products created to enhance fracture healing). “Osteoinduction” is the process of recruiting mesenchymal type cells (osteogenic stem cells) which differentiate into cartilage and bone-forming cells. Recruitment of these cells is believed to occur with mechanical, electrical and chemical forces.(58) Mechanical force may be applied nonsurgically, as with functional bracing and weight-bearing, or surgically, as with compression plates or intramedullary rods to stabilize the fracture and permit weight-bearing.

To address this question, we have used recent reviews and texts, particularly *Rockwood and Green’s Fractures in Adults*(54), as well as input from our orthopedic consultant.(53,77) Figure 1 (page 19) illustrates a framework for choosing among the options. The discussion of the overarching principles presented in the Background section will not be repeated here, but the same framework will be used for presentation of specific treatments.

**a. What supportive measures are recommended?**

Supportive measures in the care of patients with fracture nonunion were mentioned infrequently in the reviews and series examined. Pugh noted that “nutritional status and smoking habits should be improved before initiating surgical treatment.”(74) As described in the section on risk factors for nonunion, a number of authors have described a higher incidence of nonunion in patients who smoke and they recommend strongly encouraging patients to avoid smoking during treatment of nonunion. Control of infection at the fracture site was also frequently cited as important. Otherwise, articles focused on the presence of comorbid conditions as factors in the choice of procedure to be performed or avoided, but good clinical practice would include stabilizing such conditions as much as possible prior to elective surgical procedures.

**b. What surgical therapies are currently recommended for treatment of nonunion?**

As noted previously, once nonunion is diagnosed, evaluation for infection is important early in the decision-making process (step 1 of Figure 1). If the nonunion is infected, the infection must be brought under control prior to further surgical management. If this is not possible, amputation may be the surgical therapy of choice.(53,77)

In nonunions not thought to be infected, the next decision point pertains to the distinction between “atrophic” and “hypertrophic” nonunion. Hypertrophic nonunions are viewed as a mechanical or stability problem (steps 3 - 8 of Figure 1), whereas atrophic nonunions require attention to the impairment of bone formation (steps 9 -13 of Figure 1).(53) The means of achieving stability in the former and of stimulating bone formation in the latter depends on the location and other conditions of the fracture, in addition to the characteristics and preferences of the patient and the surgeon. The surgical management of nonunions will be discussed in the context of the anatomic regions involved, with emphasis on issues pertinent to the older population.

Bone grafting, in addition to stabilization, is an extremely important component of the treatment of nonunions in which normal growth factors and cellular mechanisms for

osteinduction are either absent or dysfunctional. Autogenous bone and bone marrow grafts contain both of these, but depend on adequate vascular supply at the nonunion site for healing to occur. In some instances, bone grafts are harvested with an intact vascular supply to overcome large bony defects. The iliac crest is the most commonly used donor site, although “local bone,” i.e., from a site close to the nonunion, is also used. Examples include use of bone from the distal tibia for repair of nonunion in the foot.(77)

ECRI has previously summarized complications and morbidities associated with harvesting bone for autografting.(78) This report cited an earlier review of harvest-site complications from the iliac crest published in 2000.(79) The latter review was based on eight studies retrieved from an online search of the National Library of Medicine database for the period 1966 - 1997 using the keywords “bone graft” and “complications.” ECRI pooled the complications across the studies included in that review and found that major complications (those requiring a major change in treatment or return to the operating room and prolonged hospital length of stay) such as deep infections, nerve injuries, and deep hematomas were reported for 1% to 2% of patients. Other major complications such as vascular damage, hernias, and fractures occurred in fewer than 1% of patients. Minor complications (those responding to non-operative intervention) were reported in 1% to 6% of patients and unsightly or hypertrophic scars in about 5% of patients. Chronic pain was reported in 20.5%.(78)

One of the studies included in the review above was a retrospective review of 239 patients (mean age 33 years) who had undergone autogenous bone grafting for a variety of indications at the University of California, Davis, Medical Center from 1982 – 1983. In this study, Younger and Chapman reported a number of complications associated with harvesting of bone. They defined major complications as those requiring increased length of stay, additional surgery or significant disability. Minor complications were defined as those responding to minor treatment or resolving without treatment. Harvest sites included the posterior iliac crest in 48%, the anterior iliac crest in 31.5% and other sites in the remainder. There were 10 patients with early major complications, including wound infections, hematomas requiring treatment and 1 broken

drain requiring removal. There were 11 patients with late major complications – 6 with severe chronic pain, 3 with sensory loss, 1 with osteomyelitis and 1 with wound breakdown. In this series, 84 patients with significant comorbid conditions had a major complication rate of 14.3% in contrast to the rate of 5.8% in 155 previously healthy patients ( $p = 0.02$ ).<sup>(80)</sup>

In a more recent series, Ahlmann et al. reviewed the medical records of 88 patients undergoing bone graft harvesting for limb salvage in treatment of chronic osteomyelitis between 1991 and 1998.<sup>(81)</sup> Mean age in this series was 46 years; all patients received intravenous antibiotics for five days while awaiting culture results from the site affected by the osteomyelitis. The overall major complication rate (using Younger and Chapman's definitions) was 6% (5/66 with an anterior iliac crest harvest site and 1/42 with a posterior iliac crest harvest site). The minor complication rate was 15% (10/66 in the patients with an anterior iliac crest harvest site and 0/42 in those with a posterior harvest site). Blood loss (intraoperative and drain output) was less in the posterior site patients than in the anterior site patients (169 vs. 232 ml,  $p = 0.02$ ). Fifty-eight (66%) patients completed a survey at least 2 years following the procedure. Those who had an anterior harvest site described more post-operative pain for a longer period of time (3 with pain resolving within 6 months and 1 with pain persistent after 6 months) than those with the posterior harvest site (none with pain as a complication – presumably after the early post-operative period). The authors attribute the lower incidence of complications in their series to use of antibiotics, good exposure of the donor graft site, excellent intraoperative hemostasis and use of a drain for 3 days post-operatively. They conclude by recommending posterior harvesting of iliac crest for grafting whenever possible.<sup>(81)</sup>

An unpublished study conducted by Covance Health Economics and Outcomes Services Inc. was provided to us by EBI, one of the manufacturers of non-invasive electrical bone growth stimulating devices, and is provided in Appendix E. Using the Medicare Standard Analytic Files (SAF) of claims filed for inpatient and outpatient services for a 5% random sample of Medicare beneficiaries, Covance examined claims for patients with a primary or secondary diagnosis of nonunion and a procedure code for

bone grafting during the period 1995 – 1997. They also sought data on additional hospitalizations which included orthopedic procedures following the bone grafting procedure. From these claims data, they used secondary diagnoses for the initial bone grafting hospitalization to calculate complication rates of the procedure. The rates reported in their sample included 20.6% with “acute posthemorrhagic anemia,” 3.1% with urinary tract infection, 2.6% “other specified complications, not elsewhere classified,” 2.2% pulmonary collapse, 1.7% hyposmolality and 1.4% “surgical complications, urinary tract.” Other complications listed in their report are more suggestive of pre-existing comorbid conditions or indications for the procedure. We reviewed the list and incidence of complications with our consulting orthopedist, who suggested that while blood loss is an expected complication of bone grafting procedures, the bleeding is not always of clinical significance. He also noted that the diagnosis of “acute posthemorrhagic anemia” affects the diagnosis-related group (DRG) coding for surgical hospitalizations.(28) While claims data may help to identify potential complications of surgical procedures, additional studies with more complete data on patient and treatment characteristics necessary to adjust for possible confounders would be helpful for evaluating the experience of older patients.

In a recent study, 23 nonconsecutive patients with nonunion of the lower extremity were asked to complete the Short-Form Health Survey (SF-36) questionnaire prior to surgical treatment of nonunion.(82) Within the group, 5 had an infected nonunion, and all had undergone previous surgery; one had received electrical stimulation in addition to surgery. Retreatment surgery (bone grafting in 19, additional allograft in 2, reaming and exchange nailing in 6, plating and other fixation procedures) was performed at a mean of 482 days after the original treatment, and the questionnaire was administered a second time at a mean of 449 days later. By that point, 21 of the 23 nonunions had healed. There were significant improvements in the physical functioning score (baseline 23 (SEM 5.6) to 43 (SEM 6.3),  $p = 0.002$ ) and physical role score (baseline 3 (SEM 1.6) to 36 (SEM 8.0),  $p = 0.001$ ). Unfortunately, bodily pain scores did not improve (baseline 23 (SEM 4.2) to 28 (SEM 3.7),  $p = 0.308$ ). Even the post-treatment values for all of the scales remained significantly less than population norms ( $p < 0.01$  for each of



the scales). The authors note that recovery may take longer than the followup in this study.

The following descriptions of surgical treatments by anatomic site are intended to highlight some of the methods of internal fixation described in reviews of the surgical management of nonunion, and is by no means a comprehensive or systematic review of the indications and complications of the associated procedures. In addition, we briefly describe use of the circular external fixator system for tibial nonunion. For each anatomic site, hardware including nails, plates, and screws are designed for use at the specific location. Long bones are treated differently depending on the location of the fracture within the bone – e.g., a fracture near a joint is often treated differently from a fracture in the midshaft of the bone. Hardware is designed to provide stability, but may stimulate bone growth in other ways as well. Bone growth is enhanced when a patient is able to bear weight after stabilization of a nonunion, as the cyclical axial load created by ambulation or active use of the extremity is an important stimulus. Reaming of long bones in conjunction with use of reamed intramedullary nails is generally believed to promote bone and vascular growth despite a temporary disruption of the endosteal blood supply. If a nonunion is well-aligned or if it can be manipulated into good alignment, nailing is performed percutaneously to reduce soft tissue trauma and propensity for infection. The force of compression across fracture fragments created by compression plates is also a stimulus to bone growth. Hardware materials, design, and surgical techniques for placement continue to evolve as better rates of nonunion are sought. Chandler presents a thorough discussion of the major types of hardware, including screws, cerclage wires, plates and nails in his chapter, “Principles of Internal Fixation” in *Rockwood and Green’s Fractures in Adults* in addition to appropriate usage based on fracture location and geometry.(83)

### Sternum

Sternal nonunion may occur following cardiothoracic surgery or trauma. When the nonunion is not infected, plating with or without bone grafting may be used. Wu et al. reported successful treatment of 6 sternal nonunions treated with the Sternalock system

(Sternalock, W. Lorenz Surgical, Inc.). This system uses titanium plates specifically designed for the sternum which have a locking mechanism between the plate and the screw.(84)

### Clavicle

Nonunion of the clavicle is discussed by Lazarus in *Rockwood and Green's Fractures in Adults* and specific surgical techniques are described in the text.(85) Elderly patients are most likely to fracture the outer fifth of the clavicle, and such fractures are prone to nonunion if they are displaced.(86) Some distal clavicular fracture nonunions do not impair function; in other instances, resection of the short fragment may be sufficient.(87) Plate and screw systems, with or without iliac crest grafts, have been used when surgical repair of clavicular nonunions are necessary.(88,89)

### Humerus

Humeral fractures, while not as common as fractures of the distal radius or hip, can cause significant disability in the elderly, particularly when nonunion occurs. The humerus may be the most common site of fracture nonunion in the over 65-year old population.(74,77) Patients with unhealed humeral fractures may experience a great deal of difficulty performing basic activities of daily living. As noted previously, the review by Pugh et al. of humeral nonunions stated that the use of the hanging cast, formerly a commonly used method for management of humeral fractures in older patients, may predispose to nonunion.(74)

Proximal humeral nonunion is associated with shoulder joint contracture, rotator cuff dysfunction, and severe bone loss. Open reduction with internal fixation (ORIF) and bone grafting is typically performed in younger patients, but a shoulder hemiarthroplasty may be recommended for older patients because osteoporosis may compromise the stability of the fixation. With the emergence of "locking plates" this difficult fracture has been addressed in a much improved fashion.(90) While this procedure relieves pain, it does not typically improve function significantly.

Gregory, in his description of treatment of diaphyseal humeral fracture in *Rockwood and Green's Fractures in Adults*, states that compression plating for stability, in combination with bone grafting when the nonunion is atrophic, is the current treatment of choice for nonunion of the humeral shaft.(91) The review by Pugh, et al. states that distal humeral nonunion is associated with elbow joint contracture, ulnar neuropathy and synovial pseudoarthrosis.(74) Surgical repair is complex, but if not done, severe pain and disability often result. Elbow arthrodesis may be performed to reduce pain with distal humeral nonunion, but is considered a "salvage" procedure as it results in significant disability.(74)

For each of these locations in the humerus, specific hardware and techniques have been developed for management of nonunion, following the general principles outlined above. The specific descriptions of these are beyond the scope of this report. The technical skill required for these procedures may be altered by the design of the hardware. For example, the "wave plate" used with bone grafting for diaphyseal nonunion in the study by Ring et al.(92) is said to be less technically demanding than other methods of fixation. Further, the wave plate, which is contoured to avoid contact with the cortex immediately beneath it, has the advantage of decreased resorption of bone beneath the plate compared to standard plates.(83)

Circular external fixators, described below for treatment of tibial nonunion, have also been used successfully in management of humeral nonunion.(93)

## Forearm

Fractures of the distal radius are quite common in the elderly and are discussed by Strauss et al. in the text, *Brocklehurst's Textbook of Geriatric Medicine and Gerontology*.(94) Standard treatment of an acute distal radius fracture in an older individual has traditionally been closed reduction and casting. Unfortunately, the degree of impaction that occurs with these fractures leads to bone compression, resulting in malunion and nonunion in many patients treated only by casting. More aggressive treatment of the initial fracture is now recommended.(94) The advent of "locking" distal

radius plates has provided a popular and generally successful treatment alternative for nonunion of the radius.(90) In their review of distal radius fractures, Prommersberger et al. state that wrist arthrodesis may be necessary as a last resort for management of instability and pain.(68) Dynamic compression plating and screws designed for the small fragments of bone involved, coupled with autogenous bone grafting, are described in the review by Ring for management of nonunion of the radius and ulna.(95)

### Scaphoid

Nonunion of scaphoid fractures is an important problem in younger patients, but appears to be less common in older patients.(77) A systematic review of 147 publications examining vascularized and nonvascularized bone grafting with and without internal fixation (IF) for scaphoid nonunions found that vascularized bone grafting with or without IF yielded the highest rates of union (91%), followed by vascularized bone graft with IF (84%) and nonvascularized bone graft without IF (80%).(96)

### Hand

Ring has recently published a review of malunion and nonunion of the metacarpals and phalanges.(59) He points out that the hand cannot be immobilized for prolonged periods without permanent stiffness, and advises against immobilization for more than six weeks. In some cases, amputation may result in a superior functional outcome, particularly if there is permanent sensory loss, chronic infection, severe stiffness or insufficient skin coverage. Arthrodesis is used in conjunction with internal fixation across a stiff joint when a nonunion is periarticular. If a digit is likely to be functional once the bone heals, internal fixation using varying types of plates and screws is used to provide alignment and stability, although tenolysis and arthrolysis are usually required at the same time. Nonunions in the hand are usually atrophic, and many have bone defects, both of which necessitate bone grafting. Nonstructural, or cancellous, bone is typically sufficient for stimulation of osteogenesis, but a corticocancellous graft can be used to add some structural support and share the mechanical load with the implanted

hardware. Ring cautions that even with advances in technique, however, function of digits following repair of nonunion is likely to be limited.(59)

### Pelvis

One series of 70 late post-traumatic pelvic nonunions described patients with this condition as typically having severe pain and difficulty maintaining sitting balance. The author describes surgical treatment with debridement of the nonunion site, reapproximation of the bone fragments, bone grafting and internal fixation.(97) After surgery, 96% of the patients achieved a primary union.

### Femur

Strauss et al., in the chapter on “Orthopedic Geriatrics” in *Brocklehurst’s Textbook of Geriatric Medicine and Gerontology*, state that fractures of the femoral neck may result in nonunion in 5% of patients if the fracture is not displaced, but that the rate may be as high as 35% when there is displacement. Nondisplaced fractures may be treated with internal fixation, whereas hemiarthroplasty or total hip arthroplasty is recommended for displaced fractures.(60,88,94) Intertrochanteric fractures involve cancellous bone, and consequently, they tend to heal well. Ununited femoral shaft fractures often require removal of hardware used in initial fracture management and subsequent fixation with either nailing or plates and screws.(98)

### Tibia

Tibial fractures are the most common open fractures in the elderly.(94) As in younger patients, such fractures are at risk for infection as well as compromise of vascular supply and skin coverage. Severe soft tissue disruption may result in interposition of tissue at the fracture site that prevents bone healing. Infection may also result in sequestra which interfere similarly. Atrophic skin predisposes to wound breakdown and infection. One author commented that amputation may be preferable to the “18 months of intensive orthopedic care” and uncertain functional outcome with surgical repair of

tibial nonunion.(99) Reamed intramedullary nailing was used in the majority of recent series of tibial shaft nonunions. With tibial deformity, however, compression plating was used to correct this when possible. Wiss noted, however, that the compression plate may not provide stability in patients with severe osteopenia.(30) Bone grafts and percutaneously injected marrow aspirates were used in some series.(30,88,100) To enhance the effect of axial load on bone formation, hypertrophic tibial fractures are sometimes treated by excision of a section of the fibula, causing the full force of weight-bearing to be transmitted through the tibia.(30)

ECRI previously reviewed surgical treatment for nonunion of the tibia.(78) Surgical approaches to treatment of tibial nonunions vary, but typically involve the use of a fixation device with or without a bone graft or bone-graft substitute. Hypertrophic nonunions may be treated using fixation alone. Bone grafts may not be necessary in all hypertrophic nonunions, but atrophic nonunions are likely to require osteogenic stimulation such as that provided by a bone graft.(30)

The following list briefly summarizes the commonly used surgical options for tibial nonunion:(30)

- **Fibular Osteotomy.** In some cases, an intact fibula may prevent close apposition of the tibial fragments and prevent compressive forces that enhance healing. Removing a small segment of the fibula can correct these problems and when combined with surgical stabilization of the tibia may also be necessary to aid in deformity correction. This procedure should not be performed to treat unstable atrophic nonunions.
- **Plates.** A titanium plate that spans the fracture site can be fixed with screws to either the lateral or medial aspect of the tibia. The plate helps to correct deformities, increases nonunion stability, and decreases rotational shear at the nonunion. Plating removes the need for a cast or brace. Atrophic nonunions of the tibia are typically treated with bone grafting in addition to the plate.
- **Intramedullary Nailing.** In this procedure, a metal rod (intramedullary nail) is placed inside the shaft of the bone. A hole is drilled at either the proximal or distal end of the

bone, and the rod is passed through the length of the bone, providing mechanical strength. The medullary cavity, which occupies most of the shaft of the bone, is usually reamed before rod insertion. This procedure is used only in closed fractures and in open fractures with little deformity. Intramedullary nailing may be impossible in patients with substantial deformity.(78)

External fixation may be used alone or in conjunction with internal fixation for hypertrophic nonunion in the tibia.(101,102) An external fixator stabilizes the nonunion sufficiently to permit partial to full weight-bearing, but the need for prolonged use and frequent pin-tract infections make the device less attractive. The circular fixator, known by the name of its inventor, Ilizarov, may be used in the setting of significant bone loss, deformity or infection. A “corticotomy,” or osteotomy with preserved endosteal and periosteal blood supply, followed by bone transport, is used to provide healthy bone at the site of the defect. An external fixation apparatus attached to the limb by wires under tension creates a controlled degree of distraction of the bone ends for limited periods several times a day. Stem cells fill the distraction gap and differentiate into osteoblasts. Blood flow to the area increases by up to 40%. The device also permits full weight-bearing regardless of the size of the bony defect, adding further stimulus to bone formation.(58) The drawbacks to this approach include pin-tract infections, the need for the patient to wear the device for a prolonged period of time, the extensive inventory of equipment necessary for customizing the apparatus to the individual patient, and the difficulty of mastering the techniques of application and maintenance by the surgeon.(30)

### Ankle and foot

When small bone fragments remain ununited in the foot following a fracture, they are sometimes simply excised to relieve pain. Otherwise, internal fixation and bone grafting techniques are used as in other locations. The distal tibia or the calcaneus may be used as harvest sites. Corticocancellous bone is used to bridge larger defects, with special surgical techniques adapted for the location. In one procedure, the medullary canal is drilled and a “plug” of corticocancellous bone inserted. In another technique, a dorsal

groove is created in the cortex of the ununited bone fragments and a bridging graft is compressed and placed across the fracture line into both segments.(103) The “Jones fracture” is a transverse or short oblique fracture at the junction of the metaphysis and diaphysis of the fifth metatarsal, entering the fourth-fifth intermetatarsal joint. The rate of nonunion for Jones fractures is 7 – 28%. Intramedullary screw fixation with bone grafting using corticocancellous bone from the tibia is typically used for management of Jones fracture nonunion.(104)

**c. *What orthobiologics and external devices for stimulation of bone healing in nonunion fractures have been approved by the FDA and which have not been approved by the FDA?***

To address this question, we examined the U.S. Food and Drug Administration’s (FDA) pre-market approval (PMA) and 510(k) databases for approvals and marketing clearance for orthobiologics and external bone growth stimulating devices specifically indicated for the treatment of nonunion fractures. For non-FDA approved orthobiologics and external bone growth stimulating devices being used to treat nonunion fractures, we examined all of the included and excluded studies examined for Key Question 6, FDA News, Current Healthcare News, Medscape, the American Academy of Orthopaedic Surgeons Web site, the American Orthopedic Foot and Ankle Society Web site, and Clinicaltrials.gov. The list of orthobiologics and bone growth stimulating devices with potential use in the treatment of nonunion fractures are presented in Appendix B. We acknowledge that this list does not include all orthobiologics products being used for treatment of nonunion, as some of products have either not been studied specifically in the setting of nonunion but are used at the discretion of the treating surgeon.

The FDA considers most orthobiologics to be Class II medical devices and we have listed these in Table B-1. A 510(k) is a pre-marketing submission made to FDA to demonstrate that the Class II device to be marketed is as safe and effective, that is, substantially equivalent (SE), to a legally marketed device that is not subject to premarket approval (PMA). Applicants must compare their 510(k) device to one or more



similar devices currently on the U.S. market and make and support their substantial equivalency claims. The legally marketed device(s) to which equivalence is drawn is known as the “predicate” device(s). Unlike PMA, which requires demonstration of reasonable safety and effectiveness, 510(k) requires demonstration of substantial equivalence. Substantial equivalence means that the new device is as safe and effective as the predicate device(s).

FDA section 888.3045 – Resorbable calcium salt bone void filler device (Common name: bone void filler) lists these products as Class II devices. The FDA identifies the 888.3045 category as follows: “A resorbable calcium salt bone void filler device is a resorbable implant intended to fill bony voids or gaps of the extremities, spine, and pelvis that are caused by trauma or surgery and are not intrinsic to the stability of the bone structure.” In addition, “Bone void filler devices composed of alternate materials may be demonstrated to be substantially equivalent under section 510(k) of the Act to the resorbable calcium salt bone void filler device identified in this guidance document.”(105) The bone void filler category of the FDA contains 40 products with demineralized bone matrix (DBM). DBM is processed from human bone tissue using a demineralizing agent such as hydrochloric acid. The mineral content of the bone is typically reduced to less than 5% of the native levels and the remaining substance is DBM containing a variety of bone growth stimulators (osteoinductive agents such as bone morphogenetic proteins).(106,107) DBM is used in a number of bone graft substitutes. Therefore, these products may see future use in treating nonunion fractures (an FDA off label use) and some of these products are included in Table B-1.

In addressing Key Question 6 of this report, we looked for clinical evidence that such off-label use of DBM products (as a substitute for autogenous bone graft material) in treating nonunion fractures improved outcomes. However, we identified only one study using a DBM product as a bone graft substitute. This study is examined in detail under Key Question 6.

The FDA has granted a “Humanitarian Device Exemption”(HDE) for use of OP-1 (BMP-7) in settings where an autograft has been ineffective or not feasible and alternative

treatments have failed. The single included study of this agent is discussed under Key Question 6 and summarized in Table D-6.

Table B-2 lists the external bone growth stimulating devices used to treat nonunion fractures. The medical devices listed in this table are considered to be Class III by the FDA.(108) FDA has three regulatory classes for medical devices based on the degree of control necessary to assure that the devices are safe and effective. Class III devices—those that support or sustain human life, are of substantial importance in preventing impairment of human health, or present a potential, unreasonable risk of illness or injury—are the most regulated devices. Premarket approval by the FDA is the required process of scientific review to ensure the safety and effectiveness of Class III devices. Data from clinical studies are usually required for a Class III medical device to receive a PMA.

Currently, a number of electrical stimulation devices and ultrasound devices have been approved by the FDA for treating nonunion fractures (see Table B-2). Shock wave treatment has not been approved by the FDA for use in the United States. Several studies performed in Europe have examined the efficacy of this treatment for nonunion fractures. These studies are examined in detail under Key Question 6.

**Key Question 4: What are the intermediate and patient-reported outcomes of treatment for nonunions, and how are they defined?**

Bhandari et al. addressed the question of how fracture healing is assessed by surveying 577 orthopaedic surgeons.(2) Responses were received from 444 surgeons for a response rate of 77%. Three radiographic variables were most often used by the respondents: callus size, cortical continuity, and progressive loss of fracture line. The ability of the patient to bear weight on the affected limb and pain at the fracture site on palpation were the two nonradiographic methods most often used. The authors noted, however, that a lack of consensus existed among the surgeons as to which method they most often use and which methods they would not use. Cortical continuity is believed to be most directly related to return of original bone strength while callus size is the least

related. Therefore, according to Bhandari et al.'s survey of orthopedic surgeons, cortical continuity would seem to be the preferred indicator of nonunion healing. However, this outcome may not be directly related to a patient's ability to bear weight on or have full function of an appendage without pain. The survey results also indicate that surgeons often combine the radiographic evidence with evidence from clinical examination related to weight-bearing, pain on weight-bearing, pain on palpation, and movement of the nonunion. Sharrard points out that the radiographic evidence of cortical bone bridging in his study of tibial nonunions treated with PEMF stimulation or a dummy device did not match the clinical evidence of healing.(12) After 12 weeks of treatment, radiographic evidence of bridging was seen in less than half of all patients while lack of movement in the nonunion was seen in more than half of all patients. While movement of the nonunion always indicates lack of healing, lack of movement does not always indicate healing. Sharrard states that "absence of movement on clinical examination combined with radiological evidence of union seems, therefore, to be a reliable indicator of bone union." For this report, we considered studies that used a combination of radiographic and clinical evidence of healing as superior to studies that used only radiographic evidence or only clinical evidence.

From the included studies of Key Question 6, we compiled a list of the methods used in the included studies for measuring treatment outcomes for nonunion fractures(see Appendix C). Radiographic evidence of bone bridging was used in all of the studies but various methods were used to define successful bridging, and not all studies specifically defined how this outcome was measured. Fewer studies used clinical assessments such as pain and pain on weight-bearing as outcomes related to nonunion healing.

**Key Question 5: What is the evidence for variations in outcomes attributable to surgeon, procedure and institution characteristics?**

We identified no publications that directly addressed this question.

**Key Question 6: What is the evidence for benefits and harms of bone growth stimulating devices and orthobiologics for treatment of nonunion fractures?**

**Proposed mechanisms of action**

Fracture healing relies on a coordinated series of phases in which damaged nonfunctional tissue is replaced by functional tissue that restores the original structure and function. Each phase in the healing sequence relies on specific growth factors to ensure complete healing and bone restoration. Application of these growth factors directly into the fracture has been proposed as a means of enhancing bone repair.(109) The key growth factors are members of the transforming growth factor-beta (TGF- $\beta$ ) family. The TGF- $\beta$  proteins have a broad range of cellular activities related to wound healing and to cell proliferation and differentiation in all organs of the body, especially in skeletal bone. The extracellular matrix of the bone is the largest source of TGF- $\beta$  proteins in the body. In bone tissue, these proteins stimulate the production of chondrocytes, osteoblasts, and osteoclasts from precursor cells (osteogenic cells).

Another element in the repair process is the type of stress applied to the bone during healing. Chao and colleagues have proposed that biophysical stimulation plays a key role in repairing, maintaining, and remodeling of bone to meet its functional demands.(4,29) Mechanical intervention might be the only means to assure bone remodeling after callus formation and maturation in order to restore the bone to its original structure and strength. However, the direct link between biophysical stimulation and the cellular responses controlled by the various growth factors have not yet been determined. The connection may be found in the phenomenon called Wolf's Law that relates bone stress with bone remodeling.(110) Bones under stress have increased remodeling and produce more bone matrix while bones that are not stressed undergo increased reabsorption and lose bone matrix. Osteocytes have been hypothesized as the cellular bone component that senses the changes in stress and signals osteoblasts to speed up or slow down the remodeling process. The same may be true for

osteocytes in the area of a fracture. The exact mechanism by which osteocytes sense mechanical stresses and signal other bone cells is not known.

Chao and colleagues have also proposed that the biophysical stimulation needed to enhance fracture healing can be supplied through external energy such as ultrasound, pulsed electromagnetic field stimulation, low power direct current, and extracorporeal shock wave stimulation.(4) Whether these modalities produce different cellular responses or follow a similar osteogenic pathway is still controversial. The proposed mechanisms of action for each of the various external bone growth stimulators and orthobiologics are based on extensive animal and cell culture experiments.(4,109)

### Ultrasound stimulation

Ultrasound is a form of mechanical energy that can be transmitted through tissue as acoustical pressure (sound) waves. Low intensity ultrasound used to treat nonunions does not involve heat generation or destruction of bone tissue. As the low intensity pressure wave generated by the ultrasound device passes over the surface of fracture, the tissues in the callus may be mechanically stimulated and generate a biochemical response. Ultrasound therapy may increase the expression of genes involved in bone healing, increase the secretion of growth factors, increase ossification of bone matrix, and enhance blood flow into the fracture site, all of which could contribute to the healing of nonunion fractures. Ultrasound therapy is applied for 20 minutes each day.(9,10,33,111)

### Electrical and magnetic stimulation

Mechanical stress within bone generates electrical potentials (the potential energy measured in volts between two areas with different charges). This is known as the piezoelectric effect and may be due to shifts in the interstitial fluid and its ions as bones undergo normal compression and tension. Areas of compression become electronegative and areas of tension become electropositive. The electronegative areas produce new bone while the electropositive areas increase bone resorption. Electrical

fields applied to the fracture site are thought to aid bone healing by enhancing the normal electrical potentials and upregulating the cellular processes involved in bone formation. Callus vascularization, cell proliferation, matrix protein synthesis, and secretion of growth factors may be enhanced by electrical stimulation. Electrical bone growth stimulators are of three types: direct current, capacitive coupling, and pulsed electromagnetic fields (PEMF). The proper use of externally applied electrical bone growth stimulators, capacitive coupling or PEMF usually requires patient compliance and long-term immobilization of the limb using internal fixation, external fixation, casting or bracing. Patient adherence to the treatment plan is of particular importance with PEMF given the duration of daily treatment sessions. Studies of these devices should measure patient adherence or ensure patient adherence through mechanisms built into the device.(33)

Treatment with electrical and magnetic stimulation devices may be compromised by the presence of fixation devices made from magnetic material.(112) Most of the internal and external fixation devices in current use are made from titanium alloys or cobalt-chromium alloys that are non-magnetic and are compatible with electrical and magnetic stimulation devices.(30,34,59,113-115)

*Direct current* – Direct current devices are considered invasive because they require that the cathode electrode (negatively charged) be implanted directly in the nonunion defect and the anode electrode (positively charged) be placed under the skin. The generator provides a constant current power source. The optimum current is between 5 and 20 microamperes. A nonweight-bearing cast must be used to prevent motion that might break or dislodge the cathode electrode. This system requires the least patient compliance because the device is always active. When the treatment period has ended, the electrodes may be surgically removed. The cathode, however, may be left in place within the bone. Compared to the other electrical stimulation systems, direct current devices produce a high local voltage gradient while the other devices produce small voltage gradients.(16,113,114)

*Capacitive coupling* – Capacitive stimulators consist of a power source and two electrode disks. The disks are attached directly to the skin on either side of the nonunion. A weight-bearing cast can be worn, but it must allow access to the electrodes. The stimulator produces an internal electric field with a frequency of 60 kilohertz, which does not require a high-voltage power source. The device can run on a 9-volt battery and produces a current between 5 and 10 milliamperes for optimum effect. The voltage gradients in the field are relatively small but cover a larger local area compared to direct current stimulation or PEMF. This system is noninvasive and alarms indicate when the electrodes lose contact or the battery is low. These devices are also on continuously during the treatment period.(15-17,33,34,113,114)

*Pulsed electromagnetic fields (PEMF)* – PEMF stimulators are manufactured in various designs to accommodate the bones being treated. One design consists of two external coils placed parallel to each other and over the nonunion. Other designs have only a single coil. Electromagnetic fields are generated when current flows through the coil. The fields extend at right angles to the coil and penetrate the bone. PEMF stimulators may be used with a cast. Power is delivered to the unit with a rechargeable battery. The electrical fields have a small voltage gradient but over a small tissue area. Stimulation is applied for 8 to 14 hours daily, often at night. These devices are also noninvasive but might not work effectively with internal plate fixation, which could shield the nonunion from the magnetic fields.(11,12,14,27,33,113,115-117)

### High-energy extracorporeal shock waves (ESW)

Shock waves are large-amplitude compression waves that pass through a fluid. A shock wave is caused by a sudden, violent disturbance of the fluid. For the purpose of medical therapy, the shock wave is directed at a specific site to be treated. The shock waves are not hindered by water or soft tissue but become destructive when they hit high density tissue such as bone. New microfractures and small bone fragments are believed to be formed at the site of a fracture or nonunion. For treatment of nonunions, the shock wave generator and focusing device are enclosed in a water-filled balloon that is placed next to the nonunion. A typical therapy session involves delivery of thousands of shock

waves but the patient usually requires only one session,(although some patients may require a second session if the nonunion has not healed after 3 months). Treatments are performed under local or general anesthesia, with each session lasting between 30 minutes and 1 hour. The actual mechanisms of action responsible for shock wave's effect on fractures and nonunions is unknown, but the short-term destruction of bone tissue may enhance cell proliferation and the production of new bone.(19,118-121)

### Orthobiologics

Orthobiologics require an invasive surgical procedure for placement in the nonunion site. Included in this group are materials that provide structural support for bone growth stimulated by other means and materials that directly stimulate bone growth.

*Osteoconductive matrix materials* – Osteoconductive materials provide a three dimensional substance into which capillaries, osteogenic cells, and other tissue can migrate and produce new bone. This material acts only as a scaffold into which the new cells grow. The material is porous and has chemical structures similar to cancellous bone. Calcium sulphate (plaster of Paris) and tricalcium phosphate are biocompatible and resorbable. Hydroxyapatite, a form of calcium phosphate and the principal bone salt, has a structure similar to cancellous bone and provides more support than calcium sulphate or tricalcium phosphate but is not as resorbable.(106,107,122)

*Osteoinductive bone graft substitutes* – Osteoinduction refers to the induction of osteoblast formation from osteogenic stem cells. The osteoinductive properties of bone tissue are attributed to bone morphogenetic proteins (BMPs), of which there are 14 known types (BMP-2 through BMP-15). These proteins are members of the TGF- $\beta$  supergene family. Several recombinant human BMPs have been shown to have particularly strong osteoinductive activity in a variety of animal species. These include BMP-2, BMP-4, BMP-5, BMP-6, and BMP-7. When placed in a carrier that provides a framework for bone formation, BMPs are believed to be able to provide the osteoinductive properties lacking in other bone substitutes.(31,34,122-125)



Demineralized bone matrix (DBM) is processed from human bone tissue using a demineralizing agent such as hydrochloric acid. The mineral content of the bone is reduced to below 5% of native levels. The remaining substance is 90% type I collagen and 10% non-collagenous proteins containing a variety of bone growth stimulators (osteoinductive agents such as bone morphogenetic proteins). DBM is used in a number of bone graft substitutes and is both osteoconductive and osteoinductive.(106,107,122)

*Osteoprogenitor cells* – Bone marrow obtained by aspiration from the iliac crest is a source of osteogenic stem cells that can be placed into a nonunion either by percutaneous injection or by an open surgical procedure. Centrifugation of the bone marrow allows concentration of osteogenic cells and their progenitors in the sample. The FDA has approved a system for collection and processing of bone marrow aspirate for use as a bone graft substitute (Collect™, DePuy), but its use for treatment of nonunion has not been published in the peer-reviewed literature.(31) In the future, growth factors may be used to stimulate proliferation and differentiation of stem cells.(107,122)

### **Evidence Base**

We identified 42 articles that potentially met our a priori inclusion criteria and were therefore retrieved. On retrieval, 18 of the 42 articles were found not to meet our inclusion criteria. These articles and the reason for their exclusion are listed in Table D-1 of Appendix D. Fourteen of the 18 studies were excluded because they had less than 20 patients in the study. The remaining four studies were excluded for reasons not related to patient numbers. One study was excluded because it did not examine nonunion fractures, two studies were excluded because they were technical papers and did not report patient data, and one study was excluded because the patient data were reported in another included study.

Having excluded the 18 articles above, 24 studies remained. These studies, which are listed in Table 3, consist of three studies of ultrasound, seven studies of PEMF, four studies of direct current and capacitive coupling, six studies of shock wave, and

four studies of orthobiologics. Details of these studies are presented in the tables in Appendix D.

**Table 3. Evidence Base for Key Question 6**

References	Study Design	N
Ultrasound (see Table D-2)		
Mayr et al. 2002(1)	Prospective case series	100
Nolte et al. 2001(9)	Prospective case series	29
Mayr et al. 2000(10)	Retrospective case series – registry data	1317
Pulsed electromagnetic fields (see Table D-3)		
Simonis et al. 2003(11)	RCT	34
Sharrard 1990(12)	RCT	45
Traina et al. 1991(14)	Retrospective comparison study	67
Ito and Shirai 2001(116)	Retrospective case series	30
Adams et al. 1992(126)	Retrospective case series	54
Garland et al. 1991(27)	Prospective case series	139
Meskens et al. 1990(117)	Retrospective case series	34
Direct Current and Capacitive Coupling (see Table D-4)		
Scott and King 1994(15)	RCT	21
Brighton et al. 1995(16)	Retrospective comparison study	271
Zamora-Navas et al. 1995(17)	Retrospective case series	22
Cundy and Paterson 1990(18)	Retrospective case series	37
Shock wave (see Table D-5)		
Biedermann et al. 2003(19)	Prospective case series	73
Rompe et al. 2001(20)	Prospective case series	43
Schaden et al. 2001(21)	Retrospective case series	115
Wang et al. 2001(119)	Prospective case series	72
Vogel et al. 1997(120)	Prospective case series	48
Valchanou and Michailov 1991(22)	Retrospective case series	79
Orthobiologics (see Table D-6)		
Friedlaender et al. 2001(23)	RCT	124
Wilkins and Kelly 2003(24)	Retrospective case series	35
Johnson and Urist 2000(127)	Retrospective case series	30
Johnson et al. 1992(128)	Retrospective case series	25

### **Quality of Included Studies**

Each study was examined for quality according to the USPSTF rating system of research design and internal validity, interpreted for this clinical topic, as described in the Methods section of this report. The rating is included in the evidence tables in Appendix D and will be discussed below for each study. None of the included studies were rated “poor” quality, i.e., “fatally flawed.”

### **Study Design**

We identified only four randomized controlled trials (RCT): two for PEMF, one for capacitive coupling, and one for orthobiologics. We included case series in this report based on the prevalent belief that nonunion fractures are not likely to heal without intervention (see discussion in the Background section). Some of the reviewers of the draft of this report preferred to describe these as “self-paired patient controlled” studies – with each patient serving as his or her own control.(5-8) For the purpose of this report, however, we have considered these studies with no separate comparison group to be case series rather than controlled trials.

While declared nonunions are unlikely to heal spontaneously, concomitant treatments (e.g., changes in immobilization of the fracture site or improvements in comorbid conditions) provided in addition to the primary treatment under investigation may contribute to nonunion fracture healing.(129) Of the six studies with a comparison group, five reported nonunion healing in some patients not receiving the treatment under study.

**Table 4. Included Studies with Control Groups Treated for Nonunion Fractures Addressing Key Question 6**

Reference	N	Duration of Nonunion (weeks)	Prior Treatments	Control Treatment	Time to Healing (weeks)	Healing Rate (%)
Simonis et al. 2003(11)	16 nonunions	Mean: 123 SD: 74	Patients had undergone an average of 4.2 prior surgical procedures	Oblique fibular osteotomy followed by a unilateral external fixator with compression	Not reported	50% (8 of 16)
Friedlaender et al. 2001(23)	61 nonunions	Median: 68	Prior autograft: 31% Prior IM rod: 44%	Bone graft	At 36 weeks	85% (52 of 61)
Brighton et al. 1995(16)	48 nonunions	Mean: 89.6 Range: 36 - 256	Prior bone graft: 48% Prior electrical treatment: 50% Metal fixation present: 44%	Bone graft	Not reported	58% (28 of 48)
Scott and King 1994(15)	11 nonunions	Mean: 104 Range: 48 - 172	Patients had undergone an average of 1.8 prior surgical procedures.	Managed conventionally with a plaster cast or brace as was appropriate for the specific fracture.	Study stopped after 26 weeks	None
Traina et al. 1991(14)	26 nonunions	Mean: 104 Range: 36 - 720	Patients had undergone an average of 1.4 prior surgical procedures	These patients were treated for unsatisfactory biomechanical conditions (bone loss over 1 cm, inadequate immobilization, non-alignment of bone stumps) which could account for the lack of healing by the most appropriate orthopedic technique.	Mean: 31.2	69% (18 of 26)
Sharrard 1990(12)	25 delayed unions	Mean: 24.2 SD: 4.6	No prior treatments other than initial fracture treatment (no internal or external fixation)	A full-leg plaster cast was applied.	Healing evaluated at 12 weeks	12% (3 of 25)

For a case series to be judged a “good” quality study (in terms of internal validity) in this review, it would have to be prospective, to account for all patients treated, to follow at least 80% of patients for the entire study period, to assess radiographic evidence of healing (as well as pain and weight-bearing), to use a blinded or masked assessment method, to report a statistical analysis of results, and to clearly define the interventions employed. There were no case series meeting all of these criteria; four failed to meet one or two of the criteria, and were considered “fair.”(9,20,27,119) The remaining case series were judged to have low internal validity.

### Comparability of Outcomes

Most of the studies in the evidence base rely on radiographic evidence as the only indicator of nonunion healing. As previously mentioned, Bhandari et al. 2002(2) found that 79% of surgeons use radiographic evidence of cortical continuity as their primary means of defining nonunion fracture healing, but that 42% also used weight-bearing and 37% also used pain on palpation of the fracture site. A combination of radiographic evidence and clinical evidence has been proposed as the best means of judging healing.(12) However, only nine of the 24 included studies combined radiographic evidence with clinical evidence to define nonunion fracture healing. Comparability of outcomes across studies examining the same intervention will be discussed below under each intervention.

### **Findings of Included Studies**

#### Studies using ultrasound

Three separate studies with a total of 1446 patients reported data concerning ultrasound treatment of nonunions. Specific information on each study is presented in Table D-2. All studies were case series using the Exogen system and examined the responses of multiple bone types. The Exogen system has been approved by the FDA for the treatment of nonunion fractures (see Table B-1).

Nolte et al.(9) examined 29 patients and included both radiographic evidence and clinical assessment in determining healing. Healing rates were compared using Fischer's exact test for patients grouped by types of fixation in place before and during ultrasound therapy. No differences in healing rates were found for the eight patients treated by casting, 12 patients treated by osteosynthesis, six with intramedullary rods, and three with external fixators. However, even if this analysis were adequately powered to detect a difference, it would not rule out a role for fixation and stabilization in the healing process, only that each method of fixation worked equally well with ultrasound. Not including the 12 patients excluded from their analysis, all 10 tibias healed and four out of five of the femurs, radii, and scaphoids healed. Response to treatment was monitored with clinical and radiographic examinations at 6- to 8-week intervals, and treatment was continued until the treating surgeon declared the nonunion healed. This study was considered fair rather than good quality because it did not mask patient assessment.(9)

Results for 12 patients enrolled but excluded from the analysis are also presented in the article. These patients were excluded for the following reasons: one for lack of compliance, three for early withdrawal, and eight who had undergone surgery within 90 days of receiving ultrasound (an exclusion criteria). Some of the patients who had undergone surgery within the 90-day period prior to use of ultrasound were still considered to be ultrasound "successes." This could inflate the effect of ultrasound if the prior treatment effect was still ongoing. The healing rate as reported in the study was 86% (25 of 29 nonunions) healed excluding the 12 patients described above. However, if only the eight cases that did not meet the authors' inclusion criteria are excluded, the analysis yields a 76% rate of healing (25 of 33). The article is not clear about whether the stratified analyses presented were planned before the study began or were *post hoc* analyses. Among the patients that completed the study, 18 had no treatment other than the initial procedures used to treat the fracture. Fourteen of these patients (78%) healed during the study. All 11 of the patients who received a secondary procedure prior to ultrasound therapy healed.(9)

Mayr et al. examined data on 1317 patients from a registry maintained by the manufacturer of the ultrasound device.(10) Patients were described as having “delayed union” (951 cases) if a fracture remained unhealed for 3 to 9 months following fracture, and “nonunion” (366 cases) if the time since initial fracture was greater than 9 months. Percentage of patients healed and time to healing for delayed union and nonunion in this prescription-based registry were compared to results obtained for 42 patients in the authors’ clinic, but no other validation of the registry is mentioned in the article. The authors found very similar rates of healing and time to healing in their clinic population as in the registry population, based on lack of a statistically significant difference.(10) However, one cannot conclude that two groups are the same based on non-significant results.

Among the nonunions in this study, 314 of 366 (86%) fractures healed, including 105 of 120 (88%) tibias and 57 of 66 (86%) femurs. Among the 951 “delayed unions,” 862 (91%) healed, including 350 of 380 (92%) tibias and 85 of 98 (87%) femurs.(10) Given the requirement that nonunions be diagnosed at 9 or more months following injury (mean 24.9 months), these results suggest that the ultrasound therapy contributed to healing. Of note, the mean time to healing in the nonunion patients was 152 (S.E.: 5.3) days versus 129 (S.E.: 2.7) days in the delayed union group.(10)

The size of the registry population does improve the generalizability of the results; however, retrospective data collection and post-hoc analyses of registry data generally raise concern about potential for bias in patient selection and analysis. Outcome assessments in the Mayr et al. study were not blinded and may not have been consistently applied across all patients. Compliance was not reported, and clinical examination (pain and weight-bearing) was not used as part of the assessment of healing. The study was therefore considered to have low internal validity. The study also failed to consider the effect of concurrent immobilization or other treatments in the assessment of healing rates. While the study provides an interesting overview of healing in a large number of bone types, detailed data (mean ages, numbers of patients in each age, and co-morbidity group, etc.) are not reported.

A translation of Mayr's other study, published in German after the report on the registry data, was provided to us by one of the reviewers of the draft report.(8) This publication describes 100 patients treated by Mayr with ultrasound.(1) Healing rates were 55 of 64 (86%) for delayed unions, which healed in an average of 142 days, and 31 of 36 (86%) for nonunions, which healed in an average of 171 days. Inclusion of the 21 patients who discontinued treatment reduces the overall healing rate to 86 of 121 (71%). The internal validity of the study was considered low because the outcome assessment was not blinded, pain and weight-bearing outcomes were not reported, and statistical analysis was not reported.

Although the size of the patient populations and the methods of data collection and analysis were very different, Nolte et al.(9) and Mayr et al.(10) reported 86% healing in nonunions of all bone types at an average of 152 days and Mayr et al.(1) reported 86% healing of nonunions in 171 days. Nolte et al.(9) reported that all six patients 65 or older had healed nonunions after treatment, but Mayr et al.(10) analyzed the registry data for an effect of age and reported that the healing rate for nonunions consistently declined from 97% at 20 years to 71% at 70 years.

Pre-1990 studies of ultrasound:

We identified no pre-1990 clinical studies published in English that describe the use of ultrasound to treat nonunions.

Conclusions for ultrasound:

Three case series published since 1990 (two prospective and one retrospective) using the Exogen system to treat nonunion in 1446 patients are in general agreement with each other that a high percentage of nonunions healed during ultrasound therapy.(10) While the results of these studies suggest that ultrasound promotes the healing of nonunion fractures, they do not rule out a role for other concurrent treatment procedures—such as stabilization of the nonunion—contributing to the observed effects. The two studies reporting data for patients over 65 are not in agreement as to the effect of age on response to ultrasound treatment.



## Studies using PEMF

Seven studies published since 1990 with a total of 403 patients reported data concerning PEMF treatment of nonunions. Two of the studies were double-blind RCTs examining only tibial nonunions. They evaluated the use of PEMF for treatment of tibial nonunion in two distinct clinical situations: after extensive surgical intervention in one study(11) and prior to any surgical intervention in the other.(12) One retrospective study with a concurrent comparison group included patients with fractures at multiple sites. One of the case series examined only tibial nonunions, one examined only scaphoid nonunions, and the remaining two examined multiple bone types. Specific information on each study is presented in Table D-3. No device names were reported in these studies. However, personal communications from the manufacturers of PEMF devices have revealed that Sharrard(12) used the EBI Bone Healing System and that Garland et al.(27) used the Orthofix Physio-Stim Bone Growth Stimulator. The FDA has approved these devices and several other PEMF devices for the treatment of nonunion fractures.

Simonis et al.(11) treated 34 patients with established nonunions (>1 year from the initial fracture) and an average of four surgical procedures prior to entering their study. Patients were treated with fibular osteotomy followed by unilateral external fixation and either an active PEMF device or a dummy device for 6 months. Compliance was measured with a hidden timer. Radiological assessment of bone bridging was blinded, but no clinical assessment for pain and function was reported. Simonis et al. reported that 16 of 18 (89%) healed in the active group compared to 8 of 16 (50%) healed in the dummy device group after an average of 15 weeks (unadjusted odds ratio 8.0, 95% CI of 1.5-41,  $p = 0.02$ , Fisher's exact test). However, the lower healing effect seen in the control group may have been due to the larger proportion of smokers randomized to that group (13 of 16) compared to the number in the active group (8 of 18). When the overall results were adjusted for smoking, the association was less strong and not statistically significant (odds ratio 5.4, 95% CI of 0.85 to 34,  $p = 0.07$ ).(11) Therefore, this study does not provide unequivocal evidence that PEMF promoted nonunion healing above that provided by the surgical intervention.

Sharrard(12) used a full-leg plaster cast on 45 patients with delayed unions. He treated only patients with fractures unhealed after 16 to 32 weeks of treatment with a long-leg plaster cast and no prior surgical interventions other than those required for management of the initial wound and open reduction of the fracture, if necessary. Patients were excluded if they had undergone internal or external fixation, with the exception of two patients with stabilizing pins incorporated into their casts. Patients were also excluded if the fracture gap was >0.5 cm, if the bone was severely atrophic, and if the fracture site showed significant hypertrophy.(12) He randomized patients to active and dummy devices and treated them for 3 months. Clinical assessment as well as blinded radiographic evidence of progression toward union, probable union or full union was reported. Radiographic assessments were made independently by Dr. Sharrard (an orthopedist) and a radiologist. "Progress toward healing" was defined by the radiologist as "a definite change from the earlier films, either with new subperiosteal bone, fuzziness across the fracture site or new bone peripherally across the fracture site." "Probable union" was defined as "a marked change with thicker denser bone across at least two cortices and fuzziness across the fracture site." "Full union" was diagnosed when the radiographs showed "dense and extensive new bone formation" across the "fracture site and at least three of the four cortices visible on the two films."(12) Dr. Sharrard, on the other hand, stated that "I, as an orthopaedic surgeon considered union to be sufficient to cease treatment when continuity was present over at least half the width of the bone, a category regarded by [the radiologist] as "progress to union."(13) When clinical assessment suggested healing (as judged by absence of motion at the fracture site) but radiographic assessment did not, the radiographic assessment was considered the more reliable indicator. In all cases in which radiographic union was present, movement was absent on clinical exam. Three of 20 in the active group showed full union, two probable union, five progression toward union, and 10 showed no change using the radiographic criteria described above. In contrast, none of the 25 in the dummy device group showed full union, one showed probable union, one showed progression toward union, and 23 showed no change. Clinical assessment indicated that more than half of both groups had no movement of the nonunion fracture and both groups reported reduced pain. There were statistically

significant differences in union or progress toward union in favor of the active group as judged by the radiologist ( $p = 0.002$ ) and by the orthopedist, Dr. Sharrard ( $p = 0.02$ ).<sup>(12)</sup> In view of the time to full healing reported in the majority of studies, the 3-month observation period in this study may not be adequate for concluding that PEMF promoted healing beyond that provided by the concurrent surgical intervention. However, Dr. Sharrard did follow these patients for an average of 2 years and his unpublished findings have been provided for inclusion in this report.<sup>(13)</sup>

Dr. Sharrard regarded the 3-month findings as intermediate outcomes indicating progression towards healing and defined the final positive outcome as healing with no further surgery.<sup>(13)</sup> During the follow-up period, 17 of 20 (85%) of the original active group healed without surgery, indicating that a number of patients who had not shown progression toward healing in the initial 12-week period went on to heal after the study (and presumably, the treatment) ended. Of the 25 patients who originally received dummy devices, three were lost to followup after the 12-week study and 8 of the remaining 22 patients (36%) healed during the long-term follow-up period without surgery or other intervention, again suggesting that longer periods of observation are necessary for assessing full healing of nonunion. Another 8 patients in the original dummy device group, all of whom were assessed as showing no improvement by 12 weeks, requested an active unit at the end of the 12-week study; 6 of the 8 went on to heal without surgical intervention.<sup>(13)</sup>

Based on the 12-week data and categorical modeling, Sharrard<sup>(12)</sup> concluded that patient age was not a factor in treatment outcome. However, this conclusion is based on intermediate outcomes and not on the follow-up data. A similar analysis of age was not reported in Dr. Sharrard's followup.<sup>(13)</sup> Dr. Bruce Simon, Director of Research at EBI, the manufacturer of the PEMF device used by Dr. Sharrard, has indicated in a personal communication that their categorical analysis, included in a PMA application to the U.S. Food and Drug Administration, also showed no effect of age, consistent with Sharrard's findings.<sup>(6)</sup> EBI did not report a  $p$  value but indicated that their findings were in agreement with the  $p$  value of 0.23 reported by Sharrard in his published study. These studies may have insufficient sample sizes to find a statistically significant

relationship. Sharrard(12) originally planned to recruit 100 patients but had only 45 and EBI did not report their sample size. P values  $<0.05$  are typically accepted as sufficient for *rejecting* the null hypothesis (i.e., that age has no effect on healing rate), but a p value  $>0.05$  does not *prove* the null hypothesis. Insufficient evidence to reject the null hypothesis does not imply sufficient evidence to accept it. Therefore, no conclusions as to the effect of age on PEMF treatment of nonunions can be based on these data at this time.

Traina et al.(14) treated 41 patients with PEMF and compared the results to patients treated simultaneously by other means. The average number of prior surgeries was 1.6 per patient in the treated group and 1.4 in the control group, and the average nonunion duration was 1.8 years in the treated group and 2.2 in the control group. The control group (average age of 46) was older than the treated group (average age of 38). Overall, 36 of 41 (88%) in the PEMF group healed as did 18 of 26 (69%) in the control group. However, greater differences in healing rate were seen in the presence of infected nonunions. Non-infected nonunions showed equal healing rates: 20 of 23 (87%) in the treated group and 14 of 16 (87%) in the control group. Infected nonunions healed better in the treated group: 16 of 18 (88%) in the treated group and four of 10 (40%) in the control group ( $p <0.05$ ). The authors report that the effects of stimulation were apparent within the first 3 months, and they recommend a change in therapy if progression is not observed within that time frame.(14) This study suggests that PEMF may benefit the healing of infected nonunions. However, the groups may not be directly comparable because of differences in age, the types of bone treated in each group, and differences in other patient characteristics. This study was rated low on the internal validity scale for these reasons, as well as for the retrospective data collection and absence of blinded assessment.

Garland et al. 1991(27) reported on a prospective case series that used blinded assessment and therefore had fair internal validity. Internal validity was not considered “good” because of a high dropout rate. One hundred eighty-one patients with various types of nonunions were treated, but only 139 completed the treatments (28% dropout rate). Patients had established nonunions of more than 9 months duration (average of

2.6 years) and averaged two previous surgeries including 131 internal fixations and bone grafting. Immobilization, bracing, and weight-bearing decisions were left to the judgment of the treating physician. Thirty-seven of 50 (74%) tibias, 13 of 15 (87%) femurs, and 10 of 13 (77%) scaphoids healed, but the authors did not report an average time to healing. Other bone types were treated in 10 or fewer patients. The overall reported healing rate was 80% (108 healed out of 135 fractures in the 126 patients with more than 3 hours of PEMF treatment per day). Only 126 patients were included in the healing rate analysis after excluding 42 patients who dropped out before completing the study, and 13 patients who averaged less than 3 hours per day of treatment. With all patients accounted for, the overall healing rate was 57% (108 of 190). When results were stratified by duration of nonunion prior to PEMF treatment (9 – 12 months in 78 nonunions vs. >12 months in 115 nonunions), the authors report that there was no statistically significant difference in healing rates, but data are not provided. In contrast, Brighton's study,(16) discussed in the next section of this report, describes a predictive model for nonunion healing that indicates a decline in healing rate with increasing duration of nonunion.

In a subgroup analysis of 97 patients at 4 years, 89 (92%) had healed. This study still suggests that PEMF may promote fracture healing in established nonunions given the long duration of the nonunions in the population prior to PEMF therapy. Brighton's study,(16) discussed in the next section of this report, describes a predictive model for nonunion healing that indicates a decline in healing rate with increasing duration of nonunion.

The remaining three studies of PEMF were case series with various deficiencies in design that resulted in low internal validity. None of these studies reported a statistical analysis that would indicate if their reported rates of healing were statistically significant. Ito and Shirai 2001(116) treated 30 tibial nonunions immobilized in plaster casts. Patients had established nonunions and averaged 1.8 previous surgeries and 1.5 years nonunion duration before PEMF treatment. Twenty-five of 30 cases (83%) achieved bony union in an average of 8.6 months. Adams et al. 1992(126) treated 54 scaphoid nonunions immobilized in a cast. All patients had at least one previous surgery and the

average nonunion duration was 2.9 years. Thirty-seven of the 54 (69%) cases healed in an average of 4 months. Since these two studies examined one bone type and used similar treatments for all patients, these studies provide some limited evidence that the treatment, PEMF therapy and cast immobilization, enhances the healing of established nonunion fractures. Meskens et al. 1990(117) treated 34 patients with various types of nonunions but all were immobilized in plaster casts. Patients averaged three prior surgeries and a nonunion duration of just over 3 years. Eleven of 15 (73%) tibias healed in this study, but the average time to healing for this bone type was not reported. Other bone types were treated in 10 or fewer patients. This study provides some limited evidence that PEMF plus cast immobilization may enhance healing in established nonunion fractures of the tibia.

Two of the PEMF studies provided data on older individuals. Garland et al.(27) reported that 18 of 28 (64%) patients over 60 years had healed nonunions compared to 90 of 107 (84%) patients younger than 60 years. Average time to healing for these age groups was not reported. Ito and Shirai(116) reported nonunion healing in two of three patients 65 and over.

Pre-1990 studies of PEMF:

While we chose to limit included studies to those published since 1990, several reviewers of our report noted that several studies of PEMF had been published prior to that date, and asked that we provide some additional information on those studies.(5-7,130) A technology assessment of electrical bone growth stimulation written by ECRI in 1993 (literature search up to 1992) reported an 80% healing rate for long bone nonunions treated by PEMF, including the tibia.(131) We identified 11 clinical studies published between 1975 and 1989 of PEMF treatment of nonunion fractures that evaluated 20 or more patients (see Table 5). All were uncontrolled studies and report healing rates of between 60% and 90%. Orthofix has provided patient registry data collected between March 1986 and December 1989 describing the treatment of nonunions with the Physio-Stim Bone Growth Stimulator (see Appendix E).(132) The data covered 729 patients and 859 fractures. A healing rate of 85% was reported based

on radiographic assessment. The registry includes data on 128 patients over the age of 60, but Orthofix was unable to supply us with the healing rates in this subgroup in time for inclusion in this report.(133)

#### Conclusions for PEMF:

Seven studies published since 1990 with a total of 403 patients reported data concerning PEMF treatment of nonunions. Two of the included studies were double-blind RCTs using dummy devices and blinded assessment. One RCT examined longstanding tibial nonunions, comparing PEMF with fibular osteotomy and unilateral external fixation to a dummy device, fibular osteotomy, and external fixation. The healing rate was higher in the group receiving PEMF in addition to the other treatment, but was not statistically significantly different after adjustment for confounding by the greater proportion of smokers in the control group.(11) The second RCT compared PEMF and full-leg plaster cast immobilization vs. a dummy device and cast immobilization in patients with “delayed tibial union” (failure to heal within 16 – 32 weeks of initial injury while treated with cast immobilization).(12) While radiographic assessments demonstrated significantly greater progression toward healing in the active device group at the end of the 12-week study, longer follow-up prior to further intervention may have altered the difference between the groups. Nonetheless, 17 of 20 patients treated with the active device from the beginning of the study had healed at long-term followup.(13) One nonrandomized study with a concurrent control group demonstrated higher rates of healing in the PEMF group with infected nonunions, but no adjustments were made for differences in patient and fracture characteristics in the two groups.(14) One prospective case series which included patients with nonunions of long duration also reported healing in 57%. The remaining case series showed healing when PEMF therapy was combined with cast immobilization. Studies conducted prior to 1990 were consistent with the more recent studies in terms of healing rates. Overall, these results consistently indicate that nonunions heal in patients treated with PEMF, but the effect of PEMF cannot be separated from the effect of concomitant fracture site stabilization.

**Table 5. Pre-1990 Studies of PEMF Treatment of Nonunion Fractures**

Reference	N	Bones Treated	Percentage Healed	Average Time to Healing
Krempen et al. 1981(134)	20 fractures	Multiple bone types, 17 (85%) tibia	90%	7 months
Heckman et al. 1981(135)	149 patients with 153 fractures	Multiple bone types, 94 (63%) tibias	64.4%	11.1 months
Bassett et al. 1982(136)	1007 fractures in a multi-center study	Multiple bone types, 658 (65%) tibia	77% overall, 82% for tibia	Nonunions healed within 6 to 8 months
Sharrard et al. 1982(137)	52 patients with 53 fractures	Multiple bone types, 30 (57%) tibia	72% overall, 87% for tibia	6 months median
Marcer et al. 1984(138)	147 patients	Multiple bone types, 102 (69%) tibia	73% overall, 75% for tibia	Not reported
Dunn and Rush 1984(139)	37 nonunions	Multiple bone types, 20 (54%) tibia	81% overall, 80% for tibia	Not reported
Cheng et al. 1985(140)	50 nonunions	Multiple bone types, 28 (56%) tibia	62% overall, 78% for tibia	7 months
Hinsenkamp et al. 1985(141)	235 nonunions	Multiple bone types, 148 (63%) tibia	73% overall, 79% for tibia	Not reported
Frykman et al. 1986(142)	44 patients	Scaphoid nonunions	80%	4.3 months
Colson et al. 1988(143)	32 patients with 33 fractures	Multiple bone types, 22 (67%) tibia	19 fractures treated with PEMF and surgery healed (100%) and 12 of 14 treated with PEMF alone (86%). Healing in tibia not reported	6 months for both

Studies using direct current or capacitive coupling

Three separate case studies and a single RCT with a total of 353 patients reported data concerning direct current or capacitive coupling treatment of nonunions. Specific information on each study is presented in Table D-4. One retrospective study examined tibial nonunions in separate groups of patients treated with direct current, capacitive coupling, and bone graft. The remaining two case series and the RCT examined



multiple bone types. The FDA has approved direct current and capacitive coupling devices for the treatment of nonunion fractures.

The RCT by Scott and King(15) examined only 21 patients with established nonunions treated with an active Orthopak bone-growth stimulator capacitive coupling device (n = 10) or an inactive device (n = 11). In the treated group, 6 of 10 healed in an average of 21 weeks. None of the control group healed after 26 weeks. There were five tibial nonunions of 10 total nonunions in the active treatment group, vs. 10 tibial nonunions out of 11 total nonunions in the control group, which may have negatively affected the healing rates in the control group.

The retrospective comparative study by Brighton et al. 1995(16) used logistic regression analysis to compare tibia healing rates among 167 patients treated with direct current, 56 patients treated with capacitive coupling, and 48 patients treated with bone grafts. The patients treated with electrical stimulation were all placed in casts while the bone graft patients had internal fixation, external fixation, or internal fixation plus cast. The actual healing rates and time to healing were not reported. The different methods of fixation used in the three treatment groups complicates any comparison of results for these three forms of treatment. The logistic regression analysis was described in detail and seems to have been properly constructed using logarithmic transformation of the data. The analysis calculated better than 95% healing with all three treatments when the nonunions were of 10-month duration prior to treatment and no other risk factors for failure to respond to the treatments were present. The risk factors associated with a decline in healing rates included longer duration of nonunion prior to treatment, open fracture, comminuted fracture, prior failed bone graft or prior failed electrical therapy. Patient age was used as a continuous variable in the logistic regression analysis, but any influence age may or may not have on healing was not reported by the authors. Actual healing rates and time to healing that would be useful in comparison with other studies were not reported, except for the patients treated with bone graft. Twenty-eight of 48 (58%) tibial nonunions treated with bone graft healed, but no time to healing was reported.

The remaining two studies, Zamora-Navas et al. 1995(17) and Cundy and Paterson 1990,(18) are also retrospective case series with low internal validity. Zamora-Navas et al. reported that their patients were immobilized with either plaster cast, external fixation, or other procedures, which limits our ability to distinguish the effect of electrical stimulation from these other therapies. This study specifically examined patients with large nonunion gaps (>1 cm, which is wider than is typical for nonunions treated with electrical stimulation). The study did report that 8 of 10 (80%) tibias and 4 of 6 (67%) humeri healed in a average of 26 weeks. Zamora-Navas et al. reported that one 65 year-old patient healed after 42 weeks of treatment and that one 70 year-old patient did not heal after 24 weeks of treatment.(17)

Cundy and Paterson report on their 10-year followup of patients treated with an implanted bone growth stimulator. Forty-four percent of the original patients could not be located, which reduces the validity of the study. All of the 37 contacted patients reported that their nonunions were healed, but six of these patients healed following bone grafting and internal fixation.(18)

In our search of recent meeting abstracts, we identified a single study of at least 20 patients that examined direct current stimulation. This meeting abstract, which was presented at the 2003 OTA meeting, reported that direct current stimulation can be combined with morselized allograft, demineralized bone matrix, and platelet-derived growth factors to treat nonunion fractures.(144) Multiple bone types were treated. Overall, 105 of 109 (96%) nonunions healed.

Pre-1990 studies of direct current or capacitive coupling:

As with PEMF studies, we were asked by reviewers of our report to provide some additional information on earlier studies of direct current treatment.(5-7,130) A technology assessment of electrical bone growth stimulation written by ECRI in 1993 (literature search up to 1992) reported an 80% to 90% healing rate for tibial nonunions treated by direct stimulation.(131) We identified six clinical studies published between 1975 and 1989 of direct electrical stimulation treatment of nonunion fractures that evaluated 20 or more patients (see Table 6). All were uncontrolled studies and report

healing rates of between 40% and 90%. We identified no additional studies of capacitive coupling.

#### Conclusions for Direct and Capacitive Coupling Treatment:

We identified four studies published since 1990 with a total of 351 patients treated with direct current or capacitive coupling treatment of nonunions. An RCT examined patients with established nonunions treated with an active capacitive coupling device (n = 10) or an inactive device (n = 11).(15) While 6 of 10 in the active treatment group healed in an average of 21 weeks compared to none of the control group, the inclusion of twice as many tibial nonunions in the latter group may have negatively affected the healing rates. One retrospective comparative study examined tibial nonunions in separate groups of patients treated with direct current, capacitive coupling, and bone graft.(16) This study used logistic regression analysis to estimate better than 95% healing with all three treatments when the nonunions were of 10-month duration prior to treatment and no other risk factors for failure to respond to the treatments were present. Risk factors predicting slower healing rates included longer duration of nonunion prior to treatment, open fracture, comminuted fracture, prior failed bone graft or prior failed electrical therapy. Patient age was used as a continuous variable in the logistic regression analysis, but any influence of age on healing was not reported in the study. In the remaining two studies, one specifically examined patients with large nonunion gaps (>1 cm), which is thought to be a contraindication for electrical stimulation.(17) Therefore, the results of this study are not generalizable to other types of nonunions. The other study reported on the 10-year followup of patients treated with an implanted bone growth stimulator, but 44% of the original patients were not located, reducing the validity of the reported results.(18) An additional six case series published between 1975 and 1989 had reported healing rates between 40% and 90%. Overall, these studies consistently demonstrate healing during treatment with direct current and capacitive coupling, but the effect of these therapies cannot be separated from the effect of concomitant immobilization of the fracture site.

**Table 6. Pre-1990 Studies of Direct and Capacitive Treatment of Nonunion Fractures**

Reference	Device	N	Bones Treated	Percentage Healed	Average Time to Healing
Forsted et al. 1978(145)	Direct	20 fractures	Multiple bone types, 17 (85%) tibia	90%	7 months
Paterson et al. 1980(146)	Direct	84 patients	Multiple bone types, 72 (86%) tibia	86% overall, 88% for tibia	4 months
Zichner 1981(147)	Direct	57 fractures	Multiple bone types, 16 (28%) tibia	93% overall, 100% for tibia	5.3 months
Connolly 1981(148)	Direct	49 fractures	Multiple bone types, 34 (69%) tibia	69% overall, 76% for tibia	Not reported
Ahl et al. 1984(149)	Direct	23 fractures	Multiple bone types, 14 (61%) tibia	43% overall, 50% for tibia	6.4 months
Zhong-xing et al. 1986(150)	Direct	42 nonunions	Multiple bone types, 20 (48%) tibia	88% overall, 85% for tibia	Not reported

### Studies using shock waves

Six separate studies with a total of 430 patients reported data concerning shock wave treatment of nonunions. All were case series and examined multiple bone types. The Osteostar (Siemens, Germany) was used in two studies, the MFL 5000 Lithotripter (Dornier Medizintechnik GmbH, Germany) in one study, the OssaTron (High Medical Technology, Switzerland) in one study, and the remaining two studies did not report a device name. Five of the studies were conducted in Europe and one was conducted in Taiwan. Specific information on each study is presented in Table D-5. Shock wave devices have not been approved by the FDA for use in treating nonunion fractures. Unlike the continuous or intermittent pattern of biophysical stimulation used in electrical stimulation, PEMF therapy, and ultrasound therapy, shock wave therapy only requires one or two short treatments.

Biedermann et al. 2003(19) in a prospective case series classified nonunions as long bone or other, hypertrophic or atrophic, and delayed union or nonunion. Results were reported according to these categories, limiting comparison to other studies. All patients were immobilized with cast or brace. The authors reported that hypertrophic nonunion healed better than atrophic nonunions—21 of 34 (62%)—hypertrophic nonunions and 11 of 22 (50%) atrophic nonunions) but did not report whether this was a statistically

significant difference. Rompe et al.(20) prospectively examined tibial and femoral nonunions. Treatment with casting and limited weight-bearing was continued following shock wave therapy. Unlike most case series, this study used blinded assessment of radiographic evidence and clinical examination. The study reported 31 of 43 (72%) patients with bony bridging and full weight-bearing by an average of 4 months: 13 of 19 (68%) of tibias healed; 18 of 24 (75%) femurs healed; 19 of 24 (79%) nonsmokers healed; and 12 of 19 (63%) smokers healed, but the authors did not report any statistical analysis of these results. Schaden et al. 2001(21) reported a retrospective case series in which the nonunion sites were immobilized in casts or splints if implanted devices showed signs of loosening. The study reported that 26 of 34 (76%) tibias, 14 of 21 (67%) scaphoids, and 11 of 12 (92%) femurs healed during the study period but does not report the time to healing. The follow-up period lasted from 3 months to 4 years (average of 18 months), which does not allow for an accurate accounting of the time needed to judge whether the shock wave therapy was successful or not. Schaden has updated his findings in an abstract presented at the February 2005 annual meeting of the AAOS. After a maximum followup of 5 years, 175 of 204 patients (86%) achieved bony union.(151) Wang et al. 2001(119) prospectively examined patients treated with shock wave therapy who were treated with crutches and partial weight-bearing for lower extremities and slings for upper extremities. The study reported results separately for 3, 6, and 12 months but not on an intent-to-treat basis. Within the groups of patients remaining in the study at each time period, the rates of healing for both hypertrophic and atrophic nonunions increased with each follow-up period. This could be an actual effect of treatment or it may indicate that the dropouts were unhealed patients. The authors do not provide an explanation. The study does indicate that atrophic nonunions may have a diminished response to shock wave therapy compared to hypertrophic nonunions, but no statistical analysis was performed to test this association. Vogel et al. 1997(120) prospectively examined patients treated with shock wave therapy followed predominantly by immobilization in a cast. Healing rates for individual bone types were not reported, which prevents comparison with other studies or determining if one bone type healed better than another. At a mean of 3.4 months (range of 2 to 9 months), 29 of 48 (60%) patients showed complete healing. Valchanou and Michailov 1991(22)

retrospectively examined patients treated by shock wave followed mostly by cast immobilization. The study did not report if consecutively treated patients were included, which leaves open the possibility that patients were selectively chosen for this study or that dropouts were not reported. Seventy of 79 (85%) patients showed radiographic evidence of bone bridging, but the average time until healed was not reported. The value of this study is diminished by the lack of reporting, specifically whether the patients were consecutive and the time needed to heal.

One of the studies provided data on older individuals. Rompe et al.(20) reported that three of four patients older than 65 years showed healing in an average of 4 months. One patient of 73 years did not heal.

Pre-1990 studies of shock wave:

We identified no pre-1990 clinical studies that describe the use of shock wave to treat nonunions.

Conclusions for shock wave:

Six separate case series published since 1990 with a total of 430 patients reported data concerning shock wave treatment of nonunions of multiple bone types.(19-22) Five of the studies were conducted in Europe and one was conducted in Taiwan; shock wave devices have not been approved by the FDA for use in treating nonunion fractures. These case series reported healing rates between 50% and 80%, but the effect of shock wave therapy cannot be separated from the effect of immobilization in these uncontrolled studies.

#### Studies using orthobiologics

Four separate studies, all published since 1990, with a total of 214 patients reported data concerning the use of orthobiologics to treat nonunions. One study was an RCT comparing OP-1 Implant (Stryker Biotech) to fresh bone autograft in the treatment of tibial nonunions.(23) Stryker Biotech was granted a humanitarian device exemption (HDE) by the FDA for the use of OP-1 Implant as an alternative to autograft in

recalcitrant long bone nonunions in situations where the use of autograft is not feasible and alternative treatments have failed (see Table B-1). The other three studies were case series. One examined the use of AlloMatrix Injectable Putty (Wright Medical Technology) in nonunions in multiple bone types.(24) AlloMatrix Putty contains demineralized bone matrix (Allogro from AlloSource), carboxymethylcellulose, and OsteoSet, which is calcium sulfate. AlloMatrix Putty is cleared by the FDA only for “bony voids or gaps that are not intrinsic to the stability of bony structure” (see Table B-1) and is therefore not directly cleared for use in nonunion fractures. Its use in treating nonunion fractures could therefore be considered “off label.” The remaining two studies involve the use of composite allograft material prepared by the study authors. Specific information on each study is presented in Table D-6.

Friedlaender et al. 2001(23) presented their findings from a randomized controlled trial comparing a bone graft substitute, OP-1 Implant, with standard bone grafting in the treatment of tibial nonunions. Bone autografting is the standard of care for treating tibial nonunion fractures. This procedure requires bone to be harvested from the iliac crest (hip), and morbidity at the harvest site is common. Implantation of OP-1, which contains recombinant human OP-1 (rhOP-1), is an alternative to bone autografting that eliminates the need for harvesting bone. Recombinant human OP-1 is a bone morphogenetic protein (BMP-7) embedded in a collagen matrix. It is surgically implanted at the site of nonunion to encourage bone to form across the fracture site.

In this study, patients underwent intramedullary rod fixation in addition to the grafting procedure. The internal validity of this study was rated as “fair” only because the patient could not be blinded to treatment. Autogenous bone grafting requires removal of bone from the patient’s hip; therefore, this procedure cannot be blinded. However, radiographic assessment of bone bridging was blinded. Key outcomes reported in this study included the ability to bear weight on the treated leg, pain at the fracture site, radiographic evidence of healing, retreatment surgery, surgical complications, and treatment-site complications. In general, new technologies are accepted only if they are superior to the standard of care. However, when OP-1 Implant is used, morbidities that normally occur at the bone autograft harvest site are avoided. Therefore, to be clinically

superior to autografting, OP-1 Implant does not need to have superior healing ability; it only needs to have equivalent healing ability. A statistical comparison, commonly referred to as a test for “noninferiority,” can be performed to detect equivalence of two interventions. However, the authors of this report only performed the standard statistical testing to determine whether one treatment is superior to the other.

Friedlaender et al. reported that the healing rates after 9 months were 39 of 63 (62%) for OP-1 and 45 of 61 (74%) for bone graft based on three radiographic views.(23) This difference was not statistically significant. Combined clinical success, defined as full weight-bearing, less than severe pain at the fracture site on weight-bearing, and no retreatment, was 51 of 63 (81%) for OP-1 and 52 of 61 (85%) for bone graft; this difference was not statistically significant. The need for surgical retreatment was low in both groups, 3 of 60 (5%) for OP-1 and 6 of 61 (10%) for bone graft, again not a statistically significant difference. The bone graft group did have significantly more postoperative osteomyelitis ( $p = 0.002$ ), 2 of 60 (3%) for OP-1 and 13 of 61 (21%) for bone graft.(23) However, pin tract infection associated with the use of an external fixator prior to placing a reamed tibial nail (as was done in both groups) is a risk factor for subsequent infection. Without controlling for this possible confounder it is difficult to interpret the unusually high incidence of osteomyelitis in the autograft group.(152) Atrophic nonunions were significantly more prevalent in the OP-1 group (41% vs. 25%,  $p = 0.048$ ), and there was a greater proportion of smokers in the OP-1 group as well (74% in the OP-1 group vs. 57% in the autograft group,  $p = 0.06$ ).(23) These conditions would be expected to hinder the healing process and may have reduced the likelihood of success with the OP-1 Implant.

A meeting abstract provides additional information on OP-1 treatment of long bone nonunions.(153) Forty nonunions in patients with an average of three prior surgeries were treated. Thirty-one of the nonunions (78%) showed radiographic evidence of healing in a mean of 5.9 months of treatment. Further assessment of this study must await full publication.



Wilkins and Kelly(24) reported a retrospective case series of the use of AlloMatrix Injectable Putty in treating nonunions in multiple bone types. The nonunions were also treated using standard internal/external fixation techniques. The article does not report if patients are being treated for the first time or the duration of the nonunions prior to the AlloMatrix Putty treatment. Without this information, comparisons to other studies are difficult. The study also does not report whether all consecutively treated patients were included or if dropouts occurred during the treatment period. The reported healing rate was 30 of 35 (85%) in an average of 3.5 months, but healing rates per bone type were not reported. A meeting abstract reporting on the use of demineralized bone matrix (DBM) in treating nonunions found significant problems.(25) In this study of 41 nonunions, 54% healed but high rates of wound drainage and subsequent deep infection reduced the effectiveness of DBM in treating nonunions. A second meeting abstract reported on the use of a DBM and bone marrow aspirate composite graft to treat nonunions.(26) Fourteen nonunions were treated and radiographic union was achieved in 75% of patients in an average of 9.3 months.

The remaining two studies were retrospective case series from the same laboratory that examined the use of a composite allograft with partially purified human bone morphogenetic protein (hBMP) to treat nonunions of the femur in one study, Johnson and Urist 2000(127), and multiple bone types in the other, Johnson et al. 1992.(128) The earlier study was intended to show that the composite allograft with active human BMP could enhance healing in nonunion fractures that had failed to heal after other procedures such as electrical stimulation and surgical procedures. In addition to the allograft, 22 of 25 patients underwent internal fixation and 7 of 25 received adjunctive bone grafting. Twenty of 25 (80%) nonunions healed after the first implantation of the composite graft in an average of 6 months (range of 3 to 14 months). Four of the five failures healed after revision of the failed fixation, indicating that fixation may also have contributed to the observed healing effect of treatment.(128)

Johnson and Urist 2000(127) looked at healing in 30 femoral nonunions after treatment with the composite allograft and various other treatments. Thirteen patients received additional autogenic cancellous bone graft to the intercalary segmental defect.

Twenty-six patients were implanted with a fixed angle blade plate to stabilize and lengthen the femur. The remaining patients had intramedullary nails. As with the earlier study from this laboratory, the precise role of the allograft in the healing process cannot be distinguished from the other procedures. The study reported that 24 of 30 (80%) femoral nonunions healed with an average time of 6 months and a range of 3 to 9 months.

Only the two studies of composite allograft with hBMP reported data for individuals 65 and over. In the study examining only nonunion of the femur, seven of eight older patients healed within 4 to 6 months.(127) In the other study, all five patients over 65 (three tibias and two humeri) healed.(128)

Pre-1990 studies of orthobiologics:

We identified no clinical studies of orthobiologics for treatment of nonunion published prior to 1990.

Conclusions for orthobiologics:

Four separate studies published since 1990 with a total of 214 patients reported data concerning the use of orthobiologics to treat nonunions. One study was an RCT comparing BMP-7, OP-1 Implant (Stryker Biotech) to fresh bone autograft in the treatment of tibial nonunions. Stryker Biotech was granted a humanitarian device exemption (HDE) by the FDA for the use of OP-1 Implant as an alternative to autograft in recalcitrant long bone nonunions where use of autograft is not feasible and alternative treatments have failed. Patients in both groups underwent intramedullary rod fixation in addition to the autograft or OP-1 grafting procedure.(23) The internal validity of this study was rated as “fair” only because autogenous bone grafting requires removal of bone from the patient’s pelvis; consequently, patients could not be blinded to treatment. However, radiographic assessment of bone bridging was blinded. The study found similar healing rates in the two groups. A noninferiority statistical analysis should be performed to determine whether OP-1 Implant in conjunction with internal fixation was not inferior to autogenous bone graft in the treatment of tibial nonunions. Assuming the

analysis demonstrates noninferiority, this single study would need to be replicated by other investigators before OP-1 is considered an effective substitute for autogenous bone grafting. The absence of the morbidity associated with harvesting of autogenous bone for grafting is a distinct advantage; therefore, additional studies would only need to demonstrate noninferiority as well.

The other three studies of orthobiologics were retrospective case series. One examined the use of AlloMatrix Injectable Putty (Wright Medical Technology) in nonunions in multiple bone types.(24) AlloMatrix Putty, which contains demineralized bone matrix (Allogro from AlloSource), carboxymethylcellulose, and OsteoSet (calcium sulfate), is cleared by the FDA only for “bony voids or gaps that are not intrinsic to the stability of bony structure” and is therefore not directly cleared for use in nonunion fractures. The publication did not report prior treatment or the duration of the nonunions prior to the AlloMatrix Putty treatment. Without this information, interpretation of the results is difficult. The remaining two studies were retrospective case series from a single laboratory that examined the use of a composite allograft with partially purified human bone morphogenetic protein (hBMP) to treat nonunions of the femur in one study, and multiple bone types in the other. As with other case series, the precise role of the composite allograft in the healing process cannot be distinguished from the other procedures used to stabilize the limbs. Two recent meeting abstracts describing studies utilizing DBM indicated healing rates of 54% and 75% respectively, but one found high rates of wound drainage and subsequent deep infection.(25,26) Additional studies are needed to understand the role of DBM in treating nonunions at this time.

### **Concluding Remarks**

What is the evidence for benefits and harms of bone growth stimulating devices and orthobiologics for treatment of nonunion fractures?

After searching the literature published since 1990, retrieving references, and applying our inclusion/exclusion criteria, we identified 24 published studies of bone growth stimulators and orthobiologics. Four of the studies were RCTs, two were retrospective comparison studies, seven were prospective case series, and the remaining 11 were

retrospective case series. Thus, the overall quality of the evidence for each type of intervention is for the most part low, and few of the studies can actually be used to distinguish the effect of the device or orthobiologics agent from the additional treatments these patients received. While some view case series of patients treated for nonunion as “self-paired, patient controlled” studies, the occurrence of healing at late timepoints in some patients receiving other therapies (e.g., cast immobilization) made us hesitant to view the studies in this way. Two RCTs of PEMF therapy indicate that patients treated with PEMF had healing of nonunions, but the results from one study did not reach statistical significance after adjusting for confounding, and the other was only randomized for the initial 12 weeks of treatment and observation.(11,12) One prospective case series,(27) a retrospective series with a comparison group,(14) and three retrospective case series also demonstrated healing with PEMF treatment, but the effect of PEMF could not be separated from the contribution of the immobilization procedures or casting.(11) The RCT of treatment with a capacitative coupling device demonstrated higher rate of healing in the active treatment group, although the number of tibial nonunions in the comparison group may have negatively affected the results in that group.(15) The remaining RCT, Friedlaender et al.,(23) indicates that OP-1 Implant may substitute for autogenous bone graft in the treatment of tibial nonunions in patients also being treated with reamed intramedullary nail fixation, but a noninferiority statistical analysis is needed to show that OP-1 (along with internal fixation) is not inferior to autogenous bone graft, and additional studies are needed to replicate the results. Case series studies of ultrasound and shock wave therapy report healing of nonunions with these therapies, but individual study quality limits the strength of the evidence and the effects cannot be separated from those of concomitant treatments. There is some indication from case series that DBM preparations are also useful, but additional studies are needed to understand the role of DBM in treating nonunion.

The studies’ generalizability to the Medicare population was poor with few studies either reporting results separately for individuals 65 years of age or older or analyzing results by age groups. It is commonly argued that there is no change in healing response with increasing age,(5-7) but whether this holds true across the lifespan (even in the absence of comorbid conditions that predispose to impaired healing) is not evident from

the literature we examined. The higher prevalence of osteoporosis in older adults complicates the management of nonunion by reducing the likelihood of successful stabilization with internal fixation.(28,29) Whether the results of treatments in younger adults can be generalized to persons of advanced age is not entirely clear, but reporting of outcomes separately for older patients in studies of nonunion treatments would provide useful information.

The authors gratefully acknowledge the guidance of our orthopedic consultant, Mitchel B. Harris, M.D., F.A.C.S. Dr. Harris is the Chief of the Orthopaedic Trauma Service at Brigham and Women's Hospital in Boston, Massachusetts.

## **BIBLIOGRAPHY**

1. Mayr E, Mockl C, Lenich A, Ecker M, Ruter A. [Is low intensity ultrasound effective in treatment of disorders of fracture healing?]. *Unfallchirurg* 2002 Feb;105(2):108-15.
2. Bhandari M, Guyatt GH, Swiontkowski MF, Tornetta P 3rd, Sprague S, Schemitsch EH. A lack of consensus in the assessment of fracture healing among orthopaedic surgeons. *J Orthop Trauma* 2002 Sep;16(8):562-6.
3. Court-Brown CM. Fractures of the tibia and fibula. In: Buchholz RW, Heckman JD, Rockwood CA, Green DP, editors. *Rockwood and Green's fractures in adults*. 5th ed. Vol. 1. Philadelphia (PA): Lippincott Williams & Wilkins; 2001. p. 1939-2000.
4. Chao EY, Inoue N. Biophysical stimulation of bone fracture repair, regeneration and remodelling. *Eur Cell Mater* 2003 Dec 31;6:72-84; discussion 84-5.
5. Henry DM. Personal communication. 2005 Aug 22. 33 p.
6. Simon B. (Director of Research, Orthopaedic Research Society). Personal communication. 2005 Aug 22. 17 p.
7. Galie E. (Director, Clinical Research, Orthofix, Inc.). Personal communication. 2005 Aug 22. 98 p.
8. Pounder N. (Senior Research Project Manager, Chartered Physicist, Member of the Institute of Physics, Smith & Nephew Orthopaedics. Memphis, TN). Personal communication. 2005 Aug 26. 11 p.
9. Nolte PA, van der Krans A, Patka P, Janssen IM, Ryaby JP, Albers GH. Low-intensity pulsed ultrasound in the treatment of nonunions. *J Trauma* 2001 Oct;51(4):693-702; discussion 702-3.
10. Mayr E, Frankel V, Ruter A. Ultrasound--an alternative healing method for nonunions. *Arch Orthop Trauma Surg* 2000;120(1-2):1-8.
11. Simonis RB, Parnell EJ, Ray PS, Peacock JL. Electrical treatment of tibial non-union: a prospective, randomised, double-blind trial. *Injury* 2003 May;34(5):357-62.
12. Sharrard WJ. A double-blind trial of pulsed electromagnetic fields for delayed union of tibial fractures. *J Bone Joint Surg Br* 1990 May;72(3):347-55.
13. Sharrard WJW. (Professor Associate of Orthopaedic Surgery, University of Sheffield and Emeritus Consultant Orthopaedic Surgeon). Personal communication. 1993 Jun 15. 9 p.
14. Traina GC, Fontanesi G, et al. Effect of electromagnetic stimulation on patients suffering from non-union. *J Bioelectr* 1991;10(1-2):101-17.
15. Scott G, King JB. A prospective, double-blind trial of electrical capacitive coupling in the treatment of non-union of long bones. *J Bone Joint Surg Am* 1994 Jun;76(6):820-6.
16. Brighton CT, Shaman P, Heppenstall RB, Esterhai JL Jr, Pollack SR, Friedenber ZB. Tibial nonunion treated with direct current, capacitive coupling, or bone graft. *Clin Orthop Relat Res* 1995 Dec;(321):223-34.
17. Zamora-Navas P, Borrás Verdura A, Antelo Lorenzo R, Saras Ayuso JR, Pena Reina MC. Electrical stimulation of bone nonunion with the presence of a gap. *Acta Orthop Belg* 1995;61(3):169-76.
18. Cundy PJ, Paterson DC. A ten-year review of treatment of delayed union and nonunion with an implanted bone growth stimulator. *Clin Orthop Relat Res* 1990 Oct;(259):216-22.
19. Biedermann R, Martin A, Handle G, Auckenthaler T, Bach C, Krismer M. Extracorporeal shock waves in the treatment of nonunions. *J Trauma* 2003 May;54(5):936-42.
20. Rompe JD, Rosendahl T, Schollner C, Theis C. High-energy extracorporeal shock wave treatment of nonunions. *Clin Orthop Relat Res* 2001 Jun;(387):102-11.

21. Schaden W, Fischer A, Sailler A. Extracorporeal shock wave therapy of nonunion or delayed osseous union. *Clin Orthop Relat Res* 2001 Jun;(387):90-4.
22. Valchanou VD, Michailov P. High energy shock waves in the treatment of delayed and nonunion of fractures. *Int Orthop* 1991;15(3):181-4.
23. Friedlaender GE, Perry CR, Cole JD, Cook SD, Cierny G, Muschler GF, Zych GA, Calhoun JH, LaForte AJ, Yin S. Osteogenic protein-1 (bone morphogenetic protein-7) in the treatment of tibial nonunions: a prospective, randomized clinical trial comparing rhOP-1 with fresh bone autograft. *J Bone Joint Surg Am* 2001;83(Suppl 1 Pt 2):S151-8.
24. Wilkins RM, Kelly CM. The effect of allomatrix injectable putty on the outcome of long bone applications. *Orthopedics* 2003 May;26(5 Suppl):s567-70.
25. Ziran BH, Smith WR, Lahti Z, Williams A. Use of calcium-based demineralized bone matrix (DBM) allograft product for nonunions and posttraumatic reconstruction of the appendicular skeleton: preliminary results and complications [paper No. 64]. Hippocrates Winslow & Babbage Foundation 2004 Annual Meeting. March 11, 2004; San Francisco (CA). 2004. Also available: <http://www.hwbf.org/ota/am/ota04/otapa/OTA041164.htm>.
26. Coupe KJ, Moore FN, Veurink R. The use of a demineralized bone matrix - bone marrow aspirate composite graft in the treatment of high energy fracture nonunions [poster no. 88]. Hippocrates Winslow & Babbage Foundation 2003 Annual Meeting. February 6, 2003; New Orleans (LA). 2003. Also available: <http://www.hwbf.org/ota/am/ota03/otapo/OTP03088.htm>.
27. Garland DE, Moses B, Salyer W. Long-term follow-up of fracture nonunions treated with PEMFs. *Contemp Orthop* 1991 Mar;22(3):295-302.
28. Harris MB. (Chief, Orthopaedic Trauma, Brigham and Women's Hospital, Boston MA). Personal communication. 2005 Aug 26. 1 p.
29. Chao EY, Inoue N, Koo TK, Kim YH. Biomechanical considerations of fracture treatment and bone quality maintenance in elderly patients and patients with osteoporosis. *Clin Orthop Relat Res* 2004 Aug;(425):12-25.
30. Wiss DA, Stetson WB. Tibial nonunion: treatment alternatives. *J Am Acad Orthop Surg* 1996 Oct;4(5):249-257.
31. Muschler GF. (Orthopaedic Surgery & Biomedical Engineering, The Cleveland Clinic Foundation, Cleveland, OH). Personal communication. 2005 Sep 2. 7 p.
32. Buckwalter JA, Einhorn TA, Marsh JL. Bone and joint healing. In: Bucholz RW, Heckman JD, Rockwood CA, Green DP, editors. *Rockwood and Green's fractures in adults*. 5th ed. Vol. 1. Philadelphia (PA): Lippincott Williams & Wilkins; 2001. p. 245-72.
33. Childs SG. Stimulators of bone healing. Biologic and biomechanical. *Orthop Nurs* 2003 Nov-Dec;22(6):421-8.
34. Einhorn TA. Enhancement of fracture healing. *Instr Course Lect* 1996;45:401-16.
35. Saleh KJ, Hak DJ. Socioeconomic burden of traumatic tibial fractures: nonunion or delayed union. In: Medscape [internet]. New York (NY): WebMD Corporation; 2001 Aug 28 [cited 2003 Mar 12]. [19 p]. Available: <http://www.medscape.com>.
36. Connolly JF. Tibial nonunion: diagnosis and treatment. Park Ridge (IL): American Academy of Orthopaedic Surgeons; 1991. 71 p.
37. Einhorn TA. The cell and molecular biology of fracture healing. *Clin Orthop Relat Res* 1998 Oct;(355 Suppl):S7-21.
38. Rodriguez-Merchan EC, Forriol F. Nonunion: general principles and experimental data. *Clin Orthop Relat Res* 2004 Feb;(419):4-12.
39. Reed AA, Joyner CJ, Brownlow HC, Simpson AH. Human atrophic fracture non-unions are not avascular. *J Orthop Res* 2002 May;20(3):593-9.
40. Barnes GL, Kostenuik PJ, Gerstenfeld LC, Einhorn TA. Growth factor regulation of fracture repair. *J Bone Miner Res* 1999 Nov;14(11):1805-15.
41. Hernigou P, Pognard A, Beaujean F, Rouard H. Percutaneous autologous bone-marrow grafting for nonunions: influence of the number and concentration of progenitor cells. *J Bone Joint Surg Am* 2005;87(7):1430-7.

42. Wu CC, Chen WJ. Treatment of femoral shaft aseptic nonunions: comparison between closed and open bone-grafting techniques. *J Trauma* 1997 Jul;43(1):112-6.
43. Wu CC, Shih CH, Chen WJ, Tai CL. Effect of reaming bone grafting on treating femoral shaft aseptic nonunion after plating. *Arch Orthop Trauma Surg* 1999;119(5-6):303-7.
44. Praemer A, Furner S, Rice DP. Musculoskeletal conditions in the United States. Rosemont (IL): American Academy of Orthopaedic Surgeons; 1999. Frequency of occurrence. p. 83-7.
45. 2002 National statistics: patient and hospital characteristics for ICD-9-CM all-listed diagnosis code 733.82 nonunion of fractures. [internet]. Rockville (MD): Agency for Healthcare Research and Quality; 2002 [cited 2005 Jun 21]. [1 p]. Available: <http://hcup.ahrq.gov/HcupNet.asp>.
46. Healthcare Cost & Utilization Project (HCUP). [Web site]. Rockville (MD): Agency for Healthcare Research and Quality; 2004 [updated 2005 Jun 17]; [cited 2004 Sep 30]. [various]. Available: <http://www.ahrq.gov/data/hcup/>.
47. Dieppe P, Tobias J. Bone and joint aging. In: Tallis R, Fillit H, Brocklehurst JC, editors. *Brocklehurst's textbook of geriatric medicine and gerontology*. 5th ed. London (UK): Churchill Livingstone; 1998. p. 1131-5.
48. Dempster DW. The pathophysiology of bone loss. *Clin Geriatr Med* 2003 May;19(2):259-70.
49. Kohrt WM. Aging and the osteogenic response to mechanical loading. *Int J Sport Nutr Exerc Metab* 2001 Dec;11 Suppl:S137-42.
50. Troen BR. Molecular mechanisms underlying osteoclast formation and activation. *Exp Gerontol* 2003 Jun;38(6):605-14.
51. Chan GK, Duque G. Age-related bone loss: old bone, new facts. *Gerontology* 2002 Mar-Apr;48(2):62-71.
52. Street JT, Wang JH, Wu QD, Wakai A, McGuinness A, Redmond HP. The angiogenic response to skeletal injury is preserved in the elderly. *J Orthop Res* 2001;19(6):1057-66.
53. Harris MB. (Chief, Orthopaedic Trauma, Brigham and Women's Hospital, Boston MA). Personal communication. 2005 Jul 14. 2 p.
54. Bucholz RW, Heckman JD, editors. *Rockwood and Green's fractures in adults*. 5th ed. Philadelphia (PA): Lippincott Williams & Wilkins; 2002. 2 v. 2262 p.
55. Newcombe RG. Interval estimation for the difference between independent proportions: comparison of eleven methods. *Stat Med* 1998 Apr 30;17(8):873-90.
56. Armitage P, Berry G. *Statistical methods in medical research*. 3rd ed. Oxford, England: Blackwell Scientific; 1994. 620 p.
57. Harris RP, Helfand M, Woolf SH, Lohr KN, Mulrow CD, Teutsch SM, Atkins D. Current methods of the U.S. Preventive Services Task Force. A review of the process. *Am J Prev Med* 2001 Apr;20(3 Suppl):21-35.
58. Smith WR, Shank JR, Skinner HB, Diao E, Lowenberg DW. Musculoskeletal trauma surgery. In: Skinner HB, editor. *Current diagnosis & treatment in orthopedics*. 3rd ed. Columbus (OH): McGraw-Hill Medical Publishing; 2003 Jun. p. 55-124.
59. Ring D. Malunion and nonunion of the metacarpals and phalanges. *J Bone Joint Surg Am* 2005 Jun;87-A(6):1380-8.
60. Mathews V, Cabanela ME. Femoral neck nonunion treatment. *Clin Orthop Relat Res* 2004 Feb;(419):57-64.
61. Maffulli N, Thornton A. Ultrasonographic appearance of external callus in long-bone fractures. *Injury* 1995 Jan;26(1):5-12.
62. Chen F, Osterman AL, Mahony K. Smoking and bony union after ulna-shortening osteotomy. *Am J Orthop* 2001 Jun;30(6):486-9.
63. Adams CI, Keating JF, Court-Brown CM. Cigarette smoking and open tibial fractures. *Injury* 2001 Jan;32(1):61-5.
64. Hak DJ, Lee SS, Goulet JA. Success of exchange reamed intramedullary nailing for femoral shaft nonunion or delayed union. *J Orthop Trauma* 2000 Mar-Apr;14(3):178-82.



65. Schmitz MA, Finnegan M, Natarajan R, Champine J. Effect of smoking on tibial shaft fracture healing. *Clin Orthop Relat Res* 1999 Aug;(365):184-200.
66. Kyro A, Usenius JP, Aarnio M, Kunnamo I, Avikainen V. Are smokers a risk group for delayed healing of tibial shaft fractures? *Ann Chir Gynaecol* 1993;82(4):254-62.
67. Volgas DA, Stannard JP, Alonso JE. Nonunions of the humerus. *Clin Orthop Relat Res* 2004 Feb;(419):46-50.
68. Prommersberger KJ, Fernandez DL. Nonunion of distal radius fractures. *Clin Orthop Relat Res* 2004 Feb;(419):51-6.
69. Giannoudis PV, MacDonald DA, Matthews SJ, Smith RM, Furlong AJ, De Boer P. Nonunion of the femoral diaphysis. The influence of reaming and non-steroidal anti-inflammatory drugs. *J Bone Joint Surg Br* 2000 Jul;82(5):655-8.
70. Cox MA, Dolan M, Synnott K, McElwain JP. Closed interlocking nailing of humeral shaft fractures with the Russell-Taylor nail. *J Orthop Trauma* 2000 Jun-Jul;14(5):349-53.
71. Gainor BJ, Moussa F, Schott T. Healing rate of transverse osteotomies of the olecranon used in reconstruction of distal humerus fractures. *J South Orthop Assoc* 1995 Winter;4(4):263-8.
72. O'Dwyer KJ, Chakravarty RD, Esler CN. Intramedullary nailing technique and its effect on union rates of tibial shaft fractures. *Injury* 1994 Sep;25(7):461-4.
73. Larsen LB, Madsen JE, Hoiness PR, Ovre S. Should insertion of intramedullary nails for tibial fractures be with or without reaming? A prospective, randomized study with 3.8 years' follow-up. *J Orthop Trauma* 2004 Mar;18(3):144-9.
74. Pugh DM, McKee MD. Advances in the management of humeral nonunion. *J Am Acad Orthop Surg* 2003 Jan-Feb;11(1):48-59.
75. Gonzalez del Pino J, Bartolome del Valle E, Grana GL, Villanova JF. Free vascularized fibular grafts have a high union rate in atrophic nonunions. *Clin Orthop Relat Res* 2004 Feb;(419):38-45.
76. Harley BJ, Beaupre LA, Jones CA, Dulai SK, Weber DW. The effect of time to definitive treatment on the rate of nonunion and infection in open fractures. *J Orthop Trauma* 2002 Aug;16(7):484-90.
77. Harris MB. (Chief, Orthopaedic Trauma, Brigham and Women's Hospital, Boston MA). Personal communication. 2005 Apr 15. 1 p.
78. ECRI. Recombinant human osteogenic protein-1 (rhOP-1) for healing nonunion fractures of the tibia. Plymouth Meeting (PA): ECRI Health Technology Assessment Information Service; 2005 Jan. 54 p. (Windows on medical technology; no. 122).
79. Seiler JG 3rd, Johnson J. Iliac crest autogenous bone grafting: donor site complications. *J South Orthop Assoc* 2000 Summer;9(2):91-7.
80. Younger EM, Chapman MW. Morbidity at bone graft donor sites. *J Orthop Trauma* 1989;3(3):192-5.
81. Ahlmann E, Patzakis M, Roidis N, Shepherd L, Holtom P. Comparison of anterior and posterior iliac crest bone grafts in terms of harvest-site morbidity and functional outcomes. *J Bone Joint Surg Am* 2002 May;84-A(5):716-20.
82. Zlowodzki M, Obrebsky WT, Thomison JB, Kregor PJ. Functional outcome after treatment of lower-extremity nonunions. *J Trauma* 2005 Feb;58(2):312-7.
83. Chandler RW. Principles of internal fixation. In: Bucholz RW, Heckman JD, Rockwood CA, Green DP, editors. *Rockwood and Green's fracture in adults*. 5th ed. Vol. 1. Philadelphia (PA): Lippincott Williams & Wilkins; 2001. p. 181-230.
84. Wu LC, Renucci JD, Song DH. Sternal nonunion: a review of current treatments and a new method of rigid fixation. *Ann Plast Surg* 2005 Jan;54(1):55-8.
85. Lazarus MD. Fractures of the clavicle. In: Bucholz RW, Heckman JD, Rockwood CA, Green DP, editors. *Rockwood and Green's fractures in adults*. 5th ed. Vol. 1. Philadelphia (PA): Lippincott Williams & Wilkins; 2001. p. 1041-78.
86. Robinson CM. Fractures of the clavicle in the adult. Epidemiology and classification. *J Bone Joint Surg Br* 1998 May;80(3):476-84.

87. Rokito AS, Zuckerman JD, Shaari JM, Eisenberg DP, Cuomo F, Gallagher MA. A comparison of nonoperative and operative treatment of type II distal clavicle fractures. *Bull Hosp Jt Dis* 2002-2003;61(1-2):32-9.
88. Rodriguez-Merchan EC, Gomez-Castresana F. Internal fixation of nonunions. *Clin Orthop Relat Res* 2004 Feb;(419):13-20.
89. Jones GL, McCluskey GM 3rd, Curd DT. Nonunion of the fractured clavicle: evaluation, etiology, and treatment. *J South Orthop Assoc* 2000 Spring;9(1):43-54.
90. Harris MB. (Chief, Orthopaedic Trauma, Brigham and Women's Hospital, Boston MA). Personal communication. 2005 Aug 17. 16 p.
91. Gregory PR Jr. Fractures of the shaft of the humerus. In: Bucholz RW, Heckman JD, Rockwood CA, Green DP, editor. *Rockwood and Green's fractures in adults*. 5th ed. Vol. 1. Philadelphia (PA): Lippincott Williams & Wilkins; 2001. p. 973-96.
92. Ring D, Jupiter JB, Quintero J, Sanders RA, Marti RK. Atrophic ununited diaphyseal fractures of the humerus with a bony defect: treatment by wave-plate osteosynthesis. *J Bone Joint Surg Br* 2000 Aug;82(6):867-71.
93. Patel VR, Menon DK, Pool RD, Simonis RB. Nonunion of the humerus after failure of surgical treatment. Management using the Ilizarov circular fixator. *J Bone Joint Surg Br* 2000 Sep;82(7):977-83.
94. Strauss E, Bartlett CS III, Casden A, DiGiovanni G, Frieden RA, Hahn M, Karas E, Plate AM, Sweet S. Orthopaedic geriatrics. In: Tallis R, Fillit H, Brocklehurst JC, editors. *Brocklehurst's textbook of geriatric medicine and gerontology*. 5th ed. London (UK): Churchill Livingstone; 1998. p. 1189-223.
95. Ring D. Treatment of the neglected distal radius fracture. *Clin Orthop Relat Res* 2005 Feb;(431):85-92.
96. Munk B, Larsen CF. Bone grafting the scaphoid nonunion: a systematic review of 147 publications including 5,246 cases of scaphoid nonunion. *Acta Orthop Scand* 2004 Oct;75(5):618-29.
97. Mears DC, Velyvis J. Surgical reconstruction of late pelvic post-traumatic nonunion and malalignment. *J Bone Joint Surg Br* 2003 Jan;85(1):21-30.
98. Starr AJ, Bucholz RW. Fractures in the shaft of the femur. In: Bucholz RW, Heckman JD, Rockwood CA, Green DP, editors. *Rockwood and Green's fractures in adults*. 5th ed. Vol. 1. Philadelphia (PA): Lippincott Williams & Wilkins; 2001. p. 1683-1730.
99. Goulet JA, Templeman D. Delayed union and nonunion of tibial shaft fractures. *Instr Course Lect* 1997;46:281-91.
100. Moed BR, Watson JT. Intramedullary nailing of aseptic tibial nonunions without the use of the fracture table. *J Orthop Trauma* 1995 Apr;9(2):128-34.
101. Richmond J, Colleran K, Borens O, Kloen P, Helfet DL. Nonunions of the distal tibia treated by reamed intramedullary nailing. *J Orthop Trauma* 2004 Oct;18(9):603-10.
102. Riemer BL, Sagiv S, Butterfield SL, Burke CJ 3rd. Tibial diaphyseal nonunions after external fixation treated with nonreamed solid core nails. *Orthopedics* 1996 Feb;19(2):109-16.
103. Gudas CJ, Cann JE. Complications of foot surgery. Nonunions and related disorders. *Clin Podiatr Med Surg* 1991 Apr;8(2):321-39.
104. Rosenberg GA, Sferra JJ. Treatment strategies for acute fractures and nonunions of the proximal fifth metatarsal. *J Am Acad Orthop Surg* 2000 Sep-Oct;8(5):332-8.
105. U.S. Food and Drug Administration, Center for Devices and Radiological Health. Class II special controls guidance document: resorbable calcium salt bone void filler device: guidance for Industry and FDA. Rockville (MD): U.S. Food and Drug Administration, Center for Devices and Radiological Health; 2003 Jun 2. 9 p. Also available: <http://www.fda.gov/cdrh/ode/guidance/855.pdf>.
106. Laurencin CT, Pratt LT, Kahn Y. Bone graft substitute materials. In: eMedicine [database online]. Omaha (NE): eMedicine.com, Inc.; 1996- [updated 2005 Mar 15]. [cited 2005 Jun 15]. [10 p]. Available: <http://www.emedicine.com/orthoped/topic611.htm>.
107. Parikh SN. Bone graft substitutes: past, present, future. *J Postgrad Med* 2002 Apr-Jun;48(2):142-8.

108. U.S. Food and Drug Administration, Center for Devices and Radiological Health. Guidance document for industry and CDRH staff for the preparation of investigational device exemptions and premarket approval applications for bone growth stimulator devices. Rockville (MD): U.S. Food and Drug Administration, Center for Devices and Radiological Health; 1998 Mar 18. 20 p. Also available: <http://www.fda.gov/cdrh/ode/bgsguide.html>.
109. Lieberman JR, Daluiski A, Einhorn TA. Current concepts review: the role of growth factors in the repair of bone. *J Bone Joint Surg Am* 2002;84:1032-44.
110. Pearson OM, Lieberman DE. The aging of Wolff's 'law': ontogeny and responses to mechanical loading in cortical bone. *Am J Phys Anthropol* 2004;Suppl 39:63-99.
111. Hadjiargyrou M, McLeod K, Ryaby JP, Rubin C. Enhancement of fracture healing by low intensity ultrasound. *Clin Orthop Relat Res* 1998 Oct;(355 Suppl):S216-29.
112. EBI Bone healing system. [internet]. Parsippany (NJ): EBI Medical, Inc.; [cited 2005 Sep 6]. [2 p]. Available: <http://www.ebimedical.com/products/detail.cfm?p=0C>.
113. Evans RD, Foltz D, Foltz K. Electrical stimulation with bone and wound healing. *Clin Podiatr Med Surg* 2001 Jan;18(1):79-95, vi.
114. Jervey C, Friedman RJ. Electrical stimulation: current concepts and indications. *Contemp Orthop* 1990 Jan;20(1):61-5.
115. Ryaby JT. Clinical effects of electromagnetic and electric fields on fracture healing. *Clin Orthop Relat Res* 1998 Oct;(355 Suppl):S205-15.
116. Ito H, Shirai Y. The efficacy of ununited tibial fracture treatment using pulsing electromagnetic fields: relation to biological activity on nonunion bone ends. *J Nippon Med Sch* 2001 Apr;68(2):149-53.
117. Meskens MW, Stuyck JA, Feys H, Mulier JC. Treatment of nonunion using pulsed electromagnetic fields: a retrospective follow-up study. *Acta Orthop Belg* 1990;56(2):483-8.
118. Birnbaum K, Wirtz DC, Siebert CH, Heller KD. Use of extracorporeal shock-wave therapy (ESWT) in the treatment of non-unions. A review of the literature. *Arch Orthop Trauma Surg* 2002 Jul;122(6):324-30.
119. Wang CJ, Chen HS, Chen CE, Yang KD. Treatment of nonunions of long bone fractures with shock waves. *Clin Orthop Relat Res* 2001 Jun;(387):95-101.
120. Vogel J, Hopf C, Eysel P, Rompe JD. Application of extracorporeal shock-waves in the treatment of pseudarthrosis of the lower extremity. Preliminary results. *Arch Orthop Trauma Surg* 1997;116(8):480-3.
121. Haupt G. Use of extracorporeal shock waves in the treatment of pseudarthrosis, tendinopathy and other orthopedic diseases. *J Urol* 1997 Jul;158(1):4-11.
122. Cornell CN. Osteobiologics. *Bull Hosp Jt Dis* 2004;62(1-2):13-7.
123. Damien CJ, Parsons JR. Bone graft and bone graft substitutes: a review of current technology and applications. *J Appl Biomater* 1991 Fall;2(3):187-208.
124. Einhorn TA. Clinical applications of recombinant human BMPs: early experience and future development. *J Bone Joint Surg Am* 2003;85-A Suppl:82-8.
125. Wolfe MW, Salkeld SL, Cook SD. Bone morphogenetic proteins in the treatment of non-unions and bone defects: historical perspectives and current knowledge. *Univ Pa Orthop J* 1999 Spring;12:1-6. Also available: <http://www.uphs.upenn.edu/ortho/oj/html/oj12sp99p1.html>.
126. Adams BD, Frykman GK, Taleisnik J. Treatment of scaphoid nonunion with casting and pulsed electromagnetic fields: a study continuation. *J Hand Surg [Am]* 1992 Sep;17(5):910-4.
127. Johnson EE, Urist MR. Human bone morphogenetic protein allografting for reconstruction of femoral nonunion. *Clin Orthop Relat Res* 2000 Feb;(371):61-74.
128. Johnson EE, Urist MR, Finerman GA. Resistant nonunions and partial or complete segmental defects of long bones. Treatment with implants of a composite of human bone morphogenetic protein (BMP) and autolyzed, antigen-extracted, allogeneic (AAA) bone. *Clin Orthop Relat Res* 1992 Apr;(277):229-37.

129. Cook TD, Campbell DT. Quasi-experimentation: design and analysis issues for field settings. Boston (MA): Houghton Mifflin Company; 1979. 405 p.
130. Bechtold J. (Senior Vice President, Reimbursement and Government Affairs, EBI, L.P.). Personal communication. 2005 Aug 30. 11 p.
131. ECRI. Electrical bone growth stimulation for the spine and lower leg [technology assessment report]. Plymouth Meeting (PA): ECRI; 1993 Oct. 106 p.
132. Orthofix. Physio-Stim Patient Registry Summary. McKinney (TX): Orthofix, Inc.; 1 p.
133. Fellows R. (Vice President, Government Affairs & National Accounts, Orthofix). Personal communication. 2005 Sep 1. 3 p.
134. Krempen J, Silver R. External electromagnetic fields in the treatment of nonunion bones. *Orthop Rev* 1981;10:33.
135. Heckman JD, Ingram AJ, Loyd RD, Luck JV Jr, Mayer PW. Nonunion treatment with pulsed electromagnetic fields. *Clin Orthop Relat Res* 1981 Nov-Dec;(161):58-66.
136. Bassett CA, Mitchell SN, Gaston SR. Pulsing electromagnetic field treatment in ununited fractures and failed arthrodeses. *JAMA* 1982 Feb 5;247(5):623-8.
137. Sharrard WJ, Sutcliffe ML, Robson MJ, Maceachern AG. The treatment of fibrous non-union of fractures by pulsing electromagnetic stimulation. *J Bone Joint Surg Br* 1982;64(2):189-93.
138. Marcer M, Musatti G, Bassett CA. Results of pulsed electromagnetic fields (PEMFs) in ununited fractures after external skeletal fixation. *Clin Orthop Relat Res* 1984;190:260-5.
139. Dunn AW, Rush GA 3d. Electrical stimulation in treatment of delayed union and nonunion of fractures and osteotomies. *South Med J* 1984 Dec;77(12):1530-4.
140. Cheng N, Van Hoof H, Delport PH, Hoogmartens MJ, Mulier JC. Treatment of non-union, congenital pseudarthroses and benign cystic lesions using pulsed electromagnetic fields. *Reconstr Surg Traumatol* 1985;19:118-22.
141. Hinsenkamp M, Ryaby J, Burny F. Treatment of non-union by pulsing electromagnetic field: European multicenter study of 308 cases. *Reconstr Surg Traumatol* 1985;19:147-51.
142. Frykman GK, Taleisnik J, Peters G, Kaufman R, Helal B, Wood VE, Unsell RS. Treatment of nonunited scaphoid fractures by pulsed electromagnetic field and cast. *J Hand Surg [Am]* 1986 May;11(3):344-9.
143. Colson DJ, Browett JP, Fiddian NJ, Watson B. Treatment of delayed- and non-union of fractures using pulsed electromagnetic fields. *J Biomed Eng* 1988 Jul;10(4):301-4.
144. Jimenez ML, Anderson TL. The use of allograft, platelet-derived growth factors, and internal bone stimulation for treatment of recalcitrant nonunions [poster no. 52]. Hippocrates Winslow & Babbage Foundation 2003 Annual Meeting. February 6, 2003; New Orleans (LA). 2003. Also available: <http://www.hwbf.org/ota/am/ota03/otapo/OTP03052.htm>.
145. Forsted DL, Dalinka MK, Mitchell E, Brighton CT, Alavi A. Radiologic evaluation of the treatment of nonunion of fractures by electrical stimulation. *Radiology* 1978 Sep;128(3):629-34.
146. Paterson DC, Lewis GN, Cass CA. Treatment of delayed union and nonunion with an implanted direct current stimulator. *Clin Orthop Relat Res* 1980 May;(148):117-28.
147. Zichner L. Repair of nonunions by electrically pulsed current stimulation. *Clin Orthop Relat Res* 1981 Nov-Dec;(161):115-21.
148. Connolly JF. Selection, evaluation and indications for electrical stimulation of ununited fractures. *Clin Orthop Relat Res* 1981 Nov-Dec;(161):39-53.
149. Ahl T, Andersson G, Herberts P, Kalen R. Electrical treatment of non-united fractures. *Acta Orthop Scand* 1984 Dec;55(6):585-8.
150. Yuan ZX, Tang YG, Lu XY, Yu HL, Zhao DZ. Continuous direct current in the treatment of nonunion and delayed union. *Chin Med J (Engl)* 1986 Feb;99(2):133-8.

151. Schaden W, Fischer AJ, Sailer A, Karadas E. Extracorporeal shockwave therapy (ESWT) for tibia non-unions [paper no. 355]. American Academy of Orthopaedic Surgeons 2005 Annual Meeting. February 23-27, 2005; Washington (DC). 2005. Also available: <http://www.aaos.org/wordhtml/anmt2005/sciprog/395.htm>.
152. Koval KJ. (Professor, Dartmouth Hitchcock Medical Center). Personal communication. 2005 Aug 22. 5 p.
153. Miller R, Mont MA. Clinical experience with osteogenic protein-1 for the treatment of recalcitrant long bone nonunions [poster board number: P395]. American Academy of Orthopaedic Surgeons 2005 Annual Meeting. February 23-27, 2005; Washington (DC). 2005. Also available: <http://www.aaos.org/wordhtml/anmt2005/poster/p395.htm>.
154. Office of Device Evaluation, Center for Devices and Radiological Health (CDRH). Premarket approval application notification. H010002. Stryker Biotech, OP-1 Implant. 2001 Oct 17. 8 p.
155. Wyeth Pharmaceuticals. New device approval: Wyeth Pharmaceuticals INFUSE bone graft - P000054. [internet]. Rockville (MD): Office of Device Evaluation, Center for Devices and Radiological Health (CDRH); 2004 Apr 30 [cited 2005 Jun 7]. [3 p]. Available: <http://www.fda.gov/cdrh/mda/docs/p000054.html>.
156. Orozco L, Rodriguez L, Torrico C, Douville J, Hock JM, Armstrong RD, Garcia J, Solano C. Clinical feasibility study: the use of cultured enriched autologous bone marrow cells to treat refractory atrophic and hypotrophic nonunion fractures. Ann Arbor (MI): Aastrom Biosciences, Inc.; 2005 May 12. 19 p.
157. Yoffee Aastrom Biosciences. Drug development; Bone graft trial expanded to include New York Hospital. In: NewsRx.com [internet]. Atlanta (GA): Medical Devices & Surgical Technology Week, NewsRX.com; 2005 Apr 3 [cited 2005 Jun 17]. [p. 155]. Available: [http://www.newsrx.com/cgi-bin/single\\_article\\_search.cgi](http://www.newsrx.com/cgi-bin/single_article_search.cgi).
158. McKee MD, Wild LM, Schemitsch EH, Waddell JP. The use of an antibiotic-impregnated, osteoconductive, bioabsorbable bone substitute in the treatment of infected long bone defects: early results of a prospective trial. J Orthop Trauma 2002;16(9):622-7.
159. Wilkins RM, Kelly CM, Giusti DE. Bioassayed demineralized bone matrix and calcium sulfate: use in bone-grafting procedures. Ann Chir Gynaecol 1999;88(3):180-5.
160. Luchetti R. Corrective osteotomy of malunited distal radius fractures using carbonated hydroxyapatite as an alternative to autogenous bone grafting. J Hand Surg [Am] 2004 Sep;29(5):825-34.
161. Office of Device Evaluation, Center for Devices and Radiological Health (CDRH). Premarket approval application notification. P900009/S6. Exogen 2000 or Sonic Accelerated Fracture Healing system (SAFHS). 2000 Feb 22. 6 p.
162. Exogen. Exogen 2000 summary of safety and effectiveness. P900009. Piscataway (NJ): Exogen; 2000 Feb 22. 19 p. Also available: <http://www.fda.gov>.
163. Exogen. SAFHS 2000 (sonic accelerated healing system for the treatment of nonunion: physician's instructions for use. Piscataway (NJ): Exogen, Inc.; 1998 Jun 18. 45 p. Also available: <http://www.fda.gov>.
164. Pigozzi F, Moneta MR, Giombini A, Giannini S, Di Cesare A, Fagnani F, Mariani PP. Low-intensity pulsed ultrasound in the conservative treatment of pseudoarthrosis. J Sports Med Phys Fitness 2004 Jun;44(2):173-8.
165. Lerner A, Stein H, Soudry M. Compound high-energy limb fractures with delayed union: our experience with adjuvant ultrasound stimulation (exogen). Ultrasonics 2004 Apr;42(1-9):915-7.
166. Jones NF, Brown EE, Mostofi A, Vogelien E, Urist MR. Healing of a scaphoid nonunion using human bone morphogenetic protein. J Hand Surg [Am] 2005 May;30(3):528-33.
167. Delloye C, Suratwala SJ, Cornu O, Lee FY. Treatment of allograft nonunions with recombinant human bone morphogenetic proteins (rhBMP). Acta Orthop Belg 2004 Dec;70(6):591-7.
168. Saltzman C, Lightfoot A, Amendola A. PEMF as treatment for delayed healing of foot and ankle arthrodesis. Foot Ankle Int 2004 Nov;25(11):771-3.
169. Nishikawa S, Toh S, Tsukahara S, Takahashi I. Endoscopic treatment of delayed unions and nonunions with calcium phosphate paste. Arthroscopy 2003 Apr;19(4):436-9.
170. Kloen P, Doty SB, Gordon E, Rubel IF, Goumans MJ, Helfet DL. Expression and activation of the BMP-signaling components in human fracture nonunions. J Bone Joint Surg Am 2002 Nov;84-A(11):1909-18.

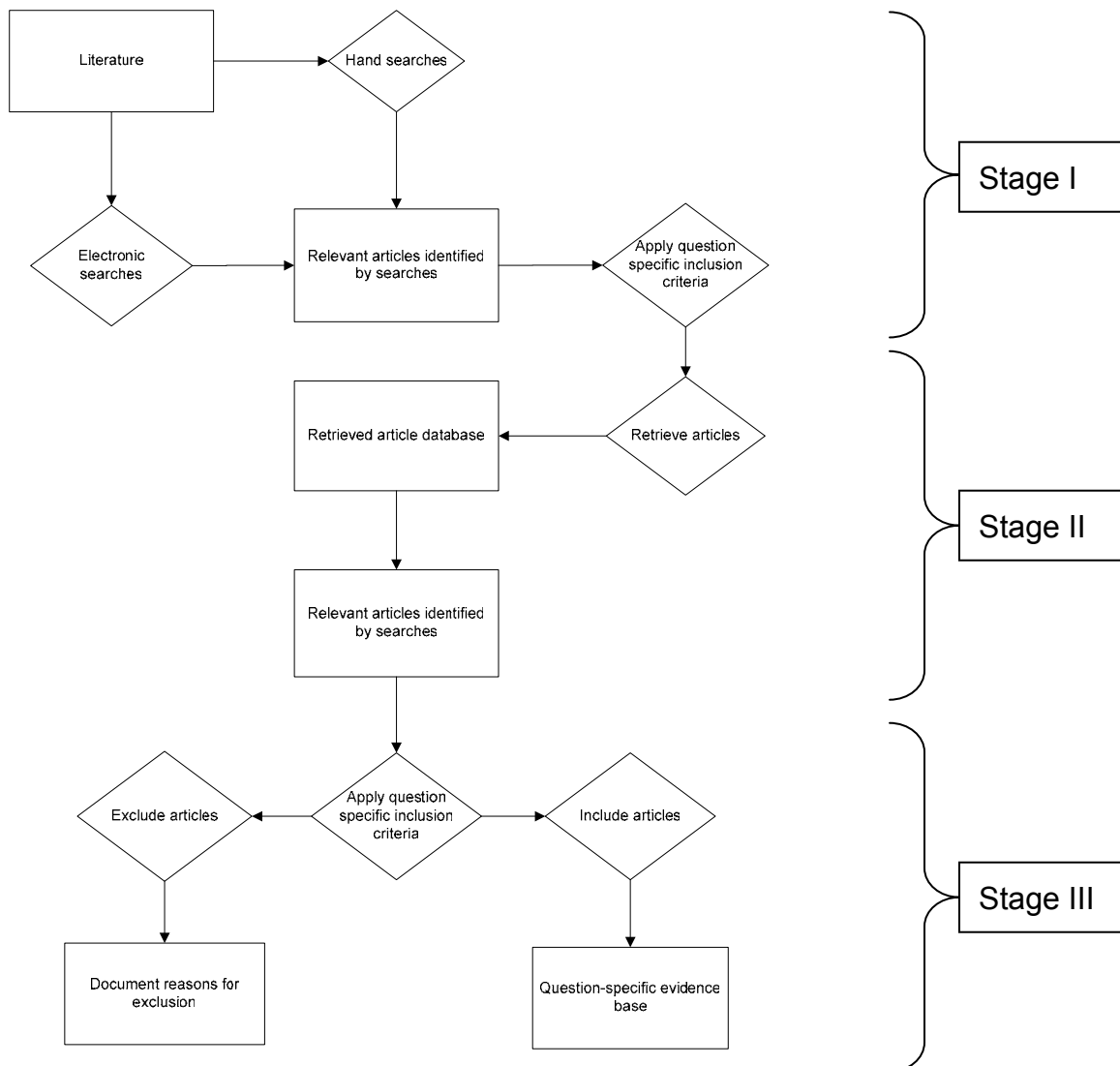
171. Ikeda K, Tomita K, Takayama K. Application of extracorporeal shock wave on bone: preliminary report. *J Trauma* 1999 Nov;47(5):946-50.
172. Rosenthal RK, Folkman J, Glowacki J. Demineralized bone implants for nonunion fractures, bone cysts, and fibrous lesions. *Clin Orthop Relat Res* 1999 Jul;(364):61-9.
173. Satter Syed A, Islam MS, Rabbani KS, Talukder MS. Pulsed electromagnetic fields for the treatment of bone fractures. *Bangladesh Med Res Counc Bull* 1999 Apr;25(1):6-10.
174. Abeer RI, Naseer M, Abel EW. Capacitively coupled electrical stimulation treatment: results from patients with failed long bone fracture unions. *J Orthop Trauma* 1998 Sep-Oct;12(7):510-3.
175. Frankel VH. Results of prescription use of pulse ultrasound therapy in fracture management. *Surg Technol Int* 1998;VII:389-93.
176. Bai MH, Liu XY, GE BF, Yallg C, Chen DA. An implant of a composite of bovine bone morphogenetic protein and plaster of paris for treatment of femoral shaft nonunions. *Int Surg* 1996 Oct-Dec;81(4):390-2.
177. Holmes GB Jr. Treatment of delayed unions and nonunions of the proximal fifth metatarsal with pulsed electromagnetic fields. *Foot Ankle Int* 1994 Oct;15(10):552-6.
178. Schleberger R, Senge T. Non-invasive treatment of long-bone pseudarthrosis by shock waves (ESWL). *Arch Orthop Trauma Surg* 1992;111(4):224-7.
179. Sharrard J. [D-1-3] A double-blind trial of PEMFS for delayed tibial union - clinical follow-up. In: 16th Annual Meeting of the Bioelectromagnetical Society; 1994; Copenhagen, Denmark. 1994.

**APPENDICES: SUPPORTING**  
**DOCUMENTATION, SUMMARY TABLES, AND**  
**EVIDENCE TABLES**

## **Appendix A. Literature Searches**

The clinical studies included in this report were identified using the algorithm shown in Figure A-1. The first stage of this multi-staged study selection process consisted of a comprehensive literature search. The second stage of the process consisted of the retrieval of all articles that met a set of a priori retrieval criteria. The final stage of the study selection algorithm consisted of the selection of the actual studies that form the evidence base for this report using a set of a priori inclusion criteria.

**Figure A-1. Study Selection Algorithm**





### **Electronic Database Searches**

The following databases have been searched for relevant information:

Cochrane Database of Systematic Reviews (through 2005, Issue 3)

Cochrane Registry of Clinical Trials (CENTRAL) (through 2005, Issue 3)

Cochrane Review Methodology Database (through 2005, Issue 3)

Database of Reviews of Effectiveness (Cochrane Library) (through 2005, Issue 3)

ECRI Health Devices Alerts (1977 through August 2005)

ECRI Health Devices Sourcebase (through August 2005)

ECRI Health Technology Forecast Database (through August 2005)

ECRI Healthcare Standards (1975 through August 2005)

ECRI International Health Technology Assessment Database (IHTA) (through August 2005)

ECRI Library Catalog (through August 2005)

ECRI TARGET (through August 2005)

Embase (1985 through August 15, 2005)

Lexis-Nexis, Healthcare News, Current (2003 – 2005)

PubMed (includes MEDLINE, HealthSTAR and CancerLit) (1975 through August 15, 2005)

U.S. Centers for Medicare & Medicaid Services (CMS) Web site (through August 2005)

U.S. Food and Drug Administration (FDA) Web site (through August 2005)

U.S. National Guideline Clearinghouse™ (NGC™) (through August 2005)

The search strategies employed a number of freetext keywords as well as controlled vocabulary terms including (but not limited to) the following concepts.

## Medical Subject Headings (MeSH) and Keywords

### Conventions:

[mh] = MeSH heading

[majr] = MeSH heading designated as major topic

[pt] = Publication Type (PubMed)

[sb] = Subset of PubMed database (PreMedline, Systematic, OldMedline)

[sh] = MeSH subheading (qualifiers used in conjunction with MeSH headings)

[tiab] = keyword in title or abstract

[tw] = Text word

.de. = controlled vocabulary heading in OVID syntax (Emtree)

### Topic-Specific

Bone void

Non union

Fracture\*

Non-united

Fracture healing[mh]

Non united

Fracture fixation.de.

Nonunion

Fracture nonunion.de.

Nonunited

Fractures[mh]

Ununited

Fractures, ununited[mh]

### Diagnosis

Malaligned

Diagnos\*

Malalignment

Di[sh]

Mal-union

### Etiology/Risk

Malunion

Causality[mh]

Malunited

Causation

Non-union

Enabling factor\*

Epidemiol\*  
Epidemiology[sh]  
Etiology[sh]  
Predisposing factor\*  
Risk factor\*  
Etiolog\*

### **Other**

Adult

### **Therapy**

Biocompatible materials[mh]  
Biological response modifier.de.  
Biologic response modifiers[mh]  
Bmp-7  
Bone graft\*  
Bone matrix.de.  
Bone morphogenetic protein\*  
Bone morphogenic protein\*  
Bone morphogenic proteins[mh]  
Bone regeneration.de.  
Bone stimulat\*  
Bone substitut\*  
Bone transplant\*  
Bone transplantation[mh]  
Drug therapy[sh]  
Effectiveness  
Efficacy  
Electric stimulat\*  
Electric stimulation therapy[mh]  
Electrotherap\*  
ELF  
External fixation  
External fixators[mh]

Fracture fixation  
“Intention to treat”  
Manipulation, orthopedic[mh]  
OP-1  
Orthopedic fixation devices[mh]  
Orthopedic procedures[mh]  
Osteogenic protein\*  
Outcome assessment  
Proteins/therapeutic use[mh]  
Recombinant protein.de.  
Recombinant proteins/therapeutic use[mh]  
rhBMP-7  
rhOP-1  
Surgery  
Surgery[sh]  
Surgical  
Therapeutic\*  
Therapeutics[mh]  
Therapy  
Therapy[sh]  
Treat\*  
Treatment\*  
Ultrasonic  
Ultrasonic therapy[mh]  
Ultrasound

### **Devices (UMDNS)**

Bolts, bone [16-077]  
Bone matrix implants, artificial [17-751]  
Bone matrix implants, biological [17-756]  
Cement, orthopedic [12-830]

Grafts, bone [11-910]  
 Grafts, bone, synthetic [16-966]  
 Jaw fracture fixation devices [15-801]  
 Nails, bone [16-078]  
 Pins, bone [16-085]  
 Plates, bone [13-050]  
 Orthopedic external fixation systems [16-044]  
 Orthopedic external fixation systems, fracture [15-767]  
 Orthopedic internal fixation systems, fracture [12-833]  
 Orthopedic internal fixation systems, other [16-031]  
 Screws, bone [16-101]  
 Staples, bone, compression, heat reshaping [20-327]  
 Staples, bone, compression, separate-leg [20-326]  
 Tissue reconstructive materials, solid [16-153]  
 Wires, bone [16-104]

### **Publication types**

#### **Guidelines:**

“Clinical pathway”  
 Consensus[pt]  
 Guideline[pt]  
 Guideline\*[ti]  
 “Policy statement”  
 “Position paper”  
 “Position statement”  
 Practice guidelines[mh]  
 “Practice parameter”  
 Standard\*[ti]

Standards[sh]

“White paper”

#### **Meta-analyses/Systematic Reviews:**

Meta-analysis

Meta-analysis[mh]

Meta-analysis[pt]

“Systematic Review”

(evidence base\* OR methodol\* OR systematic\* OR quantitative\* OR studies OR overview\*) AND review[pt]

#### **Randomized Controlled Trials:**

Crossover\*

Cross-over\*

Double-blind method[mh]

“Latin square”

Placebo\*

Placebos[mh]

Random\*[ti]

Random allocation[mh]

Randomized controlled trial[pt]

Randomized controlled trials[mh]

Single-blind method[mh]

((singl\*[tw] OR doubl\*[tw] OR trebl\*[tw] OR tripl\*[tw]) AND (mask\* OR blind\* OR sham\* OR dummy)

The detailed strategy below is presented in PubMed syntax. Parallel strategies were used to search the Cochrane Library and Embase. Keyword searches were conducted in the other listed resources.

## PubMed Search Strategy (1975 – 2005)

**Limited to English language, human population**

<b>Set Number</b>	<b>Concept</b>	<b>Search Statement</b>
1	Nonunion fracture	((Fractures[mh] OR fracture healing[mh] OR fracture*[tw]) AND (ununited OR un-united OR "un united" OR non-union OR "non union OR nonunion OR nonunited)) OR fractures, ununited[mh])
2	Diagnosis and risk factors	#1 AND (diagnos*[tw] OR diagnosis[sh] OR etiolog*[tw] OR causation[tw] OR enabling factor*[tw] OR risk factor* OR predisposing factor*[tw] OR epidemiology[sh] OR epidemiol*[tw] OR etiology[sh] OR causality[mh])
3	Treatment – general	#1 AND (th[sh] OR su[sh] OR dt[sh] OR effectiveness OR efficacy OR "intention to treat" OR treat OR treatment* OR therapy OR therapeutic* OR outcome assessment OR therapeutics[mh] OR surgery[tw] OR surgical[tw])
4	Treatment – surgical	#1 AND (fracture fixation[mh] OR surgery[sh] OR surgery[tw] OR surgical[tw] OR orthopedic procedures[mh] OR bone graft* OR bone transplant* OR bone transplantation[mh] OR orthopedic fixation devices[mh] OR )
5	Treatment – biologicals	#1 AND (biological response modifiers[mh] OR bmp-7 OR bone morphogenic protein* OR bone morphogenetic proteins[mh] OR bone regeneration[mh] OR OP-1 OR osteogenic protein* OR proteins/tu[mh] OR recombinant proteins/tu[mh] OR rhBMP-7 OR rhOP-1 OR
6	Treatment - stimulation	#1 AND (electric stimulation therapy[mh] OR bone stimulat* OR electric stimulat* OR electrotherap* OR ultrasonic therapy[mh] OR ultrason* OR ultrasound*)
7	Treatment – other	#1 AND (biocompatible materials[mh] OR bone matrix OR bone substitut* OR external fixators[mh] OR external fixation OR manipulation, orthopedic[mh])

<b>Set Number</b>	<b>Concept</b>	<b>Search Statement</b>
8	Reviews, standards & guidelines	(st[sh] OR guideline[pt] OR consensus[pt] OR "practice parameter" OR "position statement" OR "position paper" OR "policy statement" OR standard*[ti] OR guideline*[ti] OR "white paper" OR "clinical pathway" OR practice guidelines[mh] OR meta-analysis OR meta-analysis[pt] OR ((evidence base* OR methodol* OR systematic* OR quantitativ* OR studies OR overview*) AND review[pt]))
9	Background	#1 AND #8
10	Combine sets	#2 OR #3 OR #4 OR #5 OR #6 OR #7 OR #9
11	Limit publication types	NOT (letter[pt] OR editorial[pt] OR news[pt] OR comment[pt] OR case reports[pt] OR review[pt])
12	Limit to human	AND (humans[mh] OR premedline[sb] OR publisher[sb])

### **Hand Searches of Journal and Nonjournal Literature**

Journals and supplements maintained in ECRI's collections were routinely reviewed. Nonjournal publications and conference proceedings from professional organizations, private agencies, and government agencies were also screened. Other mechanisms used to retrieve additional relevant information included review of bibliographies/reference lists from peer-reviewed and gray literature. (Gray literature consists of reports, studies, articles, and monographs produced by federal and local government agencies, private organizations, educational facilities, consulting firms, and corporations. These documents do not appear in the peer-reviewed journal literature.)

**Appendix B. Orthobiologics and Bone Growth Stimulating Devices Used to Treat Nonunion Fractures**

**Table B-1. List of Orthobiologics Used to Treat Nonunion Fractures**

Specific Product Name	Company Name	US Food and Drug Administration Status	References
OP-1 Implant – recombinant osteogenic protein 1 (or BMP-7) and bovine bone collagen In Europe this product is called Osigraft	Stryker Biotech	In October 2001, the FDA granted Stryker Biotech a humanitarian device exemption (HDE) for the use of OP-1 Implant for use as an alternative to autograft in recalcitrant long bone nonunions where use of autograft is unfeasible and alternative treatments have failed.	(154) (23)
Infuse Bone Graft – contains recombinant human Bone Morphogenetic Protein-2 in an Absorbable Collagen Sponge (rhBMP-2/ACS) InductOS in Europe	Wyeth Pharmaceuticals	Has premarket approval (PMA in 2004) for use in the treatment of acute, open tibial shaft fractures in adults. To be used with internal fixation (intramedullary nail)	(155)
Palacos E-Flow (Osteopal) Bone Cement	Biomet Merck	Has premarket approval (PMA in 1998) for changes in the bone cement composition. The device, as modified, will be marketed under the trade name Osteopal (E-Flow) and is indicated for use as a bone cement in arthroplastic procedures of the hip, knee, and other joints to fix plastic and metal prosthetic parts to living bone when reconstruction is necessary because of osteoarthritis, nonunion of fractures of the neck of the femur, sickle cell anemia, osteoporosis, secondary severe joint destruction following trauma or other conditions (also for fixation of unstable fractures in metastatic malignancies), and revision of previous arthroplasty procedures. Also has 510k clearance as a polymethylmethacrylate bone cement.	
AastromReplicell System – proprietary culture process for the ex vivo production of bone marrow cells, combined with a beta tri-calcium phosphate (Calcibon Granules, Biomet Merck)	Aastrom Biosciences, Inc (Ann Arbor, Michigan)	No approvals. Currently in phase I/II clinical trials in the U.S.	(156) (157)
OsteoSet – calcium sulfate (Plaster of Paris) OsteoSet –T, osteoSet with tobramycin antibiotic	Wright Medical Technology	Received 510k clearance in 1996 as a resorbable calcium salt bone void filler	(158) (159)

**Table B-1. List of Orthobiologics Used to Treat Nonunion Fractures (continued)**

Specific Product Name	Company Name	US Food and Drug Administration Status	References
OsteoSet BVK kit – contains a sterile pre-measured surgical grade calcium sulfate, mixing solution, tools to mix	Wright Medical Technology	Received 510k clearance in 2001. Resultant paste is to be injected, digitally packed into open bone void/gap that are not intrinsic to the stability of bone structure of the skeletal system (extremities, spine, and pelvis). The open bone voids may be surgically created osseous defects or osseous defects created from traumatic injury to the bone.	
OsteoSet DBM pellets – surgical grade calcium sulfate incorporating human demineralized bone matrix (DBM)	Wright Medical Technology	Received 510k clearance in 2004. OsteoSet DBM pellets are indicated only for bony voids or gaps that are not intrinsic to the stability of bony structure. OsteoSet DBM pellets are intended to be gently packed into bony void or gaps of the skeletal system (extremities, spine, and pelvis). These defects may be surgically created osseous defects or osseous defects created from traumatic injury to the bone.	Company Web sites mentions its use for nonunions
AlloMatrix Putty – contains demineralized bone matrix (Allogro from AlloSource), carboxymethylcellulose, and OsteoSet	Wright Medical Technology	Received 510k clearance in 2004. AlloMatrix is indicated only for bony voids or gaps that are not intrinsic to the stability of bony structure. AlloMatrix is intended to be gently packed into bony void or gaps of the skeletal system (extremities, spine, and pelvis). These defects may be surgically created osseous defects or osseous defects created from traumatic injury to the bone. A variety of other AlloMatrix products were also given 510k clearance in 2004 with the same indications.	(159) (106) Company Web site mentions its use for nonunions
Allogran-R – beta tri-calcium phosphate synthetic bone substitute	Biocomposites (England)	Allogran-R has not been cleared by the FDA for any purpose.	Company Web site mentions its use for nonunions
Norian SRS Bone Void Filler – carbonated hydroxyapatite	Synthes (USA)	Received 510k clearance in 2001. Norian SRS is indicated only for bony voids or gaps that are not intrinsic to the stability of bony structure. Norian SRS is intended to be gently packed into bony void or gaps of the skeletal system (extremities, spine, and pelvis). These defects may be surgically created osseous defects or osseous defects created from traumatic injury to the bone.	(160)



**Table B-1. List of Orthobiologics Used to Treat Nonunion Fractures (continued)**

Specific Product Name	Company Name	US Food and Drug Administration Status	References
JAX CS bone graft substitute	Smith and Nephew	JAX is indicated only for bony voids or gaps that are not intrinsic to the stability of the bony structure. JAX™ is indicated to be gently packed into bony voids or gaps of the skeletal system, ( <i>i.e.</i> , the extremities, spine, and pelvis). These defects may be surgically created osseous defects or osseous defects created from traumatic injury to the bone. JAX™ provides a filler that is resorbed and is replaced with bone during the healing process. Because JAX™ is biodegradable and biocompatible, it may be used at an infected site.	Company Web site mentions its use as a bone graft substitute and that bone grafts are used for nonunions (8)

**Table B-2. List of External Bone Growth Stimulating Devices Used to Treat Nonunion Fractures**

Specific Device Name	Company Name	US Food and Drug Administration Status	References
<b>Ultrasound Systems</b>			
Sonic Accelerated Fracture Healing System Model 2A Original PMA number P900009	Smith & Nephew, Inc. Memphis, TN 38116	Received PMA in 1994 as a bone growth stimulator	
Sonic Accelerated Fracture Healing System Model 2000 Supplement to PMA number P900009	Exogen, Inc. Piscataway, NJ 08855	Received PMA in 2000 for the non-invasive treatment of established nonunions excluding skull and vertebrae, and for accelerating the time to a healed fracture for fresh, closed, posteriorly displaced distal radius fractures, and fresh, closed or Grade I open tibial diaphysis fractures in skeletally mature individuals when these fractures are orthopedically managed by closed reduction and cast immobilization. A nonunion is considered to be established when the fracture site shows no visibly progressive signs of healing	(161) (162) (163)
Exogen 3000® Sonic Accelerated Fracture Healing System Supplement to PMA number P900009	Exogen, Inc., Piscataway, NJ 08855	Received PMA in 2000 for various design and manufacturing changes which do not affect the output of the device. The device, as modified, will be marketed under the trade name Exogen 3000	
Exogen 2000 Sonic Accelerated Fracture Healing System (SAFHS®) Supplement to PMA number P900009	Smith & Nephew, Inc. Memphis, TN 38116	Received PMA in 2001 for the low intensity ultrasound fracture treatment system, Sonic Accelerated Fracture Healing System (SAFHS®). The device, as modified, will be marketed under the trade name Exogen 2000 Sonic Accelerated Fracture Healing System (SAFHS®) and is indicated for the non-invasive treatment of established nonunions* excluding skull and vertebrae. In addition, the Exogen 2000+™ or Sonic Accelerated Fracture Healing System (SAFHS®) is indicated for accelerating the time to a healed fracture for fresh, closed, posteriorly displaced distal radius fractures and fresh, closed or Grade 1 open tibial diaphysis in skeletally mature individuals when these fractures are orthopedically managed by closed reduction and cast immobilization.  *A nonunion is considered to be established when the fracture site shows no visibly progressive signs of healing.	(9) (10) (164) (165)
Exogen 3000® Sonic Accelerated Fracture Healing System Supplement to PMA number P900009	Exogen, Inc., Piscataway, NJ 08855	Received PMA in 2001 for a change in labeling for the Exogen 3000®, to incorporate both the fresh fracture and nonunion information into one set of Physician's Instructions for Use, Patient's Instructions for Use, and Product Insert Bulletin; to make manual size and formatting changes, and to add nonunion background information.	

**Table B-2. List of External Bone Growth Stimulating Devices Used to Treat Nonunion Fractures (continued)**

Specific Device Name	Company Name	US Food and Drug Administration Status	References
<b>Pulsed electromagnetic field systems</b>			
Bio Osteogen System 204 Original PMA number P790002	Electro-Biology, Inc.	Received PMA in 1979	
EBI Bone Healing System® FLX® Coilette Supplement to PMA number P790002	Electro-Biology, Inc.	Received PMA in 1997 for the FLX® Coilette which will be used to deliver the approved repetitive pulse burst signal produced by the EBI Bone Healing System Model 1200. To be used with the EBI Bone Healing System Model 1200 which is indicated for nonunions, failed fusions, and congenital pseudarthroses	
EBI Bone Healing System Model 2001 Supplement to PMA number P790002	Electro-Biology, Inc.	Received PMA in 1999 for "the treatment of fracture nonunions, failed fusions, and congenital pseudoarthroses in the appendicular system."	
EBI Bi-Osteogen™/Bone Healing System® FLX®-S Coils (FLX 2-S, FLX 3-S, and FLX 4-S) Supplement to PMA number P790002	Electro-Biology, Inc. A Subsidiary of Biomet, Inc. Parsippany, NJ 07054-1079	Received PMA in 1998 for the FLX®-S Coils (model numbers FLX 2-S, FLX 3-S, and FLX 4-S) which will be used to deliver the single repetitive pulse (SRP) signal produced by the EBI Bone Healing System® Model 1020-S control unit. The device, as modified, will be marketed under the trade name EBI FLX®-S Coils and used with the EBI Bone Healing System® Model 1020-S control unit which is indicated for the treatment of nonunions, failed fusions, and congenital pseudarthroses.	
EBI Bone Healing System Supplement to PMA number P790002	Electro-Biology, Inc. Parsippany, NJ, 07054-1079	Received PMA in 1998 for revision of the indications and usage section of the labeling for Models 1200, 1020-S, 1026, and 101, to include the definition of nonunion recommended by the Orthopedic and Rehabilitation Devices Panel on April 28, 1998 and required per FDA's letter dated June 3, 1998 (i.e., "nonunion is considered to be established when the fracture site shows no visibly progressive signs of healing").	
Orthologic 1000 bone Growth Stimulator Original PMA number P910066	DJ Orthopedics, LLC/Regentek	Received PMA in 1994 as a bone growth stimulator	

**Table B-2. List of External Bone Growth Stimulating Devices Used to Treat Nonunion Fractures (continued)**

Specific Device Name	Company Name	US Food and Drug Administration Status	References
OrthoLogic® 1000-CC Bone Growth Stimulator and OrthoLogic® 1000 (Medium) Bone Growth Stimulator Supplement to PMA number P910066	OrthoLogic, Corp. Phoenix, AZ 85034	Received PMA in 1997 for the OrthoLogic 1000 single closed coil soft pack bone growth stimulator in sizes XS, S, M, L, and XL and for the OrthoLogic 1000 Bone Growth Stimulator in the medium size. The devices, as modified, will be marketed under the trade names OL 1000-CC and OL 1000 (medium) and are indicated for the noninvasive treatment of an established nonunion acquired secondary to trauma, excluding vertebrae and all flat bones, where the width of the nonunion defect is less than one-half the width of the bone to be treated.	
OrthoLogic 1000-SC Bone Growth Stimulator Supplement to PMA number P910066	OrthoLogic Corporation Tempe, AZ 85281	Received PMA in 1998 for modifications to the sizes of the device. The device, as modified, will be marketed under the trade name OrthoLogic 1000-SC and is indicated for the noninvasive treatment of an established nonunion acquired secondary to trauma, excluding vertebrae and all flat bones. A nonunion is considered to be established when the fracture site shows no visibly progressive signs of healing.	
OrthoLogic™ 1000 and CC Bone Growth Stimulator Supplement to PMA number P910066	OrthoLogic Corporation Tempe, AZ 85281	Received PMA in 1998 for a change in the indications-for-use language to state "The OrthoLogic 1000 Bone Growth Stimulator is indicated for the noninvasive treatment of an established nonunion acquired secondary to trauma, excluding vertebrae and all flat bones. A nonunion is considered to be established when the fracture site shows no visibly progressive signs of healing"; and "The OrthoLogic CC Bone Growth Stimulator is indicated for the noninvasive treatment of an established nonunion acquired secondary to trauma, excluding vertebrae and all flat bones. A nonunion is considered to be established when the fracture site shows no visibly progressive signs of healing."	
Physio-Stim I & II Model 6000 & 7000 Original PMA number P850007	Orthofix, Inc.	Received PMA in 1986 as a non-invasive bone growth stimulator	
Physio-Stim® Lite Models 202L, 303L, 404L, 313L, and 314L Supplement to PMA number P850007	Orthofix, Inc. Richardson, TX 75081	Received PMA in 1997 for modifications to the design and labeling of the Physio-Stim® Bone Growth Stimulator. The device, as modified, is to be marketed under the trade name Physio-Stim® Lite and is indicated for the treatment of an established nonunion acquired secondary to trauma, excluding vertebrae and all flat bones, where the width of the nonunion defect is less than one-half the width of the bone to be treated.	

**Table B-2. List of External Bone Growth Stimulating Devices Used to Treat Nonunion Fractures (continued)**

Specific Device Name	Company Name	US Food and Drug Administration Status	References
<p>Physio-Stim Models 3202, 3302, 3313, 3314, 3315                      Supplement to PMA number P850007</p>	<p>Orthofix, Inc.                      McKinney, TX 75069</p>	<p>Received PMA in 2005 to modify the Physio-Stim Lite, Models 202L, 303L, 215L, 313L, as follows:</p> <ol style="list-style-type: none"> <li>1) change the power source from a 9-volt disposable battery to an 11.1-volt rechargeable</li> <li>2) change the user interface from a three color LED to a backlit LCD display</li> <li>3) change the circuit assembly from separate boards for the drive circuit and microcontroller to a single board</li> <li>4) add an optional personal data assistant (PDA) that may be used to set daily shutdown time for Orthofix personnel use only; and</li> <li>5) change the serial port cable on the compliance printer to an infrared port.</li> </ol> <p>The devices, as modified, will be marketed under the trade names Physio-Stim Models 3202, 3302, 3313, 3314, and 3315. The Physio-Stim Models are indicated for the treatment of an established nonunion acquired secondary to trauma, excluding vertebrae and all flat bones, where the width of the nonunion defect is less than one-half the width of the bone to be treated. A nonunion is considered to be established when the fracture site shows no visibly progressive signs of healing.</p>	

**Table B-2. List of External Bone Growth Stimulating Devices Used to Treat Nonunion Fractures (continued)**

Specific Device Name	Company Name	US Food and Drug Administration Status	References
<b>Capacitive coupling systems</b>			
OrthoPak Bone Growth Stimulator Original PMA number P850022	BioElectron	Received PMA in 1986	
OrthoPak Bone Growth Stimulator System Supplement to PMA number P850022	BioElectron (New Jersey), now part of EBI	<p>Received PMA in 1998 for the following modifications:</p> <ol style="list-style-type: none"> <li>1) The "tombstone" - No Part Number               <ol style="list-style-type: none"> <li>a) Change of indication</li> <li>b) Minor grammatical corrections of labeling</li> </ol> </li> <li>2) The Physician Manual - Part Number 380-0001-0001-844               <ol style="list-style-type: none"> <li>a) Change of indication</li> <li>b) Removed all references to "Snap-on Electrodes" (obsolete)</li> <li>c) Reduced the number of sizes of foam spacers provided from 2 to 1</li> <li>d) Increased the number of leads provided from 2 to 3 (20" lead added)</li> <li>e) Minor grammatical corrections of labeling</li> </ol> </li> <li>3) The Patient Manual - Part Number 380-0002-0001-844               <ol style="list-style-type: none"> <li>a) Change of indication</li> <li>b) Removed all references to "Snap-on Electrodes" (obsolete)</li> <li>c) Reduced the number of sizes of foam spacers provided from 2 to 1</li> <li>d) Increased the number of leads provided from 2 to 3 (20" lead added)</li> <li>e) Added the section "Electrode Retainers" (copied   from Physician Manual)</li> <li>f) Minor grammatical corrections</li> </ol> </li> </ol> <p>The indication change listed above in each section is as follows: removal of the reference to a 9 month clinical study time in the approved labels ("A non-union is considered to be established when a minimum of 9 months has elapsed since injury and the fracture site shows no visible progressive signs of healing for a minimum of 3 months - no change in fracture callus") and to insert language as suggested in the FDA letter of June 3, 1998. ("A nonunion is considered to be established when the fracture site shows no visible progressive signs of healing.")</p>	(15)

**Table B-2. List of External Bone Growth Stimulating Devices Used to Treat Nonunion Fractures (continued)**

Specific Device Name	Company Name	US Food and Drug Administration Status	References
<b>Direct current systems</b>			
OsteoStim (R) Original PMA number P790005	Electro-Biology, Inc.,	Received PMA in 1980 as an invasive osteogenesis stimulator	
OrthoGen®/OsteoGen™ Implantable Bone Growth Stimulator Supplement to PMA number P790005	Electro-Biology, Inc., Parsippany, NJ 07054-1079	Received PMA in 1998 for revision of the indications and usage section of the labeling to include the definition of nonunion recommended by the Orthopedic and Rehabilitation Devices Panel on April 28, 1998 and required per FDA's letter dated June 3, 1998 (i.e., "a nonunion is considered to be established when the fracture site shows no visibly progressive signs of healing").	
<b>Shock wave systems:</b> No shock wave systems have received FDA approval for the treatment of nonunion fractures. The following are the shock wave devices that are approved by the FDA for other orthopedic indications.			
HealthTronics OssaTron® Original PMA number P990086	HealthTronics, Inc. Marietta, GA 30062	Received PMA in 2000 for the OssaTron. The device is indicated for use for performing extracorporeal shock wave (ESW) treatment in patients with chronic proximal plantar fasciitis that has failed to respond to conservative treatment. Chronic proximal plantar fasciitis is defined as pain in the area of the insertion of the plantar fascia on the medial calcaneal tuberosity that has persisted for 6 months or more.	
Siemens SONOCUR® Basic Original PMA number P010039	Siemens Medical Solutions USA, Inc. Iselin, NJ 08830	Received PMA in 2002 for the Siemens SONOCUR Basic. The Siemens SONOCUR Basic is a non-surgical alternative for the treatment of chronic lateral epicondylitis (commonly referred to as tennis elbow) for patients with symptoms of chronic lateral epicondylitis for 6 months or more and a history of unsuccessful conservative treatments.	
Orthospec™ Extracorporeal Shock Wave Therapy Device Original PMA number P040026	Medispec, Ltd. Germantown, MD 20874	Received PMA in 2005 for the Orthospec Extracorporeal Shock Wave Therapy Device. The device is indicated for the treatment of Proximal Plantar Fasciitis with or without heel spur in patients 18 years of age or older. The Orthospec™ Extracorporeal Shock Wave Therapy is a non-invasive alternative method for patient with symptoms of proximal plantar fasciitis for 6 months or more and a history of unsuccessful conservative therapies to relieve heel pain. proximal plantar fasciitis is defined as heel pain in the area of the insertion of the plantar fascia on the plantar calcaneal tuberosity.	

## **Appendix C. Evidence Tables for Key Question 4**

**Table C-1. Intermediate and Patient-Reported Outcomes of Treatment for Nonunion Fractures**

Outcome	Definition of successful treatment	References
Radiographic evidence of bone bridging	Three of four cortices had to be bridged in long bones	(9-11,23)
	All four radiographic views showed bony trabeculae spanning the full width of the nonunion gap	(16,20,119)
	Two planes showing bony trabecular crossing at least half of the width of the defect	(116)
	The fracture line was bridged with callus bone in non-long bones; loss of fracture line	(9,11,119)
	Trabecular bridging of at least 80% of the fracture in the case of cancellous fractures such as scaphoid fractures	(10,11)
Pain at site of nonunion	Absence of pain	(9)
	No more than slight tenderness	(116)
Pain on weight-bearing	No pain on weight-bearing	(9)
	Less than severe pain at the fracture site on weight-bearing	(23)
Bone healing index	Patients were judged as healed when the numerical total of the radiographic score (1: no bone bridging to 5: cortical bridging) and clinical score (1: pain with rest to 5: normal function) was 8 or more	(24)
Limb function	Return of normal limb function	(9,119)
	Full weight-bearing	(23)
Retreatment	No retreatment	(23)



## **Appendix D. Evidence Tables for Key Question 6**

**Table D-1. Excluded Studies for Key Question 6**

Reference	Type of device or orthobiologic	Reason for exclusion
Jones et al. 2005(166)	Orthobiologics – hBMP was prepared by the authors	Study examined a single patient with a chronic nonunion of a proximal pole fracture of the scaphoid treated by curettage of the nonunion, single K-wire fixation, and implantation of 50 mg of human BMP followed by 12 weeks of cast immobilization. Excluded for having less than 20 patients.
Delloye et al. 2004(167)	Orthobiologics rhBMP-2 (Genetics Institute) and rhBMP-7 (Osigraft, Stryker)	Study examined 5 patients treated with bone resection, rhBMPs, and allograft for malignant bone tumor. Excluded for having less than 20 patients.
Lerner et al. 2004(165)	Ultrasound Exogen	Study examined 17 patients treated with surgical skeletal stabilization and low-intensity pulsed ultrasound for delayed unions of the long bones associated with high-energy fractures. Excluded for having less than 20 patients.
Luchetti 2004(160)	Orthobiologics Carbonated hydroxyapatite (Norian SRS)	Study examined 6 patients treated with corrective osteotomy and carbonated hydroxyapatite for malunited distal radius fracture. Excluded for not being nonunion fractures.
Pigozzi et al. 2004(164)	Ultrasound Exogen	Study examined 15 patients treated with low-intensity pulsed ultrasound for fracture nonunions at various sites. Excluded for having less than 20 patients.
Saltzman et al. 2004(168)	Pulsed electromagnetic fields EBI Bone Healing System	Study examined 19 patients treated with PEMF for delayed unions after foot and ankle arthrodeses. Excluded for having less than 20 patients.
Nishikawa et al. 2003(169)	Orthobiologics No name provided, the bone paste has been available in Japan since 2000	Study reported on use of calcium phosphate paste and endoscopic surgery to treat delayed unions and nonunions. Technical paper, no patient data.

**Table D-1. Excluded Studies for Key Question 6 (continued)**

Reference	Type of device or orthobiologic	Reason for exclusion
Kloen et al. 2002(170)	Orthobiologics	Study examined 21 patients with a delayed union or nonunion to determine the presence of BMPs during the development of a fracture nonunion. Technical paper, no treatment data.
McLee et al. 2002(158)	Orthobiologics Bone substitute (OsteoSet-T, Wright Medical Technology)	Study examined 16 patients treated with debridement, surgical stabilization, and medical grade alpha-hemihydrate calcium sulfate impregnated with tobramycin antibiotic for infected nonunions of long bones. Excluded for having less than 20 patients.
Ikeda et al. 1999(171)	Shock wave – custom made	Study examined 6 patients treated with a custom-made extracorporeal shock wave generator for delayed or nonunion fractures. Excluded for having less than 20 patients.
Rosenthal et al. 1999(172)	Orthobiologics Demineralized bone implants prepared by the authors	Study examined 8 patients treated with debridement, surgical fixation, and demineralized bone implants for fracture nonunions. Excluded for having less than 20 patients.
SattarSyed et al. 1999(173)	Pulsed electromagnetic fields – custom made	Study examined 19 patients treated with pulsed electromagnetic fields for delayed or nonunion of long bones. Excluded for having less than 20 patients.
Wilkins et al. 1999(159)	Orthobiologics Combination of AlloGro (AlloSource) and OsteoSet now marketed as AlloMatrix (Wright Medical Technology)	Study examined 11 patients treated with a combination product of bioassayed, demineralized bone matrix (AlloGro) and calcium sulfate pellets (OsteoSet) for long bone nonunions. Excluded for having less than 20 patients.
Abeed et al. 1998(174)	Capacitively coupled electrical stimulation – device not named	Study examined 16 patients treated with capacitively coupled electrical stimulation for long bone nonunions. Excluded for having less than 20 patients.
Frankel 1998(175)	Ultrasound Exogen	The data for patients with nonunion fractures is more completely reported in a later publication.(10)

**Table D-1. Excluded Studies for Key Question 6 (continued)**

Reference	Type of device or orthobiologic	Reason for exclusion
Meng-Hai et al. 1996(176)	Orthobiologics – hBMP were prepared by the authors	Study examined 16 patients treated with debridement, internal fixation, and a mixture of bovine bone morphogenetic protein and plaster of Paris for femoral shaft nonunions. Excluded for having less than 20 patients.
Holmes 1994(177)	Pulsed electromagnetic fields – no device name	Study examined 9 patients treated with pulsed electromagnetic fields for delayed unions and nonunions of the fifth metatarsal. Excluded for having less than 20 patients.
Schleberger and Senge 1992(178)	Shock wave	Study examined only 4 patients.

**Table D-2. Included Studies of Ultrasound Treatment of Nonunion Fractures Addressing Key Question 6**

Reference	Study Design / Purpose / USPSTF Study Quality Rating	Intervention / Outcomes	Demographics	Results	Comments
Nolte et al. 2001(9)	<p>Prospective Case series</p> <p>Purpose: Evaluate the effect of low-intensity ultrasound for the treatment of established nonunions in a consecutively enrolled patient population from various trauma departments.</p> <p>Level II-3</p> <p>Internal validity criteria: fair</p> <ol style="list-style-type: none"> <li>1. yes</li> <li>2. yes</li> <li>3. yes</li> <li>4. no (outcome assessment not blinded)</li> <li>5. yes</li> <li>6. yes</li> <li>7. yes</li> </ol>	<p>Sonic Accelerated Fracture Healing System (Exogen)</p> <p>Patients applied the device for a daily 20-minute treatment in their homes. Compliance was defined as the device being used 75% of the time.</p> <p>Immobilization (cast, wiring, internal or external fixation) was continued according to previous treatment. Treatment was continued until the treating surgeon declared the nonunion healed.</p> <p>Bones treated:                      5 femurs, 10 tibiae/ fibulae                      1 humerus, 5 ulnae/ radii                      5 scaphoids, 1 ankle                      1 clavicle, 1 metatarsal</p> <p>Outcomes: Nonunions were considered clinically healed when pain was absent and weight-bearing did not cause pain, or normal limb function had returned. Radiographic evidence of bone bridging.</p> <p>Patients were examined at regular 6 to 8 week intervals.</p>	<p>n = 41 nonunions in 39 enrolled patients, 29 patients completed the study; 4 patients were excluded for lack of compliance or early withdrawal, 8 nonunions in 7 patients were excluded because there was less than 90 days from last operative procedure to ultrasound therapy.</p> <p>Mean age of 47 years with a range of 18 to 90 years.</p> <p>Sex: 12 F 17 M</p> <p>Inclusion: nonunion fracture (minimum of 6 months post fracture) and healing had not progressed for a minimum of 3 months before ultrasound treatment, and surgery was not currently an option.</p> <p>Exclusion: less than 90 days from last operative procedure.</p> <p>16 patients were smoking or had stopped smoking, 2 infected nonunions.</p> <p>Initial treatments:                      8 conservative treatment                      14 osteosynthesis                      5 intramedullary nail                      2 external fixation</p>	<p>Healing was demonstrated in 86% of patients (25 of 29) with an average healing time of 152 days. Statistically significant (<math>p &lt; 0.0001</math>) when compared to an assumed rate of 5% healing for the prior failed treatment period.</p> <p>One patient was noncompliant and not used in the analysis of results but was included in the intent-to-treat analysis.</p> <p>Age and method of fixation were not a factor in healing rate (no statistically significant differences between age groups or type of fixation used with the ultrasound therapy).</p> <p>Hypertrophic (83% healed) and atrophic/oligotrophic (88%) healed at the same rate, no statistically significant difference. Smoking did reduce healing rate (<math>p = 0.05</math>).</p> <p>10 of 10 (100%) tibiae, 4 of 5 (80%) femurs, 4 of 5 (80%) radii/ulnae, and 4 of 5 (80%) scaphoids healed, 1/1 (100%) humerus healed. The clavicle and metatarsal healed; the ankle did not.</p>	<p>6 of the patients were 65 years of age or over. All 6 patients showed healed nonunions. Study reported individual patient data which allowed abstraction of data for patients 65 and over.</p>

**Table D-2. Included Studies of Ultrasound Treatment of Nonunion Fractures Addressing Key Question 6 (continued)**

Reference	Study Design / Purpose / USPSTF Study Quality Rating	Intervention / Outcomes	Demographics	Results	Comments
			<p>Secondary procedures:                      6 bone graphs (only one with previous conservative treatment)                      4 intramedullary nail                      2 external fixation</p>	<p>According to the authors, the intent-to-treat analysis showed 80% healing (33 of 41 cases healed). No statistical significance reported for intent-to-treat analysis. However, the authors added the eight cases of the excluded group who had surgery within 90 days of ultrasound treatment to the healed cases which could inflate the ultrasound results. These eight cases should not have been enrolled in the study and should not be considered. Therefore, on an intent-to-treat basis 25 of 33 healed (76%).</p> <p>14 of the 18 (78%) patients with no secondary procedures prior to ultrasound therapy healed within an average of 156 days. All 11 of the patients who received a secondary procedure prior to ultrasound therapy healed.</p>	

**Table D-2. Included Studies of Ultrasound Treatment of Nonunion Fractures Addressing Key Question 6 (continued)**

Reference	Study Design / Purpose / USPSTF Study Quality Rating	Intervention / Outcomes	Demographics	Results	Comments
Mayr et al. 2002(1)	<p>Prospective Case series</p> <p>Purpose: determine the effectiveness of low-intensity ultrasound treatment on nonunions.</p> <p>Level II-3</p> <p>Internal validity criteria: low</p> <p>1. yes</p> <p>2. yes</p> <p>3. no (outcome assessment not blinded)</p> <p>4. yes</p> <p>5. yes</p> <p>6. no (did not report pain or weight-bearing)</p> <p>7. no (no statistical analysis is reported)</p>	<p>Exogen</p> <p>Patients applied the device for a daily 20-minute treatment in their homes. Patients were removed from the study for inadequate compliance.</p> <p>64 Delayed unions and 36 nonunions treated:</p> <p>2 clavicles</p> <p>5 humeri</p> <p>12 radii/ulnae</p> <p>16 scaphoids</p> <p>14 femurs</p> <p>44 tibias</p> <p>2 fibulas</p> <p>2 other</p> <p>Outcomes: Healing rate and time to healing. Bone healing was determined by radiology methods. No specific follow-up periods were used in this study.</p>	<p>n = 100 (not including 21 patients who were excluded for discontinuing treatment)</p> <p>Mean age of 44 years with a SEM of 2 years.</p> <p>Sex: 37 F 63 M</p> <p>Inclusion: delayed union (120 days post-fracture) and nonunion (240 days post-fracture) fractures. Bone maturation, clinical stability of the fracture, vitality of the fragment ends, freedom from infection, no change in therapy within 90 days of ultrasound therapy.</p> <p>Exclusion: infection, instability, defect pseudarthrosis, change in therapy within 90 days of ultrasound therapy, fracture gap covered by ultrasound reflective surface.</p> <p>Initial and prior treatments: 29 patients with one or more spongioplasties; 41 of 44 tibia patients had prior surgery with instrumentation.</p>	<p>55 of 64 (86%) of delayed unions healed in an average of 142 days. 31 of 36 (86%) of nonunions healed in an average of 171 days. Statistical analysis was not reported.</p> <p>% healed:</p> <p>12 of 16 (75%) scaphoid</p> <p>9 of 14 (64%) femur</p> <p>43 of 44 (96%) tibia</p> <p>Scaphoid fractures healed better with initial lower arm cast.</p> <p>Smoking habits did not affect healing rates.</p>	<p>Healing rates were not analyzed by age groups, therefore the relevance of this study to the Medicare population is unknown.</p> <p>Only radiographic evidence of bone bridging was reported.</p> <p>Other outcome measures such as pain, weight-bearing, and return to normal activities were not reported.</p>

**Table D-2. Included Studies of Ultrasound Treatment of Nonunion Fractures Addressing Key Question 6 (continued)**

Reference	Study Design / Purpose / USPSTF Study Quality Rating	Intervention / Outcomes	Demographics	Results	Comments
Mayr et al. 2000(10)	Retrospective Case series – registry data Purpose: to evaluate registry data on the effects of ultrasound treatment on nonunions. Level II-3 Internal validity criteria: low 1. no (retrospective data collection and analysis) 2. yes 3. no (outcome assessment not blinded) 4. yes 5. yes 6. no (did not report pain or weight-bearing) 7. no (no statistical analysis is reported)	Sonic Accelerated Fracture Healing System (Exogen) Patients applied the device for a daily 20-minute treatment in their homes. Compliance was not reported. Delayed unions/nonunions treated: 38/ 10 clavicles 54/ 48 humeri 52/ 22 radii 43/ 0 ulna 79/ 24 scaphoids 98/ 66 femurs 380/ 120 tibias 27/ 0 fibula 39/ 0 ankle 84/ 18 metatarsals 26/ 20 feet 31/ 38 other. Healing rate and time to healing. Bone healing was defined as 3 cortices bridged in 2 x-ray planes or trabecular bridging of at least 80% of the fracture in the case of cancellous fractures such as scaphoid fractures. No specific follow-up periods were used in this study.	n = 1317 Age and sex information were not reported. Inclusion: delayed union (3 to 9 months post-fracture) and nonunion (9 months post-fracture) fractures. Exclusion: not reported. Healing rates were assessed for renal disease, vascular insufficiency, diabetes, osteoporosis, and local infection. Initial and prior treatments: delayed union – 442 surgery (average of 1.3 operations), 507 conservative nonunions – 213 surgery (average of 1.7 operations), 153 conservative. Concurrent fixation or other treatments not reported.	91% of delayed unions healed in an average of 129 days. 86% of nonunions healed in an average of 152 days. Statistical analysis was not reported. % healed – delayed unions/ nonunions: 95% / 80% clavicle 76% / 69% humerus 94% / 95% radius 81% / ---% ulna 94% / 100% scaphoid 87% / 86% femur 92% / 88% tibia 96% / ---% fibula 92% / ---% ankle 96% / 78% metatarsal 91% / 90% foot 97% / 89% other	Healing rates were analyzed by age groups. Peak incidence of delayed and nonunions occurred between 30 and 50 years with an additional peak at age 70 for delayed unions. Healing rates declined with age. Up to age 70 the healing rate for delayed unions was 89% to 99%, but after age 70 the rate dropped to 85%. For nonunions, the healing rate consistently declined from 97% at 20 years to 71% at 70 years. The report provides a great deal of analysis especially with regard to the effect of age and co-morbidities on healing rates but without reporting statistical significance. However, only the

**Table D-2. Included Studies of Ultrasound Treatment of Nonunion Fractures Addressing Key Question 6 (continued)**

Reference	Study Design / Purpose / USPSTF Study Quality Rating	Intervention / Outcomes	Demographics	Results	Comments
					overview of the analysis is provided and detailed data (mean ages, numbers of patients in each age and co-morbidity group, etc.) are not reported.



**Table D-3. Included Studies of Pulsed Electromagnetic Fields Treatment of Nonunion Fractures Addressing Key Question 6**

Reference	Study Design / Purpose / USPSTF Study Quality Rating	Intervention / Outcomes	Demographics	Results	Comments
Simonis et al. 2003(11)	<p>Prospective double-blind randomized trial with placebo controlled device</p> <p>Purpose: determine the effect of pulsed electromagnetic stimulation on the treatment of established nonunions.</p> <p>Level I</p> <p>Internal validity criteria: fair</p> <ol style="list-style-type: none"> <li>1. no (method of randomization not reported)</li> <li>2. yes</li> <li>3. yes</li> <li>4. yes</li> <li>5. yes</li> <li>6. no (did not consider pain and weight-bearing)</li> </ol>	<p>Device name not reported.</p> <p>Prior to randomization, all patients were given an oblique fibular osteotomy, followed by a unilateral external fixator with compression (active treatment). Treatment group received electrical stimulation from an active device. A pulsed electric current was delivered through two large external coils applied directly over the fracture and in contact with the skin. The control group received an identical device but current was passed through a</p>	<p>n = 34</p> <p>Mean of 32 years with a range of 16 to 61.</p> <p>Sex: F4 M 30</p> <p>Inclusion: tibial shaft fractures un-united at least 1 year after the initial fracture, no metal implant bridging the non-union gap, no radiological progression of fracture union in the 3 months prior to PEMF treatment. Patients were not excluded for active infection.</p> <p>Exclusion: none reported.</p> <p>21 of the patients were smokers.</p> <p>Initial and prior treatments: Patients had undergone an average of 4 surgical procedures before presentation in the clinic. 23 open fractures, 30 from high velocity road traffic accidents, 6 infected, 16 atrophic, 18 hypertrophic.</p>	<p>16 of 18 (89%) active treatment fractures healed in an average of 15.3 weeks (10 to 20 weeks). Only 8 of 16 (50%) dummy treatment fractures healed.</p> <p>Because of an imbalance in smoking habits between groups, a comparison was made for smokers and for non-smokers separately, and then an overall significance level was obtained using logistic regression. 13 of 16 patients in the control group were smokers and 8 of 18 patients in the active group were smokers.</p> <p>The unadjusted odds ratio comparing the active to dummy group was 8.0 (95% CI of 1.5-41, p = 0.02. Fisher's exact test). When the overall results were adjusted for smoking, the association was weaker and not statistically significant, odds ratio of 5.4 with 95% CI of 0.85 to 34, p = 0.07.</p> <p>Smokers had a lower healing rate (75% active and 46% dummy) but was not statistically different from nonsmokers.</p>	<p>This study has limited relevance to the Medicare population because none of the patients were 65 years or over.</p> <p>Only radiographic evidence of bone bridging was reported. Other outcome measures such as pain, weight-bearing, and return to normal activities were not reported.</p>

**Table D-3. Included Studies of Pulsed Electromagnetic Fields Treatment of Nonunion Fractures Addressing Key Question 6 (continued)**

Reference	Study Design / Purpose / USPSTF Study Quality Rating	Intervention / Outcomes	Demographics	Results	Comments
	7. yes	<p>small secondary coil not in contact with the leg. Both groups used the devices for a minimum of 14 hours a day and remained strictly non-weight-bearing. Treatment lasted for 6 months.</p> <p>Bones treated: Tibia only; 16 atrophic and 18 hypertrophic.</p> <p>Outcomes: Radiological signs of bone bridging: loss of fracture gap, cortical bridging, trabecular bridging. Followup of 6 months.</p>		Further adjustments for the number of previous surgical procedures did not change the odds ratio.	

**Table D-3. Included Studies of Pulsed Electromagnetic Fields Treatment of Nonunion Fractures Addressing Key Question 6 (continued)**

Reference	Study Design / Purpose / USPSTF Study Quality Rating	Intervention / Outcomes	Demographics	Results	Comments
Sharrard 1990(12)	<p>Prospective double-blind randomized controlled trial</p> <p>Purpose: To provide evidence of the true effect of pulsed electromagnetic fields on delayed union tibial fractures by comparing immobilization and active electromagnetic stimulation with similar immobilization and dummy stimulation in a double-blind trial.</p> <p>Level I</p> <p>Internal validity criteria: good</p> <p>1. yes (the method of randomization was not reported in the</p>	<p>Device name was not reported in the publication. A personal communication from EBI indicated that the device used in this trial was the EBI Bone Healing System.(130)</p> <p>A full-leg plaster cast was applied.</p> <p>The active device pulsed current through coils.</p> <p>Patients were instructed to bear no weight on the cast and to use the device for 12 hours a day.</p> <p>Treated for 12 weeks.</p> <p>Bones treated: all tibia.</p> <p>Outcomes: Radiological signs of bone bridging. Assessment was</p>	<p>n = 45; 20 active and 25 control</p> <p>Active group: mean age of 35 years with a range of 18 to 84.</p> <p>Control: mean age of 45 years with a range of 18 to 76.</p> <p>There was a significant difference in the age distribution.</p> <p>Sex: Active group - F6 M14, Control group - F7 M18</p> <p>Inclusion: 18 years or older with a fracture of the tibial shaft, closed or compound, not less than 5 cm from the ankle or knee, which had not united after at least 16 weeks and not more than 32 weeks of treatment (immobilization in a long-leg plaster cast required). After reduction, the fracture ends must be apposed over at least 50% of their surface, to be in acceptable alignment and to have no distraction. Two or more of the risk factors for developing a nonunion (moderate or severe displacement or angulation, moderate or severe comminution, or a moderate or severe wound) had to have been present for inclusion</p> <p>Exclusion: Patient who had undergone surgical procedures other than those required for the initial management of a</p>	<p>Orthopaedic surgeon's assessment</p> <p>- Active: 9 of 20 (45%) healed.</p> <p>Control: 3 of 25 (12%) healed.</p> <p>p = 0.02 based on Fisher's exact test.</p> <p>Pain was reduced in both groups with no statistically significant differences between groups in any of the clinical criteria.</p>	<p>The authors report that an analysis using categorical modeling indicated that age was not a factor in the outcome of treatment.</p> <p>The authors had originally hoped for 100 patients, but after 6 years the multicenter trial could only enroll 51 patients and a decision was made to stop the trial.</p> <p>Since the fractures were evaluated after only 12 weeks of treatment, the healing rates may not be comparable to other studies.</p> <p>Follow-up data were provided by the sponsoring company (EBI) and are discussed in the text.(13,179)</p> <p>Clinical assessment did not match the radiological assessment. More than half of both groups did not show any movement of the fracture, a clinical sign that the fracture had healed. Movement indicates failure but lack of movement does not indicate a healed union.</p>

**Table D-3. Included Studies of Pulsed Electromagnetic Fields Treatment of Nonunion Fractures Addressing Key Question 6 (continued)**

Reference	Study Design / Purpose / USPSTF Study Quality Rating	Intervention / Outcomes	Demographics	Results	Comments
	<p>article, a personal communication from EBI indicated that an acceptable randomization procedure was used)</p> <p>2. yes 3. yes 4. yes 5. yes 6. yes 7. yes</p>	<p>blinded to treatment group. Clinical assessment based on fracture movement, pain, and tenderness. All patients were assessed at 12 weeks.</p>	<p>wound and open reduction (if necessary) of the initial fracture were excluded, treatment by internal or external fixation, gap greater than 0.5 cm, severe generalized disease, receiving systemic steroid treatment, bone disease (Paget's), severely atrophic bone, and fractures with marked hypertrophy.</p> <p>Initial and prior treatments: patients with prior surgical procedures for treatment of the delayed union were excluded. The trial was limited to fractures of the tibial shaft that had received only conservative management.</p>		

**Table D-3. Included Studies of Pulsed Electromagnetic Fields Treatment of Nonunion Fractures Addressing Key Question 6 (continued)**

Reference	Study Design / Purpose / USPSTF Study Quality Rating	Intervention / Outcomes	Demographics	Results	Comments
Ito and Shirai 2001(116)	Retrospective Case Series Purpose: Assess the clinical efficacy of PEMF therapy in treating nonunion tibial fractures Level II-3 Internal validity criteria: low 1. no (wide range of nonunion characteristics, retrospective data collection and analysis) 2. no (patients not listed as consecutive) 3. no (method of patient selection is not reported which allows for the possibility that results from dropouts were not reported)	Device name not reported An electric current was generated in the bone by a pair of externally placed, oval, air-cored electromagnets. The tibia was immobilized with a long plaster cast. All patients were instructed to use the device for 8 hours each day and not to bear weight. Bones treated: tibia only Outcomes: Radiological signs of bone bridging. Patients were assessed every 6 weeks. Compliance not reported	n = 30 Mean age of 43 years with a range of 23 to 71 years Sex: F6 M24 Inclusion: delayed union or nonunion of the tibia according to the criteria of the American Orthopedic Group. Exclusion: none reported Initial and prior treatments: almost 80% had at least one surgical procedure, the average number of operations was 1.8 with 2 patients being operated on 5 times. 18 patients still had surgical hardware. Duration of disability was 6 months to 8 years with an average of 1.5 years.	25 of 30 cases (83%) achieved bony union. Mean time to healing was 8.6 months with a range of 4 to 16 months. No statistical analysis was reported. Four of six patients with necrotic nonunions did not heal.	Three of the patients were 65 or over. 2 of the 3 patients healed. Only radiographic evidence of bone bridging was reported. Other outcome measures such as pain, weight-bearing, and return to normal activities were not reported.

**Table D-3. Included Studies of Pulsed Electromagnetic Fields Treatment of Nonunion Fractures Addressing Key Question 6 (continued)**

Reference	Study Design / Purpose / USPSTF Study Quality Rating	Intervention / Outcomes	Demographics	Results	Comments
	4. no (assessment not masked) 5. yes 6. no (pain and weight-bearing not reported) 7. no (no statistical analysis)				

**Table D-3. Included Studies of Pulsed Electromagnetic Fields Treatment of Nonunion Fractures Addressing Key Question 6 (continued)**

Reference	Study Design / Purpose / USPSTF Study Quality Rating	Intervention / Outcomes	Demographics	Results	Comments
Adams et al. 1992(126)	Retrospective Case Series Purpose: assess healing of scaphoid nonunions treated with PEMF. Level II-3 Internal validity criteria: low 1.no (retrospective data collection and analysis) 2.no (did not include dropouts in analysis) 3.yes 4.no (assessment of healing not masked) 5.yes 6.no (did not report pain or weight-bearing) 7.no (no statistical analysis)	Device name not reported External PEMF coils were centered over the scaphoid and attached to either a long arm thumb spica cast or a short arm thumb spica cast. All patients were treated until the fracture healed or for at least a 3-month period. Bones treated: Scaphoid only Outcomes: Radiological signs of bone bridging and return to work. Followup: 1 to 33 months, mean of 8.5 months. Compliance not reported.	n = 54 Mean age of 26 years with a range of 14 to 46 years Sex: F3 M51 Inclusion: scaphoid nonunion fracture of at least 6 months duration and no operation had been performed during or just before initiation of PEMF treatment. Exclusion: displacement of significant angulation at the nonunions, arthritis of the periscaphoid joint, carpal instability. Initial and prior treatments: 10 patients had one previous bone-graft operation, 2 patients had previous operations. Average time from injury to treatment was 35 months, with a range of 6 to 241 months.	37 of the 54 (69%) patients healed in a mean of 4 months with a range of 2.5 to 9 months. No statistical analysis was reported. 35 of the healed patients returned to their pre-injury work.	This study has limited relevance to the Medicare population because none of the patients were 65 years or over.

**Table D-3. Included Studies of Pulsed Electromagnetic Fields Treatment of Nonunion Fractures Addressing Key Question 6 (continued)**

Reference	Study Design / Purpose / USPSTF Study Quality Rating	Intervention / Outcomes	Demographics	Results	Comments
Garland et al. 1991(27)	<p>Prospective Case Series</p> <p>Purpose: to prospectively evaluate the long-term safety and effectiveness of PEMF therapy for fracture nonunions and failed arthrodeses and to determine the effective treatment dosage ranges (hours/day) to achieve union, documented both clinically and radiographically.</p> <p>Level II-3</p> <p>Internal validity criteria: fair</p> <ol style="list-style-type: none"> <li>1. yes</li> <li>2. yes</li> <li>3. no (28% dropout)</li> <li>4. yes (blinding of assessment was not)</li> </ol>	<p>Device name was not reported in the publication. A personal communication from Orthofix indicated that the device used in this trial was the Physio-Stim Bone Growth Stimulator.(7)</p> <p>Patients were asked to use the PEMF device for a minimum of 6 months or until the nonunion healed. Immobilization, bracing and weight-bearing decisions were left to the judgment of the treating physician. A minimum of 12 weeks of treatment was considered</p>	<p>n = 181 enrolled, 139 completed treatment</p> <p>Females n = 63: mean of 49 years with a range of 14 to 83.</p> <p>Males n = 118: mean of 38 years with a range of 13 to 73.</p> <p>Inclusion: nonunion fracture that failed to demonstrate both clinical and radiographic union at least 9 months after the original injury. Established nonunions that underwent a bone graft or internal fixation were candidates for PEMF treatment if evidence of healing was not apparent by 3 months after the procedure or if no progression of healing occurred during the 3-month period.</p> <p>Exclusion: none reported.</p> <p>Average duration of nonunion was 2.6 years (9 months to 42 years).</p> <p>Initial and prior treatments: prior surgical intervention has been performed on 81% of the fractures, fractures had an average of two previous surgeries, 113 internal fixation and bone grafting, 26 external fixation.</p>	<p>% healed: Long bones 83%, short bones 81%. Nonunion duration of less than 12 months 83%, 1 to 10 year duration 82%, 10 years or greater 44%.</p> <p>87% femur, 74% tibia, 88% fibula, 100% humerus, 100% ulna, 83% radius, 77% scaphoid, 60% ankle, 80% metatarsal, and 73% other</p> <p>The average time to healing was not reported.</p> <p>Statistical analysis was based on confidence interval estimates. No statistically significant differences in success rates were observed among the usage strata above 3 hours per day. The success rate in the 13 patients averaging less than 3 hours daily use (36%) was significantly lower than that observed in the 126 patients averaging more than 3 hours (80%).</p> <p>In the 4-year subgroup, 92% of nonunions were healed. Chi-square analysis indicated no statistically significant difference between the 4-year healing rate and the original rate.</p>	<p>Union occurred in 90 of 107 (84%) patients less than 60 years of age and in 18 of 28 (64%) patients 60 years of age or older. No other information relative to age was reported.</p>



**Table D-3. Included Studies of Pulsed Electromagnetic Fields Treatment of Nonunion Fractures Addressing Key Question 6 (continued)**

Reference	Study Design / Purpose / USPSTF Study Quality Rating	Intervention / Outcomes	Demographics	Results	Comments
	<p>reported in the article but a personal communication from Orthofix indicated that the assessment was blinded)(7)</p> <p>5. yes 6. yes 7. no (dropouts were not considered in calculating healing rate)</p>	<p>necessary to complete treatment. Patients received treatment at 74 institutions.</p> <p>Bones treated: 15 femurs, 50 tibias, 8 fibulas, 7 humeri, 10 ulnae, 6 radii, 13 scaphoids, 10 ankles, 5 metatarsals, 11 other</p> <p>Outcomes: Radiological signs of bone bridging. Patients were determined to be clinically healed if they had no cast, no motion at the nonunion fracture site, and no or minimal pain at the nonunion site. Follow-up periods beyond the minimum 12 weeks of treatment were</p>			

**Table D-3. Included Studies of Pulsed Electromagnetic Fields Treatment of Nonunion Fractures Addressing Key Question 6 (continued)**

Reference	Study Design / Purpose / USPSTF Study Quality Rating	Intervention / Outcomes	Demographics	Results	Comments
		not reported. A subgroup was evaluated 4 years after treatment. Device usage was measured and a dose response relationship calculated.			

**Table D-3. Included Studies of Pulsed Electromagnetic Fields Treatment of Nonunion Fractures Addressing Key Question 6 (continued)**

Reference	Study Design / Purpose / USPSTF Study Quality Rating	Intervention / Outcomes	Demographics	Results	Comments
Traina et al. 1991(14)	<p>Retrospective Case Series with a comparison group</p> <p>Purpose: Attempt to quantify the effect of PEMF on healing of nonunion fractures</p> <p>Level II-3</p> <p>Internal validity criteria: low</p> <ol style="list-style-type: none"> <li>no (retrospective data collection)</li> <li>no (groups differed in mean age and types of bone treated)</li> <li>yes</li> <li>no (not blinded)</li> <li>yes</li> <li>yes</li> <li>yes</li> </ol>	<p>IGEA stimulator (Igea, Carpi, Italy)</p> <p>Patients were asked to use the PEMF device for 8 hours a day until they healed. A minimum of 12 months of treatment was considered necessary before the treatment could be considered a failure. The control group was treated simultaneously by the same group of surgeons.</p> <p>All patients maintained their current immobilization.</p> <p>Bones treated: Treated – 11 femur, 20 leg, 1 humerus, 8 forearm, 1 metatarsal,</p>	<p>Treated group: n = 41, average age of 38 years, 5 F, 36 M, 18 infected.</p> <p>Control group: n = 26, average age of 46 years, 5 F, 21 M, 10 infected.</p> <p>Inclusion: nonunion fracture that failed to demonstrate both clinical and radiographic union at least 9 months after the original injury. Had not been operated on in the past 3 months. Immobilization had not been changed. Showed no signs of progression toward healing.</p> <p>Exclusion: none reported.</p> <p>Average duration of nonunion was 26 months (9 months to 180 months) in the control group and 21 months (9 months to 192 months).</p> <p>Initial and prior treatments: The average number of previous surgical interventions was 1.4 in the control group and 1.6 in the treated group. Three control patients and three treated patients had never been operated on. Control group: 9 plates, 6 medullary nails, 2 external fixation, 13 autogenous bone grafts; Treated group: 5 plates, 10 medullary nails, 7 external fixation, 17 casts, autogenous bone graft not reported for this group.</p>	<p>Treated group: 36 of 41 (88%) healed in an average of 5.7 months; 20 of 23 (87%) non-infected nonunions healed and 16 of 18 (88%) infected nonunions healed.</p> <p>Control group: 18 of 26 (69%) healed in an average of 7.8 months; 14 of 16 (87%) non-infected nonunions healed and 4 of 10 infected nonunions healed.</p> <p>Among non-infected nonunions, the healing rate was the same but the time to heal was significantly shorter in the treated group (t test, p &lt;0.03). Among infected nonunions, the healing rate was significantly greater in the treated group (Fisher's exact test, p &lt;0.05) and the time to heal was significantly shorter in the treated group (t test, p &lt; 0.04).</p> <p>Effects of PEMF stimulation are usually evident in the first 3 months of treatment.</p>	<p>Due to the wide range of ages and lack of outcome reporting by age groups, the relevance of this study to the Medicare population is unknown.</p> <p>Comparison of healing rates between the treated and control groups is hindered by the differences in age and types of bone treated.</p>

**Table D-3. Included Studies of Pulsed Electromagnetic Fields Treatment of Nonunion Fractures Addressing Key Question 6 (continued)**

Reference	Study Design / Purpose / USPSTF Study Quality Rating	Intervention / Outcomes	Demographics	Results	Comments
		0 clavicle; Control – 3 femur, 15 leg, 2 humerus, 3 forearm, 1 metatarsal, 2 clavicle Outcomes: Success was defined as radiological signs of bone bridging in at least 3 out of 4 cortices, no further surgery, and weight-bearing without pain or protection. The minimum follow-up was 2 years.			

**Table D-3. Included Studies of Pulsed Electromagnetic Fields Treatment of Nonunion Fractures Addressing Key Question 6 (continued)**

Reference	Study Design / Purpose / USPSTF Study Quality Rating	Intervention / Outcomes	Demographics	Results	Comments
Meskens et al. 1990(117)	Retrospective Case Series Purpose: assess effect of PEMF in patients with a disability time of at least 24 months (interval between trauma and start of PEMF therapy), compare results with patients with shorter disability time, and evaluate prognostic factors. Level II-3 Internal validity criteria: low 1. no (retrospective data collection and analysis) 2. no (patients not listed as consecutive) 3. no (method of patient selection is not reported which	Device name not reported. All patients were strictly immobilized in a plaster cast with no weight-bearing. For the first 3 months, stimulation was 14 hours per day. For the next 3 months, stimulation was 10 hours per day. After 6 months, stimulation was only at night. Bones treated: 15 tibias, 9 femurs, 5 humeri, 2 ulnae, 2 radii, 1 fibula. Outcomes: Radiological signs of bone bridging and disappearance of gap, the disappearance of mobility on stress and of pain on percussion.	n = 34 Mean of 34 years with a range of 18 to 66 years. Sex: F11 M 23 Inclusion: Nonunion had to be at least 24-months old without any signs of progressing consolidation on x-rays taken at 2-month intervals. No operations for the nonunion in the 4 months preceding PEMF treatment. Exclusion: none reported. 8 hypertrophic, 5 atrophic, 21 neither type Initial and prior treatments: all patients had a period of unsuccessful plaster immobilization before beginning the PEMF therapy. On average, patients underwent 3 operations prior to PEMF therapy. 12 patients had prior bone graft. The mean disability time was 39 months with a range of 24 to 124 months.	68% healed in a mean of 11.5 months with a range of 3 to 43 months. % healed: 73% tibia, 78% femur, 20% humerus 75% hypertrophic 0% atrophic 80% neither type Nonunions older than 9 months healed at 69%, 9 to 24 months at 71%, and greater than 24 months at 63%. No statistical analysis reported	Due to the wide range of ages and lack of outcome reporting by age groups, the relevance of this study to the Medicare population is unknown.

**Table D-3. Included Studies of Pulsed Electromagnetic Fields Treatment of Nonunion Fractures Addressing Key Question 6 (continued)**

Reference	Study Design / Purpose / USPSTF Study Quality Rating	Intervention / Outcomes	Demographics	Results	Comments
	<p>allows for the possibility that results from dropouts were not reported)</p> <p>4. no (assessment not masked)</p> <p>5. yes</p> <p>6. yes</p> <p>7. no (no statistical analysis)</p>	<p>Follow-up: mean of 5.7 years with a range of 24 months to 9 years.</p> <p>Compliance was not reported.</p>			

**Table D-4. Included Studies of Direct Current and Capacitive Coupling Treatment of Nonunion Fractures Addressing Key Question 6**

Reference	Study Design / Purpose / USPSTF Study Quality Rating	Intervention / Outcomes	Demographics	Results	Comments
Brighton et al. 1995(16)	Retrospective Comparative study Purpose: Use logistic regression analysis to compare healing rates among 3 treatment methods, to identify risk factors adversely affecting the healing rate, and to predict the probability of successful healing of a nonunion of any given risk profile treated with each of the 3 therapies. Level II-3 Internal validity criteria: low 1. no (retrospective data collection and analysis)	Device names not reported. Direct current (used from 1971 to 1982): 4 stainless steel cathodes inserted percutaneously into the nonunion site. Stimulation applied for 24 hours per day for 12 weeks. All patients wore a non-weight-bearing cast during the entire 12 weeks. Capacitive coupling (used from 1982 to 1994): stainless steel capacitor plates or electrodes placed on the skin through windows cut in the opposite sides of a newly applied cast.	n = 271; direct current 167, capacitive coupling 56, bone graft 48. Mean age: direct current 35.9, capacitive coupling 35.9, and bone graft 33.3. No range reported. Sex: direct current F41 M126, capacitive coupling F12 M44, bone graft F16 M32. Inclusion: well-established nonunion of the tibia, defined as a fractured bone in which all radiographically demonstrable healing had ceased but bone continuity had been restored, no progressive signs of healing of the callus were seen during a 3-month period, and each nonunion had to be at least 9 months in duration. Exclusion: draining osteomyelitis of the nonunion was a cause for exclusion from treatment with direct current or bone graft surgery but not capacitive coupling.	Results of logistic regression analysis: Best case: nonunion of 10 months duration prior to treatment with no risk factors: Direct current – 99% healed Capacitive – 96% healed Bone graft – 99% healed The analysis found no statistically significant differences in healing rates between the three treatments in this best case situation. As the duration of nonunion prior to treatment and the number of risk factors increased the probability of healing decreased. Worst case: nonunion of 70 months duration prior to treatment with 4 risk factors: Direct current – 39% healed Capacitive – 38% healed Bone graft – 10% healed The 4 risk factors are comminuted fracture, open fracture, prior use of electric stimulation, and prior use of bone graft. The analysis found no statistically significant difference in healing rates between the two	Due to the lack of outcome reporting by age groups, the relevance of this study to the Medicare population is unknown. Patient age was a continuous variable in the logistic regression analysis, but any influence age may or may not have on healing is not reported. Actual healing rates and time to healing are not reported, except for the patients treated with bone graft. 28 of 48 tibial nonunions treated with bone graft healed. No time to healing was reported. The logistic regression analysis indicates that duration of nonunion prior to treatment has a significant effect on the probability of healing. Without the actual results for each therapy at each follow-up period, we cannot verify that the results of the logistic analysis accurately represent the actual study results. The findings may not be generalizable beyond the patients in this study.

**Table D-4. Included Studies of Direct Current and Capacitive Coupling Treatment of Nonunion Fractures Addressing Key Question 6 (continued)**

Reference	Study Design / Purpose / USPSTF Study Quality Rating	Intervention / Outcomes	Demographics	Results	Comments
	<p>2. yes            3. yes            4. no (assessment not masked)            5. yes            6. no (did not report pain or weight-bearing)            7. yes</p>	<p>Stimulation applied continuously for 24 hours per day for 12 to 24 weeks.            Bone graft (used throughout the study period): performed conventionally using autogenous iliac bone and accompanied by internal fixation in 15 patients, external fixation in 4 patients, and cast alone in 29 patients in whom rigid internal fixation was already in place.            Type of treatment was determined by the preference of the individual study author treating the patient.            Bones treated:            Tibia only;            167 direct current,</p>	<p>Prior treatments:            Direct current group – 44 electric and 60 bone graft;            Capacitive coupling group – 30 electric and 29 bone graft;            and Bone graft group – 24 electric and 23 bone graft.</p>	<p>electrical treatments in this worse case situation, but did find a statistically significant difference between bone graft and direct current (<math>p = 0.01</math>).            Atrophic nonunions did not respond to capacitive coupling. Bone graft surgery was less effective in nonunions with previous bone graft failure.</p>	



**Table D-4. Included Studies of Direct Current and Capacitive Coupling Treatment of Nonunion Fractures Addressing Key Question 6 (continued)**

Reference	Study Design / Purpose / USPSTF Study Quality Rating	Intervention / Outcomes	Demographics	Results	Comments
		56 capacitive coupling, and 48 bone graft.  Outcomes: Radiological signs of bone bridging.			

**Table D-4. Included Studies of Direct Current and Capacitive Coupling Treatment of Nonunion Fractures Addressing Key Question 6 (continued)**

Reference	Study Design / Purpose / USPSTF Study Quality Rating	Intervention / Outcomes	Demographics	Results	Comments
Zamora-Navas et al. 1995(17)	Retrospective Case series Purpose: Assess the healing of nonunion fractures with gaps wider than 1 cm when treated with electrical stimulation. Level II-3 Internal validity criteria: low 1. no (retrospective data collection and analysis) 2. yes 3. yes 4. no (assessment not masked) 5. yes 6. no (did not report pain or weight-bearing) 7. no (no statistical analysis)	Device name not reported. All nonunions of the extremities were immobilized with either plaster cast, external fixation, or other procedures. All patients underwent capacitive coupling induced by an externally placed unit. The plates were attached to the skin overlying the nonunion site, placed on opposite sides of the patient's limb. The unit was used all day. Bones treated: 10 tibias, 6 humeri, 2 radii, 1 femur, 1 ulna, 1 clavicle, 1 scaphoid. Outcomes: Radiological signs of bone bridging.	n = 22 Mean age of 35 years with a range of 17 to 70 years Sex: F6 M16 Inclusion: well-established nonunion, demonstrated clinically by the presence of movement at the fracture site and radiologically by the presence of a fracture line. The fracture had to remain non-united for at least 9 months from the time of injury, and there had to be no radiologic changes for the last 3 months. Gap wider than 0.5 cm. Exclusion: none reported. Initial and prior treatments: 9 patients had prior operative treatment. No patients had prior electrical stimulation therapy. Average time between the original injury and electrical treatment was 63 weeks with a range of 30 to 216 weeks.	% healed: 80% tibia 67% humerus 100% radius 100% femur 100% ulna 0% clavicle 0% scaphoid Average period of treatment was 26 weeks with a range of 8 to 42 weeks. No statistical analysis is reported.	Two patients were 65 years of age or older. A 65 year old male showed a healed nonunion of the tibia after 42 weeks of treatment. A 70 year old female did not heal after 24 weeks of treatment. Only radiographic evidence of bone bridging was reported. Other outcome measures such as pain, weight-bearing, and return to normal activities were not reported.

**Table D-4. Included Studies of Direct Current and Capacitive Coupling Treatment of Nonunion Fractures Addressing Key Question 6 (continued)**

Reference	Study Design / Purpose / USPSTF Study Quality Rating	Intervention / Outcomes	Demographics	Results	Comments
		Various treatment periods are reported with a range of 8 to 42 weeks.			

**Table D-4. Included Studies of Direct Current and Capacitive Coupling Treatment of Nonunion Fractures Addressing Key Question 6 (continued)**

Reference	Study Design / Purpose / USPSTF Study Quality Rating	Intervention / Outcomes	Demographics	Results	Comments
Scott and King 1994(15)	<p>Double-blinded, Randomized, Placebo-Controlled Trial</p> <p>Purpose: Determine the proper clinical role of electrical stimulation in the treatment of established nonunions by conducting an RCT.</p> <p>Level I</p> <p>Internal validity criteria: good</p> <ol style="list-style-type: none"> <li>1. yes</li> <li>2. yes</li> <li>3. yes</li> <li>4. yes</li> <li>5. yes</li> <li>6. yes</li> <li>7. yes</li> </ol>	<p>Orthopak bone-growth stimulator (Bioelectron, Hackensack, New Jersey) capacitive coupling device was used.</p> <p>Bones treated: Active group – 5 tibias, 4 femurs, 1 ulna; Control – 10 tibias, 0 femur, 1 ulna</p> <p>Outcomes: Radiological signs of trabecular bone bridging on all 4 radiographs (anteroposterior, lateral, 2 oblique) no movement, and no pain.</p> <p>If no healing had taken place after 6 months, the patient was removed from the study and offered other treatment.</p>	<p>n = 21 of 23 completed study, 2 removed for noncompliance.</p> <p>Active (n = 10): mean age of 40 years with a range of 27 to 55; F 2, M 8</p> <p>Control (n = 11): mean age of 46 years with a range of 23 to 87; F 3, M 8.</p> <p>Inclusion: Nonunion at least 9 months old, no clinical or radiographic signs of healing for at least 3 months, continuous immobilization from the time of the original injury with no other form of treatment, skeletal maturity.</p> <p>Exclusion: Operative or non-operative therapy in last 3 months, established Synovial pseudarthrosis, or a gap, or bone defect wider than one-half the width of the bone, generalized disorders of bone metabolism.</p> <p>Initial and prior treatments: Active - 3 patients had no prior bone surgery, 8 had internal or external fixation; Control – 1 patients had no prior bone</p>	<p>6 of the 10 (60%) actively treated patients healed in a mean of 21 weeks. None of the control patients healed after 26 weeks of treatment. Fisher exact test, p = 0.004, p = 0.02 if the two noncompliant patients are included.</p>	<p>The two patients older than 65 were included in the control group and did not heal. Therefore this study provided no evidence that older individuals will respond to ultrasound treatment.</p> <p>All 4 femur fractures were included in the Active group, which may have affected the results in favor of the active group. Analysis of the tibias only still showed statistical significance (p = 0.04)</p>

**Table D-4. Included Studies of Direct Current and Capacitive Coupling Treatment of Nonunion Fractures Addressing Key Question 6 (continued)**

Reference	Study Design / Purpose / USPSTF Study Quality Rating	Intervention / Outcomes	Demographics	Results	Comments
			surgery, 10 had internal or external fixation		

**Table D-4. Included Studies of Direct Current and Capacitive Coupling Treatment of Nonunion Fractures Addressing Key Question 6 (continued)**

Reference	Study Design / Purpose / USPSTF Study Quality Rating	Intervention / Outcomes	Demographics	Results	Comments
Cundy and Paterson 1990(18)	Retrospective Case series Purpose: A 10-year review of a prior prospective nonrandomized study was carried out to evaluate the safety and effectiveness of an implanted bone growth stimulator. Specifically, the purpose was to answer whether there were any untoward safety effects, whether there were any refractures, or if healed fractures remained healed, and the long-term outcome of the treatment failures. Level II-3 Internal validity criteria: low 1. no (retrospective	Device name not reported. The stimulator supplied a constant direct current that incorporated the anode and supplied the current via a single stainless steel or titanium cathode. Most patients received the titanium cathode helix. Stainless steel cathodes were removed but the titanium cathodes were allowed to remain and eventually become incorporated into the bone. The titanium cathode was left behind after the generator was removed. Bones treated: 33 tibias, 4 femurs,	n = 37 29 patients were less than 30 years of age, 5 patients were between the ages of 30 and 49, and 3 patients were 50 years or older Sex: F4 M33 Inclusion: this article reports on the long-term followup of patients previously treated for delayed unions or nonunions with an implanted bone growth stimulator. The presence of an infection was not a contraindication. Exclusion: none reported. Initial and prior treatments: 17 patients had no prior surgery, 13 had one operation, 7 had two, and one had 3. Time between initial injury and implant was less than 9 months in 25 patients, between 9 and 17 months in 5 patients, and 18 or more months in 8 patients.	In the original study, 72 of 84 (86%) nonunion fractures showed radiographic signs of bone bridging. All 38 fractures in the 37 patients in this followup were healed. Six of these patients had not healed in the prior study but were now healed through the use of bone grafting and internal fixation.	Due to the lack of outcome reporting by age groups, the relevance of this study to the Medicare population is unknown. Only three patients in this study were over the age of 50. Some ankles and knees were stiff due to prolonged immobilization. In some patients the remaining cathode was incorporated into the bone, but the patients had no clinical or radiographic signs of an adverse reaction to the cathode.

**Table D-4. Included Studies of Direct Current and Capacitive Coupling Treatment of Nonunion Fractures Addressing Key Question 6 (continued)**

Reference	Study Design / Purpose / USPSTF Study Quality Rating	Intervention / Outcomes	Demographics	Results	Comments
	data collection and analysis) 2. no (44% of the original patients were not located) 3. no (44% of the original patients were not located) 4. no (assessment not masked) 5. yes 6. no (did not report pain or weight-bearing) 7. no (no statistical analysis)	1 other. Outcomes: Radiological signs of bone bridging. This article reports on 10-year followup. The average follow-up period was 10 years and 3 months with a range of 9 years and 6 months to 11 years and 11 months.			

**Table D-5. Included Studies of Shock wave Treatment of Nonunion Fractures Addressing Key Question 6**

Reference	Study Design / Purpose / USPSTF Study Quality Rating	Intervention / Outcomes	Demographics	Results	Comments
Biedermann et al. 2003(19)	<p>Prospective Case series</p> <p>Purpose: To determine the value of extracorporeal shock waves for the treatment of nonunions, analyzing previous published studies and our own clinical results.</p> <p>Level II-3</p> <p>Internal validity criteria: low</p> <ol style="list-style-type: none"> <li>1. yes</li> <li>2. yes</li> <li>3. yes</li> <li>4. no (radiographic assessment was not masked)</li> <li>5. yes</li> <li>6. no (pain and weight-bearing were not reported)</li> <li>7. no (no statistical analysis)</li> </ol>	<p>MFL 5000 Lithotripter shock wave device was used in this study.</p> <p>All patients were treated once, 12 patients were treated twice. Bones were immobilized with plaster or braces for 6 weeks to 3 months.</p> <p>Bones treated: 58 long bones, 12 other; 34 hypertrophic nonunions, 12 hypertrophic delayed unions; 22 atrophic nonunions, 2 atrophic delayed unions.</p> <p>Outcomes: Radiographic evidence of bone bridging. Followup of 6 weeks, 3 months, and later for persistent nonunions.</p>	<p>n = 73</p> <p>Mean of 42 years</p> <p>Sex: F34 M39</p> <p>Inclusion: delayed or nonunion (failed bone healing of more than 6 months) fracture.</p> <p>Exclusions: bone tumors, pathologic fractures, recent infections, dysfunction of coagulation, nonunions close to the epiphyseal growth plate, pregnancy, nonunions of the thoracic bones, nonunions close to the central nervous system, open fractures.</p> <p>Initial and prior treatments: did not report prior treatments.</p> <p>Duration of nonunion before shock wave therapy averaged 19 months with a range of 6 to 74 months.</p> <p>Duration of delayed unions before shock wave therapy averaged 5 months with a range of 0.2 to 5 months.</p>	<p>% of patients with bony union:</p> <p>25 of 45 (55%) long bone nonunions; 12 of 13 (92%) of long bone delayed unions; 7 of 11 (63%) other nonunions; 1 of 1 (100%) other delayed unions.</p> <p>21 of 34 (62%) hypertrophic nonunions, 11 of 12 (92%) hypertrophic delayed unions. Mean time to heal was 5.3 months for nonunions.</p> <p>11 of 22 (50%) atrophic nonunions, 0 of 2 (0%) atrophic delayed unions. Mean time to heal was 3.4 months.</p> <p>A statistical analysis was not reported.</p> <p>No major adverse events; some transient tissue swelling and subcutaneous bleeding.</p>	<p>Due to limited reporting of patient characteristics, the relevance of this study to the Medicare population is unknown.</p> <p>Among pertinent patient characteristics, only the mean age was reported. Other outcome measures such as pain, weight-bearing, and return to normal activities were not reported.</p>



**Table D-5. Included Studies of Shock wave Treatment of Nonunion Fractures Addressing Key Question 6 (continued)**

Reference	Study Design / Purpose / USPSTF Study Quality Rating	Intervention / Outcomes	Demographics	Results	Comments
Rompe et al. 2001(20)	<p>Prospective Case series</p> <p>Purpose: Examine the effects of shock wave therapy on nonunion fractures of the femur and tibia.</p> <p>Level II-3</p> <p>Internal validity criteria: fair</p> <ol style="list-style-type: none"> <li>1. yes</li> <li>2. yes</li> <li>3. yes</li> <li>4. yes (used blinded assessment)</li> <li>5. yes</li> <li>6. no (did not consider pain)</li> <li>7. no (no statistical analysis)</li> </ol>	<p>Siemens Osteostar shock wave device was used in this study. All patients were treated once. The limbs remained in casts with limited weight-bearing.</p> <p>Bones treated: 19 tibial nonunion, 24 femoral nonunion.</p> <p>Outcomes: Radiographic evidence of bone bridging and weight-bearing.</p> <p>Followup period of 8 weeks and then monthly for 9 months.</p>	<p>n = 43</p> <p>Mean of 39.5 years and range of 18 to 74</p> <p>Sex: F20 M23</p> <p>Inclusion: Skeletally mature men and women with bony nonunion of the long bones of the lower extremity. Minimum of 9 months had elapsed since the last operation and no radiologic bridging was observed.</p> <p>Exclusion: loosening of screws and plates, bone gap more than 0.5 cm, local infection, pathologic fracture, pregnancy, patient receiving steroids, anticoagulants, nonsteroidal anti-inflammatory medication, diphosphonate therapy, calcium channel blockers, or immunosuppressive therapy, patients with a history of thrombophlebitis or vascular insufficiency, drug addiction, hepatitis, and human immunodeficiency virus infection.</p> <p>18 patients were smokers.</p> <p>Initial and prior treatments: patients averaged 2 unsuccessful operations with a range of 1 to 6.</p>	<p>31 of 43 (72%) patients showed bony bridging and could bear full weight by an average of 4 months.</p> <p>13 of 19 (68%) tibias healed; 18 of 24 (75%) femurs healed.</p> <p>19 of 24 (79%) nonsmokers healed; 12 of 19 (63%) smokers healed.</p> <p>No statistical analysis was reported.</p> <p>No major adverse events; some transient subcutaneous bleeding.</p>	<p>Four of the patients were older than 65 years (65, 70, 73, and 79). 3 of the 4 healed in an average of 4 months. The 73 year old patient did not heal.</p> <p>Provided individual patient data but did not report comorbidities other than smoking.</p>

**Table D-5. Included Studies of Shock wave Treatment of Nonunion Fractures Addressing Key Question 6 (continued)**

Reference	Study Design / Purpose / USPSTF Study Quality Rating	Intervention / Outcomes	Demographics	Results	Comments
Schaden et al. 2001(21)	<p>Retrospective Case series</p> <p>Purpose: Describe the early results in the application of high-energy shock waves using a device specifically designed for orthopedic use in the treatment of delayed unions and nonunions.</p> <p>Level II-3</p> <p>Internal validity criteria: low</p> <ol style="list-style-type: none"> <li>no (retrospective data collection and analysis)</li> <li>yes</li> <li>yes</li> <li>no (did not mask assessment)</li> <li>yes</li> <li>no (did not consider pain and weight-bearing)</li> <li>yes</li> </ol>	<p>Device name not reported.</p> <p>All patients received one shock wave treatment.</p> <p>After treatment the fractures were immobilized with casts or splints unless implanted devices showed no signs of loosening. 60 patients still had internal fixation devices.</p> <p>Bones treated: Multiple types including 34 tibias, 21 scaphoids, and 12 femurs; 35 delayed and 80 nonunions.</p> <p>Outcomes: Radiographic evidence of bone bridging. Followup of 4, 8, and 12 weeks plus a total followup of 3 months to 4 years.</p>	<p>n = 115</p> <p>Females: mean of 47 years, range of 15 to 85</p> <p>Males: mean of 41 years, range of 10 to 86</p> <p>Sex: F41 M 74</p> <p>Inclusion: nonunions (more than 6 months) or delayed (3 to 6 months) fracture healing.</p> <p>Exclusion: coagulopathy, acute infection, pregnancy, any of the following within the shock wave field: epiphyseal plate, malignant tumor, alveolar tissue, brain, or spine.</p> <p>Initial and prior treatments: 23 patients had initial conservative treatment, 92 had operative treatment. 28 patients were operated on twice and 25 were operated on 3 or more times.</p>	<p>26 of 35 (74%) delayed unions healed and 61 of 80 (76%) nonunions healed.</p> <p>26 of 34 (76%) tibias, 14 of 21(67%) scaphoids, and 11 of 12 (92%) femurs healed.</p> <p>There was no significant difference among the success rates of the groups of patients with delayed nonunions, nonunions, or previously infected nonunions (statistical methods were not reported).</p> <p>No major adverse events; some transient tissue swelling and subcutaneous bleeding.</p>	<p>Due to the wide range of ages and lack of outcome reporting by age groups, the relevance of this study to the Medicare population is unknown. The authors state that positive results and treatment failures were not correlated with the age of the patients.</p> <p>Only radiographic evidence of bone bridging was reported.</p> <p>Other outcome measures such as pain, weight-bearing, and return to normal activities were not reported.</p>

**Table D-5. Included Studies of Shock wave Treatment of Nonunion Fractures Addressing Key Question 6 (continued)**

Reference	Study Design / Purpose / USPSTF Study Quality Rating	Intervention / Outcomes	Demographics	Results	Comments
Wang et al. 2001(119)	<p>Prospective Case series</p> <p>Purpose: Review the clinical results in the treatment of patients with nonunion fractures of long bones treated with shock waves.</p> <p>Level II-3</p> <p>Internal validity criteria: fair</p> <ol style="list-style-type: none"> <li>1. yes</li> <li>2. yes</li> <li>3. yes</li> <li>4. no (assessment not masked)</li> <li>5. yes</li> <li>6. yes</li> <li>7. yes</li> </ol>	<p>The OssaTron Shockwave device was used in this study. Patients received one shock wave treatment with one additional treatment after 3 months if nonunion persisted. Patients were allowed mobilization with crutches, partial weight-bearing for fractures of lower extremity, and sling for upper extremity.</p> <p>Bones treated: 41 femurs, 19 tibias, 7 humeri, and 5 other long bones.</p> <p>Outcomes: Radiographic evidence of bone bridging, pain measured by 0 to 10 visual analog scale, percentage of weight-bearing, and functional use of affected limb. Follow-up periods of 6 weeks, 3, 6, 9, and 12 months.</p>	<p>n = 72</p> <p>Mean of 39 years and range of 15 to 74 years</p> <p>Sex: F19 M 53</p> <p>Inclusion: established nonunions of long bone fractures defined as a failure to show bone union 6 months after initial closed or open treatment. All patients must be skeletally mature.</p> <p>Exclusion: underlying neoplastic disease or other causes of pathologic fracture, fractures in the epiphyseal region of the bone, a fracture gap greater than 0.5 cm, active infection, fractures in younger patients in whom the epiphyseal plate has not closed, pregnancy, cardiac pacemakers, use of immunosuppressive drugs or anticoagulants, and fractures near major neurovascular structures in the spine, chest, and skull.</p> <p>Presence of orthopedic implants was not a contraindication.</p> <p>Initial and prior treatments: 8 patients were treated initially with a closed reduction and cast immobilization. The remaining 64 had undergone at least one open</p>	<p>9 patients were lost to followup and 8 patients chose surgical intervention.</p> <p>3 months, 70 patients: Pain declined from 2.65 to 1.11 (p &lt;0.001); weight-bearing increased from 60% to 74% (p &lt;0.001); bony union in 50% of hypertrophic nonunions (19 of 38), 47% of nonunions with a defect (9 of 19), and 0% of atrophic nonunions (0 of 13).</p> <p>6 months, 61 patients: Pain declined from 2.5 to 0.4 (p &lt;0.001); weight-bearing increased from 60% to 82% (p &lt;0.001); functional use improved from 50% to 74% (p &lt;0.001); bony union in 68% of hypertrophic nonunions (23 of 34), 69% of nonunions with a defect (11 of 16), and 27% of atrophic nonunions (3 of 11).</p> <p>12 months, 55 patients: Pain declined from 2.6 to</p>	<p>Due to the wide range of ages and lack of outcome reporting by age groups, the relevance of this study to the Medicare population is unknown.</p> <p>Report contains information on pain, weight-bearing and limb function for up to 12 months after treatment, but did not differentiate between patients in different age groups.</p>

**Table D-5. Included Studies of Shock wave Treatment of Nonunion Fractures Addressing Key Question 6 (continued)**

Reference	Study Design / Purpose / USPSTF Study Quality Rating	Intervention / Outcomes	Demographics	Results	Comments
			<p>reduction and internal fixation; 41 with femur fractures, 33 initially were treated with an intramedullary nail, 7 with plate fixation, and 1 with nail and plate. The average number of operations prior to shock wave therapy was 1.3 with a range of 1 to 6. 23 patients had received bone graft on 1 to 3 occasions.</p>	<p>0.1 (p &lt;0.001); weight-bearing increased from 60% to 91% (p &lt;0.001); functional use improved from 47% to 80% (p &lt;0.001); bony union in 81% of hypertrophic nonunions (25 of 31), 81% of nonunions with a defect (13 of 16), and 75% of atrophic nonunions (6 of 8).  Statistical methods were not reported.  No major adverse events; some transient subcutaneous bleeding.</p>	

**Table D-5. Included Studies of Shock wave Treatment of Nonunion Fractures Addressing Key Question 6 (continued)**

Reference	Study Design / Purpose / USPSTF Study Quality Rating	Intervention / Outcomes	Demographics	Results	Comments
Vogel et al. 1997(120)	<p>Prospective Case series</p> <p>Purpose: To evaluate the success rate of shock wave therapy in treating nonunions of the lower extremity.</p> <p>Level II-3</p> <p>Internal validity criteria: low</p> <ol style="list-style-type: none"> <li>1. yes</li> <li>2. yes</li> <li>3. yes</li> <li>4. no (did not mask assessment)</li> <li>5. yes</li> <li>6. no (did not consider pain and weight-bearing)</li> <li>7. no (no statistical analysis)</li> </ol>	<p>The Siemens OsteoStar was used in this study. All patients were treated once. After treatment predominantly involved applying a cast.</p> <p>Bones treated: 17 femurs, 19 tibias, 9 metatarsals, and 3 other bones.</p> <p>Outcomes: Radiographic evidence of bone bridging. Followup at 3, 6, 12, 18, 24 and 52 weeks.</p>	<p>n = 48</p> <p>Mean of 38 years and range of 12 to 81 years</p> <p>Sex: F23 M25</p> <p>Inclusion: nonunions of the leg with a history of more than 6 months.</p> <p>Exclusion: acute osteomyelitis, defects close to growth plate, pathological fractures, coagulation disorders, pregnancy, and malignancy.</p> <p>Initial and prior treatments: Patients average 2.4 operations prior to treatment.</p> <p>The mean duration of nonunion prior to treatment was 12 months with a range of 6 to 48 months.</p>	<p>At a mean of 3.4 months (range of 2 to 9 months) 29 of 48 (60%) patients showed complete healing.</p> <p>Healing rates for individual bone types were not reported.</p> <p>No statistical analysis was reported.</p> <p>No major adverse events; some transient tissue swelling and subcutaneous bleeding.</p>	<p>Due to the wide range of ages and lack of outcome reporting by age groups, the relevance of this study to the Medicare population is unknown.</p> <p>Only radiographic evidence of bone bridging was reported.</p> <p>Other outcome measures such as pain, weight-bearing, and return to normal activities were not reported.</p>

**Table D-5. Included Studies of Shock wave Treatment of Nonunion Fractures Addressing Key Question 6 (continued)**

Reference	Study Design / Purpose / USPSTF Study Quality Rating	Intervention / Outcomes	Demographics	Results	Comments
Valchanou and Michailov 1991(22)	<p>Retrospective Case series</p> <p>Purpose: Present the results of the application of extracorporeal high-energy shock wave in the treatment of delayed unions and nonunions.</p> <p>Level II-3</p> <p>Internal validity criteria: low</p> <ol style="list-style-type: none"> <li>no (retrospective data collection and analysis)</li> <li>no (patients not reported as consecutive)</li> <li>no (loss to followup not reported)</li> <li>no (did not mask assessment)</li> <li>yes</li> <li>no (did not consider pain and weight-bearing)</li> <li>no (no statistical analysis)</li> </ol>	<p>The device name was not reported. Patients were each treated once. Most fractures were immobilized in a plaster cast.</p> <p>Bones treated: 6 femurs, 10 tibias, 1 patella, 1 fibula, 5 humeri, 11 ulnae, 21 radii, 17 scaphoids, 7 phalanges.</p> <p>Outcomes: Radiographic evidence of bone bridging. No follow-up periods were reported.</p>	<p>n = 79</p> <p>Mean age of 28 years and range of 9 to 76 years</p> <p>Sex: F8 M71</p> <p>Inclusion: delayed or nonunion fractures.</p> <p>Exclusion: none reported.</p> <p>Initial and prior treatments: 52 patients had had 1 to 5 previous operations.</p> <p>The average time after injury until shock wave treatment was 20 months.</p>	<p>70 of 79 (85%) patients showed radiographic evidence of bone bridging. Average time until healed was not reported.</p> <p>Femur: 5 of 6, 83%</p> <p>Tibia: 7 of 10, 70%</p> <p>Scaphoid: 13 of 17, 76%</p> <p>Radius: 19 of 21, 90%</p> <p>Ulna: 10 of 11, 91%</p> <p>Phalanges: 7 of 7, 100%</p> <p>Humerus: 5 of 5, 100%</p> <p>Patella: 0 of 1, 0%</p> <p>Fibula: 1 of 1, 100%</p> <p>No statistical analysis was reported.</p> <p>No "troublesome" side effects were reported.</p>	<p>Due to the wide range of ages and lack of outcome reporting by age groups, the relevance of this study to the Medicare population is unknown.</p> <p>Only radiographic evidence of bone bridging was reported, but no time period for healing was reported. Other outcome measures such as pain, weight-bearing, and return to normal activities were not reported.</p>

**Table D-6. Included Studies of Orthobiologics Treatment of Nonunion Fractures Addressing Key Question 6**

Reference	Study Design / Purpose / USPSTF Study Quality Rating	Intervention / Outcomes	Demographics	Results	Comments																																																								
Friedlaender et al. 2001(23)	<p>Prospective randomized controlled trial</p> <p>Purpose: Establish the safety and efficacy of OP-1 in treating nonunions of the tibia and determine if OP-1 is comparable to bone graft for the treatment of tibial nonunions.</p> <p>Level I</p> <p>Internal validity criteria: fair</p> <ol style="list-style-type: none"> <li>yes</li> <li>yes</li> <li>yes</li> <li>no (treatment could not be blinded, but radiographic assessment was blinded)</li> <li>yes</li> <li>yes</li> <li>yes</li> </ol>	<p>All patients underwent intramedullary rod fixation.</p> <p>Osteogenic protein-1 (OP-1, also BMP-7, from Stryker Biotech) implant: patients received one or two units of recombinant human osteogenic protein-1 (rhOP-1) implanted in the fracture site. Each unit consisted of 3.5 mg of rhOP-1 and 1 gram of bovine bone-derived collagen.</p> <p>Bone autograft: the procedure is not described.</p> <p>Bones treated: tibia only.</p> <p>Outcomes: Radiological signs of bone bridging judged by three radiologists blinded to the treatment.</p> <p>Clinical assessment included the presence of pain at the fracture site upon weight-bearing, the ability to bear weight, and the need for further surgical intervention for the purpose of enhancing fracture repair (re-treatment).</p>	<p>n = 63 implant and 61 autograft</p> <p>OP-1 implant: mean of 38 years with a standard deviation of 16.</p> <p>Bone autograft: mean of 34 years with a standard deviation of 11.</p> <p>Sex: OP-1: F20 M41; Autograft: F14 M47</p> <p>Inclusion: tibial nonunions requiring 9 months duration of the non-united fracture with no evidence of progressive healing over the previous 3 months.</p> <p>Exclusion: patients who, in the judgment of their treating orthopedic surgeon, were candidates for internal fixation alone, clinically apparent infection in the fracture site, skeletally immature, severely compromised soft-tissue coverage, pathological cause for the fracture, receiving radiation, chemotherapy, immunosuppression, or chronic steroids, are or could become pregnant, breastfeeding, congenital or synovial pseudarthrosis of the tibia, neuropathy that would interfere with walking or appreciating pain, nonunions of multiple bones other</p>	<p>At 9 months:</p> <table border="1"> <thead> <tr> <th>% Success</th> <th>OP-1</th> <th>BG</th> <th>p-value</th> </tr> </thead> <tbody> <tr> <td>Weight-bearing</td> <td>86%</td> <td>85%</td> <td>NS</td> </tr> <tr> <td>Pain on weight-bearing</td> <td>89%</td> <td>90%</td> <td>NS</td> </tr> <tr> <td>Combined</td> <td>81%</td> <td>85%</td> <td>NS</td> </tr> <tr> <td>Bridging (1 view)</td> <td>75%</td> <td>84%</td> <td>NS</td> </tr> <tr> <td>Bridging (3 views)</td> <td>62%</td> <td>74%</td> <td>NS</td> </tr> <tr> <td>No retreatment</td> <td>95%</td> <td>90%</td> <td>NS</td> </tr> <tr> <td>Physician satisfaction</td> <td>86%</td> <td>90%</td> <td>NS</td> </tr> </tbody> </table> <table border="1"> <thead> <tr> <th>% Adverse events</th> <th>OP-1</th> <th>BG</th> <th>p-value</th> </tr> </thead> <tbody> <tr> <td>Arthralgia (neuralgic pain in a joint or joints)</td> <td>13%</td> <td>8%</td> <td>NS</td> </tr> <tr> <td>Pain, multiple sites</td> <td>13%</td> <td>15%</td> <td>NS</td> </tr> <tr> <td>Osteomyelitis</td> <td>3%</td> <td>21%</td> <td>0.002</td> </tr> <tr> <td>Fever</td> <td>51%</td> <td>46%</td> <td>NS</td> </tr> <tr> <td>Vomiting</td> <td>30%</td> <td>31%</td> <td>NS</td> </tr> </tbody> </table>	% Success	OP-1	BG	p-value	Weight-bearing	86%	85%	NS	Pain on weight-bearing	89%	90%	NS	Combined	81%	85%	NS	Bridging (1 view)	75%	84%	NS	Bridging (3 views)	62%	74%	NS	No retreatment	95%	90%	NS	Physician satisfaction	86%	90%	NS	% Adverse events	OP-1	BG	p-value	Arthralgia (neuralgic pain in a joint or joints)	13%	8%	NS	Pain, multiple sites	13%	15%	NS	Osteomyelitis	3%	21%	0.002	Fever	51%	46%	NS	Vomiting	30%	31%	NS	<p>Due to the lack of outcome reporting by age groups, the relevance of this study to the Medicare population is unknown. The influence of patient age on nonunion healing was not part of the reported data analysis.</p> <p>Patients and physicians could not be blinded to treatment because of the presence of a bone graft donor site in patients who received bone graft.</p> <p>The proper statistical comparison for this study is a non-inferiority analysis. See the text for a</p>
% Success	OP-1	BG	p-value																																																										
Weight-bearing	86%	85%	NS																																																										
Pain on weight-bearing	89%	90%	NS																																																										
Combined	81%	85%	NS																																																										
Bridging (1 view)	75%	84%	NS																																																										
Bridging (3 views)	62%	74%	NS																																																										
No retreatment	95%	90%	NS																																																										
Physician satisfaction	86%	90%	NS																																																										
% Adverse events	OP-1	BG	p-value																																																										
Arthralgia (neuralgic pain in a joint or joints)	13%	8%	NS																																																										
Pain, multiple sites	13%	15%	NS																																																										
Osteomyelitis	3%	21%	0.002																																																										
Fever	51%	46%	NS																																																										
Vomiting	30%	31%	NS																																																										

**Table D-6. Included Studies of Orthobiologics Treatment of Nonunion Fractures Addressing Key Question 6 (continued)**

Reference	Study Design / Purpose / USPSTF Study Quality Rating	Intervention / Outcomes	Demographics	Results	Comments
		<p>Combined clinical criteria for success was full weight-bearing, less than severe pain at the fracture site on weight-bearing, and no re-treatment. Patients were examined at 1, 2, 3, 6, 9, 12, and 24 months after treatment. The primary end-point was 9 months.</p>	<p>than the tibia, autoimmune disease, sensitivity to collagen. Smoking: 74% of OP-1, 57% of bone autograft. Initial and prior treatments: Prior autograft: 43% OP-1 and 31% bone graft. Prior IM rod: 54% OP-1 and 44% bone graft. There were no statistically significant differences in the distribution of prior autografts or bone grafts. Atrophic nonunions were significantly more prevalent in the OP-1 group, 41% vs. 25%, p = 0.048. Median duration of nonunion prior to treatment was 17 months in both groups. Tobacco/nicotine use was 74% in the OP-1 group and 57% in the autograft group but was not significant (p = 0.06).</p>	<p>Leg edema           8%   11%   NS Postoperative infection           23%   20%   NS <u>% Adverse events associated with the bone graft donor site (only BG group)</u> All patients reported post-operative pain, 80% judged the pain to be moderate or severe. At 6 months 20% of patients reported persistent pain (mild to moderate) and at 12 months 13% had persistent pain at the donor site.</p>	<p>discussion of this approach to demonstrating that one treatment is not inferior to another treatment.</p>



**Table D-6. Included Studies of Orthobiologics Treatment of Nonunion Fractures Addressing Key Question 6 (continued)**

Reference	Study Design / Purpose / USPSTF Study Quality Rating	Intervention / Outcomes	Demographics	Results	Comments
Wilkins and Kelly 2003(24)	<p>Retrospective Case series</p> <p>Purpose: Assess the effectiveness of a commercially prepared allograft demineralized bone matrix in patients with long bone gaps and nonunions.</p> <p>Level II-3</p> <p>Internal validity criteria: low</p> <ol style="list-style-type: none"> <li>1. no (retrospective data collection and analysis)</li> <li>2. yes</li> <li>3. no (loss to followup was not reported)</li> <li>4. no (assessment was not masked)</li> <li>5. yes</li> <li>6. yes</li> <li>7. yes</li> </ol>	<p>AlloMatrix Injectable Putty (Wright Medical Technology), a combination of demineralized bone matrix (AlloSource) and surgical-grade calcium sulfate carrier (OsteoSet) was used in this study. Nonunions were treated using standard internal/external fixation techniques. The periosteum surrounding the nonunion site was elevated to create an area into which the putty was placed. The periosteum was then closed around the site.</p> <p>Bones treated: 13 tibias, 10 humeri, 6 ulnae, 5 femurs, 1 fibula</p> <p>Outcomes: Bone Healing Index</p> <p>Patients were judged as healed when the numerical total of the radiographic score (1: no bone bridging to 5: cortical bridging) and clinical score (1: pain with rest to 5: normal function) was 8 or more.</p> <p>Average followup was 6 months.</p>	<p>n = 35 nonunions and 41 being treated for bone voids.</p> <p>Mean of 45 years with a range of 18 to 76 years for the nonunion group.</p> <p>Sex: F40 M36 (value for entire study group including patients being treated for bone voids)</p> <p>Inclusion: a surgeon recommended cancellous (spongy) bone graft as treatment, the void shape could accommodate graft material, and patients were willing to release medical data and return for postoperative followup.</p> <p>Exclusion: none reported.</p> <p>Initial and prior treatments: Not reported.</p>	<p>Average time to healing was 3.5 months.</p> <p>30 of 35 (85.7%) patients were healed according to radiographic evidence.</p> <p>Healing rates were not reported separately for individual bone types.</p> <p>Re-fracture after successful healing: 2</p> <p>Hardware failure: 1</p> <p>Postoperative neuromas over the scar: 1</p> <p>Decreased range of motion due to adhesions: 1</p> <p>Recurrent infection: 1</p>	<p>Due to the lack of outcome reporting by age groups, the relevance of this study to the Medicare population is unknown. The influence of patient age on nonunion healing was not part of the reported data analysis.</p> <p>Whether the authors actually used the Bone Healing Index to judge the healing process is not clear. Therefore, the extent to which normal function was achieved cannot be determined.</p>

**Table D-6. Included Studies of Orthobiologics Treatment of Nonunion Fractures Addressing Key Question 6 (continued)**

Reference	Study Design / Purpose / USPSTF Study Quality Rating	Intervention / Outcomes	Demographics	Results	Comments
Johnson and Urist 2000(127)	<p>Retrospective Case series</p> <p>Purpose: Assess the effectiveness of a composite inductive allograft in healing femoral nonunions.</p> <p>Level II-3</p> <p>Internal validity criteria: low</p> <ol style="list-style-type: none"> <li>1. no (retrospective data collection and analysis)</li> <li>2. yes</li> <li>3. yes</li> <li>4. no (assessment was not masked)</li> <li>5. yes</li> <li>6. no (did not consider pain or weight-bearing)</li> <li>7. no (no statistical analysis)</li> </ol>	<p>A composite allograft consisting of an allogeneic, autolyzed, antigen-free cortical bone carrier with partially purified human bone morphogenetic protein, abbreviated as hBMP/AAA, was used in this study. The allograft contained 100 mg of partially purified hBMP lyophilized into the implant.</p> <p>13 patients received additional autogenic cancellous bone graft to the intercalary segmental defect. 26 patients were implanted with a fixed angle blade plate to stabilize and lengthen the femur.</p> <p>The procedure involved bone lengthening. The remaining patients had intramedullary nails.</p> <p>Bones treated: all femurs.</p> <p>Outcomes: Radiological signs of bone bridging. Follow-ups averaged 58 months with a range of 11 to 153 months.</p>	<p>n = 30</p> <p>Mean age of 47 years with a range of 28 to 75 years.</p> <p>Sex: F20 M10</p> <p>Inclusion: patients with femoral diaphyseal or diaphyseal-metaphyseal reconstructions augmented with hBMP/AAA.</p> <p>Exclusion: none reported.</p> <p>Initial and prior treatments: 16 patients had 34 failed IM nailings, 17 had 25 failed diaphyseal or metaphyseal platings, 8 patients had failed IM nailing and plating. There was an average of 2 previous failed procedures per patient with a range of 1 to 4 procedures and an average of 2 failed autogenous cancellous bone grafts per patients with a range of 1 to 4 graftings.</p> <p>The average duration of nonunion was 39 months with a range of 9 to 60 months.</p>	<p>24 of 30 (80%) femoral nonunions showed healing with an average time of 6 months and a range of 3 to 9 months.</p> <p>No statistical analysis was reported.</p> <p>6 patients had a fatigue failure of the implant.</p> <p>There were no infections, wound healing problems, neurovascular compromises, or significant loss of knee motion after lengthening.</p>	<p>8 of the patients were 65 years of age or older. 7 of these 8 patients showed healing within 4 to 6 months.</p> <p>The partially purified hBMP used in this study was prepared by the authors.</p>

**Table D-6. Included Studies of Orthobiologics Treatment of Nonunion Fractures Addressing Key Question 6 (continued)**

Reference	Study Design / Purpose / USPSTF Study Quality Rating	Intervention / Outcomes	Demographics	Results	Comments
Johnson et al. 1992(128)	<p>Retrospective Case series</p> <p>Purpose: To investigate repair of unhealed fractures and bone defects under the influence of bone morphogenetic protein (BMP) implanted using cortical bone as a delivery system.</p> <p>Level II-3</p> <p>Internal validity criteria: low</p> <ol style="list-style-type: none"> <li>1. no (retrospective data collection and analysis)</li> <li>2. yes</li> <li>3. yes</li> <li>4. no (assessment was not masked)</li> <li>5. yes</li> <li>6. no (did not consider pain or weight-bearing)</li> <li>7. no (no statistical analysis)</li> </ol>	<p>A composite allograft consisting of an allogeneic, autolyzed, antigen-free cortical bone carrier with partially purified human bone morphogenetic protein, abbreviated as hBMP/AAA, was used in this study. The hBMP/AAA implant was surgically placed in the defect. 22 patients were also treated with adjunctive internal fixation and 7 patients received adjunctive bone grafting.</p> <p>Bones treated: 7 tibia, 12 femur, 6 humerus.</p> <p>Outcomes: Patients were evaluated on 3 categories: anatomic (extent of radiological signs of bone healing), economic (ability to return to work), and functional (ability to perform activities of daily living). Each category was scored from 0 (worst outcome) to 4 (best outcome). Followup averaged 20 months with a range of 5 to 82 months.</p>	<p>n = 25</p> <p>Mean of 45 years with a range of 13 to 75 years.</p> <p>Sex: F16 M9</p> <p>Inclusion: resistant nonunions including partial or complete segmental defects treated with hBMP/AAA.</p> <p>Initial and prior treatments: 22 patients had long-term failure of PEMF therapy, 23 had previous failed surgical procedures with an average of 3 and a range of 1 to 8.</p> <p>Duration of nonunions averaged 30 months with a range of 5 to 83 months.</p>	<p>20 of 25 (80%) nonunions united after the first implantation of the composite graft. 4 of the 5 failures healed after revision of the failed fixation. Average healing time was 6 months with a range of 3 to 14 months.</p> <p>14 patients finished with scores of 4 in the 3 evaluation categories. 5 patients had scores of 3 in all 3 categories. 15 of the 19 patients with tibia or femur nonunions were able to walk without support.</p> <p>All 12 femurs healed, 6 of 7 (86%) tibias healed, all 6 humeri healed.</p> <p>No statistical analysis was reported.</p> <p>There were no complications related to infection, rejection, or evidence of delayed immune response attributable to the hBMP/AAA implant.</p>	<p>5 patients were 65 years or older. 3 had nonunions of the tibia. All healed and were able to perform activities of daily living. 2 had nonunions of the humerus. All healed and were able to perform activities of daily living.</p> <p>The partially purified hBMP used in this study was prepared by the authors.</p>

## **Appendix E. Additional Data Supplied by Reviewers**

Additional unpublished data was supplied by Orthofix, Inc. and EBI regarding the use of PEMF for treatment of nonunion. The data from Orthofix supported a PMA. The information from EBI provides followup to the study by Sharrard.(12)

1. Reference: Orthofix - PMA P850007 / S20 February 7, 2000

Citation:	Physio-Stim® Bone Growth Stimulator – Patient Registry Data
Intended Use	<input checked="" type="checkbox"/> Non-union fracture <input type="checkbox"/> Osteotomy <input type="checkbox"/> Lumbar spinal fusion <input type="checkbox"/> Other: _____
Stimulation Type	<input type="checkbox"/> Internal Electrical Stimulation <input checked="" type="checkbox"/> External Electrical Stimulation
Commercial Device Name(s)	Physio-Stim®
Overall Study Design	<input type="checkbox"/> Prospective, Double-Blind Randomized Controlled Trial <input type="checkbox"/> Prospective <input type="checkbox"/> Retrospective <input checked="" type="checkbox"/> Other: <u>Patient Registry</u>
# Patients	729 patients with 859 fractures (62% male, 38% female)
Age	<18 years to 70+ years (mean 44 years; 73 patients = 60+ years, 55 patients = 70+ years)
Selection Criteria	<b>Inclusion:</b> <ul style="list-style-type: none"> <li>• Patients diagnosed by their physician to have a nonunion fracture after 2 months post-injury (range 2 months to more than one year)</li> <li>• Physio-Stim device prescribed with documented timing of the intervention.</li> </ul> <b>Exclusion:</b> <ul style="list-style-type: none"> <li>• Unknown treatment outcome</li> <li>• Fracture sites other than extremities.</li> </ul>
Prior Surgery?	Forty-eight percent of patients had one or two (or more) previous procedures (i.e., internal / external fixation, bone grafting).
Methods	<p>After FDA approval of the device, and while long-term safety and efficacy data were being collected, Orthofix kept a Registry of patients wearing the device for fracture nonunion. The Registry of physician-reported outcomes was tabulated and represents post-market use of the device from the time of approval to the completion of the four-year followup (March 1986 through December 1989). The Registry database includes patient age at the time of treatment, gender, diagnosis, date of injury, fracture location, previous surgical procedures, model number, and treatment start date. Device safety and effectiveness data were collected from the treating physicians including treatment completion date, outcome assessment and date, as well as complications or adverse events. The results are the fracture healing outcomes of 729 patients with one or more nonunion fractures (totaling 859 fractures). Physicians recorded their observations of radiographic and clinical healing on a form returned to Orthofix.</p>

Success/Failure Criteria (Radiographic, Clinical, other)	Radiographic: Success = union/healed Failure = nonunion/not healed.
Results	<p><b>Radiologic Effectiveness:</b></p> <ul style="list-style-type: none"> <li>• 729 fractures healed (85%).</li> </ul> <p><b>Clinical Effectiveness:</b></p> <ul style="list-style-type: none"> <li>• Return to normal function</li> </ul> <p><b>Other Effectiveness:</b></p> <ul style="list-style-type: none"> <li>• None</li> </ul> <p><b>Morbidity (infection, amputation, permanent loss of limb function)</b></p> <ul style="list-style-type: none"> <li>• No untoward effects.</li> </ul>
Strengths	The clinical experience within the Physio-Stim Patient Registry to heal nonunion fractures is statistically comparable to that demonstrated in the Physio-Stim prospective, multi-center, controlled clinical trial supporting the premarket approval. These Registry data offer additional support because they are derived from a larger patient population than the original clinical trial, with greater numbers of individual fractures in each site location.
Weaknesses	None identified.

TELEPHONE  
(0742) 654918

"UPLANDS"  
140 MANCHESTER ROAD,  
SHEFFIELD  
S10 5DL

15th June 1993

Naomi Aronson, Ph.D.  
Blue Cross Association  
676 North St. Clair Street  
Chicago, Illinois 60611

Dear Dr. Aronson:

I have recently had the opportunity to review the comments developed by Blue Cross/Blue Shield's Medical Advisory Panel relative to its evaluation of electrical bone growth stimulation. There appear to be several issues concerning our double blind study of delayed union as published in the British JBJS (herein referred to as Sharrard Study) and its implications concerning the benefit in delayed unions.

In the December 29, 1992 memorandum to Electro-Biology, Inc. (EBI), the Blue Cross/Blue Shield Association raised several issues concerning the Sharrard Study (in context of the article). Specifically, these are:

- 1.) Does radiographic evidence of healing after 12 weeks, an intermediate outcome, predict health outcomes such as healing and need for subsequent surgery?
- 2.) Why was statistical significance shown with radiographic assessment (after 12 weeks) but not with clinical assessment (e.g. movement at the fracture site, pain, and tenderness)? How does one assimilate this into the overall technology assessment when making a determination of efficacy?
- 3.) How do differences in the radiologist's and my evaluation of radiographic assessment affect its significance and overall interpretation.

With respect to question #1, whether positive radiographic evidence at 12 weeks (an intermediate outcome) predicts final health outcomes, it is important to understand that the purpose of our published study was to determine radiographically in a double-blind investigation whether PEMF had a positive biological effect. Based on years of clinical experience, it is apparent to orthopedists (as it will be to your Panel) upon further review of the data provided

herein), that intermediate positive radiographic assessment has a positive correlation to final clinical success.

First, let me share with you the fact that long-term follow-up data has indeed been developed which provides patient endpoints an average of 2 years after PEMF treatment had been initiated. This follow-up was the result of continued diligence on the part of myself and my colleagues to collect and evaluate long-term outcome data. It appears to us that this follow-up data responds to your Association's concerns regarding health outcome endpoint several years after initiation of therapy. The following tables and graphs establish, from a perspective of final health outcomes, that the PEMF treatment of delayed unions delivered a statistically significant advantage over placebos.

For purpose of this analysis, positive intermediate outcome is defined as the 12 week radiographic assessment of either having healed or showing progress towards healing. Positive final outcome is defined as those that healed with no further surgery as noted an average of 2 years (median 15 months) after treatment was initiated.

In the Sharrard Study, at 12 weeks the intermediate outcome of PEMF treatment was shown to be highly significant ( $p = 0.009$ ). On a combined basis, a positive intermediate outcome (radiographic progress as determined by either me or the blinded radiologist, Barrington) was noted in 65% of the patients (13 of 20) in the active group. By comparison, the control group (using identical criteria) evidenced only 32% of the patients (8 of 25) reported with a positive intermediate outcome.

Of importance is the fact that in the control group, 64% (14 of 22 patients) required further intervention, as opposed to only 15% (3 of the 20 patients) in the active group. Given the significance ( $p=0.00134$ ), it is important to reiterate that 85% (17/20) of the treatment group went on to heal without surgery versus only 36% (8 of 22) in the control group (3 patients lost to follow-up).

Finally in the control group patients opting for an active unit (8) at study termination 75% (6 of the 8 people) went on to heal with PEMF while only 25% (2 of the 8) went on to surgery. All 8 patients requesting active PEMF at the Study's termination had been assessed by both the independent radiologist (Barrington) and me as failures at the 12 week mark.

Details of the final outcome analysis are as follows:

**Table I**  
Delayed Union Study  
Long-Term Follow-Up - Final Outcome Report  
(Mean 2 years, median 15 months)

	ACTIVE (n = 20)	CONTROL (n = 25)
Healed With No Further Surgery	17 (85%)	8 (32%)
Surgery	3 (15%)	8* (32%)
PEMF (Requested Live Units > 12 Weeks No Further Surgery)	-	6 (24%)
Lost To Follow-Up > 12 Weeks	-	3 (12%)
TOTAL	20	25

\* Two patients requested live - healed after surgery.

In reviewing the long-term data (Table II) one sees a 90% correlation of positive intermediate outcome (PIO) (measured radiographically) to positive final outcome (PFO). One can be relatively confident that positive radiographic assessment after 12 weeks, an intermediate outcome, is an accurate predictor of positive final outcome (healing with no further surgery).



A detailed analysis of my radiographic assessment and that of the independent radiologist (Barrington) on the same group and the correlation to positive final outcome is as follows:

**Table II**

Delayed Union Study

Correlation Between Positive Intermediate Outcome (PIO) and Positive Final Outcome (FFO)

ASSESSMENT	GROUP	POSITIVE OUTCOME	
		INTERMEDIATE	FINAL
Sharrard	Active	11	(10/11) 91%
	Control	8	(6/7**) 86%
Barrington	Active	10	(9/10) 90%
	Control	2	(2/2) 100%
Combined *	Active	13 *	(12/13) 92%
	Control	8 *	(6/7**) 96%
	Both Groups	21	(18/20**) 90%

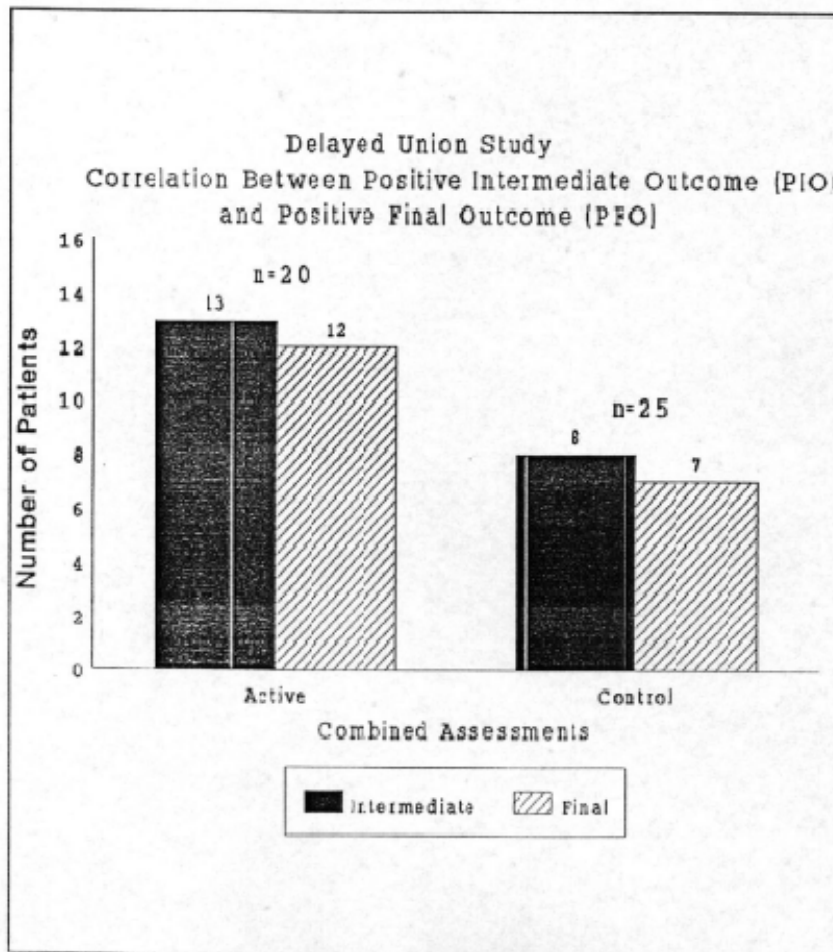
\* Combined Assessment Progressing (P) or Healed (H) at 12 weeks by either Barrington and/or Sharrard.

\*\* One patient (#37) with a positive intermediate outcome at 12 weeks was lost-to-follow-up.

One clinical fact is clear in both groups which is that there is a 90% correlation of positive intermediate outcome to positive final outcome. Thus, it is safe to conclude that positive intermediate outcome (radiographic measurement at 12 weeks) is an accurate predictor of positive final outcome (healing with no final surgery).

This correlation of positive intermediate and positive final outcome is graphically presented in the following figure:

Figure 1



**Question 2: Why was statistical significance shown with radiographic assessment (after 12 weeks) but not with clinical assessment (e.g. movement at the fracture site, pain, and tenderness)? How does one assimilate this into the overall technology assessment when making a determination of efficacy?**

The Panel's second question, related to the statistical significance shown with radiographic assessment (after 12 weeks) but not with clinical assessment (movement at the fracture site, pain, and tenderness) clearly focus in on the Panel's concerns about final health outcomes. Clinical measurements at 12 weeks while providing some valuable clinical insight, are not good evaluative criteria given both their unreliable nature and intermediate status. For example, while movement at a fracture is indicative of failure of union, absence of movement may not necessarily be a reliable indicator of successful union.

Clinical assessment is helpful, but not conclusive at the intermediate point (12 weeks) in the study. Positive radiographic assessment is indeed a better preferred predictor of positive final outcome as shown in the long-term follow-up data provided.

With this issue in mind, it is understandable that there may be some difficulty in reconciling differences in the two assessment methods (radiographic and clinical). Therefore, the final health outcomes status in the data already provided presents BCBSA with a more concise picture of the technology's efficacy rather than intermediate assessments alone.

**Question 3: How do differences in the radiologist's and my evaluation of radiographic assessment affect its significance and overall interpretation?**

The Panel's final question asks, how do differences in the radiologists and my evaluation of radiographic assessment effect their significance and overall interpretation. Fundamentally, we do not see a difference in the evaluations.

Given the radiographic criteria and techniques used in the trial, an objective assessment was possible. This is particularly true since both the radiologist and I were blinded as to radiographic origin until grading was completed.

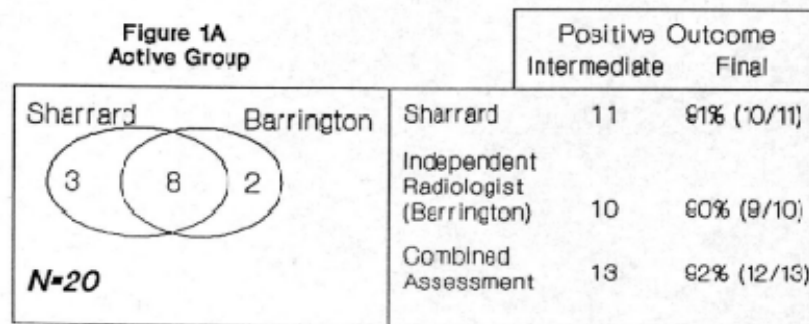
Barrington, as a radiologist, considered union in absolute terms required continuity at 4 cortices. I, as an orthopaedic surgeon considered union to be sufficient to cease treatment when continuity was present over at least half the width of the bone, a category regarded by Barrington as progress to union.

It is relevant to note that all those patients were regarded by me as having united, subsequently healed all 4 cortices, but were not necessarily receiving any further treatment, either by a plaster immobilisation or PEMF treatment.

An analysis of the patients Barrington and I determined (radiographically) as having a positive intermediate outcome confirms this statement.

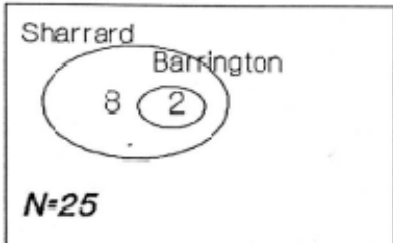
In examining (Figure 1A.) the treatment group, I evaluated 11 of the 20 patients as having a positive intermediate outcome. Assessments by the independent radiologist identified 10 patients as having a similar status. There was substantial agreement on a patient by patient basis with a total of 8 patients common in both blinded assessments. The evaluation (both the radiologist and mine) were similar (90% and 91% respectively) in the portion of patients going on to positive final outcome.

Figure 1A



In the control group at 12 weeks (figure 1B), I evaluated 8 of the 25 patients (32%) as having a positive radiographic assessment. Barrington identified 2 patients as having a similar positive intermediate outcome. Both of his 2 cases were contained in the group of 8 patients I determined favorable assessments on. Respectively, 86% (6/7) and 100% (2/2) of these cases went on to have positive final health outcomes.

Figure 1B

Figure 1B Control Group		Positive Outcome	
		Intermediate	Final
 <p>Sharrard Barrington 8 2 N=25</p>	Sharrard	6	86% (6/7)*
	Independent Radiologist (Barrington)	2	100% (2/2)
	Combined Assessment	6	86% (6/7)*

\* One patient (#37) with a positive intermediate outcome at 12 weeks was lost to follow-up.

Again, it is important to note that in the control group, the patients I gave positive assessments to which went on to heal, contained the 2 patients to which Barrington gave similar assessments.

In either case, both the radiologist and I had relatively equal accuracy in terms of the portion of patients with positive intermediate outcomes that went on to positive final outcome.

Given the fact that we were both blinded as to the radiographic origins until assessment was complete, this is a significant statement concerning the overall accuracy of both of our intermediate findings.

Given this review, let me offer the following:

- Positive intermediate outcomes (as measured radiographically at 12 weeks) strongly correlate to positive final outcomes.
- Intermediate clinical assessments are not good evaluative criteria, given their unrealistic nature and intermediate status.
- Upon closer analysis, there is no fundamental differences in the radiographic assessments given by Barrington and me.

I agree that the important evaluative criteria for your assessment should be founded on final patient outcome. The data contained herein supports the use of PEMF in achieving the desired patient outcome (healing without further intervention).

Given the technology's proven biological effect and positive contribution to patient health outcomes, PEMF therapy which should be made available to physicians as an alternative to other interventional treatment irrespective of time. In general, PEMF treatment of difficult ununited fractures has proven to be as successful as traditional noninvasive fracture management and as efficacious as surgical intervention.

Given the costs and potential risks of surgery, PEMF should be considered as a viable treatment option for orthopaedists treating difficult fractures.

Thank you for having taken this opportunity to review this data.

Sincerely,



W.J.W. Sharrard, M.D., Ch.M., FRCS

cc: EBI Medical Systems, U.S.A.

D-1-3

**A DOUBLE-BLIND TRIAL OF PEMFS FOR DELAYED TIBIAL UNION - CLINICAL FOLLOW-UP.** J. Sharrard, Sheffield S10 5DL, England.

In 1990, the results of a double-blind trial of pulsed electromagnetic fields (PEMFS) for delayed union of tibial fractures was published (*J Bone Joint Surg [Br]* 72B, 147-55), based on radiographic evidence of union after 12 weeks of treatment by plaster immobilization with PEMFS compared with treatment by plaster immobilization alone. The radiological outcome was determined blindly either by myself or by a radiologist colleague. My own orthopaedic assessment had, as its endpoint, radiological evidence of union sufficient to allow treatment by immobilization to cease; in the active group, treated by PEMFS, 11/20 showed good progress to union compared with 8/25 controls. The radiologists assessment had, as its endpoint, purely radiographic evidence of bony union; in the active group 10/20 showed union or good progress to union compared with 2/25 controls. If the results in the two assessments are combined, progress to union was present in 13/20 (65%) in the active group and 8/25 (32%) in the control group, a highly significant result ( $p = 0.009$ ) and indicating that PEMFS do influence bone healing assessed radiologically. A positive radiological result is, however an intermediate result. To determine whether radiographic evidence of healing after 12 weeks was able to predict a final outcome of successful fracture union with restoration of bone function without the need for surgical treatment, long-term clinical data were collected and analyzed. After the end of the study, the choice of further treatment was left to individual surgeons, depending on the condition of the patient. Some patients were allowed to mobilize; 8 patients who had previously received placebo treatment, requested active PEMF treatment; others were treated by bone grafting or other surgical means. The clinical condition of all the 45 patients who engaged in the trial was reviewed at an average interval of 2 years (median 15 months) after the initiation of treatment in the trial. Three patients, all of them in the control group, were lost to follow-up. Healing without surgical treatment occurred in 17/20 (85%) of the active treatment group compared with 8/20 (36%) in the control group ( $p = 0.00134$ ). Of the 8 patients in the control group who opted for PEMFS treatment at the end of the double-blind study, 6/8 went on to heal without surgery and 2/8 required surgical treatment. The aim of treatment of delayed union or non-union of a fracture by PEMFS is to enhance union by conservative management. This end-result study confirms that PEMFS significantly influence the final outcome of fracture union and can be regarded as an alternative, or, in complex or infected fractures, as preferred treatment to surgical management.

D-1-4

**EFFECT OF PULSED ELECTROMAGNETIC FIELDS (PEMF'S) ON BONE FORMATION AND BONE LOSS DURING LIMB LENGTHENING: A PRELIMINARY REPORT.** K.S. Eyres and M. Saleh. University Department of Orthopaedics, Sheffield, England.

We have studied prospectively the effect of pulsed electromagnetic fields (PEMF's) on bone formation and disuse osteoporosis sustained during limb lengthening in a double-blind study. Over an eighteen month period, 7 males (mean age 13 years, range 11 to 19 years) and 6 females (mean age 12 years, range 9 to 19 years) randomly received either an active or a dummy unit. Limb lengthening was performed by the Villarrubias technique with a unilateral external fixator system (Orthofix or Sheffield fixator) in 11 patients (85%) and a circular frame system in the remaining two patients (Ilizarov and Sequoia respectively). Bone density measurements were made using dual energy X-ray absorptiometry (DXA) with a specially modified low-threshold analysis programme.

7 patients (2 males and 5 females) received 'active' coils and 6 patients (4 males and 2 females) received 'dummy' coils. Although there was no significant age difference between the two groups (14.4 years and 13.6 years respectively), 10 segments (8 tibial and 2 femoral) were lengthened in the 'active group' compared to only 8 segments (6 tibial and 2 femoral) in the 'dummy group'.

Whereas there was no significant bone loss detected in patients treated with active coils until 2 months after surgery (reduced by  $10\% \pm 2\%$  control values), marked losses occurred earlier in the patients treated with dummy coils (reduced by  $23\% \pm 3\%$  and  $33\% \pm 4\%$  after one and two months respectively;  $p < 0.0001$ ). These difference were greater at twelve months after surgery (reduced by  $87\% \pm 4\%$  and  $46\% \pm 5\%$  respectively;  $p < 0.0001$ ). Although there was no significant effect on new bone formation with active PEMFS, there was a significant reduction in disuse osteoporosis. Further study with PEMFS of different waveform is required to assess their effect on bone formation.

D-1-5

**THE TREATMENT OF OSTEONECROSIS OF THE FEMORAL HEAD WITH PEMF.** R.K. Aaron<sup>1</sup> and B.A. Pethica<sup>2</sup>.  
<sup>1</sup>Orthopaedic Research Laboratory, Brown University, Providence, RI 02906 USA. <sup>2</sup>Columbia University, New York, NY 10012 USA.