

Chapter 48

Barbiturates

Synonyms

Pentobarbital poisoning, sodium pentobarbital poisoning

Cause

Barbiturate products are commonly used to euthanize domestic animals. The primary active component in euthanasia solutions is sodium pentobarbital, but some products also contain other minor ingredients (Fig. 48.1).

Euthanasia solutions are generally injected intravenously in domestic animals; therefore, after death, the solutions will be most concentrated in the blood and the highly vascularized organs, such as the liver or spleen, of the euthanized animal.

Euthanized carcasses that are available as carrion pose a hazard to scavenging birds and mammals. Large domestic animal carcasses, such as horses, that are not used for food or rendering but that are sufficiently valuable (monetarily or psychologically) to warrant veterinary services and euthanasia drugs are the most common sources of barbiturate poisoning in scavengers. In one instance in British Columbia, a single cow carcass was responsible for poisoning 29 bald eagles.

Circumstances that interfere with burial, such as frozen winter soil or bulky carcasses, result in euthanized carcasses being available for scavenger species. This problem could increase in the future if more stringent air-quality standards restrict carcass incineration.

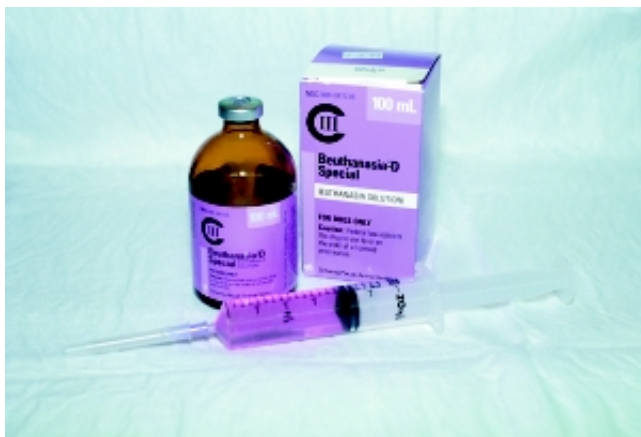

Figure 48.1 The active agent in most injectable euthanasia solutions is sodium pentobarbital.

Species Affected

Bald and golden eagles are the only free-living wildlife species that have been reported to have died of barbiturate poisoning. Raptors generally have a narrow tolerance for barbiturate compounds; therefore, an anesthetic dose is often close to a fatal dose in these species.

Distribution

As of 1997, the National Wildlife Health Center database contained records of 17 cases of barbiturate poisoning in eagles from six States (Fig. 48.2). Additional cases have been reported by other investigators.

Seasonality

Cases of barbiturate poisoning have been more frequent in late winter and early spring, but they are not confined to that period. Cases of barbiturate poisoning may be correlated with the spring thaw in northern climates, when carcasses thaw, and the internal organs become more readily available to scavengers. Residues in those carcasses become available to scavenger species at that time. Food supplies are often limited at this time, so scavenging is more common.

Field Signs

The most useful and specific field sign is the proximity of dead or moribund birds to a euthanized animal carcass that shows evidence of scavenging. In lieu of that, the proximity of dead or moribund birds to a domestic animal carcass of unknown origin is a less specific sign, but under that circumstance, barbiturates should be considered along with other poisons, such as pesticides.

Barbiturate-poisoned birds have been found near landfills in which euthanized animal carcasses were discarded. Landfills are legal disposal sites for carcasses in some States or locales.

Barbiturate poisoning may take hours to develop; therefore, poisoned birds can be found distant from the poison source. Eagles have been found beneath their roost trees without evident sources of poisoning.

Barbiturate-intoxicated birds are sedated, drowsy, sluggish, or comatose; have varying degrees of consciousness; and have slow heart and respiration rates. Although they may struggle to right themselves if they fall from a perch as toxicity progresses, signs of prolonged or violent struggling are unlikely. They are more likely to be found on undisturbed substrate. If more than one bird is exposed, the dose ingested and susceptibility to the poison may vary with each bird;

Photo by Nancy Thomas

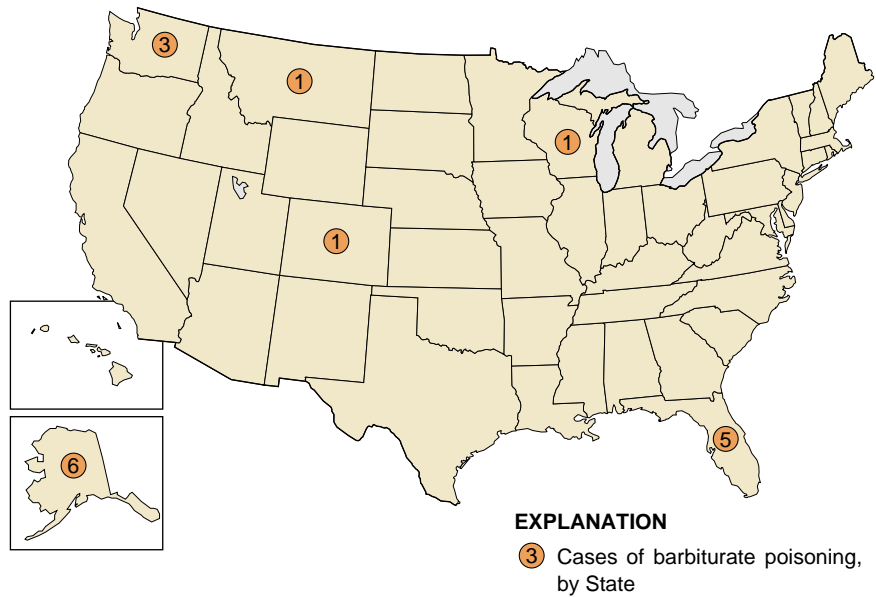


Figure 48.2 Seventeen cases of barbiturate poisoning in bald and golden eagles have been reported by the National Wildlife Health Center from six States as of 1997.

therefore, a range of signs from sublethal sedation to coma to death may be observed. Birds that are sedated or even comatose can recover if they are given supportive care until they metabolize the drug. Recovery may take several days.

Gross Lesions

There are no specific lesions. Ingesta may be present in the upper gastrointestinal tract as in other acute poisonings. The ingesta may be recognizable as domestic animal in origin. Barbiturate-poisoned birds are often in good body condition, thus reflecting the acute nature of this toxicosis.

Diagnosis

Analysis of liver or upper gastrointestinal contents detects pentobarbital and, sometimes, other components of euthanasia drugs. Liver analysis is more definitive for determining that a bird absorbed drug from the ingesta. Blood samples from live birds can be analyzed, but the clinical and field signs and the bird's recovery may be sufficient for a presumptive diagnosis.

Samples of blood-engorged organs, blood clots, or other tissue from scavenged sites in the suspect domestic animal carcass can assist in tracing the source of the poison.

Control

Treatment

Birds found alive in the field are often hypothermic (exhibiting low body temperature); warming of less affected birds, in itself, may result in recovery. A veterinarian can provide supportive care, administer cardiac and respiratory stimulants, and remove the undigested crop contents so that no further drug is absorbed.

Management

State agricultural departments in the United States generally regulate carcass disposal to assure that carcasses are not available to scavengers. Circumstances such as frozen ground that prevents burial, poor compliance with regulations, or shallow burial may circumvent these regulations. Landfill regulations or policy can guarantee that carcasses are covered before scavenging is likely.

Cases of barbiturate poisoning are generally inadvertent. Prevention can be greatly enhanced by increasing awareness of the hazard among the public and veterinary community.

Human Health Considerations

None. Euthanized carcasses are not for human consumption. Barbiturates are not absorbed through the skin.

Nancy J. Thomas

Supplemental Reading

Langlier, K.M., 1993, Barbiturate poisoning in twenty-nine bald eagles, in Redig, P.T., and others, eds., *Raptor Biomedicine*: Minneapolis, Minn., University of Minnesota Press, p. 231–232.