

Acanthocephaliasis

Synonyms

Thorny-headed worms, acanths

Cause

The phylum Acanthocephala contains parasitic worms referred to as thorny-headed worms because both the larval and adult parasites have a retractable proboscis or a tubular structure at the head, which has sharp, recurved hooks or spines. Much like the cestodes or tapeworms, they lack di-

gestive tracts and absorb nutrients from the bird's intestinal canal. This may weaken the bird and may make it more susceptible to other diseases and to predation.

Adult acanthocephalans are found in a variety of bird species and in other vertebrates. More than 50 species of acanthocephalans have been reported in waterfowl, but reevaluations of acanthocephalan taxonomy are resulting in revised speciation. Nevertheless, numerous species within the phylum are found in birds.

Definitive bird hosts

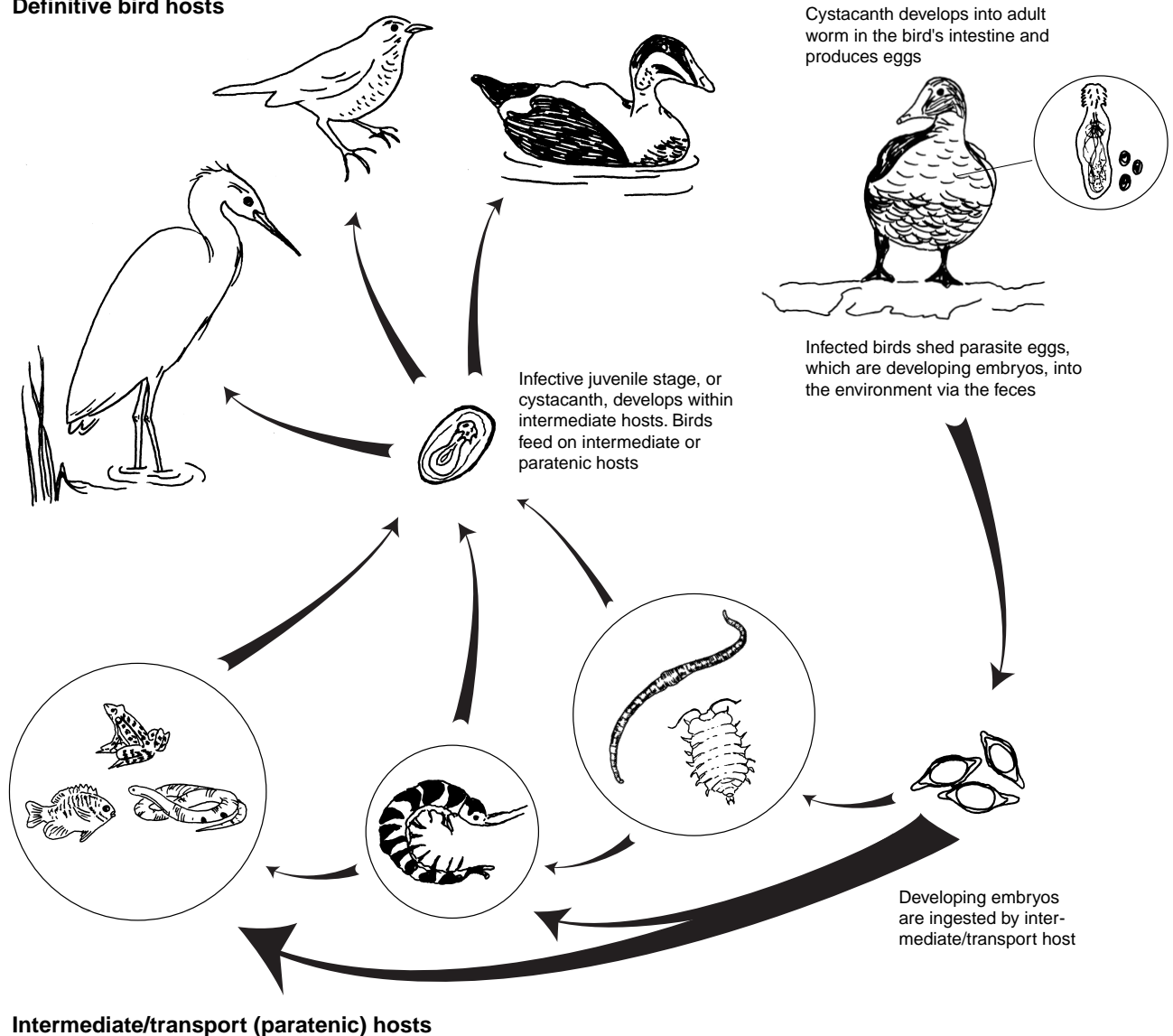


Figure 33.1 Indirect life cycle of acanthocephalan worms.

Life Cycle

All acanthocephalan species thus far examined have an indirect life cycle (Fig. 33.1) that requires at least one intermediate host. Intermediate hosts tend to be preferred food items of the definitive host; thus, the parasite also uses the intermediate host as a means of transport to the definitive host. Crustacea of the orders Amphipoda, Isopoda, and Decapoda have been identified as common intermediate hosts of acanthocephalans that infect waterfowl. Some acanthocephalans that affect passerines or perching birds are reported to use terrestrial insects as intermediate hosts. Fish, snakes, and frogs have been identified as paratenic hosts in the life cycle of some acanthocephalans that infect birds.

The adult female parasite within the definitive bird host produces eggs that are passed with the bird's feces into the environment. When the egg is ingested by the intermediate host (insect, crustacean, or centipedes and millipedes), the infective juvenile stage or cystacanth develops within the intermediate host. In many life cycles of acanthocephalans, if this intermediate host is eaten by a vertebrate host which is unsuitable as a definitive host, the cystacanth will penetrate the vertebrate's gut, encyst and cease development. This vertebrate is now a paratenic host. If the paratenic or intermediate host is eaten by a suitable definitive host the cystacanth will attach to the definitive host's intestinal mucosa via the spined proboscis, mature, mate and produce eggs. A change in body coloration has been noted in some crustaceans infected with certain species of acanthocephalan. It is thought that this change in color increases predation by definitive hosts. This might be an evolutionary adaptation which increases the chances of life cycle completion by the acanthocephalan.

Species Affected

Acanthocephalans infect all classes of vertebrates and are common in birds. Ducks, geese, and swans are considered to be the most commonly infected birds along with birds of prey, and some species of passerines. All age classes can become infected. Severe disease outbreaks have been repeatedly reported from common eiders. Eider mortality from acanthocephalans has been documented throughout the arctic areas of their range and has been attributed to food habits rather than to any increased susceptibility of their species. Historical U.S. Fish and Wildlife Service disease diagnostic records reported heavy infections of acanthocephalans and mortality in trumpeter swans from Montana.

Distribution

Worldwide.

Seasonality

Birds can be infected with acanthocephalans yearround. Epizootics usually correspond with food shortages, exhaustion (resulting from migration or breeding), or stressful cir-

cumstances. Mortality in immature and adult male eiders is commonly seen in late winter and early spring. Adult females experience mortality during or after brooding. Eider ducklings often suffer from both acanthocephalans and renal coccidia. Swan cygnets are also susceptible to lethal infections.

Field Signs

Lethargy and emaciation are nonspecific but common clinical signs associated with severe infections.

Gross Lesions

Gross lesions include white nodules on the serosal or external surface of the intestine (Fig. 33.2). Dissection of the nodules will reveal the proboscis of an acanthocephalan. Examination of the intestinal mucosa or internal lining will reveal white-to-orange colored parasites that are firmly attached to the mucosa (Fig. 33.3). Some parasites can penetrate the gut wall and project into the abdominal cavity. Adhesions between the loops of intestine are not uncommon in the severe cases where the intestine has been penetrated.

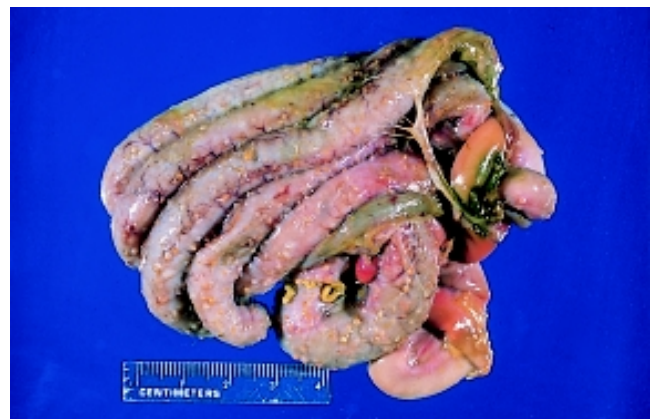

Photo by J. Christian Franson

Figure 33.2 Intestinal loops of a bird infected with acanthocephalans. Parts of the worms protrude through the intestinal wall.

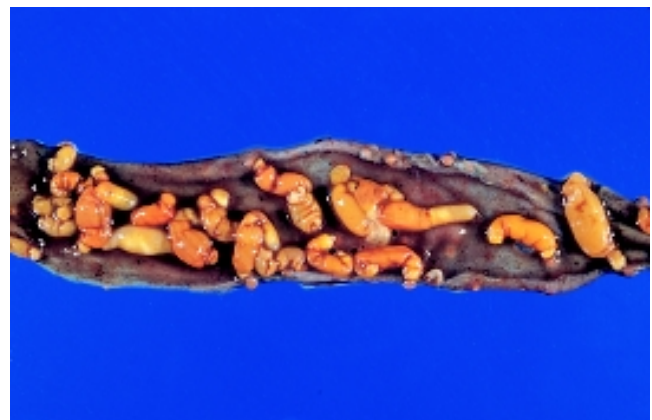


Photo by R.A. Cole

Figure 33.3 Acanthocephalans attached to the inner surface of the intestine of a bird.

Diagnosis

Postmortem examinations are required to reach a diagnosis of cause of death. When possible, submit chilled carcasses for evaluation. Fecal evaluations can be used for determining the presence of infection, but they do not provide a definitive diagnosis of disease. Evaluation by a parasitologist is required to differentiate the acanthocephalan species. If chilled carcasses cannot be submitted, the following alternatives in order of preference are: whole refrigerated intestine, frozen intestine, and formalin-fixed intestine. The formalin-fixed intestine may prohibit species identification but it will allow identification to the genus level as well as assessments of worm burden and tissue response to the parasites.

Control

Control of acanthocephaliasis in free-ranging birds is not practical. Captive flocks can be managed so that aggregations of birds and crustaceans are minimized. One approach that has been suggested for captive flocks is to limit infection in young birds by segregating them on water areas that are not used by other birds. These segregated water areas will presumably have much lower numbers of infected intermediate hosts for the birds to be exposed to. Acanthocephalans that infect mammals have been successfully treated with ivermectin or fenbendazole. Thiabendazole has been recommended for use in birds, but treatment is acknowledged to be difficult and success low.

Human Health Considerations

None

Rebecca A. Cole

Supplementary Reading

- Bowman, D., 1995, *Parasitology for veterinarians* (6th ed.): Philadelphia, Pa., W.B. Saunders, 430 p.
- Crompton, D.W.T. and Nichol, B.B., 1985, *Biology of the Acanthocephala*: Cambridge, England, Cambridge University Press, 519 p.
- McDonald, M.E., 1988, Key to acanthocephala reported in waterfowl: U.S. Fish and Wildlife Service, Resource Publication 173, Washington, D.C., 45 p.
- Wobeser, G.A., 1997, *Acanthocephala*, in *Diseases of wild waterfowl* (2nd ed): New York, N.Y., Plenum Press, p. 145–146.

