



MOUNT SINAI SCHOOL OF MEDICINE,
UNIVERSITY OF ROCHESTER SCHOOL OF MEDICINE,
ST. JOSEPH'S HOSPITAL, AND
WESTCHESTER COUNTY DEPARTMENT OF HEALTH

A Cluster of Pediatric Metallic Mercury Exposure Cases Treated with *meso*-2,3-Dimercaptosuccinic Acid (DMSA)

Joel Forman,¹ Jacqueline Moline,² Elsa Cernichiari,³ Sammi Sayegh,⁴ J. Carlos Torres,⁵ Mary M. Landrigan,⁵ Jean Hudson,⁵ Harold N. Adel,⁵ and Philip J. Landrigan^{1,2}

¹Department of Pediatrics, and ²Department of Community and Preventive Medicine, Mount Sinai School of Medicine, New York, New York, USA; ³Environmental Health Sciences Center, University of Rochester School of Medicine, Rochester, New York, USA; ⁴St. Joseph's Hospital, Yonkers, New York, USA; ⁵Westchester County Department of Health, New Rochelle, New York, USA

Nine children and their mother were exposed to vapors of metallic mercury. The source of the exposure appears to have been a 6-oz vial of mercury taken from a neighbor's home. The neighbor reportedly operated a business preparing mercury-filled amulets for practitioners of the Afro-Caribbean religion Santeria. At diagnosis, urinary mercury levels in the children ranged from 61 to 1,213 µg/g creatinine, with a geometric mean of 214.3 µg/m creatinine. All of the children were asymptomatic. To prevent development of neurotoxicity, we treated the children with oral *meso*-2,3-dimercaptosuccinic acid (DMSA). During chelation, the geometric mean urine level rose initially by 268% to 573.2 µg mercury/g creatinine ($p < 0.0005$). At the 6-week follow-up examination after treatment, the geometric mean urine mercury level had fallen to 102.1 µg/g creatinine, which was 17.8% of the geometric mean level observed during treatment ($p < 0.0005$) and 47.6% of the original baseline level ($p < 0.001$). Thus, oral chelation with DMSA produced a significant mercury diuresis in these children. We observed no adverse side effects of treatment. DMSA appears to be an effective and safe chelating agent for treatment of pediatric overexposure to metallic mercury. **Key words:** children, 2,3-dimercapto-1-propane sulfonic acid, DMPS, DMSA, *meso*-2,3-dimercaptosuccinic acid, metallic mercury, overexposure, treatment. *Environ Health Perspect* 108:575–577 (2000). [Online 5 May 2000] <http://ehpnet1.niehs.nih.gov/docs/2000/108p575-577forman/abstract.html>

Case Presentation

In January and February 1998, nine children (in one family) and their mother were exposed to vapors of metallic mercury in their apartment in Yonkers, New York. The apparent source was a neighbor's business, where mercury-filled amulets were reportedly prepared for practitioners of the Afro-Caribbean religion Santeria. The oldest child found a 6-oz vial of mercury on the neighbor's porch. Over the next several days, the children played a game in which they hit a large globule of mercury with a hammer and observed its dispersion across a wooden floor. Mercury was then tracked throughout the apartment. The mother attempted over the next week to remove the mercury with a vacuum cleaner, but only dispersed it further.

The mother took the children to a pediatrician in Yonkers, who promptly obtained urine samples for mercury analysis. After finding elevated levels of mercury in the samples, he referred the children to the Pediatric Environmental Health Specialty Unit of the Mount Sinai Hospital where all nine were hospitalized. On admission, we did not

detect tremor, other neurologic abnormalities, or other signs of mercury poisoning in any of the children. To prevent development of neurotoxicity, we initiated treatment of all nine children with oral *meso*-2,3-dimercaptosuccinic acid (DMSA). We collected 24-hr urine samples for mercury and creatinine determinations on each child throughout the admission and periodically after discharge.

Pretreatment urinary mercury levels ranged from 61 to 1,213 µg/g creatinine, with a geometric mean of 214.3 µg/g creatinine (Figure 1); the upper limit of normal recommended by the World Health Organization (WHO) is 50 µg mercury/g creatinine (1). Initially, the children were treated with 30 mg/kg/day DMSA for 5 days. The geometric mean of all measurements obtained during inpatient chelation rose by 268% above baseline to 573.2 µg mercury/g creatinine ($p < 0.0005$). The children were then discharged and continued to receive treatment with 20 mg/kg/day DMSA at home for 2 more weeks. Six weeks after discharge all nine children showed reduced urine mercury levels ranging from 71 to 239 µg/g creatinine.

The geometric mean of these follow-up levels (day 54 after initial chelation) was 102.1 µg mercury/g creatinine, which was 17.8% of the geometric mean level during inpatient treatment ($p < 0.0005$) and 47.6% of the baseline level ($p < 0.001$). Because the follow-up values still exceeded 50 µg mercury/g creatinine, we prescribed an additional 2-week course of DMSA for all nine children. Urine mercury levels obtained several months later (day 261 after initial chelation) had dropped to 27.4 µg/g creatinine. At this point, two of the children (cases #3 and #4) still had levels > 50 µg mercury/g creatinine, and they received a final course of DMSA chelation. We learned that the family, who had been relocated, had brought along a mercury-contaminated couch from their old apartment. This source, which may have contributed to the two persistently elevated levels, was removed. Twelve months after initial chelation, urine mercury levels in these two children were 11 and 9 µg/g creatinine (Table 1).

Discussion

Metallic mercury is toxic to the nervous system, kidneys, and skin (2). The neurologic manifestations of high-dose poisoning include

Address correspondence to J. Forman, Department of Pediatrics, Mount Sinai Medical Center Box 1202A, One Gustave L. Levy Place, New York, NY 10029-6574 USA. Telephone: (212) 241-0938. Fax: (212) 427-4561. E-mail: joelforman@bigfoot.com

We thank J.H. Graziano, T.W. Clarkson, W. Suk, and H.V. Aposhian for their generous advice and consultations. We also thank C. Schechter for his invaluable assistance with the statistical analysis of the data. Additionally, we acknowledge the technical expertise and services of M. Langdon.

This work was made possible by grants from the National Institute of Environmental Health Sciences (P01 ES09584) and the U.S. Environmental Protection Agency (R827039-01-1); the Agency for Toxic Substances Disease Registry (TS256-13/14); and the generous support of the Mount Sinai Auxiliary Board.

Received 20 July 1999; accepted 31 January 2000.

tremor as well as pathologic shyness, memory loss, delusions, and hallucinations. This neurologic syndrome, termed erethism, is seen most commonly in workers with poorly controlled, high-dose occupational exposure to metallic mercury (3). At lower levels of exposure, metallic mercury causes subclinical neurologic injury characterized by shortened attention span and decreased intelligence (4). In the kidneys, metallic mercury causes proteinuria, nephrotic syndrome, and, in extreme cases, renal failure. In children, metallic mercury can cause acrodynia, a syndrome characterized by swelling and erythema of the hands and feet, with bright pink peeling skin, especially on the tips of the fingers and toes (5).

Although detailed studies of subtle neurologic effects of metallic mercury overexposure in children are not available, it seems reasonable to anticipate that children are at higher risk of toxicity than adults are. Children's patterns of play are near the ground, and their

normal oral exploratory behavior increases their risk of exposure. Children's nervous systems are undergoing rapid development and differentiation, and the developmental process is easily disrupted by toxic exposures (6). In addition, children have a natural fascination with the liquid properties of metallic mercury. The information available on the detrimental neurologic effects to children of low-level lead exposure (7,8) heightens concern about the potential of metallic mercury to be a pediatric neurotoxin at relatively low-dose exposure.

Inhalation is the most common route of pediatric exposure to metallic mercury. At room temperature, mercury exerts a significant vapor pressure, and approximately 80% of inhaled mercury vapor is retained in the body (9). Infants and young children are at particularly high risk of exposure to mercury vapor because they tend to play near to the ground where the heavier-than-air vapor settles (10). Neither ingestion nor percutaneous

absorption are important routes of exposure, and swallowed metallic mercury is poorly absorbed from the gut. Mercury readily crosses the placenta, and levels in mother and fetus are virtually identical.

Potential sources of metallic mercury exposure for children include

- Household contamination with mercury that has been brought into the home from a school or place of work; such household contamination may be especially dangerous in mobile homes because of their poor interior ventilation
- Latex paint containing a mercury fungicide; pediatric exposure to such paint has been reported to cause acrodynia (11)
- Residence in mercury-contaminated former factory buildings that have been converted to loft apartments (12)
- Exposure to liquid mercury that is used in some cultures for religious or medicinal purposes. Metallic mercury has been reported to be used for these purposes by the some members of the Latino and Afro-Caribbean Communities in New York City (13).

Treatment of metallic mercury poisoning had until recently been limited to two options, both relatively unsatisfactory: British anti-lewisite (BAL) or D-penicillamine. The utility of BAL is limited in children by the need for repeated, painful deep muscular injections and also by the propensity of BAL to accelerate redistribution of mercury in body tissues, particularly to the brain; thus BAL can potentially aggravate systemic toxicity (14,15). Use of D-penicillamine is limited by its high incidence of allergic reactions, including cross-reactions with penicillin (16).

More recently, two oral chelating agents have become available in the United States: DMSA and 2,3-dimercapto-1-propane sulfonic acid (DMPS) (17,18). These compounds are chemical analogs of BAL. Because these compounds are absorbed from the gastrointestinal tract, both can be administered orally. Both have shown efficacy in animals as well as in humans in increasing the urinary excretion of mercury (16–21). The Food and

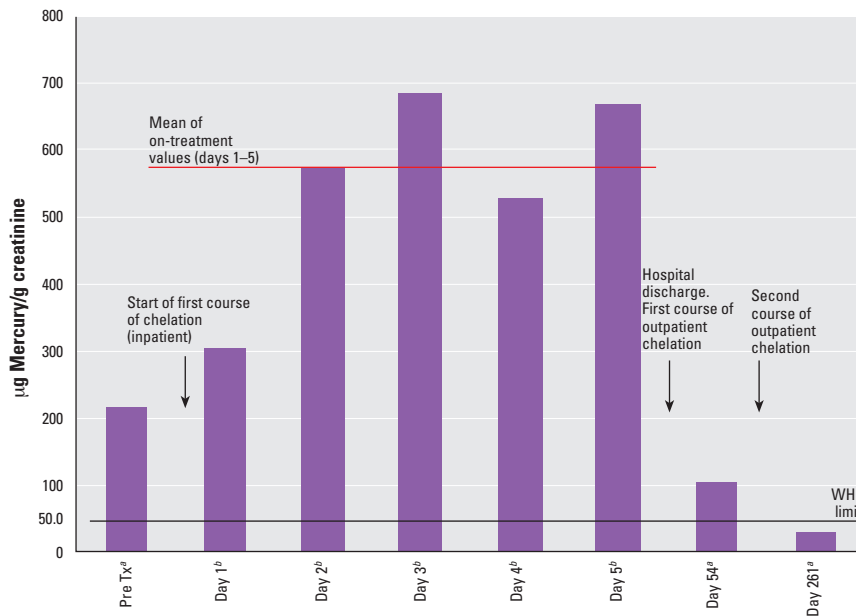


Figure 1. Geometric mean urine mercury levels in nine metallic mercury-overexposed children chelated with DMSA. Tx, treatment.

^aSpot urine samples. ^b24-hr collections.

Table 1. Urine mercury levels (µg mercury/g creatinine) in nine metallic mercury-overexposed children treated with DMSA.

Pt ID	Pt age	Pre Tx	Days of treatment ^a					Follow-up visits		
			Day 1	Day 2	Day 3	Day 4	Day 5	Day 54	Day 261	12 Months
1	5.5	174	221	<i>b</i>	560	581	580	106	15	
2	4.5	125	168	775	425	420	738	71	43	
3	1.5	439	649	<i>b</i>	1,857	2,266	1,125	123	187	11
4	1.5	1,213	427	419	1,223	551	924	239	62	9
5	0.25	130	109	293	<i>b</i>	439	628	77	35	
6	12	476	<i>b</i>	<i>b</i>	506	<i>b</i>	<i>b</i>	132	13	
7	12	236	439	<i>b</i>	<i>b</i>	230	581	77	15	
8	7.5	83	494	480	<i>b</i>	552	708	95	17	
9	13.5	68	<i>b</i>	1,338	374	353	347	73	10	
GM ^c		214.3	304.6	571.8	683.9	527.5	668.5	102.1	27.4	

Abbreviations: GM, geometric mean; Pt, patient, Tx, treatment.

^aDays 1–5 are 24-hr urine collections; all other days are spot urine levels. ^bMissing data elements are due to damaged labels or lost specimens. ^cGM of all on-treatment values (days 1–5) = 573.25 µg mercury/g creatinine.

Drug Administration has, to date, licensed DMSA only for treatment of pediatric lead poisoning.

This paper represents, to our knowledge, the largest published clinical case series describing the use of oral DMSA for the treatment of overexposure to metallic mercury in children. Our data on the rapid increase of mercury diuresis immediately following initiation of oral chelation therapy with DMSA argue that DMSA is an effective chelating agent for treatment of pediatric overexposure to mercury. Without treatment, the children would be expected to undergo a much slower diuresis, with steadily declining urine mercury levels over a period that is consistent with the half-life of metallic mercury (roughly 1–2 months) (22). These data are also consistent with previous studies that showed DMSA to be efficacious in the treatment of mercury poisoning in both animals and humans (19–21).

Our study contained no untreated comparison group. Although it would have been interesting scientifically to compare mercury diuresis between treated and untreated children, the threat of neurotoxicity was too great in these children, with their highly elevated urine mercury levels, to justify withholding DMSA.

We would, ideally, have wished to compare DMSA to DMPS in this study to judge the relative efficacy of these two chelating agents in treatment of metallic mercury overexposure. The International Programme on Chemical Safety (IPCS) of the WHO has recommended that DMPS be considered the “drug of first choice for cases of acute poisoning with inorganic mercury” (17). The IPCS also notes, however, that DMPS is somewhat more toxic than DMSA and that DMSA is also effective against mercury. Unfortunately, DMPS was not immediately available to us in this situation, whereas DMSA was readily accessible through the hospital pharmacy because of its widespread use as a chelating agent against lead poisoning.

Urine is the body fluid of choice for assessing exposure to metallic mercury. It provides a much more valid index of recent exposure than the blood mercury level. However, it is important to adjust the urine mercury level for creatinine concentration. This was illustrated dramatically in the mother of these nine children, a 31-year-old woman with poorly controlled diabetes and consequent wide swings in urine volume and concentration. She had two urine samples collected within 24 hr at the time of the children’s initial hospitalization. Her unadjusted mercury levels were 6.1 ng/mL (sample #1) and 137.4 ng/mL (sample #2), a 22-fold variation. However, when corrected

for urinary creatinine concentration, the adjusted levels were 22 µg mercury/g creatinine and 45 µg mercury/g creatinine, nearly equivalent values and both < 50 µg mercury/g creatinine.

An unresolved issue in the medical management of pediatric metallic mercury exposure is the level of mercury in urine that should be considered a trigger for initiation of chelation therapy. Symptoms of metallic mercury poisoning may first appear in children at mercury levels of 50–100 µg/g creatinine, and tremor is typically the first symptom observed (23). Unfortunately, detailed epidemiologic studies such as those undertaken to assess dose–response relationships in subclinical lead poisoning in children (7,8,24) have not yet been performed in the case of subclinical mercury exposure. Therefore, we recommend that treatment should be initiated in children with urine mercury levels ≥ 50 µg/g creatinine, as recommended by the WHO (1). This recommendation should be refined through further study.

Another unresolved question is whether the manifestations of mercury intoxication can be reversed by chelation therapy. Preliminary studies in occupationally exposed adults suggest that the effects of adult mercury poisoning are reversible with treatment (25). However, extensive studies of the chronic effects of lower level metallic mercury poisoning have not been undertaken in adults, and even less research has been done in children. Therefore, we recommend that chelation therapy be administered as soon as possible after the diagnosis of overexposure to metallic mercury in the hope that it will minimize the long-term impact of mercury intoxication, although the effectiveness of this method has not been proven. If possible, neurodevelopmental testing may be indicated at the time of exposure and periodically afterward to assess the possibility of residual neurobehavioral impairment.

Conclusion

This case along with other recent cases of pediatric poisoning with metallic mercury remind us of the importance of primary prevention of mercury exposure. Overexposure to mercury is not a rare occurrence. Steps should be taken to limit the availability of mercury. Pediatric practitioners should warn parents and children about the hazards of playing with this perennially attractive but always dangerous metal. If exposure to metallic mercury is suspected, urine samples should be obtained for both mercury and creatinine determinations. Children with urine mercury levels > 50 µg/g creatinine should be considered for oral chelation even if they are asymptomatic.

REFERENCES AND NOTES

1. WHO. Inorganic Mercury. Environmental Health Criteria 118. Geneva:World Health Organization, 1991.
2. Raffle PAB, ed. Hunter’s Diseases of Occupations. 7th ed. Rev. Boston, MA:Little, Brown and Co, 1987.
3. Parkinson DK. Mercury. In: Environmental and Occupational Medicine, 2nd ed (Rom WN, ed). Boston, MA:Little Brown and Co, 1992.
4. Rosenman KD, Valciukas JA, Glickman L, Meyers BR, Cinotti A. Sensitive indicators of inorganic mercury toxicity. Arch Environ Health 41:208–215 (1986).
5. Warkany J. Acrodynia—postmortem of a disease. Am J Dis Child 112:147 (1966).
6. National Research Council. Environmental Neurotoxicology. Washington, DC:National Academy Press, 1992.
7. Needleman HL, Gatsonis CA. Low-level lead exposure and the IQ of children. A meta-analysis of modern studies. JAMA 263:673–678 (1990).
8. Bellinger D, Stoman J, Leviton A, Rabinowitz M, Needleman HL, Wateraux C. Low level lead exposure and children’s cognitive function in the preschool years. Pediatrics 87(2):219–227 (1991).
9. Clarkson TW, Klipper RW. The metabolism of inhaled mercury vapor in animals and man. In: Heavy Metals as Environmental Hazards to Man (Clarkson TW, ed). Rochester, NY:University of Rochester Environmental Health Sciences Center, 1978.
10. ATSDR. Case Studies in Environmental Medicine. Case Study 17: Mercury Toxicity. P5. Atlanta, GA:Agency for Toxic Substances and Disease Registry, 1992.
11. Agocs MM, Etzel RA, Parrish G, Paschal DC, Campagna PR, Cohen DS, Kilbourne EM, Hesse JL. Mercury exposure from interior latex paint. New Engl J Med 323:1096–1101 (1990).
12. Orloff KG, Ulirsch G, Wilder L, Block A, Fagliano J, Pasquale J. Human exposure to elemental mercury in a contaminated residential building. Arch Environ Health 52(3):169–172 (1997).
13. Ojito M. Ritual use of mercury prompts testing of children for illness. New York Times, 14 December 1997;B1.
14. Goldfrank LR, Bresnitz EA, Howland MA, Weisman RS. Mercury. In: Goldfrank’s Toxicologic Emergencies, 4th ed (Goldfrank LR, Flomenbaum NE, Lewin NA, Weisman RS, Howland MA, eds). Norwalk, CT:Appleton and Lange, 1990:641–648.
15. ATSDR. Toxicological Profile for Mercury (update). TP-93/10. P 182. Atlanta, GA:Agency for Toxic Substances and Disease Registry, 1994.
16. Goyer RA, Cherian MG, Jones MM, Reigart JR. Role of chelating agents for prevention, intervention, and treatment of exposures to toxic metals. Environ Health Perspect 103:1048–1052 (1995).
17. Aaseth J, Jacobsen D, Andersen O, Wicksstrom E. Treatment of mercury and lead poisonings with dimercaptosuccinic acid and sodium dimercaptopropanesulfonate. A review. Analyst 120:853–854 (1994).
18. Toet AE, van Dijk A, Savelkoul TJJ, Meulenbelt J. Mercury kinetics in a case of severe mercuric chloride poisoning treated with dimercapto-1-propane sulfonate (DMPS). Hum Exp Toxicol 13:11–16 (1994).
19. Torres-Alanis O, Garza-Ocañas L, Pineyro-Lopez A. Evaluation of urinary mercury excretion after administration of 2,3-dimercapto-1-propane sulfonic acid to occupationally exposed men. Clin Toxicol 33:717–720 (1995).
20. Kostial K, Restek-Sanmarzija N, Blanusa M, Piasek M, Prester LJ, Jones MM, Singh PK. Racemic-2,3-dimercaptosuccinic acid for inorganic mercury mobilization in rats. J Appl Toxicol 17:71–74 (1996).
21. Graziano JH. Role of 2,3-dimercaptosuccinic acid in the treatment of heavy metal poisoning. Med Toxicol 1:155–162 (1986).
22. Clarkson T. Mercury. J Am Coll Toxicol 8(7):1291–1296 (1989).
23. Smith RG, Vorwald AG, Patil LS, Mooney TF Jr. Effects of exposure to mercury in the manufacture of chlorine. Am Ind Hyg Assoc J 31(6):687–700 (1970).
24. Needleman HL, Schell A, Bellinger D, Leviton A, Allred EN. The long-term effects of exposure to low doses of lead in childhood. An 11-year follow-up report. N Engl J Med 322(2):83–88 (1990).
25. Hua M-S, Huang C-C, Yang Y-J. Chronic elemental mercury intoxication: neuropsychological follow-up case study. Brain Inj 10:377–384 (1995).