

Multi-species Disposition Basics with a Public Health Focus



**Public Health Veterinarian Training
USDA FSIS Center for Learning**

Contents

Objectives

Introduction – (agency mission, regulatory basis for dispositions, professionalism in performing dispositions)

Public Health Focus–

Definitions of Terms Used in Making Dispositions

Disposition Thought Process – A Systematic Approach

- Basic Components of Disposition Decision-making
- Principles of Dispositions
- Antemortem Disposition Choices
- Postmortem Disposition Choices
- Examples of the thought process (including diagrams?)
 1. Antemortem
 2. Postmortem

Workshop I

Section I – Diseases and Conditions of Public Health Significance

Livestock

- CNS Conditions at Antemortem
- Septicemia
- Toxemia
- Pyemia
- Contamination (feces, ingesta, milk)
- Beef Cysticercosis
- Swine Cysticercosis

Poultry

- Septicemia/Toxemia
- Contamination (feces)

Workshop II

Section II – Diseases and Conditions Not of Public Health Significance

Livestock

- Abscess
- Arthritis
- Pericarditis
- Pneumonia

- Pleuritis
- Peritonitis
- Mastitis
- Metritis
- Gastritis/Enteritis
- Nephritis
- Erysipelas
- Necrobacillosis
- Caseous Lymphadenitis
- Actinomycosis/Actinobacillosis
- Tuberculosis
- Coccidioidomycosis
- Bruises and Injuries
- Emaciation
- Anasarca
- Miscellaneous Dropsical Conditions
- Uremia
- Sexual Odor of Swine
- Immaturity
- Eosinophilic Myositis
- Skin Conditions
- Asphyxia
- Cysticercosis of sheep
- Sarcocystosis
- Stephanuriasis
- Anaplasmosis
- Melanosis
- Icterus
- Carotenosis
- Xanthosis
- Neoplasms

Poultry

- Airsacculitis
- Inflammatory Process
- Cadavers
- Overscald
- Neoplasms
- Bruises
- Synovitis
- Turkey Osteomyelitis Complex

Workshop III

Multi-species Disposition Basics with a Public Health Focus

Objectives

At the conclusion of this module the trainee will be able to:

1. Describe the thought process used in making a disposition.
2. Identify the public health significance of diseases and conditions found commonly in the slaughter environment.
3. Describe the difference between public health significance and regulatory disposition requirements.
4. Identify diseases and conditions which are required by regulation to result in carcass or parts condemnation.
5. Identify the proper regulatory dispositions in given scenarios using the thought process.

Introduction

The mission of the Food Safety and Inspection Service (FSIS) of the United States Department of Agriculture is to assure the safety, wholesomeness, and proper labeling of meat and poultry for the consumer. The FSIS Public Health Veterinarian (PHV) is responsible for making dispositions of normal and diseased animals, carcasses and their parts. In poultry the PHV is responsible for supervising inspectors who make carcass and parts dispositions.

The disposition of animals is directed by criteria that are found in the Meat and Poultry Inspection Regulations. Familiarity with parts 309 and 311 of the Meat and Poultry Inspection Regulations and current written policies such as FSIS Directive 6240.1 (11/10/94), Bovine Mycobacteriosis Guideline, will greatly facilitate disposition.

A disposition must always be approached as a professional issue; the PHV is expected to make decisions with dispatch, confidence, and consistency. While normal slaughter operations should not be delayed because of hesitant diagnosis/disposition procedures, a PHV is not expected to make "snap" decisions either. For example, a PHV should not feel pressured to pass an animal for slaughter as a "U. S. Suspect" when the PHV has reason to believe that the animal should be held for observation before such a decision is made.

While the consumer is always considered first, a disposition should never be so stringent that any unnecessary waste of product results. A PHV should always be able to defend a disposition with the same evidence and reasoning that would be used in a clinical veterinary setting. Never should the impression be given that a disposition was made lightly or without considering all of the evidence.

Public Health Focus of Disposition Criteria

As a public health agency diseases and conditions that are of public health significance are a priority. The focus of this training will be on the diseases of public health significance. The outcome will be to identify animals on antemortem and postmortem inspection with disease conditions that are reasonably likely to pose a threat to public health. Once the animal or carcass with the disease is identified appropriate steps to address the situation must be taken.

Based on an evaluation by policy, certain diseases and conditions found in the 311 and 381 regulations are considered to be of public health significance. In this evaluation, diseases/conditions are deemed of public health significance if it is reasonably likely to present a meat- or poultry- borne (meat borne) hazard or an occupational hazard to the public and/or FSIS inspection personnel. Food safety hazards of public health significance may contain infectious agents (bacteria, virus, rickettsial, fungus, protozoa or helminth organism) that may cause a food to be unsafe for human consumption. Occupational hazards of public health significance may be transmitted to employees in the slaughter/processing work environment. Diseases that are of public health significance, but do not occur in this country are also included. VPHs should be vigilant in watching for and detecting signs of foreign animal disease. In the 9 CFR 311 and 381

regulations there are several pathologic conditions listed that are caused by an underlying disease. The underlying disease, not the condition itself, would serve to indicate if the pathologic condition is of public health significance. Septicemia, Pyemia, and toxemia are considered food safety hazards by FSIS and are deemed of public health significance in this paper because of the probability that the underlying condition, not always determined organoleptically while conducting postmortem inspection, may be reasonably likely to pose a threat to public health.

Many conditions found in the regulations are not of public health significance. Conditions with consumer-protection implications were taken from HIMP (HACCP –based inspection models project) material and it has been used to categorize these conditions found in 9 CFR 311 and 381. HIMP is a pilot project designed to develop, in plants, approaches based on the pathogen reduction and hazard analysis and critical control point (HACCP) regulations to slaughtering inspection of young, healthy and uniform animals and birds and to improve on the utilization of online slaughter inspectors. As part of the development of HIMP, animal diseases and conditions observable at postmortem inspection that pose food safety hazards or risks needed to be distinguished from diseases and conditions that present other consumer protection issues. Conditions under consumer-protection implications may adulterate product, but are not food safety hazards. In the consumer-protection implication (CPI) category, localized lesions are removed and the unaffected portion of the carcass is passed. Carcasses with generalized conditions would be condemned or treated to render non-infective.

The regulations outline many diseases and conditions for which removal and/or condemnation is required by law. These diseases and conditions are not always of public health significance, but do require removal and/or condemnation under the regulations as adulterants. Focusing on diseases of public health significance should not be seen as changing, or detracting from the regulatory requirements to remove other conditions seen as product adulteration. Product adulteration and condemnation requirements of the acts and the regulations must be followed. The mission of FSIS as a premier public health regulatory agency is to protect the public health by ensuring that meat and poultry are safe and wholesome. Consistent with that mission is training the PHV to be cognizant of diseases of public health significance and their critical role of ensuring that livestock and poultry disease that are reasonably likely to pose a threat to public health are identified and that affected carcasses are appropriately addressed. The public health focus will ensure that FSIS regulations and occupational safety guidelines are fully followed to protect the public health.

Definitions of Terms Used in Making Dispositions

There are some terms that are used in the regulations and guidance documents that need to be defined and understood by the PHV.

Terms applicable to neoplasia

Neoplasm/Neoplasia/Tumor - Any new and abnormal growth of tissue serving no physiological function; specifically, a growth of tissue in which the growth is uncontrolled and progressive.

Neoplastic - Pertaining to or having the characteristics of a neoplasm.

Benign - Term used to assess the behavior of a neoplasm. Benign neoplasms are characterized as being typical of the tissue of origin (well differentiated), noninvasive, purely expansive, circumscribed, and not likely to metastasize.

Malignant - Term used to assess the behavior of a neoplasm. Malignant neoplasms are characterized as being atypical of the tissue of origin (undifferentiated), infiltrative as well as expansive and hence not strictly circumscribed, and frequently metastatic.

Metastasis - The transfer of neoplastic tissue from one organ or part to another organ or part not directly connected with the neoplasm. The process may occur as a result of the transfer of cells via the general circulation, the lymphatic system, or within a body cavity (transcelomic).

Metastasize - To form new foci of neoplasia in another organ or part not directly connected with the original neoplasm. The capacity to metastasize is a characteristic of all malignant tumors.

Terms that apply to inflammatory lesion description for individual organs or parts

Note: Grossly, inflammatory lesions are described according to their dominant features and are best classified according to their degree, duration, distribution, and type of exudate. Lesion classification does not translate directly into a disposition. Lesion classification is an aid to understanding the overall disease process in a carcass at the time of slaughter.

Slight/Mild - Small in size, quantity, or number; of no significance; so small or unimportant or of so little consequence as to warrant little or no attention. As applied to certain liver abnormalities, slight means that the lesions are small and few. As applied to tuberculosis lesions in lymph nodes, slight means that the lymph node is of normal size and has more normal than diseased tissue.

Moderate - Avoiding extremes of expression, having an average or less than average quality, limited in scope, tending toward the average amount or dimension.

Marked - Having a distinctive or emphasized character, attracting notice or attention; noticeable, unlikely to escape observation; prominent, stands out from its surroundings or background; conspicuous, is obvious or unavoidable to the sight.

Well-marked - The same as marked but to a higher degree. As applied to tuberculosis lesions in lymph nodes, well-marked means that the lymph node is enlarged, or that the lymph node is of normal size but has more diseased than normal tissue.

Severe - To a great degree; serious, having important possible consequences; intense; having or showing a characteristic in extreme degree.

Diffuse/Extensive/Generalized - Not definitely limited, concentrated, or localized, widely distributed; having wide or considerable extent; widespread, widely diffused or prevalent; widely extended or spread out. Not restricted to a definite locality; existing in or affecting

all or most of a carcass or part. Exceeding the usual, proper, or normal; implies an amount or degree too great to be reasonable or acceptable. As applied to tuberculosis lesions in lymph nodes, extensive means that the lymph node is greatly enlarged, or nearly all of the lymph node tissue is affected. As applied to tuberculosis lesions in tissues other than lymph nodes, extensive means that more than half of the organ or tissue surface is affected. Multiple means that there are lesions in more than one organ. Acute, progressive means tissue surrounding caseous lesion is edematous and congested or hyperemic, or that several similar such small lesions are occurring around an older focus.

Acute - In general, acute refers to a period of time lasting from a few to several days. Acute lesions usually have some or most of the features of the classic acute response, that is, hyperemia, edema, and exudate. The components may vary considerably. There may be much edema and cellular exudation with little hyperemia, or there may be much hyperemia with little exudation. In general the presence of fluid suggests an acute lesion.

Subacute - Subacute lies between acute and chronic in character, though closer to acute; usually between one to three weeks.

Chronic - In general, chronic refers to a period of weeks, months, or years. Some degree of fibrosis and/or organization of exudates usually characterize chronic lesions. Chronic inflammation poses two special problems: (1) a chronic lesion that contains foci of acute inflammation, and (2) chronic inflammation that is actively laying down fibrous tissue.

Associated - Secondary, or related in some way as a cause and effect.

Focal - Having an area of disease within a definite locality. Describes a single, solitary lesion in a single organ or part.

Multifocal - Multiple focal lesions within an organ or part. Describes lesion distribution in a single organ or part.

Localized - Not general; restricted to a limited region or to one or more spots.

Systemic - Synonymous with generalized; systemic signs are seen on antemortem, systemic lesions on postmortem.

Serous - Composed primarily of clear fluid. Its presence indicates mild injury. Edema due to injury of vessels could be considered a form of serous exudation. Mild irritation of a serosal or mucosal surface would increase fluid exudation. The location of serous exudate may be within organs or on surfaces. It is usually acute and is a reflection of vascular injury. Hyperemia may or may not be present.

Catarrhal - Occurs on mucous membranes. The exudate has a gross appearance of clear to cloudy to pink color and has a fluid to mucoid consistency. This is one of the most common exudates and is associated particularly with the mucosal surfaces of all levels of the tubular respiratory, reproductive, and digestive tracts.

Fibrinous - Fibrin is a main feature in the exudate that is an indication of severe acute vascular injury. The exudate will be a yellowish fluid, gel, or solid rubbery mat. It usually

occurs on serosal or mucosal surfaces and is prominent on intestinal mucosa, peritoneum, pleura, synovial membranes, and in the lungs.

Purulent - Pus (a thick, opaque, usually yellowish-white liquid inflammation product composed of dead white blood cells and cellular fluids) is the predominant feature of the exudate. Purulent exudates may be acute but are usually chronic.

Granulomatous - The presence of a granuloma (lump) is a predominant feature. This granuloma may be made up of many smaller but somewhat confluent granulomas. The lesion may be a discrete or rather diffuse enlargement. It may be solid on the cut surface or may contain small foci of pus or caseous necrosis throughout.

Terms that apply to pathologic conditions affecting the carcass as a whole

Bacteremia - The presence of bacteria in the blood. Not associated with systemic illness but may be associated with a focus of inflammation that provides a continuing supply of organisms.

Septicemia - A syndrome of septic bacteremia accompanied by fever, hemorrhage, and severe systemic illness associated with the presence and persistence of pathogenic microorganisms or their toxin in the blood. It is nearly always associated with some focus of inflammation that provides a continuing supply of organisms.

Pyemia - A variant of septicemia caused by pus-forming bacteria in which secondary foci of suppuration occur and multiple abscesses are formed. Fever, chills, sweating, jaundice and abscesses in various parts of the body mark the condition.

Sapremia - A variant of septicemia associated with a gangrenous condition in which saprophytic bacteria, ordinarily growing only in dead organic matter, are able to survive in the blood and be disseminated by it throughout the living body.

Toxemia - A generalized intoxication due to the absorption and circulation in the blood of bacterial products (toxins) formed at a localized source of infection.

Septic - Relating to, involving, or characteristic of a condition resulting from the spread of bacteria or their products from a foci of infection.

Suppurative (adjective) - Producing pus, or associated with the act of becoming converted into and discharging pus.

Suppuration (noun) - The formation of pus; the act of becoming converted into and discharging pus.

Systemic - Pertaining to or affecting the entire carcass or body, generalized.

Cachexia - A profound and marked state of constitutional disorder, general ill health and malnutrition; a general physical wasting and malnutrition usually associated with chronic disease.

Degeneration - Change of tissue from a higher to a lower or less functionally active form or state. When there is chemical change of the tissue itself, it is true degeneration; when the change consists of the deposition of abnormal matter in the tissue it is infiltration. Atrophy, fibrosis, and necrosis are examples of degeneration.

Hyperemia - An excess of blood in a part due to local or general relaxation of the arterioles. Under normal circumstances, blood does not flow through all capillaries in a tissue. The amount of blood flow usually corresponds to the amount of work being carried out and will vary in different areas at different times. In hyperemia, all capillaries within an organ would be opened, dilated, and filled with red blood cells. Hyperemia usually occurs in a localized area, because if it occurred all over the body, there would not be sufficient blood in the major vessels to maintain systemic blood pressure and shock would occur.

Congestion - Congestion implies that the flow of blood leaving an area is impeded and that blood therefore accumulates in the venous circulation. It is a passive process and results from impaired blood flow in veins. The physical obstruction of either small or large vessels, or the failure of forward blood flow, as in heart failure, may cause congestion. Blood accumulates in dilated capillaries and venules and the tissue appears blue because of the poorly oxygenated venous blood.

Lipidosis - A general term for disorders of cellular lipid metabolism involving abnormal accumulations of lipids within an organ.

Sawdust - A lay term used to describe pinkish-gray to yellowish-white foci of necrosis within the liver that resemble the fine particles of wood made by a saw in cutting.

Steatosis - A muscular dystrophy in which muscle is replaced by an abnormal amount of fat without accompanying inflammatory or degenerative change.

Telangiectasia - A vascular lesion formed by an abnormal dilatation of a group of small capillary vessels and arterioles.

Telangiectasis - A condition of the liver in which purplish-red to bluish-black spots form on the surface and in the parenchyma of the organ. The surface spots have a very slightly depressed appearance.

Tissues - Fat, muscle, tendons, and bone of the carcass, as opposed to the tissues of organs.

Organs - Structures such as liver, heart, lungs, kidneys, etc.

Terms that apply to contamination

Adulterate - To make impure by the addition of a foreign or inferior substance. Generally refers to a substance that is incorporated into the organ or part and that can not be removed by trimming.

Contaminate - To soil, stain, corrupt, or infect by contact or association. Generally refers to a substance that is on the surface of an organ or part and that can be removed by trimming.

Contaminant - Something that contaminates.

Contamination - Soiling or making inferior by contact or mixture, as by the contact of a carcass or part with fecal material, inflammatory exudates, or ingesta.

Disposition Thought Process – A Systematic Approach

Dispositions require a science-based thought process to determine the eligibility of livestock and poultry carcasses for human food. Four basic components comprise this thought process. They are:

- History
- Examination
- Diagnosis
- Disposition

History

This includes data such data as ownership; geographical, herd, or lot origin; and special handling. Additional information, such as knowledge that livestock are from a producer with a history of residue violations, will have a bearing on the PHV's decisions. When history is available it is regarded as highly beneficial, though history is often unavailable.

Examination

Routine antemortem and postmortem inspection procedures identify abnormalities in the live animal or the carcass. The affected animal or carcass with significant abnormalities will be separated out for examination by the PHV. The veterinarian must examine all U.S. Suspects identified on antemortem and all carcasses retained for veterinary disposition at postmortem inspection. The examination of all nonambulatory animals (excluding cattle- which are condemned by regulation) must include taking the temperature of the animal. Other animals that must have the temperature taken during the examination include TB Reactors and any animal which may be febrile.

The examination process should utilize the knowledge and skills gained through veterinary education, experience, and training. The examination should be thorough and should result in the PHV being able to arrive at a sound, supportable diagnosis and disposition. Sometimes laboratory support in the form of histopathology, microbiology, or residue analysis may be required.

Diagnosis

A diagnosis is a definitive summary of all of the facts regarding a particular case. As such, a diagnosis may be made either after the PHV's examination at antemortem or postmortem.

As the examination is performed, the PHV should use a logical thought process to support a diagnosis. The following factors are important:

1. Correlate antemortem findings with postmortem lesions.
2. Determine if pathology is acute or chronic.
3. Determine if pathology or condition is localized or generalized.
4. Determine if a condition or disease is associated with any generalized changes.

Disposition

Disposition is the process of enforcing the regulatory requirements. The dispositions for some diagnoses are quite specific. For example, malignant lymphoma is required in 311.11 (b) to be condemned regardless of the extent. Another example would be temperatures at antemortem which require condemnation in 9CFR 309.3(c) for the various species (i.e., 105°F for all species except swine, 106°F for swine). For most conditions there is more latitude given for judgment by the PHV. Judgment is referred to in the Meat and Poultry Inspection Regulations 311.1(a).

Most dispositions require a PHV's professional judgment of the character and distribution of a disease process. For example, acute pneumonia with attendant generalized inflammatory changes present in other organs and structures requires the carcass to be condemned in its entirety. On the other hand, when the abnormality consists only of a chronic pneumonia, the lungs are condemned and the carcass and viscera would be passed for use as human food.

Principles of Disposition

The PHV should consider history, examination, diagnosis, and pertinent regulations in making a disposition determination. In making the determination the PHV should seek answers to the following questions:

1. Is there any **diseased** or **abnormal** tissue? (If so, it must be trimmed & condemned.)
2. Is the disease or condition **localized** or **generalized**?
3. If a disease, is it **acute** or **chronic**?
4. Is there evidence of a **derangement** of body functions?

5. Is the disease or condition one that would be **injurious** to the health of the consumer?
6. Is the condition one that would be **offensive** or **repugnant** to the consumer (aesthetically unacceptable)?

Antemortem Disposition Choices

Livestock examined by a veterinarian on antemortem inspection will be either:

1. Passed for regular slaughter; or
2. Passed as a "U.S. Suspect"; or
3. Identified as "U. S. Condemned."

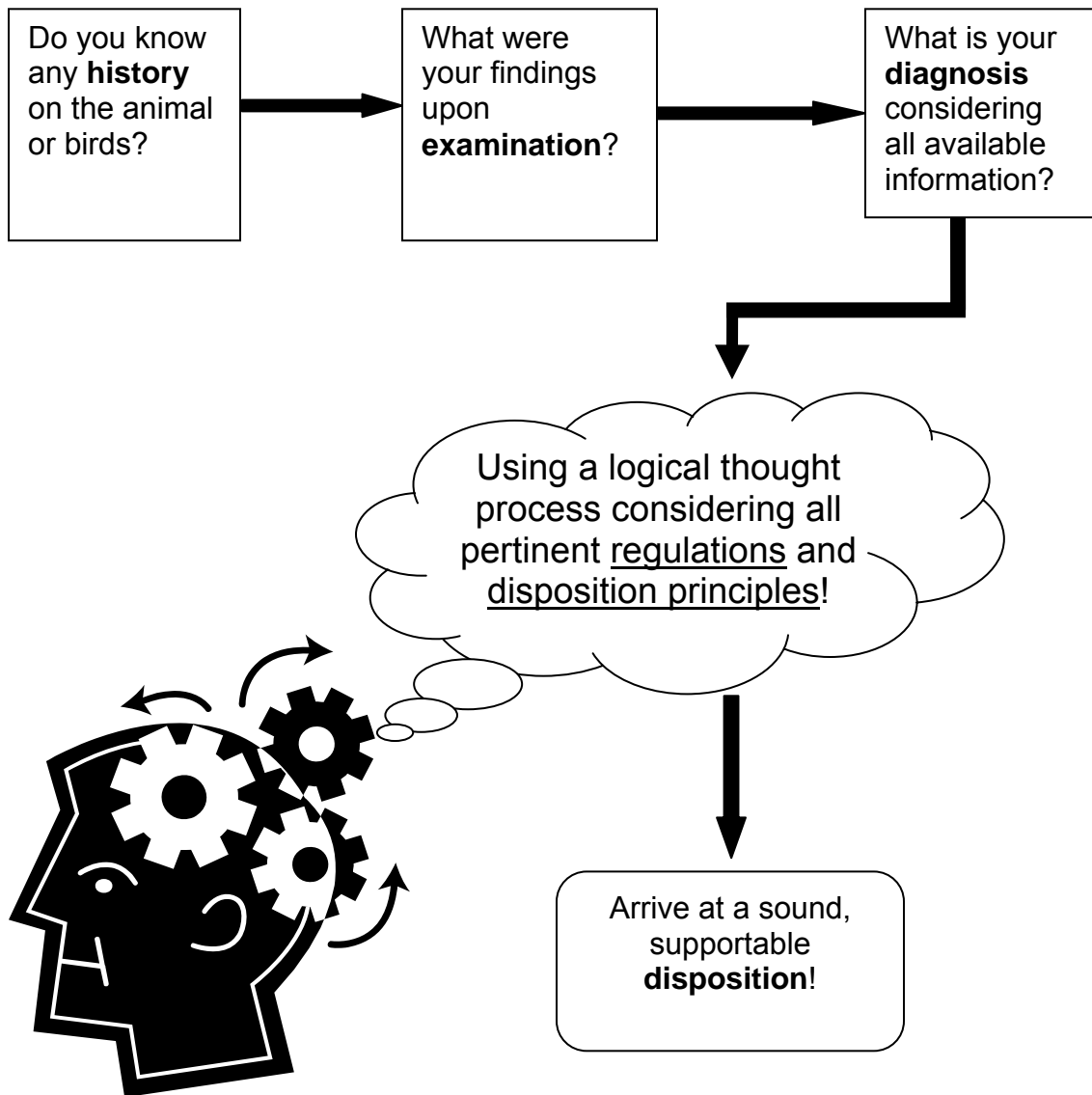
Postmortem Disposition Choices

A carcass may be passed for food or condemned, but there are other possibilities that lie between these two extremes. The postmortem disposition possibilities can be summarized as follows:

1. Pass the carcass for human food ("U.S. Inspected and Passed").
2. Retain the carcass and later pass for human food ("U.S. Inspected and Passed").
 - a. As normal or within the normal range.
 - b. After localized lesions are removed and condemned.
3. Condemn the carcass or parts for human food ("U.S. Inspected and Condemned").
 - a. Properly denature and render (on or off premises) or incinerate; or
 - b. Allow for use as pet food (only in specific cases). Carcasses and parts (unless exempted) require proper denaturation.
4. Hold carcass and parts pending laboratory tests.
5. Pass the carcass and parts with restrictions as follows:
 - a. Pass for heating: Heat thoroughly to an internal temperature of at least 140° F (e.g., certain cases of *Cysticercus bovis* or *Cysticercus ovis*).
 - b. Pass for refrigeration: Carcasses held no higher than 15° F internal temperature continuously for a minimum of 10 days (e.g., certain cases of *Cysticercus bovis*.)

- c. Pass for use as comminuted cooked product (e.g., less than pronounced sexual odor in carcasses of some older hogs or certain cases of eosinophilic myositis).
- d. Pass for cooking: Heat thoroughly to an internal temperature of at least 170° F and hold at that temperature for at least 30 minutes.

Disposition Thought Process



That's using your HEDD - History, Examination, Diagnosis, Disposition!

Workshop I

1. What are the four basic components of the disposition thought process?
2. Which animals must be examined by a Public Health Veterinarian (PHV) at antemortem? Which carcasses at postmortem must be examined?
3. Which animals at antemortem should have their temperature taken as part of the examination by the PHV?
4. What are 6 questions you will consider as part of the thought process in arriving at a sound, supportable disposition?
5. What are the options for disposition at antemortem? At postmortem?
6. What is the difference between public health significance and regulatory disposition requirements?

Livestock Diseases and Conditions of Public Health Significance

Central Nervous System Conditions at Antemortem

Various diseases, metabolic disturbances, and syndromes may present with CNS signs. Not all of these are of food safety or zoonotic significance, however, since they are often difficult to differentiate on antemortem examination, CNS-related conditions must be considered as having the potential to endanger human health.

Important! All cases of livestock exhibiting clinical signs of central nervous system disorders must be condemned on antemortem.

The Public Health Veterinarian (PHV) must keep in mind that condemning an animal on antemortem means either that the establishment shall kill the animal as stated in 9CFR 309.13(a); the livestock may be set apart and held for treatment as stated in 309.13(b) & 309.3(d); or the livestock may be released for treatment (after permission is obtained from local, State, or Federal livestock sanitary officials having jurisdiction) as stated in 309.13(d). The establishment, and not the PHV, exercises the option of holding a condemned animal for treatment or under certain circumstances moving the animal to another premises for treatment.

Some CNS disorders are reportable diseases, such as rabies (any species) and bovine spongiform encephalopathy. The CNS signs observed on antemortem from one disorder may be difficult to distinguish from another. If a PHV is uncertain of a diagnosis and the signs are consistent with those of any reportable disease he/she shall contact Veterinary Services. Because of the possible threat of adulterating our beef supply with a spongiform agent, it imperative that any cattle presented for antemortem inspection with signs of any central nervous system disorder be condemned and the appropriate APHIS (Veterinary Services) officials notified immediately.

The Food Safety and Inspection Service has agreed in a memorandum of understanding (MOU) with APHIS "to promptly notify APHIS when signs and/or lesions of foreign animal diseases are noted on livestock or poultry during antemortem and/or postmortem inspection(s)." FSIS 12-37-MU-334 A.5., page 2. Additionally, FSIS agrees, "When...reportable diseases or exotic diseases of foreign origin are suspected...during ante- or post-mortem inspection, the Area Veterinarian-in-Charge (AVIC) for Veterinary Services (VS) should immediately be notified." FSIS 12-37-MU-334, Appendix 4.

The PHV must remember local, peripheral, and/or physiological conditions can mimic CNS disorders. Examples of this are lameness, which may be difficult to differentiate from ataxia or paresis; shivering in cold weather, which may be difficult to differentiate from tremors; and water in the external ear canal, which causes a head tilt that may be indistinguishable from a head tilt caused by a CNS disorder. Swine are often sprayed with cool water in antemortem pens to keep them from overheating. If the water gets in the external ear canal, the affected pig will tilt its head.

The antemortem disposition thought process is similar in all cases with animals presenting with central nervous system disease.

Metabolic Disorders

Hypomagnesemic Tetany (Grass Tetany) in Cattle and Sheep

This is a metabolic disorder most common in adult cows and ewes in heavy lactation on lush pastures, seen especially after winter confinement. This disorder may affect cattle of any age grazing on wheat or other cereal crops. Undernourished cattle exposed to changeable, cold weather may also be affected. Hypomagnesemic tetany may also occur in 2-4 month old calves fed exclusively milk.

Antemortem findings may include the following:

The acute onset is characterized by bellowing, galloping in a blind and frenzied manner, falling, tetany, and paddling convulsions.

Animals with slow onset may appear ill at ease, irritable, walk stiffly and be hypersensitive to touch and sound. Frequent urination may be observed. The animals with slow onset may take two to three days to progress to the acute convulsive stage and could very well survive shipping to slaughter facilities.

Antemortem disposition

Regulation §309.4(a) requires, "All livestock showing, on antemortem inspection, symptoms of...ketosis, parturient paresis,...grass tetany, transport tetany,...shall be identified as U.S. Condemned and disposed of in accordance with section §309.13." And §309.13(b) states, "Any livestock condemned on account of...ketosis,...or inflammatory condition may be set apart and held for treatment under supervision of a Program employee or official designated by the area supervisor. The U.S. Condemned identification tag will be removed by a Program employee following treatment under such supervision if the animal is found to be free from any such disease.

Any cattle presented for antemortem inspection with signs of a central nervous system disease or disorder shall be condemned and the appropriate APHIS (Veterinary Services) officials notified by telephone immediately.

Transport Tetany in Ruminants

A metabolic disturbance (possibly hypocalcemia and/or hypomagnesemia), usually seen in pregnant well-fed cows and ewes after transportation and stress.

Antemortem findings may include the following:

Livestock present with restlessness and uncoordinated movements, followed by partial paralysis of the hindlegs and staggering, followed by sternal recumbency, progressive paralysis, and death.

Antemortem disposition

Follow the same disposition process as discussed in hypomagnesemic tetany.

Parturient Paresis (Milk Fever) in Cows and Ewes

A metabolic disorder (hypocalcemia) occurring in mature dairy cows following parturition and concomitant with profuse lactation. It also occurs in pregnant and lactating ewes.

Antemortem findings may include the following:

Cattle present early with an unsteady gait, quickly followed by collapse to sternal recumbency (often with the head turned into the flank) and dilated pupils. Without treatment cattle with these signs will become comatose and die. In ewes, early signs are hyperexcitability, muscle tremors, and stilted gait, followed by ataxia, paresis, coma, and death.

Antemortem disposition

Follow the same disposition process as discussed in hypomagnesemic tetany.

Ketosis

This condition is also a metabolic disorder (hypoglycemia, ketonemia, and ketonuria) and is most common in high-producing stall-fed lactating cows. It occurs within a few weeks of calving and is characterized by inappetence, weight loss, decreased milk production, and acetone odor to the breath.

Antemortem findings may include the following:

Many cows appear lethargic and depressed but some may be frenzied or aggressive. Other CNS signs are head pressing, circling, staggering, bellowing, hyperesthesia, and compulsive walking.

Antemortem disposition

Follow the same disposition process as discussed in hypomagnesemic tetany.

Pregnancy Toxemia in Cows

A metabolic disorder (ketonemia, ketonuria, [ketosis] hypoglycemia, proteinuria) occurring in beef cows fed heavily during the first two trimesters of pregnancy and nutritionally stressed the last trimester.

Antemortem findings may include the following:

Restlessness and incoordination are the early signs, followed by sternal recumbency, coma, and death.

Antemortem disposition

Follow the same disposition process as discussed in hypomagnesemic tetany.

Pregnancy Toxemia in Sheep (Ovine Ketosis)

A metabolic disorder (hyperketonemia with variable hypo/normo/hyperglycemia) of preparturient (usually undernourished) ewes.

Antemortem findings may include the following:

Affected ewes become listless, and show muscle twitching around the head, abnormal postures, grinding of teeth, loss of reflexes, blindness, ataxia, sternal recumbency, coma, and death.

Antemortem disposition

Follow the same disposition process as discussed in hypomagnesemic tetany.

Porcine Stress Syndrome (PSS) or Malignant Hyperthermia, Transport Myopathy, Back Muscle Necrosis, Pale Soft Exudative Pork (PSE)

Porcine stress syndrome is an inherited metabolic disorder of skeletal muscle calcium kinetics. Clinical signs are brought on by stress, transport, handling, exercise, or excitement. The leaner heavier-muscle pigs are the most susceptible.

Antemortem findings may include the following:

Initially pigs present with muscle tremors of the tail, back, and legs. Tremors progress to rigor and pigs are unable to move. Additionally, there is tachycardia, open-mouthed breathing, pyrexia (temperatures up to 113° F), and death, with rigor mortis developing in minutes.

Antemortem disposition

The regulations do not specifically address PSS but they do address transport tetany in §309.4(a) and §309.13(b). These regulations would apply to PSS.

Follow the same disposition process as discussed in hypomagnesemic tetany.

Polioencephalomalacia

A nervous system disorder (of nutritional-metabolic origin) in ruminants. Deficiency of thiamine is present in all cases. The deficiency is precipitated by an abrupt change in diet to concentrates and corn silage.

Antemortem findings may include the following:

Clinical signs are depression, medial dorsal strabismus, abnormal gait, moderate opisthotonos, cortical blindness, and preserved pupillary light reflex. Later signs are hyperesthesia, recumbency, severe opisthotonos and convulsions.

Antemortem disposition

Polioencephalomalacia is not specifically mentioned in §309.4, "Livestock showing symptoms of certain metabolic, toxic, nervous, or circulatory disturbances, nutritional imbalances, or infectious or parasitic diseases"; however, these animals would be condemned due to the CNS signs.

Follow the same disposition process as discussed in hypomagnesemic tetany.

Viral and Prion Diseases with Central Nervous System Signs

Rabies

A viral encephalomyelitis affecting all warm-blooded animals.

Antemortem findings may include the following:

Two classical presentations are seen in animals with rabies, paralytic and furious. Early paralysis of the throat and masseter muscles is usually accompanied by salivation in the paralytic form. In the furious form, cattle attack man and other animals. Affected cattle are alert with eyes and ears following sound and movement. Cattle also have a characteristic bellowing. Horses and mules may roll as if they had colic, bite, and strike.

Antemortem disposition

Follow the same disposition process as discussed in hypomagnesemic tetany.

Regulation §309.4(a) requires, "All livestock showing, on antemortem inspection, symptoms of ...pseudorabies, rabies, scrapie...shall be identified as U.S. Condemned and disposed of in accordance with section §309.13."

Veterinary Services shall be contacted as rabies, scrapie, and pseudorabies are reportable diseases. FSIS Directive 6200.1 VII(B) states, "Special Reports: When the following conditions [which includes rabies, scrapie, and pseudorabies] are encountered, a separate FSIS 6200-14 must be prepared." If rabies is suspected, it should be reported

to the state or local health department, plant management, and all people who could have been exposed.

Pseudorabies

Pseudorabies (Aujeszky's Disease, Mad Itch) is a viral (herpesvirus) infection of the central nervous system in pigs. Cattle and smaller ruminants are less commonly involved; however, the disease is invariably fatal in these species.

Antemortem findings may include the following:

Trembling, incoordination, convulsions, and coma are the most common CNS signs in pigs.

These CNS signs are seen after the initial signs of coughing, sneezing, anorexia, pruritus, pyrexia, and listlessness.

Cattle and smaller ruminants have a shorter clinical course and progress from excitement, trembling, and anxiety to incoordination, convulsion, coma, and death.

Pruritus is accompanied by extreme efforts to relieve itching.

Antemortem disposition

Follow the same disposition process as discussed in hypomagnesemic tetany.

Regulation §309.4(a) requires, "All livestock showing, on antemortem inspection, symptoms of ...pseudorabies, rabies, scrapie...shall be identified as U.S. Condemned and disposed of in accordance with section §309.13."

Veterinary Services shall be contacted as rabies, scrapie, and pseudorabies are reportable diseases. FSIS Directive 6200.1 VII(B) states, "Special Reports: When the following conditions [which includes rabies, scrapie, and pseudorabies] are encountered, a separate FSIS 6200-14 must be prepared."

Bovine Spongiform Encephalopathy (BSE)

Bovine spongiform encephalopathy (BSE), also known as Mad Cow Disease, is a chronic progressive degenerative disease affecting the central nervous system of cattle. There is no treatment and affected cattle die. BSE is classified as a transmissible spongiform encephalopathy (TSE). The causative agent for BSE has not been determined. Some believe it is a "slow virus" or a "virino" while others believe it is a "prion" (an aberrant form of a normal prion protein) that causes the normal protein to conform to its aberrant shape, which leads to a cascade of abnormal proteins accumulating in brain cells. The accumulation of protein plaques causes cell death and

leaves holes in the brain giving a “sponge-like” appearance. The etiologic agent is extremely resistant to destruction.

Like BSE, the TSEs in other species produce spongiform changes in the brain. The TSEs in other species are scrapie (sheep and goats); transmissible mink encephalopathy (mink); feline spongiform encephalopathy (cats); chronic wasting disease (deer and elk); and kuru, Cruetzfeldt-Jakob Disease [CJD], Gerstmann-Straussler-Scheinker syndrome, and fatal familial insomnia (humans). The TSEs have also been observed in a number of exotic species, including primates. The TSEs have long incubation periods of one to thirty years depending on the disease and species. BSE was first officially recognized in the United Kingdom (UK) in November of 1986. The incubation period for BSE in cattle is from 2 to 8 years. As of February 2004, there is no antemortem test for BSE although much work is being done in this area.

Antemortem findings may include the following:

Cattle display changes in temperament (including aggressive behavior), abnormal posture, incoordination, stumbling, or difficulty in rising. In addition to the CNS signs, cattle have a loss of body condition (in the face of a continued good appetite) and decreased milk production.

Antemortem disposition

Follow the same disposition thought process as previously discussed (i.e., condemn the animal and notify APHIS).

Scrapie

Scrapie is a progressive neurological disorder of sheep, possibly caused by an abnormally shaped protein called a prion. This is a transmissible (and possibly inherited) spongiform encephalopathy.

Antemortem findings may include the following:

A characteristic intense pruritus beginning over the rump is accompanied by excitability, fine tremors of the head and neck, and hypermetria of the forelegs when trotting.

The disease progresses with ataxia, emaciation, weakness, and death.

Antemortem disposition

Follow the same disposition process as discussed in hypomagnesemic tetany.

§309.4(a) requires, “All livestock showing, on antemortem inspection, symptoms of...pseudorabies, rabies, scrapie...shall be identified as U.S. Condemned and disposed of in accordance with section §309.13.”

Veterinary Services shall be contacted as rabies, scrapie and pseudorabies are reportable diseases. FSIS Directive 6200.1 VII(B) states, "Special Reports: When the following conditions [which includes rabies, scrapie, and pseudorabies] are encountered, a separate FSIS 6200-14 must be prepared."

Toxicities with Central Nervous System Signs

Animals showing signs of central nervous system disorders or disease related to toxicities should be:

Condemned for CNS disorders, condemned for dying condition, §309.3(a), or condemned for comatose or semicomatose condition or...any condition...which would preclude release of the animal for slaughter of human food... 309.3(d), or

Condemned for toxic encephalomyelitis, 309.4(a), 311.10(a)(8)

Any cattle presented for antemortem inspection with signs of a central nervous system disease or disorder shall be condemned and the appropriate APHIS (Veterinary Services) officials notified by telephone immediately.

Arsanilic Acid Poisoning

This poisoning occurs in pigs as a result of ingestion of excessive amounts of organic arsenical growth promoters. The CNS lesions are myelin and axonal degeneration in the optic and peripheral nerves.

Antemortem findings may include the following:

Affected pigs progress from hindlimb ataxia to tetraparesis.

Antemortem disposition

Follow the same disposition process as discussed in hypomagnesemic tetany.

Lead Poisoning

Lead poisoning occurs in livestock grazing on contaminated forage, paint, batteries, grease, or oil. Clinical signs may be acute or chronic.

Antemortem findings may include the following:

Cattle show a whole host of CNS signs including bellowing, circling, staggering, excitement, ataxia, twitching, grinding the teeth, and leaning and walking into objects as if blind. Convulsions, seizures, and death may occur.

Antemortem disposition

Follow the same disposition process as discussed in hypomagnesemic tetany.

Organochlorine (Chlorinated Hydrocarbons) Poisoning

Poisoning by organochlorines (aldrin, aphene, benzene hydrochloride, chlordane, dieldrin, endrin, heptachlor, lindane, and methoxychlor) causes stimulation of the central nervous system, manifested by colic or neurological signs.

Antemortem findings may include the following:

The CNS signs are hyperexcitability, muscle twitching, hyperesthesia, and head tremors, progressing caudally. Tonic-clinic seizures are accompanied by collapse to lateral recumbency.

Antemortem disposition

Follow the same disposition process as discussed in hypomagnesemic tetany.

Organophosphate (OP) Poisoning

Poisoning by organophosphates (chlorpyrifos, coumaphos, dermeton, dichlorvos, diazinon, famphur, fenthion, malathion, parathion, ronnel, ruelene and trichlorfon) causes cholinergic overstimulation of the parasympathetic nervous system. Cattle and sheep show depression, unlike small animals, which show convulsions in the latter stages.

Antemortem findings may include the following:

Muscarinic signs are hypersalivation, dyspnea (resulting from bronchoconstriction and bronchial secretions), miosis, diarrhea, and frequent urination.

Nicotinic signs include muscle fasciculations and weakness.

Central effects are apprehension, nervousness, ataxia, and sometimes convulsions.

Antemortem disposition

Follow the same disposition process as discussed in hypomagnesemic tetany.

Paspalum Staggers

Ingestion of paspalum grasses infested by the fungus *Claviceps paspali*. Cattle, sheep, and horses are all susceptible.

Antemortem findings may include the following:

Continuous trembling, jerky and uncoordinated movements, falling, and paralysis.

Antemortem disposition

Follow the same disposition process as discussed in hypomagnesemic tetany.

Nitrate and Nitrite Poisoning

Toxicoses can occur by ingestion of plants containing excess nitrate or accidental ingestion of fertilizers or chemicals. Ruminants are the most susceptible, but equines and pigs can be affected.

Antemortem findings may include the following:

The CNS signs associated with this condition are anxiety, weakness, muscle tremors, and ataxia. Other signs are rapid difficult breathing, rapid heart beat, and brown mucous membranes.

Antemortem disposition

Follow the same disposition thought process as discussed in hypomagnesemic tetany.

Non-protein Nitrogen Poisoning

Non-protein nitrogen (NPN) poisoning (ammonia toxicosis) is caused by the ingestion of excess urea or other NPN compounds. Ruminants are most commonly affected.

Antemortem findings may include the following:

The CNS signs include grinding of the teeth and tremors, which progress to weakness and incoordination.

Sheep appear depressed.

Horses may exhibit head pressing.

Cattle appear agitated, and become increasingly belligerent and violent.

Antemortem disposition

Follow the same disposition process as discussed in hypomagnesemic tetany.

Petroleum Hydrocarbon Toxicity

Ingestion of gasoline, diesel fuel, or other petroleum hydrocarbon products can cause illness and death. Clinical signs may be respiratory, gastrointestinal, dermatologic, or CNS.

Antemortem findings may include the following:

Visual problems, excitability, incoordination, depression, head tremors, and shivering.

Antemortem disposition

Follow the same disposition process as discussed in hypomagnesemic tetany.

Perennial Ryegrass Staggers

Perennial ryegrass staggers is a neurotoxic condition affecting all livestock ingesting *Lolium perenne* (perennial ryegrass) or hybrid ryegrasses in the summer and fall infected with the fungus *Acremonium loliae*.

Antemortem findings may include the following:

The CNS signs are tremors of the head and nodding movements, progressing to incoordination, and jerky movements. Forced running may produce more severe symptoms including collapse, nystagmus, opisthotonos, and flailing of legs.

Antemortem disposition

Follow the same disposition process as discussed in hypomagnesemic tetany.

Salt Poisoning

Salt poisoning of domestic animals is usually caused by water deprivation coupled with increased salt intake, causing toxic levels of sodium chloride to build up.

Antemortem findings may include the following:

Pigs show various CNS signs including deafness, blindness, aimless wandering, head-pushing, circling, clonic-tonic seizures, opisthotonos, paddling, and coma.

Cattle CNS signs are blindness, seizures, and partial paralysis.

Antemortem disposition

Follow the same disposition process as discussed in hypomagnesemic tetany.

Selenium Poisoning

Selenium poisoning is caused by the ingestion of toxic levels of selenium, usually in naturally seleniferous forages and grain. Soils high in selenium are found in Mexico and some areas of the western plains of Canada and the United States. Most selenium poisoning in the United States has occurred in Nebraska, South Dakota, Colorado, and Wyoming.

Antemortem findings may include the following:

The CNS signs are referred to as “blind staggers.” Cattle and sheep show signs of impaired vision, wandering, and walking into objects, followed by weak front legs and throat and tongue paralysis.

Antemortem disposition

Follow the same disposition process as discussed in hypomagnesemic tetany.

Senecio Poisoning

Senecio poisoning (seneciosis, ragwort toxicity, pyrrolizidine alkaloidosis) is caused by ingestion of a number of plants containing hepatotoxic alkaloids with a pyrrolizidine base.

Antemortem findings may include the following:

The CNS signs are stumbling, head pushing, weakness, and aggressiveness.

Antemortem disposition

Follow the same disposition process as discussed in hypomagnesemic tetany.

Nonambulatory Animals

The regulations at 9 CFR 309.2(b) state that non-ambulatory disabled livestock, including cattle, are livestock that cannot rise from a recumbent position or that cannot walk, including, but not limited to, those with broken appendages, severed tendons or ligaments, nerve paralysis, fractured vertebral column or metabolic conditions. Also, the regulation at 309.3(e) states that **non-ambulatory disabled cattle shall be condemned**. Other species of livestock would be examined by the PHV and either be condemned or passed for slaughter as a U.S. Suspect.

Non-ambulatory disabled cattle are considered unfit for use as human food. This determination is derived from Title 1, Section 1(m)(3) of the Federal Meat Inspection Act. Specifically,

The term "adulterated" shall apply to any carcass, part thereof, meat or meat food product under one or more of the following circumstances: if it consists in whole or in part of any filthy, putrid, or decomposed substance or is for any other reason unsound, unhealthful, unwholesome, or otherwise unfit for human food.

Livestock Diseases and Conditions of Public Health Significance

Septicemia

Septicemia is a condition of public health significance caused by the presence of pathogenic microorganisms and their associated toxins in the blood. The liver, spleen, and lymph nodes are usually hyperemic and swollen because these organs remove most of the bacteria from the bloodstream. Certain types of bacteria, fungi, and viruses circulate in the bloodstream (bacteremia, mycohememia, viremia) without overt disease being present. Microorganisms continually enter the blood through the mouth, intestinal wall, and lung, but the life of these organisms is usually short. If the organism is pathogenic and overwhelms the animal's defenses, acute disease will result. Septicemia is an acute disease process, caused by an infectious agent and resulting toxic products that produce a variety of clinical findings including changes in body temperature, pulse rate, and responsiveness (i.e., depression, prostration). In later stages of septicemia, toxic signs and lesions may include disseminated intravascular coagulation and shock. At postmortem, septicemias may result in congestion, hyperemia, petechial to ecchymotic hemorrhages, acute infarction, edema, darkened musculature, acute lymphadenopathy, loss of body condition, dehydration, anemia, and changes in organ appearance. A change in organ size, color (darkening or pallor), and consistency (change of normal texture from almost fluid to very firm) may be observed. All of these signs and lesions, of course, might not be present in every animal with septicemia.

The problem of differentiation between septicemia and a localized inflammatory process is often very difficult. One must be aware that generalized enlargement of lymph nodes may occur in disease remission or in chronic disease and does not necessarily indicate an active septicemia.

Many conditions that are not considered to be a food safety hazard can lead to septicemia. For example, pneumonia in its early stages may not represent a public health hazard but, if the disease progresses and overwhelms the animal's immune system, pathogens may gain access to the carcass tissues and result in a septicemia and thus pose a food safety hazard.

Antemortem findings may include the following:

Variable temperature—typically would be high, but may vary to subnormal (due to thermal regulation failing); must expect to encounter a whole range when considering the possible array of disease conditions and the drastic range of possible ambient temperatures to which such an animal might be exposed. Each case will have to be independently assessed by the PHV.

Evidence of injury or suppuration

A downer, or physical depression

Hyperemia of skin

Evidence of pain
Muscle tremors

Dyspnea

Congestion of mucous membranes

Changes in locomotion

Antemortem disposition (Regulation 309.2)

Condemn: When it is possible to establish a diagnosis of septicemia based on any combination of significant findings that would give evidence that the carcass would be condemned on postmortem.

Suspect: All animals indicating signs and lesions of septicemia, but not conclusive evidence.

Postmortem findings may include the following:

Infected wounds or bruises

Generalized, acute lymphadenitis

Degeneration of tissues or organs

Acute infarction

Imperfect coagulation of blood

Petechial or ecchymotic hemorrhage (most noticeable in kidneys, epicardium, lungs, and serous surfaces)

Sero-sanguinous fluid in abdominal and or thoracic cavities

Injection sites (recent)

Edema or other evidence of acute generalized inflammation

Postmortem disposition (Regulations 311.16, 311.17)

Condemn: In cases of generalized disease as a result of infected wounds or bruises, or when the primary pathology is masked and associated manifestations are present as outlined in the antemortem and postmortem findings.

(1) Generalized, acute lymphadenitis alone is enough for condemnation.

(2) A carcass manifesting septicemia is never passed.

Pass: Carcasses not meeting the criteria for condemnation, after condemnation and removal of any abnormal tissue.

Special Note: The term septicemia should only be used for disposition purposes when a specific disease cannot be diagnosed.

Toxemia

Toxemia is condition of public health significance due to the circulation of exotoxins, endotoxins resulting from the death of microorganisms, or toxins generated by the death or dysfunction of the animal's own cells, and the inflammatory process itself. In the latter situations, cytokines, prostanoids, and acute phase reactant proteins may produce systemic effects such as metabolic changes, fever, and necrosis. Changes in endothelial cells produced by such products may also result in pathologic hemorrhage or edema. Toxemia, as a term, is frequently used but technically the phenomenon is closely related to and may be inseparable from the syndrome seen in septicemia. In examples such as septic mastitis, metritis, or arthritis, a septicemia, a toxemia, or both may simultaneously occur. Unless bacterial culture and isolation is performed on various tissues, toxemia may be difficult to recognize grossly as a separate entity from septicemia.

Antemortem findings may include the following:

Condition that may be associated with toxemia, e.g., an old injury, or gangrenous mastitis.

Variable temperature—depending upon stage of disease and ambient temperature. Temperature may range from very high to subnormal; each case will have to be independently assessed by the PHV.

A downer, or physical depression

Dehydration—dry nose, sunken eyes, loose skin can be made to tent by digital manipulation

Pain—grinding of teeth

May appear confused or have convulsions

Changes in locomotion

Antemortem disposition (Regulations Part 309.2, 309.4)

Condemn: Animals showing conclusive signs of toxemia.

Suspect: Animals indicating signs and lesions, but not conclusive evidence, of toxemia.

Postmortem findings may include the following:

Petechial or ecchymotic hemorrhage (most noticeable in kidneys, epicardium, lungs, and serous surfaces)

Generalized, acute lymphadenitis

Degeneration of tissues or organs

Presence of areas of tissue necrosis

Postmortem disposition (Regulations Part 311.16, 311.17, 311.37)

Condemn: When lesions and or clinical findings indicate that a toxemia exists and the primary pathology is masked, the carcass is condemned for toxemia.

Pass: Carcasses not meeting the criteria for condemnation, after condemnation and removal of any abnormal tissue.

Special Note:

(1) Chronic lymphadenitis due to a previous infection or condition should not be confused with a toxemia.

(2) An enlarged pale liver from a pregnant animal nearing delivery should not be confused with a liver associated with a toxemia. Although a form of hepatic lipidosis may be seen in either, the postmortem array of lesions in one condition should not be confused with the tissue and organ changes in a periparturient carcass).

Special Note: The term toxemia should only be used for disposition purposes when a specific disease cannot be diagnosed.

Pyemia

Pyemia is a condition of public health significance resulting from the active circulation of pyogenic organisms in the blood. It is typically characterized by the development of acute suppurative lesions throughout the carcass tissues and organs.

Antemortem findings may include the following:

Depression or lethargy

Variable temperature—depending upon stage of disease and ambient temperature. Temperature may range from very high to subnormal; each case will have to be independently assessed by the PHV.

Swollen joints

Umbilical abscess

Subcutaneous abscesses

Cachexia

Scirrhus cord (funiculitis)

Antemortem Disposition (Regulations Part 309)

Condemn: Any combination of significant findings that would give evidence that the carcass would be condemned on postmortem, e. g., abscesses, as well as generalized (systemic) signs.

Suspect: Animals showing signs and lesions, but not conclusive evidence, of pyemia.

Postmortem findings may include the following:

Acute suppuration (developing foci of suppuration) occurring as a result of pyogenic organism's entry into the systemic circulation

Infarcts accompanied by acute suppuration

Pathologic hemorrhage by itself does not indicate pyemia; however, when associated with either or both of the first two findings, it does support a diagnosis of pyemia.

Degeneration of tissues or organs by itself does not indicate pyemia; however, when associated with either or both of the first two findings, it does support a diagnosis of pyemia.

Generalized, acute, reactive, or edematous lymphadenitis.

Special Note:

- (1) Neoplasia having central liquefaction necrosis may appear as a chronic abscess.
- (2) Tuberculosis may appear as a purulent event in certain situations.
- (3) Although a pyemia may have caused them, multiple, localized, encapsulated abscesses about the body should not be confused with an active pyemia.

Postmortem disposition (Regulations 311.16)

Condemn: All carcasses affected with an active pyemia are condemned, as evidenced by:

1. Presence of generalized acute suppuration occurring as a result of a pyogenic organism's entry into the systemic circulation
2. Abscesses associated with lesions of septicemia as outlined in septicemia postmortem findings.

Pass: Carcasses not meeting the criteria for condemnation for pyemia, after condemnation and removal of any abnormal tissue.

Special Note: The term pyemia should only be used for disposition purposes when a specific disease cannot be diagnosed.

Contamination

Fecal material, ingesta, and milk are vehicles for microbial pathogens in livestock, and microbiological contamination is a food safety hazard that is reasonably likely to occur in the slaughter production process (Sec. 417.2 (a) and (b)). Consequently, HACCP plans must control for microbiological contamination at slaughter, and to meet the zero tolerance standard. An establishment's controls must (among other things) include limits that ensure that no visible fecal material is present by the point of post-mortem inspection of livestock carcasses. FSIS enforces "zero tolerance" standards for fecal, ingesta, and milk contamination on livestock carcasses through postmortem inspection activities at establishments that slaughter livestock. The establishment must meet the zero tolerance standards for visible contamination at the postmortem rail inspection station, regardless of the location of the CCP. The CCP for pathogen contamination or visible contaminants may be at other locations as supported by the hazard analysis.

When the on-line inspectors at the rail station find feces, ingesta, or milk, the establishment reexamines and reworks the entire carcass (trimming all contamination).

More information will be provided on fecal zero tolerance during a later part of the training.

Cysticercosis of Cattle (Beef Measles)

Cysticercosis is a condition caused by the presence of the larval form of the beef tapeworm, *Taenia saginata*, in the carcass tissues. It is of public health significance because it is transmissible to humans through meat products which are not treated in some manner to kill the larva.

Antemortem findings—not applicable

Antemortem disposition—not applicable

Postmortem findings may include the following:

Heart muscle with degenerated cysts

Dead and degenerated cysts in musculature

Meat is watery or discolored and the carcass or parts display lesions of cysticercosis.

Any number of cysts whether live, dead, or degenerated.

Special Note:

(1) The presence of even one cyst, whether viable or not, indicates beef cysticercosis.

(2) Make certain that food inspectors can recognize live or dead and degenerated cysts, as the presence of either indicates beef cysticercosis.

(3) For purposes of discussing the inspection procedure for cysticercosis in cattle, we must define the term “usual inspection sites” as including the following locations:

- a. Muscles of mastication
- b. Heart
- c. Cut surfaces of muscles exposed during usual dressing procedure
- d. The diaphragm and its pillars
- e. Esophagus
- f. Tongue

- (4) Certain conditions such as the following could be confused with cysticercosis:
- a. Other localized parasitic or calcified conditions
 - b. Nerve sheath tumors (covered during neoplasm module)
 - c. Eosinophilic myositis--especially the large EM lesions in which the centers can be expressed
 - d. Abscesses
 - e. Fat marbling in musculature

Postmortem disposition (Regulations 311.23)

Special Note:

(1) When cysticercosis is detected during routine postmortem inspection procedures, the affected carcass and parts must undergo the following further examination by the PHV:

- a. Re-examine the cheeks and heart by sight and numerous incisions
- b. Observe and palpate the tongue; if cysts are suspected, then numerous longitudinal incisions should be made in its muscle
- c. Remove the peritoneum from the diaphragm and examine the muscles of the diaphragm and "hanging tender" by numerous incisions in them
- d. Carefully examine the esophagus and the cut surfaces of muscles exposed during regular dressing procedures. If one or more lesions are found at only one site in this inspection, then make your disposition based on these findings.

However, if lesions are found in two or more of the usual inspection sites (heart, diaphragm and its pillars, cheeks, esophagus, tongue, and muscles exposed during normal dressing operations), continue with (2).

(2) Make one incision into each round, exposing the muscles in cross-section, and one transverse incision into each forelimb, commencing two or three inches above the point of the olecranon and extending to the humerus, totaling four incisions.

Condemn: The carcass and its parts should be condemned when lesions of cysticercosis are present and:

The musculature is edematous or discolored, or

If infestation is extensive.

The carcass shall be considered extensively infested if lesions are found in at least two of the "usual inspection" sites described under (1).d of the Special Note above and at least two of the four incisions described under (2) of the Special Note above.

Passed with Processing Restriction: Any carcass with an infestation that is less than extensive and that does not show edema or discoloration in the musculature may be passed for refrigeration, or be passed for heating after removal and condemnation of affected parts.

Passed for Refrigeration

Carcasses--10 days at not higher than 15 ° F

Boned meat--20 days at not higher than 15° F

Passed for Heating

Product is brought to an internal temperature of at least 140 ° F.

Special Notes:

(1) The Veterinarian in Charge, APHIS, Veterinary Services, of the state in which the animal originated should be notified when beef cysticercosis is diagnosed, using VS Form 2-11.

(2) Edible viscera and offal shall be disposed of in the same manner as the rest of the carcass unless lesions of cysticercosis are found in these byproducts, in which case they shall be condemned.

(3) All products, appropriately identified by retain tags, are held under positive control of a USDA Inspector until the processing restrictions are accomplished.

(4) Expanded procedure: When one beef carcass in a "lot" is found to contain a tapeworm cyst, the PHV may elect to follow the procedures below on all carcasses in that lot:

(a) Multiple incising of the interventricular septum and external and internal muscles of mastication. Close observation should also be made of the esophagus and cut surfaces of muscles exposed during the dressing operation.

(b) If available and identified as part of the affected lot, hearts and cheeks from carcasses that had passed inspection prior to finding the infected carcass should be incised as above.

(c) Inspectors should be cautioned that some plants may attempt to separate an original lot into small sub-lots- to decrease the number of cattle carcasses subject to this expanded procedure. Such a practice should not be permitted.

Cysticercosis of Swine (Pork Measles)

Swine Cysticercosis is a condition caused by the larval form of the swine tapeworm *Taenia soleum*. It is of public health significance because it is transmissible to humans.

Antemortem findings—not applicable

Antemortem disposition—not applicable

Postmortem findings may include the following:

Muscle is edematous or discolored

Cysts in muscle of heart, tongue, esophagus, or carcass

Grape-like clusters in tissue underneath the tongue or attached to heart

Cysts may occasionally be found in fat and viscera.

Special Notes:

- (1) When swine cysticercosis is encountered it is generally very extensive.
- (2) Most frequently the lesions are first observed on the cheeks and in the heart.
- (3) Remind inspectors to observe the cut surfaces on the neck and thigh muscles as cysticercosis could be detected there.
- (4) The presence of even one cyst, whether viable or not, indicates swine cysticercosis.

Postmortem disposition

Detailed Examination Procedure: When cysticercosis is detected during postmortem inspection, the following procedures may be used by the PHV:

- (1) Examine the cheeks, heart, and esophagus by sight and numerous incisions. Make several deep longitudinal incisions into the tongue.
- (2) Remove the peritoneum from the diaphragm and examine the muscles of the diaphragm by numerous incisions.
- (3) Carefully examine the cut surfaces of muscles exposed during regular dressing procedures (ventral muscles of the ham). If only the initial lesions are found in (1) through (3), make your disposition based on these findings. However, if any additional lesions are found, continue to (4).
- (4) Make incisions parallel to cuts described in (3). Also remove the peritoneum from the abdominal muscles in the flank and paralumbar regions. Examine visually and then make several incisions to aid in the examination. If no additional lesions are found in (4),

make your disposition based on findings through (4). However, if any additional lesions are found, continue to (5).

(5) Make deep, bold incisions into the heavily muscled primal parts to determine if various parts of the musculature expose one or more cysts on most of the cut surfaces.

Condemn: When porcine cysticercosis infestation is excessive

Pass with processing restriction: Any swine carcass affected with *Cysticercus cellulosae* that is less than excessively infested may be passed for cooking (held at 170 ° F for 30 minutes), after removal and condemnation of all affected areas.

Special Notes:

(1) Cases of swine cysticercosis should be confirmed by the Pathology Group of the FSIS Eastern Laboratory—Athens, Georgia.

(2) After the diagnosis is confirmed:

(a) Make disposition

(b) Then notify the Veterinarian in Charge, APHIS, Veterinary Services, of the state of the animal's origin, using VS Form 2-11, and

(c) Notify the health department of the state of the animal's origin

(3) All product that is passed for cooking must be held under strict control until that processing restriction has been accomplished (Regulation 315.1).

Poultry Diseases and Conditions of Public Health Significance

Septicemia/Toxemia

Septicemia is a disease state caused by pathogenic (disease producing) microorganisms in the blood that have produced systemic change within the bird. Systemic change affects the body in its entirety rather than localized portions of it.

In septicemia the normal functions of the bird's organ systems are disrupted. The cells of the body deteriorate. This deterioration may be very rapid when highly virulent microorganisms are the cause, or it may be more gradual if less virulent ones are involved.

In some cases, the changes produced by septicemia overwhelm the bird and result in death. In other cases, the bird's immune system overcomes the causative organism before irreversible damage occurs and it recovers.

Septicemia is manifested by a group of clinical signs, not all of which will be present in a single carcass. Therefore, judgment plays an important part in correct dispositions for this condemnation category. Septicemic carcasses frequently have:

- petechial (pinpoint) hemorrhages on the heart, liver, kidneys, muscles, and serous membranes
- blood-tinged exudate in the body cavity
- swollen and hyperemic (contain an excess of blood) liver and spleen (remove most of the bacteria from the circulating blood)
- swollen and congested kidneys
- hyperemic skin
- muscle wasting (Some of this is caused by loss of appetite but most skeletal muscle breakdown is the result of changes in muscle metabolism that triggers protein degradation.)

Depending upon the cause and duration of septicemia, carcasses might be hyperemic, cyanotic, anemic, dehydrated, edematous, or exhibit a combination of these signs. No single carcass will show all of the signs.

Toxemia, poisoning caused by the absorption of toxins produced by infective organisms, shows signs similar to septicemia. Both conditions often exist simultaneously.

Septicemia/toxemia is commonly referred to as sep/tox. If a carcass shows systemic change, it is condemned. Once a diagnosis of sep/tox has been made the carcass must be condemned.

Contamination

Because fecal material is a vehicle for pathogens, and microbiological contamination is a food safety hazard that is reasonably likely to occur in the slaughter production process, a poultry slaughter establishment must adopt controls that it can demonstrate are

effective in reducing the occurrence of pathogens, including controls that prevent the fecal contamination of carcasses. FSIS enforces a "zero tolerance" standard for visible fecal material on poultry carcasses and carcass parts through post-mortem inspection and reinspection activities at slaughter establishments. This food safety standard also is reflected in FSIS' regulatory requirements. FSIS views preventing carcasses with visible fecal contamination from entering the chilling tank as critical to preventing the cross-contamination of other carcasses.

Carcasses that are contaminated with fecal material must be reconditioned by either trimming or a combination of trimming and washing with hyperchlorinated water. If a carcass is so contaminated it cannot be inspected or if it is contaminated to the extent that it cannot be made wholesome the carcass would be condemned.

More information will be provided on fecal zero tolerance during a later part of the training.

Workshop II

1. Give as many examples as you can of signs that could indicate a Central Nervous System (CNS) disorder?
2. What is the disposition for an animal that is exhibiting signs of a CNS disorder?
3. What other action should be taken for cattle showing CNS signs?
4. What is the disposition for a nonambulatory cow?
5. What are some postmortem findings that could indicate septicemia in livestock?
6. What are some postmortem findings that could indicate pyemia in livestock?
7. What are the usual inspection sites for cysticercosis in cattle?
8. What are some findings that could indicate septicemia/toxemia in poultry?
9. What is the disposition for any livestock or poultry condition ending with the suffix "emia"? Why?
10. Why is contamination with feces considered to be a public health safety issue? What about septicemia – why is it a public health hazard?

Livestock Diseases and Conditions Not of Public Health Significance

As with most of the conditions presented in this section, localized conditions may not constitute a public health concern, however, as described in Section 1, carcasses that have become septic, toxic, or pyemic from one or more of these conditions are a public health concern.

Abscess

An abscess (9 CFR 311.14) is a localized, “walled off” area of pus. Pus, according to Dorland’s Medical Dictionary, is “a liquid inflammation product made up of cells and a thin fluid called Liquor puris.”

Antemortem findings may include the following:

Swellings may be evident in various parts of the animal

Antemortem Disposition (Regulations Part 309)

Condemn: Any combination of significant findings that would give evidence that the carcass would be condemned on postmortem, e. g., abscesses, as well as generalized (systemic) signs.

Suspect: Animals showing signs and lesions, but not conclusive evidence, of pyemia.

Postmortem findings may include the following:

Abscesses in various parts of the carcass or organs

Localized, acute or chronic, reactive, or edematous lymphadenitis.

Special Notes:

- (1) Neoplasia having central liquefaction necrosis may appear as a chronic abscess.
- (2) Tuberculosis may appear as a purulent event in certain situations.
- (3) Although a pyemia may have initially caused them, multiple, localized, encapsulated abscesses about the body should not be confused with an active pyemia.

Postmortem disposition (Regulations 311.16)

Condemn: Carcasses affected with multiple abscesses to the extent that all of them could not be removed with a high degree of certainty may be condemned.

Pass: Carcasses not meeting the criteria for condemnation after condemnation and removal of any abnormal tissue. Note: all purulent exudate resulting from ruptured abscesses must be trimmed.

Arthritis

Arthritis is the inflammation of joint tissues that may be traumatic or infectious in origin.

Antemortem findings may include the following:

Enlargement of one or more joints

Abnormal locomotion

Variable temperature—depending upon stage of disease and ambient temperature. Temperature may range from very high to subnormal; each case will have to be independently assessed by the PHV.

Painful or abnormal stance and movement

Reluctance to move or stand

Depression

Cachexia

Infected navel in young animals

Special Note: Transport injury (sore feet)—this also can result from pigs being raised on concrete and must be distinguished from arthritis.

Antemortem disposition (Regulations Parts 309.2, 309.4, 309.9)

Condemn:

1. Arthritis with swollen painful joints, fever
2. Arthritis with swollen painful joints, cachexia

Suspect: We do not suspect all animals with arthritis, only those with other sufficient clinical signs suggesting that after postmortem examination the carcass may need to be condemned.

Postmortem findings may include the following:

Enlarged joints

Reactive or congested regional lymph nodes

Degeneration of tissues or organs

Associated lesions of another condition that may have predisposed to arthritis

Character of exudate in joints

1. Increased amount of synovial fluid
2. Blood-tinged synovial fluid
3. Turbid, sometimes purulent synovial fluid

Special Notes:

(1) Increased amount of synovial fluid is often associated with stress factors, such as being confined on concrete or being hauled long distances to market. Often this fluid is clear.

(2) As far as carcass disposition is concerned, the type of exudate present in the joints is not the primary consideration; whether or not the condition is generalized (systemic) is of most public health importance.

Postmortem disposition (Regulations 311.7)

Condemn: Arthritis with generalized changes.

Pass: Carcasses not meeting the criteria for condemnation, after condemnation and removal of any abnormal tissue.

Special Notes:

(1) The tarsal (hock) joints of swine carcasses affected with localized arthritis may be removed on the pork cut if the affected carcasses are segregated and held by the establishment as a group until this is accomplished.

(2) The number of arthritic joints should not be a primary consideration. If the arthritis is localized and can be removed by trimming, the joint should be condemned and removed along with draining lymph nodes and the carcass passed for food.

(3) Arthritic joints must be removed from the carcass before opening the joint capsule. This is done to avoid contamination of edible product with joint exudate. (9CFR 311.7)

Pericarditis

Pericarditis is an inflammatory condition of the pericardium that is usually due to an infectious agent.

Antemortem findings may include the following:

Subcutaneous edema of the lower abdomen and chest (brisket edema)

Distension of jugular furrow, showing a retrograde venous pulse

Tucked-up abdomen and shallow, rapid, abdominal breathing

Stiff, stilted gait; reluctance to move; elbows abducted. Front legs placed forward while at standing rest

Weakness, ataxia

Fever—variable, depending upon stage of condition

Pain elicited on palpation of cardiac region

Cachexia with dehydration, sunken eyes, rough hair coat

Antemortem disposition (Regulations Part 309)

Condemn: When pericarditis with generalized (systemic) involvement can be diagnosed, the animal shall be condemned.

Suspect: When an animal exhibits signs of pericarditis, but does not show conclusive signs of a generalized (systemic) effect, it shall be handled as a suspect.

Postmortem findings may include the following:

Traumatic reticulitis with penetration of the diaphragm and pericardium by a foreign body

Purulent pericarditis with or without traumatic origin

Serofibrinous or fibrinous pericarditis or epicarditis (shaggy heart)

Edema of body tissues and fluid accumulations (ascites, pleural effusion)

Putrefactive odor of cut-surface of pericardial, abdominal, or thoracic lesion

Postmortem disposition (Regulations 311.16)

Condemn: When there is a purulent or septic pericarditis associated with generalized changes

Pass: Carcasses not meeting the criteria for condemnation, after condemnation and removal of any abnormal tissue.

Special Note: A large pocket of pus around the heart does not require automatic condemnation.

Pneumonia

Pneumonia is an inflammatory condition of the lungs that may be caused by infectious agents, parasites, physical trauma, or foreign material inhalation.

Antemortem findings may include the following:

Variable temperature—depending upon stage of disease and ambient temperature. Temperature may range from very high to subnormal; each case will have to be independently assessed by the PHV.

General depression, reluctance to move

Swollen, watery eyes; sunken eyes from dehydration; injected sclera

Discharge from nostrils (serous to mucopurulent discharge)

Moribund

Cachexia

Pulmonary distress

Stands with forelimbs abducted

Antemortem disposition (Regulations Part 309)

Condemn:

1. If the animal has a high or subnormal temperature, general depression, and marked pulmonary distress
2. Pneumonia in a moribund animal

3. Pneumonia associated with cachexia

Suspect: Any animal showing signs of pneumonia without conclusive signs of a generalized (systemic) effect.

Postmortem findings may include the following:

Stages of pneumonia

1. Hyperemia—increased blood flow in pulmonary vessels
2. Red hepatization—lung is heavy, firm, and “liver-like” due to hyperemia, hemorrhage, edema, and leukocytes
3. Gray hepatization—fibroplasia into areas of red hepatization
4. Consolidation—chronic areas where fibroplasia is being organized

Lungs may be in one or more stages (red and gray hepatization) concurrently

Lymph nodes draining lungs may be swollen and hemorrhagic

Generalized lesions resulting from septic or toxic conditions may be present:

1. Reactive, hyperemic, or hemorrhagic lymph nodes in addition to those of the lungs
2. Degeneration of tissues or organs
3. Petechial or ecchymotic hemorrhages

Foreign substances in the lung, such as medicinal agents; foreign material may be medicinal in nature and it should be determined that a residue is not present in carcass tissues. Residues will be covered in a different section of the training.

Parasites

Chronic suppurative bronchopneumonia—chronically dilated airways contain exudate, which on cross-section appears as abscesses

Pneumonia with large amounts of fluid

Pneumonia/pleuritis associated with hardware disease

Special Note:

(1) Pleuritis can be associated with pneumonia or be a separate entity.

(2) Examination of the lungs for pneumonia should include incising the lung as well as opening the airways.

The following are examples of generalized conditions that may have an associated pulmonary lesion. However, they should not be confused with pneumonia caused by primary pulmonary pathogens of livestock.

(1) Pyemia with pulmonary abscesses

(2) Necrobacillosis

(3) Tuberculosis

(4) Actinobacillosis

(5) Parasitism

(6) Caseous lymphadenitis

(7) Pleuritis

(8) Aspiration of scald tank water

(9) Neoplasia

Postmortem dispositions (Regulations 311.16)

Condemn:

1. Acute extensive pneumonia associated with reactive/hyperemic lymph nodes draining lungs. Generalized (systemic) changes may not be observed at this time because the animal's system has not had a chance to react. (In this situation, if there is reason to believe that the product of the carcass may give rise to food poisoning, condemnation of the carcass is required.) (Regulations 311.1)

2. Acute extensive pneumonia with acute pleuritis

3. Pneumonia with associated generalized (systemic) changes

4. Marked pulmonary necrosis with associated toxemic changes.

Pass: Carcasses not meeting the criteria for condemnation, after condemnation and removal of any abnormal tissue.

Pleuritis

Pleuritis is an inflammatory condition of the pleural lining due primarily to infectious agents.

Antemortem findings – same as pneumonia

Antemortem disposition (Regulations Part 309)

Condemn:

1. Fever (or subnormal temperature), general depression, and marked pulmonary distress
2. Pleuritis in a moribund animal
3. Pleuritis associated with cachexia

Suspect: Any animal showing signs of pleuritis without conclusive signs of a generalized (systemic) effect.

Postmortem findings may include the following:

Fibrous adhesions between the lungs and pleura

Fibrinous exudates covering the pleura

Fluid in the thoracic cavity

Reactive thoracic lymph nodes

Pericarditis

Special Note: Pleuritis can be associated with pneumonia or be a separate entity.

Postmortem dispositions (Regulations 311.16)

Condemn:

1. Acute extensive pleuritis and pneumonia associated with reactive/hyperemic lymph nodes draining lungs. Generalized (systemic) changes may not be observed at this time because the animal's system has not had a chance to react. (In this situation, if there is reason to believe that the product of the carcass may give rise to food poisoning, condemnation of the carcass is required.) (Regulations 311.1)

2. Acute extensive pneumonia with acute pleuritis

3. Pleuritis with associated generalized (systemic) changes

Pass: Carcasses not meeting the criteria for condemnation, after condemnation and removal of any abnormal tissue.

Peritonitis

Peritonitis is a condition marked by inflammatory processes affecting the peritoneal lining which is usually caused by infectious agents although it can be initiated by intraperitoneal medications, ruptured bladder, or other irritants.

Antemortem findings may include the following:

Tucked-up abdomen, shallow thoracic breathing

Stiff-stilted gait, reluctance to move

Variable temperature—depending upon stage of disease and ambient temperature, may range from very high to subnormal; each case will have to be independently assessed by the PHV.

Congestion of mucous membranes

Loss of body condition, dehydration

Depression

Abdominal wound suggesting perforation of the peritoneal cavity

Recent parturition

Pain indicated by grinding of teeth, or elicited on palpation of abdominal wall

Rumen atony

Antemortem disposition (Regulations Part 309)

Condemn: When significant findings of peritonitis are present and there is conclusive evidence of a generalized effect.

Suspect: When an animal exhibits signs of peritonitis, but does not show signs of a generalized effect.

Postmortem findings may include the following:

Pathologic hemorrhage

Generalized, acute lymphadenitis

Injection sites

Degeneration of tissues or organs

Accumulation of fluid in abdominal cavity

Trauma of the abdomen (trocar wounds, penetrations of the genital tract, injuries of the abdominal wall and primary reticuloperitonitis)

Special Note: The following are examples of conditions that may be associated with peritonitis, but should not be confused with infectious peritonitis that might occur in livestock:

1. Tuberculosis of the peritoneum
2. Injections into abdominal musculature; bruises of or trauma to the abdominal wall
3. Adhesions
4. Neoplasia
5. Free hemorrhage gives peritoneal surfaces a reddish appearance

Postmortem disposition (Regulations 311.16)

Condemn:

1. When there is an acute diffuse peritonitis without generalized changes
2. Peritonitis associated with generalized changes.

Pass: Carcasses not meeting the criteria for condemnation, after condemnation and removal of any abnormal tissue.

Gastroenteritis

Gastroenteritis is an inflammation of the stomach and intestinal tract usually caused by an infectious agent or parasite.

Antemortem findings may include the following:

Variable temperature—depending upon stage of disease and ambient temperature. Temperature may range from very high to subnormal; each case will have to be independently assessed by the PHV.

Diarrhea, rectal prolapse, or vomiting

Dehydration, dry nose, sunken eyes; loose skin may be made to "tent" by digital manipulation

Gaunt—tucked-up abdomen

Weakness, ataxia, depression

Stiff, stilted gait, saw-horse stance

Pain—teeth grinding

Antemortem disposition (Regulations Part 309)

Condemn:

1. Abnormal temperature with profuse diarrhea or vomiting.
2. Debilitation, dehydration, or cachexia associated with gastroenteritis.

Suspect: Any animal with diarrhea or vomiting, but inconclusive signs of generalized effect.

Postmortem findings may include the following:

Inflammation of stomach or intestine

Intussusception, volvulus, torsion, rectal prolapse

Acute generalized (systemic) changes in lymph nodes

Degenerative changes in tissues or organs

Gangrenous stomach or intestine

Acute, extensive hemorrhagic or gangrenous enteritis with or without generalized changes

Postmortem disposition (Regulations 311.16)

Condemn:

1. When there is acute, extensive hemorrhagic or gangrenous enteritis
2. When there is any degree of gastroenteritis with generalized (systemic) changes

Pass: Carcasses not meeting the criteria for condemnation, after condemnation and removal of any abnormal tissue.

Nephritis

Nephritis is an inflammatory condition of the kidneys. Etiologies may include infectious agents, parasites, or toxins.

Antemortem findings may include the following:

Variable temperature—depending upon stage of disease and ambient temperature. Temperature may range from very high to subnormal; each case will have to be independently assessed by the PHV.

Abnormal physical appearance of urine (purulent material, blood)

Frequent urination or attempts to urinate

Poor condition

Uremic odor of breath

Accumulations of crystals on preputial hair

An animal with acute nephritis usually shows pain (e.g., grinding of teeth, kicking at abdomen, switching of tail).

Toxic signs of renal impairment (muscle tremors, exophthalmia, abdominal pain, frothy salivation, polyuria, and bruxism), with muscle tremors progressing to incoordination and weakness; pulmonary edema leads to marked salivation, dyspnea, and gasping.

Antemortem disposition (Regulations Part 309)

Condemn: A specific diagnosis of nephritis is not really possible without more specific diagnostic assistance than is available to in-plant PHVs.

Suspect: Animals showing signs of nephritis that may require condemnation of the carcass on postmortem inspection.

Postmortem findings may include the following:

Inflammation, enlargement, pathological hemorrhage, or change of color in kidney

Multiple abscesses of entire kidney

Pyelonephritis--an ascending infection resulting in accumulation of pus in the ureters, renal pelvis, medulla and or cortex

Generalized degeneration of tissues, organs, and lymph nodes

Generalized edema from hypoproteinemia

Uremic odor of carcass, indicating uremia

Special Note: Certain conditions should not be confused with primary nephritis:

- (1) Kidney worms in swine
- (2) Urinary obstructions (uroliths)
- (3) Infarcts
- (4) Neoplasms
- (5) Renal cysts or polycystic kidneys
- (6) Hydronephrosis
- (7) Traumatic injuries
- (8) Depressed white areas—scars resulting from previous infarcts or nephritis

Postmortem dispositions (Regulations Part 311)

Condemn:

1. Nephritis (acute or chronic) associated with generalized lesions or disease
2. Pyelonephritis associated with generalized changes
3. Uremia associated with any stage or type of nephritis

Pass: Carcasses not meeting the criteria for condemnation, after condemnation and removal of any abnormal tissue.

Special Note:

- (1) Carcasses with chronic interstitial nephritis—white, firm, depressed, or pitted kidneys—should be passed for food, if there are no generalized changes, after condemnation of and removal of abnormal tissues.
- (2) Hydronephrosis and extensively cystic kidneys do not warrant condemnation of the carcass in the absence of uremia when no generalized changes are present. All abnormal tissues should be condemned and removed.
- (3) White spotted kidneys of calves are a subacute to chronic nephritis that contain extensive infiltrates of lymphocytes and plasma cells that produce masses that may be difficult to differentiate from lesions of lymphoma. Laboratory assistance may be required.
- (4) Specific disease conditions that have an associated nephritis should carry the diagnosis of the specific condition.

Mastitis

Mastitis is an inflammation of the udder tissue usually associated with a bacterial infection.

Antemortem findings may include the following:

Traumatic injury to the udder

Swollen udder may range from a slight edema to a hard, feverish, painful enlargement involving the quarter or whole udder

Reluctance to move because of avoidance of pain

Anorexia, dehydration, cachexia, depression

Variable temperature—depending upon stage of disease and ambient temperature. Temperature may range from very high to subnormal; each case will have to be independently assessed by the PHV.

Purulent to sero-sanguinous exudate

Gangrenous blue-black discolored area may be sloughing

Antemortem disposition (Regulations Part 309)

Condemn: Any animal with mastitis exhibiting generalized signs.

Suspect: Animals with mastitis having sufficient clinical signs to indicate that the carcass will likely be condemned on postmortem inspection.

Special Note: There may be conditions affecting the udder that will not require suspecting the animal, such as pendulous udders. Cattle with pendulous udders are, however, prone to mastitis.

Postmortem findings may include the following:

Hyperemia in the area of udder attachment

Associated metritis

Traumatic injury of the udder

Foul-smelling exudate—abnormal milk, gangrenous tissue

Disease-related hemorrhage

Reactive or edematous lymph nodes

Degenerative changes of organs/tissues

Postmortem disposition (Regulations 311.16)

Condemn: When mastitis is associated with generalized (systemic) changes

Pass: Carcasses not meeting the criteria for condemnation, after condemnation and removal of any abnormal tissue.

Special Note:

(1) Mammary lymph nodes in mature dairy cows are often hyperplastic.

(2) Enlarged, hyperplastic regional lymph nodes alone are not sufficient reason to condemn the carcass if the carcass and viscera are otherwise normal.

(3) An acute lymphadenitis of a mammary lymph node might be significant, particularly if the udder has been removed and discarded during dressing.

Metritis

Metritis is an inflammatory condition of the uterine tract, usually of bacterial origin.

Antemortem findings may include the following:

Vaginal discharge with foul odor

Exudate on perineal hair

Remnants of fetal membranes protruding from vulva

Tucked-up abdomen

Temperature—variable, depending on stage of infection, ambient temperature

Depression, cachexia

Tenesmus

Antemortem disposition (Regulations Part 309)

Condemn: Animals with metritis exhibiting generalized signs

Suspect: Animals with diagnosis of metritis showing inconclusive signs of generalized involvement

Special Note: Any animal with retained fetal membranes should be withheld from slaughter. Upon passage of fetal membranes, if the animal is otherwise normal, pass for regular slaughter. Any animal treated for retained fetal membranes should meet withdrawal times for any medication used.

Postmortem findings may include the following:

Thickened, hyperemic or congested uterine wall

Endometritis

Purulent to watery material (often with a foul odor) within uterus

Generalized, acute, reactive, or edematous lymphadenitis

Associated degenerative changes in tissues/organs indicative of generalized involvement

Pyemia

Dead macerated fetus

Special Note: Metritis is not associated with a dry mummified fetus.

Postmortem disposition (Regulations 311.16)

Condemn: When the metritis is associated with generalized (systemic) changes

Pass: Those carcasses not meeting the criteria for condemnation shall be passed after condemnation and removal of any abnormal tissue.

Special Note: Purulent material in the uterus alone does not indicate generalized (systemic) involvement. The uterus tends to discharge its contents and contain its disease processes relatively well.

Necrobacillosis

Necrobacillosis is a condition resulting from the entry of the organism *Fusobacterium necrophorum* into the tissue or organs.

Antemortem findings may include the following:

Foot rot

Cachexia

Dyspnea

Nasal discharge

Pyrexia

Antemortem disposition (Regulations Part 309)

Condemn: When evidence indicates foot rot is associated with a generalized (systemic) condition.

Suspect: When foot rot is associated with other clinical signs, suggesting that after postmortem examination the carcass may need to be condemned.

Postmortem findings may include the following:

Generalized multiple purulent lesions (pyemia) occurring as a result of the entrance of the bacteria *Fusobacterium necrophorum* into the systemic circulation (e.g., acute lesions in the lung after rupture of a hepatic abscess into the vena cava, or pulmonary hemorrhage resulting from the erosive processes of a lung lesion).

Abscesses in liver, lungs, rumen, etc

Disease-related hemorrhages

Reactive or edematous lymph nodes

Degenerative changes of organs/tissues

Special Note: The number of lesions present in a liver is less significant than the presence of associated generalized toxic changes and bacterial embolism.

Postmortem disposition (Regulations 311.17)

Condemn: When necrobacillosis is associated with generalized lesions.

Pass: Those carcasses not meeting the criteria for condemnation shall be passed after condemnation and removal of any abnormal tissue.

Swine Erysipelas

Erysipelas is a disease of swine caused by the organism *Erysipelothrix rhusiopathiae*.

Antemortem findings may include the following:

Fever in acute stages; some variation, but this is a highly febrile disease

Will move about if forced, but squeal in pain

Bright and alert, but are reluctant to move due to painful or swollen joints 022A

Diffuse areas of purple skin (acute) to raised, red, edematous, rhomboid wheals (acute stages) to sloughing of affected dead areas of skin (chronic)

Arthritis, a lesion seen in naturally occurring disease and vaccine-associated disease

Sudden death of affected animals in acute disease is characteristic—especially if animal is excited

Antemortem disposition (Regulations 309.2)

Condemn: If fever and signs of acute erysipelas are present, indicating the carcass would be condemned on postmortem

Suspect: If skin lesions and clinical signs indicate erysipelas, but insufficient for condemnation

Special Note:

(1) Transport injury (sore feet): This can result from pigs being raised on concrete and should not be confused with erysipelas.

(2) Trauma from cane or boot marks, rough handling, or animals fighting can be confused with lesions of erysipelas.

Postmortem findings may include the following:

Arthritis

Vegetative endocarditis

Skin lesions, which may vary from acute to chronic

In acute disease, generalized lymphadenitis

Petechial hemorrhage may be noticeable in lungs, kidneys, heart, or on serosal surfaces

Degeneration of tissues or organs

Postmortem dispositions (Regulations 311.5 and 311.6)

Condemn:

1. If disease is acute, as evidenced by skin lesions associated with petechial hemorrhages in the kidneys, hemorrhagic and congested lymph nodes, and degeneration of organs
2. Acute, extensive skin lesions, with generalized, acute, reactive, lymphadenitis with no visible involvement of body organs
3. Erysipelas resulting in arthritis when associated with acute degeneration of organs and tissues

Pass: Carcasses not meeting the criteria for condemnation, after condemnation and removal of any abnormal tissue

Special Note: "Diamond skin" is a common name for erysipelas in swine with skin lesions. This condition is often localized to the skin without generalized lesions. The skin, in such cases, is condemned and trimmed, and the carcass may then be passed for human food.

Caseous Lymphadenitis

Caseous Lymphadenitis (CLA) is a disease of sheep and goats caused by the organism *Corynebacterium pseudotuberculosis*.

Antemortem findings may include the following:

Weight loss, cachexia, debilitation.

Enlargement (suppuration) of superficial lymph nodes

Abscesses in the lungs and associated pneumonia often produce respiratory signs.

Fever

Antemortem disposition

Condemn: When obvious CLA is associated with systemic signs

Suspect: When the animal exhibits signs of CLA and has possible, but not conclusive, signs of systemic effects

Special note: The dispositions of sheep and goat carcasses with CLA are based on two criteria: the carcass condition (well nourished or thin) and the extent and distribution of lesions in the carcass and viscera (slight, well marked, extensive and numerous). When an affected carcass is allowed to be used as human food (either passed for cooking or passed after trimming), all diseased tissue must be removed and condemned.

Postmortem findings may include the following:

Enlarged abscessed lymph nodes with greenish white-yellow caseous exudate, which tends to become dry and granular

In sheep, cross-sections of lesions contain remnants of connective tissue capsules (resembles the concentric rings seen on the cut surface of an onion). This is not characteristic of the infection in goats.

Lesions found in many lymph nodes, especially the subiliac, superficial cervical, deep popliteal, tracheobronchial, and mediastinal, as well as lungs, heart, liver, spleen, and kidneys

Definition of terms in the caseous lymphadenitis regulation (311.18)

Viscera - A primary compartment; includes organs and associated lymph nodes that may be affected with lesions of caseous lymphadenitis

Skeletal lymph nodes - The other primary compartment; includes the carcass lymph nodes

Slight - Small in size, quantity, or number; of no significance; so small or unimportant or of so little consequence as to warrant little or no attention. As applied to certain liver abnormalities, slight means that the lesions are small and few.

As applied to tuberculosis lesions in lymph nodes, slight means that the lymph node is of normal size and has more normal than diseased tissue.

Well-marked - To a higher degree than having a distinctive or emphasized character, attracting notice or attention; noticeable, unlikely to escape observation; prominent, stands out from its surroundings or background; conspicuous, obvious or unavoidable to the sight

Numerous - Consisting of great numbers of units or individuals

Extensive - Not definitely limited, concentrated, or localized; widely distributed; having wide or considerable extent; widespread, widely diffused or prevalent; widely extended or spread out. Not restricted to a definite locality; existing in or affecting all or most of a carcass or part. Exceeding the usual, proper, or normal; implies an amount or degree too great to be reasonable or acceptable. As applied to tuberculosis lesions in lymph nodes, extensive means that the lymph node is greatly enlarged, or nearly all of the lymph node tissue is affected. As applied to tuberculosis lesions in tissues other than lymph nodes, extensive means that more than half of the organ or tissue surface is affected.

Well-nourished carcass - having the flesh characteristics of a robust, healthy, immature or mature carcass

Thin carcass - While not emaciated or anemic, this carcass has much less flesh quality than a well-nourished carcass

Postmortem disposition (Regulations 311.18)

Condemn:

1. A thin carcass having well-marked lesions in the skeletal lymph nodes and viscera
2. A thin carcass having numerous and extensive lesions in either the skeletal lymph nodes or the viscera
3. A well-nourished carcass having both numerous and extensive lesions

Pass for cooking:

1. A thin carcass showing well-marked lesions in either the skeletal lymph nodes or the viscera

2. A well-nourished carcass showing marked lesions in both the skeletal lymph nodes and the viscera

Special Note: Diseased carcasses with lesions less severe than those requiring condemnation of the carcass but more severe than those allowed to pass after trimming are eligible for use as “Passed for Cooking”. Affected tissues from such carcasses must be condemned and thoroughly trimmed before being designated as “Passed for Cooking.” These carcasses must be held under FSIS control until the product has met the processing restriction “Passed for Cooking” before being allowed for use as human food.

Pass: Those carcasses not meeting the criteria for condemnation or “Passed for Cooking,” after condemnation and removal of any abnormal tissue; this disposition category accounts for the great majority of cases of caseous lymphadenitis in sheep and goats.

Caseous Lymphadenitis Disposition Guide

Any carcass:

affected with numerous and extensive lesions is *condemned*

affected with slight lesions only is trimmed and *passed*

A thin carcass:

affected with well-marked lesions in any one compartment must be *cooked*

affected with well-marked lesions in both compartments must be *condemned*

A well nourished carcass:

affected with well-marked lesions in one compartment is *trimmed and passed*

affected with well-marked lesions in both compartments must be *cooked*

(“carcass” includes edible viscera)

Actinobacillosis and Actinomycosis

(1) Actinobacillosis is due to infection of soft tissues, especially the tongue, by *Actinobacillus lignieresii*, a gram-negative rod. Granulomas caused by this agent may also be present in cervical lymph nodes, muscles, lungs, or other internal organs.

(2) Actinomycosis is due to infection by *Actinomyces bovis*, a gram-positive filamentous rod that causes granulomas, most often in the bone of the mandible or maxilla of cattle, but which may also affect lymph nodes and other soft tissues.

Special Note: "Acti" is the term commonly applied to both of these conditions.

Certain conditions can be confused with "acti" on antemortem:

- (1) Abscessed teeth
- (2) Sinusitis
- (3) Injuries
- (4) Lymph node metastasis of squamous cell carcinoma
- (5) Sialoadenitis, sialoliths, cysts
- (6) Neoplasms
- (7) Food impacted in the jaw (especially in old cows)

Antemortem findings may include the following:

Swelling or enlargement of soft tissue (including tongue) or hard tissue of head and neck. There may be draining fistulous tracts.

Draining fistulous tracts on udders of sows

Excessive salivation

Cachexia

Antemortem disposition (Regulations Part 309)

Condemn: Livestock plainly showing, on antemortem inspection, actinobacillosis or actinomycosis to the extent that, under Meat and Poultry Inspection Regulation part 311, it would cause condemnation of the carcasses on postmortem inspection, shall be identified as U. S. Condemned and disposed of according with part 309.13.

Suspect: Any animal having actinobacillosis or actinomycosis to a lesser degree than that requiring condemnation

Postmortem findings may include the following:

Generalized involvement—as indicated by distribution of active lesions (definition below), made possible only by entry into the systemic circulation; e.g., extensive lesions (definition below) or active lesions beyond the mandibular lymph nodes and the lungs and their lymph nodes

Localized involvement—as indicated by confinement with no indication of generalized (systemic) involvement

Extensive lesions—Not definitely limited, concentrated, or localized; widely distributed; having wide or considerable extent; widespread, widely diffused, or prevalent; widely extended or spread out. Not restricted to a definite locality; existing in or affecting all or most of a carcass or part. Exceeding the usual, proper, or normal; implies an amount or degree too great to be reasonable or acceptable; involvement indicated by numerous lesions distributed throughout lung, or most of lung tissue involved with large lesions

Active lesions—Lesions showing acute inflammation and lack of encapsulation

Special Note: The following lesions could be confused on postmortem with lesions of "acti":

- (1) Tuberculosis
- (2) Fungal granulomas
- (3) Chronic pneumonia with abscess
- (4) Granulomas due to foreign bodies (parasites, weed awns) or other agents (coccidioidomycosis, mucormycosis)
- (5) Metastatic tumors

Postmortem disposition [Regulations 311.2 (a)(1)]

Condemn: When active acti lesions are generalized (when the lesions are distributed in a manner that is possible only by entry of the bacilli into the systemic circulation)

Pass: With condemnation and removal of affected parts. (Regulations 311.9)

1. Heads (including the tongue) that are affected with either disease shall be condemned except:
 - a) When the disease is slight, strictly localized, without suppuration, without fistulous tracts, and without lymph node involvement, the tongue may be passed for human food if free from disease.

- b) When the disease is slight and confined to the lymph nodes, the head and tongue may be passed for human food after the affected lymph nodes are removed and condemned.
2. When the disease is slight and confined to the tongue, with or without involvement of the corresponding lymph nodes, the head may be passed for food after removal and condemnation of the tongue and corresponding lymph nodes. The "corresponding" lymph nodes include the medial retropharyngeal, lateral retropharyngeal, and the mandibular lymph nodes.
3. Well-nourished carcass with localized lesions is passed after infected parts are removed and condemned.

Tuberculosis

Tuberculosis is an infectious disease caused by certain pathogenic acid-fast organisms of the genus *Mycobacterium*.

Special Notes:

(1) APHIS TB reactors are tagged and branded (on the left hip) prior to being sent to slaughter. Cattle that have reacted to a tuberculin test administered by an Animal and Plant Health Inspection Service (or State or accredited veterinarian) are accompanied by APHIS Form V.S. 1-27, and are tagged as APHIS TB reactors. TB reactors are treated by an FSIS PHV as "U.S. Suspect" for slaughter and inspection purposes.

(2) TB-suspect and TB-exposed cattle are antemortem designations based on testing results or the ecological background of cattle. For Veterinary Services Live Animal Categories, Handling Procedures, and Collection of Identification Devices for TB-suspect cattle, TB-exposed cattle, and Mexican (M-branded cattle), refer to FSIS Directive 6240.1. (Also refer to Directive 6240.1 for information regarding preparation of lesions for submittal and preparation of forms to report lesions.)

(3) Establishment personnel must segregate all APHIS TB reactors [referred to in (1) above], TB suspects, or TB-exposed animals and must identify them to the PHV before antemortem inspection is performed (FSIS Directive 6240.1).

(4) The FSIS PHV performs all of the antemortem and postmortem inspection, diagnosis, and disposition procedures on all TB reactors, TB-exposed, and TB-suspect cattle (laboratory assistance for diagnostic purposes).

(5) The term "TB suspect," used to identify animals that reacted inconclusively to the injection of tuberculin, should not be confused with the term "U.S. Suspect" used on animals identified on antemortem.

(6) Special references for all species includes the Meat and Poultry Inspection Regulations; FSIS Directives 6240.1, Bovine Mycobacteriosis (*M. bovis*) Disposition Guideline, and 6200.1, Preparation and Submission of FSIS 6200 Form Series.

(7) Bovine mycobacteriosis is defined as cattle having *Mycobacterium bovis* [FSIS Directive 6240.1, Bovine Mycobacteriosis (*M. bovis*) Disposition Guideline]. However many pathologists also refer to Johne's Disease (*M. paratuberculosis*) in cattle as mycobacteriosis.

Antemortem findings may include the following:

Weakness

Weight loss

Cachexia

Low-grade fever

Intermittent, "hacking" cough

Superficial lymph nodes swollen and firm

Antemortem disposition (Regulations 309.2)

Special note: Bovine TB reactors that are dead on arrival, died in pens, or that were condemned by a PHV shall be given a complete postmortem examination in the inedible products department or other non-edible area found suitable to the PHV.

Condemn: If a TB reactor has to be condemned on antemortem, it shall be given a thorough postmortem examination in the inedible products department or other area approved by the PHV (FSIS Directive 6240.1).

Suspect: All reactors are identified U.S. Suspects (using the USDA Reactor tag in lieu of Suspect tag)

Postmortem findings may include the following:

Definitions that apply to tuberculosis lesions

Localized - Not extensive; restricted to a limited region or to one or more foci.

Slight - As applied to tuberculosis lesions in lymph nodes, slight means that the lymph node is of normal size and has more normal than diseased tissue.

Well-Marked - As applied to tuberculosis lesions in lymph nodes, well-marked means that the lymph node is enlarged, or that the lymph node is of normal size but has more diseased than normal tissue.

Extensive - As applied to tuberculosis lesions in lymph nodes, extensive means that the lymph node is greatly enlarged, or nearly all of the lymph node tissue is affected. As applied to tuberculosis lesions in tissues other than lymph nodes, extensive means that more than half of the organ or tissue surface is affected. Multiple means that there are lesions in more than one organ. Acute, progressive means tissue surrounding caseous lesion is edematous and congested or hyperemic; or that several similar small lesions are occurring around an older focus.

Special Note:

- (1) The FSIS PHV performs all postmortem inspection, diagnostic, and disposition procedures on all TB reactors, TB-exposed, and TB- suspect cattle.
- (2) The PHV should be sure to report all nonreactor cattle and calves with lesions resembling tuberculosis on V.S. Form 6-35. Send specimens to the Veterinary Services Laboratory at Ames, IA (FSIS Directive 6240.1).
- (3) Cattle identified as TB reactors and TB suspects shall receive a postmortem examination using the procedures described above.
- (4) Cattle identified as TB-exposed shall receive a modified expanded inspection procedure by incision of the superficial inguinal and mesenteric lymph nodes, in addition to the routine inspection procedure.
- (5) In the case of cattle without any special tuberculosis designation as well as those identified as TB- exposed and TB suspects that are found on postmortem inspection to have lesions that are suspicious of being mycobacteriosis, the PHV shall submit the specimens for diagnostic laboratory assistance.
- (6) The following are examples of conditions that could be confused with tuberculosis on postmortem:
 - A. Other granulomas (such as coccidioidomycosis or mucormycosis)
 - B. Non-tuberculous abscesses
 - C. Caseous lymphadenitis
 - D. Actinobacillosis or actinomycosis
 - E. Adrenal gland tumors (often have a "gritty" calcified texture when incised)
 - F. In situ or metastatic neoplasia
 - G. Malignant lymphoma
 - H. Mesothelioma

TB Granulomas

Tuberculosis granulomas vary in morphology because of the organism's unique virulence factors and the host species physiologic response. Such a granuloma consists of two components, an exudative one and the proliferation of a limiting capsule.

1. Cattle— *M. bovis* and *M. tuberculosis* primarily affect the respiratory system. In cattle, the exudative (caseous-calcareous) component is typically more prominent than the capsule.

- A. Lymph nodes of head and lungs; the lungs and pleura are usually affected
- B. Lesions involving the lymph nodes of the digestive tract, liver, and peritoneum, also occur.
 - i. Active (acute) lesions may have edema and congestion or hyperemia in the periphery surrounding the caseous mass.
 - ii. Chronic lesions typically have caseo-calcareous exudate with heavier capsule proliferation-fibroplasia (organization).
 - iii. Old, inactive lesions may become very calcareous and heavily encapsulated.

2. Swine—Mycobacterial infections in swine primarily affect the digestive system and are due to bacteria of the *Mycobacterium avium* group, though infections with *M. bovis* or *M. tuberculosis* may occur

Lesions are most frequently found in the cervical lymph nodes, mesenteric lymph nodes, liver, and spleen. Pulmonary involvement may also occur. In swine, the proliferative component (thick-walled capsule) is more abundant. In incising these lesions, the cut surface demonstrates the production of the capsule with a small focus of caseous exudate, which may be mineralized.

3. Sheep & Goats— Disease is rare. Lesions (similar in most respects to cattle) most commonly occur in the lymph nodes of the respiratory tract and lungs.

4. Calves— Prenatal tuberculosis has been reported

- A. Peritoneal lesions.
- B. Pleural and thoracic lesions.
- C. Other visceral lesions (liver, intestine, spleen).

5. Horses— TB is rare; most infections, when they occur, are of the alimentary tract, chiefly due to *M. bovis*. Lesions most often occur in the retropharyngeal or mesenteric

lymph nodes and have a lepromatous appearance (resembling a sarcoma), occasionally with some caseous exudate (though calcification is unusual).

6. Cervids— for comparative medicine purposes, tuberculosis occurs both in captive and wild cervids; the appearance of lesions are often that of a suppurative abscess.

Postmortem disposition (Regulations 311.2)

Special Notes:

(1) Laboratory assistance:

- A. For cattle, TB-exposed and TB-suspect specimens, send V.S. Form 10-4 with the specimen to the USDA/APHIS National Veterinary Services Laboratory (NVSL), Ames, Iowa.
- B. For cattle, a routine postmortem on nonreactors, send V.S. Form 6-35 with the specimen to USDA/ APHIS National Veterinary Services Laboratory (NVSL), Ames, Iowa.

Histopathology results from NVSL indicating that the lesions are “compatible” with or “suggestive” of mycobacteriosis shall be considered positive for *M. bovis*.

- C. For swine, the specimen should be sent with a completed FSIS Form 10,300-2 to the USDA/FSIS Eastern Laboratory, Athens, Georgia.

Condemn:

1. The carcass of any species (including organs and parts) [Reg. 311.2(a)] is condemned for tuberculosis when any of following conditions occur:

- A. TB lesions are generalized (when lesion distribution indicates entry of the organism into the systemic circulation).
- B. TB occurs in any muscle, intermuscular tissue, bone, joint, or abdominal organ (excluding the gastrointestinal tract), or in any lymph node as a result of draining a muscle, bone, joint, or abdominal organ (excluding the gastrointestinal tract).
- C. TB lesions are extensive in the thoracic or abdominal cavity.
- D. Active TB lesions associated with fever on antemortem.
- E. TB lesions are associated with cachexia
- F. TB lesions are multiple, acute, and actively progressive.
- G. The character of TB lesions are otherwise not indicative of a localized condition.

2. An organ or part [Reg. 311.2 (b)]:

When an organ or part or its corresponding lymph node of swine, cattle, sheep, goat, or equine is affected with a TB lesion and the carcass is otherwise normal, that organ or part or lymph node shall be condemned.

Carcasses (and parts) passed without processing restriction for human food:

1. Cattle—only nonreactors, TB suspects, or TB-exposed cattle that do not have tuberculosis lesions can be passed for human food without restriction [Reg. 311.2 (c)].

TB Reactors (even those having no lesions) cannot be passed for human food without the “U. S. Passed for Cooking” processing restriction [Reg. 311.2 (d)(1)].

2. Swine—a swine carcass may be passed without restriction as long as any TB lesions are localized and limited to one primary seat. (Primary seats are defined as the mandibular, mesenteric, and mediastinal lymph nodes [Reg. 311.2(e)]. Affected tissues must be removed and condemned.

3. Any livestock (excluding TB reactors) that do not have any tuberculosis lesions can be passed for human food without any processing restriction. TB Reactors (with no lesions) cannot be passed for human food without the “U S. Passed for Cooking” processing restriction. [Reg. 311.2(g)].

Carcasses and parts with a “U. S. Passed for Cooking” processing restriction (170 ° F internal temperature, for 30 minutes) must remain under FSIS control until the processing restriction is met [Reg. 315.1].

1. Cattle [Reg. 311.2(d)]

A. TB reactors, TB suspects, TB-exposed carcasses or non reactors with lesions that are localized and calcified or encapsulated must be passed with the “U.S. Passed for Cooking” restriction before being allowed to be used as human food. To accomplish this, any gross lesions that are present must be:

- i. Less extensive than that requiring condemnation of the carcass, and
- ii. The lesions are condemned and removed.

B. Carcasses of TB reactors must be “U. S. Passed for Cooking” before being allowed for human food, even if they are free of gross lesions.

2. Swine [Reg. 311.2 (f)]

A. A swine carcass with lesions of tuberculosis that are localized and calcified or encapsulated confined to two primary seats, or

B. To an extent less than that requiring condemnation must be “U. S. Passed for Cooking” before being allowed for human food.

C. Further inspection procedures used for swine to provide data to arrive at a disposition.

- i. Abscess/tuberculosis: When a swine carcass has cervical lymph nodes with a slight abscess and mesenteric lymph nodes with a tuberculosis lesion, such carcass shall be retained and examined by the PHV. If the cervical lesion is definitely an abscess, the carcass may be passed without restriction for food.
- ii. Further incisions: Public Health Veterinarians should incise and observe all body lymph nodes of carcasses retained for tuberculosis with the following exceptions:
 - a. Incisions of body lymph nodes may be omitted when lesions are in the lymph nodes of head and mesentery only.
 - b. Incision of superficial cervical (prescapular) lymph nodes may be omitted when caudal deep cervical lymph nodes (prepectorals) and thoracic pleura have no lesions.
 - c. Incision of subiliac (prefemoral) lymph nodes may be omitted when scrotal (superficial inguinal), sublumbar, and iliac lymph nodes show no lesions.

3. Sheep, Goats, and Equine [Regulations 311.2 (h)]

Any carcass affected with tuberculosis to a lesser extent than that requiring condemnation shall be “U. S. Passed for Cooking”.

Coccidioidal Granuloma

A disease of mammals caused by the organism *Coccidioides immitis*. It usually manifests itself as thoracic granulomas.

Antemortem findings and disposition - not detectable on antemortem.

Special Notes:

- (1) Usually these granulomas are a sequella to a rapidly healing and common pneumonia (up to 20% of cattle may be affected in endemic areas) due to infection by a soil borne fungus (*Coccidioides immitis*) common in the Southwestern U. S.
- (2) Endemically seen in man in the same areas that are endemic for cattle

- (3) In endemic infection in cattle, lesions are generally confined in the lungs and their lymph nodes
- (4) Infection not easily spread
- (5) The real significance of coccidioidal granulomas is that they may be confused with lesions of tuberculosis.

Postmortem findings may include the following:

Granulomas in the lymph nodes of the lungs. The lesion will commonly make the lymph node appear pear-shaped.

Granulomas in the lungs

Postmortem disposition (Regulations 311.36)

Condemn:

1. When there is acute diffuse lung disease and lymph node disease due to *Coccidioides immitis*.
2. When there are generalized (systemic) changes associated with *Coccidioides immitis* infection.

Pass: Carcasses not meeting the criteria for condemnation, after condemnation and removal of any abnormal tissue.

Remember, it is important to consider tuberculosis when dealing with any potential granuloma!

Bruises and Injuries

Antemortem findings may include the following:

Impaired function such as downer or a lame animal

Fractures, dislocations

Abrasions, wounds, and hematomas.

Generalized (systemic) change or signs of septicemia, toxemia, /or a variable temperature.

Antemortem disposition

Condemn: Bruised or injured animals showing signs of generalized (systemic) effects

Suspect: Those animals showing signs of injury or fracture with no conclusive signs of generalized (systemic) involvement

Special Note: All non-ambulatory disabled cattle must be condemned and disposed of according to 309.13.

Postmortem findings may include the following:

Septic inflammations

Injection lesions

Agonal hemorrhages, especially of the kidney

Localized recent bruises, injury, or fracture with hemorrhage into the tissues

Bruise showing hemorrhagic regional lymph nodes

Extensive bruises of body tissues over practically the whole carcass

Postmortem disposition

Condemn:

1. Carcasses showing extensive, generalized bruising that cannot be removed by trimming.
2. Bruised or injured carcasses that show associated systemic changes of septicemia or toxemia.

Pass: Localized bruised tissues or fractures may be removed from the carcass by trimming and the remaining tissues may be passed for food.

Special Notes:

(1) From an otherwise acceptable carcass, even a small amount of normal tissue may be saved for human food.

(2) The establishment may choose not to trim a bruised/injured carcass; if so, the carcass will be reported on applicable reports as being tanked by the establishment and not as being condemned by the veterinarian.

(3) A carcass condemned for non-septic bruises or injuries is eligible for animal food (pet food) provided:

- A. The circuit supervisor has granted permission. (Regulations 314.11)
- B. All parts are freely slashed and adequately identified in an inedible area under FSIS supervision. (Regulations 314.11)

Emaciation

Emaciation is a condition that develops because of a low intake of food or an increase in the metabolic rate that causes the animal to deplete its normal body fat and protein reservoir. As this depletion becomes more pronounced, a typical abnormal physiological change in the fat and muscle tissues occurs. Some causes are poor teeth, poor diet, starvation, or chronic wasting diseases.

Special Note:

(1) Emaciation is purely a postmortem descriptive term and does not in any way apply to antemortem inspection.

(2) A thin animal may be a normal animal with small amounts of body fat.

(3) Cachexia is an antemortem descriptive term that indicates a chronic wasting condition.

Antemortem findings

Poor condition, tight skin or wrinkled skin

Weakness, debilitation

Rough hair coat, may be patchy

Sunken eyes

Gauntness

Depression

Antemortem disposition

Condemn: This should not occur; emaciation is a postmortem descriptive term indicating the condition of a carcass that shows serous infiltration of its fat and muscle tissues.

Suspect: Animals with a primary clinical disorder associated with cachexia that do not justify condemnation on antemortem inspection.
Emaciation

Postmortem findings may include the following:

Serous infiltration and degenerative change of virtually all visceral and body fat

Serous infiltration and degeneration of muscular tissue is observed. The affected muscle usually has a glassy, moist appearance

Disease or abnormal condition associated with emaciation

A pronounced serous infiltration and degeneration might be observed at the head inspection station

In the split carcass of an older normal cow, the fat between the spinal processes will droop, but retain normal fat appearance

In the old emaciated cow, fat becomes clear and jelly-like or watery and “actually hangs from an intervertebral space.” Fluid from a hanging emaciated carcass will “drip” from the neck.

Special Note: If any appreciable amount of normal fat is found in the carcass, it would be an important factor in deciding to pass the carcass if everything else is normal. A fairly common finding is heart cap fat showing degeneration and the rest of the carcass showing no signs of serous infiltration and degeneration. This is noted especially in bulls after completion of a heavy service period, and is also seen in old ewes. The following conditions could be confused with emaciation, as they can produce some of the same findings:

- (1) Generalized edema, dropsy
- (2) Leanness
- (3) Anemia
- (4) Uremia—sometimes caused by obstructions such as urinary calculi.

Serous infiltration and degeneration of the fat precedes the serous infiltration of the muscle.

Standards for condemnation should not change when changing from a young cattle kill to an old cattle kill. Remember, the old cattle will look poor compared to the young cattle, but are not necessarily emaciated.

Postmortem disposition (Regulation 311.16)

Condemn: When virtually all visceral and body fat or muscles show serous infiltration and degenerative change. A gelatinous change of the fat of the heart and kidneys of well-nourished carcasses and mere leanness is not to be classified as emaciation.

Pass: All carcasses retained for emaciation, but determined to be wholesome, will be reported as normal.

Special Note: A carcass condemned for emaciation is eligible for animal food (pet food) provided:

(1) The circuit supervisor has granted permission. (Regulations 314.11)

(2) All parts are freely slashed and adequately identified in an inedible area under FSIS supervision. (Regulations 314.11)

Anasarca

When edema is severe and generalized and causes swelling of all tissues, it is called anasarca. Also, anasarca is the name given to a condition that is seen occasionally in cattle, principally in well-fed steers. It is characterized by an edema occurring subcutaneously primarily in the limbs and in the shoulder region, and brisket. Generalized edema occurs most often in one of two basic mechanisms, either from increased hydrostatic pressure or due to decreased colloid osmotic pressure of plasma proteins (as might be seen in chronic blood loss anemia, chronic renal disease, and starvation). When protein levels in plasma fall below 5%, the potential for edema is present.

Antemortem findings may include the following:

Swelling in areas of legs, brisket, and shoulders

Swollen areas that pit on pressure and are of a firm, doughy consistency, and even cool to the touch

No redness or signs of pain

Normal temperature

Reluctant to move, depressed, lethargic

Diarrhea

Antemortem disposition

Condemn: When the condition has progressed to advanced stages and is characterized by an extensive edema

Suspect: When the condition appears on antemortem to be localized

Postmortem findings may include the following:

Edema in brisket, shoulder, and shanks.

Hydropericardium

Ascites

Hydrothorax

Postmortem disposition

Condemn: When the condition is in an advanced state and is generalized

Pass: When localized, after removal and condemnation of affected tissues

Special Note:

A carcass condemned for anasarca is eligible for animal food (pet food) provided:

(1) The circuit supervisor has granted permission. (Regulations 314.11)

(2) All parts are freely slashed and adequately identified in an inedible area under FSIS supervision. (Regulations 314.11)

Miscellaneous Dropsical Conditions

Dropsy denotes the presence of abnormal amounts of body fluid in the tissues or the body cavities and is often associated with chronic disease of the liver, heart, lungs, and kidneys.

Antemortem findings may include the following:

Areas of edema that pit on pressure and have a firm, doughy consistency and are sometimes cool to the touch

Neither redness nor sign of pain

Normal temperature

Dyspnea

Cyanosis

Marked jugular pulse

Reluctant to move, depressed, lethargic

Diarrhea or constipation

Antemortem Disposition

Condemn: When the condition has progressed to advanced stages and is characterized by an extensive edema

Suspect: When the condition appears on antemortem to be localized

Postmortem Findings may include the following:

Hydrothorax

Ascites or abdominal edema

Excess fluid in tissues with no active inflammation

Carcass dripping excess fluid

Chronic lesions of liver, heart, or kidneys

Postmortem Disposition

Condemn: When the condition is in advanced state and is generalized

Pass: When localized, after removal and condemnation of affected tissues

Uremia

Uremia is an intoxication caused by the accumulation of waste materials in the blood which is normally excreted through the kidneys.

Antemortem findings may include the following:

Variable temperature

Urine infiltration of ventral body wall from urethral rupture

Urinary odor to exhaled breath

Special Notes:

Animals showing early signs of blockage of urinary tract, e.g., anxious expression, twitching of ears, restlessness, tenesmus, and possibly frequent attempts to urinate.

If an animal has had an urethrotomy with no detectable symptoms of uremia, the animal should be examined to see if the surgical correction was successful and the animal has recovered.

Antemortem disposition

Condemn: When the condition has progressed to the point of generalized involvement (anasarca) or is associated with cachexia

Suspect: When the condition does not require condemnation of the animal

Postmortem findings may include the following:

Hydrothorax

Ascites or edema in the abdominal cavity

Fluid in all body tissues with lack of inflammatory process

Nephritis or pyelonephritis

Peritonitis

Cystitis

Calculi

Hydronephrosis

Carcass edema and reddening

Uriferous odor to muscles

Ruptured urinary bladder with peritonitis

Postmortem Disposition

Condemn:

(1) Carcasses that exhibit a urine odor, regardless of the cause

(2) When it is possible to identify the primary cause based on postmortem findings, the primary cause should be reported as the cause for condemnation.

Pass: When the disease or disorder is localized and there are no indications of a generalized process resulting in carcass adulteration

Special Notes:

(1) If there is evidence of a localized urine odor in tissues, this area should be trimmed and condemned.

(2) It is possible that a ruptured bladder can result from faulty dressing procedures. Such contaminated areas should be thoroughly trimmed and condemned.

Sexual Odor of Swine

This is a condition most commonly found in boars, stags, and cryptorchids in which there is a distinct odor to the tissues.

Antemortem findings—not applicable

Antemortem disposition—not applicable

Postmortem findings may include the following:

Any sex odor of carcass or viscera of any swine

Postmortem disposition (Regulations 311.20)

Condemn: Any carcass that exhibits a pronounced odor

Passed with Processing Restriction: Any carcass that exhibits a sexual odor that is less than pronounced may be passed for use as human food after the product meets a specific processing restriction. Carcasses with a sexual odor that is less than pronounced may be passed for use as human food as either cooked comminuted product or for rendering as lard.

Special Notes:

(1) A rule of thumb: a warm carcass should be considered to have a pronounced odor if the odor emanates toward you when you are several inches from the carcass.

(2) If the odor is less than pronounced, you will normally have to get very close to the carcass and search out the odor.

Immaturity

This represents an animal that is too young to have normal muscle development and coordination.

Antemortem findings may include the following:

Muscular incoordination

Inability to stand and walk normally

Lack of muscular development

Antemortem disposition

Condemn: Animals showing an inability to stand and walk normally that is a result of lack of muscular development

Suspect: Those animals that show inconclusive signs of immaturity, such as some muscular incoordination or some difficulty in standing or walking

Special Note: Remember to watch for breed differences as beef calves are usually much stronger than dairy calves.

Postmortem findings may include the following:

Muscle tissues have water-soaked appearance, with loose, flabby tissue that tears easily and can be perforated with the fingers.

Grayish-red muscle color

Lacking good muscular development, especially noticeable on upper shanks

Postmortem disposition

Condemn:

- (1) If the meat appears water-soaked, is loose, flabby, tears easily, and can be perforated with the fingers
- (2) If muscle color is grayish-red
- (3) If muscular development is lacking

Pass: Animals with muscular development and otherwise normal tissues

Special Notes:

A carcass condemned for immaturity is eligible for animal food (pet food) provided:

- (1) The circuit supervisor has granted permission.
- (2) All parts are freely slashed and adequately identified in an inedible area under FSIS supervision. (Regulations 314.11)

Eosinophilic Myositis (EM)

Eosinophilic myositis (9 CFR 311.35) is characterized by large numbers of eosinophilic granulocytes associated with myonecrosis. The cause of the condition has not been determined although two theories are Sarcocystis spp. and allergic reaction.

Special Notes:

- (1) Found primarily in cattle, occasionally in sheep, rarely in swine
- (2) EM occurs primarily in highly fattened steers and heifers, one to two years of age, and less often in older cattle. The cause is unknown at this time.

Antemortem findings—not applicable

Antemortem disposition—not applicable

Postmortem findings may include the following:

- (1) the most common lesions are the irregularly distributed yellowish-green, yellowish-white, and red spindle-shaped foci found in the heart and tongue.
- (2) Striking, but less frequently found lesions, are the large, well-defined, bright green to greenish-gray areas found in the more active muscles; they may not be discovered until the carcass is broken into primal parts.

Special Notes:

Some other conditions are noteworthy as possibly being confused with eosinophilic myositis, especially by less experienced inspectors:

- (1) Cysticercosis—however, the lesions are usually much larger than EM lesions
- (2) Steatosis—where normal fat has replaced muscle tissue

(3) Muscle degeneration

(4) True marbling of meat—intramuscular fat appearing as streaks of fat in the cut surface of muscles

(3) Lesions may be localized in one site or any combination of head, tongue, esophagus, heart, diaphragm, and "hanging tender."

(4) The lesions may be found in carcass musculature alone or in combination with the head, esophagus, heart, diaphragm, or "hanging tender."

(5) The lesions may be slight in the carcass, in which case they might be removed by trimming, or

(6) The distribution of the lesions might make it impractical to remove them.

(7) When lesions of eosinophilic myositis are observed during routine postmortem inspection, the following procedures should be used:

(a) Thoroughly incise and observe the lateral and medial masticatory muscles and heart

(b) Observe and palpate the esophagus.

(c) Make several deep longitudinal incisions into the tongue.

(d) Thoroughly incise and observe diaphragm and pillars after removal of peritoneum

(e) Observe cut surfaces of muscles exposed during the dressing operations (ventral muscles of neck, brisket, medial muscles of round.)

(f) When lesions are in any of the locations in (e) above, make several parallel incisions to all such cut surfaces. Also, after removing the peritoneum, thoroughly incise and observe the abdominal muscles in the flank and paralumbar region

(g) If lesions are in any cut surface exposed during the preceding procedures, the affected primal part should be freely slashed and closely examined.

(8) Eosinophilic myositis is most readily detected in warm carcasses. Chilling causes muscle contraction and reduction in the size and visibility of lesions present. In most cases, active muscles are affected first and more severely than other muscles.

(9) Incisions made transverse to muscle fibers usually give the best exposure of lesions.

(10) When performing the expanded inspection procedures, you should strive to avoid excessive carcass mutilation.

Postmortem disposition (Regulations 311.35)]

When lesions are extensive and impractical to remove:

Condemn: If muscular lesions (in the carcass) are found to be distributed in such a manner or to be of such character that removal is impractical.

When lesions are slight or complete removal is uncertainly accomplished:

Pass for comminuted cooked product: If the lesions are slight or of such character as to be insignificant from a standpoint of wholesomeness, the carcass or parts may be passed for use in the manufacture of comminuted cooked product after removal and condemnation of the visibly affected portions.

When lesion removal is practical:

If muscular lesions are found to be distributed in such a manner or to be of such character that removal is practical, the following rules shall govern the disposal of the carcasses, edible organs, and other parts of carcasses:

(1) If a part has numerous lesions, or if the character of the lesion is such that complete removal is difficult and uncertainly accomplished, or if the lesion renders the part in any way unfit for human food, the part shall be condemned.

(2) If the lesions are localized in such a manner and are of such a character that the affected tissues can be removed, the non-affected parts of the carcass may be passed for human food after the removal and condemnation of the affected portion.

Some examples of dispositions based on these regulations would be as summarized in the following chart:

Parts Affected	Disposition
Head or tongue only	Pass carcass—condemn affected head or tongue
Heart only	Pass carcass—condemn heart
Esophagus only	Pass carcass—condemn esophagus
Hanging tender only	Pass carcass—condemn hanging tender
Diaphragm	Pass carcass—condemn diaphragm
Any combination of above	Pass carcass—condemn affected part(s)
Carcass-lesions extensive and removal is impractical	Condemn carcass
Lesions slight or removal is uncertainly accomplished	Trim lesions recognized, allow for comminuted cooked
Lesion removal is practical	Trim and condemn affected product, pass remainder

Special Note:

A carcass condemned for eosinophilic myositis is eligible for animal food (pet food) provided:

(1) The circuit supervisor has granted permission. (Regulations 314.11)

(2) All parts are freely slashed and adequately identified in an inedible area under FSIS supervision. (Regulations 314.11)

Skin Conditions

Skin conditions are varied and many are very nonspecific, including conditions such as dermatitis, erythema, urticaria, and photosensitization.

Antemortem findings may include the following:

Erythema

Photosensitization

Burns

Parasites—lice and mites

Pruritis

Alopecia

Ringworm

Antemortem disposition

Condemn:

(1) Severe skin involvement with associated cachexia, such as in extreme parasitism.

(2) Severe skin involvement with associated generalized disease involvement.

Suspect: Those animals with inconclusive signs of generalized disease resulting from the primary skin lesion.

Postmortem findings may include the following:

Dermatitis

Generalized lymphadenitis

Tissue or organ degeneration

Petechia or ecchymotic hemorrhages in tissues/organs

Special Notes: There are conditions that might be confused with disease.

(1) Hogs overscalded as a result of being in the scald vat for too long or at too high a temperature

(2) Erythema and bruising caused by improper antemortem handling

Postmortem dispositions

Condemn: Those animals with extensive skin lesions and associated generalized disease

Suspect: Those animals with extensive skin lesions and inconclusive signs of generalized disease

Asphyxia (Suffocation)

This condition is most often seen in swine when they enter the scalding vat alive and are suffocated by drowning. Usually this is due to a defective stick wound.

Antemortem findings—not applicable

Antemortem disposition—not applicable

Postmortem findings may include the following:

Generalized hyperemic appearance to carcass and viscera

Possible absence of stick wound

Water-logged lungs

Postmortem disposition

Condemn: When there is a generalized hyperemia of carcass and viscera

Special Note: Carcasses like this would be condemned and ineligible for use as animal food because excess blood makes a very unsound product and also will mask signs of septicemia, toxemia, and other conditions.

Pass: When involvement is to a lesser extent than that requiring condemnation.

Cysticercosis of Sheep

Cysticercus ovis is not transmissible to man; the definitive hosts are wild carnivores.

Antemortem findings—not applicable

Antemortem dispositions—not applicable

Postmortem findings may include the following:

Cysts, usually calcified, found in heart, esophagus, tongue, diaphragm, and muscles of the diaphragm

Meat is watery or discolored

Cysticercus ovis may be confused with:

- (1) Nodular worms--Oesophagostomum species, seen primarily along intestinal tract
- (2) Bladder Worm--Cysticercus tenuicollis, seen in peritoneal cavity often in the pelvic viscera and liver

Postmortem disposition (Regulations 311.25(b))

Detailed Examination Procedure: When cysticercosis is detected during routine postmortem inspection procedures, the affected carcass and parts should undergo the following further examination by the PHV.

- (1) Re-examine the heart and esophagus by sight and palpation.
- (2) Palpate the muscles of the diaphragm.
- (3) Carefully examine the cut surface of muscles exposed during regular dressing procedures (ventral muscles of the neck and brisket and medial muscles of the leg). If only the initial lesions are found in (1) through (3), make your disposition based on these findings. However, if any additional lesions are found, continue to:
- (4) Make incisions parallel to the cuts described in (3). Also remove the peritoneum from the abdominal muscles in the flank and paralumbar regions. Examine visually and then make several incisions to aid in the examination. If no additional lesions are found in (4), make your disposition based on the findings through (4). However, if any additional lesions are found, continue to (5).
- (5) Make deep bold incisions into the heavily muscled primal parts to determine if various parts of the musculature expose one or more cysts on most of the cut surfaces.

Condemn: If the infection is to such an extent that complete removal is impractical

Pass with Processing Restriction: Pass for heating to an internal temperature of 140° F after trimming and condemnation of affected tissue where there are more than five cysts in the tissues, excluding the heart, and the parasites are distributed in such a manner that their removal is practical

Pass: When five or fewer cysts are found in the tissues, excluding the heart, the carcass may be passed for human food after trimming and condemnation of affected tissues

Sarcocystosis (Sarcosporidiosis)

This parasitic condition is most frequently seen in older sheep originating from certain geographical areas, especially the Western United States. Sarcocystosis is caused by specific protozoans not considered pathogenic for humans in the United States.

The esophagus is usually the first site at which the lesions are detected; this alerts the inspection team that many sheep in the lot will probably be affected.

Antemortem findings—not specific for disease, so cannot correlate disposition to disease

Antemortem disposition—disease signs not specific for disease, so can't correlate disposition to disease

Postmortem findings may include the following:

Lesions detected in the esophagus as white, semi-oval, cigar-shaped, or rice grain shaped lesions

Lesions detected in the diaphragm, skin muscles, internal abdominal muscles, or intercostal muscles

Lesions found in skeletal muscles, detected after incision and observation of primal parts

Special Notes:

(1) Lesions can best be observed by making incisions parallel to muscle fibers rather than by making transverse cuts.

(2) Avoid excessive carcass mutilation with the incisions and cuts made for examination purposes.

Postmortem disposition

Detailed Examination Procedure: When sarcocystosis is detected during routine postmortem inspection procedures, the affected carcass and parts should undergo the following further examination by the PHV:

(1) Re-examine the esophagus, superficial and cut surfaces of muscles, diaphragm, and internal abdominal and intercostal muscles. If lesions are found in locations other than the esophagus, proceed to (2).

(2) Expose muscles of shoulder, round, and back.

Condemn: When the infestation is excessive—if the lesions are found to be distributed in such a way that their removal is impracticable, no part of the carcass shall be saved for human food

Pass with Processing Restriction: When an infestation is moderate, the carcass may be passed for cooking (held at 170 ° F for 30 minutes) after removal and condemnation of affected tissues

Pass: When the lesions can be completely removed and condemned, the unaffected portions of the carcass can be passed for human food.

Special Note:

A carcass condemned for sarcocystosis is eligible for animal food (pet food) provided:

The circuit supervisor has granted permission. (Regulations 314.11)

All parts are freely slashed and adequately identified in an inedible area under FSIS supervision. (Regulations 314.11)

Stephanuriasis (Swine Kidney Worms)

A parasitic condition due to the presence of *Stephanurus dentatus* in the carcass tissues.

Antemortem findings—not specific for disease, so can't correlate disposition to disease

Antemortem disposition—signs not specific for disease, so cannot correlate disposition to disease

Postmortem findings may include the following:

Adult kidney worms

Lesions:

Pelvic inlet, pelvic and femoral canal

Abdominal lining

Muscle-primarily loin and ham muscles

Organs-primarily kidney, liver, pancreas, spleen, and lungs

Brownish-lemon color of skin and fat

Special Notes:

(1) The larvae migrate to perirenal tissues, form cysts and abscesses, and develop to adulthood. The perirenal area often appears reddish-brown, and the cysts contain a

creamy to reddish-brown colored substance. It is even possible to palpate cord-like masses in the perirenal fat, which are tracts made during migration.

(2) In the liver, there are sometimes multiple extensive orange-tan hemorrhagic areas, with the liver parenchyma later taking on a mahogany color. Usually abscessation occurs where the larvae have been trapped. Also, severe scarring results where abscessation has occurred.

Postmortem disposition

Detailed Examination Procedure: When a carcass is retained for stephanuriasis on regular inspection, the PHV may find it necessary and helpful to perform the following examination:

(1) Re-examine the carcass and organs by incision into the liver, lungs, spleen, pancreas, kidney, and perirenal region.

(2) Upon finding numerous lesions during (1), make a lengthwise incision into each ham and loin. If no lesions are found, no further incisions are necessary. Check in particular the femoral and pelvic canal.

(3) If abscesses are found in the loin, make additional incisions into the loin and ham. Check all body cavities.

Condemn: When the disease is associated with generalized disease, such as uremia or septicemia

Pass: After removal and condemnation of all affected tissues

Special Note: The parasites in themselves are usually of little significance unless secondary pathology has developed.

Anaplasmosis

Anaplasmosis is an infectious disease of cattle caused by the rickettsia, *Anaplasma marginale*. It is not commonly diagnosed on antemortem, although an anemia, debilitation, jaundice, or fever, plus the knowledge that an animal originated in an enzootic area, or the presence of ticks are signs associated with this condition.

Antemortem findings may include the following:

Anemia, pale mucous membranes

Icterus

Variable temperature

Debilitation

Listlessness

Polypnea

Antemortem disposition

Condemn: All animals showing signs of this disease on antemortem.

Suspect: All animals that have reacted to a test for the disease, but which show no signs

Postmortem findings may include the following:

Pale musculature

Marked splenomegaly, blackberry-jam consistency

Distended gall bladder with dark, thick, tarry bile

Thin, watery blood that clots very poorly

Lemon-yellow color exhibited by the connective tissue—check connective tissue sites such as aponeurosis of diaphragm, tendons, pleura, peritoneum, and sclera of the eye

Special Note: The spleen in malignant lymphoma, malignant myeloma, anthrax, and anemia may be similar in appearance to that in anaplasmosis. Detailed examination of the spleen and relation of these findings to other lesions in the carcass is required to arrive at a diagnosis.

Postmortem disposition

Condemn: Carcasses showing lesions of anaplasmosis

Pass: Where recovery from anaplasmosis has occurred to the extent that the yellow carcass color disappears after chilling and other carcass lesions are not present

Melanosis

Melanin is a normal black pigment of the body. Melanosis is excessive melanin deposits or deposits in abnormal locations. Such deposits must be removed from product for human food purposes.

Antemortem findings—not applicable

Antemortem disposition—not applicable

Postmortem findings may include the following:

Melanin pigment in lungs, liver or other organs

Melanin in skin

Melanin in eye

Melanin associated with inflammation

Postmortem disposition (Regulation 311.13)

Condemn:

Carcasses with generalized pigmentary deposits shall be condemned

When melanin cannot be removed or its removal is impractical, or when it renders a carcass, organ, or part unfit for human food, the affected carcass, organ, or part shall be condemned

Slight melanin deposits in spinal meninges are insignificant. However, when extending into spinal nerves and into meat, they must be removed.

Pass:

When localized, pigmentary deposits can be effectively removed and condemned.

Uniform melanin deposits over or in circumscribed skin areas of swine are not required to be removed unless they are tumorous or smeary.

Icterus

If for any reason the amount of bilirubin increases in the blood and therefore in the tissues, a yellowish pigmentation of the tissues arises that is called icterus or jaundice. There are three basic types of icterus: obstructive, hemolytic, and toxic. Obstructive icterus is caused by obstruction of the bile duct by parasites, calculi, abscesses, tumors, etc. Hemolytic icterus is caused by increased destruction of erythrocytes such as may

occur in anaplasmosis or eperythrozoonosis. Toxic icterus can be caused by a degeneration of liver cells that occurs during an intoxication, such as copper toxicity.

Antemortem findings may include the following:

Yellowish discoloration of sclera

Extensive greenish-yellow discoloration of skin (white hogs only)

Antemortem disposition

Special Note: Findings of icterus are inconclusive making condemnation for icterus on antemortem difficult to justify; however, if it is possible to identify a disease or condition causing the icterus, disposition should be made for that cause

Condemn: When it can be definitely established that the animal is icteric

Suspect: All animals with inconclusive evidence of icterus should be handled as suspects.

Postmortem findings may include the following:

Yellow discoloration of connective tissues, sclera, visceral organs

Degenerative changes in liver

Ascarids, neoplasia, or calculi obstructing bile outflow

Special Note: Look for icterus where the tissues are normally very white or pale, such as the sclera of the eye, tendons, pleura, peritoneum, omentum, joint surfaces, and mesentery.

Fat may be yellow due to diet, breed, and age changes that are essentially normal.

Yellow fat is normal in some animals

Postmortem disposition (Regulation 311.19)

Condemn: Carcasses showing any degree of icterus shall be condemned.

Special Note: Carcasses showing any degree of icterus associated with a degeneration of organs, the result of infection or intoxication, and those showing pronounced yellow or

greenish-yellow discoloration without evidence of infection or intoxication shall be condemned.

Final disposition of carcasses showing slight yellow discoloration with no visible pathological changes in organs shall be deferred until they have been chilled out and reexamined, preferably under natural light or a good quality light of at least 50 foot-candles. If discoloration disappears, such carcasses shall be passed for food, provided there are no other conditions warranting a different disposition.

Carotenosis

Carotenoid pigments enter the body with food. Therefore, they are classified with the exogenous pigments. When carotenoid pigments are deposited in the fat tissues and liver to the extent they become grossly visible, the resulting discoloration of tissues is carotenosis.

Antemortem findings—not applicable

Antemortem disposition—not applicable

Postmortem findings may include the following:

Yellow fat

Yellow to yellow-orange liver

Special Notes: Certain conditions such as the following are not to be confused with carotenosis:

- (1) Yellow fat common to certain breeds
- (2) Pale yellow liver tissue common in pregnant cows (fatty infiltration)
- (3) Steatitis-yellow fat disease (swine)

Postmortem disposition Regulation 311.31(a)

Condemn: Livers with carotenosis are to be condemned

Special Notes:

Deposition of carotenoid pigments in the fatty tissue does not affect carcass disposition.

Place a white paper towel or napkin on the cut surface of the liver. A bronze-orange stain indicates carotenoid pigment.

Xanthosis (Brown Atrophy)

Xanthosis is the deposition of excessive quantities of cellular waste pigments. The condition is usually seen in older cattle and those suffering from chronic wasting disease. It is recognized only on postmortem. More commonly affects heart and head musculature.

Antemortem findings—not relevant

Antemortem disposition—not relevant

Postmortem findings may include the following:

Cardiac muscle

Muscle of head

Carcass muscle less frequently

Special Note: Affected muscle has dark brown or coffee-colored discoloration of otherwise normal tissue.

Postmortem Disposition

Condemn: Carcasses with generalized pigmentary deposits shall be condemned.

Pass: Carcasses with less than generalized distribution of pigmentary deposits, after condemnation and removal of the affected areas.

Special Note: By far, most cases of xanthosis are deemed to be localized and affected tissues are trimmed and condemned, and the remainder is passed for human food.

Neoplasms

Papilloma

Papillomas are benign tumors often occurring at multiple sites on the skin of the animal or the mucosa of the mouth, esophagus, and rumen.

Antemortem findings may include the following:

Cutaneous growths (warts)

Antemortem disposition

These affect the skin and should not impact postmortem decisions.

Condemn: When livestock plainly show any disease or condition that would cause condemnation of their carcasses on postmortem

Suspect: When livestock, do not clearly show, but are suspected of being affected with a disease or condition that may cause condemnation of their carcasses on postmortem

Postmortem findings may include the following:

esophageal lesions

rumen lesions

Postmortem disposition

Condemn:

(1) An individual organ or part of a carcass affected with a neoplasm

(2) The entire carcass if there is evidence of metastasis or that the general condition of the animal has been adversely affected by the size, position, or nature of the neoplasm

Embryonal Nephroma

Embryonal nephroma is a neoplasm most often seen in swine. It is generally benign; however, metastasis to the renal lymph nodes, lungs, or liver is possible. The general condition of the carcass is usually not affected by the tumor but a large nephroma may cause stenosis of the digestive tract, partial occlusion of the aorta, or renal dysfunction resulting in uremia.

Antemortem findings— not a consideration

Antemortem disposition—not relevant on antemortem

Postmortem findings may include the following:

Found in or near kidney

Single or multiple tumors

Unilateral or bilateral

Firm, but may contain areas of necrosis

Size varies from small nodules buried in the renal cortex to a large mass completely replacing the kidney.

Grayish-white on cross-section, but may contain multiple yellow foci

Separated into lobules by numerous connective tissue septa

Postmortem disposition

Condemn:

(1) An individual organ or part of a carcass affected with a neoplasm.

(2) The entire carcass if there is evidence of metastasis or that the general condition of the animal has been adversely affected by the size, position, or nature of the neoplasm.

Pass

When criteria for condemnation are not met – affected tissues must be removed and condemned

Neurofibroma (Nerve Sheath Tumor)

This is a neoplasia of nerve sheath cells most often seen in cattle. It may be found along any nerve trunk of the carcass but are most often found in the intercostal and paravertebral spaces, heart, brachial plexus, and coeliac plexus. It may be seen as multiple nodular enlargements along any nerve. It is generally regarded as benign, but may metastasize to regional lymph nodes. Neurofibromas are often seen in multiple sites because of multicentric origin of neoplasm. The tumors may be firm or soft and often have gelatinous centers and appears as a shiny, glistening, white-to-gray, lobulated, firm nodular growth on or within the nerve. When identified on postmortem inspection, be sure to examine brachial and coeliac plexus for lesions.

Antemortem findings—not normally recognized on antemortem

Antemortem disposition—not relevant

Postmortem findings

Along spine

Along ribs

Brachial plexus

Heart

Tongue

Postmortem disposition

Condemn:

(1) An individual organ or part of a carcass affected with a neoplasm shall be condemned.

(2) The entire carcass, if there is evidence of metastasis or that the general condition of the animal has been adversely affected by the size, position, or nature of the neoplasm.

Mesothelioma

Mesothelioma is a neoplasia of the mesothelial cells lining the peritoneal and pleural cavities. Primarily found in cattle, it may be found on both the parietal and visceral serosal membranes, particularly the peritoneum. You will typically see multiple, grayish, firm, papillary growths which have homogenous consistency on cross section of the lesion.

Antemortem findings—not recognized on antemortem

Antemortem disposition—not relevant

Postmortem findings may include the following:

Peritoneum, parietal serosa—nodular lesions

Peritoneum, visceral serosa—nodular lesions

Pleura, parietal serosa—nodular lesions

Postmortem disposition

Condemn:

- (1) An individual organ or part of a carcass affected with a neoplasm
- (2) The entire carcass if there is evidence of metastasis or that the general condition of the animal has been adversely affected by the size, position, or nature of the neoplasm

Adrenal Gland Tumors

Adrenal gland neoplasia may arise in both the cortex and medulla (pheochromocytoma). It may occur in many species but are usually seen in older animals, particularly cattle. Tumors often have yellowish to orange to grayish consistency. Incision into the neoplasm may reveal mineralization. This neoplasia may be benign or malignant. Metastasis may occur in organs such as the lung, but frequently these tumors may grow or spread along blood vessels such as the vena cava.

Antemortem findings—not recognized on antemortem

Antemortem disposition—not a consideration

Postmortem findings may include the following:

Neoplastic adrenal gland

Cortical tumor

Tumor of adrenal medulla

Metastasis to lung

Growth into and along vena cava

Postmortem disposition

Condemn:

- (1) An individual organ or part of a carcass affected with a neoplasm shall be condemned.
- (2) The entire carcass if there is evidence of metastasis or that the general condition of the animal has been adversely affected by the size, position, or nature of the neoplasm.

Ocular Squamous Cell Carcinoma (Epithelioma)

This is a neoplasm of the epithelial cells surrounding the eye. These tumors should be regarded as malignant. They can metastasize and be extremely destructive locally or they can metastasize via the lymphatics to lymph nodes and or organs. It is found in all breeds of cattle, but Herefords are most commonly affected. It may be found in mature sheep at a frequency similar to cattle and has also been recognized in swine and equine, although rare.

Antemortem findings may include the following:

Ocular neoplastic lesion

Ocular neoplasia and infection

Ocular neoplasia and suppuration

Ocular neoplasia and necrosis

Ocular neoplasia and cachexia

Absence of an eye

Antemortem disposition

Condemn: (Regulation 309.6)

When the eye has been destroyed or obscured by neoplastic tissue and there is extensive infection, suppuration, and necrosis, or the epithelioma is accompanied by cachexia.

Suspect: Regulation 309.2 (e)

(1) When epithelioma case does not require condemnation

(2) When the eye is missing from any bovine presented for antemortem inspection

Postmortem findings may include the following:

Neoplastic lesion involving eye and/or orbital region

Metastasis to lymph node

Infection, suppuration, or necrosis of bony orbit

Metastasis to lungs

Emaciation

Postmortem disposition (Regulation 311. 12)

Condemn the carcass of animals affected with epithelioma of the eye or the orbital region if one of the following three exists:

The affection has involved the osseous structures of the head with extensive infection, suppuration, and necrosis; or

There is metastasis from the eye, or the orbital region, to any lymph node, including the parotid lymph node, internal organs, muscles, skeleton, or other structures, regardless of the extent of the primary tumor; or

The affection, regardless of extent, is associated with cachexia or primary evidence of adsorption or secondary changes.

Pass: When the carcass does not require condemnation, it may be passed for human food, after removal and condemnation of the head, including the tongue.

Special Note: A carcass condemned for epithelioma is eligible for animal food (pet food) provided:

The circuit supervisor has granted permission. (Regulations 314.11)

The neoplastic tissue has been removed and condemned to tankage.

All parts are freely slashed and adequately identified in an inedible area under FSIS supervision. (Regulations 314.11)

Malignant Lymphoma

Lymphoma is a neoplastic condition of the lymphocytes and is by its very nature considered to be malignant. There are many manifestations of the disease, which allows it to be confused with other disease processes such as granulomas, abscesses, or other types of neoplasia.

(2) Its occurrence in the carcass and or viscera, regardless of the extent and distribution of the disease process, requires that the carcass and viscera be condemned in its entirety.

Antemortem findings may include the following:

Enlargement of superficial lymph nodes

Bloat due to abomasal neoplasms

Debilitated cachetic condition

Ocular protrusion due to retrobulbar neoplastic tissue

Antemortem disposition

Condemn: Cannot be adequately diagnosed on antemortem; however, can be suspected.

Suspect: Antemortem signs may very well suggest malignant lymphoma and so animal would be suspected.

Postmortem findings may include the following:

Gross enlargement of one or more lymph nodes

Focal or diffuse neoplastic growth in the heart

Focal or diffuse neoplastic growth in the cattle abomasum

Focal or diffuse neoplastic retrobulbar growth in the cattle

Focal or diffuse neoplastic growth in the uterus of cows

Postmortem disposition

Condemn: The carcass of any species with malignant lymphoma regardless of the degree of involvement

Melanoma

Melanoma is a neoplasia of the naturally occurring melanocytes in the skin. They are usually found in swine and grey horses. Benign lesions (melanocytomas) and malignant lesions (malignant melanoma) occur, and these must be differentiated from melanosis.

Antemortem findings

Black tumors may be seen in the skin of any species. In swine these most often might be seen at the base of the ears, mid-back, tail-head and flanks, while in equines these are most often seen in the perineal region .

Antemortem disposition

Condemn: Condemnation is not recommended on antemortem examination since it cannot be determined to have metastasized or not.

Suspect: Those animals that have a melanoma that are likely to be condemned on postmortem.

Postmortem findings may include the following:

Deep black, gray, or brown nodular protruding masses of variable size

Metastasis to regional lymph nodes

Metastasis to the lungs

Metastasis to the liver, spleen, and other internal organs

Postmortem disposition

Condemn:

An individual organ or part of a carcass affected with a neoplasm shall be condemned.

If there is evidence of metastasis or that the general condition of the animal has been adversely affected by the size, position, or nature of the neoplasm, the entire carcass shall be condemned.

Poultry Conditions Not of Public Health Significance

Leukosis Complex

This category includes several neoplastic diseases caused by various viruses. All produce tumors in domestic poultry and present similar gross lesions.

The age and species of bird affected by leukosis tumors suggests which viral agent is involved. The most common manifestations of the leukosis complex are:

- 1) Mark's disease, which is an important disease only in young chickens less than six months of age
- 2) Lymphoid leukosis, which is most common in semi-mature and mature chickens
- 3) Reticuloendotheliosis, which occasionally produces liver and spleen tumors in turkeys and, rarely, runting disease in chickens
- 4) Lymphoproliferative disease, which affects turkeys, producing a greatly enlarged spleen as well as tumors in other organs.

There is no evidence that viruses of the leukosis complex are pathogenic for humans.

One definitive lesion justifies condemnation of the carcass. Definitive means a lesion that can be defended grossly as a lesion of leukosis.

Synovitis

Synovitis is caused by a number of organisms, most often members of the genus *Mycoplasma*. Injury and nutritional deficiencies also lead to synovitis. The result is acute or chronic inflammation of the membranes lining one or more joints and tendon sheaths.

Joints are often noticeably swollen and might contain varying amounts of exudate. The liver, kidneys, and spleen may be swollen, and the liver is sometimes stained green from bile stasis. Lesions vary depending upon whether or not the condition is confined to the joints or has overwhelmed the bird's defense mechanisms and caused systemic changes.

A carcass with synovitis is not condemned unless it also shows systemic or sep/tox changes.

Neoplasia

This category refers to neoplasia other than those of the leukosis complex. Some of the more common ones include keratoacanthomas, adenocarcinomas, leiomyomas, and fibromas.

- Keratoacanthomas are skin tumors found in young chickens that arise from feather follicle epithelium.
- Adenocarcinomas generally are located on abdominal organs and are common in older birds.
- Leiomyomas are most often identified in the oviduct of fowl.
- Fibromas may develop in any connective tissue. They are more common in older birds.

Numerous other types of tumors occur in domestic poultry but at a low frequency.

There is no evidence that any of these types of tumors are a health threat to humans.

Condemn a carcass for tumors if there is gross evidence of metastasis (more than one tumor indicating spread). The general rule is: one tumor - trim and pass; two or more tumors - condemn.

NOTE: The exception to the rule is for Keratoacanthomas, previously known as “dermal squamous cell carcinomas”: Condemn young chickens showing generalized signs of avian keratoacanthosis with large coalescing or large multiple dermal ulcers. Trim all tumors and pass chickens with localized or only a few small lesions.

Bruises

If bruises cause systemic change in a carcass, the carcass is condemned and recorded under this category. If not, the bruises are trimmed and the remainder of the carcass is passed.

Cadavers

Poultry that die from causes other than slaughter are condemned under the cadaver category. These birds are not physiologically dead when they enter the scald vat. When submerged in the water, they drown. Those that die from drowning may exhibit signs of incomplete exsanguination (bleed-out), resulting in an unwholesome carcass. The skin of the carcass or neck is cherry red to purple.

Overscald

Carcasses that are cooked in the poultry scald are condemned. The muscle must be cooked through the level of the deep pectoral muscle. Many times these carcasses will also be mutilated by picking machines. It is important for inspectors to differentiate an overscald carcass from a hardscald carcass. Cooking of the most superficial surface of

the superficial pectoral muscle occurs in a hardscald carcass. This produces a whitening of that surface.

Airsacculitis

Numerous microorganisms cause airsacculitis, inflammation of air sacs. Often more than one infectious agent is identified in an outbreak. Members of the genus *Mycoplasma* are frequently involved. Birds are more susceptible to infections of the air sacs when they are under stress. Vaccination, other disease, poor nutrition, insanitary conditions, and poor ventilation are contributing factors.

The lesions of airsacculitis can be acute or chronic. Their appearance ranges from slight clouding of air sac membranes and small amounts of watery exudate to thickened, opaque membranes and large amounts of thick, white-to-cream colored and/or cheesy exudates. The exudates can be confined to the air sacs and their diverticuli, or they may be found in other areas if the air sac membranes are ruptured.

Pneumonia, pericarditis, and perihepatitis might be present. In some cases all portions of the respiratory tract (nasal passages, sinuses, trachea, bronchi, lungs, and air sacs and their diverticuli) are affected. In other cases, little involvement beyond the air sacs is evident. Systemic change can occur.

Carcasses are condemned if airsacculitis is extensive or prevents evaluation of the wholesomeness of the carcass. If the exudate cannot be effectively removed, the carcass is condemned. Carcasses are also condemned if airsacculitis occurs in conjunction with systemic change.

One organism that causes airsacculitis in birds, *Chlamydia psittaci*, also can cause disease in humans. Outbreaks of this disease are sporadic and generally occur in turkeys rather than chickens. The turkey industry watches closely for any evidence of chlamydiosis, so infected flocks are usually identified and treated before slaughter. However, PHV's must stay alert for any poultry that show signs suspicious for this disease.

Two viral poultry diseases of significance that may involve the air sac system are Exotic Newcastle Disease (END) and Avian Influenza (AI).

Inflammatory Process (IP)

Inflammatory process is usually manifested in poultry as bright yellow caseous material underneath the skin. When the condition is generalized or cannot be practically removed the carcass would be condemned. Otherwise, it may be trimmed and passed.

Turkey Osteomyelitis Complex

The classic lesions of TOC are osteomyelitis, swelling of the joints and adjacent soft tissue, and green discoloration of the liver. Two external signs are frequently seen in

TOC-affected carcasses—joint swelling and green discoloration of the liver. The latter sign is the most consistent indicator that TOC may be present. However, it is not pathognomonic. Although, most carcasses affected by TOC exhibit a green liver, most carcasses exhibiting a green liver do not have TOC.

In order to distinguish lots of turkeys affected by TOC from those showing external signs compatible with TOC but caused by other conditions, the Agency requires PHV's to conduct special diagnostic examinations on suspicious lots. If the presence of TOC is confirmed during the diagnostic exam, the PHV requires the plant to conduct additional examination procedures on all carcasses identified as suspects at the postmortem inspection stations.

When osteomyelitis is detected during the plant examination, all tissues to the next normal joint must be removed and condemned. Product that is salvaged must be held for re-examination by FSIS personnel before it is allowed to enter normal production flow. All aspects of the TOC procedure must be consistently performed in accordance with FSIS policy and in a manner acceptable to the IIC or approval can be rescinded and the procedure discontinued.

Affected tissues must be removed from TOC carcasses. If this is not possible or if the carcass is showing signs of systemic disturbance, the entire carcass would be condemned.

The "inspector's helper" should be instructed to record condemned birds under the "Other" category on the FSIS Form 6000-16, the Lot Tally Sheet (See XII. B. for completing the documentation on FSIS Form 6000-16, Lot Tally Sheet).

Ascites

Broiler ascites is an abnormal condition occurring in young, rapidly-growing chickens. Rapid growth (resulting from nutritional and genetic improvements by the industry) may cause an increase in the oxygen demands on the chicken. The higher oxygen demand placed on the cardiopulmonary system of the chicken under stress leads to right heart failure and the subsequent accumulation of clear to amber fluid around the heart. The right heart failure may force the ascitic fluid into the abdominal cavity. Fluid is present in the body cavity at post-mortem in varying amounts. Ascitic fluid in the thoracic cavity may prevent inspection of the interclavicular air sac space. The liver may also present with a ground-glass appearance because of the deposition of fibrin on the surface.

Inspection program personnel are to:

a. condemn birds with any amount of ascitic fluid present in the body cavity that also has signs of septicemia (9 CFR 381.83) or other disease conditions, including inflammatory lesions, tumors, or other degenerative conditions;

- b. condemn birds with any amount of ascitic fluid present in the body cavity that prevents visualization of the interclavicular space; and
- c. instruct the “inspector’s helper” to record condemned birds under the “Other” category on the FSIS Form 6000-16, the Lot Tally Sheet (See XII. B. for completing the documentation on FSIS Form 6000-16, Lot Tally Sheet).

Occult Vaccination Lesions

Occult (obscured or concealed) vaccination lesions found in mature fowl are tissue responses to vaccines that laying hens receive at 10-14 weeks of age. Vaccines are administered in the muscle tissue of the breast, leg, wing, or tail, or subcutaneously in the dermis of the inguinal fold, neck, or wing web. Vaccine lesions may cause a reddened or inflamed area around the injection site, or a more severe lesion extending into the surrounding tissue. Adjuvants (or boosters) in vaccines generally cause the more extensive inflammatory reactions.

Off-line inspection program personnel are to verify that:

- a. establishments slaughtering mature fowl in which occult post-vaccination lesions occur have considered vaccine lesions in their hazard analysis (9 CFR 417.2(a)).
- b. if an establishment determines that vaccine lesions are a food safety hazard reasonably likely to occur in their process, they have established a Critical Control Point (CCP) and met the other requirements of 9 CFR 417.2(c).

If an establishment determines that vaccine lesions are a food safety hazard reasonably likely to occur and has established a CCP, then off-line inspection program personnel are to perform procedure codes 03J01/03J02 at the frequency determined by the Performance Based Inspection System (PBIS) scheduling, or if notified by on-line inspection program personnel that an establishment’s process is not under control for vaccine lesions.

If the establishment has considered vaccine lesions not reasonably likely to occur because they have a prerequisite program in place to assure removal of the lesions, then off-line inspection program personnel are to verify the effectiveness of the prerequisite program by following the instructions in FSIS Directive 5000.1, Verifying an Establishment’s Food Safety System.

Workshop III

This workshop will be facilitated by the instructor. The facts of the case will be presented, slides of the associated pathologies will be shown, and then you will be asked to use the **disposition thought process** to arrive at a **sound, supportable disposition**.

Case Number 1

Antemortem - a normal appearing dairy cow was presented.

Postmortem - carcass had evidence of mastitis with extensive ventral inflammatory edema. The carcass was dark and moderately dehydrated. There were massive hemorrhages on the spleen and epicardium. The lungs also had large zones of hemorrhages and there were petechial hemorrhages around the great vessels. The liver was enlarged, dark and congested - large amounts of blood drained from its cut surface. There were petechial hemorrhages throughout the carcass evident on fascial planes between muscle groups.

Case Number 2

Antemortem – subject was a normal appearing dairy cow

Postmortem - a ruptured spleen was evident. The spleen was greatly enlarged. The cut surface of the spleen had very prominent 1-2 mm white nodules. Several abdominal lymph nodes were enlarged, congested, and had normal cortico-medullary anatomy on cut section. There was a large quantity of dark red watery fluid in the abdominal cavity.

Case Number 3

Antemortem – normal appearing market hog

Postmortem - petechial hemorrhages were present on the skin, kidneys, lungs, small intestine, stomach, and peritoneal cavity. The carcass lymph nodes were hemorrhagic and the liver was slightly enlarged.

Case Number 4

Antemortem – normal appearing market hog

Postmortem - both kidneys were enlarged with diffuse sawdust-like lesions concentrated at the distal ends. The bladder was markedly enlarged (3X) and the lumen was hemorrhagic with fibrous and reactive tissue present. The renal lymph node showed reactive change.

Case Number 5

Antemortem – normal appearing dairy cow

Postmortem - large abscess/cellulitis was present on the right cranioventral abdomen. There was hemorrhage, congestion, and areas of necrosis associated with the lesion. There were also multifocal areas of consolidation throughout both lungs. The heart and liver were grossly normal.

Case Number 6

Antemortem – normal appearing dairy cow

Postmortem - there was a marked thickening of the intestinal mucosa. Mucosal redundancy was so pronounced that it was observable through the serosal surface. The entire small intestine from the distal duodenum to the ileo-colic junction was involved.

Case Number 7

Antemortem – normal

Postmortem - cranioventral consolidation of both lungs was evident. There was also a fibrinous pleuritis. Lesions were more extensive and severe in the left lung. On cut surface there was interlobular fibrin and edema. Smaller bronchi and bronchioles contained purulent exudate. The carcass was well hydrated and well fleshed.

Case Number 8

Antemortem - a normal fattened beef breed heifer from northern Michigan was presented.

Postmortem - a large 6 cm x 3 cm x 3 cm granuloma was replacing the caudal mediastinal lymph node. A large 5 cm x 5 cm x 4 cm pyogranuloma-like lesion was present in the diaphragmatic lobe of the left lung. Several smaller granulomas up to 1 cm diameter were present throughout both lung fields.

Case Number 9

Antemortem – a normal dairy cow was presented

Postmortem - greenish discoloration of the liver was evident. A more intense green pigment was observed in the hepatic lymph nodes. The mediastinal lymph nodes and kidneys were normal.

Case Number 10

Antemortem - 6 month old market hog - there was a large, raised black mass on the side of the head.

Postmortem - numerous black, flat masses were present on the carcass trunk. Spots of black pigment were scattered throughout the liver, spleen, and pancreas. There was diffuse pigment seen in most of the peripheral lymph nodes.

Case Number 11

Postmortem- 60 day old chicken in good condition. The spleen is 4 times normal size with large and small white foci protruding from the surface. The liver is enlarged and has the same foci. The bursa of fabricius is about normal for that age. The kidneys are slightly pale.

Case Number 12

Gross description of lesions - 53 day old bird with small yellow glistening masses in the anterior thorax. Air sac membranes reddened and thickened with some areas of exudate on and inside them. Liver has a fibrinous coating firmly attached, the pericardial sac is thick and whitish with areas of exudate and redness. The heart has a whitish coating on it with areas of hemorrhage and redness.

Case Number 13

Description of gross lesions - 46 day old chicken. All skin and viscera are bright red and appear to have petechia and echymosis. The liver is dark reddish brown, the lungs are a bright pink and the spleen appears normal. Intestinal and mesenteric vessels are prominent.

Case Number 14

This young turkey was in poor body condition, dehydrated, and dark in color. The liver was greatly enlarged (3-4 x normal) with areas of white, very firm tissue, light green and small areas of normal appearing liver tissue.

Case Number 15

Gross description of lesions - 55 day old bird in good condition. The left leg has an area about 1 inch wide by 3-4 inches long that is raised, yellow, and firm. On incision, a yellow-gray leathery material is exposed. The surface of all visible muscles is reddened and inflamed. The spleen is pale but other tissues are normal.