

**DOCUMENTATION OF CANCER DIAGNOSIS
EXTENT OF DISEASE AND TREATMENT**
(NAACCR Item #'s 2600, 2610, 2620, 2630, 2640, 2650, 2660, 2670)

Text information to support cancer diagnosis, stage, and treatment codes **MUST BE PROVIDED BY ALL FACILITIES**. Document all types of the **first course** of definitive treatment administered, regardless of where the treatment was received, in date order.

Text documentation is an important element of a complete abstract. It is critical for quality assurance and special studies. Text is used to support coded values and to provide supplemental information not transmitted within coded values. Complete text documentation facilitates consolidation of information from multiple reporting sources. The text field must contain a description that has been entered by the abstractor. Cancer Registry software generating text automatically from coded data cannot be utilized to support coded values. Information documenting the disease and treatment must be entered manually from the medical record. **TNM staging is not an acceptable substitute for stage documentation.**

Text documentation should explain where the cancer started, where it went (lymph nodes, other organs) and how it got there (direct extension, metastasis, implants). Clinical and pathological findings should be documented.

Always use text to document certain basic information:

1. The date of the examination or procedure (06152006); **keep dates in chronological order.**
2. The name of the examination or procedure (excisional biopsy).
3. The results of the examination or procedure—any pertinent **positive or negative** information (negative margins, chest X-ray negative, liver biopsy positive for metastasis).
4. The diagnostic impression, final diagnosis, or final conclusion if one is given (Ductal carcinoma of left breast).
5. The planned treatment, whether or not it is known if treatment was given (chemotherapy planned after left modified mastectomy).
6. The date and type of treatment given, even if it was done at another institution (06152006 5FU administered at ABC hospital).
7. Specific subsite of primary site (upper outer left breast).
8. Specific number, chain of lymph nodes examined and results (0/15 left axillary lymph nodes).
9. Specific information about metastatic spread of disease to lymph nodes and/or other organs and tissues (metastasis to 15 supraclavicular lymph nodes, brain metastasis).

Documentation is used to verify all coded fields regarding the patient, disease, extent of disease and spread of disease. Text should be documented in the appropriate text fields (staging text should be in staging text field).

Extent of Disease:

In situ means “in place.” It describes a neoplasm that is non-invasive and confined to a small, circumscribed area within the tissue of origin. There is no penetration of the basement membrane of the tissue and no stromal invasion. Clinical evidence alone cannot identify the behavior as in situ. In situ behavior must be based on pathological examination and documentation. (Figure 1)

Note: Organs and tissues that have no epithelial layer cannot be staged as in situ, since they do not have a basement membrane. There cannot be a diagnosis of “sarcoma in situ.” The following histologies are not accepted with in situ behavior:

- 8000–8005
- 8020, 8021
- 8331, 8332
- 8800–9055
- 9062
- 9082, 9083

- 9110–9493
- 9501–9989

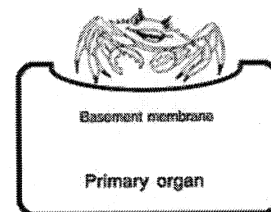
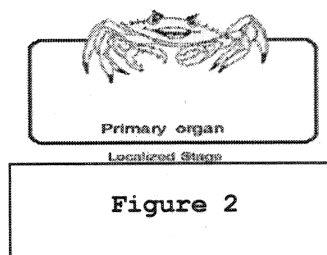


Figure 1

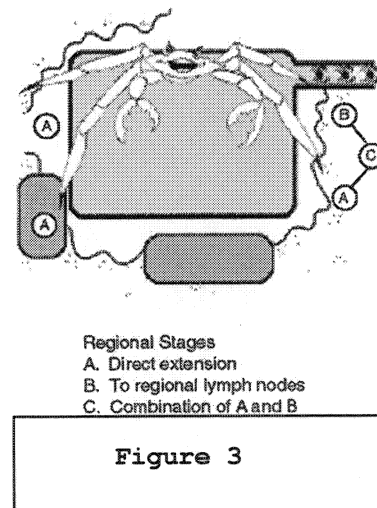
In situ and/or carcinoma In situ Synonymous with In situ	Adenocarcinoma in an adenomatous polyp with no invasion of stalk
	AIN III (C211)
	Bowen Disease
	Clark’s Level I for melanoma (limited to epithelium)
	Comedocarcinoma, noninfiltrating (C50.)
	Confined to epithelium
	Hutchinson’s melanotic freckle, NOS (C44.)
	Intracystic, non-infiltrating
	Intraductal
	Intraepidermal, NOS
	Intraepithelial, NOS
	Intrasquamous
	Involvement up to, but not including, the basement membrane
	Lentigo maligna (C44.)
	Lobular neoplasia (C50.)
	Lobular, noninfiltrating (C50.)
	Noninfiltrating
Noninvasive	

	No stromal invasion
	Papillary, noninfiltrating or intraductal
	Precancerous melanosis (C44.)
	Preinvasive
	Queyrat erythroplasia (C60.)
	Stage 0 (except Paget's disease (8540/3) of breast and colon and rectal tumors confined to the lamina propria)
	VAIN III (C529)
	VIN III (C51.)

Localized: describes a neoplasm that has not spread beyond the organ of origin or basement membrane. There must be no extension beyond the boundary of the organ and no evidence of metastasis elsewhere in the body. The tumor may be widely invasive, or even show metastasis within the organ of origin and still be considered localized. (Figure 2)



Regional: describes a neoplasm that has spread to adjacent organs or tissues or to lymph nodes surrounding the primary organ. Two factors are important in assigning cases to this stage: first, it must be established that the cancer is more than localized; and second, remote or distant spread must be reasonably ruled out on the basis of all evidence available in the medical record. (Figure 3)



Distant: describes tumor cells that have broken away from the primary tumor to remote areas of the body and have started growing at the new area. Distant stage is also called remote, diffuse, disseminated, metastatic or secondary disease. For more details, refer to page 8 of the *SSM2K Manual*. (Figure 4, through the blood system; Figure 5, distant lymph nodes; Figure 6, implantation metastases).

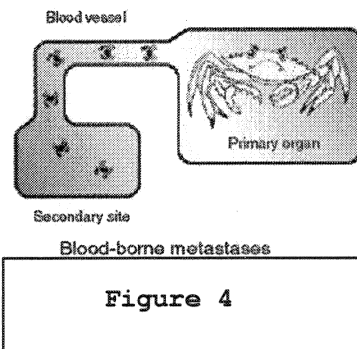
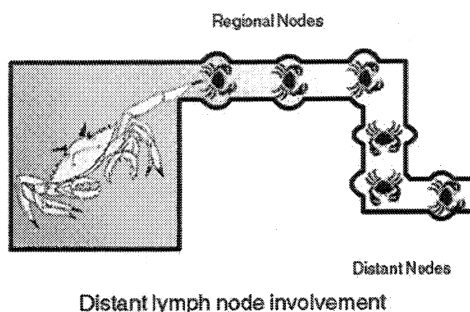
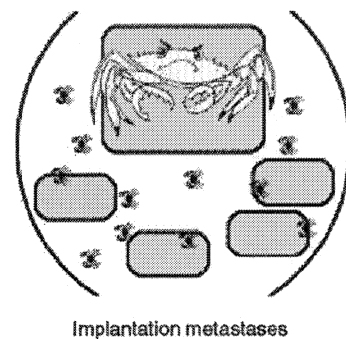


Figure 4



Distant lymph node involvement



Implantation metastases

Figure 5

Figure 6

TERMS INDICATING DISTANT OR DISCONTINUOUS METASTASIS
Ascites (must be documented as malignant) <i>Note: Ascites is considered local for fallopian tubes, C57.0 (pg C521 SEER 2004).</i>
Carcinomatosis
Implantation
Implants <i>Note: Implants is considered regional for ovary, C56.9 (pg C514, SEER 2004).</i>
Pleural effusion (must be documented as malignant)
Seeding
Studding

Unknown is used when there is insufficient information to determine stage or extent of disease. If the primary site is unknown (C80.9) or a benign CNS tumor, then the Summary Stage must be unknown.

Call your Health Service Region for technical assistance if additional direction is needed to determine the appropriate information to document. TCR staff may request copies of the necessary reports with your data submission in order to assist you.

Documentation is necessary to verify all coded fields regarding types and timing of treatment. Be sure to document in the Treatment Documentation field if the medical record indicates no treatment was planned or given, or if there is no information in the medical record that definitive treatment was given. If it cannot be determined whether therapy was actually performed, record that it was recommended but it is not known if the procedure was administered. For example, “radiation recommended, unknown if given.”

Types of reports to review:

Medical imaging can provide key information for evaluating clinical extent of disease. For example, a CT of the lung can show the size and location of the tumor within the lung. It can demonstrate the presence of pleural effusion, or extension of the tumor to other tissues such as ribs, chest wall or pleura. Bone scans and MRI or CT of the brain are often used to evaluate for metastatic sites. History and Physical reports sometimes give the results from outside imaging studies. Documentation of all positive and negative findings from imaging exams should be recorded in the Summary Stage Documentation field.

Physical exam or **History and Physical (H&P)** can provide the size for palpable masses and information regarding palpable lymph nodes. For example, during a digital rectal exam (DRE) the prostate is palpated. The physician will note findings such as nodularity, induration, fixation of seminal vesicles, enlargement, firmness, etc. All positive and negative findings pertinent to the patient’s cancer are an important aspect of Collaborative Staging and must be noted in the Summary Stage Documentation field to support coding.

Pathology reports provide key information including **cell type, grade, size and location** of tumor, **number of lesions or foci, depth of invasion, spread of tumor to other organs, and lymph node involvement**. Record each of these items in the Summary Stage Documentation. Be sure to record the furthest extension that the pathologist mentions, for example: confined to mucosa; into subserosa; through full thickness of abdomen wall, etc.

Operative reports will often contain the surgeon’s observations regarding involvement or lack of involvement of lymph nodes or other organs. Record these findings in the Summary Stage Documentation.

Discharge summaries, clinical notes, or progress reports are good sources for treatment information. Review all available reports and document all planned treatment, as well as the date and modalities of known treatment in the Treatment Documentation. Give specific information when available such as type and number of courses of chemotherapy. If no treatment is planned or the patient refuses recommended treatment, include this information in the text field.

Specific Instruction on Involvement

Lymph Node Involvement: For solid tumors, the terms “fixed” or “matted” and “mass in the mediastinum, retroperitoneum, and/or mesentery” (with no specific information as to tissue involved) are considered involvement of lymph nodes. Any other terms, such as “palpable,” “enlarged,” “visibly

swelling,” “shotty,” or “lymphadenopathy” should be ignored; look for a statement of involvement, either clinical or pathological. A metastatic nodule in connective tissue of a lymph drainage area is considered to be evidence of lymph node metastasis.

Note: Regional lymph nodes are not palpable for inaccessible sites such as bladder, kidney, prostate, esophagus, stomach, lung, liver, corpus uteri, and ovary. The best description concerning regional lymph node involvement will be the surgeon’s evaluation at the time of exploratory surgery or definitive surgery.

Venous Invasion: An assessment of blood vessels **within** the primary organ. This does not constitute regional or distant spread of malignancy.

Lymphatic Invasion: A microscopic assessment of involvement of the lymphatic channels **within** the primary organ and at the margins of resection. This is an assessment of the potential, from the primary tumor, to metastasize to lymph nodes, even though the tumor has extended no further than the lymph channels and is still confined to the primary site.

Residual Tumor: Refers to the status of the margins after a surgical procedure of the primary site. It is important to document this information if it is available in the pathology and/or operative report. **Microscopic residual tumor** is identified by the pathologist through the microscope but is not grossly visualized. An example would be a positive margin of resection when the surgeon stated that the tumor was completely removed. **Macroscopic residual tumor** is identified during the procedure by the surgeon and is a tumor that is grossly visualized. An example of this would be tumor adhering to another structure that the surgeon could not remove.

Lymphomas: Any mention of lymph nodes is indicative of involvement. In staging lymphomas, bilateral node involvement should be considered 2 chains for the purpose of assigning a stage. For example, bilateral inguinal nodes, bilateral iliac nodes, etc., would be considered 2 chains.

Note: When there is doubt about assigning the appropriate stage, assign the lesser stage. Do not over stage.

Consider the following terms as involvement:

<i>Adherent</i>	<i>Induration</i>
<i>Apparent(ly)</i>	<i>Infringe/infringing</i>
<i>Appears to</i>	<i>Into</i>
<i>Comparable with</i>	<i>Intrude</i>
<i>Compatible with</i>	<i>Invasion to, into, onto, out onto</i>
<i>Consistent with</i>	<i>Matted (for lymph nodes only)</i>
<i>Contiguous/continuous with</i>	<i>Most likely</i>
<i>Encroaching upon</i>	<i>Onto</i>
<i>Extension to, into, onto, out onto</i>	<i>Overstep</i>
<i>Features of</i>	<i>Presumed</i>
<i>Fixation to another structure</i>	<i>Probable</i>

<i>Fixed</i>	<i>Protruding into (unless encapsulated)</i>
<i>Impending perforation of</i>	<i>Suspected</i>
<i>Impinging upon</i>	<i>Suspicious</i>
<i>Impose/imposing on</i>	<i>To, Up to</i>
<i>Incipient invasion</i>	

Do not consider the following terms as involvement:

<i>Abuts</i>	<i>Cannot be excluded/ruled out</i>
<i>Approaching</i>	<i>Efface/effacing/effacement</i>
<i>Approximates</i>	<i>Encased/encasing</i>
<i>Attached</i>	<i>Encompass(ed)</i>
<i>Entrapped</i>	<i>Questionable</i>
<i>Equivocal</i>	<i>Reaching</i>
<i>Extension to without invasion/involvement of</i>	<i>Rule out</i>
<i>Kiss/Kissing</i>	<i>Suggests</i>
<i>Matted (except for lymph nodes)</i>	<i>Very close to</i>
<i>Possible</i>	<i>Worrisome</i>

The pertinent information in the following examples has been documented in **bold lettering** for easier identification of required text.

DOCUMENTATION EXAMPLES

Case #1 Lung

Imaging Reports

2/18/05 VA Clinic: CT Chest: Findings: Supraclavicular, axillary, and mediastinal structures unremarkable. No mediastinal or hilar adenopathy. There is a 2.8 x 2.4 x 4.8cm mass in the right lower lobe. The margins are well defined with minimal peripheral ground-glass opacity, probably some degree of obstructive pneumonitis. The remainder of the lungs is clear.

IMPRESSION

1. Lobulated soft tissue mass in the right lower lobe consistent with neoplasm. No evidence of adenopathy, mediastinal or hilar spread.

2/28/05 CT Brain Your Hospital: Impression: No evident disease process.

Pathology Reports

2/28/05 Your Hospital: Final Diagnosis: Fine Needle Aspirate, right lower lobe lung: positive for malignant cells

3/1/05 Your Hospital: Final Diagnosis: Superior segment right lower lobe, resection: moderately differentiated squamous cell carcinoma, maximum tumor diameter 5.0cm, resection margin free of tumor, peribronchial lymph node negative for tumor, right lower paratracheal lymph node negative for tumor, right pretracheal lymph node negative for tumor.

Clinic Reports

3/15/05 SWRCC: Oncologist recommended 4 cycles of adjuvant taxol and carboplatin. The patient would rather receive treatment closer to home and has been referred to an oncologist in that area.

Summary Stage Documentation (2600)

2/18/05 CT Chest: 4.8cm mass in RLL c/w neoplasm, supraclavicular, axillary, and mediastinal structures unremarkable, no mediastinal or hilar lymphadenopathy, probably some obstructive pneumonitis, remainder of lungs clear

2/28/05 Fine Needle Aspirate RLL lung: positive for malignant cells

2/28/05 Ct Brain: No evident dz process

3/1/05 RLL Resection: MD Squamous cell car, 5cm, margin free, 0/3 peribronchial, paratracheal and pretracheal lns

Treatment Documentation (2610, 2620, 2630, 2640, 2650, 2660, 2670)

3/1/05 RLL lobectomy with mediastinal ln dissection

3/15/05 Oncologist recommends 4 cycles adjuvant taxol and carboplatin. PT wants treatment closer to home, referred to oncologist in his area, unknown if chemo done.

Case #2 Lung**Imaging Reports**

6/25/05 River Ranch Radiology CT Chest: I see **no pneumothorax or pleural effusion**. There is an **11.7 x 8.5cm soft tissue mass in the right apex**. There is associated **marked mediastinal lymphadenopathy** with **enlarged nodes in the anterior mediastinum, enlarged nodes lying lateral to the main pulmonary artery, and enlarged nodes in the pretracheal and precarinal region**. There are **enlarged nodes around the right hilum**. The **left lung appears normal**.

Conclusion: Right upper lobe mass with associated marked mediastinal lymphadenopathy. The findings are **highly suspicious for a primary carcinoma of the lung**.

7/1/05 Oncology Associates Bone scan: Non-specific increased uptake at L3 and L5, **no obvious metastasis**.

7/1/05 Oncology Associates MRI brain: **Diffuse cerebral atrophy**

Bronchoscopy Report

6/26/05 Bronchoscopy: The **vocal cords** were visualized and **appeared to move normally**. The bronchoscope was passed to the trachea, which was widely patent. **No endobronchial lesions were noted**. There was a small amount of bleeding from the right upper orifice. **No lesions were noted at the right lower lobe or right middle lobe**. Endobronchial biopsy was performed times six at the right upper lobe. Bleeding was minimal.

Pathology Report

6/26/05 Right upper lobe mass biopsy Final Diagnosis: **non-small cell carcinoma**

Clinical Reports

7/5/05 Oncology Clinic Consultation: This patient has at least Stage 3b disease. This **condition can best be treated with a combination of chemotherapy and radiation therapy concurrently**. We want to start treatment as soon as possible

7/15/05 Discharge Summary: The **patient has been treated with VP-16 times three days along with daily radiation therapy** for a diagnosis of non-small cell carcinoma. He was hospitalized because of shortness of breath and iron deficiency anemia. At this time his condition has stabilized.

Summary Stage Documentation (2600)

6/25/05 CT chest: no pneumothorax or pleural effusion, 11.7cm mass in rt apex, highly suspicious for lung carcinoma, marked mediastinal lymphadenopathy, enlarged nodes in anterior mediastinum,

enlarged nodes lateral to main pulmonary artery, in pretracheal and precarinal region and in rt hilum, lft lung appears normal
6/26/05 Bronchoscopy: vocal cords appear to move normally, no endobronchial, rll or rml lesions
6/26/05 RUL mass bx: Non-small cell carcinoma
7/1/05 Bone Scan: no mets
7/1/05 MRI brain: diffuse cerebral atrophy

Treatment Documentation (2610, 2620, 2630, 2640, 2650, 2660, 2670)

7/5/05 concurrent chemo/radiation therapy recommended
7/15/05 Discharge Summary: PT has been treated with VP-16 x 3 days along with daily radiation therapy

Case #3 Breast**Imaging Reports**

1/2/05 Mammogram: Left breast: No dominant masses, or suspicious calcifications, or architectural disturbances are present. In the right breast there is a 3.5 x 4.6cm irregular spiculated mass in the lower-outer quadrant.

Impression: Large mass in the lower-outer quadrant of the right breast, biopsy is recommended.

1/12/05 CT Chest: COPD with mild parynchymal scarring. No evidence of cardiomegaly. There is **bone destruction of posterior ribs/spine. CT Abdomen and Pelvis no abnormal findings.**

Impression: Bone destruction of posterior ribs/spine, probably mets from known breast cancer.

Pathology Reports

1/10/05 Core biopsy right breast lower outer quadrant: Final Diagnosis: Infiltrating ductal carcinoma, poorly differentiated

Clinical Reports

1/15/05 Surgery consult: Patient noted a mass in the lower-outer quadrant of her right breast. There is marked lymphadenopathy in the right axilla. The left breast is with-in normal limits. HEENT: Clear conjunctivae, pupils equal, round and reactive to light. Nasal passages clear without drainage.

Neck: Supple, full range of motion. No thyromegaly, trachea is midline.

Lungs: No wheezing or crackles. There are no bronchial breath sounds or pleural rub.

Abdomen: Soft, non-tender, non-distended without hepatosplenomegaly or masses. Normal bowel sounds.

Patient will be referred to Radiation Oncology for consideration of radiation therapy to known bony mets.

2/1/05 Oncology Note: Patient has decided to try alternative therapy and has declined radiation therapy and chemotherapy.

Summary Stage Documentation (2600)

1/2/05 Mammogram: Lt breast no masses, Rt breast 4.6cm mass in LOQ, biopsy recommended.

1/10/05 Bx rt breast LOQ Infil ductal car, PD

1/12/05 CT Chest: Bone destruction posterior ribs/spine, probably mets from breast ca, CT

Abdomen/Pelvis: no abnormal findings

1/15/05 Surg consult: marked lymphadenopathy in rt axilla

Treatment Documentation (2610, 2620, 2630, 2640, 2650, 2660, 2670)

1/15/05 Surg Consult: Patient referred to radiation oncology for consideration of radiation therapy to bony mets.

2/1/05 Oncology note: Pt has decided to try alternative therapy, declined radiation therapy and chemotherapy.

Case #4 Breast**Imaging Reports**

6/1/05 Mammogram: In the **right breast** there is a **1.2 x 1.5cm mass in the upper-outer quadrant**. There is **no evidence of axillary lymphadenopathy**. The **left breast appears normal**.

6/14/05 Chest Xray: **With-in normal limits**

6/14/05 Bone Scan: Impression: **No evidence of skeletal disease. Thoracic and lumbar spine negative for metastases.**

Pathology Reports

6/8/05 Right breast fine needle aspiration cytology: **Adenocarcinoma**

6/15/05 Right breast modified radical mastectomy: Final Diagnosis: **Infiltrating ductal carcinoma, tubular type, 1.4cm, margins clear, Bloom Richardson score 3, no dermal or lymphatic invasion, no evidence of tumor in 32 regional lymph nodes.**

Clinical Reports

6/1/05 History and Physical: Family physician noted **2cm mass in right breast on physical exam**. No pain or tenderness; **no nipple discharge; no skin changes**. Slight nipple retraction. Freely movable mass. **Left breast: no masses palpated. No enlarged lymph nodes.**

10/12/05 Oncology Clinic Follow-up Note: Patient started **3 cycles of adjuvant Adriamycin and Cytoxan on 7/20/05**, recently completed and now **has begun Tamoxifen.**

Summary Stage Documentation (2600)

6/1/05 Mammogram: 1.5cm mass rt breast UOQ, no lymphadenopathy, lft breast appears normal

6/1/05 H&P 2cm mass in right breast, no masses palpated in lt breast, no enlarged lymph nodes

6/14/05 CXR: WNL; Bone Scan: no evident mets

6/8/05 Rt Breast fine needle aspiration = adenoca

6/15/05 Rt breast mastectomy: infiltrating duct carcinoma, tubular type, 1.4cm, margin clear, Bloom Richardson score 3, 0/32 LNS positive

Treatment Documentation (2610, 2620, 2630, 2640, 2650, 2660, 2670)

6/15/05 Rt breast modified radical mastectomy

10/12/05 Oncology note: pt had 3 cycles Adriamycin and Cytoxan begun on 7/20/05, recently completed and has begun Tamoxifen.

Case #5 Colon/Rectum**IMAGING REPORTS:****4/20/2005 CT ABDOMEN AND PELVIS****CONCLUSION:**

1. **Two areas of circumferential colonic wall thickening affecting the distal sigmoid colon and a loop of colon in the right lower quadrant/right pelvic region with multiple low-density lesions being noted in the liver. Although these could represent incidental benign hepatic cysts, metastatic liver disease cannot be excluded at this time as colonic carcinoma is one of the causes of cystic liver metastasis. It should be noted although there are shotty lymph nodes present, there is no definite lymphadenopathy demonstrated.**
2. History of uterine cancer with evidence of prior hysterectomy. This is not usually a cause of cystic liver metastasis.
3. **Otherwise, unremarkable CT scan of the abdomen and pelvis with other incidental findings as noted above.**

4/25/05 WHOLE BODY PET SCAN**CONCLUSION:**

1. Radionuclide uptake in the left abdomen, representing a nonspecific finding.
No focal areas of increased uptake are seen in the liver to suggest hepatic metastasis.

PATHOLOGY REPORTS:

4/15/2005 Final Diagnosis: Colon biopsy at 135cm moderately differentiated adenocarcinoma, mucin producing signet ring cell, high grade

5/1/2005 Final Diagnosis right hemicolectomy

- A. **High-grade mucin-producing signet ring cell carcinoma, 4 cm in size and located in colon near ileocolic junction, tumor invades pericolonic adipose tissue, (PT3)**
- B. **No evidence of lymph node metastasis among seven lymph nodes. (PNO)**
- C. **Distant metastasis cannot be assessed. (PMX)**
- D. **Excision margin is negative.**

OPERATIVE REPORT:

Date of Procedure: 5/1/05

PREOPERATIVE DIAGNOSIS: Right colon cancer.

POSTOPERATIVE DIAGNOSIS: Right colon cancer, with adhesive bowel disease.

PROCEDURES PERFORMED: Exploratory laparotomy, lysis of adhesions, **right hemicolectomy**, **Findings: On exploration of the abdomen, the liver was palpated found to be unremarkable. There were no lesions in the colon other than in the right colon.** In the small bowel, there were adhesions, especially in the terminal ileum, adherent to the cecum

Oncology Consult 5/15/05

HISTORY OF PRESENT ILLNESS: Patient is a 56-year old female who had a diagnosis of endometrial cancer, status post surgery followed by radiation therapy fifteen years ago. A few weeks ago the patient had a routine colonoscopic examination and the patient was found to have lesions in the right side of the colon. The patient underwent surgery on May 1, 2005.

ASSESSMENT: The patient has a new diagnosis of **high-grade mucin producing signet ring cell adenocarcinoma of colon**. This is about **4 cm in size with pericolonic tissue invasion**. Based on these reports and findings, **the patient may benefit from adjuvant chemotherapy**.

Summary Stage Documentation (2600)

4/15/05 Colon biopsy at 135cm: Moderately differentiated adenoca, mucin producing signet ring cell, high grade.

4/20/05 Ct Abdomen and Pelvis: 2 areas circumferential colonic wall thickening affecting the distal sigmoid colon and a loop of colon in the rt lower quadrant/rt pelvic region. Multiple liver lesions could represent benign hepatic cysts, mets liver dz cannot be excluded; shotty lymph nodes present, no definitive lymphadenopathy, otherwise unremarkable CT abdomen and pelvis

4/25/05 Whole body PET scan: no focal areas of increased uptake in liver to suggest hepatic mets

5/1/05 Operative report: Liver palpated, found to be unremarkable, no lesion in colon other than rt colon

5/1/05 Right hemi-colectomy: High-grade mucin producing signet ring cell carcinoma, 4cm, located near ileocolic junction, invades pericolonic adipose tissue, 0/7LNS positive, excision margin is negative

Treatment Documentation (2610, 2620, 2630, 2640, 2650, 2660, 2670)

5/1/05 Right Hemi-colectomy

5/15/05 Oncology consult: The patient may benefit from adjuvant chemotherapy; unknown if chemotherapy given.

Case #6 Melanoma**IMAGING REPORTS**

5/10/05 CT Chest : Impression: **Probably malignant involvement of left axillary lymph nodes.** Several lymph nodes seen in supraclavicular region too small to characterize. **The remainder of the exam is normal.**

PATHOLOGY REPORTS

5/3/05 Final Diagnosis: Shave biopsy skin of left forearm, Malignant melanoma

5/11/05 Final Diagnosis: Wide excision of skin of left forearm, Malignant melanoma, nodular type, Clark's Level III, Breslow's depth 1.0mm, papillary dermis invaded. Margins of resection free, but within less than 2mm.

ONCOLOGY REPORT

6/15/05 The patient was started on an interferon regimen today.

Summary Stage Documentation (2600)

5/3/05 Shave bx skin of lt forearm: Malignant melanoma

5/10/05 CT chest: Probably malignant involvement of lt axillary lymph nodes, remainder of exam normal

5/11/05 Wide exc skin of lt forearm: Malignant melanoma, nodular type, Clark's Level 3, Breslow's depth 1.0mm, papillary dermis invaded, margin free but within less than 2mm

Treatment Documentation (2610, 2620, 2630, 2640, 2650, 2660, 2670)

5/11/05 Wide excision of skin of lt forearm

6/15/05 started interferon regimen

Case #7 Melanoma**IMAGING REPORTS**

11/18/05 Chest Xray: With-in normal limits

11/24/05 CT Chest, Abdomen and Pelvis: Impression: Nonspecific soft tissue nodule in the right upper lobe. This is nonspecific but would be consistent with benign parenchymal scar or granuloma. The remainder of the lungs is clear.

There is no evidence of metastatic disease in the chest, abdomen or pelvis.

PATHOLOGY REPORTS**Outside Facility:**

11/12/05 Final Diagnosis: Excision of lesion on right side of neck, 1.5 x .0.8 x 0.5 cm specimens contains a pigmented, 0.4 x 0.3cm area consistent with malignant melanoma in situ, extending to margins of excision.

Your Facility:

11/25/05 Final Diagnosis: Wide re-excision skin of right neck, Inflammation and organizing granulation tissue, negative for any residual melanoma, margins of resection negative.

Summary Stage Documentation (2600)

11/18/05 CXR: Within normal limits

11/24/05 CT Chest/abdomen/pelvis: No evidence of mets in chest, abdomen or pelvis

Treatment Documentation (2610, 2620, 2630, 2640, 2650, 2660, 2670)

11/12/05 Exc of lesion rt side of neck: 0.4x0.3cm malignant melanoma in situ, Ext to margin

11/25/05 Wide re-excision of skin rt neck, negative for residual melanoma, margins negative

Case #8 Lymphoma**Imaging Reports**

2/2/05 CT Chest Impression: Extensive **right and left hilar lymphadenopathy, enlarged lymph nodes in the mediastinum.**

2/2/05 CT Abdomen Impression: **Splenomegaly, otherwise with-in normal limits.**

2/4/05 PET scan: Intense focus of tracer uptake seen in peri-portal region consistent with lymphoma.

Pathology Reports

2/3/05 Biopsy of left axillary lymph nodes, Follicular Lymphoma, Gr 1

H&P

2/2/05 Patient presents with **bilateral cervical and axillary lymphadenopathy**, night sweats, and subjective fevers.

Oncology Consult

2/12/05 The patient was started on **combination chemotherapy including Rituxan on February 5** and has done well with the exception of nausea. We will start him on a trial of antiemetics.

Summary Stage Documentation (2600)

2/2/05 H&P Pt has bilateral cervical and axillary lymphadenopathy

2/2/05 CT Chest: rt and lt hilar lymphadenopathy, enlarged lymph nodes in the mediastinum

2/2/05 CT Abdomen: Splenomegaly, otherwise with-in normal limits

2/3/05 Biopsy lt axillary lns: Follicular Lymphoma, Gr 1

2/4/05 PET scan: focus of tracer uptake in peri-portal region consistent with lymphoma

Treatment Documentation (2610, 2620, 2630, 2640, 2650, 2660, 2670)

2/5/05 Combination chemotherapy including Rituxan, other types of chemo not mentioned

Case #9 Prostate**Imaging Reports**

4/14/05 CT Abdomen/Pelvis Impression: 1. Tiny cyst in the liver.
2. **No lymphadenopathy in abdomen or pelvis.**

4/14/05 Bone scan Impression: Evidence of previous fracture in right 12th rib, otherwise **negative bone scan.**

Pathology Reports

4/1/05 Final Diagnosis: Prostate **core needle biopsy, adenocarcinoma present in 8 of 12 cores, Gleason Score 3+3=6**

Clinical Reports

3/27/05 **Surgical consult:** Patient is seen in consultation because of elevated PSA. **DRE shows slightly enlarged prostate with no nodularity or enduration. The abdomen and pelvis are examined and show no palpable abnormalities.**

7/1/05 Patient was counseled regarding various treatment options including radiation therapy, surgery and hormonal treatment. He decided to proceed with **external beam radiation therapy** and this was **completed on 6/15/05.**

Summary Stage Documentation (2600)

3/27/05 PE: DRE shows slightly enlarged prostate with no nodularity or enduration, abdomen and pelvis with no palpable abnormalities
4/1/05 Prostate core needle biopsy: adenocarcinoma in 8/12 cores, Gleason Score 3+3=6
4/14/05 CT Abdomen/Pelvis: no lymphadenopathy in abdomen or pelvis
4/14/05 Bone scan: negative

Treatment Documentation (2610, 2620, 2630, 2640, 2650, 2660, 2670)

External beam radiation therapy completed on 6/15/05, start date not given; estimate start date 5/2005