

# Woodcock Reovirus

## Synonyms

None

This chapter provides information on a recently identified disease of the American woodcock. Little is known about the disease or the virus that causes it. It has been included in this Manual to enhance awareness that such a disease exists and to stimulate additional interest in further investigations to define the importance of woodcock reovirus. More information about this disease is needed because it is not known whether or not this virus is a factor in the decline of woodcock populations within the United States.

## Cause

The first virus isolated from the American woodcock is a reovirus that was found during woodcock die-offs during the winters of 1989–90 and 1993–94. Avian reovirus infections have been associated with numerous disease conditions including viral arthritis/tenosynovitis or inflammation of the tendon sheath; growth retardation; pericarditis or inflammation of the sac surrounding the heart; myocarditis or inflammation of the heart muscle; hydropericardium or abnormal accumulation of fluid in the pericardium; enteritis or inflammation of the intestine; hepatitis or inflammation of the liver;

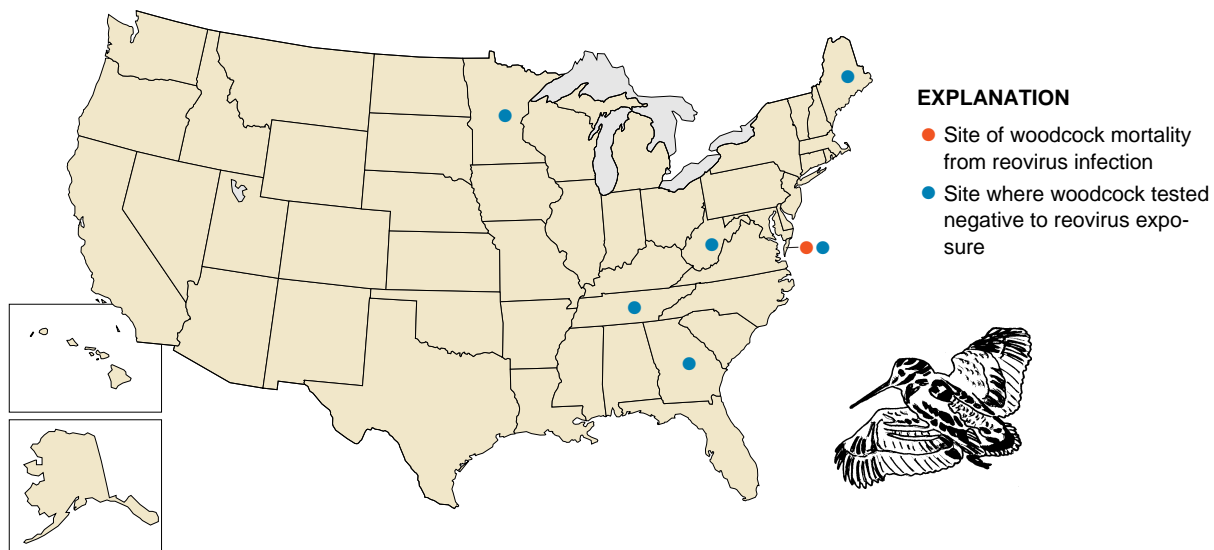
bursal and thymic atrophy or wasting away; osteoporosis or rarefaction of the bone; and respiratory syndromes. The infections are generally systemic, transmitted by the fecal-oral route, and are often associated with nutritional factors or concurrent infections with other agents.

## Species Affected

American woodcock are the only species known to be infected with this particular reovirus. Investigations have not been conducted to determine whether or not other species are susceptible to infection, which species are not susceptible, and which species become diseased.

## Distribution

The virus was isolated from woodcock that were found dead at the Eastern Shore of Virginia National Wildlife Refuge (Fig. 23.1). To determine the prevalence of woodcock reovirus in the eastern and central regions of the United States, virus isolation was attempted from woodcock samples collected from the breeding and wintering populations in 1990–92 (Fig. 23.1). No viruses were isolated from 481 tissue samples or 305 cloacal swabs that were obtained from live-trapped and hunter-killed woodcock.



**Figure 23.1** Site of woodcock mortality from reovirus infection and field sampling sites where other woodcock were tested and found to be negative for exposure to this disease.

## Seasonality

Both die-offs occurred during the winter months. Nothing more is known about the seasonality of this disease.

## Field Signs

Sick woodcock have not been observed. Therefore, field signs are unknown.

## Gross Lesions

Most of the birds found dead were emaciated. Little or no food was found in their digestive tracts, and no obvious gross lesions were noted upon necropsy of the carcasses. Healthy “control” woodcock collected during the same time did not yield virus.

## Diagnosis

Diagnosis requires laboratory isolation and identification of the causative virus. Winter concentrations of woodcock should be monitored and carcasses picked up and submitted for diagnosis. Whole carcasses of woodcock found dead should be shipped to a diagnostic laboratory where pathological assessments and virus isolation can be made (see Chapter 3, on Specimen Shipment). Although the virus has been isolated from a variety of tissues including intestine, brain, cloacal swab, heart, and lung, the majority of isolates were obtained from intestines and cloacal swabs. These findings suggest that a fecal-oral route of transmission is likely.

## Control

Field carcasses not needed for diagnostic study should be collected for disposal to minimize environmental contamination. Too little is known about this disease to recommend response actions.

## Human Health Considerations

There are no known human health considerations.

*Douglas E. Docherty*

## Supplementary Reading

Docherty, D.E., Converse, K.A., Hansen, W.R., and Norman, G.W., 1994, American woodcock (*Scolopax minor*) mortality associated with a reovirus: Avian Diseases, v. 38, p. 899–904.