

ELEPHANT RESEARCH AND TISSUE REQUEST PROTOCOL

(Elephas maximus and Loxodonta africana)

***The American Zoo and Aquarium Association
Elephant Species Survival Plan
And
The Elephant Research Foundation***

January 2003

TABLE OF CONTENTS

Elephant Herpesvirus Alert	3
Elephant Tuberculosis Alert	3
Internet Sites.....	4
Introduction.....	5
Search List	6
Measurements Checklist	6-10
Selected Bibliography	10
Research Requests	11-14
Form for Requesting Elephant Tissue/Blood Samples.....	15
Elephant Serum Bank Submission Form.....	16

ELEPHANT HERPESVIRUS DISEASE ALERT

The cause of a highly fatal disease of elephants in North American and European Zoos has been identified recently as a new type of herpesvirus. The herpesvirus affects mainly young elephants and usually has a fatal outcome within an hour to a week of onset. Clinical signs are variable and include lethargy, edematous swellings of the head and thoracic limbs, oral ulceration and cyanosis of the tongue. Necropsy findings include extensive cardiac and serosal hemorrhages and edema, hydropericardium, cyanosis of the tongue and oral and intestinal ulcers. Histological features are microhemorrhages with very mild inflammation in the heart, liver and tongue accompanied by intranuclear inclusion bodies in the capillary endothelium. Transmission electron microscopy of the inclusion bodies shows 80-90 nm diameter viral capsids consistent with herpesvirus morphology.

Serological tests have been recently developed (2002) using molecular techniques to express antigens because it has not been possible to cultivate the virus *in vitro*. Some of the epidemiological aspects of the disease are not yet clear and are still under study. Although African elephants are known to carry the virus that is fatal for Asian elephants, there have been a number of cases in Asian elephants in which no direct contact occurred with African elephants. Asian calves (less than two years of age) from different facilities in the U.S. became ill with the clinical signs noted above, and were found to have the herpesvirus by a blood test using polymerase chain reaction (PCR). Of seven elephants that were treated with famciclovir, three recovered. The onset of the disease may be very rapid with few prodromal signs and peracute death within 24 to 36 hours. This occurred in 1999-2000 in a six and eight year old Asian elephant that both died even though famciclovir was administered several hours after herpes infection was suspected.

If you suspect an elephant in your care may have died from this disease or shows clinical signs, please contact one of the principals listed below. Consult the Tissue Checklist section of this necropsy protocol for instructions on sending diagnostic samples from any elephants suspected of having this disease.

Serum samples from sick or dead elephants should be obtained for diagnostic testing in any suspected case of herpesvirus infection.

Contacts: R. J. Montali, Smithsonian National Zoo, Washington DC, W: 202-673-4869,

H: 703-718-2870; Cell: 703-860-0186; Email: montalir@nzp.si.edu

Laura K. Richman, Smithsonian National Zoo, Washington DC, W: 202-673-4869, H: (301) 253-8723; Cell: 410-491-2294; Email: lkrichma@aol.com

ELEPHANT TUBERCULOSIS ALERT

An intense search for lesions of tuberculosis (TB) is encouraged in all elephant necropsies. This should include all elephants that die or are euthanized for other reasons even though TB is not suspected. Be advised that elephant TB is likely to be caused by *Mycobacterium tuberculosis* which is contagious to humans. Therefore be prepared with proper protective apparel, and contain any suspicious organs or lesions as soon as possible.

Ideally, elephants should be bled for serology (ELISA), and trunk wash(es) collected just prior to euthanasia. Elephants that die naturally should have a post mortem trunk wash performed and serum should be harvested from post mortem blood for serological assays. Consult **Guidelines for the Control of Tuberculosis in Elephants 2003** (www.aphis.usda.gov/ac/TBGuidelines2003.html).

All elephants undergoing necropsies should have a careful examination of the tonsillar regions and submandibular lymph nodes for tuberculous appearing lesions. All lymph nodes should be carefully evaluated for lesions since other sites may also be infected (ex. reproductive or gastrointestinal tract). Take any nodes that appear caseous or granulomatous for culture (freeze or ultrafreeze), and fixation (in

buffered 10% formalin). In addition, search thoracic organs carefully for early stages of TB as follows: after removal of the lungs and trachea, locate the bronchial nodes at the junction of the bronchi from the trachea. Use clean or sterile instruments to section the nodes. Freeze half of the lymph node and submit for TB culture to NVSL or a laboratory experienced in mycobacterial culture and identification (**even if no lesions are evident**). Submit sections in formalin for histopathology. Carefully palpate the lobes of both lungs from the apices to the caudal borders to detect any firm B-B shot to nodular size lesions. Take sections of any suspicious lesions. Open the trachea and look for nodules or plaques and process as above. Regional thoracic and tracheal lymph nodes should also be examined and processed accordingly. Split the trunk from the tip to its insertion and take samples of any plaques, nodules or suspicious areas for TB diagnosis as above. Look for and collect possible extra-thoracic TB lesions, particularly if there is evidence of advanced pulmonary TB.

For further information on laboratories performing diagnostic tests for TB, consult **Guidelines for the Control of Tuberculosis in Elephants 2003**. In the event of an elephant necropsy (elective or otherwise), please notify Dr. R. J. Montali, AZA-Elephant SSP Pathology Advisor, National Zoo, Washington DC, W: 202-673-4869, H: 703-718-2870; Cell: 703-863-0186; E-mail: montalir@nzp.si.edu, for further instructions and possible participation.

INTERNET SITES

These guidelines and other elephant protocols are available at the following sites:

1. www.aphis.usda.gov/ac/TBGuidelines2003.html (available to the public)
2. www.aphis.usda.gov/ac/ElephNecropsy.html (available to the public)
3. www.aazv.org (available to AAZV members by password)
4. www.elephantcare.org (available to the public).

INTRODUCTION

This protocol is an effort of the Elephant Species Survival Plan (SSP) Propagation Group of the American Zoo and Aquarium Association (AZA) and the Elephant Research Foundation. Its purpose is to provide a format for the systematic collection of information and samples that will add to our knowledge of elephants. All North American institutions holding elephants will receive a copy.

We hope that most institutions will not have to face the immense task of immobilizing or performing an elephant necropsy, but this occur, it should be viewed as an important learning opportunity. Although it may not be feasible to collect all the information and samples requested, we encourage the collection of as much as possible. With the increased availability of digital cameras, it is strongly recommended that photographs of both normal and pathologic structures be recorded for future reference.

Sample and data collection information for research is contained in this document. (Specific necropsy information is contained in a separate document, **Elephant Necropsy Protocol**.) The *Search List* describes those parts of the anatomy for which data is lacking or about which previous observations need to be confirmed or refuted. The *Measurements Checklist* may seem tedious, but only this type of attention to detail will allow us to expand our knowledge of elephant anatomy. Both of these requested data sets are optional and included in this document. Some of these observations may be applied to live animals. Therefore, this protocol should be referred to when planning a procedure that might facilitate data collection. Please send the completed measurements checklist to Dr. J. Shoshani (contact information on page 11) and a copy to Dr. Michele Miller.

Acquainting oneself with the protocols in both documents (Elephant Necropsy Protocol and Elephant Research and Tissue Request Protocol) and having the necessary equipment ready will facilitate sample collection. A team should be designated in advance for data and sample collection to save valuable time. A list of researchers interested in participating in elephant necropsies is included in the Elephant Necropsy Protocol.

A revised Elephant Research and Tissue Protocol will be forwarded periodically as new requests are received and projects end. Contact Dr. Michele Miller for current requests. A copy of the completed data should be sent to the appropriate researcher. A copy of the necropsy report should be completed and sent to Drs. R.J. Montali and Genny Dumonceaux (see Elephant Necropsy Protocol for details).

Michele Miller
Disney's Animal Kingdom
Department of Veterinary Services
P.O. Box 10,000
Lake Buena Vista, FL 32830-1000

Work: (407) 939-7316
FAX: (407) 938-1909
Email: Michele.Miller@disney.com

SEARCH LIST (OPTIONAL)

The following are anatomical features that need to be confirmed or refuted, or for which few data exist. They are not arranged in order of importance, but rather as one studies the elephant by regions from the tip of the trunk to the tip of the tail. Please be aware of these anatomical questions and attempt to obtain the needed additional data as you proceed in your dissection.

1. Record the number of toenails.
2. Weigh skin after dissection from limbs and carcass.
3. Search for sesamoids especially under tendons. There may be one at the proximal end of the humerus, but check other sites as well.
4. Obtain total skeletal weight. Remove as much soft tissue as possible.
5. Note any pathological conditions in the joints. Slight erosions on articular surfaces can be viewed best in fresh tissues and should be examined soon after death. Grooves and fractures on articular surfaces cannot be mistaken and should be sought. Look also for "joint mice," calcium deposits, and any other abnormal signs.
6. Measure the volume of the nasal passages by instilling water soon after death or by measuring the diameter of the passages at intervals (record total length of trunk and diameter of passages at intervals of 10 cm).
7. Look for the intercommunicating canal between the two nasal passages of the trunk and the associated fibrous arches by sectioning the trunk every 10-20 cm. These structures were described as being located 13 cm from the tip of the trunk in a young female Asian elephant. Other searches in adult Asian females have revealed neither the arches nor the canals (Shoshani *et al.*, 1982).
8. Harvest the lenses from the eyes and weigh them (or keep intact eyes frozen).
9. Search for the trachea-esophageal muscle. This muscle is small and may be overlooked or cut during dissection so we suggest that a section about 20 cm posterior and 50 cm or more anterior to the bifurcation be removed and examined carefully outside the carcass. This muscle was found in only three of twelve elephants examined (Shoshani *et al.*, 1982).
10. Examine the dividing arrangement of the arteries from the aortic arch. There are two possibilities three branches or two branches. In the three-branch arrangement the sequence is right subclavian, a trunk common to the two carotids and the left subclavian. In the two-branch arrangement, the right subclavian and the common carotids merge into one vessel and the left subclavian remains separate.

MEASUREMENTS (OPTIONAL)

This data sheet is a general guideline to the pre-euthanasia or post mortem measuring of an elephant. Refer to the anatomical diagrams, Figures 1 and 2. The numbering system begins at the trunk and continues in a clockwise direction. All measurements should be taken in a straight line, except when indicated otherwise. Measurements to be taken between corresponding points on opposite sides of the body are marked with a plus symbol (+). These should be taken in a straight line, essentially through, not around, the elephant. Calipers can be improvised from two long straight poles or straight edges. Place the end of each pole on one of the two points, keeping the poles parallel to one another. Measure the straight line distance between the free ends of the two parallel poles.

GENERAL		
Subject	Reference numbers on figures	Measurement between these points (cm)
Tip of trunk to tip of tail (along the curve)	Fig.1: 1-9	
Length of trunk (along the curve)	Fig.1: 1-2	
Length of tail	Fig.1: 8-9	
Shoulder height	Fig.1: 5-14	
Dorsum height (the highest point of back or "hump")	Fig.1: 6-13	

DETAILED			
TRUNK	Tip to base	Fig.1: 1-2	
	Tip width	Fig.1: 1-21	
	Base width	Fig.1: 40+	
HEAD	Dorsal length (along the curve)	Fig.1: 2-3	
	Ventral length (along the curve)	Fig.1: 19-20	
	Neck height	Fig.1: 3-19	
	Width between ears	Fig.1: 38+	
	Width between temporal glands	Fig.1: 38a+	
	Width between eyes	Fig.1: 39+	
	Width of mouth	Fig.1: 40+	
EAR	Anterior width	Fig.1: 22-23	
	Posterior width	Fig.1: 24-25	
	Dorsal length	Fig.1: 22-24	
	Ventral length	Fig.1: 23-25	
NECK	Length	Fig.1: 3-4	
	Width	Fig.1: 37+	
	Height	Fig.1: 3-19	
BODY	Dorsal length (along the curve: number 7 is in a straight line with number 11)	Fig.1: 4-7	
	Middle length (make sure this and the next measurement are taken parallel to each other)	Fig.1: 32-26	
	Bottom length (make sure this and the previous measurement are taken parallel to each other)	Fig.1: 10-27-18a	
	Width at front	Fig.1: 36+	
	Width at middle	Fig.1: 35+	
	Width at back	Fig.1: 34+	
	Height at front of forelimb	Fig.1: 5-27	
	Height at front of hindlimb	Fig.1: 6-30	
Height at back of hindlimb	Fig.1: 7-10		
TAIL	Length (excluding hair)	Fig. 1: 8-9	
	Width at base	Fig. 1: 8-33	

DETAILED			
FORELIMB	Length (height)	Fig. 1: 16-26	
	Width at top	Fig. 1: 18b-28	
	Width at bottom (include side width, if different)	Fig. 1: 15-17	
HIND LIMB	Length (height)	Fig. 1: 11-31	
	Width at top	Fig. 1: 29-31	
	Width at bottom (include side width since it is narrower)	Fig. 1: 11-12	
FEET	Count number of “toenails”		Left front
			Right front
			Left hind
			Right hind
TEETH (can be measured soon after death or at a later date)	Total number of plates (including very small ones)	Fig. 2A: (1b)	
	Total length	Fig. 2A: (1)	
	Maximum width	Fig. 2A: 3 (1a)	
	Maximum grinding length of individual teeth	Fig. 2A: (1a)	
	Maximum grinding length of entire grinding surface	Fig. 2A: 1b	
	Maximum height	Fig. 2A: 2	
	Weight (in grams)		
TUSKS	Present_____Absent_____	Fig. 2B	
	Length from tip to gum line	Fig. 2B: b-c	
	Length from gum line to base	Fig. 2B: a-c	
	Length of pulp cavity	Fig. 2B: a-d	
	Width of pulp cavity	Fig. 2B: e-e	
	Total length	Fig. 2B: a-b	
PENIS	Circumference at base		
	Circumference at head		
	Length		
CLITORIS	Circumference at base		
	Circumference at head		

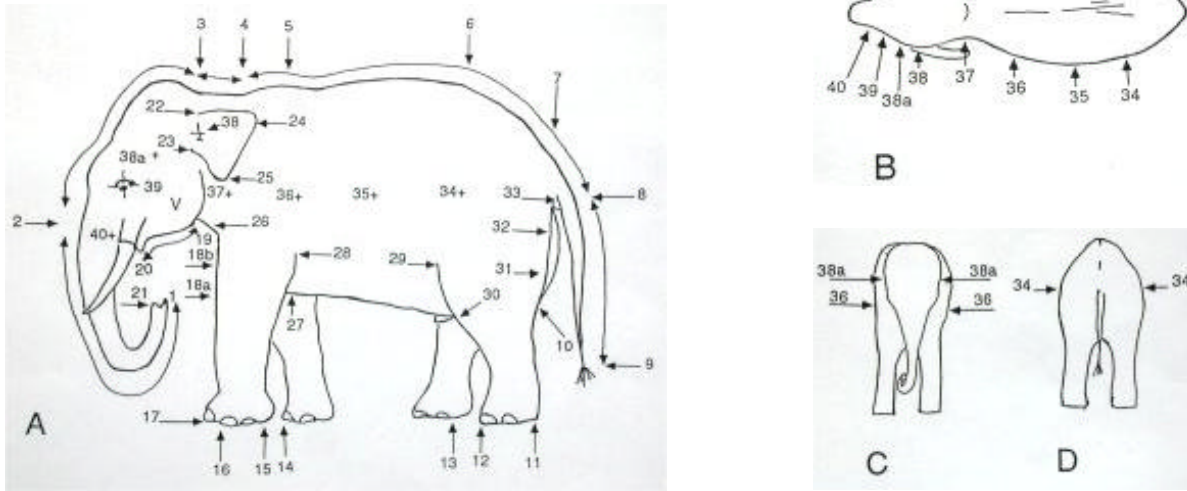


Figure 1. Generalized illustrations of an elephant showing points for measurement: A) after Deraniyagala (1955); all others by Shoshani. Letter “V” on the head indicates the approximate location of the vent gland.

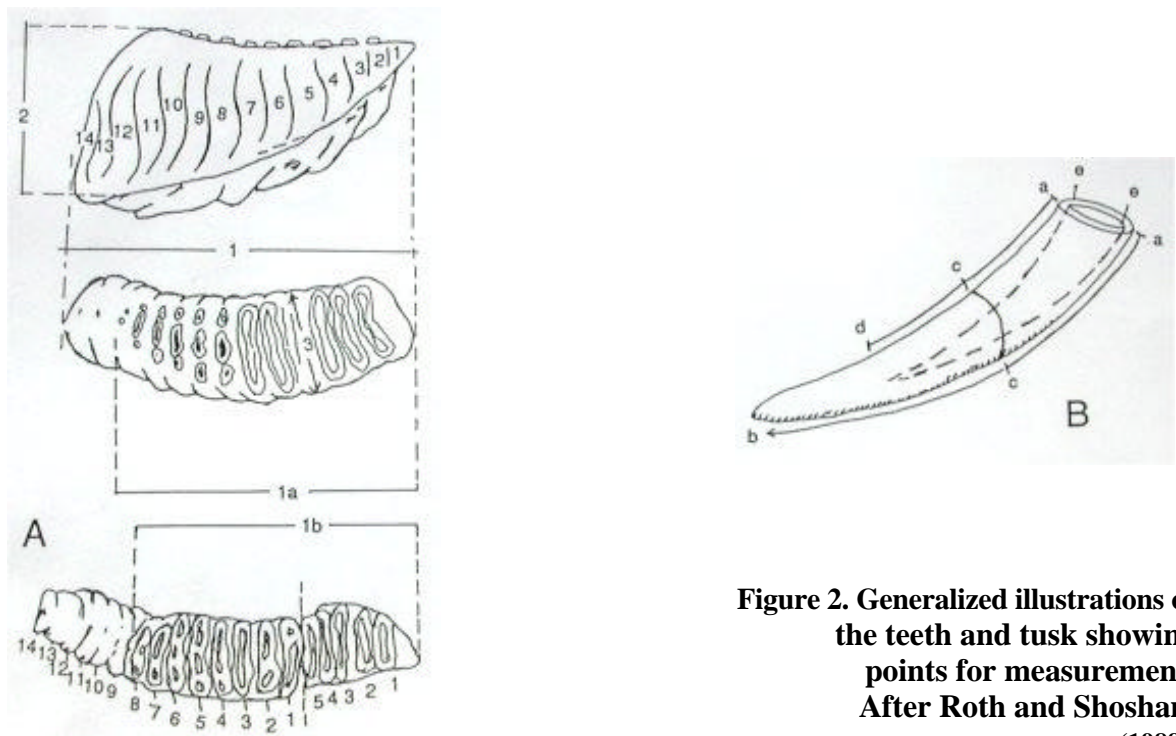


Figure 2. Generalized illustrations of the teeth and tusk showing points for measurement. After Roth and Shoshani (1988).

LITERATURE CITED and SELECTED BIBLIOGRAPHY

- Benedict, F.G. (1936). The physiology of the elephant. Carnegie Institution of Washington, Washington, pp. 302.
- Blair, P. (1710a). Osteographia elephantina: or, a full and exact description of all the bones of an elephant which dy'd near Dundee, April the 27th, 1706, with their several dimensions, etc. Part I. Philos Trans R Soc Lond [Biol] 27(326): 51-116. Part II. Philos Trans R Soc Lond [Biol] 27(327): 117-168.
- Boas, T.E.V. and Pauli, S. (1925). The elephant's head. The Carlsberg Fund, Copenhagen.
- Deraniyagala, P.E.P. (1955). Some extinct elephants, their relatives and the two living species. Ceylon National Museum Publ., Colombo, 161 pp.
- Eales, N.B. (1925). External features, skin, and temporal gland of a foetal African elephant. Proc Zool Soc Lond 2:445-456.
- Eales, N.B. (1926). The anatomy of the head of a foetal African elephant, *Elephas africanus (Loxodonta africana)*. Trans Roy Soc Edin 54, part III (11):491-551 plus 12 plates.
- Eales, N.B. (1928). The anatomy of a foetal African elephant, *Elephas africanus (Loxodonta africana)* Part II. The body muscles. Trans Roy Soc Edin 55, part III (25):609-642 plus 5 plates.
- Eales, N. (1929). The anatomy of a foetal African elephant, *Elephas africanus (Loxodonta africana)*. Part III. The contents of the thorax and abdomen, and the skeleton. Trans Roy Soc Edin 56, part I (11): 203-246.
- Hill, W.C.O. (1938). Studies on the cardiac anatomy of the elephant: II-the heart and great vessels of a foetal Asiatic elephant. J Sci 21:44-61.
- Laursen, L. and Beckoff, M. (1978). *Loxodonta africana*. Mamm Species 92:1-8.
- Laws, R.M. (1966). Age criteria for the African elephant, *Loxodonta a. africana*. East Afr Wildl J 4:1-37.
- Laws, R.M. (1967). Eye lens weight and age in the African elephant. East Afr Wildl J 5:46-52.
- Laws, R.M., Parker, I.S.C. and Archer, A.L. (1967). Estimating live weights of elephants from hindleg weights. East Afr Wildl J 5:106-111.
- Mariappa, D. (1986). Anatomy and histology of the Indian elephant. Indira Publishing House, Oak Park, Michigan, 209 pp.
- Miall, L.C. and Greenwood, F. (1879). The anatomy of the Indian elephant. Part I. The muscles of the extremities. J Anat Physiol. 12:261-287. Part II. Muscles of the head and trunk. J Anat Physiol. 12:385-400. Part III. J Anat Physiol. 13:17-50.
- Mikota, S.K., Sargent, E.L., and Ranglack, G.S. (1994). Medical management of the elephant. Indira Publishing House, West Bloomfield, Michigan, 298 pp.
- Mikota, S.K., Larsen, R.S., and Montali, R.J. Tuberculosis in elephants in North America (Zoo Biology, publication pending).
- Rasmussen, L.E., and Hultgren. (1990). Gross and microscopic anatomy of the vomeronasal organ in the Asian elephant, *Elephas maximus*. In: Chemical signals in vertebrates 5, McDonald d., Muller-Schwarze, D., and Natynczuk, S.E., eds., Oxford University Press, pp154-161.
- Richman, L.K., Montali, R.J., Garber, R.L., Kennedy, M.A., Lehnhardt, J., Hildebrandt, T., Schmitt, D., Hardy., Alcendor, D.J., and Hayward, G.S. (1999) Novel endotheliotropic herpesvirus fatal for Asian and African elephants. Science, 283(5405): 1171-1176.
- Robertson-Bullock, W. (1962). The weight of the African elephant *Loxodonta africana*. Proc Zool Soc Lond 138:133-135.
- Rooney, J.R.,II, Sack, W.O., and Habel, R.F. (1967). Guide to the dissection of the horse. Wolfgang O. Sack, Ithaca, New York.
- Roth, V.L. and Shoshani, J. (1988). Dental identification and age determination in *Elephas maximus*. J Zool (Lond) 214(4): 567-588.
- Shimizu, Y., Fujita, T., and Kamiya, T. (1960). Anatomy of a female Indian elephant with special reference to its visceral organs. Acta Anat Nippon 35(3):261-301.
- Shindo, T. and Mori, M. (1956). Musculature of the Indian elephant. Part I. Musculature of the forelimb. Okajimas Folia Anat Japonica 28:89-113. Part II. Musculature of the hindlimb. Okajimas Folia Anat Japonica 28:114-147. Part III. Musculature of the trunk, neck, and head. Okajimas Folia Anat Japonica 29:17-40.
- Shoshani, J., Alder, R., Andrews, K., Baccala, M.J., Barbish, A., Barry, S., Battiata, R., Bedore, M.P., *et al* (1982). On the dissection of a female Asian elephant (*Elephas maximus maximus* Linnaeus, 1758) and data from other elephants. Elephant 2 (1):3-93.
- Shoshani, J. (1996). Skeletal and other basic anatomical features of elephants. In: The Proboscidea: evolution and palaeoecology of elephants and their relatives. Shoshani, J. & Tassy, P. eds., Oxford University Press, Oxford, p. 9-20.
- Sikes, S.K. (1971). The natural history of the African elephant. American Elsevier Publishing Company, Inc., New York, pp. 397.
- Sisson and Grossman's the anatomy of the domestic animals. Getty, R., ed. (1975). W.B. Saunders Company, Philadelphia.
- Sreekumar, K.P. and Nirmalan, G. (1989). Estimation of body weight in Indian elephants (*Elephas maximus indicus*). Vet Res Commun 13:3-9.

RESEARCH REQUESTS

- | | | | |
|----|--|----|--|
| 1. | Dr. Jeheskel (Hezy) Shoshani
Elephant Research Foundation
106 East Hickory Grove Road
Bloomfield Hills, Michigan 48304 USA
Work: (248) 540-3947
Email: jshosh@sun.science.wayne.edu | or | Dr. William Kupsy
Phone: (313) 745-2542; email: wkupsky@dmc.org
or
Gary Marchant
Phone: (248) 559-2278; email: merchant@ic.net
or
Mahmood Mokhayesh
Phone: (313) 557-2872;
email: carnassial@hotmail.com |
|----|--|----|--|

Intact brain from any age, sex or species of elephant. Preserve in 10% formalin.

- | | | |
|--|----|--|
| Dr. Jeheskel (Hezy) Shoshani
Elephant Research Foundation
106 East Hickory Grove Road
Work: (248) 540-3947
Email: jshosh@sun.science.wayne.edu | or | Dr. Shozo Yokoyama
Phone: (315) 443-9166
Email: syokoyam@mailbox.syr.edu |
|--|----|--|

Intact eyes from any age, sex or species of elephant. Preserve in 10% formalin.

Copy of completed measurements checklist (Anatomical studies). Please send to Dr. Shoshani.

- | | |
|----|--|
| 2. | Dr. Larry Agenbroad
The Mammoth Site
1800 Hwy 18 By-pass
Hot Springs, South Dakota, 57747 USA
Work: (605) 745-6017 Fax: (605) 745-3038 |
|----|--|

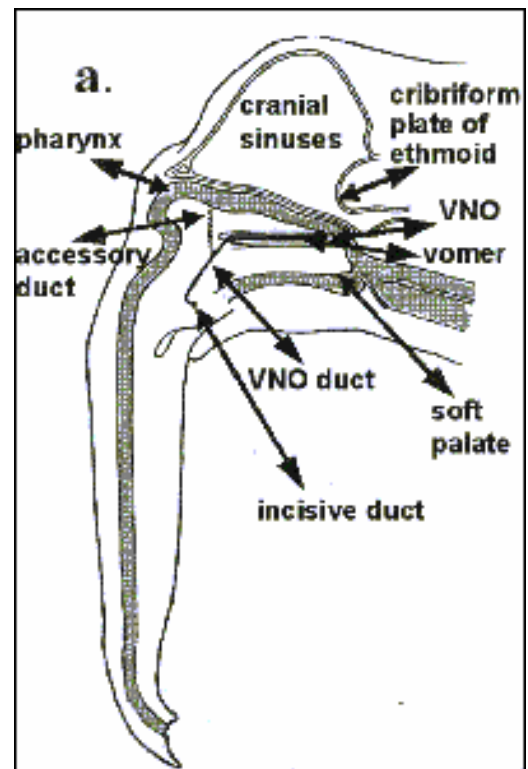
Skeletal remains; Asian or African (Exhibit; comparative collection). Rough flesh if possible and ship frozen or just freeze. Will pay shipping.

- | | | |
|----|--|--|
| 3. | Dr. Bets Rasmussen
Professor of Biochemistry
Oregon Graduate Institute
20,000 NW Walker Rd
Beaverton, Oregon 97006 USA | Work: 503-748-1263
Home: 503-621-1435
Fax: 503-748-1464
Email: betsr@bmb.ogi.edu |
|----|--|--|

For any MALE ELEPHANT please call Bets Rasmussen immediately at 503-748-1263 or 503-621-1435. She will come on the next airplane as certain tissues are of extreme and immediate value in her studies.

Fixatives. Fixatives are available from Dr. Rasmussen. If there is an immediate need, contact your local medical school. Preferred fixative is 4% glutaraldehyde (EM grade) in a pH 7.2 buffer. Cut pieces for EM 0.5cm³. Save (in 10% buffered formalin) the larger section from which the EM piece was taken. If glutaraldehyde is not available submit tissues in 10% buffered formalin.

Vomer nasal organ (RNA & DNA studies; electron microscopy). See diagram a. **Adults:** Only the incisive ducts are requested. These paired openings on the roof of the mouth are 1-2 cm in diameter, several cms posterior to the juncture of the mucosa of the mouth with the lip region.



Fetal, neonates & young elephants. The whole vomeronasal organ is requested. It is found in the vomer bone, dorsal and posterior to the incisive ducts. It is paired, pear-shaped and surrounded by cartilage. In immediately post-natal elephants it does not connect with the ducts. In these young elephants to obtain the organ, work dorsal/posteriorly from the ducts, looking for shiny white cartilage surrounding receptive tissue, which is hollow in the center. **FIRST PRIORITY** is (1cm³) pieces frozen in cryotubes in liquid nitrogen. Second priority is fixed tissue.

Palatal pits. (Histological and cytological studies.) The palatal pits are dual series of small (smaller than VNO duct opening) openings (0-13), asymmetrically and bilaterally located along the approximate demarcation line in the upper head between the hard palate and the trunk. Push aside the upper lip to locate. Dissect out a pit (0.5-1.0cm), making sure at least 2 cm of underlying tissue are included (4% buffered glutaraldehyde).

Temporal gland. Asian or African: large pieces including ducts in formalin 4 and small pieces (several mm square) fixed in 4% glutaraldehyde.

Skin. 5 x 5 cm full thickness sections of skin from the back, forehead, abdomen, upper front leg, and upper rear leg. Make sure the subcutaneous tissue is included. Fix in 10 % formalin

Brain. The anterior, olfactory bulb region is requested if the brain is being removed. Especially the anterior-ventral region where connections to olfactory turbinates and vomeronasal nerve occur. This is a special request and Dr. Rasmussen will be present for such procurement.

4. Dr. C. Earle Pope
Audubon Center for Research of Endangered Species (ACRES)
14001 River Road
New Orleans, Louisiana, 70131 USA
Work: (504) 398-3161 Home: (504) 734-5381 Fax: (504) 391-7707 Email: epope@acres.org

Intact ovaries (To recover oocytes for *in vitro* maturation and culture). Remove ASAP; rinse with saline to remove blood and adhering tissue. Wrap in sterile gauze pre-soaked in saline and place in plastic bag or specimen container. Keep at room temperature if sample can be shipped the same day; if longer, pack in crushed ice. Ship overnight; will pay shipping.

<p>5. Vaughan A. Langman Ph.D. LSU in Shreveport Department of Biological Sciences One University Place Shreveport, Louisiana, 75115-2399 USA Work: (318) 797-5244 Home: (318) 797-2750 Fax: (318) 797-5222</p>	<p>Dr. D. J. Hillman Louisiana State University Department of Veterinary Anatomy School of Veterinary Medicine Baton Rouge, Louisiana, 79803 USA Work: (225) 346-3246 or 346-3164 Home: (225) 272-0156 Fax (504) 272-0156 Email: dhillmann@mail.vetmed.lsu.edu</p>
---	---

Intact head, neck and ears with cervical vertebrae if possible (To study venous drainage.) Contact prior to necropsy. Will pay shipping.

<p>6. Dr. William A. Akersten Curator of Vertebrate Paleontology Idaho Museum of Natural History Campus Box 8096 Pocatello, Idaho, 83209 USA Work: (208) 236-4151 or 236-3168 Home: (208) 232-5436 Fax: (208) 236-4600</p>	<p>Susanne J. Miller 1450 Antares Drive Idaho Falls, Idaho, 83402 USA Work: (208) 526-0938 Home: (208) 529-2453 Email work: ski@inel.gov Email home: olbonz@srv.net</p>
--	---

Complete or partial neonate or juvenile skeleton Asian preferred (Aid identification of fossil mammoths for comparative osteology collection). Bones must be rough-fleshed and dried to avoid spoilage during shipping. Will pay shipping costs and labor for rough-fleshing.

-
7. Dr. Linda Munson
Department of Veterinary Pathology, Microbiology Immunology
University of California at Davis
1126 Haring Hall / One Shields Ave.
Davis, CA 95616 USA
Work: 530-754-7567 Fax: 530-752-3349 Email: lmunson@ucdavis.edu

Sections of uterine endometrium (Characterization of endometrial lesions.) Endometrial samples including any polyps, cysts, tumors or other lesions. Samples should include lesion and adjacent normal tissue. Fix in 10% formalin. Ship by U.S. mail. Will pay shipping.

-
8. Dr. Richard J. Montali
National Zoological Park, Department of Pathology
3001 Block of Connecticut Avenue, NW
Washington, DC, 20008-2598 USA
Work: (202) 673-4869 Home (301) 926-2622 Fax: (202) 673-4660 Email: montalir@nzp.si.edu

Complete set of formalin fixed tissues (as per SSP Necropsy Protocol). (For elephant herpes virus study). For formalin fixed tissues 0.5-1.0cm thick sections. Call before shipping. Will pay shipping.

-
9. Dr. Laura K. Richman
National Zoological Park, Department of Pathology
3001 Block of Connecticut Avenue, NW
Washington, DC 20008-2598 USA
Work (202) 673-4869 Home (301) 253-8723 E-mail: lkrichma@aol.com

1. Ultra frozen (-70 °C) heart, liver, tongue, spleen, intestinal, oral ulcers and lymphoid patch sections from distal vestibulum. 2. Whole blood (5-10 ml); serum (5-10 ml). (For elephant herpes virus study). Take samples to be frozen as soon as possible place in sterile container and freeze. Send frozen tissue overnight on dry ice. Send blood and serum samples overnight on wet or dry ice. Call before shipping. Will pay shipping.

-
10. Dr. Richard J. Montali / Dr. Janine Brown
National Zoological Park, Department of Pathology
3001 Block of Connecticut Avenue, NW
Washington, DC, 20008-2598 USA
Work: (202) 673-4869 Home: (301) 926-2622 Fax: (202) 673-4660 Email: montalir@nzp.si.edu

1. Sections of uterine leiomyoma. 2. Sections of normal uterine wall. 3. Serum sample (2-3 ml). (To compare nuclear receptors and estrogen receptors in the normal and abnormal elephant uterus with human and guinea pig models to identify non GnRH analogs to reverse tumors). Need 2-3 representative sections of leiomyomas and normal uterine wall approximately 1-2 cm thick. Fix 1 set in 10% neutral buffered formalin. Freeze a replicate set in liquid nitrogen or "Revco" ultra freezer at -70°C. Send frozen samples overnight on dry ice. Will pay shipping. Call for billing number. Please include brief reproductive history.

-
11. Anthony T. Boldurian, Ph.D.
Professor of Anthropology
University of Pittsburgh at Greensburg
Smith Science Building
1150 Mt. Pleasant Road
Greensburg, Pennsylvania, 15601 USA
Work: (724) 836-9989 Fax: (724) 836-7129 E-mail: folsom@pitt.edu

Two whole large thoracic ribs; femur or humerus from either species; adult or sub-adult. (For experimental archeological study to replicate mammoth shaft wrench artifact.) Minimum width 60 mm; minimum thickness 20 mm. Samples must be in a "green" or unweathered state, preferably from a recently deceased individual. Pack in ice or cool packs if tissue still adhering. Call before shipping. Will pay shipping.

-
12. Mark Stetter, DVM, DACZM
Director of Veterinary Services
Disney's Animal Programs
Department of Veterinary Services
P.O. Box 10,000
Lake Buena Vista, Florida 32830-1000 USA
Work: (407) 939-7352 Fax: (407) 938-1909 E-mail: Mark.Stetter@disney.com

Please call if an elephant euthanasia is being planned. Project involves abdominal laparoscopy for developing reproductive intervention methods (vasectomy/ovariectomy).

-
13. Denise Sofranko, DVM
USDA, APHIS, AC
1629 Blue Spruce Drive, Suite 204
Ft. Collins, CO 80524-2013
Voice mail: (703) 812-6682 Fax: (505) 293-7466 E-mail: Denise.M.Sofranko@aphis.usda.gov

Heparinized whole blood (20 ml) shipped to NVSL within 24 hours of collection. (For development of gamma interferon assay for TB diagnosis in elephants.) Elephants that have had positive trunk washes and/or treated for mycobacterial infection are especially needed for development of this assay. Participation and results would not be used to substitute for official TB test (see "Guidelines for the Control of Tuberculosis in Elephants 2003").

-
14. Michele Miller, DVM, PhD
Disney's Animal Kingdom
Department of Veterinary Services
1200 N. Savannah Circle East
Bay Lake, Florida 32830
Work: (407) 939-7316 Fax: (407) 938-1909 E-mail: Michele.Miller@disney.com

Minimum 5-10 ml frozen serum for SSP serum bank. Instructions for sample preparation: Serum samples should be separated within 1 hr of collection and frozen in 1-2 ml aliquots in cryovials. Freeze at -70C until shipment. Ship on dry ice or ice packs overnight to address above. Please complete serumbank submission form (see below) and send with shipment.

-
15. Dr. Fahad Sultan
Department of Cognitive Neurology, University Tübingen
Auf der Morgenstelle 15
72076 Tübingen, Germany
Work: +49-7071-2980464 Fax: +49-7071-295724 E-mail: fahad.sultan@uni-tuebingen.de

Intact elephant brain immersed in 3.5% paraformaldehyde. (For neurologic study) Studying quantitative comparative neuroanatomical aspects of mammalian cerebella. Part of the research has been dealing with the size and form of the unfolded cerebellar cortex. Duration of study: 2-5 years. Special instructions: Brains should be as intact as possible (after careful removal from skull), immerxe in 3.5% paraformaldehyde fixative. Researcher will pay for shipping. CITES permit for shipping samples required.

REQUEST FOR ELEPHANT TISSUE/BLOOD SAMPLES

Name _____ Date of request _____

Affiliation _____

Address _____

Work phone (____) _____ Home phone (____) _____

Fax (____) _____ Email _____

Sample(s) requested _____

Purpose of study _____

Duration of study _____

Instructions for sample preparation _____

Shipping instructions (dry ice? Overnight? Will you pay for shipping?) _____

Special instructions _____

Attach any additional information. Send to: Michele Miller, Disney's Animal Kingdom, Department of Veterinary Services, P.O. Box 10,000, Lake Buena Vista, Florida 32830-1000. Work: (407) 939-7316; Fax: (407) 938-1909; Email: Michele.Miller@disney.com

Elephant Serum Bank Submission Form

Institution/owner: _____

Submitter: _____

Address: _____

Tel: _____ Fax: _____ Email: _____

Animal InformationAsian African ISIS# _____ Studbook # _____Name _____ Age: _____ actual estimateSex: male female***SAMPLE COLLECTION INFORMATION***

Date of sample collection: _____ Time of collection : _____

Site of sample collection: ear vein leg vein other: _____Health status of animal: normal abnormalFasted: no yes – how long _____Weight _____ actual estimatedType of restraint: manual anesthetized/sedated behavioral controlTemperament of animal: calm active excited

Type of blood collection tube:

 no anticoagulant (red-top) EDTA (purple) heparin (green) other: _____Sample handling: separation of plasma/serum by centrifugation(check all that apply) stored as whole blood frozen plasma/serum other – describe _____**TB EXPOSURE STATUS** Known infected animal Known exposure to culture positive source within the past 12 months Known exposure to a culture positive source within the past 1-5 years No know exposure to a culture positive source in the last 5 years**TREATMENT INFORMATION****Is elephant currently receiving any medication or under treatment?** yes no**If yes, please list drugs and doses:** _____

Time between blood collection and last treatment: _____

Ship samples overnight frozen with shipping box marked "PLACE IN FREEZER UPON ARRIVAL"**Send completed form with samples to:****Dr. Michele Miller**

Disney's Animal Kingdom-Dept. of Vet. Services

1200 N. Savannah Circle West

Bay Lake, FL 32830

(407) 939-7316; email: Michele.Miller@disney.com

2/20/03