

Effects of Ozone and Endotoxin Coexposure on Rat Airway Epithelium: Potentiation of Toxicant-Induced Alterations

James G. Wagner, Jon A. Hotchkiss, and Jack R. Harkema

Department of Pathology and Diagnostic Investigation, College of Veterinary Medicine, Michigan State University, East Lansing, Michigan, USA

Tropospheric ozone is the major oxidizing component in photochemical smog and is one of the most pervasive problems to human health of the criteria air pollutants for which the National Ambient Air Quality Standards have been designated by the Clean Air Act. Although many adverse health effects of ozone exposure have been documented in both humans and laboratory animals, controversy surrounds the establishment and implementation of ozone standards set forth by the U.S. Environmental Protection Agency. Because people are commonly exposed to more than one air pollutant at a time, studies that examine coexposures to airborne materials may be more relevant for assessing their risks to human health. Airborne biogenic substances such as pollens, spores, and bacterial products are ubiquitous in the environment, and when inhaled can cause adverse respiratory symptoms. One such biogenic agent, bacterial endotoxin, is a potent stimulus of airway inflammation and is a ubiquitous airborne contaminant commonly found in domestic, agricultural, and industrial settings. Little is known about the interaction of exposures to biogenic substances and criteria air pollutants such as ozone. In the last few years we have performed a series of studies in rodents that examined the biologic responses of the respiratory epithelium after airway exposures to both endotoxin and ozone. When exposed to ozone (0.5 ppm 8 hr/day for 3 days), Fischer rats develop lesions in the nasal transitional epithelium, whereas intranasal instillation of endotoxin (20 µg) elicits epithelial lesions in the respiratory epithelium of the nose and conducting airways. Our studies were designed to examine how exposure to one toxicant may affect the airway epithelial lesions induced by the other toxicant. We investigated the potential role of acute inflammation in the enhancement of airway epithelial lesions after exposure of these two toxicants in neutrophil-sufficient and neutrophil-deficient rodents. A summary of these results indicates that epithelial and inflammatory responses to coexposure of these two pollutants are greater than those elicited by either agent alone. Interestingly, each toxicant enhances the epithelial alterations induced by the other. Furthermore, the synergistic effects elicited by coexposure to ozone and endotoxin are mediated partly by neutrophils. These studies provided some new insights into how inhaled co-pollutants interact to initiate and promote alterations of airway epithelium. Further studies with these and other air pollutants will help define their true risk to human health. *Key words:* airway epithelium, endotoxin, mucous cell metaplasia, neutrophil, ozone. — *Environ Health Perspect* 109(suppl 4):591–598 (2001).

<http://ehpnet1.niehs.nih.gov/docs/2001/suppl-4/591-598wagner/abstract.html>

Background

Human Ozone Exposure

Considerable progress has been made in improving U.S. air quality in the last decade. Significant decreases have occurred in the ambient concentrations of the criteria air pollutants, specifically carbon monoxide (39% decrease), lead (56%), nitrogen dioxide (14%), particulate matter with a mass median aerodynamic diameter less than 10 µm (PM₁₀) (25%), and sulfur dioxide (39%) (1). However, ambient ozone concentrations have decreased by only 4% nationwide and have increased by as much as 10–20% in some parts of the country. In 1998 it was estimated that 51 million people in the United States lived in areas that were not in compliance with the 1-hr National Ambient Air Quality Standard (NAAQS) (1) of 0.12 ppm. Furthermore, almost 50% of the U.S. population (131 million people) currently live where the average ambient concentrations of ozone exceed the 8-hr standard of 0.08 ppm.

High ambient concentrations of ozone result from the interaction of ultraviolet light (sunlight) with airborne volatile organic compounds (VOCs) and nitrogen oxides derived primarily from combustion of fossil fuels. Large urban and industrial areas in the Western and Southern United States are especially prone to high levels of ambient ozone. For example, several communities in southern California and Texas often experience ambient ozone concentrations of 0.2 ppm or higher that pose significant health risks to humans (1). Less severe ozone levels above or near the NAAQS standards also occur in several regions of the Midwest and Northeast United States during the summer months. Despite the large numbers of human and animal studies documenting the health risks of exposure to ambient ozone concentrations, controversy exists over the implementation of newly proposed standards (2). Recent U.S. Supreme Court rulings upheld the U.S. Environmental Protection Agency's (U.S. EPA) scientific basis for determining new air quality standards but

found some of the timetables for compliance to meet these standards to be ambiguous and therefore unlawful (3). The Court left it to the U.S. EPA to formulate more reasonable implementation strategies of ozone standards.

Health Effects of Ozone Exposure

Controlled studies of ozone exposure (0.08–0.18 ppm) in healthy adults document increases in airway reactivity and decreases in respiratory function and athletic performance (4). People who live in Mexico City, Mexico, which has high ambient air concentrations of ozone, have substantially more histologic alterations in their nasal mucosa than people living in areas of Mexico with little air pollution (5). Ozone inhalation also exacerbates the bronchoconstrictive and allergic symptoms in asthmatic individuals (6,7) and causes nasal inflammation in both healthy and allergic adults (8,9). Epidemiologic studies show similar results. In two separate studies, increases in airway inflammatory responses of asthmatics correlate with the fluctuations in ambient ozone concentrations that occur between May and October (9,10). High levels of ozone are associated with increased hospital emergency room visits, especially from asthmatics, the elderly, and individuals with preexisting obstructive pulmonary disease (11–14). As such, asthmatics and people with chronic or preexisting respiratory diseases are deemed susceptible groups to the health risk of ozone. In addition, otherwise healthy individuals who spend several hours outside during the summer months, such as children, outdoor workers, and physically active adults, have greater rates of ozone exposure and therefore greater risks of adverse health effects.

Ozone: Pollutant Coexposure as a Susceptible Risk Group

Exposure of people to more than one air pollutant is common, but there is little

This article is based on a presentation at the Workshop on Inhaled Environmental/Occupational Irritants and Allergens: Mechanisms of Cardiovascular and Systemic Responses held 31 March to 2 April 2000 in Scottsdale, Arizona, USA.

Address correspondence to J.R. Harkema, 212 Food Safety and Toxicology Bldg., Michigan State University, East Lansing, MI 48824 USA. Telephone: (517) 353-8627. Fax: (517) 353-9902. E-mail: harkemaj@msu.edu

This work was supported by grant RO1 HL59391-02. Received 22 December 2000; accepted 9 March 2001.

understanding of the risk to human health of coexposure to multiple pollutants relative to that presented by a single pollutant. Tropospheric ozone most always occurs in combination with nitrogen oxides and VOCs and is frequently present with criteria air pollutants such as sulfur oxides and PM. Laboratory rats chronically exposed to combinations of ozone and nitrogen dioxide develop fibrotic lung lesions greater than those produced by either toxicant alone (15). Conversely, chronic coexposure of rats to ozone and sulfuric acid produces neither additive nor synergistic responses in the structural and biochemical end points induced by each pollutant alone (16). After acute 3-hr coexposures, however, sulfuric acid antagonizes ozone-induced airway hyperreactivity (17). These results suggest that the pathologic interaction between ozone and co-pollutants is both complex and variable. Indeed, epidemiologic studies demonstrate that increased respiratory symptoms and hospital admissions are correlated not only with ozone exposure, but also with the overall air quality as determined by the mixture of ozone with other criteria air pollutants (18–21).

Because NAAQS are primarily based on the toxicologic effects of single pollutants, it is probable that the health risk of breathing a mixture of air pollutants is underestimated. Currently there are no guidelines for estimating the health risk of human exposure to more than a single air pollutant. As such, people routinely exposed to certain pollutants in addition to ozone may represent a unique group of at-risk, or susceptible, individuals. Even if exposures to more than one pollutant do not occur simultaneously, the long-term effects of exposure may alter the normal respiratory response to a second exposure for days or weeks.

In addition to the other criteria air pollutants, ozone exposure may alter or enhance the respiratory responses to the inhalation of other airborne materials. Compounds present in occupational, agricultural, and domestic environments make a significant contribution to the morbidity and mortality of respiratory disease. Health effects and risks associated with exposures to many widely used, man-made compounds such as formaldehyde and benzene are well documented. However, a large class of naturally occurring biogenic substances also elicit adverse respiratory responses when inhaled. Biogenic substances are agents derived from a broad range of living organisms, including plants, fungi, molds, and bacteria. Some of these materials are antigens, and exposure to these substances may induce asthmatic or allergic-type symptoms. Despite the clear relationships between adverse respiratory symptoms and exposure to pollen, mold spores, and bacterial toxins,

there are no occupational exposure limits to many of these biogenic substances.

Airborne Bacterial Endotoxin

Bacterial endotoxins are lipopolysaccharide-protein compounds derived from the cell wall of Gram-negative bacteria (e.g., *Escherichia coli*, *Pseudomonas aeruginosa*). Endotoxins are the principal etiologic agents responsible for the acute inflammation in pneumonia and sepsis caused by infections of these bacterial organisms. Inhalation exposure can occur occupationally (endotoxin-contaminated organic dusts in waste treatment plants, textile mills, swine or poultry confinement buildings, and grain silos) and domestically (inadvertent bacterial contamination of aerosols produced by ultrasonic humidifiers and evaporative cooler-type air conditioners). Human exposure to endotoxin has been implicated as the principal pathogenic agent in several occupational diseases including byssinosis (22), mill fever (23), bagassosis (24), and asthmalike or bronchitislike diseases induced by exposure to machining fluid aerosols (25–27).

Endotoxins have been detected at biologically active concentrations in air humidification systems (0.13–0.3 $\mu\text{g}/\text{m}^3$) (28,29), in house dust extracts (0.45–500 mg/mL) (30), and in organic dusts associated with animal handling (150–1,000 ng/mg) (31).

Inhaled endotoxin causes nose and throat irritation in humans, and the production in the nasal and pulmonary airways of soluble inflammatory mediators such as interleukin (IL)-8, tumor necrosis factor- α (TNF- α) and IL-1, and large infiltrates of inflammatory cells, particularly polymorphonuclear neutrophils (PMNs) (32–35). Instillation of endotoxin into the airways of laboratory rodents causes a similar inflammatory response to that observed in humans, including neutrophil infiltration and cytokine production. We have further documented some structural and cellular changes in the airways of laboratory rodents elicited by intranasal instillation (36–38) and aerosolized endotoxin (39). Among these are epithelial cytotoxicity, hyperplasia, and increased synthesis, storage, and secretion of products by airway secretory cells.

Mucous Cell Metaplasia in Respiratory Disease

The protective mucus blanket that coats respiratory airways is a mixture of secretions from serous and goblet cells and consists of electrolytes, antibacterial and antioxidant products, and cross-linked mucin glycoproteins. Normal mucus secretions are essential for clearance and transport of inhaled particles and pathogenic substances. People with chronic airway conditions such as asthma,

bronchitis, and other obstructive pulmonary diseases commonly have abnormally high numbers of mucous cells in submucosal glands and respiratory surface epithelium lining the conducting airways. When an increase occurs in the number of mucous cells in an airway epithelium that normally contains some of these secretory cells, this epithelial cellular change is referred to as mucous cell hyperplasia (or secretory cell hyperplasia). However, when numerous mucous cells are present in areas of the respiratory tract that are normally devoid of these cells, this change in epithelial phenotype is designated as mucous cell metaplasia. Mucous cell hyperplasia, metaplasia, and hypersecretion of mucus can lead to mucus plugs and severe airway obstruction observed in patients with severe asthma, bronchitis, and other airway diseases such as cystic fibrosis.

The core protein of mucin glycoproteins is the product of 1 of 12 reported genes encoding mucin molecules (MUC1-4, 5AC, 5B, 6-9, 11, and 12) (40). Seven of these 12 genes are found in lung tissue, and upregulation of MUC2 and MUC5AC is most often associated with inflammation and allergic responses in nasal and pulmonary airways (41). Upregulation of mucin genes during disease and inflammation may be critical for the overproduction and hypersecretion of mucus that contributes to airway obstruction. Several studies demonstrate that inflammatory mediators (e.g., IL-1, TNF- α), neutrophil-derived proteases, and bacterial products can elicit the overexpression of mucin genes (e.g., Muc5AC) in airway epithelial cells (42–44).

Ozone-Induced Mucous Cell Metaplasia in Nasal Epithelium

In 1989, we first reported that Fischer rats (F344/N) exposed for 7 days to 0.8 ppm ozone for 6 hr/day developed a conspicuous mucous cell metaplasia in the nasal transitional epithelium (NTE) lining the maxilloturbinate, lateral wall, and lateral aspects of the nasoturbinate in the proximal nasal passages of these rodents (45). The ozone-induced lesions in the F344/N rats resembled those that we previously observed in the nasal cavity of bonnet monkeys repeatedly exposed to 0.15 or 0.3 ppm ozone for 6 or 90 days (46). We further demonstrated in rats that the cellular population in the ozone-exposed NTE was markedly hyperplastic and metaplastic, with approximately 15% of the cell population consisting of mucous cells compared to a normal mucous cell density of 0–1% in the NTE of control rats exposed to filtered air (45,47).

In 1991 we reported that ozone-induced mucous cell metaplasia and epithelial hyperplasia in the NTE of rats can be induced

with only three consecutive 6-hr/day exposures to 0.5 ppm ozone (48). Seven days after the start of the exposures, rats exposed to ozone for 3 days had mucous cell metaplasia indistinguishable from that in rats exposed to the same concentration of ozone for 7 consecutive days. Thus, once initiated, the development of ozone-induced phenotypic changes within the epithelium are not dependent on additional ozone exposure. As depicted in Figure 1, the proliferation of mucous cells in the NTE is preceded by a cellular inflammatory response, (i.e., neutrophilic influx), an initial loss of sensitive nasal epithelial cells, and subsequent proliferation of resistant epithelial cells and mucin gene overexpression (49,50).

Endotoxin, Ozone, and Coexposure: Summary of Experimental Results

We are primarily interested in the premetaplastic events and inflammatory responses that precede the onset of epithelial lesions in rats. In recent studies we have used two different airway toxicants to initiate these changes—ozone and endotoxin. Ozone induces mucous cell metaplasia in the NTE (i.e., a surface normally devoid of mucous cells) after short- (days) or long-term exposure to near-ambient concentrations. Conversely, airway endotoxin induces mucous cell metaplasia rapidly (within 48 hr) in the tracheobronchial airways (i.e., a surface containing respiratory epithelium and preexisting secretory cells) of rats after a single or repeated treatments. Interestingly, the metaplasia induced by ozone exposures appears to be restricted to the nasal airways of these rodents. Ozone does not cause metaplasia in the epithelium lining the pulmonary airways of rats. In contrast, mucous cell metaplasia induced by endotoxin is restricted to the tracheobronchial epithelium. Endotoxin instillation does not cause mucous cell metaplasia in the NTE such as that observed in rats exposed to ozone. Using these two novel models of mucous cell metaplasia, we performed a series of studies to examine the effects of *a*) endotoxin instillation on ozone-induced mucous cell metaplasia and *b*) ozone exposure on endotoxin-induced mucous cell metaplasia. Our overall goal was to characterize morphometrically the potential interactions of ozone and endotoxin exposure on airway inflammatory and epithelial cell responses. Our specific aims were to test the hypotheses that endotoxin would enhance the epithelial and inflammatory responses induced by ozone in the NTE of rats and that ozone exposure would enhance the epithelial and inflammatory responses induced by endotoxin in pulmonary airways.

Protocols and Methodologic Approaches for Assessing Mucous Cell Metaplasia

Below are descriptions of the standard methods and procedures we follow to induce mucous cell metaplasia in the airways of laboratory animals, and the morphometric, histochemical, and molecular approaches we used to assess metaplasia lesion in rat airways.

Animals. Male F344/N (Harlan Sprague-Dawley, Indianapolis, IN, USA) rats 10–12 weeks of age were used in all studies. Rats were free of specific pathogens and respiratory disease and used in accordance with guidelines set forth by the All-University Committee on Animal Use and Care at Michigan State University.

Ozone exposures. Rats were exposed to filtered air (controls) or 0.5 ppm ozone for 3 days, 8 hr/day. At this concentration (0.5 ppm), ozone produces epithelial lesions in NTE of F344/N rats by 4 days after exposure, with little or no effect on adjacent nasal respiratory epithelium (51). The methods of ozone generation and monitoring of air concentrations have been previously described in detail (50,52).

Endotoxin instillations. To induce mucous cell metaplasia in pulmonary airways, rats are first anesthetized with 4% halothane in oxygen and 50 mL endotoxin (lipopolysaccharide from *P. aeruginosa*) in pyrogen-free saline is instilled into each nasal passage (total doses of 0 or 20 mg). A second instillation was given 24 hr later. This dosing regimen induces a dose-dependent mucous cell metaplasia in the distal axial airways of the lung 48 hr after the second endotoxin instillation.

Neutrophil depletion. We determined the role of neutrophilic inflammation in our animal models by using a rabbit anti-rat PMN antiserum. Treatment with this antiserum is known to deplete circulating blood neutrophils below 1% of normal levels by 12 hr, and depletion persists for up to 5 days (53). Anesthetized animals were injected intraperitoneally with either 1 mL of antiserum or normal rabbit serum (control serum). Depending on the study design, animals were depleted of circulating neutrophils before inhalation exposure to ozone, or in endotoxin studies, before intranasal instillations.

Necropsy and tissue preparation. Rats were sacrificed and complete necropsies performed. The procedures for collection of nasal and pulmonary tissues have been previously reported in detail (38,50). Briefly, the trachea and lungs were excised intact and intratracheally perfused with zinc formalin fixative for 2 hr. The head of each rat was removed from the carcass, and the lower jaw and skin were removed. The skull was split in a sagittal plane adjacent to the midline and one-half of the head was immersed in zinc-formalin for at

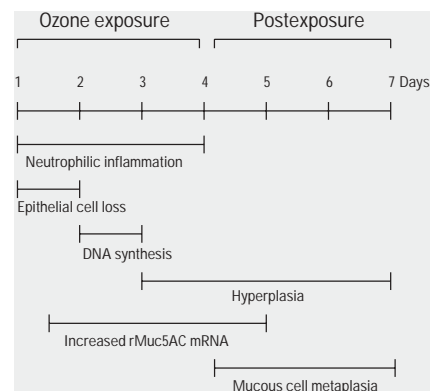


Figure 1. Temporal sequence of inflammatory and epithelial cell responses in the rat nasal mucosa after 4 days of ozone exposure (0.5 ppm, 8 hr/day).

least 48 hr. After fixation this half of the head was decalcified in 13% formic acid. A tissue block was removed from the anterior nasal cavity by making two cuts perpendicular to the hard palate: *a*) immediately posterior to the upper incisors and *b*) at the level of the incisive papilla. This procedure results in a proximal section of the nasal cavity containing the proximal nasal septum, which consists of respiratory epithelium, and the maxilloturbinate, which are lined with NTE. The tissue blocks were then embedded in paraffin and 5- to 6-mm thick sections were cut from the anterior surface. Nasal sections were then stained with hematoxylin and eosin (H&E) for routine histology or with Alcian blue (pH 2.5)/periodic acid-Schiff (AB/PAS) to detect intraepithelial mucosubstances. The maxilloturbinate from the other half of the head was removed by microdissection and homogenized in TriReagent (Sigma Chemical Co., St. Louis, MO, USA) and kept at -80°C until further processing for RNA isolation.

After fixation the left lung lobe was microdissected along the axial airways, and two sections were then excised at the level of the fifth and eleventh airway generation, as we have described previously in detail (38).

Morphometry of stored intraepithelial mucosubstances. To estimate the amount of the intraepithelial mucosubstances in NTE lining maxilloturbinate and the respiratory epithelium lining the axial pulmonary airways, the volume density of AB/PAS-stained mucosubstances was quantified using computerized image analysis and standard morphometric techniques. The area of AB/PAS-stained mucosubstance was calculated from the automatically circumscribed perimeter of stained material using a personal computer and the public domain U.S. National Institutes of Health Image program (54). The length of the basal lamina underlying the surface epithelium was calculated from the contour length of the digitized

image of the basal lamina. The volume of stored mucosubstances per unit of surface area of epithelial basal lamina was estimated using the method described in detail by Harkema et al. (46) and is expressed as nanoliters of intraepithelial mucosubstances per square millimeter of basal lamina (i.e., volume density).

Morphometry of cell densities. Neutrophil influx within the NTE of maxilloturbinates was determined in H&E-stained sections by counting the total number of neutrophils within the nasal mucosa (area between the turbinate bone and airway lumen) and dividing by the total length of the basal lamina. Mucous cells with the epithelial layer were counted and expressed as the total number of AB/PAS-staining cells per millimeter basal lamina.

Mucin gene expression. Total RNA was isolated from microdissected and homogenized maxilloturbinates and pulmonary axial airways by following the method of Chomczynski and co-workers (55,56). Steady-state levels of rat mucin 5AC (rMuc5AC) mRNA were then determined in RNA samples using a quantitative reverse transcriptase-polymerase chain reaction (RT-PCR) technique. This method employs a recombinant competitor RNA (rcRNA), used as an internal standard (IS), that is reverse transcribed and amplified in the same tubes as the target sequence (rMuc-5AC). The IS rcRNA was synthesized as described previously (57). RT-PCR for rMuc-5AC was performed as outlined by Gilliland and co-workers (58,59), except that known amounts of the IS rcRNA are reverse-transcribed into complementary DNA. For each RNA sample a known concentration of IS rcRNA molecules was added that is similar in concentration to the RNA samples. The density ratio of the rMuc-5AC PCR product band to the corresponding IS PCR product band present in each sample was determined as described by Gilliland and colleagues (58,59). We report our data as the number of rMuc-5AC mRNA molecules per nanogram of total sample RNA that was added to the RT-PCR reaction.

Statistical analysis. Data are expressed as mean \pm standard error of the mean (SEM) and were analyzed by using a completely randomized analysis of variance. Multiple comparisons were made by Student-Newman-Keuls post hoc test. Criterion for significance was taken to be $p < 0.05$.

Neutrophil Depletion of Ozone-Exposed Animals

As mentioned earlier, exposure of humans to ozone causes neutrophil influx into nasal airways (8,9). Although epithelial lesions have not been characterized during human ozone inhalation studies, inflammatory responses

and nasal epithelial alterations similar to those induced in ozone-exposed rats are common in people living in areas with high ambient ozone concentrations (60,61). We recently performed studies to determine the role of neutrophilic inflammation on the development of ozone-induced mucous cell metaplasia in rats exposed to ozone (0.5 ppm, 8 hr/day) for 3 consecutive days. We depleted animals of circulating neutrophils with a rat-specific neutrophil antibody to assess the ozone-induced epithelial alterations in the absence of neutrophilic inflammation. Circulating neutrophils were approximately 1% of normal levels throughout the ozone exposure, and nasal lesions were examined 2 hr or 4 days after the last ozone exposure.

Ozone exposure of rats caused the infiltration of neutrophils into the NTE and underlying lamina propria that cover the proximal aspects of the maxilloturbinates. The significant increase in mucosal neutrophils present 2 hr after the last ozone exposure in neutrophil-sufficient rats was attenuated in neutrophil-depleted rats (Figure 2A). We estimated the degree of mucous cell metaplasia by counting the number of mucous cells in the NTE overlying maxilloturbinates (Figure 2B) and by measuring the volume density of intraepithelial mucosubstances in nasal sections stained with AB/PAS, which indicates the presence of acidic and neutral mucosubstances (Figure 2C). Four days after the last ozone exposure, the number of mucous cells and volume density of intraepithelial mucosubstances was

significantly increased in rats exposed to ozone. In neutrophil-depleted animals, metaplastic responses were only 40% of those observed in ozone-exposed rats. Overexpression of the mucin gene encoding for rMuc-5AC occurred during the first day of ozone exposure and stayed elevated during the postexposure period (50). In rats depleted of circulating neutrophils, ozone-induced overexpression of rMuc-5AC was similar to that measured in neutrophil-sufficient animals (Figure 2D).

These findings suggest that ozone-induced mucous cell metaplasia is in part neutrophil dependent, whereas the increase in mucin-specific mRNA is independent of the ozone-induced neutrophil influx into nasal tissues. These results are consistent with those of our previous work in which ozone-induced mucous cell metaplasia in the NTE of rats was attenuated by treatment with a topical steroid (62). In that study, neutrophilic inflammation was markedly decreased in steroid-treated animals. Because the effects of steroids are broad and affect several cell types other than neutrophils, including possibly epithelial cells, it was unclear from those studies if inhibition of metaplastic responses was due to the steroid-induced blockade of neutrophilic influx. Thus, our studies using neutrophil-depleting antibodies provides stronger evidence that neutrophils specifically play a critical role in ozone-induced mucous cell metaplasia in rat nasal epithelium.

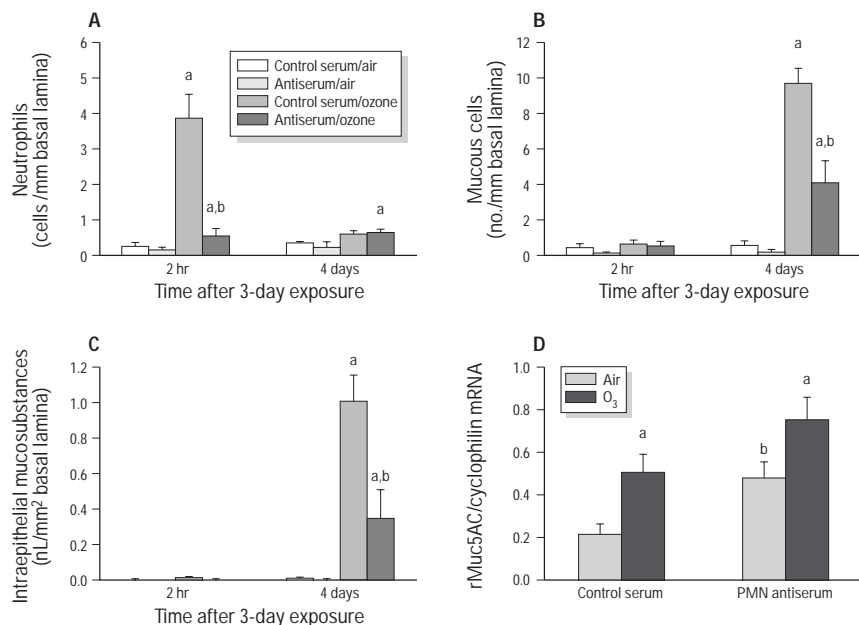


Figure 2. Effect of neutrophil-depletion on ozone-induced neutrophilic inflammation (A), mucous cell numbers (B), intraepithelial mucosubstances (C), and mucin gene expression (D) in rat maxilloturbinates. Bars represent group mean \pm SEM ($n = 6$ animals/group). ^aSignificantly different from respective group exposed to air. ^bSignificantly different from respective group given control serum.

Endotoxin Enhancement of Ozone-Induced Mucous Cell Metaplasia

The acute inflammation caused by endotoxin in both upper and lower airways of laboratory animals is well documented. A robust migration of neutrophils is an early response elicited by instilled and aerosolized endotoxin, and the oxidant and proteolytic potential of activated neutrophils have been implicated in epithelial cell alterations in endotoxin-treated airways (63,64). Furthermore, we have used endotoxin-instilled animals to document epithelial cell changes such as hyperplasia and metaplasia in the respiratory epithelium, which normally consists of some secretory cells (36,37). As mentioned previously, endotoxin does not cause mucous cell metaplasia in rat NTE.

Because airway endotoxin elicits a significant infiltration of neutrophils into airways, we exposed rats to both ozone and endotoxin to determine the effects of augmented neutrophilic inflammation on the pathogenesis of ozone-induced mucous cell metaplasia that occurs in the NTE and the pathotoxicologic interaction of two common air pollutants on the development of nasal epithelial cell alterations. In these studies rats were first exposed to ozone for 3 consecutive days; some animals were then instilled intranasally with endotoxin (100 mg) for 2 more days after ozone exposures (52). We evaluated epithelial and inflammatory responses at both 6 hr and 3 days after the last endotoxin instillation.

Endotoxin instillation caused a significant neutrophilic inflammation in the mucosa underlying the NTE in both ozone and air-exposed animals 6 hr after instillations (Figure 3A). By 3 days postinstillation the ozone-induced increases in stored mucosubstances were increased 5-fold when animals were also exposed to endotoxin (Figure 3B). Despite increasing tissue neutrophils in air-exposed animals, endotoxin treatment alone did not cause any metaplastic lesions in the NTE. These results suggest that neutrophilic inflammation alone is not sufficient to produce metaplasia and that additional components (e.g., ozone exposure, neutrophil activation) are necessary for mucous cell metaplasia to develop in the NTE.

Neutrophil Depletion and Endotoxin/Ozone Coexposure

To determine the role of neutrophilic inflammation in the potentiation by endotoxin of ozone-induced mucous cell metaplasia, we depleted rats of circulating neutrophils after ozone exposures but during the time of endotoxin-induced inflammation. Neutrophilic inflammation elicited by endotoxin instillation was completely inhibited in neutrophil-depleted rats (Figure 4A). Moreover, the augmentation by endotoxin of ozone-induced increases in stored mucosubstances in the

NTE was blocked completely in neutrophil-depleted rats (Figure 4B). Thus, endotoxin-induced neutrophilic inflammation is required for endotoxin-induced enhancement of ozone-initiated metaplastic responses. However, neutrophils do not appear to be involved in the endotoxin-induced overexpression of mucin mRNA in ozone-exposed animals. Overexpression of rMuc5AC after endotoxin instillation was similar in both neutrophil-sufficient and neutrophil-deficient rats exposed to ozone (Figure 4C). We interpreted these results to mean that neutrophils mediate metaplastic responses by a mechanism other than just turning on the mucin gene. These results are reminiscent of the results of neutrophil depletion studies of ozone-induced mucous cell metaplasia described above, where mucin gene overexpression caused by ozone exposure was unaffected by neutrophil depletion (65).

Ozone Enhancement of Endotoxin-Induced Mucous Cell Metaplasia

In 1992 we demonstrated that intranasal instillation of endotoxin causes significant alterations in the mucous apparatus lining axial pulmonary airways of rats (37). Specifically, increases in stored mucosubstances, secretory cell hyperplasia, and secretory cell metaplasia occurred in the respiratory epithelium of airways that normally consist of ciliated and secretory cells. This is in contrast to ozone-induced mucous cell metaplasia that occurs in the NTE that

contains no secretory cells. Furthermore, unlike endotoxin, ozone exposure has no effect on the mucous apparatus in axial pulmonary airways of rats.

To test the effects of ozone exposure on endotoxin-induced mucous cell metaplasia, we treated rats with intranasal endotoxin for 2 consecutive days, postexposed rats to ozone (1 ppm, 8 hr/day) for 2 days, and then morphometrically estimated the number of inflammatory cells and amount of secreted mucus in the lavage fluid and characterized epithelial lesions on the fifth day. Endotoxin caused an increase in the number of neutrophils recovered in lavage fluid that was further increased after exposure to ozone (Figure 5A). Instillation of endotoxin also induced hypersecretion of mucus into airways compared with saline instillation (Figure 5B). Ozone alone did not cause mucus hypersecretion, but the combination of ozone exposure with endotoxin enhanced the endotoxin-induced

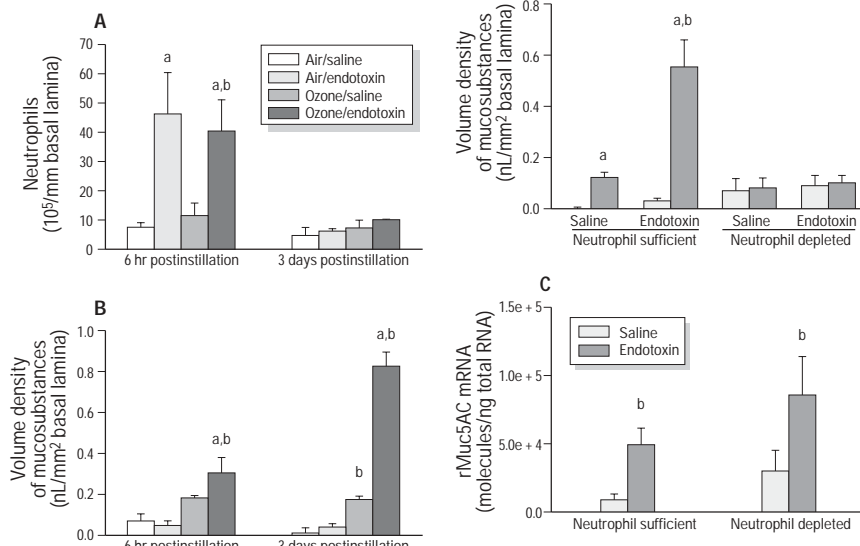


Figure 3. Effect of intranasal endotoxin instillation on ozone-induced neutrophilic inflammation (A) and intraepithelial mucosubstances (B) in rat maxilloturbinate. Bars represent group mean \pm SEM ($n = 6$ animals/group). ^aSignificantly different from respective group exposed to air. ^bSignificantly different from respective group given intranasal saline.

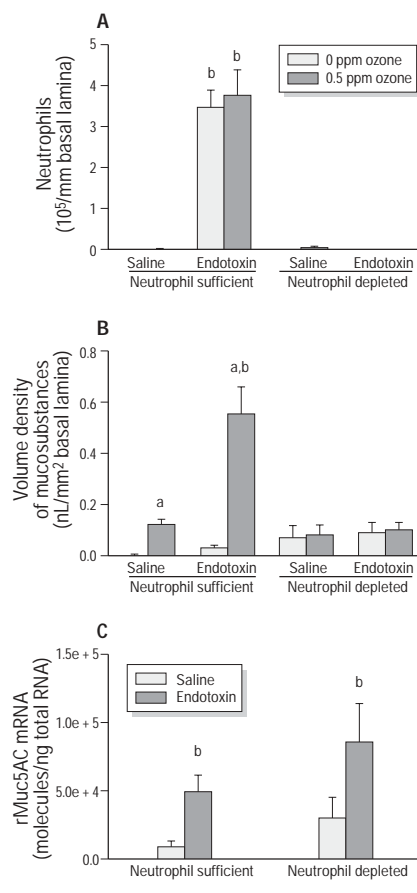


Figure 4. Effect of neutrophil depletion on ozone/endotoxin-induced changes in neutrophilic inflammation (A), intraepithelial mucosubstances (B), and mucin gene expression (C) in rat maxilloturbinate. Bars represent group mean \pm SEM ($n = 6$ animals/group). ^aSignificantly different from respective group exposed to air. ^bSignificantly different from respective group given intranasal saline.

secretion of mucin protein (Muc5AC) in airway fluid. Lastly, endotoxin caused an increase in the amounts of stored intraepithelial mucosubstances in axial airways; these amounts were further increased in rats subsequently exposed to ozone (Figure 5C). Thus, ozone exposure enhances both the secretion and storage of mucin glycoprotein induced by endotoxin instillation.

We have previously shown that endotoxin-induced mucous cell metaplasia in the pulmonary airways is partially dependent on neutrophils (66). Thus, ozone may augment the metaplasia initiated by endotoxin by increasing the neutrophilic inflammation, as suggested by the increase in lavage neutrophils. In the future, neutrophil-depleted rats will be coexposed to ozone and endotoxin to test this hypothesis.

Neutrophils, Inflammatory Mediators, and Mucous Cell Metaplasia

Based on our experimental results, it is clear that ozone and endotoxin elicit mucous cell metaplasia in different locations in the

respiratory tract (Figure 6). Interestingly, each toxicant acts to enhance the metaplastic lesions induced by the other toxicant. Specifically, endotoxin enhances ozone-induced metaplasia in the NTE but does not itself cause metaplasia in the NTE. Conversely, ozone does not cause metaplasia in the respiratory epithelium in pulmonary airways, but it does augment endotoxin-induced mucous cell metaplasia in that tissue. This unique, reciprocal potentiation of epithelial cell alterations by ozone and endotoxin extends the toxicologic profile of each agent beyond what is described in studies where each toxicant is used by itself. As such, regulatory standards derived primarily from studies that employ a single pollutant may underestimate the risk of adverse health effects when more than one co-pollutant is present. It is likely that both ozone and endotoxin will exacerbate the respiratory responses to other inhaled criteria air pollutants and biogenic substances.

Our results clearly implicate neutrophils in the development of mucous cell metaplasia in both the respiratory epithelium of pulmonary airways and in the NTE lining the proximal nasal airways. Importantly, our results suggest that neutrophils are not entirely responsible for metaplasia initiated by either ozone in the NTE (only a 60% reduction in metaplasia in neutrophil-depleted animals) (65), or by endotoxin in the respiratory epithelium (only 50% reduction in metaplasia in neutrophil-depleted animals) (66). These results suggest that ozone or endotoxin may be having direct effects on epithelial cells, or that other inflammatory mediators (cellular or soluble) account for the remainder of the metaplastic response. We recently used an *in vitro* tissue culture system to show that endotoxin, in the absence of neutrophils,

increases mucin gene expression in preexisting secretory cells (57). This result is consistent with our *in vivo* findings of both ozone- and endotoxin-induced mucous cell metaplasia, which indicate that neutrophils are required for some (increased storage of mucosubstances) but not all (hyperplasia and mucin gene overexpression) events leading to the development of metaplastic lesions.

Whereas ozone- and endotoxin-induced mucous cell metaplasia is partially dependent on neutrophilic inflammation, endotoxin enhancement of ozone-induced metaplasia is blocked completely in neutrophil-depleted animals. This difference may be due to the type of epithelium where the metaplasia occurs. Potentiation by endotoxin of ozone-induced metaplasia occurs in the NTE, whereas mucous cell metaplasia elicited by endotoxin treatment alone occurs in preexisting secretory cells of the respiratory epithelium. We have yet to examine the contribution made by neutrophilic inflammation to ozone enhancement of endotoxin-induced metaplasia in respiratory epithelium. It may be that the potentiation pathways elicited by both toxicants are entirely mediated by neutrophils.

It is interesting that in all our studies where neutrophil depletion inhibited mucous cell metaplasia, the mucin gene overexpression normally associated with metaplasia was unaffected. Thus, the upregulation of mucin mRNA alone is insufficient for the full phenotypic development of mucous cell metaplasia induced by ozone or endotoxin. The protein product of mucin gene translation undergoes considerable modification by glycosyltransferases, which catalyze the addition of fucose and sialic acid among other saccharide groups, and sulfotransferases, which add sulfur-containing groups, to the core mucin apoprotein. It is these sugar groups and

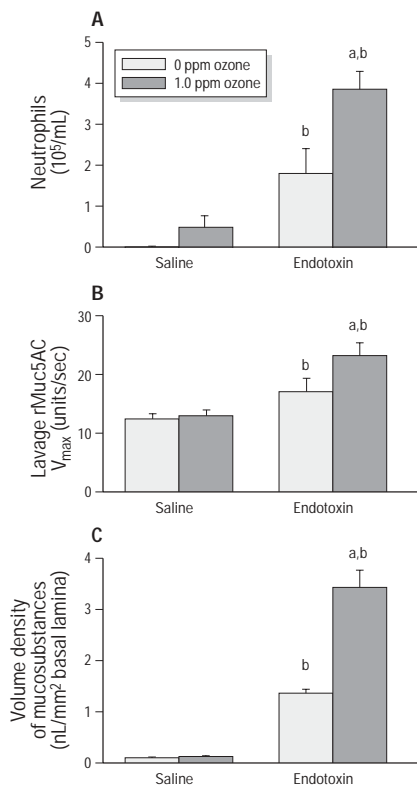


Figure 5. Effect of ozone inhalation on endotoxin-induced increase in lavaged neutrophils (A) mucus hypersecretion (B), and increase in intraepithelial mucosubstances (C) in pulmonary airways. Bars represent group mean \pm SEM ($n = 6$ animals/group). ^aSignificantly different from respective group exposed to air. ^bSignificantly different from respective group given intranasal saline.

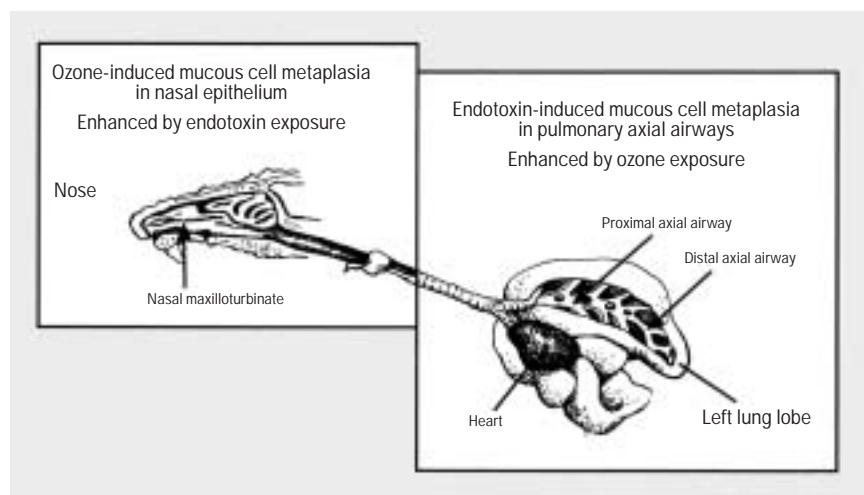


Figure 6. The unique, reciprocal potentiation by ozone and endotoxin of mucous cell metaplasia in the NTE of the upper airways and respiratory epithelium in pulmonary conducting airways.

sulfated residues within mucous cell globules that react histochemically with AB/PAS stains and are used to quantitate intraepithelial mucosubstances. Thus, unmodified, nonglycosylated, and nonsulfated mucin apoprotein may be present in epithelial cells, but it is undetected by AB/PAS staining because it lacks reactive groups. One interpretation of these results is that neutrophils mediate the pathways responsible for the glycosylation and sulfation of mucin proteins. In the absence of neutrophils, the signals to modify the core mucin protein by glycosylation might not be present. Alternatively, mucin protein may not be translated despite the transcription of mucin genes. Either possibility requires further study.

Neutrophils are primary sources of inflammatory mediators. Proteases derived by neutrophils (e.g., cathepsins, elastase) are well-known mucous secretagogues in airway epithelial cells (67,68). Intraairway instillation of neutrophil elastase induces mucous cell metaplasia in hamster airways (67,69). Elastase inhibitors can prevent mucous cell metaplasia induced by neutrophil elastase (70) and mucus hypersecretion caused by ozone (71). Furthermore, elastase has been shown to increase mucin-specific mRNA and protein expression in cultured human airway cells (44). It is unclear how neutrophil-derived proteases induce mucus secretion and mucin gene expression in epithelial cells. Elastase binds to an extracellular site on bronchial epithelium prior to initiating metaplasia in hamster airways (72). Elastase and cathepsin G may promote cellular responses by cleaving and thereby activating a protease-activated receptor (PAR) on airway epithelial cells (73). In this regard, mucus secretion has been shown to be triggered by activation of a membrane-bound PAR in the rat sublingual gland (74). It is possible that PAR activation on airway epithelial cells may promote pathways that lead to the expression of mucin and glycosyltransferase genes.

In addition to proteases, neutrophils can release other inflammatory mediators, including TNF, platelet activating factor, and IL-1 and IL-6, that can induce mucus secretion and/or mucin gene upregulation in airway epithelial cells (43,75,76). It should be noted that these mediators can be produced by other inflammatory cells (i.e., monocytic cells) as well as by activated epithelial cells. A common effector pathway of proteases and inflammatory mediators to induce metaplasia in airway epithelial cells may be the epidermal growth factor receptor (EGFR) system. EGF is an important growth factor for the development of neonatal lungs and is often expressed during repair processes in adult lung (77,78). Airway instillation of EGFR ligands into rat airways can lead to the development of

mucous cell metaplasia, but only after EGFR expression is induced on airway epithelium by prior treatment with TNF- α (79). Exposure of humans to ozone causes expression of EGFR and production of EGFR ligands in the nasal mucosa, suggesting a similar process of activation may occur during ozone-induced mucous cell metaplasia that we observe in the rat NTE (80). We have addressed the role of the EGFR system in the development of mucous cell metaplasia by using a novel in vitro system of cultured nasal explants (81). In these studies neutrophil-derived products enhanced the increase in intraepithelial mucosubstances in respiratory epithelium initiated by treatment of cultures with endotoxin. When treated with kinase inhibitors that block pathways of EGFR signal transduction, we observed an attenuation of the metaplastic response elicited by the neutrophil-derived products. Other recent studies have implicated the EGFR system in mucous cell metaplasia in models of allergic airway disease (82) and in response to cigarette smoke (83). We are presently performing studies to further elucidate the role of the EGFR system in the neutrophil-mediated and toxicant-induced mucous cell metaplasia in nasal and pulmonary airways.

Clearly, further studies are needed to clarify the mechanisms by which ozone and endotoxin, which target different airway epithelium, enhance the metaplastic response of each other. Although some of the potential factors involved in mucous cell metaplasia, such as the EGFR system, proteases, and mucin and transferase gene induction, have been suggested by results from other studies, the complete pathway and processes are unresolved. If the development of mucous cell metaplasia is a multicomponent process, then endotoxin and ozone engender all the required components in the respiratory epithelium and nasal transitional epithelium, respectively. Our results show that endotoxin by itself does not cause, but can enhance, mucous cell metaplasia in the NTE caused by ozone exposure. Therefore, endotoxin must enhance at least one, and maybe all, of the necessary components in the development of mucous cell metaplasia in NTE. Likewise, ozone may enhance one or all of the steps in the development of mucous cell metaplasia in the respiratory epithelium. Discerning the specific points in the metaplastic process targeted by each toxicant in each epithelium type is the focus of ongoing research in our laboratory.

Taken together, our results illustrate a unique interaction between two airborne toxicants to alter airway epithelium that would not have been predicted from the known toxicologic profile of either pollutant given alone. The importance of these findings is

2-fold. First, they provide a biologic rationale from which to better evaluate the risk of coexposure to ozone and endotoxin. In addition, our results with ozone and endotoxin might be extended to predict the potential airway responses to exposures to other oxidant gases and biogenic substances. Second, the mechanism of toxicity in this model of mucous cell metaplasia implicates a major role for neutrophilic inflammation. Therapeutic approaches that target neutrophils, their recruitment, or their products (i.e., proteases) may protect from toxicant-induced alterations in the airway mucous apparatus. Increased research efforts are needed to clarify the true risk of exposures to multiple airborne pollutants and to determine the most effective interventions to prevent or reverse the overproduction and hypersecretion of mucus in human airways.

REFERENCES AND NOTES

1. U.S. EPA. National Air Quality and Emissions Trends Report, 1998. EPA 454/R-00-003. Washington, DC:U.S. Environmental Protection Agency, 2000.
2. Breslin K. EPA: airing on the side of caution or pulling standards out of thin air? *Environ Health Perspect* 108:A176-A177 (2000).
3. Whitman, Administrator of the Environmental Protection Agency et al., v. American Trucking Associations Inc. et al. Case No 99-1257. U.S. Supreme Court, 2001.
4. Lippmann M, Schlessinger RB. Toxicological bases for the setting of health-related air pollution standards. *Annu Rev Public Health* 21:309-333 (2000).
5. Calderon-Garciduenas L, Osorno Velazquez A, Bravo Alvarez H, Delgado Chavez R, Barrios Marquez R. Histopathologic changes of the nasal mucosa in southwest metropolitan Mexico City inhabitants. *Am J Pathol* 140:225-232 (1992).
6. Hiltermann TJN, Peters EA, Alberst B, Kwikkers K, Borggreven PA, Hiemstra PS, Dijkman JH, van Bree LA, Stolk J. Ozone-induced airway hyperresponsiveness in patients with asthma: role of neutrophil-derived serine proteases. *Free Radic Biol Med* 24:952-958 (1998).
7. Vagaggini B, Carnevali S, Macchioni P, Taccola M, Fornai E, Bacci E, Bartoli ML, Cianchetti S, Dente FL, Di Franco A, et al. Airway inflammatory responses to ozone in subjects with different asthma severity. *Eur Respir J* 13:274-280 (1999).
8. Graham DE, Koren HS. Biomarkers of inflammation in ozone-exposed humans. Comparison of the nasal and bronchoalveolar lavage. *Am Rev Respir Dis* 142:152-156 (1990).
9. Hiltermann TJN, de Bruijne CR, Solk J, Zwinderman AH, Speikma FTM, Roemer W, Steerenberg PA, Fischer PH, van Bree L, Hiemstra PS. Effects of photochemical air pollution and allergen exposure on upper respiratory tract inflammation in asthmatics. *Am J Respir Crit Care Med* 156:1765-1772 (1997).
10. Frischer TM, Kuehr J, Pullwitt A, Meinert R, Forster J, Studnicka M, Koren H. Ambient ozone causes upper airway inflammation in children. *Am Rev Respir Dis* 148:961-964 (1993).
11. Cody RP, Weisel CP, Birnbaum G, Lioy PJ. The effect of ozone associated with summertime photochemical smog on the frequency of asthma visits to hospital emergency departments. *Environ Res* 58:184-195 (1992).
12. Thurston GD, Ito K, Kinney PL, Lippmann M. A multi-year study of air pollution and respiratory hospital admissions in three New York State metropolitan areas: results for 1988 and 1989 summers. *J Expos Anal Environ Epidemiol* 2:429-450 (1992).
13. Stieb DM, Burnett RT, Beveridge RC, Brook JR. The association between ozone and asthma emergency department visits in Saint John, New Brunswick, Canada. *Environ Health Perspect* 104:1354-1360 (1996).
14. Fauroux B, Sampli M, Quenel P, Lemoulec Y. Ozone: a trigger for hospital pediatric asthma emergency room visits. *Pediatr Pulmonol* 30:41-46 (2000).
15. Farman CA, Watkins K, van Hoozen B, Last JA, Witschi H, Pinkerton KE. Centriacinar remodeling and sustained procollagen gene expression after exposure to ozone and nitrogen dioxide. *Am J Respir Cell Mol Biol* 20:303-311 (1999).

16. Last JA, Pinkerton KE. Chronic exposure of rats to ozone and sulfuric acid aerosol: biochemical and structural responses. *Toxicology* 116:133–136 (1997).
17. el Fawal HA, McGovern T, Schlesinger RB. Nonspecific bronchial responsiveness assessed in vitro following acute inhalation exposure to ozone and ozone/sulfuric acid mixtures. *Exp Lung Res* 21:129–139 (1995).
18. Gold DR, Damokosh AI, Pope CA III, Dockery DW, McDonnell WF, Serrano P, Retama A, Castillejos M. Particulate and ozone pollutant effects on the respiratory function of children in southwest Mexico City. *Epidemiology* 10:8–16 (1999).
19. Sheppard L, Levy D, Norris G, Larson TV, Koenig JQ. Effects of ambient air pollution on nonelderly asthma hospital admissions in Seattle, Washington, 1987–1994. *Epidemiology* 10:23–30.
20. Wong TW, Lau TS, Yu TS, Neller A, Wong SL, Tam W, Pang SW. Air pollution and hospital admissions for respiratory and cardiovascular diseases in Hong Kong. *Occup Environ Med* 56:679–683 (1999).
21. Linn WS, Szlachetka Y, Gong H Jr, Kinney PL, Berhane KT. Air pollution and daily hospital admissions in metropolitan Los Angeles. *Environ Health Perspect* 108:427–434 (2000).
22. Rylander R, Nordstrand A. Pulmonary cell reactions after exposure to cotton dust extract. *Br J Ind Med* 31:220–223 (1974).
23. Pernis B, Vigliani EC, Cavagna C, Finuli M. The role of bacterial endotoxins in occupational diseases caused by inhaling vegetable dusts. *Br J Ind Med* 18:120–129 (1961).
24. Salvaggio J, Bucchner HA, Seabury JA. Precipitins against extracts of crude bagasse in the serum of patients. *Ann Intern Med* 61:748–758 (1966).
25. Jarvholm B. Cutting oil mist and bronchitis. *Eur J Respir Dis Suppl* 118:79–83 (1982).
26. Jarvholm B, Bake B, Lavenius B, Thiringer G, Vokmann R. Respiratory symptoms and lung function in oil-mist-exposed workers. *J Occup Med* 24:473–479 (1982).
27. Oxhøj H, Andreassen H, Henrius UM. Respiratory symptoms and ventilatory lung function in machine shop workers exposed to cooler lubricants. *Eur J Respir Dis Suppl* 118:85–89 (1982).
28. Flaherty DK, Deck FH, Cooper J, Bishop K, Winzenburger PA, Smith LR, Bynum L, Wiltmer WB. Bacterial endotoxin isolated from a water spray air humidification system as a putative agent of occupation-related lung disease. *Infect Immun* 43:206–212 (1984).
29. Rylander R, Haglund P. Airborne endotoxin and humidifier disease. *Clin Allergy* 14:109–112 (1984).
30. Peterson RD, Wicklund PE, Good RA. Endotoxin activity in house-dust extracts. *J Allergy* 35:134–142 (1964).
31. Simpson JC, Niven RM, Pickering CA, Oldham LA, Fletcher AM, Francis HC. Comparative personal exposures to organic dusts and endotoxin. *Ann Occup Hyg* 43:107–115 (1999).
32. Wesselius LJ, Nelson ME, Bailey K, O'Brien-Ladner AR. Rapid lung cytokine accumulation and neutrophil recruitment after lipopolysaccharide inhalation by cigarette smokers and non-smokers. *J Lab Clin Med* 129:106–114 (1997).
33. Michel O, Nagy AM, Schroeven M, Duchateau J, Neve J, Fondou P, Sergysels R. Dose-response relationship to inhaled endotoxin in normal subjects. *Am J Respir Crit Care Med* 156:1157–1164 (1997).
34. Peden DB, Tucker K, Murphy P, Newlin-Clapp L, Boehlecke B, Hazucha M, Bromberg P, Reed W. Eosinophil influx to the nasal airway after local, low-level LPS challenge in humans. *J Allergy Clin Immunol* 104:388–394 (1999).
35. Eldridge MW, Peden DB. Allergen provocation augments endotoxin-induced nasal inflammation in subjects with atopic asthma. *J Allergy Clin Immunol* 105:475–481 (2000).
36. Harkema JR, Hotchkiss JA. In vivo effects of endotoxin on nasal epithelial mucosubstances: quantitative histochemistry. *Exp Lung Res* 17:743–761 (1991).
37. Harkema JR, Hotchkiss JA. In vivo effects of endotoxin on intraepithelial mucosubstances in rat pulmonary airways. Quantitative histochemistry. *Am J Pathol* 141:307–317 (1992).
38. Steiger D, Hotchkiss J, Bajaj L, Harkema J, Basbaum C. Concurrent increases in the storage and release of mucin-like molecules by rat airway epithelial cells in response to bacterial endotoxin. *Am J Respir Cell Mol Biol* 12:307–314 (1995).
39. Gordon T, Harkema JR. Effect of inhaled endotoxin on intraepithelial mucosubstances in F344 rat nasal and tracheobronchial airways. *Am J Respir Cell Mol Biol* 10:177–183 (1994).
40. Hanisch F-G, Muller S. MUC1: the polymorphic appearance of a human mucin. *Glycobiology* 10:439–449 (2000).
41. Wills-Karp M. Trophic slime, allergic slime. *Am J Respir Cell Mol Biol* 22:637–639 (2000).
42. Basbaum C, Lemjabbar H, Longphre M, Li D, Gensch E, McNamara N. Control of mucin transcription by diverse injury-induced signaling pathways. *Am J Respir Crit Care Med* 60:544–548 (1999).
43. Borchers MT, Carty MP, Leikauf GD. Regulation of human airway mucins by acrolein and inflammatory mediators. *Am J Physiol* 276:L549–L555 (1999).
44. Voynow JA, Young LR, Wang Y, Horger T, Rose MC, Fischer BM. Neutrophil elastase increases MUC5AC mRNA and protein expression in respiratory epithelial cells. *Am J Physiol* 276:L835–L843 (1999).
45. Harkema JR, Hotchkiss JA, Henderson RF. Effects of 0.12 and 0.8 ppm ozone on rat nasal and nasopharyngeal epithelial mucosubstances: quantitative histochemistry. *Toxicol Pathol* 17:525–535 (1989).
46. Harkema JR, Plopper CG, Hyde DM, St. George JA, Wilson DW, Dungworth DL. Response of the macaque nasal epithelium to ambient levels of ozone. A morphologic and morphometric study of the transitional and respiratory epithelium. *Am J Pathol* 128:29–44 (1987).
47. Harkema JR, Hotchkiss JA. Ozone-induced proliferative and metaplastic lesions in nasal transitional and respiratory epithelium: comparative pathology. *Inhal Toxicol* 6:187–204 (1994).
48. Hotchkiss JA, Harkema JR, Henderson RF. Effect of cumulative ozone exposure on ozone-induced nasal epithelial hyperplasia and secretory metaplasia in rats. *Exp Lung Res* 17:589–600 (1991).
49. Hotchkiss JA, Harkema JR, Johnson NF. Kinetics of nasal epithelial cell loss and proliferation in F344 rats following a single exposure to 0.5 ppm ozone. *Toxicol Appl Pharmacol* 143:75–82 (1997).
50. Cho HY, Hotchkiss JA, Harkema JR. Inflammatory and epithelial responses during development of ozone-induced mucous cell metaplasia in the nasal epithelium of rats. *Toxicol Sci* 51:135–145 (1999).
51. Harkema JR, Hotchkiss JA. Ozone- and endotoxin-induced mucous cell metaplasias in rat airway epithelium: novel animal models to study toxicant-induced epithelial transformations in airways. *Toxicol Lett* 68:251–263 (1993).
52. Fanucchi MV, Hotchkiss JA, Harkema JR. Endotoxin enhances ozone-induced mucous cell metaplasia in rat nasal epithelium. *Toxicol Appl Pharmacol* 152:1–9 (1998).
53. Snipes MB, Barnett AL, Harkema JR, Hotchkiss JA, ReBar AH, Reddick LJ. Specific biological effects of an anti-rat PMN antiserum intraperitoneally injected into F344/N rats. *Vet Clin Pathol* 24:11–17 (1995).
54. National Institutes of Health. NIH Image. Available: <http://rsb.info.nih.gov/nih-image> [cited 2 July 2001].
55. Chomczynski P, McKay K. Substitution of chloroform by bromochloropropane in a single-step method of RNA isolation. *Anal Biochem* 225:163–164 (1995).
56. Chomczynski P, Sacchi N. Single-step methods of RNA isolation by acid guanidinium thiocyanate-phenol-chloroform extraction. *Anal Biochem* 162:156–159 (1987).
57. Fanucchi MV, Harkema JR, Plopper CG, Hotchkiss JA. In vitro culture of microdissected rat nasal airway tissues. *Am J Respir Cell Mol Biol* 20:1274–1285 (1999).
58. Gilliland GS, Perrin K, Blanchard K, Bunn HF. Analysis of cytokine mRNA and DNA: detection and quantitation by competitive polymerase chain reaction. *Proc Natl Acad Sci U S A* 87:2725–2729 (1990).
59. Gilliland GS, Perrin K, Blanchard K, Bunn HF. Competitive PCR for quantitation of mRNA. In: *PCR Protocols: A Guide to Methods and Applications* (Innes M, Gelfand DH, Sninsky JJ, White T, eds). San Diego, CA: Academic Press, 1990:60–66.
60. Calderon-Garciduenas L, Rodriguez-Alcaraz A, Garcia R, Sanchez G, Barragan G, Camacho R, Ramirez L. Human nasal mucosal changes after exposure to urban air pollution. *Environ Health Perspect* 102:1074–1080 (1994).
61. Calderon-Garciduenas L, Rodriguez-Alcaraz A, Garcia R, Ramirez L, Barragan G. Nasal inflammatory responses in children exposed to polluted urban atmosphere. *J Toxicol Environ Health* 45:427–437 (1995).
62. Hotchkiss JA, Hilaski R, Cho H, Regan K, Spencer P, Slack K, Harkema JR. Fluticasone propionate attenuates ozone-induced rhinitis and mucous cell metaplasia in rat nasal airway epithelium. *Am J Respir Cell Mol Biol* 18:91–99 (1998).
63. Davreux CJ, Soric I, Nathens AB, Watson RW, McGilvray ID, Sutures ZE, Shek PN, Rotstein OD. N-Acetyl cysteine attenuates acute lung injury in the rat. *Shock* 8:432–438 (1997).
64. Kawabata K, Hagio T, Matsumoto S, Nakao S, Orita S, Aze Y, Ohno H. Delayed neutrophil elastase inhibition prevents subsequent progression of acute lung injury induced by endotoxin inhalation in hamsters. *Am J Respir Crit Care Med* 161:2013–2018 (2000).
65. Cho HY, Hotchkiss JA, Bennett CB, Harkema JR. Neutrophil-dependent and neutrophil-independent alterations in the nasal epithelium of ozone-exposed rats. *Am J Respir Crit Care Med* 162:629–636 (2000).
66. Hotchkiss JA, Harkema JR. Effect of neutrophil depletion on endotoxin-induced mucous cell metaplasia in pulmonary airways of F344 rat. *Am J Respir Crit Care Med* 149:A994 (1994).
67. Breuer R, Christensen TG, Lucey EC, Stone PJ, Snider GL. Elastase causes secretory discharge in bronchi of hamsters with elastase-induced secretory cell metaplasia. *Exp Lung Res* 19:273–282 (1993).
68. Takeyama K, Agusti C, Ueki I, Lausier J, Cardell LO, Nadel JA. Neutrophil-dependent goblet cell degranulation: role of membrane-bound elastase and adhesion molecules. *Am J Physiol* 275:L294–L302 (1998).
69. Jamil S, Breuer R, Christensen TG. Abnormal mucous cell phenotype induced by neutrophil elastase in hamster bronchi. *Exp Lung Res* 23:285–295 (1997).
70. Breuer R, Christensen TG, Lucey EC, Bolbochan G, Stone PJ, Snider GL. Quantitative study of secretory cell metaplasia induced by human neutrophil elastase in the large bronchi of hamsters. *J Lab Clin Med* 105:635–640 (1985).
71. Nogami H, Aizawa H, Matsumoto K, Nakano H, Koto H, Miyazaki H, Hirose T, Nishima S, Hara N. Neutrophil elastase inhibitor, ONO-5046 suppresses ozone-induced airway mucus hypersecretion in guinea pigs. *Eur J Pharmacol* 390:197–202 (2000).
72. Christensen TG, Alonso PA. Immunocytochemical evidence for extra-cellular initiation of elastase-induced bronchial secretory cell metaplasia in hamsters. *Eur J Respir* 9:535–541 (1996).
73. Matthews JL, Shaw RJ, Bunce KT. Effects of elastase on bronchial epithelial cells may involve activation of protease activated receptors [Abstract]. *Am J Respir Crit Care Med* 159:A448 (1999).
74. Kawabata A, Morimoto N, Nishikawa H, Kuroda R, Oda Y, Kakehi K. Activation of protease-activated receptor-2 (PAR-2) triggers mucin secretion in the rat sublingual gland. *Biochem Biophys Res Commun* 270:298–302 (2000).
75. Lou YP, Takeyama K, Grattan KM, Lausier JA, Ueki IF, Agusti C, Nadel JA. Platelet-activating factor induced goblet cell hyperplasia and mucin gene expression in airways. *Am J Respir Crit Care Med* 157:1927–1934 (1998).
76. Levine SJ, Larivee P, Logun C, Shelhamer JH. IL-6 induces respiratory mucous glycoprotein secretion and MUC-2 gene expression by human airway epithelial cells [Abstract]. *Am J Respir Crit Care Med* 149:A27 (1994).
77. Holgate ST. Epithelial damage and response. *Clin Exp Allergy* 30:37–41 (2000).
78. Fisher DA, Lakshmanan J. Metabolism and effects of epidermal growth factor and related growth factors in mammals. *Endocr Rev* 11:418–442 (2000).
79. Takeyama K, Dabbagh K, Lee HM, Agusti C, Lausier J, Ueki I, Grattan KM, Nadel JA. Epidermal growth factor system regulates mucin production in airways. *Proc Natl Acad Sci U S A* 96:3081–3086 (1999).
80. Polosa R, Krishna MT, Holgate ST, Howarth HP, Frew AJ, Davies DE. Effect of ozone exposure on EGFR, EGF, TGF α expression in human bronchial and nasal epithelium [Abstract]. *Am J Respir Crit Care Med* 159:A493 (1999).
81. Hotchkiss JA, Farrar AK, Harkema JR. The epidermal growth factor receptor system mediates neutrophil-dependent mucous cell metaplasia induced by bacterial endotoxin [Abstract]. *Am J Respir Crit Care Med* 161:A778 (2000).
82. Shim JJ, Dabbagh K, Takeyama T, Dao-Pick T, Ueki IF, Nadel JA. The cytokine IL-13 induces mucin production by stimulating EGF receptors in rats [Abstract]. *Am J Respir Crit Care Med* 161:A245 (2000).
83. Takeyama K, Borge P-R, Shim JJ, Dao-Pick T, Ueki IF, Nadel JA. Cigarette smoke causes mucin synthesis in NCI-H292 cell via transactivation of epidermal growth factor receptors [Abstract]. *Am J Respir Crit Care Med* 161:A156 (2000).