

Proliferative Lesions in the Male Reproductive System of F344 Rats and B6C3F1 Mice: Incidence and Classification

by Kunitoshi Mitsumori* and Michael R. Elwell*

The incidences of all primary neoplasms in the testes and accessory reproductive organs of 51,230 male Fischer 344 (F344) rats and 46,752 male B6C3F1 mice were obtained from the pathology data base of more than 300 long-term toxicity/carcinogenicity studies performed for the National Toxicology Program.

The overall incidence of reproductive system neoplasms in male F344 rats was 81.5%. The most common neoplasms were interstitial cell adenoma of the testis (76.6%), adenoma/carcinoma of the preputial glands (2.9%), mesothelioma of the tunica vaginalis (1.5%), and adenoma of the prostate gland (0.3%). The combined incidence (0.1%) of 59 other rare neoplasms consisted of 18 different types that occurred with a frequency of 4 or less.

In contrast to the rats, male B6C3F1 mice had a low overall incidence (0.6%) of neoplasms in reproductive organs. The most common neoplasm was the interstitial cell adenoma (0.4%). Thirty additional types of neoplasms were identified. Each of these uncommon neoplasms occurred at a frequency of 12 or less with an overall combined incidence of 0.2%. Morphological features are described for neoplasms in the rat and mouse, and criteria are presented for differentiation of testicular interstitial cell adenoma, prostatic adenoma, and mesothelioma from hyperplastic changes.

Introduction

The Fischer 344 (F344) rat and B6C3F1 mouse are the two rodent strains most commonly used for toxicity and/or carcinogenicity studies by the National Toxicology Program (NTP). With the exception of interstitial cell adenoma of the testis in the F344 rat, primary neoplasms of the male reproductive system in the F344 rat and B6C3F1 mouse are not common. The purpose of this presentation is to report the classification and incidence of all primary spontaneous neoplasms of the testis and accessory sex organs from the NTP data base of 51,230 male F344 rats and 46,752 male B6C3F1 mice. For this review, all available examples of rare neoplasms were examined microscopically to confirm the initial diagnoses. Representative examples of the more common neoplasms in the F344 rats, viz, interstitial cell adenoma, prostatic adenoma, and mesothelioma, were examined and criteria are presented for differentiation of these neoplasms from hyperplasia.

Neoplasms in Reproductive Organs of Male F344 Rats

Primary neoplasms of the testis or accessory sex organs occurred in 41,742 of 51,230 treated and control

rats from long-term toxicity/carcinogenicity studies (Table 1). There was no evidence of a treatment-related increase for these neoplasms in any of the studies included in this review. Those studies with a treatment-related increase in mesothelioma or preputial gland neoplasms are not included in the incidence figures. Of all male rats with primary neoplasms in the reproductive system, the majority (76.6%) had interstitial cell adenoma of the testis. The true incidence of this neoplasm in 2-year-old F344 rats has been estimated to be 95 to 100% (1). The lower incidence in the NTP data base is

Table 1. Incidence of neoplasms of male reproductive organs in F344 rats in the NTP data base.

	Total number	%	Number
Rats at risk	51,230		
Rats with neoplasms	41,742	81.5	
Testicular interstitial cell neoplasm	39,253	76.6	50
Preputial gland adenoma/carcinoma	1,514	2.9	0 ^a
Mesothelioma	754	1.5	30
Prostatic adenoma	158	0.3	32
Other tumors (<i>n</i> = 18)	59	0.1	33 ^b

^aMorphological features of preputial gland adenoma/carcinomas are reviewed and discussed by Maronpot (13).

^bTwenty-six cases were not available because of Pathology Working Group and Quality Assessment reviews or missing slides.

*National Institute of Environmental Health Sciences, P.O. Box 12233, Research Triangle Park, NC 27709.

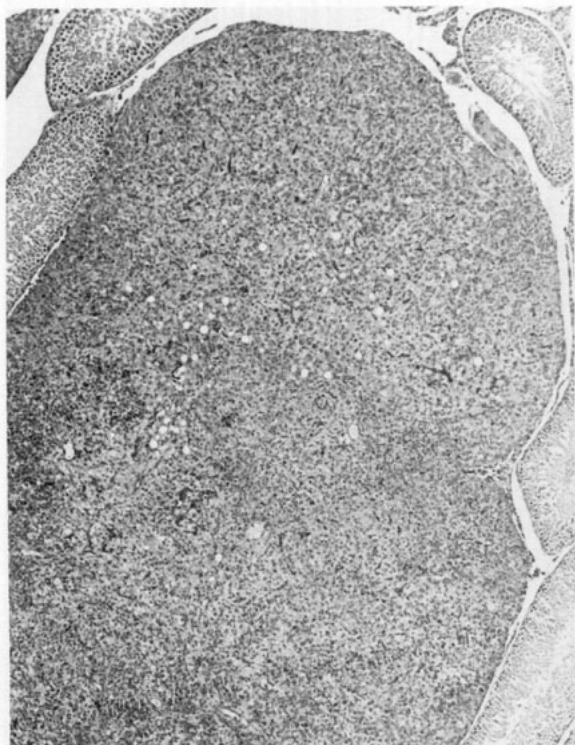


FIGURE 1. Interstitial cell adenoma of the testis in a F344 rat showing compression of adjacent tubules.

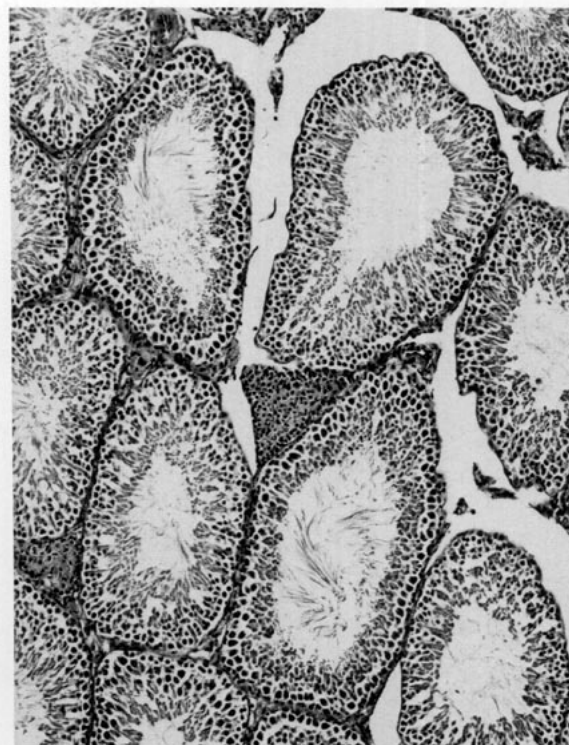


FIGURE 2. Interstitial cell hyperplasia of the testis in a F344 rat consisting of a focal lesion smaller than the diameter of one seminiferous tubule. Nuclear/cytoplasmic ratio is high, and nuclear atypia is not seen.

Table 2. Classification and occurrence of testicular neoplasms in F344 rats.

Classification	Occurrence
Germ cell origin	
Seminoma	— ^a
Yolk-sac carcinoma	—
Embryonal carcinoma	—
Teratoma	—
Rete testis	
Adenocarcinoma	3
Gonadal stroma origin	
Interstitial cell neoplasm	39,253
Sertoli cell neoplasm	—
Other gonadal stromal neoplasm	
Other	
Hemangiosarcoma	2
Leiomyosarcoma	1

^aA dash indicates that the tumor was reported in the literature, but not in the NTP data base.

probably related to the early deaths that occurred in 20 to 40% of the rats before the end of 2-year studies.

The incidence of preputial gland neoplasms, mesotheliomas of the tunica vaginalis, and prostate gland adenomas were 2.9, 1.5, and 0.3%, respectively. We randomly selected 50 testicular interstitial cell adenomas, 30 mesotheliomas, and 32 prostatic adenomas for the present histological reexamination. The morphological features of preputial gland neoplasms in F344 rats are reviewed elsewhere in this symposium by Maronpot and are not described in this report.

In addition, 59 other neoplasms (18 types) of the male reproductive organs were listed in the data base. Slides from 33 of the 59 neoplasms were examined histologically; 26 were not available because of ongoing Pathology Working Group and Quality Assessment reviews in the NTP or missing slides.

Testicular Neoplasms in F344 Rats

Testicular neoplasms in F344 rats are listed in Table 2. The rare occurrences of neoplasms of germ cell origin, including seminoma (2), yolk-sac tumor (3), embryonal carcinoma (4), and teratoma (4) have been reported in other rat strains. However, these neoplasms were not identified in F344 rats from the present study.

For neoplasms of gonadal stromal origin, interstitial cell adenoma was the most common in F344 rats. This neoplasm usually had a nodular growth pattern. In larger neoplasms, testicular architecture was totally destroyed. Larger adenomas were usually composed of three cell types: eosinophilic, vacuolated, and basophilic. Eosinophilic cells had abundant eosinophilic cytoplasm, poorly defined cell borders, and a central nucleus. Vacuolated cells were large with a central nucleus and had a pale vacuolated or foamy cytoplasm. Basophilic cells, the smallest of the three cell types, had scant

Table 3. Some criteria for testicular interstitial cell hyperplasia and adenoma in F344 rats.

Morphologic feature	Interstitial cell	
	Hyperplasia	Adenoma
Size of lesion	Usually smaller than diameter of one seminiferous tubule	Usually larger than diameter of one seminiferous tubule
Compression of adjacent tubules	Sometimes	Usually
Nuclear/cytoplasmic ratio	High	Low (abundant cytoplasm)
Nuclear or cytoplasmic atypia	No	Yes

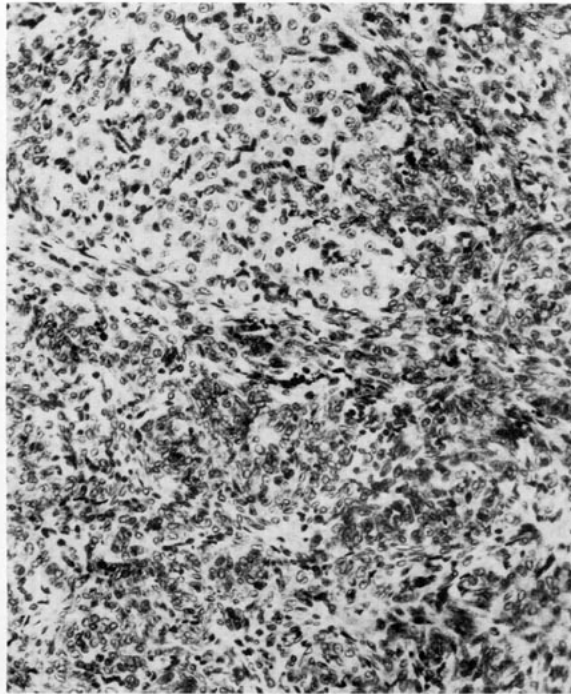


FIGURE 3. Gonadal stromal tumor of the testis in a F344 rat showing proliferation of spindle-shaped cells arranged in bundles. A pale staining area composed of cells resembling interstitial cells can be seen.

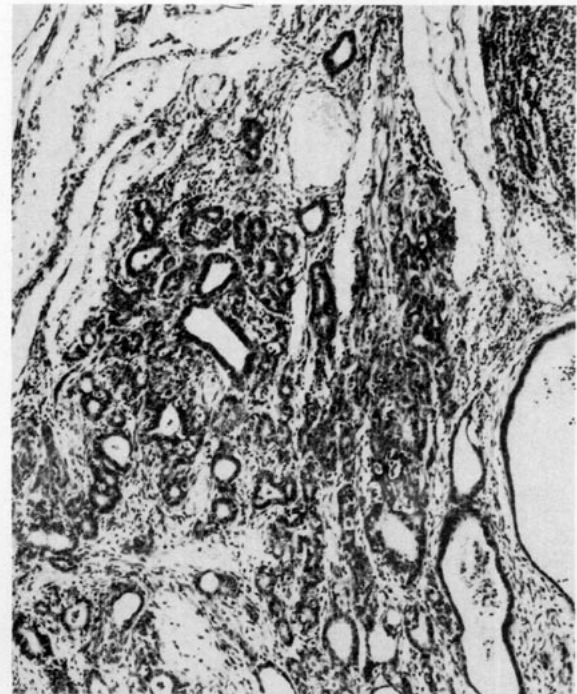

FIGURE 4. Adenocarcinoma of the rete testis in a F344 rat showing prominent glandular formation by cuboidal cells and marked scirrhous response.

cytoplasm and were located at the margin of nodules composed of larger eosinophilic or vacuolated cells.

Differentiation of interstitial cell adenoma from interstitial cell hyperplasia is sometimes difficult. Because the interstitial adenoma is a progression of hyperplasia, distinguishing between hyperplasia and the smallest adenoma is often arbitrary. Several criteria are currently used in the NTP (Table 3). If the lesion is larger than the diameter of one seminiferous tubule and there is compression of adjacent tubules, low nuclear/cytoplasmic ratio, and nuclear or cytoplasmic atypia, it is classified as adenoma (Fig. 1). For interstitial cell hyperplasia, the size of the lesion is smaller than the diameter of one seminiferous tubule (Fig. 2). In hyperplastic lesions, nuclear/cytoplasmic ratio is low and nuclear and cytoplasmic atypia are not seen; however, slight compression of surrounding seminiferous tubules is sometimes observed.

Other neoplasms of gonadal stromal cell origin are extremely rare in the rat. Malignant interstitial cell

neoplasms have been diagnosed when local invasion of the epididymis is present; pulmonary metastases occurred in a few cases. Sertoli cell neoplasia was not observed in this review, although a malignant Sertoli cell neoplasm has been reported in a F344 rat (5). Gonadal stromal neoplasia other than of interstitial cell or Sertoli cell origin was observed in only one male rat. The neoplastic cells grew in bundles and were generally spindle shaped with indistinct cell boundaries. A few cells had eosinophilic cytoplasm with some resemblance to interstitial cells (Fig. 3). When observed by electron microscopy, the neoplastic cells contained abundant free ribosomes, conspicuous rough endoplasmic reticulum, and numerous mitochondria. Desmosomes were occasionally seen, and formation of basement membrane was not observed. There was no evidence suggestive of germ cell origin.

Three adenocarcinomas originating from the rete testis were observed. Two of these appeared to arise within the intratesticular portion of the rete, and the third originated on the surface of the testis from the extra-

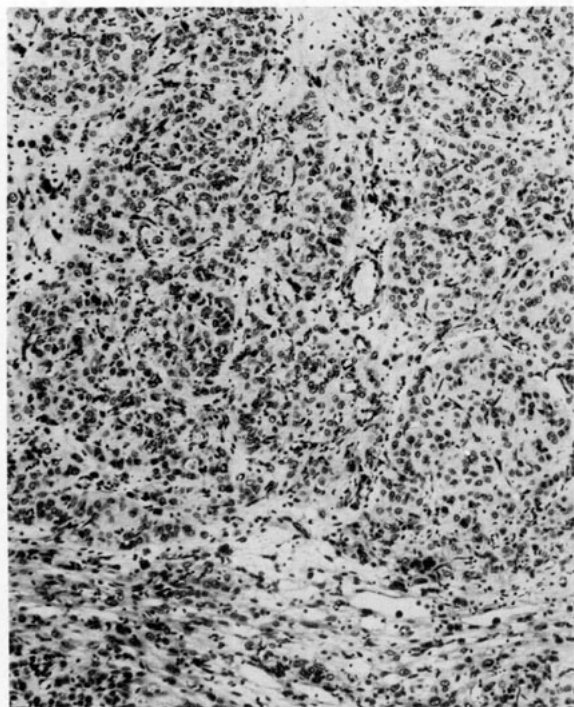


FIGURE 5. Leiomyosarcoma of the testis in a F344 rat consisting of spindle-shaped and pleomorphic cells arranged in bundle or in fascicular pattern.

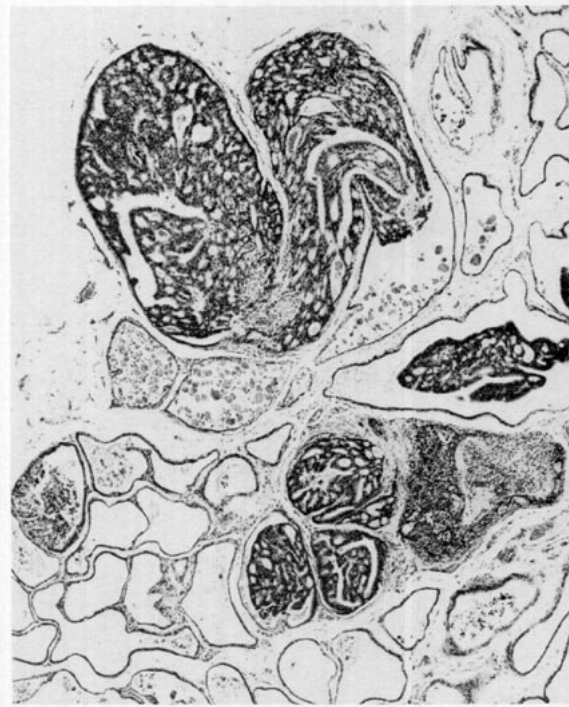

FIGURE 7. Adenoma of the ventral prostate in a F344 rat showing prominent intra-acinar growth of epithelial cells with a complex papillary or prominent cribriform pattern.

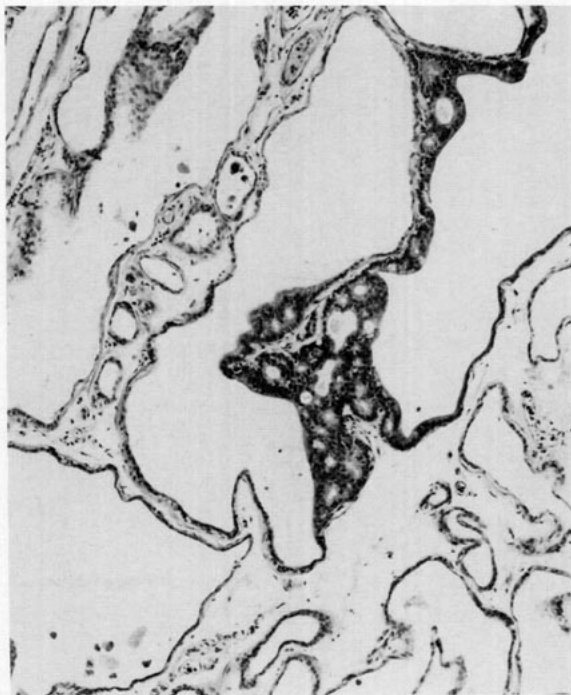

FIGURE 6. Epithelial hyperplasia of the ventral prostate in a F344 rat composed of a focal area with a cribriform pattern.

testicular portion of the rete. Glandular structures lined by cuboidal epithelial cells were prominent (Fig. 4). In some areas, glandular structures similar to normal rete testis were observed. Marked scirrhous response, hemorrhage, and necrosis were features of these neoplasms.

Other rare testicular neoplasms included two hemangiosarcomas and one leiomyosarcoma. The leiomyosarcoma consisted of spindle-shaped and pleomorphic cells with abundant eosinophilic cytoplasm (Fig. 5). Neoplastic cells were arranged in a fascicular pattern. By electron microscopy, intermediate filaments with fusiform densities similar to smooth muscle fibers were frequently seen in the cytoplasm of neoplastic cells. In addition, a half desmosomelike structure similar to attachment plaques in smooth muscle was also seen on the plasma membrane, and basement membrane was also prominent around the cells. This neoplasm may have arisen from blood vessel walls or peritubular smooth muscle cells in the testis.

Neoplasms in Sex Accessory Glands of F344 Rats

Neoplasms in the sex accessory glands of F344 rats are listed in Table 4. Except for prostatic adenoma, mesothelioma, and preputial gland adenoma/carcinoma, all neoplasms observed in the accessory glands were quite rare.

In the epididymis, one lipoma, one liposarcoma, and one sarcoma were observed. One epididymal leiomy-

Table 4. Classification and occurrence of neoplasms by topography in F344 rats.

Site/tumor	Occurrence
Epididymis	
Lipoma	1
Liposarcoma	1
Sarcoma	1
Leiomyosarcoma	1 ^a
Prostate	
Adenoma	158
Adenocarcinoma	10
Squamous cell carcinoma	1
Sarcoma	1
Leiomyosarcoma	1
Tunica vaginalis	
Mesothelioma	754
Prostatic urethra	
Transitional cell carcinoma	1
Penis	
Squamous cell papilloma	1
Squamous cell carcinoma	1
Seminal vesicle	
Adenoma	2
Adenocarcinoma	1 ^a
Coagulating gland	
No neoplasm observed	
Vas deferens	
Sarcoma	1
Preputial gland	
Adenoma	618
Carcinoma	896
Prepuce	
Keratoacanthoma	2
Squamous cell carcinoma	4

^aSlide not available for the present review.

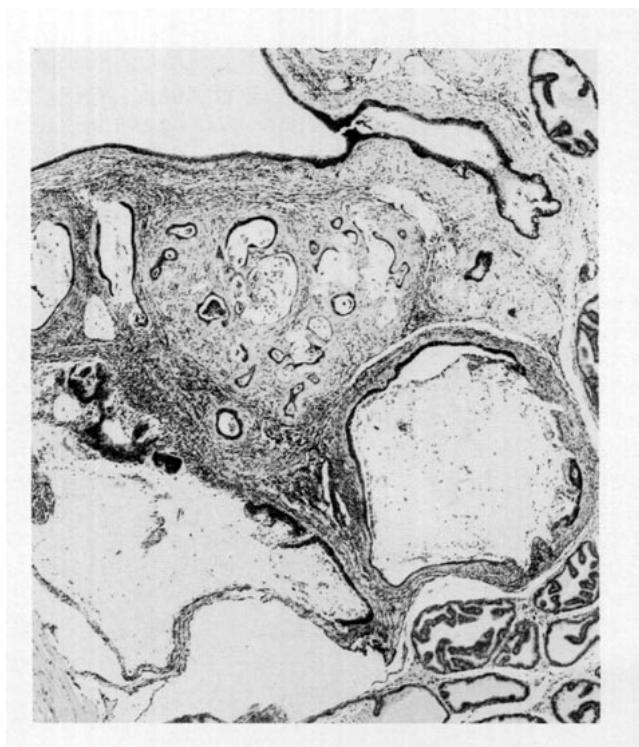

FIGURE 8. Adenocarcinoma of the dorsolateral prostate in a F344 rat showing irregular glandular and scirrhous reaction.

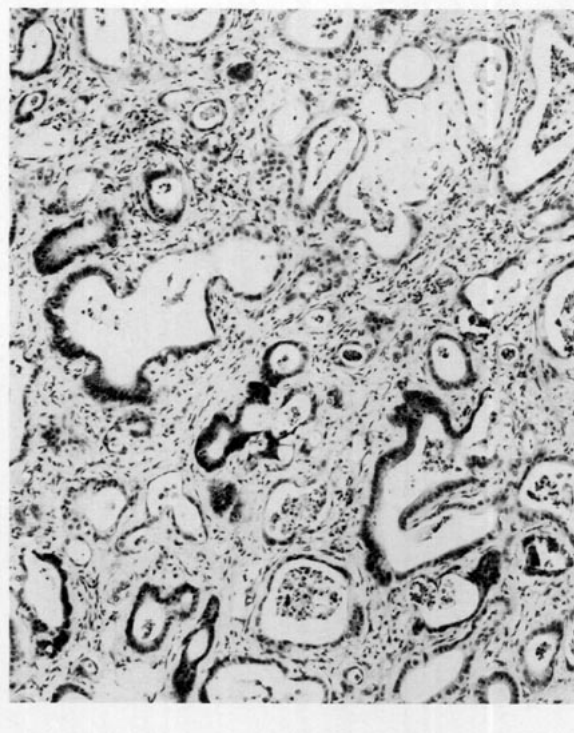


FIGURE 9. Adenocarcinoma of the dorsolateral prostate in a F344 rat characterized by severe invasive growth of pleomorphic cells forming glandular structure with marked scirrhous reaction.

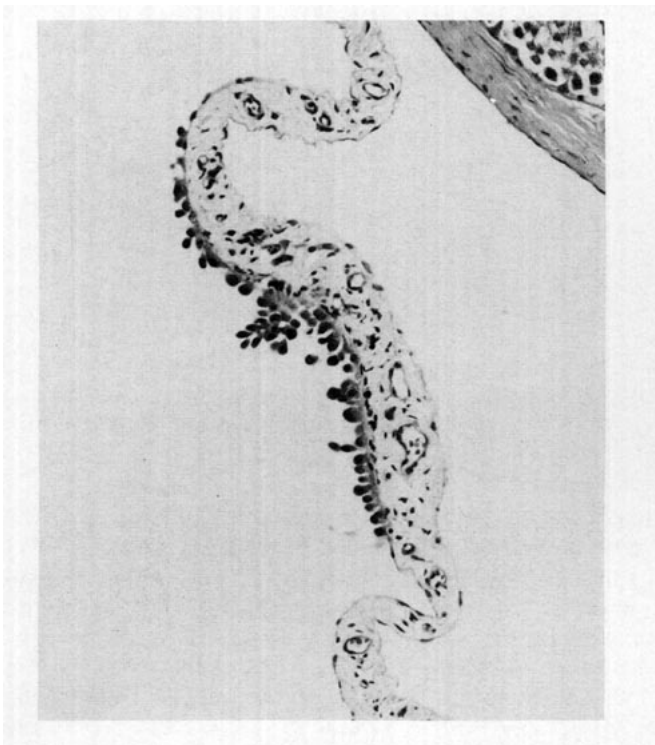
osarcoma was recorded in the data base, but this slide was not available for review.

In the prostate, adenoma was relatively common compared to other prostatic neoplasms. In the historical control data from the 60 most recent NTP studies, the incidence of this neoplasm in 3262 rats was 26 (0.8%). This neoplasm was usually seen in the ventral lobe and was characterized by prominent intra-acinar growth of atypical epithelial cells arranged in a cribriform pattern. Because normal epithelial cells in the ventral lobe from aged rats are low cuboidal or flattened as compared to those in the dorsolateral lobe, recognition of a proliferative lesion by light microscopy is easy under low magnification.

It is sometimes difficult to differentiate between epithelial hyperplasia and adenoma of the ventral prostate because the cellular morphology of epithelial hyperplasia is very similar to that of the adenoma. Several criteria are used in the NTP (Table 5). Simple papillary growth or a focal area with a cribriform pattern is seen in epithelial hyperplasia (Fig. 6). Intra-acinar growth is prominent in adenomas that may have a complex papillary, prominent cribriform or solid pattern (Fig. 7). Compression of surrounding tissues is sometimes observed in adenomas, but not in hyperplasia. Although it has been reported that there is progression from adenoma to adenocarcinoma in the ventral prostate of aging F344 rats (6), we found no adenocarcinomas originating from the ventral prostate. The 10 adenocarcinomas in the present study were from the dorsolateral lobe (Fig. 8). The morphologic features of the carcino-

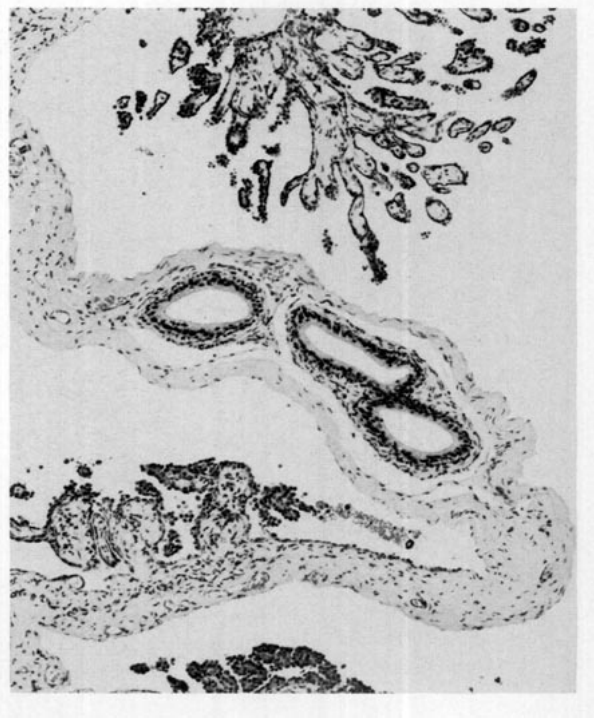Table 5. Some criteria for prostatic hyperplasia and adenoma in F344 rats.

Morphologic feature	Hyperplasia	Adenoma
Predilection site	Ventral lobe	Ventral lobe
Compression of surrounding tissue	No	Yes
Growth pattern	Simple papillary Cribriform	Complex papillary Cribriform Solid
Intra-acinar growth	Slight	Prominent
Obliteration of acinar lumens	No	Yes

**FIGURE 10.** Mesothelial hyperplasia of the tunica vaginalis in a F344 rat composed of focal papillary projection of mesothelial cells without any stromal proliferation.

mas were different from those of adenomas occurring in the ventral lobe. The carcinomas were characterized by invasive growth of pleomorphic cells forming glandular structures (Fig. 9). Mitoses were frequently observed and scirrhous response was a common feature of these malignant neoplasms. We also found one squamous cell carcinoma located in the dorsolateral lobe. It has been reported that the dorsal lobe is the common site for human prostatic carcinoma and the ventral lobe is the common site for benign prostatic hypertrophy (?). It appears that the anatomical location of prostatic carcinoma in F344 rats is the same as that of the human prostatic carcinoma. Other rare neoplasms of the prostate observed in the NTP data base included one leiomyosarcoma and one sarcoma.

Neoplasms of the seminal vesicle were rare. Only two adenomas were identified. The adenoma was a discrete mass consisting of proliferating epithelium arranged in

**FIGURE 11.** Mesothelioma of the tunica vaginalis in a F344 rat showing complex papillary growth of mesothelial cells with stromal proliferation.

a glandular pattern. The cells were well differentiated. Although one adenocarcinoma of the seminal vesicles was recorded in the data base, the slide was not available for review.

No neoplasms were identified in the coagulating gland. Only one sarcoma was seen in the vas deferens.

Mesotheliomas in the tunica vaginalis ranged from several focal areas, consisting of complex papillary structures on the serosa to neoplasms in which most of the abdominal serosa was covered by a proliferation of mesothelial cells in a papillary growth pattern and glandular formation within the proliferative stroma. In the historical control data from the 60 most recent NTP studies, the incidence of this neoplasm among 3427 rats was 51 (1.4%). There is sometimes difficulty in differentiation between mesothelial hyperplasia and mesothelioma. The criteria currently used in the NTP (Table 6) is that focal thickening or single papillary (villous) projection of mesothelial cells without stratification or stromal proliferation is mesothelial hyperplasia. Pleomorphism is not seen and mitoses are uncommon in hyperplasia (Fig. 10). In mesotheliomas, complex papillary growth of mesothelial cells with stromal proliferation can be seen (Fig. 11). Stratification of mesothelial cells and glandular formation within the proliferative stroma is sometimes observed. Even in small lesions, if complex papillary growth of mesothelial cells with stratification and stromal proliferation are observed, these are diagnosed as mesothelioma.

Preputial gland adenomas and carcinomas were the second most frequent neoplasms in the reproductive

Table 6. Some criteria for mesothelial hyperplasia and mesothelioma in F344 rats.

Morphologic feature	Hyperplasia	Mesothelioma
Growth pattern	Simple papillary	Complex papillary or glandular
Shape of cells	Cuboidal	Cuboidal, columnar, or flattened
Stratification	No	Sometimes
Pleomorphism	No	Yes
Mitosis	Uncommon	Sometimes
Stromal proliferation	No	Yes
Invasion	No	Sometimes

Table 7. Incidence of neoplasms of male reproductive organs in B6C3F1 mice in the NTP data base.

	Total number	%	Number reviewed
Mice at risk	46,752		
Mice with neoplasms	283	0.6	
Testicular benign interstitial cell neoplasm	169	0.4	26
Other neoplasms (<i>n</i> = 30)	114	0.2	100 ^a

^aFourteen cases were not available because of Pathology Working Group and Quality Assessment reviews or missing slides.

Table 8. Classification and occurrence of testicular neoplasms in B6C3F1 mice.

Classification	Occurrence
Germ cell origin	
Seminoma	1
Choriocarcinoma	— ^a
Embryonal carcinoma	—
Teratoma	—
Others	
Hemangioma	12
Hemangiosarcoma	12
Schwannoma	1
Gonadal stroma origin	
Interstitial cell neoplasm	
Well-differentiated	169
Fusiform cell type	2
Undifferentiated type	12
Sertoli cell neoplasm	1
Other gonadal stromal neoplasm	7

^aA dash indicates that the tumor was reported in the literature, but not in the NTP data base.

organs. In the historical control data from the 60 most recent NTP studies, the incidence of preputial gland tumors in 3427 rats was 159 (4.6%). The morphological features of these neoplasms and criteria for the differentiation between adenoma and carcinoma are described elsewhere in this symposium by Maronpot.

Other rare neoplasms observed in this review included one transitional cell carcinoma of the urethra, one squamous cell carcinoma of the penis, two keratoacanthomas, and four squamous cell carcinomas of the prepuce.

In this review of F344 rats, it was confirmed that although interstitial cell adenoma is the most common neoplasm of the male reproductive system, and pre-

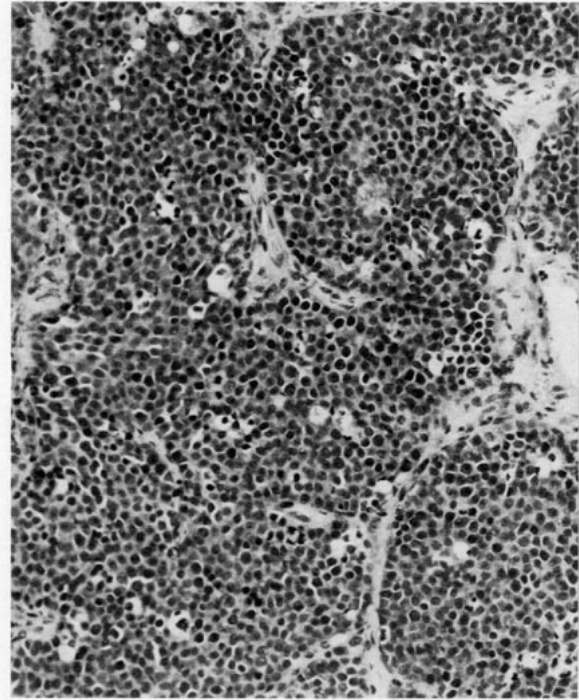

FIGURE 12. Seminoma of the testis in a B6C3F1 mouse. Tubular structures and sheets of round to polyhedral neoplastic cells with distinct cell borders.

putial gland adenoma and carcinoma, mesothelioma and prostate gland adenoma are relatively common, other primary neoplasms of the male reproductive system are extremely rare. With respect to proliferative lesions of the testicular interstitial cell, mesothelium and prostatic gland, there is often no clear-cut distinction between hyperplasia and neoplasia. It is important that consistent morphologic criteria are established to achieve uniformity of diagnoses for these lesions in long-term toxicity/carcinogenicity studies.

Neoplasms in Reproductive Organs of Male B6C3F1 Mice

Two hundred eighty-three mice (0.6%) with primary neoplasms of the male reproductive system were identified from the data base of 46,762 mice used in toxicity/carcinogenicity studies performed by the NTP (Table 7). Those few studies with a treatment-related increased incidence in neoplasms of the male reproductive system were not included in this review.

Of the 283 mice, 169 had benign testicular interstitial cell neoplasms. Twenty-six of the interstitial cell neoplasms from 169 were selected and reexamined histologically in the present study. Of the 114 other neoplasms of the reproductive organs in mice, 100 were reexamined; slides of 14 cases were not available.

Testicular Neoplasms in B6C3F1 Mice

Testicular neoplasms in B6C3F1 mice are listed in Table 8. Although choriocarcinoma (8), embryonal car-

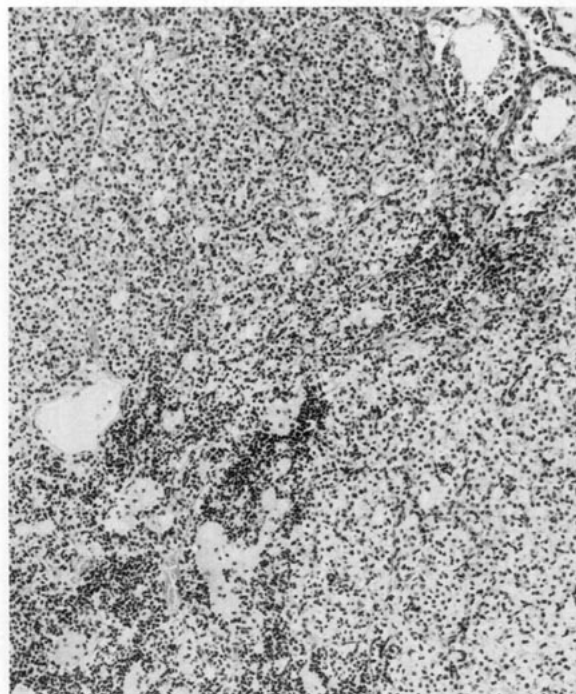


FIGURE 13. Interstitial cell neoplasm (well-differentiated type) of the testis in a B6C3F1 mouse showing nodular growth of vacuolated, pigmented, and basophilic cells.

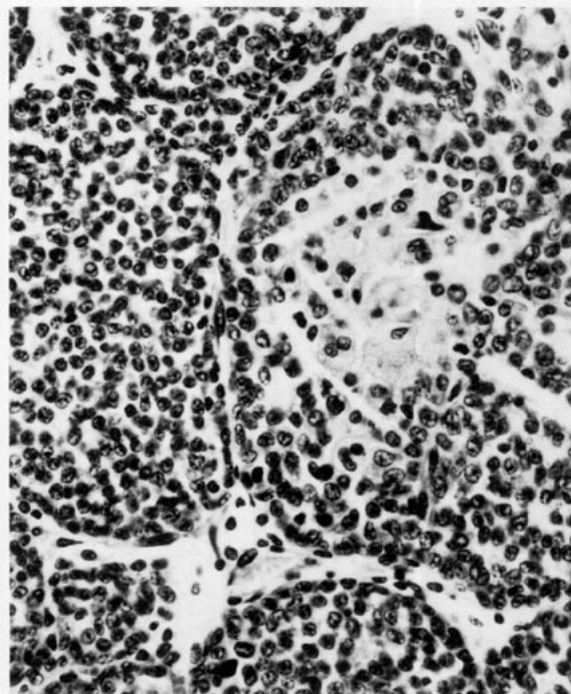


FIGURE 15. Gonadal stromal tumor of the testis with cells and pattern resembling ovarian granulosa cell tumor in a B6C3F1 mouse.

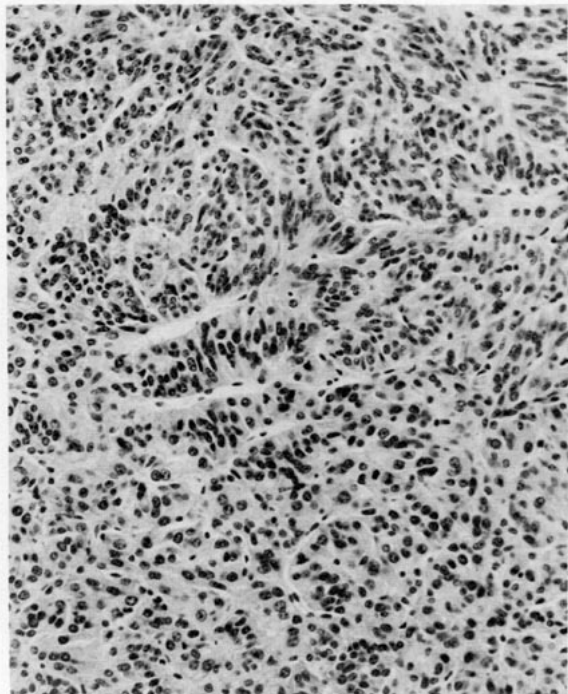


FIGURE 14. Sertoli cell tumor of the testis in a B6C3F1 mouse showing nuclear palisading array of neoplastic cells.

cinoma (8), and teratoma (8) have been reported to occur in mice other than the B6C3F1 strain, these neoplasms were not identified in our review. Only one neoplasm of germ cell origin, a seminoma, was observed in the present study. Neoplastic cells were arranged either in tubular structures or diffuse sheets. The cells, which resembled spermatogonia, were round to polyhedral with distinct cell boundaries, basophilic cytoplasm, and fine nuclear chromatin (Fig. 12). Mitotic figures were common.

Neoplasms of gonadal stromal origin included interstitial cell, Sertoli cell, and other gonadal stromal cells. Interstitial cell neoplasms were subclassified to three types: well differentiated; fusiform cell; and undifferentiated. Of the total of 183 interstitial cell neoplasms, 169 were the well-differentiated type. There were 2 fusiform and 12 undifferentiated cell types. The well-differentiated neoplasms morphologically resembled testicular interstitial cell adenomas in F344 rats. Nodular growth of neoplastic cells was usually seen. These neoplasms were composed of four cell types: eosinophilic cell, vacuolated cell, pigmented cell, and small basophilic cell (Fig. 13). Brown pigment in the pigmented cell was confirmed to be lipofuscin.

In the fusiform cell type of interstitial cell neoplasm, the majority of neoplastic cells were fusiform or spindle-shaped cells with moderate eosinophilic cytoplasm and a morphological similarity to theca cells in the ovary. Vacuolated interstitial cells were present in some areas of this neoplasm.

The undifferentiated type of interstitial cell neoplasm was characterized by a diffuse proliferation of undiffer-




FIGURE 16. Schwannoma of the testis in a B6C3F1 mouse showing typical nuclear palisading array of Schwann cells.

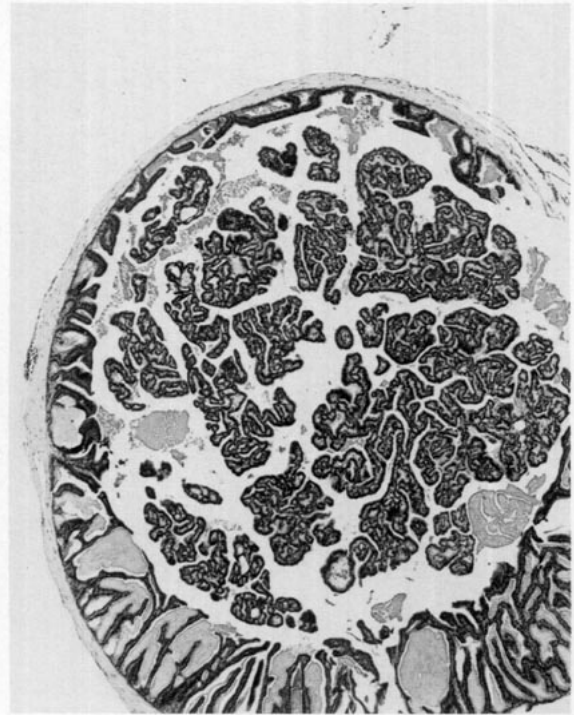


FIGURE 18. Adenoma of the seminal vesicle in a B6C3F1 mouse characterized by papillary growth of epithelial cells.

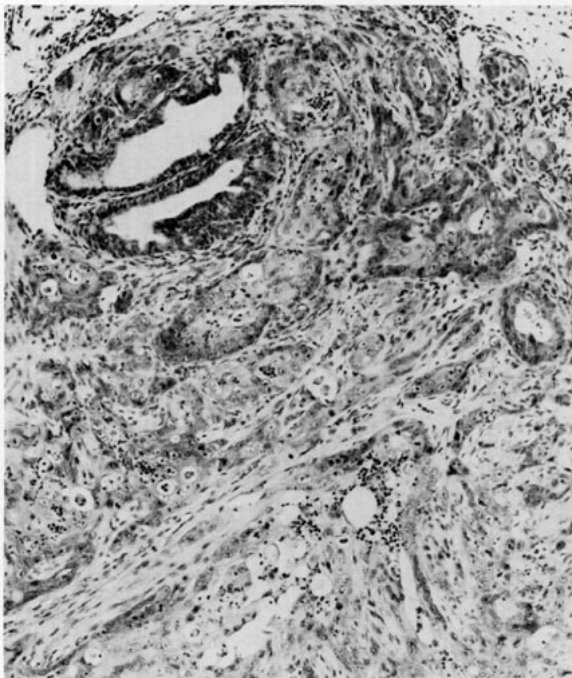


FIGURE 17. Adenocarcinoma of the prostate in a B6C3F1 mouse showing invasive growth of pleomorphic cells forming glandular structures with scirrhous response.

entiated basophilic cells. Neoplastic cells had scant cytoplasm and indistinct cell borders. Nuclei of these cells had a morphological resemblance to Leydig cells, although the chromatin pattern was more condensed than that of normal Leydig cells. Invasive growth of neoplastic cells through the tunical albuginea was seen in several cases.

A Sertoli cell neoplasm occurred in only one mouse. Neoplastic cells were arranged in tubular structures and diffuse sheets. Within the tubular structures, cells were tightly packed and had homogeneous eosinophilic cytoplasm. The morphologic features of nuclei differed from those of Leydig or spermatogenic cells. A vesicular nucleus with one or two prominent nucleoli was seen in each cell. Because of the parallel arrangement of adjacent neoplastic cells within the tubular structures, a nuclear palisading array was sometimes observed (Fig. 14). In addition, seven other gonadal stromal neoplasms characterized by nodular growth patterns were recognized in the present study. These neoplasms resembled granulosa cell neoplasms of the ovary (Fig. 15) and had no similarity to interstitial cells, Sertoli cells, or spermatogenic cells. The term gonadal stromal cell neoplasms was chosen because evidence suggestive of granulosa cells was not obtained.

Besides the gonadal stromal neoplasms, 12 hemangiomas, 12 hemangiosarcomas and 1 schwannoma were seen in the testis. The morphologic features of the vascular neoplasms were similar to those previously described in the other tissues such as liver (9) and subcutis (10). The one schwannoma replaced the seminiferous

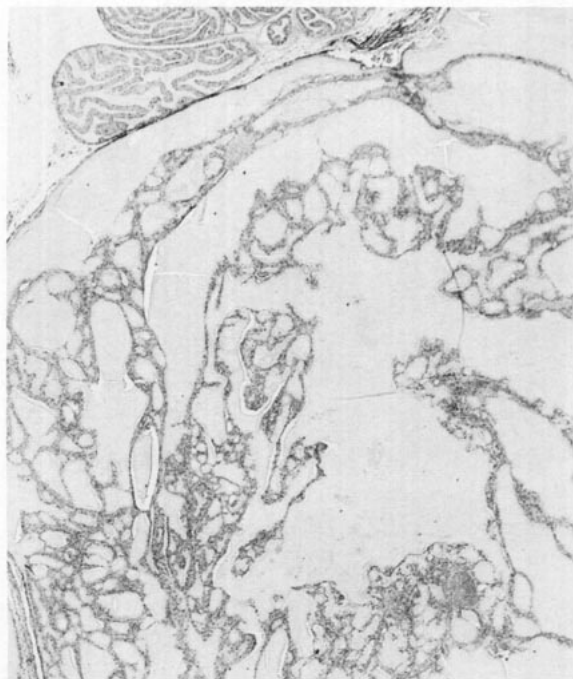


FIGURE 19. Adenoma of the coagulating gland in a B6C3F1 mouse showing papillary growth and glandular formation.

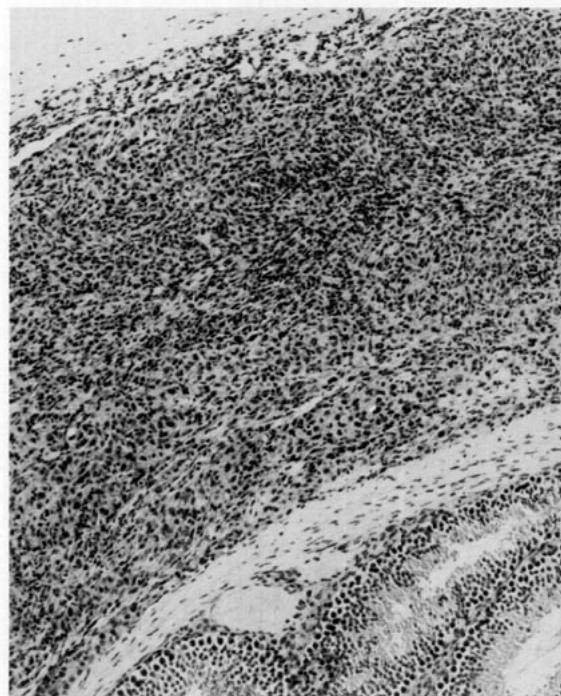

FIGURE 21. Sarcoma of the tunica vaginalis in a B6C3F1 mouse. Space between scrotum and tunica albuginea occupied by pleomorphic cells with abundant eosinophilic cytoplasm.

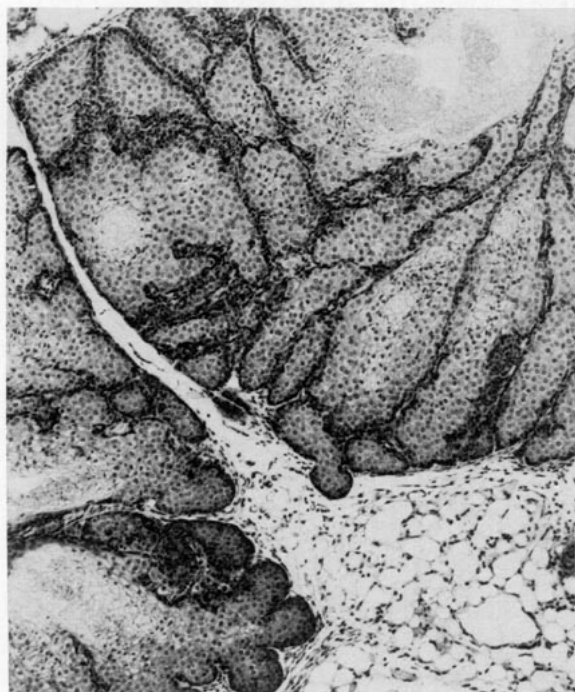

FIGURE 20. Adenoma of the preputial gland in a B6C3F1 mouse showing expansive growth of each acinus due to increased number of basal cells and foamy sebaceous cells.

tubules of the testis. Although occurrence of a palisading array of neoplastic cells is relatively rare in mouse schwannomas, this feature was frequently seen in this neoplasm (Fig. 16).

Neoplasms in Sex Accessory Glands of B6C3F1 Mice

Neoplasms in sex accessory glands of B6C3F1 mice are listed in Table 9. All neoplasms observed in these organs were extremely rare with a frequency of eight or less. In the epididymis, eight ectopic interstitial cell adenomas, two sarcomas, one lipoma, and four hemangiosarcomas were recognized. The ectopic interstitial cell adenomas occurred in the interstitium of the epididymis. In these cases, no adenomas were present in the testis. The neoplastic cells were generally vacuolated and pigmented and similar to testicular Leydig cells. Since Leydig cells do not exist in the normal epididymis, the qualifier "ectopic" was chosen for these interstitial cell adenomas of the epididymis.

In the prostate, one adenocarcinoma, one hemangioma, and five hemangiosarcomas were found. Prostatic leiomyosarcoma has been reported as a rare tumor in the literature (11), but none was identified in the present study. In the one prostatic adenocarcinoma, invasive growth of pleomorphic epithelial cells forming glandular structures was prominent (Fig. 17). This malignant neoplasm was accompanied by scirrhous response similar to that occurring in prostatic adenocarcinomas of rats.

Table 9. Classification and occurrence of neoplasms by topography in B6C3F1 mice.

Site/tumor	Occurrence
Epididymis	
Interstitial cell adenoma (ectopic)	8
Sarcoma	2
Lipoma	1
Hemangiosarcoma	4
Prostate	
Adenocarcinoma	1
Hemangioma	1
Hemangiosarcoma	5
Leiomyosarcoma	— ^a
Tunica vaginalis	
Sarcoma	2
Urethra	
Transitional cell carcinoma	1
Penis	
Squamous cell carcinoma	1
Seminal vesicle	
Adenoma	3
Adenocarcinoma	2
Squamous cell carcinoma	1
Undifferentiated carcinoma	1
Sarcoma	1
Coagulating gland	
Adenoma	2
Carcinoma	1
Vas Deferens	
Hemangiosarcoma	1
Preputial gland	
Adenoma	1
Adenocarcinoma	—
Squamous cell papilloma	2
Squamous cell carcinoma	5
Hemangioma	1
Hemangiosarcoma	5
Sarcoma	1

^aA dash indicates that the tumor was reported in the literature, but not in the NTP data base.

In the seminal vesicle, three adenomas, two adenocarcinomas, one squamous cell carcinoma, one undifferentiated carcinoma, and one sarcoma were recognized. All adenomas (Fig. 18) and adenocarcinomas were characterized by a papillary projection of epithelial cells into the lumen. In the adenocarcinomas, cell arrangement was more irregular than adenomas, and pleomorphic cells were frequently seen. The malignant neoplasms were accompanied by necrosis and hemorrhage.

Two adenomas and one carcinoma were observed in the coagulating gland. The adenomas revealed both papillary growth and glandular proliferation of epithelial cells (Fig. 19). Morphologic similarity to normal acinar epithelium of the coagulating gland was present in the adenomas.

Neoplasms in the preputial gland included one adenoma, two squamous cell papillomas, five squamous cell carcinomas, one hemangioma, five hemangiosarcomas, and one sarcoma. Although adenocarcinoma of the preputial gland has been reported (12), this neoplasm was not identified in the present review. The cells in the adenoma were similar to those in the normal gland, but expansive growth of each acini due to an increased num-

ber of basal cells and foamy sebaceous cells was prominent (Fig. 20).

In the other accessory sex organs, one hemangiosarcoma of the vas deferens, two sarcomas of the tunica vaginalis, one transitional cell carcinoma of the urethra, and one squamous cell carcinoma were seen. In the sarcomas of the tunica vaginalis, the space between scrotum and tunical albuginea was occupied by neoplastic cells. These cells had abundant eosinophilic cytoplasm and large pleomorphic nuclei with indistinct cell borders (Fig. 21). It is possible these neoplasms are of mesothelial cell origin.

Based on the present review, we confirmed that with the exception of well-differentiated type of interstitial cell neoplasms of the testis, spontaneous neoplasms of the male reproductive organs in B6C3F1 mice are extremely rare. Gonadal stromal neoplasms were subclassified into several types based upon cellular morphology. Other neoplasms occurred at a very low incidence and further studies using immunohistochemistry and electron microscopy may be useful to determine the cell origin for these rare neoplasms.

REFERENCES

- Boorman, G. A., Hamlin, M., and Eustis, S. L. Focal interstitial cell hyperplasia, rat. In: *The Male Genital System, Monographs on Pathology of Laboratory Animals* (T. C. Jones, U. Mohr, and R. D. Hunt, Eds.), Springer-Verlag, Berlin, 1987, pp. 200-204.
- Kim, S., Fitzgerald, J. E., and De La Iglesia, F. A. Spermatocytic seminoma in the rat. *Toxicol. Pathol.* 13: 215-221 (1985).
- Damjanov, I. Yolk sac carcinoma (endodermal sinus tumor). *Am. J. Pathol.* 98: 569-572 (1980).
- Mostofi, F. K., and Bresler, V. M. Tumours of the testes. In: *Pathology of Tumours in Laboratory Animals, Vol. I, Part 2, Tumours of the Rat* (V. S. Turusov, Ed.), International Agency for Research on Cancer Scientific Publication 6, 1976, pp. 135-150.
- Abbott, D. P. A malignant Sertoli cell tumour in a laboratory rat. *J. Comp. Path.* 92: 339-342 (1983).
- Reznik, G., Hamlin, M. H., Ward, J. M., and Stinson, S. F. Prostatic hyperplasia and neoplasia in aging F344 rats. *Prostate* 2: 261-268 (1981).
- Price, D., and Williams-Ashman, H. G. The accessory reproductive glands of mammals. In: *Sex and Internal Secretions*, 3rd ed. (W. C. Young, Ed.), Williams and Wilkins, 1961, pp. 366-435.
- Mostofi, F. K., and Bresler, V. M. Tumours of the testis. In: *Pathology of Tumours in Laboratory Animals, Vol. II, Tumours of the Mouse* (V. S. Turusov, Ed.), International Agency for Research on Cancer Scientific Publication 23, 1979, pp. 325-348.
- Turusov, V. S., and Takayama, S. Tumours of the liver. In: *Pathology of Tumours in Laboratory Animals, Vol. II, Tumours of the Mouse* (V. S. Turusov, Ed.), International Agency for Research on Cancer Scientific Publication 23, 1979, pp. 193-233.
- Stewart, H. L. Tumours of the soft tissues. In: *Pathology of Tumours in Laboratory Animals, Vol. II, Tumours of the Mouse* (V. S. Turusov, Ed.), International Agency for Research on Cancer Scientific Publication 23, 1979, pp. 487-525.
- Upton, A. C., Kimball, A. W., Furth, J., Christenberry, K. W., and Benedict, W. H. Some delayed effects of atom-bomb radiations in mice. *Cancer Res.* 20 (Suppl. 8, Part 2): 1-60 (1960).
- Fekete, E., and Kent, E. L. Transplantable mouse tumours. *Transplant. Bull.* 2: 61-62 (1955).
- Maronpot, R.R., Ulland, B., and Mennear, J. Transplantation characteristics, morphologic features, and interpretation of preputial gland neoplasia in the Fischer 344 rat. *Environ. Health Perspect.* 77: 33-36 (1988).