

# A Combined Carcinogen Bioassay Utilizing Both the Lung Adenoma and Skin Papilloma Protocols

by Merrel Robinson,\* Richard J. Bull,† Gary L. Knutsen,‡ Robert P. Shields,\*\* and Judy Stober\*

To test the feasibility of employing a combined lung adenoma/skin papilloma assay for broader detection of chemical carcinogenesis than that realized with either bioassay done separately, four strains of mice, SENCAR, BALB/c, A/J, and ICR-Swiss, were administered carcinogens either by the oral or intraperitoneal (IP) routes. The carcinogens administered were ethyl carbamate (EC), benzo(a)pyrene [B(a)P], *N*-[4-(5-nitro-2-furyl)thiazolyl]formamide (FANFT), and acrylamide (ACR). Starting 2 weeks later, 1 to 5  $\mu$ g (depending on strain) of 12-O-tetradecanoylphorbol-13-acetate (TPA) in 0.2 mL acetone/mouse was applied three times weekly to the shaved back for 20 weeks. All strains displayed increases in the yield of lung adenomas in response to EC at 32 weeks. B(a)P increased lung adenomas in only the SENCAR and A/J strain. Only the SENCAR and ICR-Swiss mice gave positive responses in the skin. In the SENCAR mice, positive response was seen with all four chemicals, however, FANFT gave an inconsistent response. The ICR-Swiss mice responded with an increased skin papilloma yield only to EC. In a separate experiment involving only SENCAR mice, animals were treated with a single oral dose of diethylnitrosamine (DEN) followed by triweekly application of 1.0  $\mu$ g TPA. This treatment resulted in 51/57 animals developing lung adenomas vs. 5/57 in the control animals. No treatment-related skin tumors resulted with DEN. Histopathologically confirmed lesions indicate that the spectrum of chemicals detected in the SENCAR mouse may be broadened using a combined bioassay that examines both lung and skin responses.

## Introduction

The mouse skin papilloma assay as described by Berenblum et al. (1,2) and Boutwell et al. (3,4) and mouse lung adenoma assay as described by Shimkin et al. (5) and Stoner et al. (6) are two carcinogen test systems that have been suggested by Bull et al. (7) for Tier 2 confirmation testing of putatively carcinogenic chemicals or mixtures. Although several different strains of mice have been used for these tests, the SENCAR mouse is the most sensitive model in the skin papilloma assay (8), and the A/J strain is the most susceptible model for lung adenomas (9). In an attempt to offset the occurrence of false negatives in these two carcinogen test models, our laboratory is testing the feasibility of using a single mouse model for conducting a combined assay for skin papillomas and lung adenomas. To that end, we have studied skin and lung responses of four different strains of mice to the administration of four different chemical carcinogens. One strain (ICR-Swiss)

was examined because it is known to be sensitive to the induction of both lung adenomas and skin papillomas by chemical carcinogens (9,10). The BALB/c strain was included as a strain that was recognized to be relatively insensitive to skin tumor initiation and lung tumor development. All four strains were compared grossly for their carcinogenic response to benzo(a)pyrene[B(a)P], ethyl carbamate (EC), acrylamide (AC). *N*-[4-(5-nitro-2-furyl)thiazolyl]formamide (FANFT). Diethylnitrosamine (DEN) was also tested in the SENCAR mouse. These findings were more critically assessed by histopathological examination.

## Methods

### Chemicals

B(a)P was obtained from Aldrich (Milwaukee, WI), DEN from Eastman Kodak Co. (Rochester, NY), FANFT from Saber Labs (Morton Grove, IL), and EC from MCB (Gibbstown, NJ). B(a)P was designated 98% pure, and the other chemicals were of reagent grade classification; all were used as received. ACR was purchased from Eastman Kodak and found to be more than 99% pure by GC-MS analysis (11). 12-O-tetradecanoyl-

\*Toxicology and Microbiology Division, U.S. Environmental Protection Agency, Cincinnati, OH 45268.

†College of Pharmacy, Washington State University, Pullman, WA 99164-6510.

‡Pathology Associates Inc., Ijamsville, MD 21754.

\*\*University of Florida, Gainesville, FL 32610.

phenol-13-acetate (TPA) was purchased from Chemical Carcinogenesis (Eden Prairie, MN).

## Biological Testing

Only female mice were used for this study. The SENCAR and ICR-Swiss were obtained from Harlan Sprague-Dawley, Inc. (Indianapolis, IN), BALB/c mice from Charles River (Wilmington, MA), and A/J mice from Jackson Labs (Bar Harbor, ME). Three experiments were conducted. In experiment 1, DEN was tested only in the SENCAR mouse. A single dose of 50 mg/kg was administered by oral intubation in a 10% Emulphor (polyoxygenated vegetable oil) solution. There were 60 animals in the group with 40 receiving TPA (1.0 µg, three times weekly for 20 weeks) and 20 receiving acetone as indicated above. The skin tumors were charted for one year in this group, and lung adenoma determinations were made following sacrifice at that point. In experiment 2 only SENCAR mice were tested, and B(a)P was administered in a single dose of 100 mg/kg, rather than the 50 mg/kg as used in experiment 3. All other aspects of the protocol are the same as described below for experiment 3. In experiment 3 a single dose of EC (300 mg/kg), B(a)P (50 mg/kg), or FANFT (500 mg/kg) was administered intraperitoneal (I.P.) to 60 mice of each of the four strains. Two days following this dose, 40 of the 60 mice in each group received 1.0 µg (SENCAR), 2.5 µg (A/J and ICR-Swiss), or 5.0 µg (BALB/c) TPA in 0.2 mL acetone applied topically three times weekly for 20 weeks. The remaining 20 mice received only acetone for the same schedule and duration of treatment. The appearance and regression of skin tumors were charted weekly. Only tumors of 1 mm or greater and persisting for a least three observations were included in the cumulative count. The animals were sacrificed at 36 weeks of age, and gross lung adenoma counts were determined according to the method reported by Shimkin (5). Briefly described, the method involves excising the lungs at time of sacrifice and fixing them in a 10% formalin solution. Three to four days later, the lungs were examined under a Spencer dissecting microscope (×10) and the number of surface adenomas was counted. Microscopic examinations were done on all grossly observed nodules, and final counts were adjusted to include only confirmed adenomas.

In each study, papillomas were included in the tumor count only if they were observed for three consecutive weeks. At the time of sacrifice, all gross lesions were noted and fixed in 10% buffered formalin for subsequent histopathological evaluation. To further validate the gross lung tumor counts in experiments 2 and 3, all questionable lung lesions were examined microscopically and total counts were adjusted to reflect confirmed adenomas. Skin lesions present at sacrifice were also examined microscopically (findings not reported). To determine the statistical significance of the data, the chi-square was used for experiment 1. For experiments 2 and 3, lung adenoma data were analyzed by Fisher's

**Table 1. Results of combined lung adenoma and skin papillomas assays in SENCAR mouse following oral treatment with diethylnitrosamine.**

Chemical and dose <sup>a</sup>	Animals with tumors, %	
	Lung adenoma	Papilloma
Diethylnitrosamine 50 mg/kg	85 <sup>b</sup>	13
Vehicle (Emulphor 10%)	8	23

<sup>a</sup>Chemical was administered in single injection in Emulphor to 60 animals. Two weeks later applications of TPA were made at 1.0 µg in 0.2 mL acetone three times weekly for 20 weeks to shaved backs of 40 animals. Results are reported as percentage of animals having tumors after 40 weeks on study. Lung adenoma counts include the total of 60 animals in the group (40 receiving TPA—33 had adenomas; and 20 not receiving TPA—18 had adenomas), whereas data on skin papillomas are derived only from the 40 animals receiving TPA promotion.

<sup>b</sup>Significantly different from control value ( $p < 0.0001$ ) as determined by chi-square test.

exact test and skin papillomas data by the Gehan-Wilcoxon-type multiple comparison test (12).

## Results

In the first experiment (Table 1), treatment with DEN resulted in a significant increase ( $p < 0.0001$ ) in the number of mice bearing lung tumors compared to the vehicle control group. The Shimkin method of counting lung adenomas was not used in this experiment, and, therefore, the total adenoma count is not available. Of the animals treated with DEN, only 13% had skin papillomas, whereas in the control group, 23% of the animals developed papillomas. This high rate may be partially attributable to the longer time to sacrifice in this experiment, but it still represents a higher rate than average for historical controls for SENCAR mice held for the same period in our laboratory (11%). This laboratory has recently started using a 2% Emulphor vehicle for oral administration of test materials requiring an organic solvent, in an attempt to alleviate this problem. These data suggest that SENCAR mice might be appropriately used in a combined skin and lung assay.

The skin and lung responses of the four strains of mice following treatment with three known carcinogens are presented in Table 2. The relative sensitivity of the different mouse strains to EC-induced lung adenomas was A/J > SENCAR = ICR > BALB/c, with the last strain displaying a very marginal response. ACR also induced lung tumors, but the sensitivity of the SENCAR and A/J mice was approximately equivalent. A very marginal response was seen in ICR mice and no lung tumors were observed in BALB/c mice. B(a)P produced an increased yield of lung tumors in the SENCAR ( $p < 0.05$ ) and A/J ( $p < 0.05$ ) strains. A slight increase in lung adenomas was seen in ICR-Swiss mice with exposure to B(a)P, but this increase was not significant. FANFT was negative for lung adenomas in all strains. Both experiments 2 and 3 produced similar lung adenoma yields in the SENCAR mouse.

Only the SENCAR skin responded positively to carcinogen administration (Table 2). The four chemicals

**Table 2. Comparison of strain sensitivities to lung adenoma and skin papilloma induction in a combined protocol following intraperitoneal treatment with known animal carcinogens.<sup>a</sup>**

Tumor	Chemical	Dose, mg/kg	Expt. 2, SENCAR	Expt. 3			
				SENCAR	BALB/c	A/J	ICR
Lung adenoma	Ethyl carbamate	300	1.38 <sup>b*</sup>	1.53*	0.14	4.92*	1.26*
	Benzo(a)pyrene	50 <sup>c</sup>	0.37	0.49†	0.02	0.56†	0.16
	FANFT	500	0.07	0.07	0.11	0.08	0.09
	Acrylamide	50	0.38	0.42†	0.05	0.43	0.10
	Emulphor (vehicle)		0.29	0.14	0.03	0.16	0.05
	Water		0.22	0.04	0.03	0.11	0.00
Skin papilloma	Ethyl carbamate	300	1.68*	0.75‡	0.08	0	0.68
	Benzo(a)pyrene	50 <sup>c</sup>	0.70 <sup>c</sup>	0.23	0	0	0.03
	FANFT	500	0.43	0.15	0	0	0.20
	Acrylamide	50	0.25‡	0.38*	0	0	0.25
	Emulphor (vehicle)		0.18	0.08	0.05	0	0.08
	Water (vehicle)		0.08	0.05	0	0	0.13

<sup>a</sup>The indicated carcinogens were administered in a single IP injection in an Emulphor or water (acrylamide) vehicle to 60 animals. Two weeks later applications of TPA were started. TPA doses varied for different strains and were applied in 0.2 mL acetone 3 times weekly for 20 weeks to the shaved backs of 40 animals in each group. SENCAR mice received 1.0 µg, BALB/c 5.0 µg, and both A/J and ICR-Swiss mice 2.5 µg of TPA per topical application 3 times weekly for 20 weeks.

<sup>b</sup>Values represent average number of tumors per animals.

<sup>c</sup>B(a)P dose for experiment 2 was 100 mg/kg.

\*Significantly different from control value ( $p < 0.01$ ) as determined by Fisher's exact test (lung adenoma) and the Gehan-Wilcoxon test (skin papilloma).

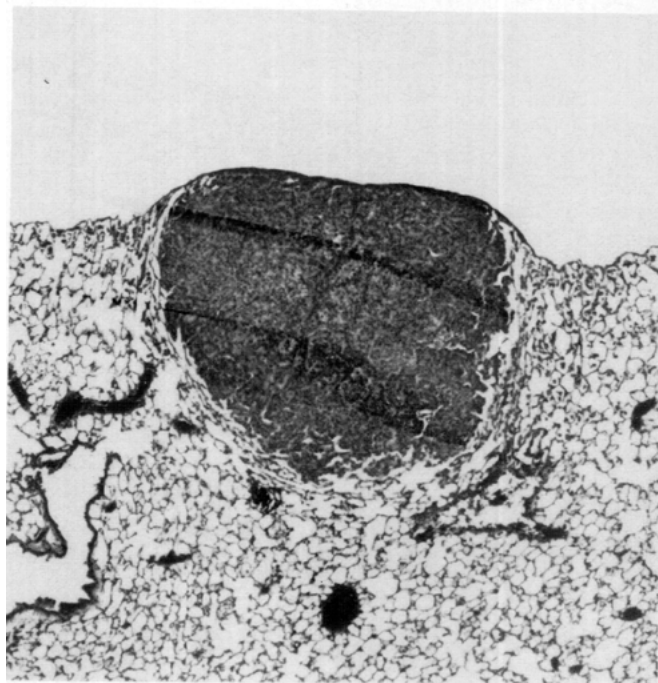
†Significantly different from control value ( $p < 0.001$ ) as determined by Fisher's exact test (lung adenoma) and Gehan-Wilcoxon test (skin papilloma).

‡Significantly different from control value ( $p < 0.05$ ) as determined by Fisher's exact test (lung adenoma) and the Cox-type trend test (skin papilloma).

used in the experiment 2 all increased the papilloma count in the SENCAR strain. In experiment 3 in the case of B(a)P, somewhat smaller responses were observed. These responses could be partially accounted for by the lower dose used in experiment 3. However, decreased responses in the experiment 3 to EC and FANFT appear to reflect variability in the model. ACR produced a small but consistent response in both the SENCAR and ICR strains. This response would ordinarily be considered negative. However, concurrent experiments at higher doses have clearly shown that acrylamide is capable of initiating skin tumors in both the SENCAR (11) and the ICR Swiss mouse (10). In the ICR-Swiss mice, only EC and FANFT increased skin tumor yields, but these yields were not significantly different from those in the control groups.

Another experiment using the same dose of TPA for all strains (1 µg three times weekly) produced similar lung responses to these chemicals (data not shown). However, at this dose of TPA, only the SENCAR skin responded to the initiators.

In experiments 1 and 3 for all animals, lesions diagnosed as primary lung tumors by the Shimkin method and all other lung lesions of questionable diagnosis based on gross examination were evaluated microscopically for confirmation, and final tumor counts were adjusted based on these findings. In the ICR-Swiss, BALB/c, and A/J strains, there was generally close diagnostic correlation between the Shimkin gross interpretation and the microscopic diagnosis. However, in the SENCAR strain, the presence of a variety of inflammatory and proliferative lesions in the lungs greatly compromised the diagnostic accuracy of the Shimkin method.



**FIGURE 1.** Alveolar bronchiolar adenoma. This photograph shows a low magnification of a solid appearing, subpleural lung adenoma typical of strain "A" tumors observed in most of the tumor-bearing SENCAR mice. ( $\times 50$ )

The morphologic features of various lung lesions observed in the SENCAR strain are demonstrated in Figures 1-5. Typical subpleural primary lung adenomas were frequently found in the SENCAR lungs in this

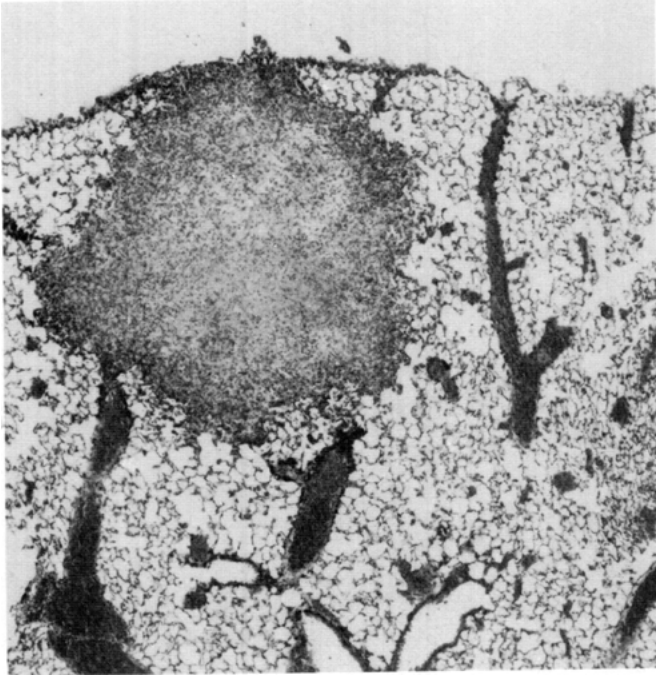


FIGURE 2. Granulomatous inflammation. This pulmonary inflammatory lesion is solid, subpleural in distribution, and had a gross presentation very similar to that of the primary lung tumor in Fig. 1. ( $\times 80$ )

study (Fig. 1). The lesion is morphologically solid in type and on gross examination presents as a raised pale tan circumscribed nodule. However, nonneoplastic lesions in the SENCAR strain interfere with the accuracy of the Shimkin method of lung adenoma counting because they often appear grossly similar to primary tumors. These lesions occur as chronic-active or granulomatous

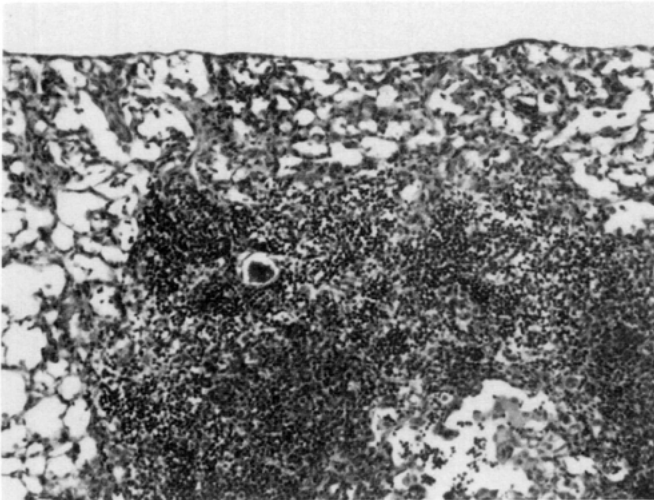


FIGURE 3. Proliferative inflammation. This inflammatory change, with an airway distribution, consisted of Type II lining cell hyperplasia and alveolar histiocytosis. Its gross appearance was very similar to that of lung tumor shown in Fig. 4. This lesion appeared to be treatment-related and toxic in origin. ( $\times 50$ )

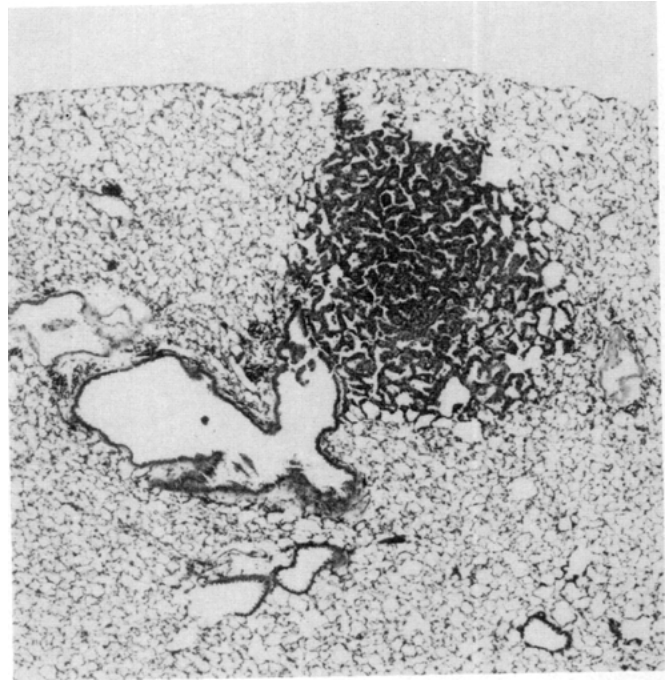


FIGURE 4. Alveolar bronchiolar adenomas. Many of the lung adenomas in the SENCAR strain were parenchymal tumors with an airway distribution. These were small, less distinct, more loosely arranged tumors making them difficult to interpret by gross observation. ( $\times 50$ )

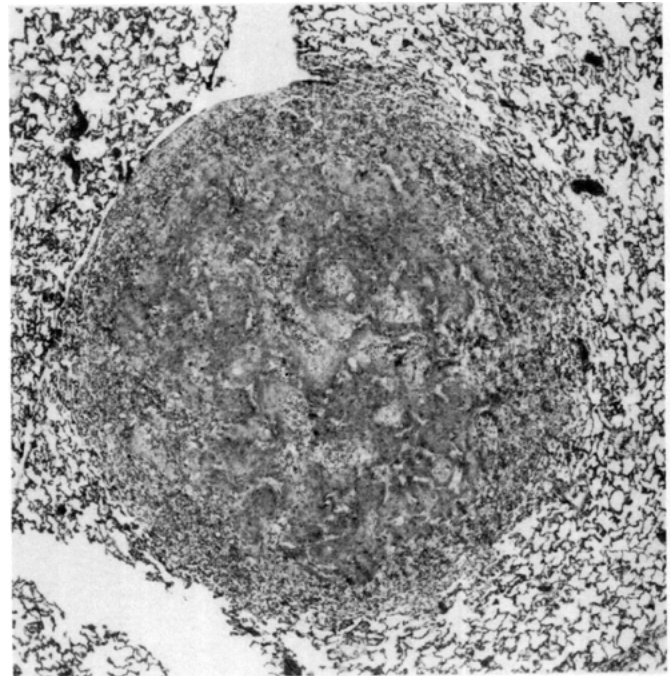


FIGURE 5. Metastatic squamous cell carcinoma. A number of these malignant skin lesions in the SENCAR mouse combined study metastasized to the lung. This well circumscribed metastases appeared very similar grossly to the primary lung tumor shown in Fig. 4. ( $\times 50$ )

inflammation (Fig. 2) and consist of alveolar lining cell hyperplasia, alveolar histiocytosis, and interstitial fibrosis with infiltration of interstitial and alveolar spaces by lymphocytes (Fig. 3). Lung tumor counting in SENCAR mice is further complicated by the size, depth, and loose arrangement of many adenomas, which makes them less easily defined on gross examination (Fig. 4), and by the presence of metastatic squamous cell carcinomas (Fig. 5) that result from the carcinogenic response in the skin.

## Conclusion

This study confirms the findings of Slaga et al. (8) that the SENCAR mouse is the most sensitive of the four strains tested for use in the skin papilloma assay. In addition, we have shown that the SENCAR strain also responds to chemical carcinogens by developing lung adenomas. However, the presence of inflammatory changes in the lungs that have a similar gross appearance as that of primary tumors makes it necessary to confirm microscopically all lung lesions in the SENCAR mouse. Although these proliferative inflammatory lesions may be treatment related, it could not be determined whether they were induced by the carcinogens used, Emulphor, or some other agent.

Although the A/J strain is the most sensitive in the lung adenoma test, it was totally nonresponsive in the skin to the chemicals tested. The BALB/c mice were also negative for these chemicals in the skin and only very marginally responsive in the lung with EC and FANFT treatments. The carcinogenic activity of the three chemicals tested in ICR-Swiss mice produced responses in both the lung and skin. However, the ICR-Swiss mice were generally less responsive than the SENCAR mice in both target organs.

It should be noted that the present study does not assess the responsiveness of the lung in the classical manner, that is, only one dose of carcinogen was administered. Repeated dosing as advocated in the original studies of Shimkin would increase the yield of lung adenomas. For example, repeated oral or intraperitoneal doses of 25 and 30  $\mu\text{g}/\text{kg}$ , respectively, of ACR 3 times weekly for 8 weeks produced approximately 1.4 and 2.2 tumors per animal, respectively, in recent studies (11).

Ideally, the application of a combined bioassay should use the responses of two target tissues to broaden the number of classes of chemical carcinogens that could be detected with either assay alone. The present experiments suggest that the SENCAR mouse does possess this advantage. This was most dramatically illustrated by the fact that DEN, generally found to be negative

in the mouse skin initiation/promotion assay, elicited a positive response in the lung of the SENCAR strain under the same experimental conditions. A similar, but less effective argument can be made with respect to the fact that the tumorigenicity of FANFT was demonstrated in the mouse skin assay (confirming earlier studies in our laboratory) but did not produce a positive response in the lung of any strain. However, the low-level response in the skin to FANFT in experiment 1 was not as apparent in experiment 2. Finally, it must be noted that the advantage gained by using a single animal in these tests must be offset by the greater difficulty in scoring lung adenoma yields in strains other than the A/J mouse. Within the context of the present study, this difficulty seems unique to SENCAR mice.

We would like to express our thanks to David Cmeil for his technical assistance in completing the bioassays and to Pat Underwood for her assistance in the preparation of this manuscript.

The research described in this article has been reviewed by the Health Effects Research Laboratory, United States Environmental Protection Agency and approved for publication. Approval does not signify that the contents necessarily reflect the views and policies of the Agency nor does mention of trade names or commercial products constitute endorsement or recommendation for use.

## REFERENCES

1. Berenblum, I. A reevaluation of the concept of carcinogenesis. *Progr. Exptl. Tumor Res.* 11: 21-30 (1969).
2. Berenblum, I., and Shubik, P. A new, quantitative approach of the study of the stages of chemical carcinogenesis in the mouse skin. *Brit. J. Cancer* 1: 373-391 (1947).
3. Boutwell, R. K. Some biological aspects of skin carcinogenesis. *Progr. Exptl. Tumor Res.* 4: 207-250 (1964).
4. Boutwell, R. K., Verma, A. K., Ashendel, C. L., and Astrup, E. Mouse skin: a useful model system for studying the mechanism of chemical carcinogenesis. *Carcinogenesis* 7: 1-12 (1982).
5. Shimkin, M. B., and Stoner, G. D. Lung tumors in mice: application to carcinogenesis bioassay. *Cancer Res.* 21: 1-58 (1975).
6. Stoner, G. D., McCloskey, E. A., and Cowan, P. B. Strain A mouse lung adenoma bioassay for chemical carcinogens. *Proceedings of the 12th Conference of Environmental Toxicology Nov. 3-5, 1981, AFAMRL-TR-81-149, 1982.*
7. Bull, R. J., and Pereira, M. A. Development of a short-term testing matrix for estimating relations carcinogenic risk. *J. Am. Coll. Toxicol.* 1: 1-15 (1982).
8. Slaga, T. J., Fischer, S. M., Triplett, L. L., and Nesnow, S. Initiation in mouse skin: tumor initiation—promotion a reliable short-term assay. *J. Am. Coll. Toxicol.* 1: 83-99 (1982).
9. Stoner, G. D., and Shimkin, M. B. Strain A mouse lung tumor bioassay. *J. Am. Coll. Toxicol.* 1: 145-169 (1982).
10. Bull, R. J., Robinson, M., and Stober, J. Carcinogenic activity of acrylamide in the skin and lung of Swiss-ICR mice. *Cancer Letters* 24: 209-212 (1984).
11. Bull, R. J., Robinson, M., Laurie, R. D., Stoner, G. D., Greisiger, E., Meier, J. R., and Stober, J. Carcinogenic effects of acrylamide in SENCAR and A/J mice. *Cancer Res.* 44: 107-111 (1984).
12. Gehan, E. A. A generalized Wilcoxon test for comparing arbitrarily singly-censored samples. *Biometrika* 52: 203-223 (1965).