



CLINICAL HOSPITAL SPLIT

## Liver Angiosarcoma and Hemangiopericytoma after Occupational Exposure to Vinyl Chloride Monomer

Izet Hozo,<sup>1</sup> Dinko Mirić,<sup>2</sup> Lovre Bojić,<sup>3</sup> Lovel Giunio,<sup>2</sup> Ivo Lušić,<sup>4</sup> Viktor Čulić,<sup>2</sup> and Miroslav Šimunić<sup>1</sup>

<sup>1</sup>Department of Gastroenterology and Hepatology, Division of Endoscopic and Ultrasound Investigation; <sup>2</sup>Department of Cardiology; <sup>3</sup>Department of Ophthalmology; and <sup>4</sup>Department of Neurology, Clinical Hospital Split, Split, Croatia

Various malignant tumors of the liver, especially liver angiosarcoma, have been described after occupational exposure to vinyl chloride monomer. We present the case records and pathologic findings of two plastic industry workers who had been exposed to high concentrations of vinyl chloride. These workers developed hepatic neoplasms, angiosarcoma, or hemangiopericytoma. We discuss the histogenesis of these tumors; the common vascular origin and the mutual transformation of these two tumors suggest that the hemangiopericytoma may also have developed during occupational exposure to high concentrations of vinyl chloride monomer. **Key words:** hemangiopericytoma, liver angiosarcoma, vinyl chloride. *Environ Health Perspect* 108:793–795 (2000). [Online 13 July 2000]

<http://ehpnet1.niehs.nih.gov/docs/2000/108p793-795hozo/abstract.html>

### Case Presentation

We analyzed the course of disease in workers involved in the manufacture and processing of polyvinyl chloride who had been exposed to high doses of vinyl chloride monomer (VCM) and who were treated at the Clinical Hospital in Split, Croatia, from 1987 to 1996. Out of 17 workers admitted in that period, we singled out the case histories of two patients whose focal lesions were established by ultrasonography and who received complete clinical examinations. The clinical examinations were performed at the Clinical Hospital in Split, and histologic findings were analyzed by the Clinical Hospital Department of Pathology.

We calculated average concentrations of VCM in the working environments of the two men on the basis of measurements performed by the Chemical Technological Laboratory (Jugovnil, Kaštel Sućurac, Hrvatska). The Chemical Technological Laboratory performed a retrospective investigation of the exposure to VCM in workers (autoclave cleaners) who were maximally exposed to VCM in a suspension polymerization plant. The investigation covered 1969–1987, when the factory was closed because it was the highest emitter of VCM in the country. The early measurements (before 1980) were performed with Dräger tubes (Dräger, Lübeck, Germany). Beginning in 1980, a Miran analyzer (Miran, Wilks, OH, USA) was used to perform measurements. Automatic sample collection occurred every

3 min from 12 positions inside the factory; VCM concentrations were qualitatively measured by infrared technology and results were printed. The majority of workers were exposed to concentrations of 300–400 ppm VCM.

One of the two patients who worked in the PVC plant was exposed to concentrations of 50–100 ppm VCM (based on periodic measurement for protection of worker's health).

**Angiosarcoma of the liver (ASL).** One patient, a male born in 1944, worked as an autoclave cleaner for 2 years (1969–1971) and from 1971 to 1973 as an autoclave foreman exposed to high concentrations of VCM (up to 1,000 ppm). The patient was admitted to the hospital in 1987 after ultrasonography, which was performed as part of a regular medical surveillance program.

The ultrasonograph revealed a focal lesion of the left lobe of the liver, which was solid, partly mixed, and contained a predominantly hyperechoic zone (10 cm in diameter, including some smaller hypoechoic areas and beams spreading radially into the adjacent parenchyma). Physical findings revealed hepatomegaly (4 cm). Laboratory findings included albumin/globulin inversion, gamma globulin of 24%, slightly prolonged prothrombin time (14 sec), and a prothrombin index of 43%. A computerized tomographic scan of the liver showed a focal lesion in the left lobe with a diameter of 10 cm and consisting of hypodense areas not

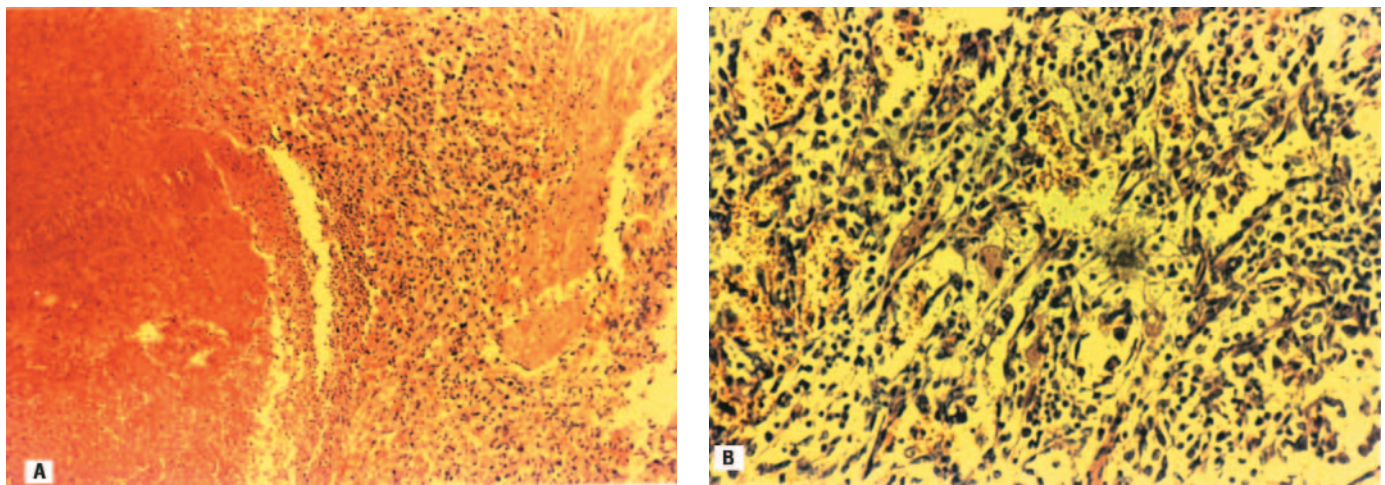
enhanced with contrast, but with a structure whose density was enhanced after contrast. The right lobe was of normal density, with homogenous absorption values.

Hepatic angiography revealed a well-vascularized structure with malignant characteristics in the left lobe (10 cm in diameter). Laparoscopy showed that the right liver lobe was dark red with livid hues, whereas the left lobe was completely invaded with adhesions. The patient was referred to a surgeon who performed partial resection of the liver. The left lobe with tumorous tissue was resected deep into the healthy parenchyma. Histologic analysis suggested angiosarcoma of the liver (Figure 1); dense rows of tumorous cells (Figure 1A) can be seen near the areas of hemorrhage, and the vascular space of the tumor is lined with atypical endothelium, marked sarcomatous stroma, dense rows of tumorous cells with distinct polymorphism, and hyperchromatosis (Figure 1B).

**Hemangiopericytoma of the liver.** The second patient was born in 1937 and worked for 7 years processing PVC powder with concentrations of 50–100 ppm of VCM. This patient was admitted to the hospital because of cachexia, enlarged lymph nodes of the neck, and septic temperatures. The findings included an erythrocyte sedimentation rate of 63 mm/hr, alkaline phosphatase of 610 U/L, prothrombin time of 19 sec, with an international normalized ratio of 3.1 (normal values 0.9–1.2). Ultrasonography revealed a large tumor in the left liver lobe (diameter of 16 cm) with ultrasonic characteristics of a mixed tumor with hyperechoic and hypoechoic islets and expansion into adjacent tissue. A biopsy of the liver was not performed because of coagulopathy. A chest X ray showed disseminated metastatic infiltration in the form

Address correspondence to I. Hozo, Department of Gastroenterology and Hepatology, Clinical Hospital Split, Pujanke 57/VI, 21 000 Split, Croatia. Telephone/fax: 385 21 376 304. E-mail: Izet.Hozo@st.tel.hr

Received 12 October 1999; accepted 20 April 2000.



**Figure 1.** Photomicrograph of the liver angiosarcoma (hemalaun-eosin stain) from a VCM-exposed worker. (A) Magnification  $\times 79$ . (B) Magnification  $\times 200$ .

of seals of varying size. The histologic findings of an extirpated lymph node confirmed the diagnosis of hemangiopericytoma (Figure 2A). The patient died shortly afterward, and the patient's relatives did not permit an autopsy. The tumor tissue was formed by an accumulation of atypical pericytes mostly arranged in rows on the outer side of the vessel. In places, the tumor cells appeared anaplastic, with numerous pathologic mitoses and large areas of necrosis (Figure 2A). After silver staining, reticulin fibers are visible (Figure 2B).

## Discussion

The toxic effects of vinyl chloride monomer (VCM) on the livers of plastic-industry workers was first noted in 1948 by Tribukh (1), and the full attention of the public dates back to 1974, when Creech and Johnson (2) reported angiosarcoma of the liver (ASL) in two plastic-industry workers. Angiosarcoma is a rare tumor with an incidence of 1:7,000,000 inhabitants; a clear excess of cases in vinyl chloride workers reported by Lee et al. (3) offered firm epidemiologic proof of the carcinogenic effects of VCM. Viola (4) exposed guinea pigs to high concentrations of VCM and established the various forms of malignancy, including liver angiosarcoma. Up to 1984, 114 patients with ASL were registered by the Association of Plastic Manufacturers in Europe, and over the next three decades, 300 new patients can be expected in Europe and up to 1,200 can be expected in the United States (5).

Since 1975, after the discoveries of Creech and Johnson (2), some countries have accepted rigorous regulations on the emission of VCM (below 1 ppm) in the working environment (6–8) to prevent occupationally induced liver damage. In Croatia, the regulations in 1971 allowed 75 ppm VCM in the work environment. This was

valid until recently, in contrast with the minimal dose for VCM (1 ppm in work area) accepted in developed countries (9).

Popper and colleagues (10–11) and Gedigt et al. (12) described the histology of liver angiosarcoma and the presumed scheme of development of liver angiosarcoma. Proliferation of sinusoidal cells and sinusoidal dilatation leads to atypical hyperplasia, whereas direct stimulation of hepatocytes with VCM leads to the proliferation of hepatocytes and formation of regenerative nodules (10–12).

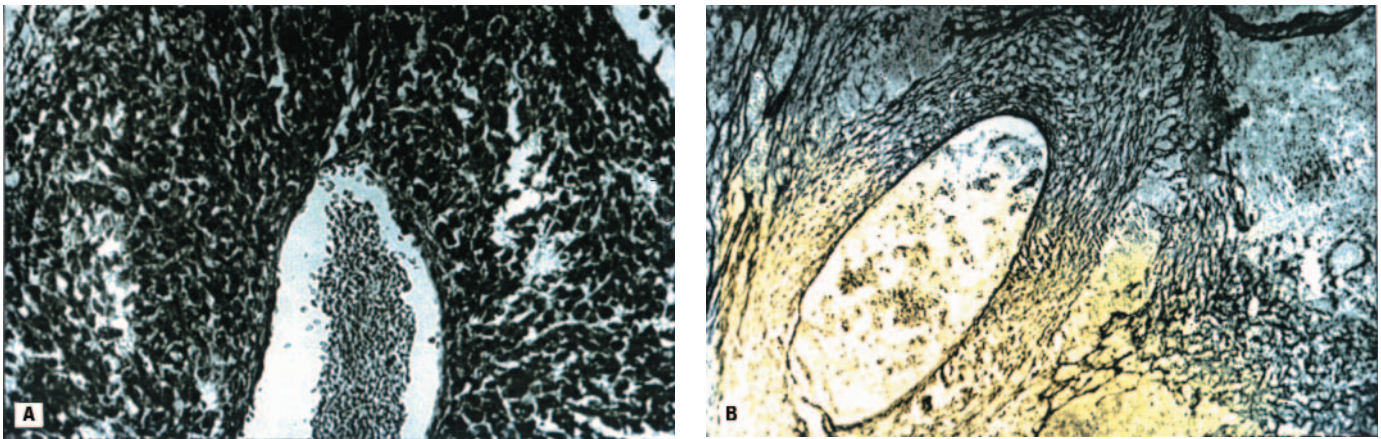
Zorica et al. (13) noted angiosarcoma of the liver in workers in the plastic plant (Jugovinil, Kaštel Sućurac, Croatia) 1 year after the discovery by Creech and Johnson (2). Since then 12 cases of ASL have been registered in that factory (14–16). To help with the early discovery of liver lesions and diagnosis of ASL, a secondary prevention program with medical surveillance programs and screening tests has been instituted. However, it has been generally accepted that primary prevention of occupationally related cancers depends on recognizing the risk and then educating the employers and employees about the practical steps to eliminate or reduce exposure; the best prevention method is the introduction of regulations on VCM emissions in the workplace (9).

**ASL.** Popper and colleagues (10,11) and Gedigt et al. (12) have undoubtedly provided the greatest contribution in the study of the histogenesis and pathohistology of ASL. The onset of angiosarcoma usually includes proliferation of sinusoidal cells and sinusoidal dilatation leading to atypical hyperplasia, whereas direct stimulation of hepatocytes with VCM leads to proliferation of hepatocytes, formation of regenerative nodules, and development of hepatoma (12). Tumors may also occur in papillary form, growing into adjacent tissue and occasionally forming large

cavernous spaces as a result of greatly dilated sinusoids as the dominant feature. In a typical histologic picture, there are wide vascular spaces and systems of anastomosed vessel canals lined with atypical endothelium, with marked sarcomatous stroma (17–20). The histologic finding of ASL in our patient (Figure 1) shows large vascular spaces lined with atypical vascular epithelium and with polymorphism and hyperchromatism of cells. This is in complete agreement with the description of ASL in the literature (11,12). This patient's medical history is characteristic for at least two reasons: *a*) there was a relatively brief period of occupational exposure to VCM, and *b*) the tumor developed 15 years after the 4-year occupational exposure to high VCM concentrations, although after the exposure, the patient was transferred to a job where no VCM emissions occurred (transport worker). This is in agreement with the view that the length of occupational exposure is not decisive and that there is no definitive latency until the onset of tumor: the only essential condition is the increased concentration of VCM in the work environment. ASL developed without any symptoms or gradation (hepatitis, fibrosis, cirrhosis, angiosarcoma). The patient did not complain of subjective discomfort at admittance, nor did he seem seriously ill. There were no significant aberrations in laboratory findings. Once initiated, the process of histogenesis of the tumor is irrepressible, regardless of further occupational exposure to VCM (21).

**Hemangiopericytoma of the liver.** Hemangiopericytoma is a rare malignant tumor formed from pericytes winding around the capillaries (17). The tumor is ubiquitous, but is very rarely found in the liver (22). Hemangiopericytoma metastasizes in approximately 12% of cases. Otherwise, it grows rather slowly, displacing the adjacent structures and causing little discomfort.





**Figure 2.** Photomicrograph of the haemangiopericytoma (hemalaun-eosin stain) from the lymph node of a VCM-exposed worker. (A) Magnification  $\times 200$ . (B) Details of the same tumor (hemalaun-eosin impregnated with silver). Magnification  $\times 200$ .

Hemangiopericytoma most commonly spreads through lymphatics. The histogenesis of hemangiopericytoma has not been sufficiently explained. Hemangiopericytoma is characterized by rich vascular tissue consisting of endothelial canals surrounded by spindle-shaped, oval, or rounded cells with marked nuclei; cells are arranged around the basal membrane of collapsed capillaries and preserved reticulin stroma. In the case of angiosarcoma, endothelial cells proliferate and break off the reticulin stroma (17). Histologic examination of our patient's liver revealed tumorous tissue formed from atypical pericytes, mostly arranged around the walls of the blood vessels. Tumorous cells in some sites assumed anaplastic appearance, with numerous mitoses and marked fields of necroses (Figure 2). Because pericytes are separated from endothelial cells only by the basal membrane, there is reciprocal transition of pericytes into endothelial cells and vice versa, which may suggest a causal interrelationship between hemangiopericytoma and angiosarcoma (23). Increased cellularity and intensive mitotic activity, in addition to areas of necrosis and hemorrhage, are characteristic of malignant hemangiopericytoma (23). The highest degree of malignancy is shown particularly by areas of necrosis in the same tumor.

## Conclusion

The interrelationship of these two types of tumors, their common (vascular) etiology, and occupational exposure to increased VCM concentrations in both patients lead to the conclusion that the onset of hemangiopericytoma (probably primarily in the liver) may be associated with long-term occupational exposure to VCM. This possibility is important because during exposure to VCM, not only ASL but other tumors of similar

(vascular) origin can develop. Also, for workers exposed to VCM in the secondary processing of polyvinyl chloride powder, the risk of developing ASL or hemangiopericytoma cannot be excluded. This powder contains some residual VCM, even after the stripping process (i.e., removal of VCM) (9). It is important to provide systematic preventive checkups for workers involved in the secondary manufacture of polyvinyl chloride products.

In most patients with liver tumors after exposure to VCM, the diagnosis is established late, treatment is generally unsatisfactory, and death ensues within a few months. Segmental liver resection or liver transplantation offers the best hope, but is suitable in only a minority of cases. Continuous preventive checkups for these patients after early VCM exposure may have alerted physicians to the development of their tumors and enabled timely surgical treatment, providing better prognoses.

## REFERENCES AND NOTES

1. Tribukh SI. Working conditions and measures of sanitation in production and utilisation of vinyl chloride plastics. *Gig Sanit* 10: 380 (1949).
2. Creech JL, Johnson MN. Angiosarcoma of the liver in the manufacture of polycinyl chloride. *J Occup Med* 16:150–151 (1974).
3. Lee FI, Smith PM, Bennett B, Williams DM. Occupationally related angiosarcoma of the liver in the United Kingdom 1972–1994. *Gut* 39: 312–318 (1996).
4. Viola PA. Pathology of VCM. *Med Lavoro* 61:174–180 (1970).
5. Forman D, Bennet B, Stafford J, Doll R. Exposure to vinyl-chloride and angiosarcoma of the liver—a report of the register of cases. *Brit J Ind Med* 42:750–753 (1985).
6. HSC. Threshold Limit Values for 1977. Guidance Notes from the Health and Safety Executive. London:Health and Safety Commission, 1977.
7. CEC. Council directive of 29 June 1978 on the approximation of the laws, regulations and administrative provisions of the Member States on the protection of the health of workers exposed to vinyl chloride monomer. *Off J Eur Communities* L197:12–18 (1978).
8. U.S. EPA. Scientific and Technical Assessment Report on Vinyl Chloride and Polyvinyl Chloride. EPA 600/6-75-004. Research Triangle Park, NC:U.S. Environmental Protection Agency, 1975.
9. Barr J. Safety and environmental concern in resin manufacture. In: *Encyclopedia of PVC*, 2nd ed (Nass LI, Heiberger CA, eds). New York:Marcel Dekker, 1986:293–307.
10. Popper H, Thomas L. Alterations of liver and spleen among workers exposed to vinyl chloride. *Ann N Y Acad Sci* 246:172–194 (1975).
11. Popper H. Pathology of angiosarcoma of the liver among vinyl chloride-polyvinyl chloride workers. *Ann N Y Acad Sci* 246:268–277 (1975).
12. Gedigk P, Mueller R, Bechtelheimer H. Morphology of liver damage among polyvinyl chloride production workers. A report on 512 cases. *Ann N Y Acad Sci* 246:278–285 (1975).
13. Zorica M, Šarić M, Konstantinović M, Kovač I. Two cases of angiosarcoma of the liver after exposition to vinyl chloride monomer. *Arh Hig Rada* 26:275 (1975).
14. Hozo I, Miše S, Rumboldt Z, Perić G, Biliškov J, Alfrević D, Stojan R. Tumori jetre u ekpoziciji vinilklorid monomeru: novi slucajevi angiosarkoma jetre [in Serbo-Croatian]. *Liječ Vjesn* 115:347–350 (1993).
15. Hozo I, Anđjelinić S, Ljutić D, Gojic L, Mirić D, Giunio L. Two new cases of liver angiosarcoma: history and perspectives of liver angiosarcoma among plastic industry workers. *Toxicol Ind Health* 13:639–647 (1997).
16. Hozo I. Sociomedical and Clinical Aspects of Liver Lesions by the Workers in Plastic Industry [Dissertation]. Sarajevo, Bosnia-Herzegovina:Medical Faculty Sarajevo, 1989.
17. Ashley DJB. Tumors of vasoformative tissue. In: *Evans' Histological Appearances of Tumours* (Ashley DJB, ed). Edinburgh:Churchill Livingstone, 1987:77–84.
18. Summer HW, Rosai J. Liver. In: *Ackerman's Surgical Pathology*, 6th ed (Rosai J, ed). St. Louis:Mosby, 1981:632–635.
19. Titus JL, Han-Seob K. Blood vessels and lymphatics. In: *Anderson's Pathology*, 8th ed (Kisane JM, ed). St. Louis: Mosby, 1985:724–729.
20. Robbins S, Cotran R, Kumar V. The liver and biliary tract. In: *Pathologic Base of Disease* (Robbins S, Cotran R, Kumar V, eds). Philadelphia, PA:WB Saunders, 1984:924–927.
21. Berk P, Martin J, Waggoner J. Persistence of vinyl chloride injury after cessation of exposure. *Ann N Y Acad Sci* 246:70–77 (1975).
22. Thapa BR, Narashuimarao KL, Marwaha RK, Walia BN, Bannerjee CK, Mitra SK, Pathak IC. Malignant hemangiopericytoma of liver. *Indian Pediatr* 23:551–553 (1986).
23. Hulberg BM, Daugaard S, Johansen HF, Mouridsen HT, Houjensen K. Malignant haemangiopericytomas and haemangioendotheliosarcomas—an immunohistochemical study. *Histology* 12:404–414 (1988).