

# The *p53* Heterozygous Knockout Mouse as a Model for Chemical Carcinogenesis in Vascular Tissue

Neil G. Carmichael, Eric L.M. Debruyne, and Dominique Bigot-Lasserre

Rhône-Poulenc Agro, Centre de Recherche, Sophia Antipolis, France

Heterozygous *p53* knockout mice were investigated as a potential model for vascular tumor carcinogenesis. Groups of 20 male mice were exposed by gavage for 6 months to the vascular carcinogen urethane at 1, 10, or 100 mg/kg body weight/day. Wild-type and heterozygous *p53* knockout control groups were exposed by gavage to the vehicle alone. Another group of 20 male mice received *d*-limonene by gavage (*d*-limonene is noncarcinogenic in mice). The high dose of urethane caused early mortality in the majority of mice associated with histopathologic evidence of toxicity and tumors, including a high incidence of benign and malignant vascular tumors, in all animals. At the intermediate dose, toxicity was less marked and 3 of 20 mice had tumors; mice that received the low dose did not have signs of toxicity or neoplasia. The two control groups had no tumors and the *d*-limonene group had one tumor of the prostate, which was considered spontaneous. We conclude that the *p53* knockout mouse is a useful tool for investigating vascular tumorigenesis. **Key words:** carcinogenicity models, *p53* knockout mouse, vascular tumors. *Environ Health Perspect* 108:61–65 (2000). [Online 14 December 1999] <http://ehpnet1.niehs.nih.gov/docs/2000/108p61-65carmichael/abstract.html>

The *p53* knockout mouse is the subject of great interest for its potential as a tool to study chemical carcinogenesis. The heterozygote could be used in carcinogenicity testing strategies that would potentially reduce the number of full-scale lifetime studies in conventional mouse models (1,2). Because heterozygous *p53* knockout mice should be more sensitive to carcinogens than normal mice, such rodent bioassays would use fewer animals and take less time. Furthermore, because heterozygous *p53* knockout mice have a low incidence of tumors until 9–12 months of age, it should be easier to identify the treatment-related effects of chemicals in a mouse strain with a low background of spontaneous cancers (3,4). After 12 months of age, the rate of tumor development accelerates and by 18 months of age, 50% of the heterozygous mice have succumbed to tumors, mainly osteosarcomas, malignant lymphomas, and hemangiosarcomas. Therefore, 6 months is a suitable test duration; the expected yield of spontaneous tumors should be low.

Mice, as with other experimental species, have a strain-dependent profile of tumor types. Hepatocellular tumors are common in many strains of mice and are the subject of much discussion with respect to their relevance in carcinogen evaluation (5,6). Lung tumors and lymphoreticular tumors are also relatively common. Although vascular tumors are also found, they usually occur at a relatively low incidence (7,8). The most commonly found tumors in *p53* homozygous and heterozygous knockout mice are sarcomas, malignant lymphomas, and hemangiosarcomas (4).

Vascular tumors are increased in the mouse by relatively potent chemical carcinogens such as vinyl chloride (9). Because of the nature of vascular tissue, which does not lend itself easily to mechanistic studies, little is known about the susceptibility of this tissue.

To explore the potential of the *p53* knockout mouse for studying vascular tumors we selected the genotoxic compound urethane, which produces these tumors in lifetime studies in mice. Urethane, which is genotoxic via the formation of a reactive electrophilic metabolite, vinyl carbamate epoxide (10), has well-documented carcinogenic activity in rodent models; studies date back more than 20 years (11). Urethane was previously used as an anesthetic, but is also a natural compound found in low concentrations in many fermentation products (12).

One of the assumptions with the knockout model is that a mutation at the intact *p53* allele is necessary for development of the carcinogenic process. In principle, nongenotoxic compounds that induce tumors by other mechanisms should be negative in this system. Therefore, *d*-limonene, which is neither genotoxic nor carcinogenic in mice but is carcinogenic in the male rat by a nongenotoxic mechanism (13–15), was included as a negative control substance.

The criteria established for assessing the usefulness of this model were zero incidence of vascular tumors in untreated *p53* knockout mice, untreated wild-type mice, and in *d*-limonene-treated *p53* knockout mice (at 6 months); a high incidence of vascular tumors in *p53* knockout mice that receive a toxic dose of urethane; and a dose-related decrease

in vascular tumors in *p53* knockout mice with lower doses of urethane.

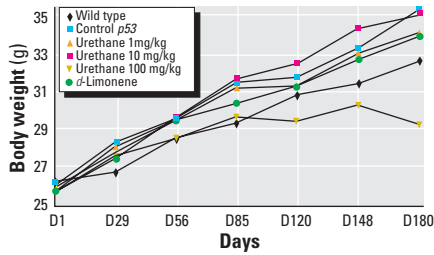
## Materials and Methods

Heterozygous *p53* knockout mice (C57Bl/6Tac-[KO] *Trp53*N5-T) and wild-type (C57Bl/6Tac-[KO] *Trp53*N5-W) mice were purchased from Taconic (Germantown, NY). These mice are derived from a chimera based on two inbred strains (129/Sv × C57Bl/6) (16). Four groups of 20 male heterozygous *p53* knockout mice (*p53*<sup>+/-</sup>), 8 weeks of age at the start of treatment, were dosed daily by gavage [5 mL/kg body weight (bw)] with urethane at 1, 10, and 100 mg/kg/day, respectively, or with *d*-limonene at 250 mg/kg/day for at least 180 days. These dose levels were based on published mouse bioassay data (17–19). Two control groups of 20 mice each, one heterozygous *p53* knockout mouse (*p53*<sup>+/-</sup>) and one wild type (*p53*<sup>+/+</sup>), received vehicle alone for the same period of time. Urethane (batch 125H0318, a white powder of 100% purity) and *d*-limonene (batch 075H3530, a colorless liquid of 99.4% purity) were suspended or diluted in 0.5% methylcellulose and 0.2% Tween 80 in sterile water. Urethane and *d*-limonene were purchased from Sigma Chemical Company (St. Louis, MO). The methylcellulose and Tween 80 were purchased from Fluka (Buchs, Switzerland).

The animals were checked daily for clinical signs, moribundity, and mortality. Detailed physical examinations were performed weekly during the treatment period. Body weight and food consumption were measured weekly during the first 14 weeks and monthly thereafter. All animals were necropsied; adrenal gland, brain, heart, kidney, liver, spleen, testis, and thymus were weighed fresh at final sacrifice only. The tissues (adrenal glands, aorta, articular surface, bone, bone marrow, brain, cecum, colon, duodenum, epididymides, esophagus, eyes, gallbladder, Harderian glands, heart, ileum, jejunum, kidneys, larynx, liver, lung, mammary gland, mesenteric lymph nodes, ovaries, pancreas,

Address correspondence to N.G. Carmichael, Rhône-Poulenc Agro, Centre de Recherche, 355 rue Dostoievski, B.P. 153, F-06903 Sophia Antipolis Cedex, France. Telephone: 33 4 92 94 34 02. Fax: 33 4 93 65 41 39. E-mail: neil.carmichael@sophia.rhone-poulenc.com

Received 11 February 1999; accepted 19 August 1999.



**Figure 1.** Body weight curves: mean body weight of the urethane-treated (1, 10, or 100 mg/kg bw/day), *d*-limonene-treated (250 mg/kg bw/day) or vehicle control-treated heterozygous *p53* knockout mice as compared to vehicle control-treated wild-type mice over the 6-month study period.

parathyroid glands, pituitary gland, prostate, rectum, sciatic nerve, seminal vesicles, skeletal muscle, skin, spinal cord, spleen, stomach, submaxillary glands, submaxillary lymph nodes, testes, thymus, thyroid glands, tongue, trachea, urinary bladder, uterus, vagina, and all gross lesions detected at necropsy) were fixed in 10% neutral buffered formalin with the exception of the eyes, Harderian glands, testes, and epididymides; these were fixed in Davidson’s fixative (20). All of the standard protocol tissues (with the exception of the larynx) were embedded in paraffin wax, sectioned at 5 μm, and stained with hematoxylin and eosin for routine light microscopic histopathologic examinations.

During the study, the care and use of animals were in accordance with regulations of the Guide for the Care and Use of Laboratory Animals (21) and the directive 86/609/CEE (22).

**Results**

***p53* Knockout Mice Versus Wild-Type Mice**

The body weight of the *p53* knockout mice was higher than the body weight of wild-type animals from the end of the first week of the study (Figure 1). This difference, which ranged between 3 and 8%, was statistically significant during most of the study

**Table 1.** Group-related summary table for time of death, significant gross findings at necropsy, and factors that contributed to the death of animals either found dead or sacrificed moribund.

Treatment group	Animal no.	Time of death (day on study)	Major gross findings	Factors that contributed to death
Wild type/vehicle control	HT1M0655	36	Accidental	None
<i>p53</i> <sup>+/-</sup> /vehicle control	HT2M0681	44	None identified	None
<i>p53</i> <sup>+/-</sup> /urethane, 10 mg/kg/day	HT4M0731	156	Intrathoracic cloudy fluid Markedly large thymus	M: lymphoma, thymus (widespread metastases)
	HT4M0735	54	Thoracic hemorrhage	None identified
	HT5M0736	153	Abdominal hemorrhage	M: hemangiosarcoma, spleen B: hemangioma, liver M: hepatocellular carcinoma
	HT5M0737	139	Intrathoracic clear fluid	M: lymphoma, thymus Markedly large thymus
	HT5M0738	175	Abdominal hemorrhage Liver: red foci	B: hemangioma, liver
	HT5M0740	176	Liver: red spots	Hepatocyte necrosis, liver M: hemangiosarcoma, liver
	HT5M0742	172	Liver: red spots Stomach: erosions	B: hemangioma, liver M: hepatocellular carcinoma
	HT5M0743	104	Thoracic hemorrhage Thymus: mass	M: lymphoma, thymus (widespread metastases)
	HT5M0744	174	Liver: red areas Abdominal hemorrhage	B: hemangioma, liver M: hepatocellular carcinoma
	HT5M0745	177	Abdominal and thoracic hemorrhage	Hepatocyte necrosis, liver B: hemangioma, liver
HT5M0746	120	Abdominal hemorrhage Liver: red areas	B: hemangioma, liver M: hemangiosarcoma, liver	
HT5M0747	141	Abdominal hemorrhage Liver: red masses	B: hemangioma, liver Hepatocyte necrosis, liver	
HT5M0749	159	Abdominal hemorrhage Liver: red areas	M: hemangiosarcoma, liver M: hepatocellular carcinoma Hepatocellular necrosis, liver	
HT5M0750	126	Subcutis: bleeding mass Liver: red spots	M: sarcoma, subcutis M: hemangiosarcoma, liver	
HT5M0751	139	Abdominal hemorrhage Liver: red masses; red spots	M: sarcoma, subcutis M: hemangiosarcoma, liver	
HT5M0752	163	Abdominal hemorrhage Liver: red masses	B: hemangioma, liver Hepatocellular necrosis, liver	
HT5M0753	153	Abdominal hemorrhage Liver: red masses	B: hemangioma, liver Hepatocellular necrosis, liver B: hemangioma, heart	
HT5M0754	177	Abdominal hemorrhage Liver: red spots	B: hemangioma, liver M: hemangiosarcoma, liver Hepatocellular necrosis	
HT5M0755	177	Markedly large thymus Liver: red spots	M: hemangiosarcoma, abdominal fat M: lymphoma, thymus (widespread metastases) M: hemangiosarcoma, liver M: hemangiosarcoma, liver	
<i>p53</i> <sup>+/-</sup> / <i>d</i> -limonene, 250 mg/kg/day	HT6M0767	56	Kidneys: white nodules	Pyelonephritis, severe, kidneys Myocarditis, mild, heart

Benign tumors are distinguished by the letter B and malignant tumors by the letter M.

and was related, in part, to differences in food consumption between the heterozygous *p53* knockout versus wild-type mice.

In this study, there were no differences in organ weight or gross findings at necropsy between the untreated *p53* knockout mice and their wild-type counterparts. Microscopic examinations revealed midzonal hepatocyte fatty change characterized by the accumulation of intracellular large vacuoles in 25% of the *p53* knockouts as compared to 0% in the wild type. In the kidney, 20% of the *p53* knockout mice showed minor degenerative changes (cortical basophilic tubules) or inflammatory changes (peripelvic mononuclear cell infiltrates) as compared to 10 and 5%, respectively, in the wild-type mice. Focal epithelial hyperplasia of the prostate was noted in 20% of the *p53* knockout mice as compared to none in the wild type. Mononuclear cell infiltrate of the pancreas was noted in 25% of the *p53* knockout mice as compared to 5% in the wild type. No neoplastic changes were noted in the untreated *p53* knockouts or in the wild-type mice.

### Urethane Treatment: *p53* Knockout Mice

**Clinical observations, mortality, and necropsy.** The highest dose of urethane tested (100 mg/kg bw/day) was toxic from the fourth month in the study, and it had significant effects on body weight (Figure 1). At 100 mg/kg bw/day, the mean body weight was 5.5% lower than the vehicle control animals from day 85 of the study; this difference reached up to 15% at the end of the study. By the end of the 6-month exposure period, 17 of the 20 mice at this dose had died or

had been sacrificed moribund (Table 1). The probable cause of death in the highest dose group was internal hemorrhage related to and most likely secondary to vascular tumors (Table 1). Although a few sporadic deaths were noted in other groups, these were considered unrelated to treatment and did not exceed 2 of 20 in any group. At necropsy, all of the high-dose urethane *p53* knockout mice presented with masses or red colored spots on the liver. Dark fluid, presumably blood, was often present in the abdominal and/or thoracic cavities in animals that died. Ten of 20 mice had enlarged spleens. Other changes noted at necropsy in the high-dose urethane *p53* knockout mice included red spots on the stomach mucosa and/or markedly large thymus in a small proportion of mice. Mice treated with urethane at 1 or 10 mg/kg bw/day showed no obvious differences from control during the live phase of the study. At necropsy of the 10 mg/kg bw/day group, 8 of 20 mice of had red spots on the liver, dark fluid was noted in the thoracic cavity of two mice, and an enlarged spleen in two mice. No significant organ weight changes were noted at this dose level. At 1 mg/kg/day only one mouse had a red spot on the liver.

**Histopathology (Table 2). Vascular system.** We noted nonproliferative vascular changes in a high proportion of mice treated with the two higher dose levels of urethane. Angiectasis, consisting of dilated vascular spaces lined by endothelial cells and filled with erythrocytes, was present in the liver of 8 of 20 and 9 of 20 *p53* knockout mice at 10 and 100 mg/kg/day, respectively. A single focus of angiectasis was also noted in the

perirenal fat of one high-dose urethane mouse. Proliferative vascular changes consisting of hemangiomatous-like endothelial hyperplasia were present in the liver of 2 of 20 mice and in the heart of a single mouse from the 100 mg/kg/day urethane group. Neoplasms of the vasculature, benign hemangioma (Figure 2), and/or malignant hemangiosarcoma (Figure 3) were noted in the liver of a total of 18 (90%) mice treated at 100 mg/kg/day urethane (Table 2). Of the mice from the 100 mg/kg/day urethane group, we found hemangiomas in 70%, hemangiosarcomas in 40%, and both hemangioma and hemangiosarcoma in 20%. These vascular tumors were generally multiple, affecting a large surface area of the liver section. Large thrombi were generally associated with the presence of vascular neoplasms. At this dose level, single occurrences of hemangiosarcoma were noted in the spleen and in the abdominal cavity and a hemangioma was present in the heart of a single mouse. In the 10 mg/kg/day group, multiple hemangiomas were noted in the liver of a single treated *p53* knockout mouse. These changes were generally correlated with the gross observations made at necropsy. At 1 mg/kg/day, no vascular changes of any type were detected at microscopic examination of any of the organs examined.

**Liver.** At 100 mg/kg/day urethane, we noted large areas of hepatocyte zonal necrosis affecting essentially the centrilobular or midzonal areas (functional zones 1 and 2) of the hepatic lobules in 70% of the heterozygous *p53* knockout treated mice. These degenerative changes, which were located in the liver parenchyma not affected by the presence of tumors, were sometimes associated with signs of regeneration of hepatocytes such as marked cytomegaly or increased number of mitotic figures. Foci of cellular alteration, eosinophilic type, were noted in 10% of the treated mice. Oval cell hyperplasia was also noted in 10% of the mice at this dose level. Hepatocellular carcinomas, which are closely associated with hemangioma or hemangiosarcoma, were diagnosed in 20% of the mice treated at 100 mg/kg/day. Foci of cellular alteration, clear cell type, were noted in 30%, midzonal hepatocyte fatty change in 35%, and hepatocyte hypertrophy in 20% of the 10 mg/kg/day treated mice. No significant liver changes were noted in the 1 mg/kg/day group.

**Thymus.** We found malignant lymphomas (Figure 4) in 1 of 20 (5%) and 3 of 20 (15%) of the mice treated at 10 and 100 mg/kg/day, respectively. These neoplasms, originating in the thymus, were spreading to other tissues (liver, kidney, lung, spleen, heart, adrenal gland, sternum, subcutis, aorta, and spinal cord). Six (30%) of the 100 mg/kg/day

**Table 2.** Incidence summary table for the number of animals affected by selected microscopically observed lesions.

Vascular tissue	Wild-type vehicle <sup>a</sup>	<i>p53</i> <sup>+/-</sup> vehicle <sup>a</sup>	<i>p53</i> <sup>+/-</sup> urethane <sup>b</sup>	<i>p53</i> <sup>+/-</sup> urethane <sup>c</sup>	<i>p53</i> <sup>+/-</sup> urethane <sup>d</sup>	<i>p53</i> <sup>+/-</sup> <i>d</i> -limonene <sup>e</sup>
Endothelial proliferation, liver	0	0	0	0	2	0
Angiectasis, liver	0	0	0	8	9	0
B: hemangioma, liver/heart	0	0	0	1	14	0
M: hemangiosarcoma, liver, spleen/abdominal cavity	0	0	0	0	8	0
Benign and/or malignant tumors	0	0	0	1	18	0
M: lymphomas, lymphoreticular tissue	0	0	0	1	3	0
B: adenoma, lung	0	0	0	0	5	0
M: sarcoma, subcutis	0	0	0	1	1	0
Focus of cellular alteration, eosinophilic, liver	0	0	0	0	2	0
Focus of cellular alteration, clear cell, liver	0	0	0	6	0	0
M: hepatocellular carcinoma, liver	0	0	0	0	4	0
Oval cell proliferation, liver	0	0	0	0	2	0
Retinal atrophy, bilateral, eyes	0	0	0	0	12 <sup>f</sup>	0
B: adenoma, prostate	0	0	0	0	0	1
Tumor-bearing animals <sup>g</sup>	0	0	0	3	20	1

Twenty animals per group were available for microscopic examinations. Benign tumors are distinguished by the letter B and malignant tumors by the letter M.

<sup>a</sup>Dose level 0 mg/kg/day. <sup>b</sup>Dose level 1 mg/kg/day. <sup>c</sup>Dose level 10 mg/kg/day. <sup>d</sup>Dose level 100 mg/kg/day. <sup>e</sup>Dose level 250 mg/kg/day. <sup>f</sup>Only 13 animals were available for the eye in the 100 mg/kg/day group. <sup>g</sup>All types of tumors.

mice had generalized atrophy/involution of the thymus as did one mouse at 10 mg/kg/day. Cortical lymphocytolysis/apoptosis was noted in 5 (25%) of the mice that received 100 mg/kg/day. No changes were noted at 1 mg/kg/day.

**Lung.** We found bronchioloalveolar adenomas (Figure 5) in 5 mice (25%) treated at 100 mg/kg/day. Interstitial mononuclear cell infiltrate of the pulmonary parenchyma was noted in 15 of 20 (75%) of the mice at the same dose level. No significant changes were found at 10 and 1 mg/kg/day.

**Subcutis.** A large subcutaneous sarcoma was present in a single *p53* knockout mouse treated at 10 mg/kg/day and in one treated at 100 mg/kg/day.

**Testis.** Twenty-five percent of the mice from the 10 and 100 mg/kg/day group had diffuse atrophy of the seminiferous tubules.

**Eye.** Twelve of 13 (92%) of the mice treated with urethane at 100 mg/kg/day had bilateral retinal atrophy consisting of the complete loss of the bacillary, outer nuclear, and outer plexiform layers of the eye.

### *d*-Limonene Treatment: *p53* Knockout Mice

**Clinical observations, mortality, and necropsy.** No significant changes were found in the *d*-limonene-treated *p53* knockout mice as compared to the untreated control group.

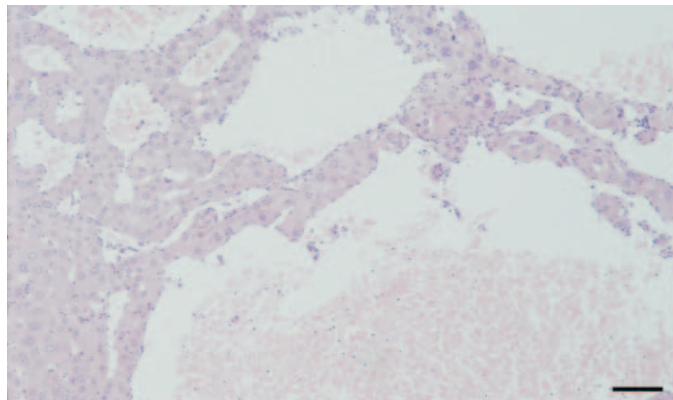
**Histopathology.** We observed hyperplasia of the nonglandular stomach in 85% of the *d*-limonene-treated *p53* knockout mice. With the exception of a single adenoma of the prostate, no neoplasms were observed in this dose group.

### Discussion

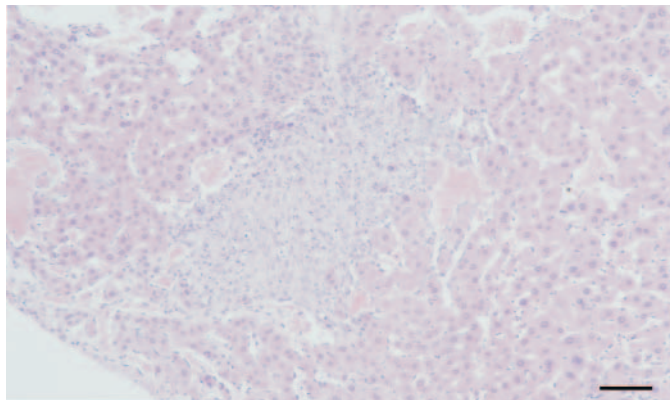
The *p53* knockout mouse model is used in fundamental studies of the mechanisms of carcinogenesis (3,23–26). To better understand the role of the *p53* gene in this process, the model is also under validation for its usefulness as a more sensitive rodent model for identifying potential carcinogens (1,3).

Our purpose was to test whether heterozygous *p53*-deficient mice are a good model to detect vascular tumors caused by

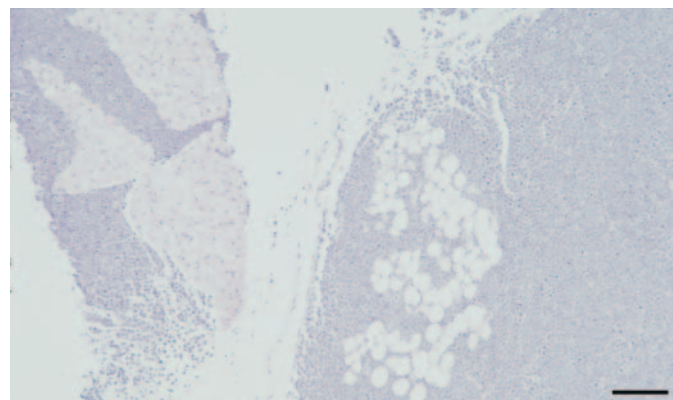
genotoxic carcinogens using urethane as a positive control. Urethane is a well-known carcinogen that forms a reactive electrophilic metabolite (10). Mirvish et al. (11) showed that urethane induced malignant lymphoma, hepatoma (depending on the strain), mammary carcinoma, hemangioma, and lung adenoma in mice. In a later study, Schmähl et al. (27) reported lung adenoma, mammary tumors, and hemangioendothelioma after 2 years of treatment. Although these are old studies, the findings are consistent from one study to another. In the present study, our findings are similar to those of Mirvish et al. (11) and Schmähl et al. (27): lung adenoma, hemangioma and/or hemangiosarcoma, hepatocellular tumors and malignant lymphoma were observed in urethane-treated mice. We did not observe mammary tumors because only male animals were used. The incidence of vascular tumors in *p53*-deficient mice administered with 100 mg/kg/day urethane was high (90%). The other tumor types (malignant lymphoma and sarcoma), which are usually detected in aging *p53*



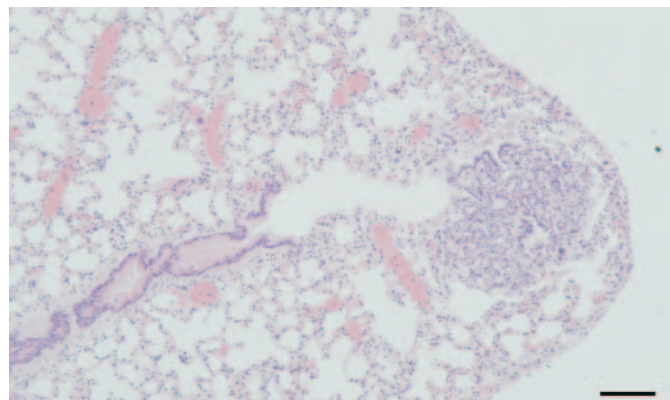
**Figure 2.** Benign hemangioma in the liver of a heterozygous *p53* knockout mouse treated with urethane at 100 mg/kg for 180 days. The lesion is characterized by dilated, blood-filled spaces lined by a single layer of prominent uniform endothelial cells without atypia. They are differentiated from angiectasis, which consists of cystic dilated normal blood vessels with no evidence of endothelial proliferation. Bar = 100  $\mu$ m.



**Figure 3.** Malignant hemangiosarcoma in the liver of a heterozygous *p53* knockout mouse treated with urethane at 100 mg/kg for 180 days. The lesion is characterized by solid growth of pleiomorphic endothelial cells presenting a fibrosarcomatous pattern. Bar = 100  $\mu$ m.



**Figure 4.** Malignant lymphoma in the thymus of a heterozygous *p53* knockout mouse treated with urethane at 100 mg/kg for 180 days. The tumor is invading the surrounding fatty tissue. Bar = 100  $\mu$ m.



**Figure 5.** A small benign bronchioloalveolar adenoma in the lung of a mouse treated with urethane at 100 mg/kg for 180 days. Bar = 100  $\mu$ m.

knockout mice, were also present in the 100 mg/kg/day urethane group. We also obtained a dose-related effect with urethane treatment; no tumor was detected at 1 mg/kg/day and there was only a low incidence of tumors at 10 mg/kg/day.

Inai et al. (19) used a range of urethane doses that can be compared to ours for the purposes of making conclusions about the sensitivity of the model. In their study, dose levels equivalent to 1, 10, and 100 mg/kg bw/day were administered in drinking water to B6C3F<sub>1</sub> mice for 70 weeks. Their study also found early death in the highest dose (600 ppm; approximately 100 mg/kg/day). In addition, the authors considered the early mortality to be attributable to the rupture of the vascular tumors, which occurred in approximately 80% of the high dose mice. Inai et al. (19) showed a few vascular tumors at 10 mg/kg/day; at lower doses the incidence was comparable to background. Their study showed a lower threshold for detecting lung tumors (significant increases were seen at 10 mg/kg/day), whereas we had none at this dose. However, Inai et al. (19) had an 18.4% incidence of this tumor in controls. Considering the differences in experimental design, the coherence of the results between these two studies appears remarkably good.

No tumors were seen in untreated heterozygous *p53* knockout mice or in the wild-type mice. *d*-Limonene, which is not genotoxic or carcinogenic in mice, did not induce any treatment-related tumors in heterozygous *p53* knockout mice. The single adenoma of the prostate was considered incidental. *d*-Limonene caused signs of chronic irritation of the nonglandular stomach that were associated with hyperplasia but not neoplasia. Field and Roe (28) reported similar lesions, associated with the irritant effect of the compound.

Thus, the *p53* model proved efficient for the induction of vascular tumors. It was possible to induce a high incidence of hemangioma and/or hemangiosarcoma in the heterozygous *p53* knockout mice treated with urethane in a short period of time as compared to a classical 2-year bioassay for carcinogenicity studies. The appearance of the tumors was dose related with neither

neoplastic nor nonneoplastic proliferative findings at the low dose. There were no vascular tumors in the untreated animals or in animals treated with *d*-limonene. Therefore, we consider that our three criteria for the usefulness of the model were met, namely: zero incidence of vascular tumors in untreated *p53* knockout mice, untreated wild-type mice, and in *d*-limonene-treated *p53* knockout mice (at 6 months); a high incidence of vascular tumors in *p53* knockout mice receiving toxic doses of urethane; and a dose-related decrease in vascular tumors in *p53* knockout mice with lower doses of urethane.

In conclusion, the heterozygous *p53* knockout mouse seems to be a good model for identifying vascular tumors. The essentially nonexistent level of vascular tumors in control *p53* knockout mice might make this system particularly suitable for studying low potency compounds suspected of being vascular carcinogens.

#### REFERENCES AND NOTES

- Tennant RW, French JE, Spalding JW. Identifying chemical carcinogens and assessing potential risk in short-term bioassays using transgenic mouse models. *Environ Health Perspect* 103(10):942-950 (1995).
- Ashby J. Alternatives to the 2-species bioassay for the identification of potential human carcinogens. *Hum Exp Toxicol* 15:183-202 (1996).
- Donehower LA. The *p53*-deficient mouse: a model for basic and applied cancer studies. *Semin Cancer Biol* 7:269-278 (1996).
- Harvey M, McArthur MJ, Montgomery CA Jr, Butel JS, Bradley A, Donehower LA. Spontaneous and carcinogen-induced tumorigenesis in *p53*-deficient mice. *Nat Genet* 5:225-229 (1993).
- Carmichael NG, Enzmann H, Pate I, Waechter F. The significance of mouse liver tumor formation for carcinogenic risk assessment: results and conclusions from a survey of ten years of testing by the agrochemical industry. *Environ Health Perspect* 105:1196-1203 (1997).
- Maronpot RR, Haselman JK, Boorman GA, Eustis SE, Rao GN, Huff JE. Liver lesions in B6C3F<sub>1</sub> mice: the National Toxicology Program experience and position. *Arch Toxicol Suppl* 10:10-26 (1987).
- Lang PL. Spontaneous Neoplastic Lesions in the Cr:CD-1 (ICR)BR Mouse. Wilmington, MA:Charles River Breeding Laboratories, 1987.
- Engelhardt JA, Gries CL, Long GG. Incidence of spontaneous neoplastic and nonneoplastic lesions in Charles River CD-1 mice varies with breeding origin. *Toxicol Pathol* 21:538-541 (1993).
- Barbin A, Froment O, Boivin S, Marion MJ, Belpoggi F, Maltoni C, Montesano R. *p53* gene mutation pattern in rat liver tumors induced by vinyl chloride. *Cancer Res* 57(9):1695-1698 (1997).
- Park KK, Liem A, Stewart BC, Miller JA. Vinyl carbamate epoxide, a major strong electrophilic, mutagenic and carcinogenic metabolite of vinyl carbamate and ethyl carbamate (urethane). *Carcinogenesis* 14(3):441-450 (1993).
- Mirvish SS. The carcinogenic action and metabolism of urethan and *N*-hydroxyurethan. *Adv Canc Res* 11:1-42 (1968).
- Ough CS. Ethylcarbamate in fermented beverages and foods. I: Naturally occurring ethylcarbamate. *J Agric Food Chem* 24(2):323-328 (1976).
- Swenberg JA.  $\alpha_2\mu$ -globulin nephropathy: review of the cellular and molecular mechanisms involved and their implications for human risk assessment. *Environ Health Perspect* 101(suppl 6):39-44 (1993).
- Hard GC, Whysner J. Risk assessment of *d*-limonene: an example of male rat-specific renal tumorigens. *Crit Rev Toxicol* 24(3):231-254 (1994).
- Whysner J, Williams GM. *d*-Limonene mechanistic data and risk assessment: absolute species-specific cytotoxicity, enhanced cell proliferation, and tumor promotion. *Pharmacol Ther* 71(1/2):127-136 (1996).
- Donehower LA, Harvey M, Stagle BL, McArthur MJ, Montgomery CA Jr, Butel JS, Bradley A. Mice deficient for *p53* are developmentally normal but susceptible to spontaneous tumours. *Nature* 356:215-221 (1992).
- NTP. Toxicology and Carcinogenesis Studies of *d*-Limonene (CAS No. 5989-27-5) in F344/N Rats and B6C3F<sub>1</sub> Mice (Gavage Studies). TR-347. Research Triangle Park, NC:National Toxicology Program, 1990.
- NTP. NTP Technical Report on Toxicity Studies of Urethane in Drinking Water and Urethane in 5% Ethanol Administered to F344/N Rats and B6C3F<sub>1</sub> Mice. TOX-52. Research Triangle Park, NC:National Toxicology Program, 1996.
- Inai K, Arihiro K, Takeshima Y, Yonchara S, Tachiyama T, Khatun N, Nishisaka T. Quantitative risk assessment of carcinogenicity of urethane (ethyl carbamate) on the basis of long-term oral administration to B6C3F<sub>1</sub> mice. *Jpn J Cancer Res* 82:380-385 (1991).
- Humason GL. Special procedures 1. In: *Animal Tissue Techniques*. San Francisco, CA:W.H. Freeman and Co., 1962:423-448.
- Guide for the Care and Use of Laboratory Animals. NIH Publication 86-23. Bethesda, MD:National Institutes of Health, 1985.
- Directive 86/609/CEE du 24 Novembre 1986. Le Guide du Journal Officiel des Communautés Européennes L358 (18 Décembre 1986).
- Donehower LA, Bradley A. The tumor suppressor *p53*. *Biochim Biophys Acta* 1155:181-205 (1993).
- Purdie CA, Harrison DJ, Peter A, Dobbie L, White S, Howie SEM, Salter DM, Bird CC, Wyllie AH, Hooper ML, et al. Tumour incidence, spectrum and ploidy in mice with a large deletion in the *p53* gene. *Oncogene* 9:603-609 (1994).
- Nicol CJ, Harrison ML, Laposa RR, Gimelshtein IL, Wells PG. A teratologic suppressor role for *p53* in benzo[a]pyrene-treated transgenic *p53*-deficient mice. *Nat Genet* 10:181-187 (1995).
- Nishino H, Knöll A, Buettner VL, Frisk CS, Maruta Y, Haavik J, Sommer SS. *p53* wild-type and *p53* nullizygous Big Blue transgenic mice have similar frequencies and patterns of observed mutation in liver, spleen and brain. *Oncogene* 11:263-270 (1995).
- Schmähl D, Port R, Wahrendorf J. A dose-response study on urethane carcinogenesis in rats and mice. *Int J Cancer* 19:77-80 (1997).
- Field WE, Roe FJ. Tumor promotion in the forestomach epithelium of mice by oral administration of citrus oils. *J Natl Cancer Inst* 35(5):771-787 (1965).