


# Woods Hole Oceanographic Institution



## Beaked Whale Necropsy Findings for Strandings in the Bahamas, Puerto Rico, and Madeira, 1999-2002

by

Darlene R. Ketten

November 2005

### Technical Report

Funding was provided by the Office of Naval Research under Contract Number N0000140010284  
and NOAA Fisheries under Grant Number 44221200.

---

WHOI-2005-09

**Beaked Whale Necropsy Findings for Strandings  
in the Bahamas, Puerto Rico, and Madeira, 1999-2002**

by

**Darlene R. Ketten**

November 2005


**Technical Report**

Funding was provided by the Office of Naval Research under Contract Number  
N0000140010284 and NOAA Fisheries under Grant Number 44221200.

Reproduction in whole or in part is permitted for any purpose of the United States  
Government. This report should be cited as Woods Hole Oceanog. Inst. Tech. Rept.,  
WHOI-2005-09.

Approved for public release; distribution unlimited.

Approved for Distribution:



\_\_\_\_\_

**John Stegeman, Chair**

Department of Biology

**Beaked Whale Necropsy Findings**  
**Examinations conducted January, 1999-2002**  
**Darlene R. Ketten, Ph.D.**  
**Senior Scientist, Biology Dept.**  
**Woods Hole Oceanographic Institution**  
**Asst. Professor, Dept. of Otology and Laryngology**  
**Harvard Medical School**

**Necropsy and histologic findings for examinations performed on beaked whales stranding between October, 1999 and June, 2002 are summarized below. They are presented in chronological order of exams and comprise strandings from the following areas:**

- I. Puerto Rican collections from Virgin Islands and Puerto Rican waters, 1999-2000**
- II. Northern Bahamas**
- III. Madeira**
- IV. Puerto Rico coastal, 2002**

**I. Puerto Rico/Virgin Islands**

**USVI/PR Strandings Oct – Dec. 1999; examinations 19-22 January 2000;**  
**Vieques Stranding, 3 May 2000; examination 25-27 May 2000**

**I. Puerto Rico/Virgin Island Study Overview**

Under ONR contract N0000140010284 and at the request of several Navy offices and NMFS, Dr. D.R. Ketten (WHOI/Harvard Medical School) traveled 19-22 January, 2000 to Puerto Rico to examine the remains of beaked whales (*Ziphius cavirostris* and *Mesoplodon spp.*) that stranded in Puerto Rico and nearby Caribbean waters between October, 1999 and January, 2000. The examinations were carried out to determine whether the remaining tissues showed any evidence of auditory trauma or other pathology relevant to the recorded stranding events. Three of the residual skulls, minus lower jaw and in some cases ear elements, were sent by Dr. Anthony Mignucci and received in June, 2001 at WHOI for additional examinations.

Heads from the Oct-Jan. strandings were collected by Dr. Anthony Mignucci and his associates. These heads were flensed and buried by the stranding response team or local officials prior to the examination. This is often the standard procedure in tropical areas particularly for strandings in remote areas; however it destroys all soft tissue evidence which is crucial for a comprehensive analysis. Dr. Mignucci was advised to change the procedure to removal and preservation of the intact head by freezing or fixation and preservation in formalin or alcohol whenever possible. Consequently, only one intact head from a stranding in May, 2000 was examined in a state comparable to heads examined from other regions in this report. That head was transported to the Roosevelt Roads Naval Base and through the cooperation of personnel at the base was frozen within

12 hours of removal and shipped to Boston for full CT examination and dissection. With the exception of the latter head, only bony skull elements (Fig. 1a) were available to assess for other animals examined from this area.

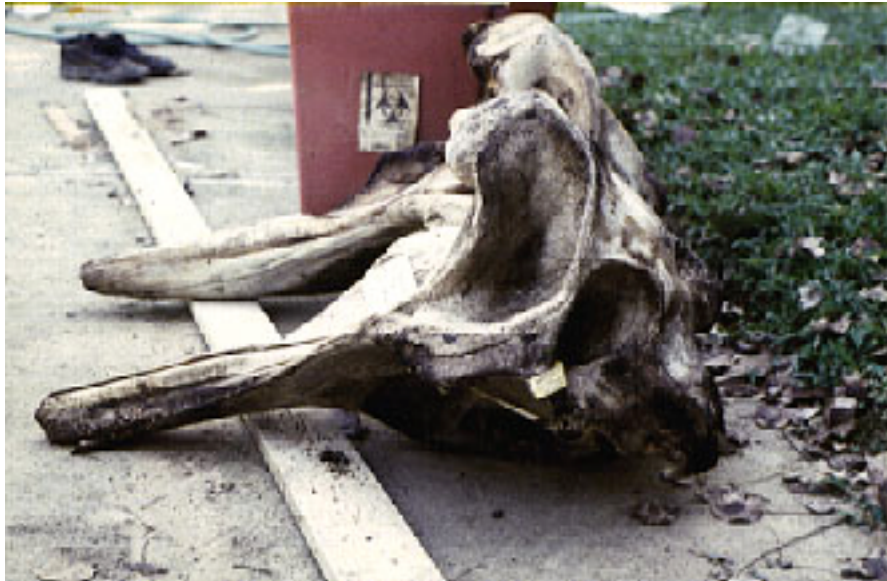

Figure 1a. Skulls from adult beaked whales stranded in the US Virgin Islands, Oct. 1999.

Summary findings are that skulls and heads of adults of both sexes and some juvenile males were examined grossly and by CT scanning. All but one skull were overtly normal although their preservation is insufficient for any firm conclusion. There is no evidence of blunt or shock related trauma in any specimen. One skull presumed to belong to an older male has evidence of long-term disease in the lower jaw and ears which was likely to have compromised hearing. There was no indication of blunt or auditory trauma in the intact head. The gross appearance of this head and the scan data suggest it is an older male. Similar to the one abnormal skull, it also has cranial abnormalities consistent with prolonged infection or age related degeneration consistent with diminished hearing.

### **I.1 Skull Exams/January, 2000:**

#### **Observations**

Tentative IDs of skulls examined:

NEPST 506 (498 cm. adult female stranded 25 November 1998, Hatillo),

NEPST 531 (536 cm. adult male stranded 18 January 1998, Vieques),

NEPST 576 (520 cm. adult female stranded 03 October 1999, Coral Bay St. John),

NEPST 575 (494 cm. adult female stranded 03 October 1999, N. Green Cay, St. Thomas),

NEPST 579 (360 cm. adult male stranded 03 October 1999, Cowpet Bay, St. Thomas).

Five skulls were examined on site at the facility directed by Dr. Antonio Mignucci in San Juan, P.R. ID tags were missing from the skulls when examined by Dr. Ketten. The ID markers for each skull were reportedly lost during a flood at the skull burial site;

therefore sex, age category, and body mass are uncertain. Because of the extreme sexual dimorphism and because body mass-skull morphometric relationships are moderately well established for beaked whales, it is theoretically possible to match skulls to the original data sheets. A preliminary sorting by sex and skull mass vs. recorded body length was done on site by Dr. Ketten assisted by Dr. Mignucci students and staff. Dr. Mignucci has agreed to supply the stranding records from his data base and to loan the skulls in order to perform the necessary measurements for a more definitive ID survey. As noted above, three skulls were received within the last month for which measurements are underway, but only estimated ID matches are available at the time of this report.

Based on gross cranial shape and length, the skulls were obtained from adult and older juvenile male and female beaked whales. With the exception of one skull, all were normally configured with no remarkable pathology. The odd skull was that of a presumed adult male with an aberrant right jaw and ear, tentative ID of NEPST531, stranded on Vieques, January 1998. The right mandible had two significant healed fractures (evidenced by displaced segments joined by replacement bone) and extensive associated osteolytic areas (Fig. 1c). The latter consisted of thinned, bubbled bony foci surrounding and radiating from the fracture sites. The auditory bulla on this side had rugose lateral and ventral surfaces consistent with otosclerotic or degenerative changes, presumably from an associated infection or aging. The left jaw and bulla had moderate demineralization but no extensive, overt lesions.

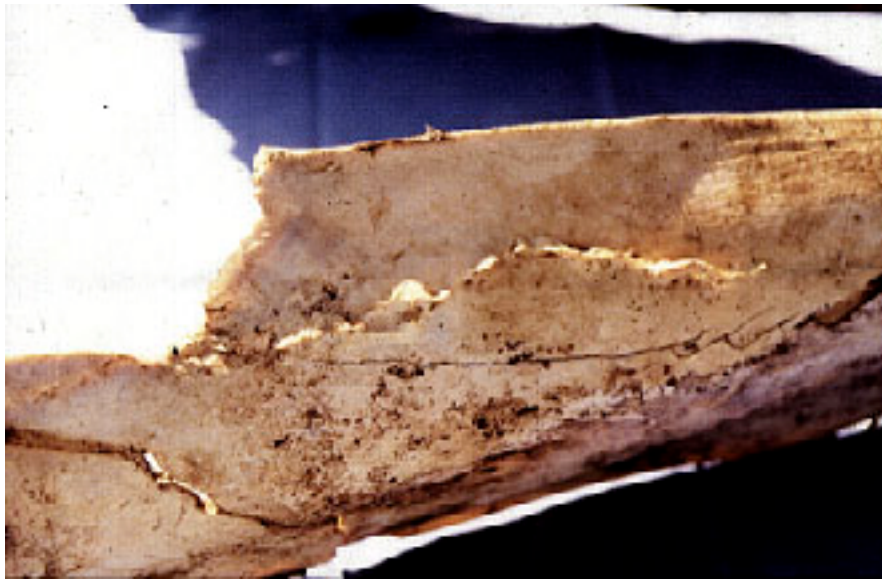

Figure 1b. Right lower jaw with healed fracture and osteolytic lesions from male *Ziphius cavirostris*, tentative ID NEPST531.

### Conclusions

Residual skull elements including the ears in the majority of animals examined have no overt abnormalities. Their appearance at a gross level is consistent with normal hearing in four of the five skulls examined. One male skull with an abnormal jaw and ear has

evidence of a unilateral chronic infection that resulted in extensive bony pathology in both the ear and lower jaw. The jaw was deeply ravaged, and the pattern of lytic areas suggests repeat and severe infectious bouts. The extent of healed bone juxtaposed with the lytic lesions (spongy, bubbled areas of thin bone radiating from the denser line of the healed fracture; see Fig. 1b) suggests that the original insult damaging the jaw resulted in a severe infection, possibly septic osteolysis, which continued to erupt over several months if not years following the fracture. The pitted, rugose surface of the ear bones associated with this jaw suggests the ipsilateral ear was also compromised by the infection. This skull was requested for loan in order to scan the inner ears to determine if inner ear inflammatory responses in the form of labyrinthine replacement bone could be confirmed, but the specimen has not yet been received. This animal can reasonably be assumed to have had moderate to profound hearing loss in at least the ipsilateral ear from labyrinthitis ossificans attending the fulminating infection. In most mammals, sympathetic loss is common in the contralateral ear, therefore this animal is likely to have had a long term, infection-derived, bilateral hearing impairment. There was no evidence in this or any of the other four skulls examined of direct blows or blunt trauma that would suggest a recent precipitous loss; however, because of the lack of soft tissues, less traumatic damage cannot be ruled out.

### **Summary**

One animal with chronic disease consistent with profound long term hearing loss. All other skulls were normal with no evidence of blunt or direct trauma.

### **I.2. Intact Head Exam**

**ID:** NEPST 601, 453 cm adult male, stranded 3 May, 2000, Isla de Vieques, examined 25-27 May, 2000:

The head of a male adult beaked whale (*Ziphius cavirostris*) was harvested by Dr. A. Mignucci from an animal that stranded and died in Vieques, 3 May 2000. Storage was supplied by the Navy base, Roosevelt Road, Puerto Rico at Dr. Mignucci's request. Mr. Winston Martinez, USN, supervised crating and shipping arrangements within Puerto Rico. The head was shipped frozen in a sealed body bag (sent to RRNB from Dr Ketten's laboratory) inside a wooden crate (constructed at RRNB) via a non-stop commercial jet flight (American Airlines) from San Juan, Puerto Rico to Boston, Mass. and transported in its unopened packaging by truck to Dr. Ketten's laboratory at WHOI on 25 May 2000. Collection, packaging and shipping were jointly supported by NMFS and ONR.

On receipt at WHOI, the head was uncrated, tagged with a WHOI archive ID (ZC09), rebagged in a locked body bag, and placed in a -20 degree C freezer. There was no evidence of external deterioration or thawing of the specimen. The head was subsequently transported in its packaging by private van to Mass. Eye and Ear Infirmary for CT examination.

At MEEI, the inner bags were opened and the head examined visually by D. Ketten. There were was no external evidence of thawing or tissue distortion. Externally, the head

was intact with minor fresh abrasions (superficial tears or cuts, <3 cm. in length), particularly on the ventral surface. These are consistent with beaching and handling. The head had been removed at the occiput. Both condyles were intact. The spinal cord was creamy with moderate firmness and appeared well preserved. There was frank blood consistent with decapitation, but no clotting or evidence of hemorrhage. Superficial lividity was noted on the ventral surface particularly in the area of the throat grooves. The rostrum and melon had multiple depigmented streaks that likely represent tooth scars from conspecific battles and are common in adult males of this species. Both eyes were present and the globes intact. Peri-ocular tissues were normal; i.e., there was no evidence of contusion or hemorrhage in either eye or in surrounding tissues. Hand exploration of the blowhole and adjacent narial passages showed normal configuration and pigmentation. There were no contusions or blood deposits, and the airways appeared patent. The mouth cavity was clear and normal in appearance with the following notations: two holes are evident in the rostral tip of the mandibles which are consistent with the removal of the tusks. Consequently, no comments on wear or tooth structure are possible. It is recommended that Dr. Mignucci be consulted to determine if he excised the teeth, and if so that they are be examined by Dr. James Mead or Dr. Aleta Hohn and sectioned for age estimates. The labia of this animal are noticeably worn and heavily wrinkled. The general appearance of the skin is thickened and wrinkled but this is particularly evident surrounding the mouth. This, combined with the scarring and skull shape, suggests the animal is an older male. Lastly, there are abundant parasitic cysts of 1-3 mm diameter visible superficially.

Scanning was done at 3 mm slicing using a spiral protocol through the accessible head area. There is no evidence in the scans of fracture of any skull element nor of hemorrhage in the soft tissues, cranial spaces, or ears. The sinuses and ear cavities are clear. The mandibles show bilateral thinning and osteolytic lesions in the posterior rami. In order to investigate the substructure of these lesions and the inner ear status, a second imaging session is planned using 100 micron, ultra-high resolution scanning at the WHOI facility followed by extraction and dissection of the ears.

## **Conclusions**

Jaw and ear lesions of the type found in this animal and in the one skull have previously been seen in older animals of other species, including *Tursiops* and *Phocoena*. They are consistent with a long standing (i.e., multi-year), repeat, fulminating infection of the jaw and/or throat and ear regions and are most often found in older males in odontocetes. In humans, infections often spread from the throat to the inner ear and can result in labyrinthitis and partial to complete deafness. Jaw abnormalities observed in this head in tandem with the general condition of cranial structures, skin condition, demineralization of major skull elements, head size, etc. suggest this was an older male afflicted with chronic and age-related pathology that may have resulted in partial or profound hearing loss.

## **Summary**

Older male animal with grossly normal head structure and moderate mandibular pathology. There is no evidence of blunt or auditory trauma. Poor skin tone, scarring, obvious moderate to heavy parasite load, and pathologic corruption of the jaw structures suggest geriatric debilitation compounded by long-term, repeated infections of the jaw and peribullar tissues.



## **II. Northern Bahamas**

### **Strandings 15-16 March, 2000; examinations 17 March, onward**

#### **II. Northern Bahamas Study Overview**

From 15-17 March, 2000, a mixed species mass stranding event was recorded involving beachings of animals on the northern Bahamian islands of Grand Bahama, Abaco, and surrounding cays. At the request of NMFS, in cooperation with the Bahamian government, several American scientists assisted in the assessment of these animals and in post-mortem analyses of the stranded animals that died. This report covers cranial structures assessed through gross observation, dissection, scanning, and inner ear histologies completed at this time.

Tissues from six whales have been examined to date by gross dissection and computerized tomography. Exams of 3 animals consisted of gross dissections of heads in an advanced state of decomposition. A fourth head was dissected in a relatively fresh state on site in Abaco, Bahamas. The ears of this animal were extracted and secondarily examined with ultra-high resolution computerized tomography (UHR-CT scanning) at the MEEI Radiology Dept.. Two undissected heads, one in an intact animal, were also examined with UHR CT at MEEI. Of these specimens, one is a delphinid (*Stenella frontalis*) and the remainders are ziphiids from two genera (*Ziphius cavirostris* and *Mesoplodon densirostris*). The ziphiids are uncommon stranders. The findings summarized below were discussed with the chairs of Radiology and Otolaryngology of Mass. Eye and Ear Infirmary, Harvard Medical School and Dr. S. Ridgway, SPAWAR before distribution; scan and necropsy findings were reviewed by Dr. Dale Dunn of AFIP and NMFS personnel at a meeting in July, 2000.

#### **Summary Findings**

In no animal was there evidence of profound or near-field blast damage, but in two of the fresher heads, there is a preliminary finding of *in vivo* auditory system pathology or trauma in the beaked whale specimens. This evidence consists of intra-cochlear (IC) and temporal region subarachnoid hemorrhages (SAH) with cerebral ventricular clots (LVH). In simpler terms, there are deposits of blood within some of the inner ear chambers, and, in at least one animal, the blood trail can be traced to a hemorrhage in a discrete region of the fluid spaces surrounding the brain. This animal also has clotting on the dorsal surfaces of both lateral ventricles of the brain (Fig. 2). These pathologies were first observed in the CT scans and subsequently confirmed by gross dissection.

The number and coincidence of the strandings combined with these necropsy findings suggest pressure related trauma in the beaked whales. The patchy patterning of blood in the *Ziphius* and *Mesoplodon* ears indicates that the inner ear membranous partitions were intact and that the cochlear aqueduct was a primary conduit for blood movement between the cranial and inner ear spaces. The presence of blood in only

restricted intracranial spaces and the intact inner ear membranes are not consistent with simple post-mortem pooling. Indiscriminate post-mortem pooling is generally greater on the dependent areas (side down on beaching) and occurs throughout the whole ear because normal ear tissues that seal and divide the inner ear are lost through post-mortem necrosis.

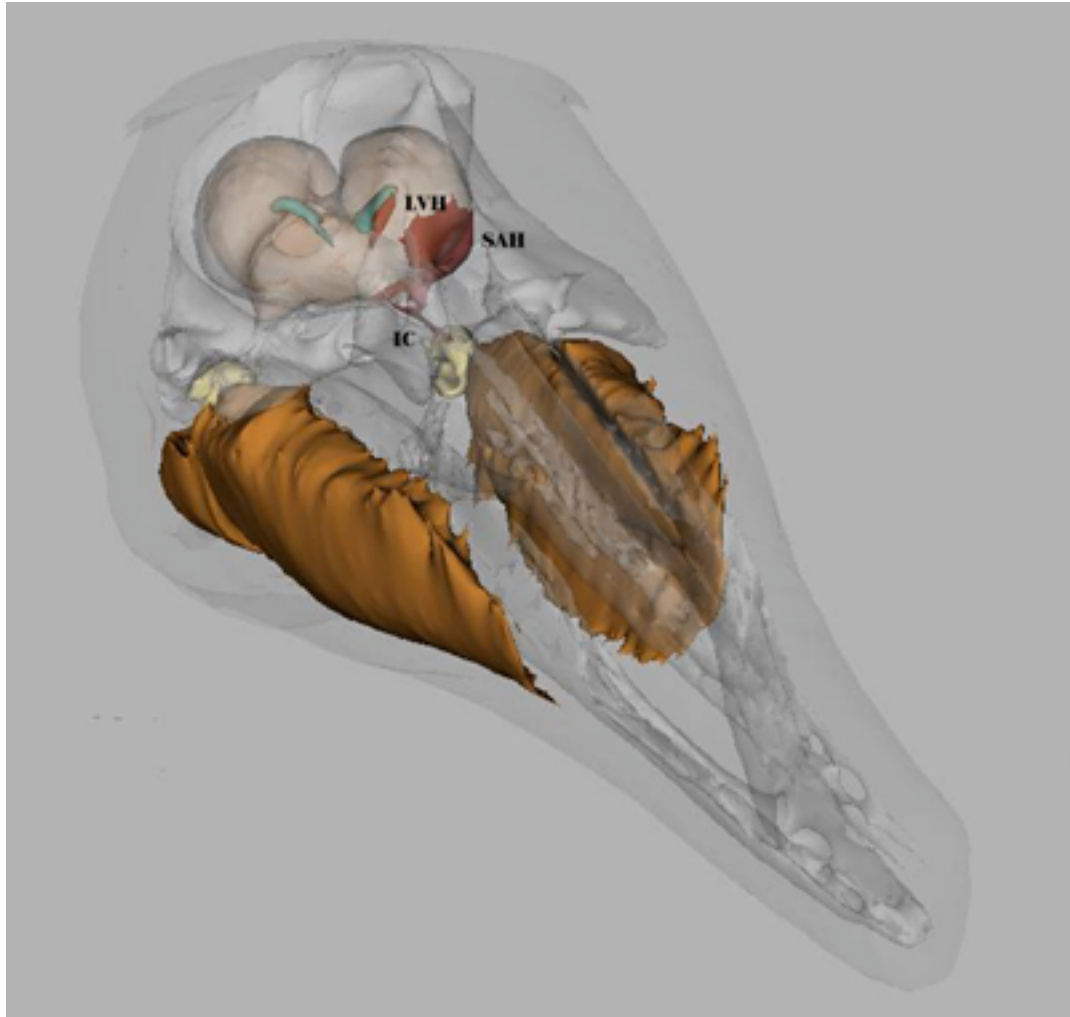


Fig. 2. 3D reconstruction of beaked whale trauma suite from scan data, MD12

In these specimens, the SAH and ventricular hemorrhages are not consistent with a simple pattern of lividity or dependent pooling in these animals. Further, blood is present in only two of three inner ear divisions. The inner ear hemorrhages line the cochlear aqueduct and auditory nerve canal which connect with the subarachnoid space surrounding the brain. The integrity of the ear and the absence of blood in the middle ear and in lower, pendant areas of the head suggest strongly that a cerebrospinal fluid “squeeze” concomitant with an intense pressure event was the source of inner ear blood in these animals. The patterning of the hemorrhages therefore suggests the ear was structurally intact and the animals were alive at the time of injury.

Findings in the poorly preserved specimens are consistent with those in the fresher animals, but are not conclusive because of the animals' poor preservation. Observations are consistent for all animals examined to the extent that bloody effusions were found in and near the ears, and there were no indications of ship strike or other large, direct impacts. However, in the three poorest specimens we cannot rule out post-mortem migration and deposition of blood in the auditory areas. There are no findings for the brains of these animals because of autolysis.

The strongest consistent finding among all animals; i.e., in both the well and poorly preserved specimens, is the presence of a mandibular hemorrhage in the "acoustic" fats of the jaw. In one poorly preserved animal the extent of the hemorrhage mirrors the hemorrhage in the jaw fats of one well-preserved head. Because these hemorrhages are distinct and adjacent tissues do not have hemorrhages in any of the cases, they are unlikely to be explained by simple lividity.

### **Study Conclusions**

The state of the poorly preserved animals makes any conclusion from their tissues debatable. Therefore, the most significant findings to date are based on observations on animals for which the heads are well preserved. Two of these are beaked whales found on the southwestern shore of Abaco which have consistent injury patterns. The preliminary conclusion is that the stranded beaked whales have consistent auditory and CSF trauma. The third well-preserved animal, a delphinid, stranded on a northeastern shore of the Abaco Cays, has no findings related to or consistent with recent auditory trauma but did have extensive necrosis and wasting. It is likely that this dolphin was an unrelated, coincidental stranding.

There are several important implications from the observations on these animals. First, the level of intracochlear blood and hemorrhage in these animals is consistent with a transient, intense event. Second, the observed damage does not necessarily indicate permanent hearing loss or mortality. While these lesions are likely to be painful initially, humans with similar auditory system hemorrhage and animals with similar experimentally induced lesions in lab studies typically regain any hearing that is impaired by the event. In fact, in some cases there is often no significant hearing loss reported. Humans usually report only substantial transient head pain and the hemorrhages are found by scan or post-mortem exam in the case of lab studies.

It is important to remember that what killed these animals; i.e., the cause of death was the physical consequences of stranding, including hyperthermia, suffocation, and blood loss from external wounds from coral cuts, shark attack, etc.. The fact that animals that were rapidly returned to sea have not to date re-stranded is consistent with non-permanent trauma. Therefore, the cause of the auditory trauma *per se* is not the cause of death in these animals, but it may be an important contributing factor. Even if the auditory damage evident in the necropsied animals was recuperable, it is still important to analyze it carefully and to determine its cause since it is likely to have played a significant role, perhaps by initiating the strandings. Ear damage therefore should be viewed as a marker or bell-whether for a potential cause of these strandings.

The current necropsy findings in the heads argue most strongly for a source with characteristics that are especially significant or traumatic for beaked whales. The get at the cause, the fundamental issues that must be addressed are: 1) why did beaked whales dominate the strandings and is their physiology a contributing factor relevant to any potential cause; 2) were there any explosive or unusual acoustic events coincident or contemporary with the strandings; 3) if so, what was there about the event(s) that could be particularly important to beaked whales; 4) if there is no outstanding single event that fits an underlying cause, is there a combination of the known events that could explain the strandings. The latter is particularly important to consider; i.e., we may be looking at a combination of a man-made source or sources that are insignificant except that the event took place in the presence of beaked whales *plus* near shore.

Based on current medical and experimental data, the hemorrhagic patterns observed in these animals are found in the following etiologies (*n.b.*: order not significant): concussive acoustic trauma from blasts or intense impulse events, barotrauma, direct or contact concussive trauma (head blows with or without fracture), auditory concussion from non-impulse source, sonic booms, spontaneous subarachnoid hemorrhage and hyperemia (bleeding into the cranial fluid spaces), vestibular atelactasis (vestibular collapse accompanied by sudden vertigo and nausea), intraoperative birth trauma (canal squeeze and forceps use), and diathetic (hemorrhage enhancing) disease.

This list raises several interesting possibilities and a few spectres. Consider the known etiologies one by one. The number, temporal coincidence, and age of the animals stranding make birth trauma and random spontaneous hemorrhage quite unlikely candidates for a related cause. Diathetic disease? This is an important consideration warranting full investigation. Hemorrhagic diathesis generally relates to impaired clotting mechanisms. In humans, diseases related explicitly to subarachnoid and intracochlear hemorrhages include hemophilia (rarely), Wegener's granulomatosis, and leukemia. The patterning of diathetic hemorrhage observed in the whales mirrors that of diathetic, stress induced and spontaneous hemorrhage in humans and land mammals who are prone to hemorrhagic diathesis. We also know that some species of dolphins lack some clotting factors. Were any of these diseases present, there should be evidence found in the body cavity tissue histologic analyses. At this time those analyses have been requested but have not been completed. In addition, while clotting factor analyses have been done on a few cetacean species, there are no data available for beaked whales. It is possible that beaked whales have effectively a diathetic state or condition that is for them normal and possibly even adaptive for diving but which makes them particularly fragile to stress or prone to hemorrhage. If so, the stress of the sound field may have induced hemorrhage, and that they were not directly an acoustically induced event. As with the disease case, looking for symptoms of such a condition should certainly be a priority in the necropsy analyses for beaked whales in this and in other stranding cases. Vestibular? A hyper-responsive vestibular system, particularly for lower frequency signals, is certainly an important possibility for beaked whales considering that they have a better developed vestibular system and Eustachian tube than most cetaceans. However, even were this true, while interesting, it begs the important, underlying question that must be addressed.

Determining if beaked whales have some especially fragile aspect of their physiology is important but not in itself sufficient. Avoiding future events requires understanding what was the catalyst - related or not to some special physiology - that precipitated an event of this magnitude dominated by beaked whales. Consequently, of the known potential causes, intense impulsive sources, shock waves, and sources that mimic pressure characteristics of sonic booms are the most probable and clearly warrant careful consideration.

In summary, the findings in the beaked whale heads examined to date are that hemorrhages were found in the inner ears and some cranial spaces. These pathologies are consistent with trauma that may have compromised hearing but was not immediately lethal. Other related observations include hemorrhages and contusions in the jaw fats and mandibles in some of the animals. The pattern of damage is consistent with acoustic trauma but a number of other causes are equally possible and cannot be ruled out at this stage of analyses. Additional analyses that may be valuable for determining with greater certainty any contributory cause(s) of this stranding include light microscopic examinations of the inner ear and related tissues. Results from inner ear analyses can confirm the presence and distributions of intracochlear blood consistent with the CT finding and determine whether critical inner ear trauma exists. It cannot, however, be said from the scan observations whether the pathologies noted were the result of direct or indirect acoustic exposures. To solve that element will require explicit histologic evidence, experimental investigation of trauma susceptibility (frequency dependent phenomena), and physiologic specializations (clotting phenomena) in beaked whales.

## **INDIVIDUAL SPECIMEN REPORTS**

Analysis Requested by: NMFS/T. Rowles; Bahamian Fisheries Service/ A. Bater

Field Dissections: 19-21 March, 2000

Preliminary Oral Report: 22 March, 2000

Written Summary Report: 13 April, 2000/revised 31 May 2000/finalized 25 October 2000

This report is based on dissections and computerized tomographic data as noted for each specimen. Each specimen is assessed individually and listed in chronological order of examination. Findings for each individual are summarized at the end of each specimen section.

### **II.1 Specimen ID/sex: 10-Zc female 18 feet total length**

Species: *Ziphius cavirostris*

Date of stranding: reported 16/03/00; presumed 15/03/00

Location: Golden Rock Creek G.B 26.30N/78.22W

Preliminary condition: Code 3/Dead-decaying

Analyses to date: field dissection

Tissue Dispositions: Bater/Ewing unless otherwise noted

Skull– frozen

Right ear – formalin  
Left ear *in situ*-frozen  
Eye, lung, ovary -formalin  
Stomach contents – frozen  
Renal parasites – EtOH  
Skin-frozen  
Serum, hemolyzed blood-frozen

**Observations/other observers:**

The animal was first reported stranded at Gold Rock Creek, Grand Bahama, by Dr. Alan Bater of Freeport, Grand Bahama. Dr. Bater conducted a preliminary examination of the whale on March 17, and requested that a NMFS veterinary pathologist assist with the necropsy. Others who reported seeing the whale earlier said she stranded live but appeared debilitated. Dr. Bater and Mr. Chris Allison reported that the whale had blood coming from the eye sockets and mouth at the time of their exam. Samples of the blood from the eye area were obtained by Dr. Bater and refrigerated. Dr. Ruth Ewing from NMFS Southeast arrived on March 18 to assist. The whale, which had been buried on order of local authorities on the afternoon of March 17, was exhumed on March 18 at 1200. Dr. Ewing and Dr. Bater conducted the necropsy of the body cavity. Mr. Ken Balcomb, Mr. Hoyt Peckham, and Ms. Nan Hauser assisted with the necropsy and documented it on film and video. The head was removed, transported to Dr. Bater's office, and placed in barrels with ice. Dr. Darlene Ketten (WHOI/HMS) and Mr. Charles Potter (Smithsonian MNH) arrived March 19 to conduct the cranial exam. The results from the body cavity will be reported by Dr. Ewing. All observations noted below were photo-documented.

**Observations/Ketten/Cranial/Temporal regions:**

The head was extracted from the ice bath and placed ventral up for examination. Most of the superficial tissue had been removed during the beach necropsy, including the majority of the dorsal, ventral, and lateral blubber layer, underlying fats, and musculature. There are extensive superficial deposits of sand and sediment.

Intermandibular length is 32.5 cm; interbullar length at mid-tympanic, 30 cm.

Basic condition of the residual head tissues is badly necrosed. The brain is fully autolyzed; no samples of residual central nervous system tissues were taken.

Gross examination of the major skull elements shows no evidence of fracture or dislocation. Sutures are intact and fused. The narial passages are clear although the mucosa has some necrotic regions. There are no gross hemorrhages in the mandibular fats or remaining jaw musculature and no overt contusions of the maxillary or mandibular bones.

The peribullar complex is somewhat bleached bilaterally.

The temporal bones (tympano-periotic complex) are normally positioned, and there is no indication of overt fracture in the bony elements of the tympanic or periotic bullae. The external surfaces of the tympano-periotic complex are clean and well-formed. The VIIIth

nerve was absent and the cochlear windows were compromised. There is a moderate pooling of blood in the retrobullar space on the right. The left peribullar areas are unremarkable.

The right posterior tympanic prominence cartilaginous shield has moderate bruising. The middle ear corpus cavernosum is heavily invested with blood bilaterally. The right ear was extracted as a complete complex, perfused with buffered formalin via the round window, and placed in buffered formalin in a sealed whirl pak. The left ear was left *in situ* since the gross condition of the head did not appear to warrant a bilateral harvest of tissues.

**Findings:**

Because of the absence of gross damage, the state of the head (necrotic and flensed) makes any conclusion about trauma or disease equivocal. The superficial debris is consistent with burial. The condition of the tissues is consistent with 3 days or more post-mortem at the local temperatures. The dimensions and overall appearance of the head are consistent with an adult female. The lack of fracture and deep bone bruising in combination with a lack of preferential hemorrhage in the perimandibular tissues suggests the animal was not subjected to an intense pressure from a near-by blast or shock wave. The gross condition of the tympano-periotic complex is consistent with a healthy adult ear with no overt indicators of prior severe otitis media. Intra-labyrinthine condition cannot be assessed reliably in this examination because conventional indicators (e.g., fenestral integrity, VIIIth nerve dimensions and condition) are absent. Exsanguination of the peribullar spaces is likely to be related to decapitation followed by soaking in the ice bath. Pooling of blood in retrobullar spaces, effusion of the corpus cavernosum, and the mottled appearance of the peribullar cap are suspicious but are also consistent with post-mortem artifact. The presence of blood on the right side may be attributed to post mortem lividity or to a unilateral insult. Histological analyses of the samples taken of the ear tissues may be warranted to address the question of whether the gross changes occurred ante or post mortem, but it is unlikely that the inner ear structures required to address acoustic or vestibular trauma remain. CT examinations of these tissues may be able to determine bilateral differences in intracochlear blood, but, again, such findings would be equivocal.

**Summary:**

Poor preservation/Extensive autolysis/Retrobullar blood Rt/Peribullar blood Rt

**II.2 Specimen ID/sex: 11-Zc male 17 feet total length**

Species: *Ziphius cavirostris*

Date of stranding: reported 16/03/00; presumed stranded 15/03/00

Location: Golden Rock Creek G.B 26.30N/78.22W

Preliminary condition: Code 3/Dead-decaying

Analyses to date: field dissection

Tissue Dispositions: Bater/Ewing unless otherwise noted

Skull-frozen

Left ear – formalin

Right ear *in situ*-frozen

Eye, testes-formalin

Skin-frozen and DMSO

Serum, hemolyzed blood-frozen

Tooth - dried (K. Balcomb)

Observations/other observers:

This animal was found, buried, exhumed, and examined in tandem with the female described above. All observations noted below were photo-documented.

**Observations/Ketten/Cranial/Temporal regions:**

As described for the previous animal, the head was extracted from the ice bath and placed ventral up for examination. Most of the superficial tissue had been removed during the beach necropsy, including the majority of the dorsal, ventral, and lateral musculature. The head had been cleanly decapitated at the occiput. All tissues are badly necrosed. There is no gross evidence of fracture on any cranial surface. Sutures are intact and fused. Occipital notch to tip of mandible length is 87 cm; the length between mandibular rami, 28.5 cm. The brain is fully autolyzed; no samples of central nervous system tissues were taken.

Substantially more flesh was removed from the right vs. left side prior to this exam. There are extensive, diffuse patches of blood throughout the head. The nasal passages have multiple, mottled areas in the superficial mucosa. There are no discrete external hemorrhagic areas in either mandible, however, discrete hemorrhagic regions are present in the left, medial, intra-mandibular fat body and in adjacent tissues adhering to the ventral surface of the pre-maxillaries.

The temporal bones (tympano-periotic complex) are normally positioned, and there is no indication of overt fracture in the bony elements of the tympanic or periotic bullae. The bone of the periotic bulla is slightly rugose, suggesting either a fully adult male or a prior moderate inflammatory episode. The majority of the residual peribullar tissues are poorly preserved and the residual tissues are unremarkable, considering their state of preservation, with the following exceptions. The left peribullar cap has petechial hemorrhagic areas. Blood is found on the medial periotic surface filling the left internal auditory meatus and the facial nerve foramen. There is a similar deposition of blood in the left round window niche. The cochlear aqueduct - remarkably - is relatively free of blood, and in comparison to the female ear described above, the corpus cavernosum is significantly less infiltrated. The right peribullar areas are unremarkable and the right ear was left *in situ*.

The left ear was extracted, perfused with buffered formalin via the internal auditory canal and round window and placed in buffered formalin in a sealed whirl pak.

**Findings:**



As in the female reported above, the state of the head (necrotic and flensed) makes any conclusion about trauma or disease equivocal. The dimensions and appearance of the skull and temporal bones are consistent with an adult male of this species. There is no overt evidence of fracture and deep bone bruising consistent with near blast trauma. However, there is concern of a pressure induced trauma based on the well-defined hemorrhagic region present in the left, medial, intra-mandibular fat bodies and in adjacent premaxillary tissues. Depositions of this type are consistent with pressure dependent trauma, including shock wave and because the fats are thought to be pinnal and tympanic analogues, they may respond similarly (e.g. hemotympanum) to moderate or low blast pressure zones or to exceptionally intense acoustic pressures. Were these hemorrhagic areas simple lividity, similar depositions would be expected in adjacent lateral tissues as well. The absence of attendant lateral hemorrhagic areas therefore raises the concern but does not assure that the areas noted are the result of a specific insult. The smaller hemorrhagic areas in the narial passages are consistent with this concern. Pooling of blood in periotic apertures and mottling of the peribullar cap are suspicious but consistent with post-mortem artifact. Given the differences in observations on the male and female heads examined the CT examinations are likely to be worthwhile to determine whether there are significant patterns of intracochlear blood, although findings are still likely to be equivocal. As with the female noted above, the utility of histological analyses of the ears from this animal are of questionable value at this point.

**Summary:**

Poor preservation/Extensive autolysis/Superficial narial mottling/Diffuse cranial bruising/Discrete bruising Lt mandibular fats/Temporal bone bilateral inflammatory changes/Peribullar petechiae Lt/IAM and FR niche clots

**II.3. Specimen ID/sex: 14-Zc male 18 feet**

Species: *Ziphius cavirostris*

Date of stranding: reported 20/03/00; presumed stranded 15/03/00

Location: Plane Crash Beach, G.B./26.35N/78.29W

Preliminary condition: Code 3-4/Dead-decaying

Analyses to date: field dissection

Tissue Dispositions: Bated unless otherwise noted

External meatus – formalin

Skin –frozen and DMSO

Blubber and parasite-formalin

**Observations/other observers:**

This animal was reported on the 20th after having been spotted in a fly-over by BMMS. All observations noted below were photo-documented. D.R. Ketten, C. Potter, N. Hauser, D. Nowacek, and H. Peckham attending.

**Observations/Ketten/Cranial/Temporal regions:**

The animal was severely decayed but flesh was largely intact. It was found lying on its left side, fully exposed, lying parallel to the tidal line, ventral surface seaward. The flesh was taugt, oozing, and clearly distended by post-mortem decay processes. Relatively little scavenger activity had taken place, but there were multiple small fissures with mixed exudate spread over the exposed surface. Because of its advanced state of decay, the minimal personnel available, and coincident time constraints for flights to examine fresher material, only the most superficial cranial exam was performed. Dr. Bater arrived near the end of our preliminary exam and decided the tissue samples and observations listed below were sufficient. The disposition of this carcass is unknown to me at the time of this report.

Lateral diameter 41.5 cm.

Dorso-ventral diameter 69 cm.

Anterior insertion of right pectoral fin to mid pupil area of right eye 66 cm.

Anterior insertion of right pectoral fin to posterior limit of mouth 91 cm.

Mid-pupil point of eye to ventral field 37 cm.

Externally, the animal had moderate, diffuse patches of lividity. A dorso-ventral incision of approximately 15 cm was made on the right side posterior to the external meatus. The meatus was intact and unremarkable. The blubber in this area was heavily infested with parasitic lightly calcified cysts which superficially resembled those of *Phyllobothrium spp.*. These were photographed, and a 3 cm by 5 cm wedge of blubber with embedded cysts was excised and placed in formalin. There is a mild purpling throughout visible tissues and no evidence of discrete trauma sites. A second, orthogonal incision was made along the jaw to expose the peribullar space and mandible. There was consistent, diffuse blood in the superficial soft tissues in the exposed areas. The right tympano-periotic bones were palpated and visually inspected. No overt abnormalities were found. The mandible and peri-mandibular areas were unremarkable.

Findings:

Considering the advanced state of decomposition and cursory exam, little can be concluded about this whale. There is no overt evidence of profound blast trauma. Hemorrhagic areas are consistent with simple lividity and post-mortem decomposition.

**Summary:**

Advanced decomposition/Encysted subcutaneous parasites

**II.4 Specimen ID/sex: 8-ZC male 16 feet total length**

Species: *Ziphius cavirostris*

Date of stranding: reported 15/03/00 or 16/03/00; collected 17/03/00

Location: Water Cay in the Burrows Group/Abaco, Bahamas/26.26N/77.47W

Preliminary condition: Code 1-2/Live-fresh

Analyses to date: Field dissection/CT scans/Laboratory dissection

Tissue Dispositions:

Two ears preserved in formalin-Ketten

Head/frozen - Ketten

All other tissues - Balcomb

**Observations/ other observers:**

March 15 @ time unknown, fishermen reported two 18 foot whales stranded in the Burrows Group (26 26N 77 46W). Ken Balcomb flew over the island on March 16 and saw a whale on shore at Water Cay in the Burrows Group, but none in the water. Later information suggests the first two whales were both *M. densirostris* that later escaped. Therefore the exact time of stranding and death of the whale that was actually retrieved near the same location is unknown. Ken Balcomb and Dave Ellifrit collected the head of a male goose-beaked whale (*Ziphius cavirostris*) on 17 March, 2000. It had been mauled by sharks; the dorsal fin, flippers and tail were missing, and it was partly exsanguinated. The head was frozen on March 17, at 2000 hours local time.

**Observations/Ketten/Cranial/Temporal regions:**

All observations noted below were photo-documented, and the observations are based on both the field dissection observations and on available CT data.

The partially thawed head of this specimen was dissected by D. Ketten with assistance from D. Nowacek on March 21, beginning at 0900. The dissection was filmed by K. Balcomb and H. Peckham. N. Hauser observed and kept field records for this document. The total dissection time and exposure of the head to ambient air temperatures was approximately 3 hours. The head was placed on a dissecting platform with the ventral surface up. All tissues appeared to be in excellent condition. Following the extraction of the temporal bone, the head was repackaged and refrozen.

The head was partially flensed but all soft tissues and peribullar tissues are intact. The dissection began with a 5 cm lateral, longitudinal incision on the right side of the animal adjacent to the external meatus. The incision exposed the fibrous sheath of the external canal. The canal was bisected approximately 1 cm. medial to the surface in order to examine the canal interior. The exposed segment showed two significant elements: there was blood in the canal lumen and the walls of the meatal canal are well developed. The inner lumen is moderately narrow and lined with conventional, pigmented epithelium. Blood in the lumen was fresh and fluid. Surrounding this core is a distinct fatty layer with a radius of approximately 2.7 mm. This is a unique and exceptional finding for odontocetes that has important implications for ziphiid reception paths. The canal was pursued medially and fully dissected. It tapered noticeably and appeared to terminate several cm distal to the tympanic bulla. Segments of the canal were extracted and preserved in formalin. The boundary tissues in some segments when injected with formalin swelled and doubled in size, suggesting that this is cavernous tissue.

An anterior-posterior incision paralleling the mandible revealed a moderate amount of bruising in the lateral mandibular fats. No similar hemorrhage was found in the soft tissues on the medial face of the mandible. The mandible itself was normal with no indication of hemorrhage or contusion, nor was there any evidence of prior fracture or osteolytic processes.

The peribullar plexus of the right ear is well preserved and extensive. There is a moderate but not exceptional effusion of the plexus. The corpus cavernosum has a deep burgundy colouring, but it is unclear whether this is a normal condition for fresh tissue in this species. As in most odontocetes, there is a posterior cartilaginous pad that is interposed between the hyoids and the tympanic prominences. In this specimen, the cartilage is clean with no evidence of contusion or hemorrhage.

Both Eustachian tubes were partially occluded by ice crystals. Each is 10 to 13 mm in diameter and attaches to a sesamoid bone located immediately at the anterior tympanic rim. The right bulla was opened. The middle ear ossicles are intact and normally articulated. Coagulated blood occupied the round window niche but was easily dislodged with gentle irrigation. The right periotic was firmly articulated with the squamosal and the sutures had to be weakened with a sharpened chisel in order to free the periotic from its peribullar sinus. The medial face of the periotic revealed intact and well-preserved VIIth and VIIIth cranial nerves. The neural apertures were filled with blood as were the cochlear and vestibular aqueducts. The VIIIth nerve and round windows were injected with formalin and the entire periotic was placed in buffered formalin.

The left ear and mandibular regions showed more extensive hemorrhagic changes. There is a small, discrete contusion along the ventral surface of the left tympanic bone and significantly more hemorrhagic areas in the perimandibular soft tissues. Primary areas of hemorrhage extend along the ventral surface for 54 cm, from the tip of the rostrum will into the intramandibular fats. Smaller areas of hemorrhage located close to the lateral surface of the mandible were also noted. Like the right ear the peribullar regions, particularly the medial surface had abundant evidence of retro and peribullar hemorrhage. The left ear was extracted intact, injected via the round window and placed in buffered formalin in a sealed whirl pak. The head was then bagged, sealed, and returned to a local freezer.

Both the head and ears were delivered for scanning at MEEI, Boston on 30 March 2000. The frozen head was transported in an insulated box by charter and commercial airlines from Abaco to Boston on 30 March 2000 with a total transit time of 9 hours. On arrival the specimen was transported by van to the scan facility of Mass. Eye and Ear Infirmary. Scanning of this and all coincident specimens in the shipment took place over an 8 hour period between 19:30 to 0300. During that time, the ears and head were removed from the external container. The ears were transferred to formalin filled jars for their protection; the head remained inside sealed plastic bags and was not scanned in this session. There was no evidence of thawing of any tissues during the scan sessions. Following scanning, the head was returned to the van, driven to WHOI, and placed in a -20 degree C freezer where it currently remains in a locked body bag. The ears were placed in new formalin the following day and are presently undergoing decalcification.

The ear specimens were scanned in an arbitrary plane using an ultra high resolution spiral CT protocol with 0 degree gantry tilt. One mm acquisitions were obtained; submillimeter images of the inner ear were reformatted at 0.1 mm increments from the 1 mm spiral data. Ultra-high resolution bone kernels were used for the inner ear images. 2D scan images,

histograms of intralabyrinthine attenuations for the inner ears, and 3D reconstructions of target tissue segmentations were imaged and filmed.

The ears appear to be well-preserved with no evidence of freezer artifact. There is no evidence of bullar fracture in the scans but there are extensive areas of intracochlear blood. Attenuations consistent with fresh blood were observed bilaterally in the inner ear in the majority of scala tympani, in the helicotrema, and in scala vestibuli adjacent to the hook region. All cochlear apertures have external blood pools but the cochlear fenestrae are intact. Intracochlear blood is evident in the cochlear aqueduct and in the perilymphatic spaces and is most abundant in the basal turn. The auditory nerve canal is also well-imaged, like the cochlear aqueduct, because of blood deposited in these spaces. The trough evident in the inner ear canal reconstruction is coincident with an intact scala media.

**Findings:**

The findings from scans are completely consistent with the dissection observations; i.e. the ears are infiltrated with blood but the membranous compartments and super structure are intact. The round and oval windows are also intact. In combination with relatively limited hemorrhages in other head regions, the inner ear pathologies demonstrated on the scans are most consistent with a mild concussive event and are similar to observed pathology in ears exposed experimentally to exceptionally intense impulsive sources or relatively distant or low charge weight blast events. The inner ear observations are also consistent with a diathetic condition.

**Summary: (See also laboratory dissection notes)**

Good preservation/EAC hemorrhage/Discrete bruising Rt lateral mandibular fats/Retro and Peribullar hemorrhages bilateral/IAM and FR clots/Bilateral intracochlear blood/Intraductal blood bilateral/ Extensive hemorrhage Lt mandibular fats/

**II.5 Specimen ID/sex: 12-Md male 11 feet total length**

Species: *Mesoplodon densirostris*

Date of stranding: reported 16/03/00; presumed 15/03/00

Location: Cross Harbour Creek, Abaco (25 58N 77 16W)

Preliminary condition: Code 2/Dead-fresh

Analyses to date: CT scans

Tissue Dispositions:

Head/frozen - Ketten

All other tissues - Balcomb

**Observations/other observers:**

March 16, 2000, 1000 local time, an eleven foot, male, dense-beaked whale (*Mesoplodon densirostris*) was found by Diane Claridge stranded dead in the mangrove lagoon of Cross Harbour Creek, Abaco (25 58N 77 16W). The body was towed to a nearby beach and a body cavity necropsy performed by BMMS personnel. The specimen was reported by

D. Claridge and K. Balcomb to be in an excellent state of preservation and was estimated to have been dead less than twenty-four hours on sighting. If this conclusion is correct, it is likely this whale died early on March 16. The body necropsy was photographed and videotaped by K. Balcomb. The head was removed and placed in a conventional chest freezer by 1730 local time, and the frozen head was transported by air to D. Ketten on 30 March 2000.

**Observations/Ketten/Cranial/Temporal regions:**

The frozen head was transported in an insulated box by charter and commercial airlines from Abaco to Boston on 30 March 2000 with a total transit time of 9 hours. On arrival the specimen was transported by van to the scan facility of Mass. Eye and Ear Infirmary. Scanning of this and all coincident specimens in the shipment took place over an 8 hour period between 19:30 to 0300. During that time, the head was removed from the external container but remained inside two sealed plastic bags during scanning. There was no evidence of thawing of any but the most superficial layers during the scan sessions. Following scanning, the head was returned to the van, driven to WHOI, and placed in a -20 degree C freezer where it currently remains in a locked body bag. All observations noted below are based on the available CT data.

The specimen was scanned in the transaxial plane using an ultra high resolution spiral CT protocol with 0 degree gantry tilt. Three and 1 mm acquisitions were obtained; submillimeter images of the inner ear were reformatted at 0.1 mm increments from the 1 mm spiral data. Ultra-high resolution bone kernels were used for the inner ear images; both conventional clinical soft-tissue and bone kernels were used for the brain and fluid labyrinth imaging. 2D scan images, histograms of intralabyrinthine attenuation characteristics for the inner ears and subarachnoid areas, and 3D reconstructions of target tissue segmentations were imaged and filmed.

The head is well-preserved with little evidence of freezer artifact. The brain is well formed with no evidence of large or abnormal air pockets. The sulci and ventricles are well defined and normal. The brain is centrally positioned and the subarachnoid areas are clear with the exception of a discrete ovoid (54 by 41 mm) subarachnoid hemorrhage in the left temporal fossa.

There is no evidence of any cranial fracture in the scans and no indication of other gross hemorrhagic areas. The brain densities are normal bilaterally. The nasal passages are clear and aerated as are the sinus, oral cavity, Eustachian tubes, and middle ear spaces. There are no scan indicators of gross hemorrhagic areas in the middle ear or peribullar spaces. Blood was observed bilaterally in the inner ear and in the cochlear apertures. Intracochlear blood is evident in the cochlear aqueduct and in the perilymphatic spaces and is most abundant in the basal turn.

**Findings:**

Based upon scan images, the head is in an excellent state of preservation. The lack of overt fractures, particularly to the temporal bone, ossicles or other cranial regions, suggests the animal was not subjected to an intense blast. The gross condition of the tympano-periotic complex is consistent with a healthy adult ear. The presence of a subarachnoid hemorrhage and the absence of pooled blood in other cranial fossa and otherwise normal aerated spaces is significant. In particular, the position and containment of the subarachnoid hemorrhagic and of the restriction of the clots to the dorsal surface of the ventricles is not consistent with post-mortem pooling. The presence of intracochlear blood and its dispersal pattern are also consistent with the subarachnoid hemorrhage and suggest a cochlear aqueduct route, at least unilaterally, for deposition of blood into scala tympani. This pattern of bleeding is consistent with a concussion derived from any number of sources, including direct trauma, blast trauma, or impulsive noise, or explicitly from any underwater source that mimics sonic boom insults. Similar patterns are also observed in birth trauma and diathetic disease. The presence of blood in the contralateral ear may result from the same conditions with or without a localized subarachnoid hemorrhage; i.e., intracochlear bleeding has also been reported without concomitant intracranial bleeding. Therefore, the CT results clearly demonstrate a hemorrhagic condition that is likely to be an *in vivo* insult of traumatic origin (considering the age and general condition of the animal and pending the body necropsy findings). However, while these results are strongly suggestive of a pressure induced trauma, without further finer grained histologic analyses, it is not possible to independently speculate on the required characteristics of a source

**Summary: (See also laboratory dissection notes)**

Good preservation/Left subarachnoid hemorrhage/Clots bilateral lateral ventricles/Ethmoid sinus hemorrhage/Minor hematomas narial plugs/Laryngeal bruising/Minor melon contusions/Minor bruising Lt lateral mandibular fats/Extensive hemorrhage Rt mandibular fats/Mandibular contusion Rt/Minor retrobullar hemorrhage Rt/Eustachian clots/Bilateral intracochlear blood/Intraductal blood bilateral/

**II.6 Specimen ID/sex: 13-Sf female 5 feet total length**

Species: *Stenella frontalis*

Date of stranding: reported 15/03/00

Location: Powell Cay, Abaco/(26.54N/77.29W)

Preliminary condition: Code 1-2/Live-Died under observation

Analyses to date: CT scans

Tissue Dispositions:

Whole body/frozen - Ketten

Serum, hemolyzed blood/frozen - Balcomb

**Observations/other observers:**

March 15, 2000, a five foot Atlantic spotted dolphin (*Stenella frontalis*) was reported stranded alive at Powell Cay (26 54N 77 29W) at 0700 local time. Tourists kept the

dolphin moistened until Dr. Bater from Freeport, Grand Bahama and Diane Claridge arrived around 1700. The entire post-mortem specimen was placed in a freezer at Sandy Point, Abaco at 2000. Ken Balcomb and Diane Claridge transported the intact frozen specimen to Boston for scanning by Dr. Ketten on 30 March, 2000.

**Observations/Ketten/Cranial/Temporal regions:**

The frozen intact animal was transported in an insulated box by charter and commercial airlines from Abaco to Boston on 30 March 2000 with a total transit time of 9 hours. It was transferred from the airport to MEEI for scanning immediately upon arrival. Scanning of all three specimens in the shipment took place over an 8 hour period between 19:30, 30 March 2000 to 0300 31 March 2000. The animal was removed from the primary carton but left inside sealed plastic bags during scanning. There was no evidence of thawing of any but the most superficial layers during the scan and transport times. Following scanning, the head was returned to the van, driven later that morning to WHOI, where it was placed in a -20 degree C freezer. It is currently secured in a locked body bag within the freezer.

The specimen was scanned in the transaxial plane using an ultra high resolution spiral CT protocol with 0 degree gantry tilt. Three and 1 mm acquisitions were obtained; submillimeter images of the inner ear were reformatted from the spiral data. Both conventional clinical soft-tissue and bone kernels images sets reviewed were used for the brain and auditory system assessments.

The head region is well-preserved with little evidence of freezer artifact. The body cavity was not imaged at this time. The brain is well defined and normally configured. The sulci, ventricles, and subarachnoid regions are well defined and normal.

There is no evidence of any fracture in the scans and no indication of gross hemorrhagic areas. The nasal passages are clear and well aerated as are the major sinuses and oral cavity. In contrast to the previous structures, the peribullar and middle ear spaces are occluded with mid to low density, mixed tissues. Because of the volume of tissue, the substructure is difficult to differentiate in the scans. The attenuation values of the occlusive tissues are consistent with mixed fats and mucosa, suggesting parasitic nematodes in part or peribullar and corpus cavernosum distention of unknown origin. The attenuations are not consistent with simple hemorrhage. The inner ear is normal and patent.

**Findings:**

Based upon scan images, the animal is in an excellent state of preservation. There is no evidence of blast or overt correlates with the previous specimens. The apparently distended tissues resemble those seen in ears of animals with otitis media and/or a moderate parasite burden but this must be considered speculation until a full necropsy and ear dissection are completed. The gross condition of the tympano-periotic complex is consistent with a healthy adult inner ear but hearing may have been compromised by



middle ear infection or immobilization of the ossicular chain if there is substantial distention in the middle ear tissues.

**Summary: (See also laboratory dissection notes)**

Good preservation/Inflammatory changes sphenethmoid sinus/Retro-peri-bullar necrosis bilateral/

### **III. Madeira Archipelago; Strandings 10-12 May, 2000; Examinations 2-8 September, 2000**

#### **Study Overview**

Bodies of 3 *Ziphius cavirostris* were examined post mortem by Dr. Luis Freitas and his assistants following a mass stranding of animals reported 10-12 May 2000. The reports (*op cit*) of those exams, written by Dr. Freitas, follow this summary of findings by D. Ketten on the heads removed from two of these animals. A fourth animal was reported floating in the Madeiran waters by fisherman but did not come ashore/

According to a verbal report from Dr. Freitas, two heads were taken, one intact, one partially flensed and seared from a fire started by local residents in an attempt to dispose of the whale. The better preserved head, referenced in Dr. Freitas's report as "second reported stranded", was examined with CT and gross dissection. The charred head (sex and age unknown) was examined only by gross observation.

Several observations on these beaked whales are consistent with the findings on the Bahamian specimens. In particular, blood in and around the eyes, kidney lesions, pleural hemorrhage, lung congestion, and in the one preserved head, subarachnoid and ventricular hemorrhages, were found which are consistent with Bahamian pathologies that are consistent with stress and pressure related trauma. The coincidence of pathology and the stranding patterns in both sites raises the concern that a similar pressure event precipitated or contributed to strandings in both sites.

#### **III.1 *Ziphius cavirostris* 410 cm, subadult female**

ID Second reported.

Stranding estimated 14 May, 2000; Beach necropsy, 15 May, 2000; Head exam 5-8 September, 2000

The head was removed from this animal as described in the appended report by Dr. Freitas. After removal, it was transported to Madeira to Dr. Freitas's stranding and necropsy facility in Caniçal and stored, frozen, in a sealed bag at -20 degrees C. On 6 September, the day of the scan exam, the head was removed from the freezer by L. Freitas and D. Ketten and placed outdoors on a concrete surface for basic photography and gross observation. Overtly, the head showed moderate lividity and generally good preservation for a code 3 specimen. Explicit details on the external condition are included in the gross necropsy findings below.

In the early evening the head was rebagged and transported by car to a private medical facility, Clinica Santa Lucia, Funchal, Madeira. Computerized tomographic (TAC) scans were performed by technologists Luisa Gouveia and Alcindo Andrade of the clinic, working under the supervision of Dr. Jose Franco, M.D., the neuroradiologist in charge of the facility. Parameters for scanning were set in consultation with Dr. Ketten. Dr. Luis Freitas and two veterinarians, Dra. Nelida Aguicir and Dra. Isabel Quaresma were in attendance.

The scanner employed is a GR Sytec Sri with spiral and contiguous modes. Scans were obtained with a spiral protocol and imaged in bone format at 5 mm. increments through the entire head and at 3mm increments for positions -224 through -264, which comprise the temporal bone regions. The clinic personnel were extremely cooperative and enthusiastic through all phases of the scanning and very willing to assist with this exam.

The scans show no evidence of blunt trauma; i.e., no major fractures or displacements were found. The cranial sinuses and airways are clear with little or no fluid deposition, indicating reasonable preservation of tissues. The brain is in moderate condition, consistent with the post-mortem time but most regions, including the ventricles, can be distinguished and the dural boundaries are clearly demarcated. There are two distinct pathologies: bilateral subarachnoid hemorrhages and frank blood in the left ventricle. The SAH are nearly symmetrical and well-defined (Fig. 3).

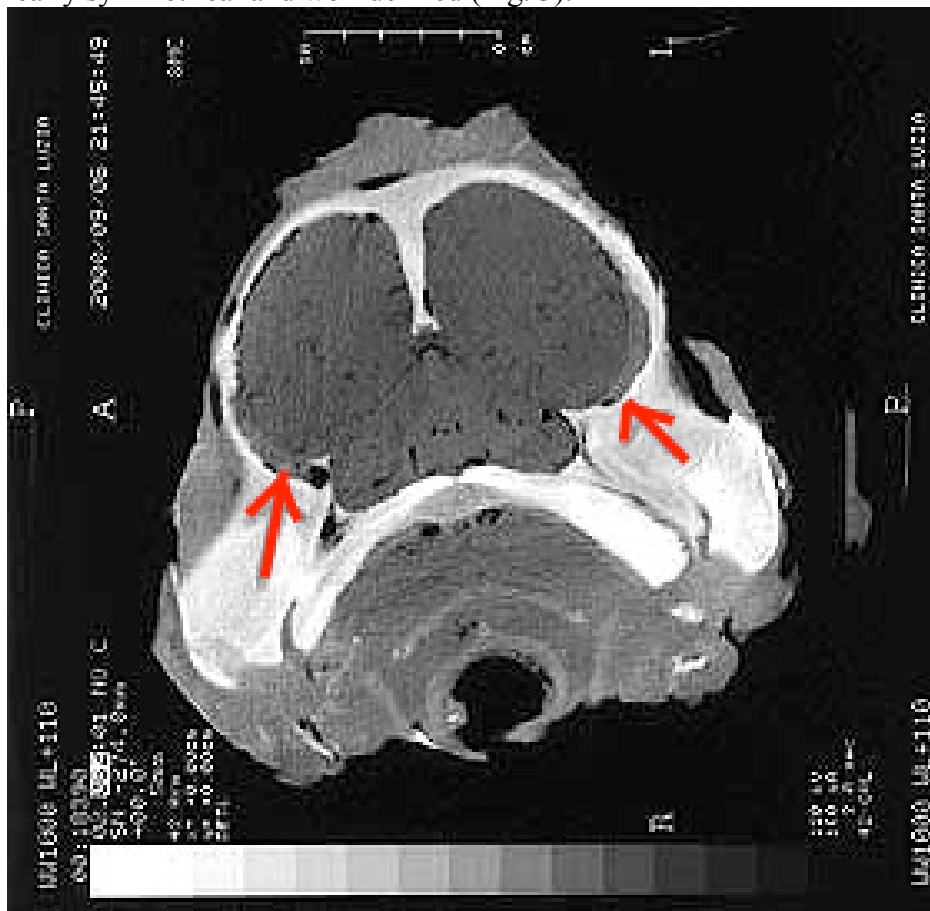

Figure 3. Bilateral subarachnoid hemorrhage in *Ziphius cavirostris*, stranded May, 2000, Madeira.

The scans show also a shadowing of the cochlear canal that is consistent with an abnormally high intracochlear density, but it is not possible to state with assurance from a 3 mm scan whether the increased densities over normal represent blood, fibrous tissue or some other moderate density intracanal inclusion. Similarly, the internal auditory canals

contain increased density tissue but it cannot be stated from these scans whether they represent blood or other tissues in addition to normal neural loads. Both middle ears had normal cavernous tissues and ossicular configurations with one notable abnormality; i.e., the right malleal joint was displaced. Following the scans the head was transported to the dissection facility of Instituto Oceanografico in Funchal, where it was left with partial insulation and water to allow a slow thaw overnight for further dissection. Periodic checks were performed by the facility guard overnight to assure the maintenance of the room temperature.

The head necropsy was performed by Dr. Ketten, Dr. Freitas, Dra. Aguicir, and Dra. Quaresma on 7 Sept. 2000. Overtly the head has partial loss of the epidermis, consistent with post-mortem necrosis and transport abrasions. There is a notable swelling of the left periocular tissues with pockets of fluid. The right eye area is superficially normal. No teeth are in evidence, which is normal for a female of this species. There were moderate numbers of encysted parasites in the subcutaneous blubber, which is common in this species and a general diffuse lividity but no remarkable external bruises. Basic measurements were as follows: dorso-ventral occipital axis 48.7 cm; lateral axis, 43.4 cm.; occiput diameter, 13.7 cm; occiput to rostral tip, 77.3 cm;

The dissection was begun with an exploration of the right side of the head. A parasagittal incision paralleling the longitudinal axis of the jaw showed no external fat abnormalities other than normal lividity for this code. The underlying blubber, muscle and lateral jaw fats are normal. Mandibular length was 64 cm. The inner jaw fat was exposed by a ventral incision, revealing a 1cm diameter hematoma spreading medially from the pan bone area in the posterior flange of the jaw. Medial and anterior muscle bundles were friable with multiple hemorrhagic sites. The right tympanic was normal, externally but surrounded by small (3-5 mm) clots. These clots were densest in the medial or retrobullar space. The tympanic was removed by opening the posterior tympano-periotic suture. The middle ear corpus cavernosum was moderately distended on the medial side. The remainder was normal in appearance with no notable discoloration. The malleus and incus were disarticulated, however the incudo-stapedial articulation was intact and the stapes was in place in the oval window. This is consistent with the scan observation and not a result of opening the tympanic. The round window was intact with a distinct clot on its intracochlear face. The window was opened with a 22 gauge needle, some portion of the internal fluid withdrawn, and the inner ear was then irrigated with buffered formalin. The VIIIth nerve was intact but heavily stained, suggesting blood deposition in the ganglionic spaces and internal auditory canal. No substantial peribullar or intrabullar parasites were noted.

The left ear presented a similar pattern although no clear, extensive hemorrhages of the fats were observed. There was more diffuse lividity on this side, however, which complicates any interpretation for pathologies on the left. The left ear presented a similar pattern of peribullar clotting. The middle ear was normal with no overt pathologies. The ossicular articulations were intact. Blood was noted behind the round window and in the IAC. Both ears were extracted and preserved in buffered formalin with the intention to

ship to Dr. Ketten for further examination, pending award of a CITES export permit to Dr. Freitas.

The right and left eyes both have periorbital staining and surrounding ring hemorrhages. The left eye has contusions distributed primarily superiorly, anteriorly and ventrally. Underlying tissues of the peribullar spaces are normal.

The melon and narial areas were normal with some moderate superficial staining consistent with post mortem necroses and lividity.

The dorso-posterior surfaces of the skull were removed with a Stryker saw. The brain was in poor condition and ventricle status could not be confirmed. The sub arachnoid spaces were compromised bilaterally with distinct clots and bloody deposits, consistent with the scan observations; however, because of decomposition, their precise extent could not be determined.

### **Conclusions:**

The eye abnormalities and pattern of peribullar and ocular hemorrhages are remarkably consistent with the observations noted for the Bahamian strandings. Some of the eye pathology can certainly be attributed to post-mortem migration, necroses, and lividity, however the ear findings and intracranial hemorrhage pattern are fairly robust and consistent with auditory trauma suites observed in the Bahamian strandings as well as in the relevant experimental literature. The presence of this suite in these animals in conjunction with multiple simultaneous strandings of adult and subadult animals that do not have other postcranial pathologies or evidence of debilitation strongly suggests a phenomenon similar to the Bahamian incident.

### **Summary**

Fair preservation/EAC hemorrhage/Discrete bruising Rt inner mandibular fats/Retro and Peribullar hemorrhages bilateral/IAM and FR clots rt. ear/Bilateral intracochlear blood/ / Extensive hemorrhage bilaterally in subarachnoid space

### **III.2 430 cm estimated; age/sex unknown,**

This skull was immolated by nearby residents and has undergone active insect and larval activity. No overt soft tissues remain. The residual bone is blackened with soot and sutures are compromised. Some laminar surfaces have separated. There is no overt indication of blunt trauma, but no further observations to determine or rule out more subtle trauma were possible. It was decided that scanning and ear extractions were not warranted and the skull will instead be prepared as an osteologic exhibit.

### **Summary**

jaw absent, moderate assymetry of skull, presumed subadult male/ skull suture separations consistent with heat contractions/

### III Appendix

#### **Report appended as forwarded by Dr. Luis Freitas, Madeira Grande Beach Necropsy Observations**

FIRST REPORTED STRANDING

*CODE:* AR.O.00.2

*SPECIES:* ZIPHIUS CAVIROSTRIS

*STRANDING DATE:* 10.05.2000

*NECROPSY DATE:* 11.05.2000

*NECROPSY LOCATION:* Porto Santo garbage dumping site

*PLACE OF STRANDING:* South coast of Porto Santo Island.

*DESCRIPTION OF THE STRANDING SITE:* sandy beach

*ESTIMATED DATE OF DEATH:* between 9 and 10.05.2000

*ANIMAL CONDITION:* Starting decomposition. it had several wounds at the skin caused by handling

*ANIMAL LENGTH:* 380 cm

*AGE:* sub-adult (did not have teeth)

*SEX:* male

The animal was collected by the local authorities (maritime police) and transported to Porto Santo garbage dumping site.

#### OBSERVATIONS DURING NECROPSY

Animal presented several marks and wounds caused by being handled by an excavator . These marks and wounds were well identified. No marks or wounds of other origin or of unknown origin were observed. The animal stayed dry around 24 hours. The eyes were filled with blood.

#### THE FOLLOWING OBSERVATIONS WERE MADE INSIDE THE BODY:

Macroscopic lesions: bloody liquid (2 to 3 liters) in the pleural cavity, pulmonary linfatic nodes slitley swollen. The lungs looked normal. (left lung 3,026kg ; right lung 3,096Kg). Presence of parasites in the kidneys.

#### Microscopic lesions:

Left lung with lesions from pneumonia. Right lung: first sample had edema and congestion; second sample lesions from pneumonia; liver with a congested area. No other lesions were observed;  
kidneys with hemorrhagic congestion

#### Microbiology: the following microorganisms were isolate:

lungs- *Vibrio damsela*;

Pulmonary linfatic nodes - no pathogenic agents were isolated;

Cardiac blood - Pasteurella spp+ Providencia stuartii + providencia rettgeni+Pasteurella ureae + E. coli . (it was not possible to properly disinfect (by burning with a very hot object the surface of the left ventricle) due to the strong winds felt at the place where the necropsy was performed. We tried to clean with alcohol but it was not enough.

Kidneys - no pathogenic agents were isolated;

Liver - no pathogenic agents were isolated;

It was not possible to take to Madeira the head of the animal and preserve it.

## SECOND REPORTED STRANDING

*CODE:* AR.O.00.3

*SPECIES:* ZIPHIUS CAVIROSTRIS

*ANIMAL FOUND:* 13.05.2000

*NECROPSY DATE:* 14.05.2000

*NECROPSY LOCATION:* Sandy beach located in the East coast of Porto Santo

*PLACE OF STRANDING:* Northeast of Porto Santo Island.

*DESCRIPTION OF THE STRANDING SITE:* rocky beach (pebbles) with a barrier of rock outcrops just at the entrance of the beach. The animal was laying on its left side.

*ESTIMATED DATE OF DEATH:* more than 4 days before necropsy day.

*ANIMAL CONDITION:* moderate decomposition; body swollen; smelling

*ANIMAL LENGTH:* 410cm

*SEX:* female

*AGE:* sub-adult (no corpora lutea were observed in the gonads)

The animal was pulled away from the beach. It was stranded in a rocky platform at the sea level. The animal was towed afloat to a sandy beach south of the stranding place with the minimum conditions for a necropsy to be performed. The animal was stranded at this sandy beach at high tide and we worked on it as the tide fell.

## OBSERVATIONS DURING NECROPSY

Animal the left side completely white. The skin had been removed by the contact of the animal with the rocky platform at the stranding site. The right side presented several superficial wounds and scratches that were possibly caused by the stranding. The genitalia and anus slits were protruded. At the pectoral fin area it was observed hematoma, indicating the animal may have stranded alive.

## THE FOLLOWING OBSERVATIONS WERE MADE INSIDE THE BODY:

Macroscopic lesions: bloody liquid (1 to 2 liters) in the pleural cavity, pulmonary lymphatic nodes normal. Small purulent nodules in a small area of the lungs. Presence of parasites in the lungs.

Microscopic lesions:

lung with pneumonia. At the alveoli level parasites larvae were observed.

Other organs in decomposition. No histopathologic exam conclusive.

Microbiology: no samples were collected due to the advanced state of organs decomposition.

The animals head was collected and frozen.

### THIRD REPORTED STRANDING

*CODE:* AR.O.00.4

*SPECIES:* ZIPHIUS CAVIROSTRIS (subject to confirmation)

*ANIMAL FOUND:* 14.05.2000

*NECROPSY DATE:* we were informed the animal had stranded on the 27.05.2000. It was only possible to observe it on the 30.05.2000

*NECROPSY LOCATION:* it was not performed

*PLACE OF STRANDING:* Calhau da rocha do Navio. North of Madeira Island, facing Porto Santo Island.

*DESCRIPTION OF THE STRANDING SITE:* Pebble beach.

*ESTIMATED DATE OF DEATH:* indetermined

*ANIMAL CONDITION:* The animal was set on fire by some local people in an attempt to stop the smell. as expected it actually increased it.

*ANIMAL LENGTH:* 430cm (estimated) probably bigger

*SEX:* indetermined

*AGE:* indetermined

The skull was collected. The animal had been sited at sea previously it stranded by some fishermen. The jaws had been removed at sea before stranding according to some local.

There is only one record of stranding of an animal of this species in the past at Madeira archipelago. It was in 1999.



#### **IV. Puerto Rico, 2002**

**re: NEPST838 M *Mesoplodon densirostris***

**WHOI Case Number: NEPST838/12apr02/Puerto Rico**

**Imaging Analysis Requested by: Dr. Teri Rowles; Dr. Janet Whaley; NOAA Fisheries**

**Scan date: 12 April, 2002**

**Scan technician(s): J. Arruda; S. Marsh**

**Scan Analyses: D.R. Ketten**

**Report Date: 15 April, 2002**

##### **History**

NOTE: All information in this section is based on telephone or faxed information provided to this office. Report times and conditions may therefore vary from information provided by other related incident reports.

This animal was first reported to the WHOI office on 10 April, 2002 by the SE stranding coordinator, Jenny Lutz, who was notified originally by Dr. Antonio Mignucci of the Caribbean Stranding Network during the afternoon of 10 April. Dr. Ketten spoke directly with Dr. Mignucci at 1900 on 10 April, requesting photo-documentation and information on exam procedures for the thoracic and abdominal tissues as well as instructions for the removal, preservation, and shipment of the head.

Dr. Mignucci stated that the animal was located at Dorado, on the main island of Puerto Rico. He and a team from the Caribbean Stranding Network performed the necropsy on site at Dorado on 10 April. The animal was reported verbally as approximately 800 lbs., lying on its right side, with evident fractures, and graded as a Code 3 with moderate decomposition. According to Dr. Mignucci, the animal washed ashore in a rocky area and was battered repeatedly through wave action.

The head was removed the night of 11 April and placed in a conventional freezer; temperature and timing were not specified. Sarah Marsh at WHOI arranged shipping of a body bag, plastic bags and padding to be delivered by early AM to Dr. Mignucci's lab at his request for their use in shipping the head to WHOI. He was also given the Ketten Laboratory Fed-Ex account number to pay for shipping costs. The specimen (approximately 35 kg.) was shipped via Fed-Ex, overnight priority, on 11 April and received at WHOI in the Ketten lab before noon, 12 April, 2002. It was scanned and placed in the Ketten lab  $-20^{\circ}\text{C}$  freezer by 1400 on 12 April. Scans were shipped to D. Ketten in DC via Fed-Ex for this analysis. Therefore, observations are limited to scan based observations at this time. A faxed copy of the CSN necropsy report has also been received and notations from it incorporated where appropriate.

##### **General Observations**

The head is intact, decapitated at the occiput. There is a mid-ventral cut extending approximately 134 mm. posterior to anterior. A portion of the dorsal blubber layer from the posterior to mid-cranial areas was removed before shipping. Margins of this tissue region are relatively clean suggesting it was sampled rather than traumatically removed.

The remainder of the skin appears intact, however the interior tissues have a generally unhealthy, decomposed appearance suggesting moderate post-mortem time consistent with the Code 3 designation by CSN (see details below by anatomical region). Bright signals that appear on the surface of the animal are likely to be sand or other similar material

### **Cranial Soft Tissues**

All soft tissues of the head are in relatively poor condition based on extensive separation of tissue layers and multiple air pockets distributed throughout the head.

The soft tissue scans indicate a broad area of contusion evident as a gray shadowing in the blubber layer that extends from the mid-rostral region posteriorly and bilaterally. Based on the scans, the coherent contusion field is a trapezoid oriented with the broad base posteriorly, covering primarily the ventral surface, with lateral wings wrapping upward towards the posterior head regions. On the left side, sand and soil (bright signal areas) are embedded in the skin adjacent to the contused area.

The soft-walled narial passages are poorly defined.

There are extensive air pockets that dissect the blubber-musculature interface and compromise tissues throughout the entire head. Notable air pockets are present on the left side of the anterior melon, sublingually on the right, and near the right intramandibular tusk. There are anomalous and extensive air pockets adjacent to the medial surface of the intramandibular fat bundles bilaterally.

Sinuses are normal with good pneumatization. The mucosa is normal; there are no significant depositions of fluids in any sinus cavity.

The melon has a uniform attenuation, suggesting moderate decomposition although it retains a fundamentally fatty attenuation signature.

### **Skull**

There are extensive mandibular fractures bilaterally.

On the left side, there are two complete transverse fractures. One is located anterior to the tooth bulge; the second occurs approximately two-thirds the length from the anterior mandibular symphysis (SP 264.5-270.5). The second left mandibular fracture involves a region extending from SP 352.5 to 546.5. In effect, the posterior third of the left mandible is compromised by compound fractures with multiple areas of bone displacement and loss. The mandibular segment delimited by the anterior transverse and posterior complex fractures is displaced laterally. Subsections of the displaced lateral wall are oriented orthogonal to the normal vertical plane of the mandibular shaft and project outward, cutting into the overlying fats and musculature (SP 388.5-404.5). Lighter gray areas near the projecting bone shards represent mixed emulsified tissues and blood. In several regions, a track of compromised tissue can be seen extending to the surface of the head from the lateral edges of larger bony spicules. The extent and shape of the affected soft tissues suggest that the shards may have moved repeatedly through in the overlying tissue bed and were not simply displaced in a single motion.

The right mandible has mixed transverse and longitudinal fractures located nearly parallel to the posterior fracture region noted on the left. There are two substantial

transverse fractures of the right mandible interconnected by secondary longitudinal fractures creating two stepwise breaks in the posterior third of the mandibular ramus.

The inferior margin of the pan bone is fractured bilaterally with smaller elements displaced medially and embedded in the surrounding musculature.

There is a minor fracture of the premaxillary bones with a displaced fragment.

All other skull elements are normal.

Two intact, well-enameled teeth are evident buried in the mandible (SP 246.5-282.5), suggesting this is an immature male.

### **Brain**

There is no evidence of hemorrhage or contusion in any brain region and no deposition of blood or other abnormal fluids in the subarachnoid and subdural spaces. Meningeal suspensory fibers and vessel tracks are visible traversing the subarachnoid spaces.

There is little differentiation of the cortical layers in the soft tissue scans, suggesting moderate to severe autolysis.

Ventricular inflation is within normal ranges bilaterally; the spaces are well defined and slightly larger on the right side compared to the left.

### **Eyes**

#### **Optic Nerve**

Optic nerves are intact but weakly structured in that there are large, distinctive spaces within the neural bundle. The optic nerve conventionally appears as a coherent bundle. Therefore being able to visualize distinct fiber groups suggests that some neural fibers are disrupted or degenerated.

#### **Globe**

The left globe is collapsed. The lens is displaced ventrally in both eyes (SP 484.5-500.5). There is little differentiation of the external and internal regions of the globe bilaterally indicating that both eyes are seriously compromised and possibly hemorrhagic.

#### **Periocular Region**

The orbital musculature is degenerated.

### **Ears**

#### **IAC/Acousto-Vestibular/Facial Nerve**

The internal auditory canals are well defined. There is no evidence of blood or other abnormal material within either IAC. VIIIth and VIIth nerves are intact bilaterally and well defined. As noted above for the optic nerve, separate, distinct fiber bundles are evident, suggesting that some fiber loss has occurred.

#### **Middle Ear**

The middle ear cavities are normal with distinct middle ear air spaces bilaterally and a distinct corpus cavernosum. All ossicles are intact and normally configured bilaterally. Neither stapes is displaced from the oval window (SP 548-552); the round window is normal bilaterally. The retrobullar and peribullar spaces are normal bilaterally with good pneumatization and no evidence of sero-sanguinous deposits.

#### **Inner Ear**

The canals are symmetrical and normal in appearance. There is no evidence in these scans of abnormal intracochlear blood or other cochlear compromise, however, submillimeter images are required to confirm this observation.

**Other Significant Features**

No additional notations

**Summary**

Extensive fractures of the mandible, with minor fractures in the maxillary and premaxillary bones. Contusions in the subcutaneous fats in the latero-ventral regions of the head. Extensive pneumatized areas throughout the extracranial soft tissues, consistent with postmortem autolysis. Fiber loss in cranial nerves consistent with post-mortem decomposition. Poor differentiation of CNS features consistent with postmortem autolysis

**Cause of Death**

Indeterminate: Cause of death cannot be determined from the scan-based information available to date.

**Additional Comments**

Two issues raised by the CSN report need to be clarified. The first is whether this animal has evidence of blast trauma. The second is whether it was alive within 24 hours of the necropsy.

It cannot be determined without direct examination whether the fractures evident in the scans occurred pre, peri, or post mortem. To address this issue requires a full head necropsy.

Based on the scan images, blast effects can neither be confirmed nor denied. The jaw fractures and subcutaneous contusions that are present are consistent with shock wave effects from a blast, but they are also consistent with many other potential sources of blunt trauma.

Were these fractures the result of a blast, it would require exposure to a relatively high psi. Other tissue conditions are not consistent with blast exposures with high pressures. Based on the scans, the ears are essentially normal and the brain has no abnormal findings with the possible exception of moderate inflation of the right ventricle. Lung, liver, kidney, and intestines as described in the CSN necropsy report are essentially free of any injuries consistent with blast.

According to the CSN report, initial observers of this animal believed it to be alive on 10 April, however this is inconsistent with the head's soft tissue appearance. The head tissue condition is far more degraded than is typical of a relatively fresh animal. The assumption that it was alive on the day preceding the necropsy is based on the observation of motion of the body. Because this animal beached on a rocky shore with substantial waves, the possibility that the body motion was the result of movement of a buoyant carcass coupled with wave action should be considered.

<b>REPORT DOCUMENTATION PAGE</b>	1. REPORT NO. <b>WHOI-2005-09</b>	2.	3. Recipient's Accession No.
4. Title and Subtitle Beaked Whale Necropsy Findings for Strandings in the Bahamas, Puerto Rico, and Madeira, 1999-2002		5. Report Date November 2005	
7. Author(s) Darlene R. Ketten		8. Performing Organization Rept. No. WHOI-2005-09	
9. Performing Organization Name and Address  Woods Hole Oceanographic Institution Woods Hole, Massachusetts 02543		10. Project/Task/Work Unit No.  11. Contract(C) or Grant(G) No. (C) N0000140010284 (G) 44221200	
12. Sponsoring Organization Name and Address  Office of Naval Research		13. Type of Report & Period Covered Technical Report	
15. Supplementary Notes This report should be cited as: Woods Hole Oceanog. Inst. Tech. Rept., WHOI-2005-09.		14.	
16. Abstract (Limit: 200 words) Necropsy and histologic findings for examinations performed on beaked whales stranding between October, 1999 and June, 2002 are summarized and the finding interpreted. They are presented in chronological order of exams and comprise strandings from the following areas: I. Puerto Rican collections from Virgin Islands and Puerto Rican waters, 1999-2000 II. Northern Bahamas III. Madeira IV. Puerto Rico coastal, 2002.			
17. Document Analysis a. Descriptors beaked whales trauma necropsy  b. Identifiers/Open-Ended Terms    c. COSATI Field/Group			
18. Availability Statement  Approved for public release; distribution unlimited.		19. Security Class (This Report) <b>UNCLASSIFIED</b>	21. No. of Pages 38
		20. Security Class (This Page)	22. Price

## DOCUMENT LIBRARY

*Distribution List for Technical Report Exchange – July 1998*

University of California, San Diego  
SIO Library 0175C  
9500 Gilman Drive  
La Jolla, CA 92093-0175

Hancock Library of Biology & Oceanography  
Alan Hancock Laboratory  
University of Southern California  
University Park  
Los Angeles, CA 90089-0371

Gifts & Exchanges  
Library  
Bedford Institute of Oceanography  
P.O. Box 1006  
Dartmouth, NS, B2Y 4A2, CANADA

NOAA/EDIS Miami Library Center  
4301 Rickenbacker Causeway  
Miami, FL 33149

Research Library  
U.S. Army Corps of Engineers  
Waterways Experiment Station  
3909 Halls Ferry Road  
Vicksburg, MS 39180-6199

Marine Resources Information Center  
Building E38-320  
MIT  
Cambridge, MA 02139

Library  
Lamont-Doherty Geological Observatory  
Columbia University  
Palisades, NY 10964

Library  
Serials Department  
Oregon State University  
Corvallis, OR 97331

Pell Marine Science Library  
University of Rhode Island  
Narragansett Bay Campus  
Narragansett, RI 02882

Fisheries-Oceanography Library  
151 Oceanography Teaching Bldg.  
University of Washington  
Seattle, WA 98195

Library  
R.S.M.A.S.  
University of Miami  
4600 Rickenbacker Causeway  
Miami, FL 33149

Maury Oceanographic Library  
Naval Oceanographic Office  
Building 1003 South  
1002 Balch Blvd.  
Stennis Space Center, MS, 39522-5001

Library  
Institute of Ocean Sciences  
P.O. Box 6000  
Sidney, B.C. V8L 4B2  
CANADA

National Oceanographic Library  
Southampton Oceanography Centre  
European Way  
Southampton SO14 3ZH  
UK

The Librarian  
CSIRO Marine Laboratories  
G.P.O. Box 1538  
Hobart, Tasmania  
AUSTRALIA 7001

Library  
Proudman Oceanographic Laboratory  
Bidston Observatory  
Birkenhead  
Merseyside L43 7 RA  
UNITED KINGDOM

IFREMER  
Bibliothèque La Pérouse  
Centre de Documentation sur la Mer  
15 rue Dumont d'Urville  
Technopôle Brest-Iroise  
BP 70 — 29280 Plouzané  
FRANCE