

Morphometry, gross morphology and available histopathology in North Atlantic right whale (*Eubalaena glacialis*) mortalities (1970-2002)¹

MICHAEL J. MOORE*+, AMY R. KNOWLTON#, SCOTT D. KRAUS#, WILLIAM A. MCLELLAN** AND ROBERT K. BONDE++

Contact e-mail: mmoore@whoi.edu

ABSTRACT

Fifty-four right whale mortalities have been reported from between Florida, USA and the Canadian Maritimes from 1970 to 2002. Thirty of those animals were examined: 18 adults and juveniles, and 12 calves. Morphometric data are presented such that prediction of body weight is possible if the age, or one or more measurements are known. Calves grew approximately linearly in their first year. Total length and fluke width increased asymptotically to a plateau with age, weight increased linearly with age, weight and snout to blowhole distance increased exponentially with total length, whereas total length was linearly related to fluke width and flipper length. Among the adults and juveniles examined in this study, human interaction appeared to be a major cause of mortality, where in 14/18 necropsies, trauma was a significant finding. In 10/14 of these, the cause of the trauma was presumed to be vessel collision. Entanglement in fishing gear accounted for the remaining four cases. Trauma was also present in 4/12 calves. In the majority of calf mortalities (8/12) the cause of death was not determined. Sharp ship trauma included propeller lacerations inducing multiple, deep lacerations that often incised vital organs including the brain, spinal cord, major airways, vessels and musculature. Blunt ship trauma resulted in major internal bruising and fractures often without any obvious external damage. In at least two cases fatal gear entanglements were extremely protracted: where the entanglements took at least 100 and 163 days respectively to be finally lethal. The sum of these findings show two major needs: (1) that extinction avoidance management strategies focused on reducing trauma to right whales from ship collisions and fishing gear entanglement are highly appropriate and need to be continued and; (2) that as mitigation measures continue to be introduced into shipping and fishing industry practices, there is a strong effort to maximise the diagnostic quality of post-mortem examination of right whale mortalities, to ensure an optimal understanding of resultant trends.

KEYWORDS: MORPHOMETRICS; CONSERVATION; STRANDINGS; RIGHT WHALE; NORTH ATLANTIC; SHIPSTRIKE; INCIDENTAL MORTALITY

INTRODUCTION

Coastal North Atlantic right whale (*Eubalaena glacialis*) habitat in the western North Atlantic ranges from the southeastern US coast for calving, to New England and Canada for feeding, although whether there is a specific site for major breeding activity is unclear (Winn *et al.*, 1986). The estimated population size has remained at 300-350 for the period 1980-1998 (Kraus *et al.*, 2001). These authors cited significant anthropogenic mortality and diminishing reproductive rates for failure of the population to grow. The low viability of this population and the finding that it is probably declining (Caswell *et al.*, 1999) is concerning (e.g. IWC, 2001a; b). This decline in productivity is in contrast to a 7% net growth rate for southern right whales (Payne *et al.*, 1990; Best *et al.*, 2001). The reproductive rate for North Atlantic right whales is half that of southern right whales (Knowlton *et al.*, 1994; Best *et al.*, 2001; Kraus *et al.*, 2001) although the exact cause of the decline in North Atlantic right whale reproduction is not known.

The mortality rate for North Atlantic right whales is double that of southern right whales (Kraus, 1990; Best *et al.*, 2001). Collisions with vessels and entanglement in fishing gear are major contributors to the increased mortality

rate of adults (Kraus, 1990; Knowlton and Kraus, 2001). Calf mortalities have been more difficult to assign a specific cause of death.

This review summarises data from necropsies of 30/54 confirmed western North Atlantic right whale mortalities from 1970 to 2002. It is notable that had those 54 mortalities not occurred the population would be 20% larger today. This review allows us to assess the quality of data collected, to examine natural history measurements, and suggest possible lines of investigation that might allow better interpretation of data gathered from past cases and lead to better examination techniques and interpretation of future cases. It will also focus attention on particular etiologic agents that may be potentially significant in the reproductive failure of this population.

METHODS

Reports for 54 mortalities during the period between 1970 and 2002 are available in the New England Aquarium data archive (Appendix Table 1; Knowlton and Kraus, 2001). These reports vary in detail from date and location only, to full history, morphometrics and necropsy reports with supporting histopathology and other follow-up investigations. At least partial necropsy data were available for 30 of these cases: 12 calves (<9.2m total length; Best and R  ther, 1992) and 18 juveniles and adults. Data were tabulated to summarise significant gross and histological

¹ This review is dedicated to the memory of David St Aubin: amongst many other things the prosector of Staccato, Eg # 1014, one of the most complete necropsies reported here.

* Biology Department, Woods Hole Oceanographic Institution, Woods Hole, MA 02543, USA.

+ Cape Cod Stranding Network Inc., Box 287, Buzzards Bay, MA 02532, USA.

New England Aquarium, Central Wharf, Boston MA 02110, USA.

** Biological Sciences and Center for Marine Science, University of North Carolina Wilmington, Wilmington NC 28403, USA.

++ US Geological Survey, Florida Caribbean Science Center, 412 NE 16th Avenue, Room 250, Gainesville, FL 32601, USA.

findings, key morphometrics, carcass condition and presumed cause of death, as well as disposition of bones, voucher materials and other samples. Statements in the reports concerning carcass decomposition condition were normalised to a standard scale (Geraci and Lounsbury, 1993) where: 2=fresh; 3=decomposed; 4=severely decomposed. Attention was given to availability of samples that could contribute to a retrospective analysis of reproductive function and pathology. Many of the data and conclusions were taken from the necropsy reports as submitted. These reports are also summarised in the text, where appropriate.

During necropsies, identification photographs were taken of most carcasses for comparison to the right whale catalogue archived at the New England Aquarium (Hamilton and Martin, 1999). This catalogue collates and matches all photographs of right whales taken at sea by research groups that contribute to the Right Whale Consortium. Photographs at necropsy are matched to archived images to compare head callosity patterns and other distinguishing marks such as scars and mutilations. The catalogue details time, place and associated individuals for all recorded sightings, giving a detailed history of the life of each animal. For animals first identified in the catalogue as a calf, an age in years was included in the data and for those not first identified as a calf, a minimum age was listed. The cases that involve chronic fishing gear entanglement have often been previously managed by the Atlantic Large Whale Disentanglement Network, where routine updates on disentanglement attempts are logged by the Center for Coastal Studies, Provincetown MA (<http://www.coastalstudies.org/>).

In a few necropsy cases, the weight of the carcass was determined. This was done by either placing the entire carcass on a flatbed truck and taking it to a local weigh station (truck weighed with carcass and then without carcass to calculate weight of carcass), or using a vessel travel lift as the whale was hauled out of the water (weight sensors are usually present on these devices), or by weighing each load of flesh and bones of the dismantled carcass at a weigh station before taken to the burial site; 6.8% was added to the weight to account for fluid loss for those carcasses that were weighed by this latter method (McLellan *et al.*, 2002). Length and weight measurements were compared to minimum ages to develop curves for predicting weight and age from length. Length data for calves were also reviewed to determine the mean length at or near birth. When necropsies were performed and where a thorough search for gonads was conducted the success at finding gonads is reported.

Morphometric data were plotted and regressed using *Statistica*.

RESULTS

Not all carcasses come ashore or can be examined in detail. As far as it is possible to determine from the available data, necropsies were conducted on 3/9 animals in 1970-79, 5/15 in 1980-89, 17/21 in 1990-99, and 4/10 in 2000-02. Carcass decomposition condition averaged 3.4 (moderate to severely decomposed). Body weight was determined in 10 cases, and ranged from calves at 1,000kg to adults up to 52,640kg. There are 19 partial or complete skeletons archived at a variety of museums. Soft tissue archives were deposited for 18 individuals at various institutions, but the current state and availability of these materials has not been established in all cases.

Table 1 shows the 18 adults and juveniles, and 12 calves for which there are necropsy reports. In 14 cases the presumed cause of death was stated to be, or likely to be, vessel collision. Four deaths were presumed to be caused by gear entanglement. In 12 cases, no cause was given.

Table 2 shows available blubber thickness measurements, and Appendix Table 2 shows available morphometric measurements. Girth data were at times available, and have been included where the animal was not thought to be significantly bloated or deflated. Table 3 shows weight records of total and individual organ weights for a neonate.

Fig. 1a shows the relationship between Julian Day of stranding and calf total length. Fig. 1b shows the logarithmic relationship between age and total length. Fig. 1c shows the linear relationship between age and body weight for a limited subset for which weight and age were available ($n=8$). Fig. 1d shows the exponential relationship between length and weight. Fig. 1e shows the linear relationship between total length and fluke width. Fig. 1f shows the exponential relationship between snout to blowhole length against total length. Fig. 1g shows age against fluke width and Fig. 1h, total length against flipper length. Trauma from collisions of right whales with ships is shown both externally (Fig. 2) and internally (Fig. 3). Fig. 4 shows fishing gear entanglement, Fig. 5 shows summary sketches of two entanglements and Fig. 6 shows lesions in the integument of one case.

Case reports (for which greater details are available than summarised in Table 1)

NEAq 1504

This animal was found floating and retrieved off Cape Cod. It was examined on 4 August 1986. Four cuts, 250-300cm in length, ran cranially from a point 60cm cranial to the flukes on the left lateral aspect, through blubber and muscle into the abdominal cavity. The cuts were spaced at approximately 30cm intervals. The most caudal incision penetrated to the spine and possibly through a vertebra.

MH-89-424-Eg

This calf live stranded on Cumberland Island, GA on 3 January 1989 with foetal folds still visible. It was frozen and trucked to Boston for a full necropsy in March 1989. There were no obvious signs of injury. It did have significant oedema that was not described in detail, but a full forensic examination was not conducted, so the cause of death was undetermined beyond a perinatal death. Detailed organ weights for this animal are given in Table 3.

NEAq 1907

This animal was last seen alive two weeks before washing ashore on 12 March 1991. It was a two year old in poor body condition. Net and line were wrapped tightly around the tail stock for at least eight months, with apparent restriction of movement. Several meters of 6mm line had embedded up to 5cm in to the tail stock, with scar tissue overgrowing the embedded line. Blood flow was not affected. An inflamed area 50cm in diameter was observed caudal to the blowhole. Severe and massive comminuted fractures in the right maxillary and frontal bones extended in to the cranial vault (Fig. 3c). Blood clots were observed around the fractures and in adjacent tissues. Haemorrhage was also observed under the periosteum in the pterygoid sinus area. Dermal discolouration above this area revealed the impact point. Mud was found in gullet and vagina suggesting the whale

Table 1
Summary of post-mortem findings for right whales that died in the NW Atlantic between 1970 and 2002.
(Dashes = no data).

Year	ID number(s)	Sex	Age (y)	Tissue quality (0-4)	Presumed cause of death
1975	USNM 504257	M	-	4	Undetermined
1976	JGM 165/ USNM 504343	M	0	3	Possible collision
1979	JGM 415/ 504886	M	3	-	Vessel collision
1981	HNN 893	M	0	-	Undetermined
1983	MME00084/ NEAq 1128	M	2	-	Vessel collision
1986	MH86142 Eg	F	-	2	Vessel collision
1989	MH89424 Eg	M	0	2	Live stranded/probable perinatal
1991	RKB-1420/ MH91762Eg/ NEAq 1907	F	2	3	Vessel collision
1992	NEAq 1223	F	Min 12	3	Vessel collision
1993	RKB-1424	M	0	2	Vessel collision
1993	RKB-1425	F	0	4	Undetermined
1995	NEAq 2366	M	2.5	-	Entanglement
1995	NEAq 2250	M	Min 4	4	Probable vessel collision
1996	RKB-1429/ NEAq 1623	M	Min 12	3	Vessel collision
1996	MH96441Eg/ NEAq 2220. Satellite tagged	M	Min 5	4	Vessel collision or septicaemia
1996	Jan 02 96 calf	F	0	4	Undetermined
1996	RKB-1430	F	0	4	Undetermined
1996	GA96II2201	M	0	-	Undetermined
1997	NEAq 2450	F	Min 4	3	Vessel collision
1997	RKB-1449	M	0	3	Undetermined
1998	WJW 001/ NEAq 1333/ NCSM 8287	M	Min 21	4	Undetermined
1998	RKB-1451	F	0	3	Undetermined
1999	NEAq 1014	F	Min 28	3	Vessel collision
1999	NEAq 2030	F	Min 10	4	Entanglement
2001	NEAq 1238	M	Min 19	4	Entanglement
2001	RKB-1452 VMSM 2001 1021	M	0	3	Vessel collision
2001	NY-2680-2001	F	0	3	Vessel collision
2002	VMSM 20021097	F	-	-	Undetermined
2002	WAM 577 Eg	F	-	4	Undetermined
2002	NEAq 3107	F	1	3	Entanglement

Table 2
Axillary blubber + skin thickness (cm). * = blubber only.

Case	Sex	Age	Dorsal	Lateral	Ventral
NEAq 3107	F	1	11	27	-
NY-2680-2001	F	0	13	14	17
RKB-1452	M	0	11	11	-
NEAq 1238	M	Min 19	10.5*	-	-
NEAq 1623	M	Min 12	15	17	20
NEAq 2030	F	Min 10	15*	15*	-
NEAq 1014	F	Min 28	13	13.5	-
NEAq 2450	F	Min 4	13.3	-	-
RKB 1449 calf	M	0	3.7	5	4.8
NEAq 2220	M	Min 5	-	-	16.5
504343	M	-	11.3	10.5	12
504886	M	3	13	15	14
HNN 893 calf	M	0	3	5	5
NEAq 1504	F	-	17	17	17
RKB 1420	F	2	8	8	10
NEAq 1223	F	Min 12	14.5	16.2	21.6
NEAq 2250	M	Min 4	12.5	-	-
Jan 02 96 calf	F	0	2.75*	3*	3.5*
RKB 1430 calf	F	0	5	-	-

was forced into the bottom. Diagnosis was vessel collision impact. The debilitation from entanglement could have compromised the whale's ability to avoid vessel traffic.

NEAq 1223 – Delilah

The animal was seen with her first calf in the Bay of Fundy on 5 September 1992, when she was photographed thrashing violently, after which she became motionless and was then determined to be dead on close approach. The calf survived.

The carcass floated ashore on Grand Manan on 9 September. Three possible bruises were then photographed: on the chest ventrally between the flippers; one meter cranial to the genital slit; and a large area 80cm in diameter 250cm caudal to the insertion of the left flipper. A necropsy was undertaken on September 13 and 14. Large amounts of blood were found in the thorax and abdomen suggestive of internal haemorrhaging. Several dark red masses about 10cm in diameter, of a putty-like consistency, soluble in formalin, were thought to represent 'cooked' clotted blood. Samples from these were positive for occult blood. A few of the same were also in the thoracic cavity. Microscopic examination at 400x of smears revealed abundant terminal sporulating bacilliary bacteria. The left lung appeared normal. Other solid visceral organs were badly autolysed. Mammary glands were full of milk. The gastrointestinal tract was largely intact, with some gastric fluid and scant faeces in the lumen. A complete dissection revealed no broken bones. Lung, intestine and skeletal muscle were examined histologically. All were very decomposed. The intestinal serosa were covered in a strongly acidophilic material suggestive of autolysed blood. The internal bleeding along with the surface bruising was assumed to have been caused by severe blunt trauma.

RKB 1424

This calf was run over off the Florida coast by a twin screw 25m vessel travelling at 15 knots on 5 January 1993. It was observed bleeding severely at the surface for 45 minutes before the crew lost sight of it. It was relocated, towed ashore and necropsied five days later. Two distinct and separate propeller laceration series were observed (Fig. 2a).

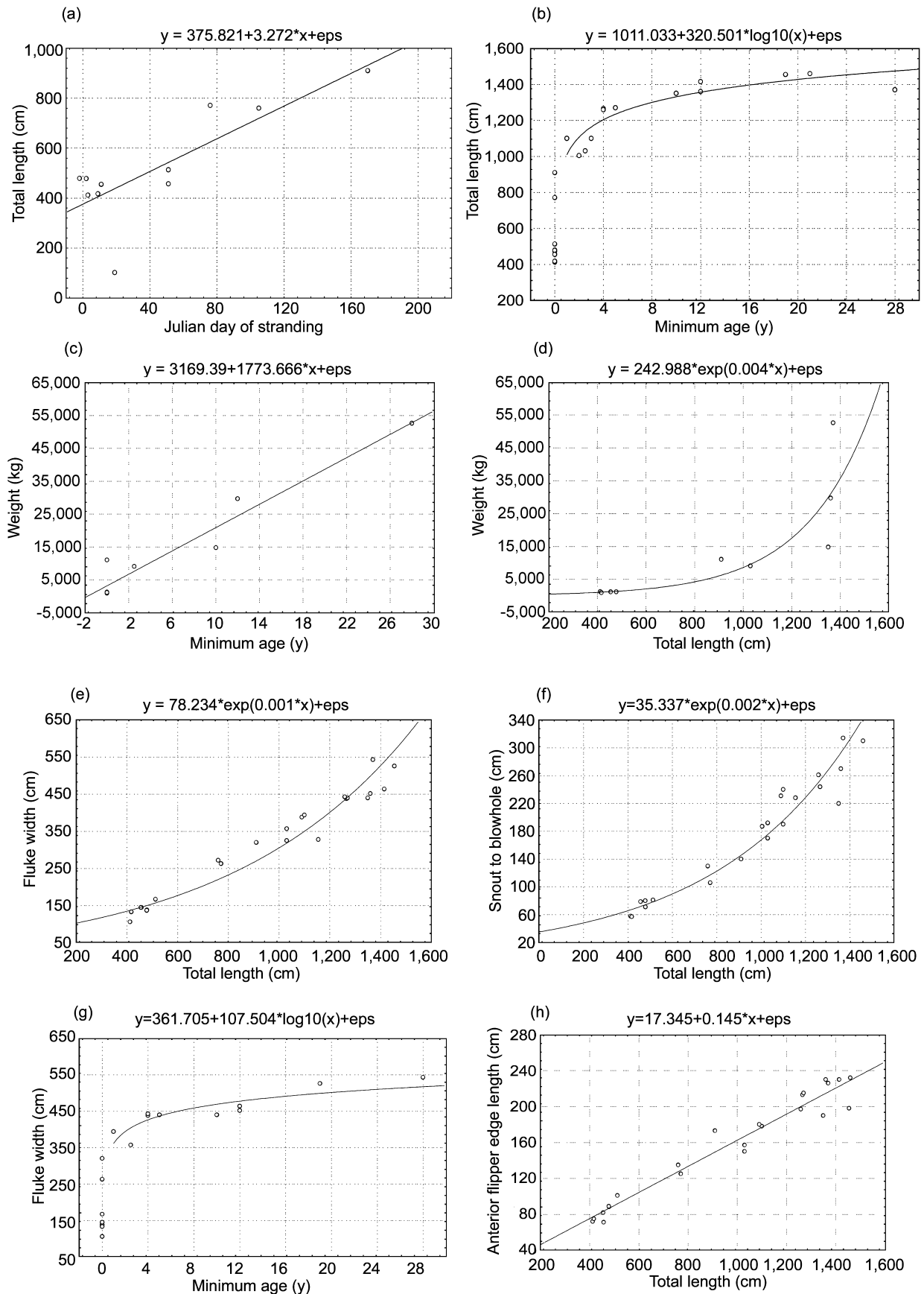


Fig. 1. Relationships between age, weight and length parameters in North Atlantic right whales examined at necropsy in the period 1970 to 2002. Animals less than 9.2 m were assumed to be calves in their first year. (a) Julian day of stranding of calves vs. total length; (b) Age vs. total length; (c) Age vs. body weight; (d) Total length vs. weight; (e) Total length vs. fluke width; (f) Total length vs. snout to blowhole distance; (g) Age vs. fluke width and (h) Total length vs. anterior length of flipper.

Table 3
Total and some organ weights for MH-89-424-Eg.

Item	Weight (kg)	Dimension (cm)	% of total weight
Total whole weight:	861.84		100
Testis R	0.136	15.3 x 4.6 x 2.5	0.02
Testis L	0.128	14 x 4.2 x 4	0.01
Epididymis R	0.105		0.01
Epididymis L	0.71		0.08
Vas deferens	0.256		0.03
Prostate	0.351		0.04
Heart	7.9		0.92
Lung L	5.178		0.60
Liver	14.29		1.66
Spleen	0.216		0.03
Kidney R	3.14		0.36
Kidney L	2.97		0.34
Stomach	3.7		0.43
Intestine	22.9	3,100	2.66
Pancreas	1.06		0.12
Adrenal R	0.015		0.00
Adrenal L	0.021		0.00
Thymus R	0.42		0.05
Thymus L	0.49		0.06
Skull	21.26	106L x 59W	2.47
Humerus R	1.64		0.19
Flukes	17.35		2.01
Thyroid L	0.0685		0.01
Epaxial muscle	26.942		3.13
Hypaxial muscle	11.98		1.39
Transversus	1.95		0.23
Diaphragm	3.904		0.45
Rectus abdominus	0.8		0.09
Iliocostalis	4.114		0.48
External oblique	2.1		0.24
Internal oblique	2.07		0.24
Pectoralis	0.659		0.08
Seratus	0.226		0.03
Levator ani	0.789		0.09
Intercostalis	2.875		0.33
Post cranial skeleton (incl. ribs & scapulas)	102.22		11.86
Blubber	181.3656		21.04
Tongue	46.9476		5.45

Vertebrae: 7 cervical, 14 thoracic, 11 lumbar, 23 caudal, 12 chevron. There was significant edema, so weight data should be interpreted with caution. In addition to body fluid loss, some organs and/or tissues were not weighed as parts. Brain was liquid.

The first extended from the dorsal peduncle to just caudal to the cranium, while the second entered the ventral left flank and ran down the ventral throat to the head. The blade marks travelled from the tail to the head. The viscera were autolysed and severely macerated. A patent ductus arteriosus was present with a 1.5cm internal diameter. Severe massive acute fractures affected the left frontal bone in to the cranium, the left humerus, radius and the proximal tip of one rib. A large contusion with clotted blood was evident dorsally caudal to the cranium. The diagnosis was severe massive acute trauma with fractures and associated haemorrhage, as caused and witnessed by the vessel.

RKB 1425

This calf was observed floating dead on 18 January 1993 off the Florida coast. A necropsy was conducted on 19 January. It was severely decomposed and had severe post-mortem shark predation. Nutritional state appeared to be good. Most of the viscera were missing, although some meconium was present in the distal colon. A patent ductus arteriosus was observed with a 1cm diameter. The intact lungs were heavy




Fig. 2. External trauma from collisions of right whales with ships. Orientation is shown by a long arrow pointing cranially, and a short arrow dorsally. (a) Multiple lacerations in a right whale calf induced by a large ship propeller. Case: RKB 1424. Photographer: Robert Bonde. (b) 12 propeller cuts from the right mid-rostrum, over the dorsal midline to the left-lateral at mid-thoracic. Box show area of dissected detail in Figure 3e. Case: NY-2680-2001 Photographer William McLellan. (c) Sternal bruise (arrows) overlying blubber hemorrhage and fractured transverse processes. Such external evidence of major internal trauma is rare in right whales. Case: NEAq 1014. Photographer: New England Aquarium.

and saturated with blood. Diffuse haemorrhage was observed in the coronary groove of the heart. The diagnosis was perinatal death.

NEAq 2366

This animal came ashore in Rhode Island and was examined on 17 July 1995. It was entangled in 1cm diameter lobster line, with one piece through the mouth at the tongue base, and 6 to 8 lines wrapped tightly around the right flipper insertion, embedded several cm into the distal end of the radius (see Fig. 4a-c). The animal had been entangled for at least one and a half years. The soft tissues overlying the lesion in the radius had a complex pattern of diffuse patchy ossification. These changes were lost in the museum preparation, except for those evident in the image, adherent to the periosteum. The testes were weighed, measured and fixed in formalin: left – weight 1,003g, length 22.5cm, width 12cm, circumference 35.5cm, and right – weight 800g, length 22.5cm, width 11.5cm and circumference 29cm. Many other samples were also taken. No necropsy or histology report can be located.

NEAq 2250

This animal was towed ashore on 20 October 1995. The whale appeared to have been dead about two weeks. It was last seen in good health when satellite tagged on 8 October. Logistics precluded a full necropsy. The animal was deflated with a large area of missing skin, blubber and muscle dorsally, with the spine separated from surrounding muscle and partially protruding. The satellite tag never functioned, nor was it found. The tag insertion point was recorded to have been in the region missing from the dorsum. The wound started 3.6m caudal to the blowholes, and ran caudal for 4.6m. It is unclear if the wound was induced by a propeller, and if it were, whether the wound preceded death. The blubber directly caudal to the blowhole was dark red. Samples of dorsal blubber that were frozen, had little of the usual structural integrity on thawing. Ventral blubber retained its structure under the same treatment. Bacteriological and histological study of dorsal blubber for evidence of septicæmia, in terms of vasculitis and inflammation proved negative, albeit with severe autolysis noted. Blubber samples also tested negative for bacterial endotoxin, using the Limulus Amebocyte Lysate test. At least four vertebral epiphyseal plates were fractured on the ventral surface, with others fractured on the dorsolateral aspect. It was assumed that these fractures were induced by ship strike. Given the good condition of the animal two weeks prior to the discovery of the carcass, an ante-mortem ship strike was assumed to be the most parsimonious cause of death.

Jan 02 1996

This calf was discovered on 2 January 1996 stranded in Florida. It died at least four days prior to being frozen. It was necropsied nine days after discovery. The umbilicus had a 5cm diameter ragged orifice, through which intestinal loops herniated. The baleen was missing, and sand had been driven into the orifices. The only bone fractures were two ribs, thought to be post-mortem. Yellowish waxy deposits were found in the muscle cranial of the peduncle, in the pleural space and elsewhere. Kidney, heart, stomach, intestines and reproductive tract appeared normal. The thymus weighed 1.04kg. No histological samples were taken. Umbilical vessels were patent, with no evidence of infection. The ductus arteriosus was patent with a 15mm diameter. The foramen ovale was occluding with five, 4-6mm circular openings still patent. The major abnormality was the herniation of the intestine at the umbilicus. It was debatable as to whether this was a sign of ante-mortem herniation, or as a result of post-mortem bloating. In the absence of any other changes, it was assumed that the animal died from a congenital umbilical defect.

NEAq 1623 – Lindsay

This animal was found floating dead on 30 January 1996 off the coast of Georgia. It was towed ashore and necropsied the next day. Overall the animal looked fat and healthy. There was no external evidence of any trauma. Most of the viscera were cranial to the liver. The gastrointestinal tract was largely empty of contents. Kidneys and lungs were autolysed but unremarkable. Testes were absent. A 2 × 1.5m area of blubber and underlying musculature just dorsal to the left flipper was infused with blood. This area overlay a region of acute bone damage. Severe massive comminuted fractures affected the occipital, basioccipital and parietal bones, penetrating fully through these massive bones into the brain cavity. Clotted blood infused the musculature overlaying these fractures. Both ear bone complexes

suffered extreme multiple fractures suggesting intense mechanical force. Samples of these areas were taken in formalin. Left ribs 2 and 3 and the caudal tip of the left scapula were also fractured. It was concluded that the animal had suffered massive blunt trauma from a moving vessel and died approximately five days prior to examination.

RKB 1430

This calf was observed off the Georgia coast on 19 February 1996, was towed ashore and necropsied at Gainesville Veterinary School, FL on 20 February. It was in good physical condition with no external abnormalities. Milky fluid was found in the oesophagus and stomach, and mustard yellow colonic contents were also observed. The viscera were autolysed, with a reddened intestinal serosa. Samples of the severely oedematous lungs floated, but marginally. The autolysed right ovary measured 20 × 10 × 3cm. Some cranial bones were disarticulated along fissure lines, but it was unclear if this was pre- or post-mortem. Histologically the left eye showed chronic, active perivascularitis, the lung, ovary, heart, skeletal muscle, retrobulbar tissue and left optic nerve were unremarkable. The animal was assumed to have died two to three days prior to examination of an undetermined cause.

GA96II2201

This calf was found floating off the Georgia coast, towed ashore and examined on 24 February 1996. There was substantial post-mortem shark scavenging, including the blowhole and ventral abdomen areas. There were no other external marks. The stomach contained a watery fluid, while most of the small intestine was missing. The remaining distal 2m of colon contained meconium. The testes measured 14cm in length and 4cm in diameter. The heart had a small amount of pericardial fluid. The lungs had a prominent sub-capsular oedematous serosanguinous exudate: a sample floated in water. Haemorrhage and loose blood clots were observed caudal to the left orbit. There was no evidence of skeletal trauma. Histology showed multifocal alveolar oedema and congestion in the lung, with multifocal patchy atelectasis and haemorrhage also present, suggestive of acute agonal cardiovascular collapse. Heart, eyes and skin were all unremarkable histologically. The unilateral retrobulbar haemorrhage suggested a unilateral traumatic event, but with the absence of external ocular trauma the changes were inconsistent with a concussion event. Ears showed no fracture or structural disruption. Both middle ears contained mesenchymal webs with associated soft tissue. Postnatal persistence of these in humans is often associated with respiratory, middle ear and mastoid disease. The diagnosis remained open.

NEAq 2220

This animal washed up on the beach as a deflated 'blubber bag' containing dissociated bones on 9 March 1997. Remarkably, the epidermis was still adherent to the dermis. One of its vertebrae was found 100m down the beach. Surf and tide precluded adequate anchoring. 8mm polypropylene line ran through the mouth and then over the body to the tail, where there was a single tagged lobster trap, that had been set as part of a string of 20 on 14 November 1996 in the Bay of Fundy, Canada. The string was noted missing in mid-December. The animal was last sighted alive at a satellite tagging attempt on 3 October 1996. The tag had failed to penetrate, but the tag anchor was assumed to have remained in the whale. The polypropylene line had incised the oral

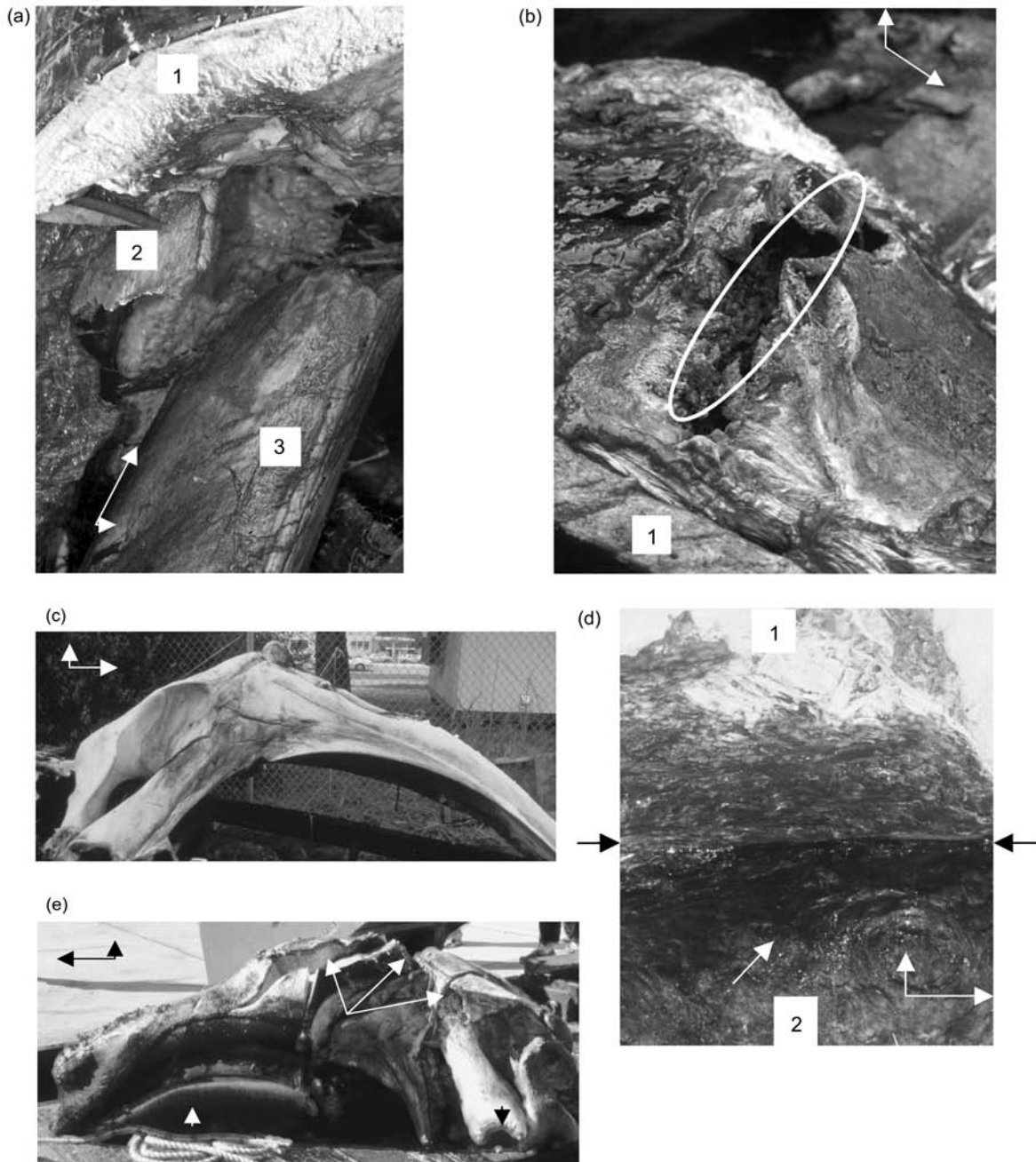


Fig. 3. Internal trauma from collisions of right whales with ships. Orientation is shown by a long arrow pointing cranially, and a short arrow dorsally. (a) Fractured right mandible. 1: lip dermis overlying fractured mandible. 2: Distal and 3: Proximal part of fractured mandible. A 15 cm mandibular fragment was found free in the oral cavity. Case: NEAq 2450. Photographer: Christopher Slay. (b) Fractured right mandible of case in Fig. 2c. Oval overlies fracture site. 1: lip dermis overlying fractures mandible. Case: NEAq 1014. Photographer: New England Aquarium. (c) Cleaned skull of a right whale that sustained a heavy blow to the right side of the head. Fractures in the right maxillary and frontal bones that entered the brain are evident. Case: NEAq 1907. Photographer Robert Bonde. (d) Incised blubber/ muscle interface on the right flank of thorax/abdomen, showing gross evidence of hemorrhage and oedema on the muscle surface. The carcass lay on its left side. The blubber sheet (1) has been partially reflected from the underlying muscle (2). Arrows show the base of the incision at the sub-dermal sheath. Case: NEAq 2450. Photographer: Michael Moore. (e) Multiple propeller cuts through the skull of a juvenile right whale shown in Fig. 2b. The series of cuts (long white arrows) completely bisected the right blowhole, severed the right premaxilla and maxilla, penetrated into the braincase and cleaved the right orbit from the rest of the skull as the trauma proceeded from cranial to caudal across the skull. Short black arrow: baleen. Short white arrow: left orbit. Case: NY-2680-2001. Photographer: William McLellan.

rete, scarred the upper and lower lips, damaged the baleen, and scarred the peduncle and fluke leading edges with scars showing at least two lines wound around the peduncle in opposite directions. Blubber condition was good. A 326cm sagittal slice through the blubber on the left of, but parallel to the dorsal midline ran from the peduncle cranially. The depth of penetration below the blubber was not determined, as the skeletal muscle was mostly absent, following liquifaction. The cranial end of the cut ended in three

parallel propeller type cuts at a 30-degree angle to the major cut, at 20cm spacings. A healed penetration wound was found dorsal to the right axilla. A tract in the fascial plane between the blubber and muscle, containing a purulent exudate, ran from this abscessed area up towards the blowhole. Histology and microbiology of this area was unremarkable. No internal organs remained. A fracture of the left palatine bone adjacent to the left occipital condyle was observed to protrude from the roof of the mouth. The



Fig. 4. Fishing gear entanglement of right whales – external and internal trauma. Orientation is shown by a long arrow pointing cranially, and a short arrow dorsally. (a) Multiple wraps of 1cm diameter line around the right flipper. View from caudal, animal lying on back. Case: NEAq 2366. Photographer: Amy Knowlton. (b) The same flipper as in 4a after the rope was removed at necropsy. The leading edge of the flipper was deeply incised. View from cranial. Case: NEAq 2366. Photographer: Philip Hamilton. (c) Medial aspect of right radius: rope induced erosion, and adjacent periosteal proliferation in the leading edge of the distal third of cleaned right radius from the specimen shown in 4a and b. Skeleton at Museum of Comparative Zoology, Harvard University, Cambridge MA MCZ 62052. Case: NEAq 2366. Photographer: Michael Moore. (d) Rope wrapped around the right flipper of a right whale that struggled acutely and apparently died as a result of entanglement in what was probably a Danish Seine. Image taken looking down on the antero-ventral aspect of the flipper. Case: NEAq 1238. Photographer: Amy Knowlton. (e) Ventral aspect of peduncle of an animal that was chronically entangled with a single loop of line. The line was removed, but the animal subsequently floated ashore dead. Case: 3107. Photographer: Peter Brown. (f) Loss of dorsal post-blowhole blubber sheet induced by a single polypropylene line slowly cutting in dorsally between both axillae during the period May to October 1999. Case: NEAq 2030. Photographer: Lisa Conger. (g) Right side of the case shown in 4f. Part of head and flipper still in the water. Rope is knotted around the right axilla. The line incising the dorsal blubber is evident at left. Case: NEAq 2030. Photographer: Lisa Conger.

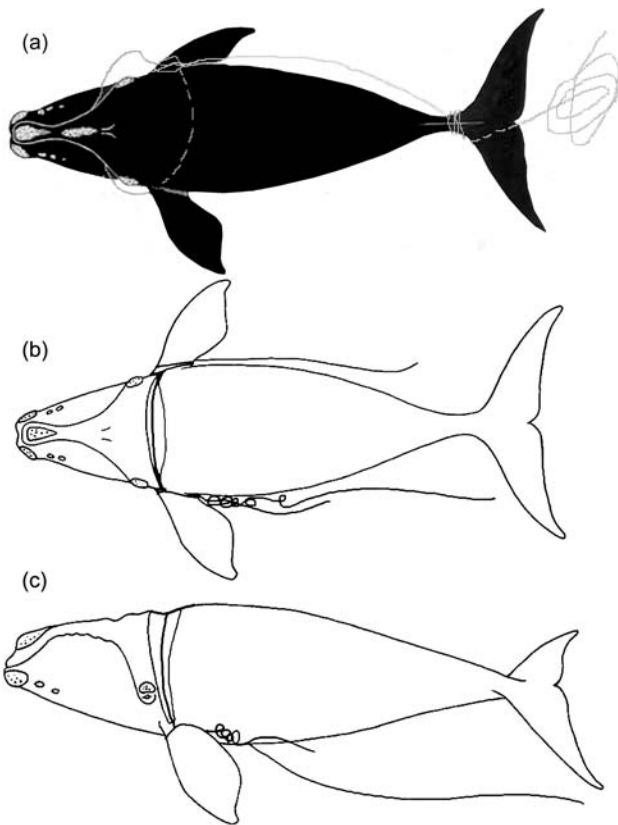


Fig. 5. Sketches of fatal entanglements. Artist: Scott Landry. Sketch made at necropsy (a) or two months prior (b and c). (a) Case: NEAq 1238. Dorsal view, see Fig. 4d; (b) Case: NEAq 2030. Dorsal view, see Fig. 4 f and g; (c) Case: NEAq 2030. Left lateral view.

advanced state of decomposition precluded determination if the ship strike was pre- or post-mortem, although given that dead right whales usually float on their side, a dorsal propeller cut is likely to be pre-mortem. There was also speculation that the healed penetrating wound may have induced a septicæmia. The gear entanglement was assumed to be insufficiently severe to cause the death, especially as the good blubber condition gave no indication of debilitation. The diagnosis remained open.

RKB-1449

This calf stranded dead on 9 January 1997 at Flagler Beach, FL, with evidence of bruising on the tongue and underlying muscle. The lungs were inflated, foetal skin folds remained along the flank of the peduncle, callosities and cyamids were absent, umbilical vessels were open, baleen plates were short (*ca* 5cm), and physical condition was good. The stomach was empty and meconium was present in the intestine. Liver and kidney were autolysed. The heart was normal. Histology revealed widespread autolysis with abundant alveolar and interstitial proteinaceous fluid in the lung, and focally extensive haemorrhage in the tongue. The animal was assessed as a neonate, with death at or close to parturition, that was possibly associated with dystokia, given the lingual bruising.

NEAq 2450

This animal was found floating dead on 19 August 1997 in the Bay of Fundy; it was towed ashore for necropsy on the next day. It appeared to be in good body condition. It had an open comminuted fracture of the right mandible 1/3 the length of the bone from the temporomandibular joint, with a 15cm section lying free in the oral cavity (Fig. 3a). The




Fig. 6. Surface lesions of case shown in Figs 2c and 3b. Case NEAq 1014. (a) Lingual ulcerations. Scale bar = 5cm. Photographer: New England Aquarium; (b) Dermal papillomatous ulcer. Scale bar = 2cm. Photographer: Moira Brown.

fracture surface varied from ragged to smooth, suggesting some chronicity, with a creamy exudate at the fracture site. Clots were found in adjacent severed blood vessels, with haemorrhage in the adjacent lip and gingiva. Several loose bone fragments were found ventral and caudal to the right middle/inner ear complex. Both ear bone complexes were frozen and scanned later using a spiral CT protocol at 140kV and 206mA. Foci of demineralisation most probably caused by a traumatic event, but possibly a degenerative disease were observed. Histology suggested these to be ante-mortem. An extensive area of haematoma and oedema was observed in the blubber-muscle interface on the left lateral, from the cranial thorax to the genital slit region, with red tinged fluid and torn underlying muscle (Fig. 3d). The muscle tears extended to the underlying vertebrae. This lesion measured 6×1 m in width a depth of 3-5cm. Histology failed to confirm if this was an ante-mortem traumatic lesion. The kidneys contained 3cm diameter calcified masses, which were found to contain nematodes of unknown species on histological examination. A ruptured diaphragm was found, with intestinal loops and hepatic lobes in the thoracic cavity. Diaphragmatic muscle adjacent to the left body wall had a diffuse area of haemorrhage which underlay the area of bruising described above. Other than the aortic arch and some lung tissue, little else remained of the viscera. The cervix, uterus and mesosalpinx were not decomposed, but the ovaries were not found in

spite of an intense search. Diagnoses were mandibular fracture at some time prior to death, probable massive blunt trauma to the left side and parasitic nephritis. It is interesting to note that there was an anecdotal report of a right whale behaving oddly in the shipping channels for the two days prior to discovery of the carcass, which would concur with the finding of some remodelling in the jaw fracture, suggesting the animal survived for some days after a major traumatic event. The skeleton was taken to the Nova Scotia Museum of Natural History in Halifax, NS. Once the skull had been cleaned (04/2003), it became apparent that the premaxilla, maxilla, vomer and nasals were all damaged. The nature of the fractures appeared to be pre-mortem (A. Hebda, pers. comm.). This finding corroborates the diagnosis made after necropsy of death due to vessel collision.

RKB 1451

This calf was found floating off the Georgia coast, towed ashore and examined at the Gainesville FL Veterinary School on 11 January 1998. No cyamids were present. It was in good body condition and had moderate to severe contusions in the musculature surrounding the left flipper and along the spinous processes. The abdominal cavity contained several litres of serosanguineous fluid. Bruising was also present at the base of the tongue and several areas around the cranium. The serosae of the stomach and intestines were dark purple. The stomach was empty except for a small piece of membrane, identified histologically as amnion. The liver was congested and dark purple. The pericardium contained about a litre of dark red watery fluid. The pleural cavity contained several litres of dark red watery fluid. A lung sample did not float in water. The following organ weights were recorded in kg: lungs 38, left ovary 0.25, right ovary 0.2565, brain 1.25, right kidney 7.4, left kidney 6.9, heart 16 and spleen 0.7. The intestines were 35.3m long. No broken bones were observed. Histology of heart and kidney was unremarkable. Lung, liver and kidneys were totally autolysed. The diagnosis was perinatal stillborn, with possible delivery complication, given the bruising observed. The absence of cyamids concurs with the assumption that the animal had not suckled.

NEAq 1014 – Staccato

This animal was seen alive in Cape Cod Bay on 15 April 1999 and found dead on 20 April and towed ashore. On the 15 April she was observed with her mouth open just below the surface, in aggregates of pteropods and copepods, suggestive of normal feeding activity. When the animal was examined by a diver prior to towing ashore, blood was observed to be pooling along the lower, right jaw. Multiple papillomatous lesions were found on the body surface, especially along the caudal peduncle, up to 8cm in diameter, with a whitish, mottled, proliferative centre often raised above the skin surface (Fig. 6b). On a cut section a firm well-demarcated nodule of connective tissue was found in the underlying dermis. Histology showed vacuolation and hydropic degeneration of keratinocytes, ulceration, papilliform proliferation, loss of pigment, and perivascular infiltration of acute and chronic inflammatory cells. No viral inclusions were observed. A sternal patch of haemorrhage was observed in the epidermis (Fig. 2c) extending into underlying blubber, along with a granulating abrasion on the left pectoral flipper. Good blubber quality and thickness were observed. Oedema was present in the ventral thoracic fascia from right axilla to mid-abdomen. A fracture was observed in the right mandible (Fig. 3b), 1m from the

temporomandibular joint, with haemorrhage and oedema overlying the fracture site. A thin layer of regenerating cartilage was observed histologically on the exposed fracture surface, suggesting the fracture was at least seven days pre-mortem. The right transverse processes of the last two thoracic and first three lumbar vertebral transverse processes were also fractured. Oedema and haemorrhage were observed in the right axillary and right hypaxial musculature overlying the above transverse process fractures sites. Extensive multi-focal ulceration of the glossal mucosa was observed (Fig. 6a): histology showed full thickness loss of the epithelium. Autolysis prevented adequate gross or histological analysis of the viscera. A dark pasty faecal material was observed in the distal 3-4m of the intestine, red blood cells were observed here microscopically. Diagnoses were: traumatic injury sustained on the right side fracturing the mandible, lingual ulcerations, epidermal papillomatosis and ulceration, haemorrhagic colitis, and suspected septicaemia precipitated by trauma and complicated by chronic illness. The precipitating traumatic event was assumed to be a ship strike. A conference abstract was published on this case (De Guise and St Aubin, 1999).

NEAq 2030

This animal was first sighted entangled on 10 May 1999 on Cultivator Shoals, on the western edge of Georges Bank. It had three wraps of 7/16th inch diameter polypropylene line and gillnet across its back which was tight but not incising. The animal was then sighted in the Bay of Fundy on 2 September. Subsequently two wraps were cut by the disentanglement team, but a third remained deeply embedded across the back, tightly stretched between the two axillae. The last sighting in the Bay of Fundy on 13 September showed the dorsal line to have incised to the base of the blubber. It was found floating dead on 20 October, 5 miles east of Cape May, NJ. Both flippers were incised at the leading edge by the lines into the bone to a depth of 13cm by one wrap on the left and 18cm by two wraps on the right (Fig. 4g). There were knotted tangles at each flipper leading to a single embedded line dorsally and two tight lines under the ventral surface. Tangled line and monofilament gillnet trailed from the left flipper. By this time the dorsal line had embedded in to the musculature, and 1.4m of muscle tissue along the dorsal midline was exposed (Fig. 4f). As the cut moved laterally the gap tapered until closing at the flippers. There was evidence of shark bites at the wound edge. As the animal was hauled up the beach the left scapula partially fell away from the animal. The lines were under extreme tension and snapped back when cut. No histology samples were taken. The medial aspect of the right scapula was described as having proliferative bony change. This was not evident in photographs of the scapula after cleaning. Blubber thickness was low: 11 to 15cm, except in the dorsal keel cranial to the tail, suggesting an emaciated condition. Internally there was no evidence of traumatic skeletal damage or haemorrhage in soft tissue. Internal organs were autolysed, no samples were taken for histology. Skin and blubber were frozen. The diagnosis was massive traumatic injury induced by entanglement in fishing gear with resultant starvation. A sketch of the entanglement is shown in Fig. 5b.

NEAq 1333 – Delta

This animal was examined on the beach in North Carolina on 8 October 1998. There was no skin or baleen remaining and the carcass had been heavily shark scavenged. The

premaxilla and maxilla at mid-rostrum were fractured. Additional old healed fractures were found in the vomer. There was no evidence of bruising in the blubber. Fractured neural spines were found between vertebrae T8 and T17, with the trauma increasing in depth caudally. The shoulder and rib/transverse process joint capsules were heavily ossified. Viscera were absent, with the exception of large vessels and rings of bronchial cartilage. An experimental protocol from the Armed Forces Institute of Pathology (AFIP) was conducted on this specimen. It was designed to determine if there was evidence of anti- or post-mortem tissue reaction from the bones of severely decomposed large whales that were potentially killed from ship strike. Histological examination found no evidence of a vital tissue reaction within the marrow spaces, periosteum or trabeculae of the examined sections of bone, suggesting that the fractures at this site occurred after the animal's death. Cause of death was undetermined.

NEAq 1238

This animal was examined on the beach in the Magdelene Islands, Canada from 4–6 November 2001. It was heavily wound up in approximately 200m of 22mm diameter synthetic three-strand line that passed the right corner of the mouth, between two baleen plates, across the tongue, and exited by the left corner of the mouth, to go under the left flipper, across the chest to the right flipper, circling the right axilla three times and trailing off (Figs 4d and 5a). Each strand of the rope carried a lead filament. A second piece of line appeared to pass through the baleen with a frayed end that exited the mouth at the middle of the right lip. The exact relationship of this line to the rest was obscured by the use of some of the lines to secure the carcass at the initial beaching. At that time, before the necropsy examination, 30m of line was removed that was trailing from the flukes. This line was of a similar size, but different manufacture. A deep rope abrasion was evident around the tailstock, despite the absence of skin. There was also an abrasion on the ventral surface of the left fluke from the leading edge at the insertion to the caudal notch. At the initial beaching a further three wraps were also observed on the peduncle. The majority of fisheries specialists who examined the gear believed the ropes were from a Danish Seine system, although one suggested that it was offshore crab pot line. The depth of the rope-induced wounds was assumed to have arisen from trauma that could only have been induced prior to death, suggesting the animal had struggled in more of the seine gear than was present at the necropsy. Before the animal could be examined internally it was rolled up the beach using an excavator bucket as a lever at the thoracic region. Sub-dermal bruising was observed in the peduncle region beneath the rope burns described above. Blubber was in good condition. Testes and all other internal organs except tongue and aortic arch were fully autolysed. Vertebral epiphyses were fused. No broken bones were observed, except those damaged during carcass manipulation on the beach. It was concluded that the animal had struggled in the entangling gear, although the actual cause of death was unclear, but likely to reflect severe entanglement.

RKB-1452

This animal was examined on the beach in Chincoteague, VA on 19 March 2001; it was in good general nutrition condition, with ample body fat. Five large propeller slashes were observed at 50cm spacing along the dorsal peduncle, penetrating up to 70cm into hemorrhagic tissue. Detailed measurements of the wounds were recorded. Two of the

wounds penetrated the abdominal cavity. The muscle mass appeared ischaemic, suggesting heavy blood loss. Viscera were fully autolysed with the exception of the terminal large intestine. Several of the lumbar vertebrae and epiphyses directly beneath the external propeller lacerations were fractured, and the associated epaxial muscle was hemorrhagic, as observed grossly and histologically. The cuts suggested that the vessel travelled from right caudal to left cranial. The strike had to be pre-mortem as dead whales tend to float on their sides after death. It appeared the animal had its head down to dive at the time of the strike. The diagnosis was that the animal died after massive trauma from a propeller of at least 165cm in diameter.

NY-2680-2001

This animal was found floating off the coast of Long Island and towed to a pier in New York harbour on 19 June 2001. It had 12 propeller cuts from the mid-rostrum, over the dorsal midline to the left-lateral at mid-thorax (Fig. 2b). Epaxial muscle had ruptured through the middle 4–5 wounds in the incision series. Slice 3 cut through the blowhole, maxilla and premaxilla. Four went through the nasal and frontal bones (Fig. 3c). Five went through the sagittal crest. The remaining cuts were in the thoracic region. A number of left ribs and the heart were found dorsal to the transverse processes of the thoracic vertebrae. Haemorrhage was evident at the wound sites and throughout the fascia. Viscera were largely autolysed. The vagina and caudal uterus were present. The diagnosis was vessel strike with 12 propeller gashes along the left side of the animal.

NEAq 3107

First sighted entangled on 6 July 2002, this animal washed up dead in heavy surf on Nantucket Island on 14 October 2002. A single loop of 3/8" polypropylene three-strand line was removed by a disentanglement team from its peduncle five weeks prior to beaching. The entanglement lasted at least seven weeks. The disentanglement followed attachment of a satellite tag buoy to the entangling line to enable relocation of the case. The animal was observed by an aerial survey to be alive, but 'somewhat thin' two weeks prior to beaching. On the beach it was observed to have a substantial post cranial dorsal dip in the lateral profile, typical of an emaciated right whale (Pettis *et al.*, 2004). Extreme surf conditions precluded examination before most of the soft tissues and bones were macerated and extruded via the oral cavity from within the blubber coat, however examination of the peduncle laceration revealed 15 and 19cm cuts respectively in the left and right lateral aspects, and 5cm ventrally (Fig. 4e). Tendons were intact, but two ventral 8mm internal diameter medial caudal veins (which are thick walled) appeared to have been severed and walled off. The dorsal blubber coat was incised from blowhole to tail. The blubber was found to be thinnest caudal to the blowhole, reflecting the emaciation described above. Death was assumed to have resulted from complications arising from the chronic entanglement. Blubber samples were retained. Unremarkable histology was taken of one of the walled off veins.

DISCUSSION

The major finding of these incomplete reports is that the primary cause of death in adults and juveniles appears to be human induced trauma from ship collisions (14/30) and fishing gear entanglement (4/30). Thus, of the 443 animals catalogued in the period 1976–2002 (Kraus *et al.*, 2001;

Right Whale Consortium Database, contact aknowlton@neaq.org) plus 16 dead neonates that were never catalogued, a minimum of 3% (14/459) of the population were killed by ships. It is important to note that ship struck whales may come to shore or be sighted more easily than whales dying from gear entanglement or debilitation. Both the latter cases are more likely to sink if feeding has been precluded for a significant time prior to death, resulting in a significant loss of the low density body lipids, making the carcass negatively buoyant. Furthermore, whereas shipping density decreases rapidly with distance from shore, much of the heavier fixed fishing gear is on the offshore half of the continental shelf, reducing the likelihood that rapidly fatal entanglements will be identified, as such cases once dead are likely to go further offshore with the prevailing offshore wind and currents in much of the North American Eastern seaboard. In spite of the majority of adult and juvenile cases receiving a diagnosis, the conclusions are based on an incomplete dataset given the limitations of the material. An even less complete understanding of the causes of death is evident for the neonatal cases. Necropsy reports used various descriptors, such as 'peri-natal' death, or 'stillbirth'. These conclusions are highly valid, given the recorded size class, lung inflation, presence of meconium in the gastrointestinal tract, and carcass recovery location in the calving ground. But there was no diagnostic conclusion as to etiology in any case. In three cases there were contusions thought to reflect dystokia. It is possible that these cases are all expressions of the expected mortality associated with parturition in any wild mammal population, but equally it is possible that these cases represent other etiologies. It is thus important to analyse any available material and future cases with the concern in mind that these neonatal mortalities may have one or more common underlying causes.

Many of the case reports summarised here raise more questions than they give answers. The enormity of the problem facing an objective analysis from necropsy of the causes underlying right whale mortality is eloquently summarised by the opening narrative of the internal examination of NEAq Catalogue #1907 (Buoy Girl): 'A violent eruption occurred on opening the abdominal cavity. Several meters of intestine and liver were expelled'. On another occasion on 17 October 1990 where a very large male right whale was examined in Maine; the body was on one island and the head on another. In addition to these obvious practical barriers to a complete gross necropsy, none of the necropsies for which histopathological sampling was conducted had tissues available from a full suite of organs. The complex physical, legal and political logistics of this kind of case usually add up to inevitable delays. Autolysis always compromised or destroyed many of the tissues. Eye, aorta and lung seem in general to be the least affected by autolysis. We are thus limited here to a very incomplete dataset, but one which has substantially improved for some more recent mortalities in terms of reducing the time delay between discovery of the animal and necropsy, completeness of the necropsy examination, and the utilisation of diagnostic histopathology and laboratory analysis.

The need to retrieve and fully examine and sample carcasses as rapidly as possible is obvious, given the rapid autolysis that occurs in these extremely well insulated animals. Unfortunately, the material and the working conditions rarely afford the opportunity to fulfil such a protocol in its entirety. Abdominal autolysis occurs rapidly. Given the importance of analysis of the reproductive tract in

helping to understand reproductive failure the abdomen should be opened as soon as the animal is in place for a necropsy. This will allow a search for the gonads as soon as practical, minimising the extent of autolysis. It should be noted that it seems probable that autolysis was the likely cause for the absence of gonads in Eg 2450. A major disappointment in this case series is the frequent absence of gonads. Two reasons could account for this: (1) the right whale ovary and testis is very susceptible to liquefaction and autolysis post-mortem; or (2) there is a significant proportion of the population that is agonadal. The latter would seem to be highly unlikely, but a number of experienced anatomists have been surprised by the absence of these organs in specific cases. To standardise post-mortem observations on right whales, a necropsy protocol has been developed (McLellan *et al.*, 2004).

The numerical data shown in Fig. 1 provide a useful starting point for the management objectives needed for entangled and otherwise injured right whales. In particular, knowledge of length, fluke width, snout to blowhole distance and age will give an indication of likely body weight. This will allow calculations for possible drug doses, logistic planning for necropsies, and mechanical engineering input for fishing gear entanglement mitigation studies. The general shape of the length to weight graphs is strongly reminiscent of those shown for fin and sei whales taken by Icelandic whaling operations (Lockyer and Waters, 1986).

Blubber thickness measurements should be regarded with significant caution. The following affect their accuracy: (1) the orientation of the animal in relation to where the measurement was taken – if the measurement was made close to the ground, there will be many tons of whale compressing that portion of blubber; (2) whether the measurement is taken from an extracted sample, from the resulting hole in the animal, or from an incised blanket piece, the act of incising the fibroelastic blubber system in itself imparts new stresses and releases others, so that it is not possible to obtain an absolute blubber thickness measurement; (3) when blubber is peeled off an animal the hypodermis tears variably, leading to varying thicknesses left on the animal. The records rarely give the necessary details to allow unbiased comparisons between different data series.

There are two cases reported here with diffuse soft tissue ossification in the area around where rope chronically incised into bone (#'s 2030 and 2366). Both lesions were largely or totally lost during museum preparation. Thus, this lesion type should be carefully sampled in future cases.

Data in Table 5 allow an approximation of the proportion of the total weight contributed by individual organs and muscle groups to a neonate.

In summary, this review has shown that gross observations at necropsy have given a good case series of the trauma associated with vessel collisions and gear entanglement. In contrast, the more subtle processes underlying the causes of neonatal mortalities require greater focus on laboratory diagnostic procedures that may elucidate the underlying cause and effect. For all right whale mortalities, a more rapid necropsy response is needed. Finally, each death must be viewed as an opportunity to: (1) test a variety of methods to better assess the health and reproductive status of this species; and (2) provide the federal and state managers of this species the necessary information to assess whether strategies to mitigate human impacts are successful. There are no obvious trends of improvement evident in this dataset.

ACKNOWLEDGEMENTS

The line drawings are all by Scott Landry, Center for Coastal Studies, Provincetown, MA, USA. Data reviewed here were taken from unpublished reports submitted to the New England Aquarium right whale group. Necropsies were led by France Boilly, Greg Early, Joe Geraci, Philip Hamilton, Joanne Lowenstein-Whaley, Jim Mead, Hans Neuhauser, Charlie Potter, Butch Rommel, David St Aubin, Bill Schevill and Scott Wright. Pathology reports were submitted by Greg Bossart, Claus Buergelt, Pierre-Yves Daoust, Sylvain DeGuise, Dale Dunn, Darlene Ketten, Tom Lipscomb, Scott McBurney and the authors. There is also a vast number of other people over the past three decades that have contributed to this dataset. We thank them all, recognising the physically challenging and fiscally unrewarding conditions large whale necropsies always seem to represent. Necropsies were conducted under NE and SE US NMFS MMPA Regional Letters of Authorisation, and under NMFS permit to Dr Teri Rowles, or with the support of Canada's Department of Fisheries and Oceans. Funding to RKB was provided by the US Geological Survey. Logistics funding for the more recent right whale necropsies has been from the National Marine Fisheries Service to the New England Aquarium. Funding for this analysis was provided to MJM as veterinarian for the Cape Cod Stranding Network supported by Baker Trust, Humane Society of the US, International Fund for Animal Welfare, the International Wildlife Coalition and the Pegasus Foundation. We thank Frances Gulland and an anonymous reviewer for constructive reviews. Woods Hole Oceanographic Institution Contribution Number 10951. NOAA Right Whale Research Program NA04NMF4720392.

REFERENCES

- Best, P.B. and Rüther, H. 1992. Aerial photogrammetry of southern right whales, *Eubalaena australis*. *J. Zool., London*. 228:595-614.
- Best, P.B., Brandão, A. and Butterworth, D.S. 2001. Demographic parameters of southern right whales off South Africa. *J. Cetacean Res. Manage.* (special issue) 2:161-9.
- Caswell, H., Fujiwara, M. and Brault, S. 1999. Declining survival probability threatens the North Atlantic right whale. *Proc. Natl Acad. Sci. USA* 96(6):3,308-13.
- De Guise, S. and St Aubin, D. 1999. A non-union chronic fracture in a North Atlantic right whale: the importance of histopathology. Abstracts of the 13th Biennial Conference of the Biology of Marine Mammals, Maui, Hawaii, USA.
- Geraci, J.R. and Lounsbury, V.J. 1993. *Marine Mammals Ashore – A Field Guide For Strandings*. Texas A&M Sea Grant Publication, Galveston, Texas, USA. i-xi+305pp.
- Hamilton, P.K. and Martin, S.M. 1999. *A Catalog of Identified Right Whales from the Western North Atlantic: 1935-1997*. New England Aquarium, Boston. 27pp. [382 plates].
- International Whaling Commission. 2001a. Chairman's Report of the Fifty-Second Annual Meeting. Appendix 1. Resolutions adopted during the 52nd annual meeting. IWC Resolution 2000-8. Resolution on western North Atlantic right whales. *Ann. Rep. Int. Whaling Comm.* 2000:57.
- International Whaling Commission. 2001b. Report of the Workshop on Status and Trends of Western North Atlantic Right Whales. *J. Cetacean Res. Manage.* (special issue) 2:61-87.
- Knowlton, A. and Kraus, S. 2001. Mortality and serious injury of northern right whales (*Eubalaena glacialis*) in the western North Atlantic Ocean. *J. Cetacean Res. Manage.* (special issue) 2:193-208.
- Knowlton, A.R., Kraus, S.D. and Kenney, R.D. 1994. Reproduction in North Atlantic right whales (*Eubalaena glacialis*). *Can. J. Zool.* 72(7):1,297-305.
- Kraus, S.D. 1990. Rates and potential causes of mortality in North Atlantic right whales (*Eubalaena glacialis*). *Mar. Mammal Sci.* 6(4):278-91.
- Kraus, S., Hamilton, P., Kenney, R., Knowlton, A. and Slay, C. 2001. Reproductive parameters of the North Atlantic right whale. *J. Cetacean Res. Manage.* (special issue) 2:231-6.
- Lockyer, C. and Waters, T. 1986. Weights and anatomical measurements of northeastern Atlantic fin (*Balaenoptera physalus*, Linnaeus) and sei (*B. borealis*, Lesson) whales. *Mar. Mammal Sci.* 2(3):169-85.
- McLellan, W.A., Koopman, H.N., Rommel, S.A., Read, A.J., Potter, C.W., Nicolas, J.R., Westgate, A.J. and Pabst, D.A. 2002. Ontogenetic allometry and body composition of harbour porpoises (*Phocoena phocoena* L.) from the western North Atlantic. *J. Zool., London*. 257:457-71.
- McLellan, W., Rommel, S., Moore, M. and Pabst, D. 2004. Right whale necropsy protocol. Final report to NOAA Fisheries for contract #40AANF112525. 51pp.
- Payne, R., Rowntree, V., Perkins, J.S., Cooke, J.G. and Lankester, K. 1990. Population size, trends and reproductive parameters of right whales (*Eubalaena australis*) off Peninsula Valdes, Argentina. *Rep. int. Whal. Commn* (special issue) 12:271-8.
- Pettis, H., Rolland, R., Hamilton, P., Knowlton, A., Kraus, S. and Brault, S. 2004. Visual health assessment of North Atlantic right whales (*Eubalaena glacialis*) using photographs. *Can. J. Zool.* 82:8-19.
- Winn, H.E., Price, C.A. and Sorensen, P.W. 1986. The distributional biology of the right whale (*Eubalaena glacialis*) in the western North Atlantic. *Rep. int. Whal. Commn* (special issue) 10:129-38.

Appendix Table 1
 Summary of right whale mortalities on file at New England Aquarium 1970-2002. Dash = no data.

Case #	Field number(s)	Date of Exam.	Location found	Sex	Initial state	Necropsy	Primary observer	Disposition of skeleton	Disposition of other samples
1	-	Jan 26 1970	Neptune Beach, FL	F	Live on beach	N	D. and M. Caldwell	-	-
2	-	Fall 1971	Atlantic Beach, NY	-	-	N	-	-	-
3	-	Jan 20 1972	Freeport, TX		Tail severed	N	-	-	-
4	USNM 500860	Jan 12 1974	Edisto Island, SC	M	-	N	-	Skull to USNM	-
5	USNM 504257 MH-75-044-Eg	May 13 1975	Monomoy Island, MA	M	-	Y	J. Mead, SIMNH	Skull to USNM	Blubber to NEAq
6	JGM 165/ USNM 504343 MH-76-056-Eg	Apr 15 1976	Duck Hbr., Wellfleet, MA	M	Floating off Race Pt. then beached.	Y	J. Mead, SIMNH	Skull to USNM	-
7	SEAN1226	Nov 05 1976	32km SE of Portland ME	-	Floating, lost. Cuts and slashes on back	N	-	-	-
8	JGM 415/ 504886 MH-76-026Eg	Mar 25 1979	Wainscott, Long I., NY	M	Tail severed	Y	J. Mead, SIMNH	Skull to SIMNH	-
9	S-Eg-42	Dec 11 1979	Atlantic Beach, FL	?F	Stranded dead	N	R. Jenkins, Marineland	Towed out to sea	-
10	HNN 893	Dec 30 1981	St Simons Isl., GA	M	Stranded dead	Y	H. Neuhauser	-	-
11	JEH 1063	Feb 20 1982	Ossabaw Island, GA	F	Stranded dead	N	R. Bonde, USGS	Natural History Museum of Los Angeles County (LA 054763)	None
12	-	Apr 19 1982	SW Georges Bank	F	Floating	N	T. Joyce WHOI	-	-
13	MME00084/ NEAq 1128/ MMS 83-003	Feb 2 1983	Isl. Bch., State Pk., NJ	M	Tail severed	Y	-	-	-
14	MH-86-142-Eg/ NEAq1504	Aug 07 1986	17nm ENE Race Pt, MA	F	Prop slashes: floating	Y	G. Early, NEAq	Callosity to USNM	NEAq
15	-	May 22 1987	42° 17'N, 70° 27'W (MA)		Floating	N	M. Weinrich, Cet. Res. Unit	-	-
16	-	Jul 09 1987	Cobble Bch., Seaforth, NS	M	Several gashes in back	N	-	Buried on site	-
17	-	Jan 17 1988	Melbourne Bch. FL	M	-	Y?	D. Odell, Sea World FL	Sea World of FL	-
18	-	Mar 15 1988	Portan Pnsl., Newfoundland	-	Stranded dead	N	J. Lien, Memorial U.	-	-
19	-	Nov 17 1988	Bay of Fundy	-	Drowned in lobster gear	N	L. Murison, Grand Manan	Discarded at sea	-
20	MH89-424-Eg	Jan 03 1989	Cumberland Isl., GA	M	Alive on beach. Dead 6h. later	Y	N.E.Aq.	MCZ 61280, Harvard	-
21	-	Jan 26 1989	Ormond Beach, FL	-	Decomposed	Y	J. Lowenstein-Whaley	-	-
22	S89Eg22/ NEAq 1219	Sep 08 1989	St Augustine, FL	F	Beached: decomposed	N	D. Odell	-	-
23	S-89-Eg-23	Sep 08 1989	Nr, St Augustine, FL (6 mi from Eg-22)	-	Stranded dead	-	-	-	-
24	-	Oct 17 1990	Head Hbr. Isl., ME	M	Stranded dead	N	P. Stevick, Coll. Atl.	-	-
25	RKB-1420/ MH-91-762-Eg/ NEAq 1907	Mar 12 1991	Fernandina Bch., FL	F	Stranded dead	Y	R. Bonde, USGS	Bone and baleen FL Mus. Nat Hist., Gainesville, FL	-
26	NEAq 1223	Sep 05 1992	Nr. Bulkhead, Bay of Fundy	F	Death photographed at sea	Y	S. Kraus, NEAq	New Brunswick Mus.	-
27	RKB-1424	Jan 10 1993	Off St Augustine, FL	M	Hit by USCG Jan 05	Y	R. Bonde, USGS	Held at necropsy site.	-
28	RKB-1425	Jan 19 1993	Off Plyalinda Bch. FL	F	Floating dead	Y	R. Bonde, USGS	-	-
29	-	Dec 06 1993	15 nm E of Cape Charles, VA	-	Floating dead, lost	N	K. Cute, Manomet	-	-
30	GM-94-01	Jul 13 1994	So. Cove, Kent Island	M	Stranded dead	N	GM?	-	-

Cont.

Appendix Table 1 cont.

Case #	Field number(s)	Date of Exam.	Location found	Sex	Initial state	Necropsy	Primary observer	Disposition of skeleton	Disposition of other samples
31	NEAq 2250	Oct 20 1995	Long Island, NS	M	Stranded dead	Partial	P. Hamilton, NEAq	Left on beach	-
32	NEAq 2366	July 17 1995	Middletown, RI	M	Dead	Y		MCZ 62052	-
33	Jan 02 96 calf	Jan 11 1996	Atlantic Beach, FL	F	Stranded dead Jan 02, frozen and trucked to Boston	Y	G. Early, NEAq	Skull to MCZ	-
34	EGNE9603WBB	Feb 08 1996	22 nm E of Jacksonville Bch., FL	F	Floating dead, lost	N	W. Brooks, FI DEP	-	-
35	RKB-1429/ NEAq 1623	Feb 01 1996	10 nm E of Sapelo Isl., GA	M	Floating dead	Y	R. Bonde, USGS	U. GA Mus. Nat. Hist.	-
36	RKB-1430	Feb 20 1996	20nm E of S end of Cumberland I., GA	F	Floating dead Feb 19	Y	R. Bonde, USGS	Skull retained at FL Vet Sch.	-
37	GA96II2201	Feb 24 1996	-	M	-	Y	S. Wright, FL Mar. Res. Inst.	-	-
38	MH-96-441-Eg/ NEAq 2220	Mar 11 1996	Newcomb Hollow Bch, Wellfleet, MA	M	Stranded dead	Y	G. Early, NEAq	North-Eastern U.	-
39	RKB-1449	Jan 09 1997	Flagler Beach, FL	M	Stranded dead	Y	R. Bonde, USGS	Skull and baleen to FI Mus. Nat. Hist.	-
40	NEAq 2450	Aug 20 1997	Flour Cove, Long Isl. NS	F	Floating dead	Y	W. McLellan, UNC Wilm.	Nova Scotia Museum	-
41	RKB-1451	Jan 11 1998	30 nm E of St. Simmons I, GA	F	Floating dead	Y	R. Bonde, USGS	Not retained	-
42	WJW 001/ NEAq 1333/ NCSM 8287	Oct 8 1998	VA/NC State line	M	Stranded dead	Y	W. McLellan, UNC Wilm.	NC State Museum	-
43	MH-99-601-Eg/ NEAq1014	April 21 1999	Duck Hbr. Wellfleet, MA	F	Floating dead	Y	D. StAubin, Mystic Aq.	U. Mass. Amherst	-
44	CCSN99-143, NEAq 2030	Oct 21 1999	Cape May, NJ	F	Floating dead	Y	D. StAubin, Mystic Aq.	Paleontological Research Inst., Ithaca, NY	-
45	EGNEFL0103CTT	Feb 13 2001	Flagler Beach	M	Stranded dead	N	J. Hain, Assoc. Sci. of Woods Hole	-	-
46	RKB 1452 VMSM2001 1021	Mar 17 2001	Assateague Island, VA	M	Stranded dead	Y	R. Bonde, USGS	-	-
47	NY-2680-2001	June 19 2001	Jones Beach Inlet, Long Island, NY	F	Floating dead	Y	W. McLellan, UNCW	Buried	-
48	-	July 1 2001	St Theresa's, Newfoundland	M	Stranded dead	N	W. Ledwell, MUN	MUN - partial	-
49	Eg 1238	Nov 04 2001	Magdalen Isl., QE, Canada	M	Stranded dead	Y	P.Y. D'Aoust, AVC	Royal Ontario Museum	-
50	NEA130602	Jun 10 2002	93 mi. E of Provincetown MA	M	Floating dead	N	H. Pettis, NEAq	-	-
51	02-EGL-34	Aug 22 2002	23 mi. off Ocean City, MD	F	Floating dead	N	C. Driscoll MD DNR	-	-
52	VMSM 20021097	Sep 25 2002	See Note 1	F	Floating dead	N	M. Swingle	-	-
53	WAM 577 Eg	Sep 14 2002	See Note 2	F	Stranded dead	N	W. McLellan, UNCW	Scattered on beach	-
54	NEAq 3107 MH 02 726 Eg	Oct 12 2002	Nantucket, MA	F	Stranded dead	Y	M. Moore, WHOI	11 ribs only, WHOI	-

AFIP: Armed Forces Institute of Pathology; AVC: Atlantic Veterinary College, PEI Canada; CCS: Center for Coastal Studies; MCZ: Museum of Comparative Zoology, Harvard University; MD DNR: State of Maryland Dept. Natural Resources; MUN: Memorial U., Newfoundland; NEAq: New England Aquarium - (MH #'s); USNM: United States National Museum, Smithsonian Institution; UNCW: University of North Carolina, Wilmington; USGS: United States Geological Survey; VMSM: Virginia Marine Science Museum (now Virginia Aquarium and Marine Science Center).

Note 1: Probably the same carcass as sighted 20mi. E Chincoteague VA on Sept 3 2002. Examined at False Cape State Park, VA.

Note 2: Probably the same carcass as sighted by US Navy 93 mi. SSE Ocean City MD Sept 6 2002. Examined at Pea Island National Wildlife Reserve, NC.

