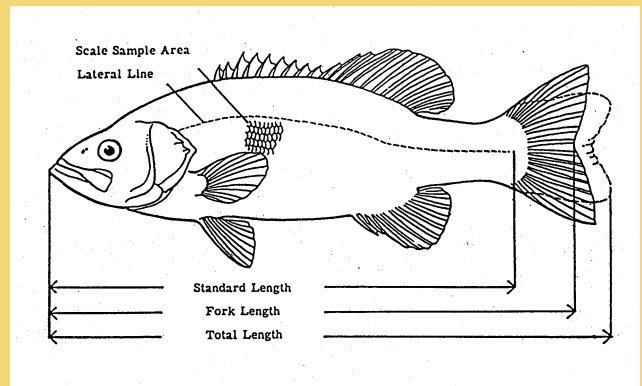


Illustrated Field Guide for Assessing External and Internal Anomalies in Fish

Information and Technology Report
USGS/BRD/ITR-2002-0007



Technical Report Series

The Biological Resources Division publishes scientific and technical articles and reports resulting from the research performed by our scientists and partners. These articles appear in professional journals around the world. Reports are published in two report series: Biological Science Reports and Information and Technology Reports.

Series Descriptions

Biological Science Reports

ISSN 1081-292X

This series records the significant findings resulting from sponsored and co-sponsored research programs. They may include extensive data or theoretical analyses. Papers in this series are held to the same peer-review and high-quality standards as their journal counterparts.

Information and Technology Reports ISSN 1081-2911

These reports are intended for publication of book-length monographs; synthesis documents; compilations of conference and workshop papers; important planning and reference materials such as strategic plans, standard operating procedures, protocols, handbooks, and manuals; and data compilations such as tables and bibliographies. Papers in this series are held to the same peer-review and high-quality standards as their journal counterparts.

Copies of this publication are available from the National Technical Information Service, 5285 Port Royal Road, Springfield, Virginia 22161 (1-800-553-6847 or 703-487-4650). Copies also are available to registered users from the Defense Technical Information Center, Attn.: Help Desk, 8725 Kingman Road, Suite 0944, Fort Belvoir, Virginia 22060-6218 (1-800-225-3842 or 703-767-9050).

An electronic version of this report is available on-line at: http://www.cerc.usgs.gov/pubs/center/pdfDocs/ITR_2002_0007.pdf

NOTE: The mention of trade names does not constitute endorsement or recommendation for use by the Federal Government.

Illustrated Field Guide for Assessing External and Internal Anomalies in Fish

Information and Technology Report
USGS/BRD/ITR—2002-0007
September 2002

by

Stephen B. Smith¹
Anne P. Donahue²
Robin J. Lipkin²
Vicki S. Blazer³
Christopher J. Schmitt²
Ronald W. Goede⁴

¹U.S. Geological Survey, Biological Resources Discipline, Office of the Northeast Regional Hydrologist, 12201 Sunrise Valley Drive MS 433, Reston, VA, 20192

²U.S. Geological Survey, Columbia Environmental Research Center, 4200 New Haven Road, Columbia, MO, 65201

³U.S. Geological Survey, Leetown Science Center, National Fish Health Laboratory, 1700 Leetown Road, Kearneysville, WV, 25430

⁴Utah Division of Wildlife Resources, Fisheries Experiment Station, 1465 West 200 North, Logan, UT, 84321

Contents

	<i>Page</i>
Abstract.....	iv
1.0 Introduction.....	1
1.1 Background and Development.....	1
1.2 Scope and Intent.....	1
1.3 Typographic Conventions.....	2
1.4 Animal Welfare.....	2
2.0 Roles and Responsibilities.....	2
2.1 Landowner Permission.....	2
2.2 Shipment of Samples and Records.....	2
2.3 Shipment of Equipment and Supplies.....	2
2.4 Determining the Age of Fish.....	2
2.5 Photographs and Videotape.....	2
2.6 Communication.....	3
3.0 Equipment and Supplies.....	3
4.0 Record Keeping and Housekeeping Items.....	3
5.0 General Field Procedures.....	3
5.1 Before Leaving on a Collecting Trip.....	3
5.2 Procedures to be Followed Upon Arrival at a Station.....	3
5.3 Collecting and Holding Fish.....	8
6.0 Processing Fish.....	8
6.1 Fish Processing Flow Chart.....	8
6.2 Procedures for External Examination.....	11
6.2.1 Body Surface.....	11
6.2.2 Head and Oral Cavity.....	15
6.2.3 Eyes.....	18
6.2.4 Opercula.....	20
6.2.5 Gills.....	21
6.2.6 Fins.....	23
6.3 Procedures for Internal Examination.....	25
6.3.1 Liver, Gall Bladder, and Bile.....	25
6.3.1.1 Liver.....	25
6.3.1.2 Liver Sample Collection.....	26
6.3.1.3 Gall Bladder Fullness and Bile Color.....	27
6.3.2 Gonads.....	28
6.3.3 Spleen.....	30
6.3.4 Kidney(s).....	31
6.3.4.1 Posterior (Trunk) Kidney.....	31
6.3.4.2 Anterior (Head) Kidney.....	32
6.4 Scales or Spines.....	33
6.5 Cleaning Equipment.....	33
7.0 Post-collection and Processing Procedures.....	33
7.1 Complete and Check Fish Health Examination and Station Identification Forms.....	33
7.2 Clean-up.....	33
8.0 Upon Return from the Field.....	33
8.1 Photocopy and Mail Data Forms and Other Records.....	33
8.2 Ship Histopathology Samples.....	33
8.3 Process Film.....	34
8.4 Age Fish and Mail Age Data.....	34
8.5 Thoroughly Clean Non-Expendable Equipment.....	34
9.0 Acknowledgements.....	34
10.0 References.....	34
Appendix A.....	37
Appendix B.....	43

Table, Boxes and Flow Chart

	<i>Page</i>
Table 1. Suggested Equipment and Supplies.....	4
Box 1. Suggested Housekeeping Activities.....	6
Box 2. Suggested Quality Assurance and Record Keeping Activities.....	6
Flow Chart.....	9

Figures

Figure 1. Tag and scale envelope labeled with a unique fish ID number.....	7
Figure 2. Diagnostician and recorder conducting a fish health assessment.....	7
Figure 3a. Outdoor work area and equipment setup.....	7
Figure 3b. Indoor work area and equipment setup.....	7
Figure 3c. Outdoor work area and equipment setup, with biologists processing fish.....	7
Figure 4. Layout of equipment and supplies.....	8
Figure 5. Biologists collecting fish using an electrofishing boat.....	8
Figure 6a. Length measurements and scale sampling areas for spiny-rayed fish.....	10
Figure 6b. Length measurements and scale sampling areas for soft-rayed fish.....	10
Figure 7. Biologists examining the external features of fish.....	11
Figure 8. Normal body surface.....	11
Figure 9a. Raised growths on body surface.....	11
Figure 9b. Raised growths on body surface.....	12
Figure 10a. Body surface lesion.....	12
Figure 10b. Body surface lesion (ulcer).....	12
Figure 11a. Example of normal spine versus deformed.....	12
Figure 11b. Examples of spine deformities.....	12
Figure 12a. An example of hemorrhagic body observation.....	12
Figure 12b. Hemorrhaging within the body surface.....	13
Figure 13. Example of the presence of abnormal dark spots on the body surface.....	13
Figure 14a. Example of the appearance of body fungus.....	13
Figure 14b. Body fungus.....	13
Figure 15. White spots on body surface.....	13
Figure 16. Leech attached to the dorsal fin.....	13
Figure 17. Black spots.....	14
Figure 18. Anchor worm.....	14
Figure 19a. Example of normal versus deformed head.....	15
Figure 19b. Deformed head.....	15
Figure 20a. Lower lip growth.....	15
Figure 20b. Lower lip growth.....	15
Figure 20c. Upper and lower lip growth.....	15
Figure 21. Swollen nare.....	16
Figure 22a. Missing barbels.....	16
Figure 22b. Stubbed barbels.....	16
Figure 22c. Deformed barbels and lower lip growth.....	16
Figure 23a. Head lesion.....	17
Figure 23b. Head lesion.....	17
Figure 23c. Leech attached to the oral cavity.....	17
Figure 24. Example of a normal eye.....	18
Figure 25a. Example of exophthalmia.....	18
Figure 25b. Example of exophthalmia (also an example of emboli).....	18
Figure 26a. Opaque or cloudy eye.....	18
Figure 26b. Opaque eye.....	18
Figure 27a. Missing eye.....	19
Figure 27b. Missing eye.....	19
Figure 28. Hemorrhagic eye.....	19
Figure 29a. Emboli; visible gas bubbles within the eye.....	19
Figure 29b. Emboli or gas bubbles (also an example of popeye).....	19

Figure 30a.	Normal operculum.....	20
Figure 30b.	Normal operculum.....	20
Figure 31.	Slight shortening of the opercular flap.....	20
Figure 32.	Example of severely shortened opercula with gills clearly exposed.....	20
Figure 33.	Curled opercular flap.....	20
Figure 34.	Normal gill with no apparent aberrations.....	21
Figure 35.	Marginate and frayed gill.....	21
Figure 36.	Example of pale gills.....	21
Figure 37a.	Parasites on the gills.....	22
Figure 37b.	Abnormal discoloration (mottled appearance) of the gills.....	22
Figure 38.	Normal fins.....	23
Figure 39a.	Caudal fins displaying active mild erosion.....	23
Figure 39b.	Active fin erosion.....	23
Figure 40a.	Fins with severe erosion.....	23
Figure 40b.	Severe erosion of the caudal fin with a possible secondary infection.....	23
Figure 41.	Caudal fin with frayed or ragged edges.....	24
Figure 42a.	Fins with reddened or hemorrhagic areas.....	24
Figure 42b.	Hemorrhagic and frayed fins.....	24
Figure 43.	Visible gas bubbles (emboli) within the fins.....	24
Figure 44a.	Fin containing a nodule.....	24
Figure 44b.	Dorsal fin with leech.....	24
Figure 45.	Viscera removed from the fish for the purpose of conducting the internal examination.....	25
Figure 46.	Normal liver.....	25
Figure 47.	Tan or “coffee with cream” colored liver.....	25
Figure 48a.	Liver with general discoloration.....	25
Figure 48b.	Generally discolored liver.....	26
Figure 49.	Liver with focal discoloration.....	26
Figure 50a.	Nodules in the liver.....	26
Figure 50b.	Nodules in the liver.....	26
Figure 51.	Normal gall bladder.....	27
Figure 52a.	Empty gall bladder.....	27
Figure 52b.	Empty gall bladder.....	27
Figure 53a.	Immature male gonads.....	28
Figure 53b.	Mature male gonads.....	28
Figure 54.	Immature female gonads.....	28
Figure 55a.	Mature female gonads.....	28
Figure 55b.	Mature female gonads.....	28
Figure 55c.	Mature female gonads.....	28
Figure 56.	Large mass located in gonads.....	29
Figure 57a.	Normal spleen with no apparent aberrations.....	30
Figure 57b.	Normal spleen.....	30
Figure 58.	Spleen sample containing nodules of various sizes.....	30
Figure 59.	Abnormally enlarged spleen.....	30
Figure 60.	Normal kidney compared to abnormal kidney (mottled in appearance).....	31
Figure 61.	Swollen kidney.....	31
Figure 62.	Various aberrations found in the kidney.....	31
Figure 63.	Abnormal kidney; enlarged and mottled with white nodules.....	32
Appendix A-1.	Station identification form.....	39
Appendix A-2.	Fish health examination form.....	41
Appendix B-1.	External features of a composite fish.....	44
Appendix B-2.	Anatomy of spiny-rayed bony fish.....	45
Appendix B-3.	Anatomy of soft-rayed bony fish.....	46

ILLUSTRATED FIELD GUIDE FOR ASSESSING EXTERNAL AND INTERNAL ANOMALIES IN FISH

by

Stephen B. Smith
Anne P. Donahue
Robin J. Lipkin
Vicki S. Blazer
Christopher J. Schmitt
Ronald W. Goede

Abstract. Procedures are described for processing fish for examination of external and internal anomalies and pathologies indicative of exposure to environmental contaminants and other perturbations. For the procedures described here, fish are captured (preferably by electrofishing) and held alive until processing (generally <1 h). Fish are weighed, measured, and necropsied, and a scale sample is obtained from for age determination. Information is given for the collection and preservation of tissue samples for histopathological analysis. Photographs of most abnormalities are included along with normal conditions for easier identification of external (oral, head, eye, gill, opercula, and fin) and internal (liver, spleen, gonad, and kidney) anomalies. The report also includes recommendations for record keeping, sample labeling, and shipping records, equipment, supplies, and samples. A list of suggested equipment and supplies for field processing is included as are instructions for cleaning equipment.

Keywords: contaminants, fish health, external anomalies, internal anomalies, histopathology.

Suggested citation:

Smith, S.B., Donahue, A.P., Lipkin, R.J., Blazer, V.S., Schmitt, C.J., and Goede, R.W., 2002, Illustrated field guide for assessing external and internal anomalies in fish: U.S. Geological Survey, Information and Technology Report, 2002-0007, 46 p.

Conversion Factors

Multiply	By	To Obtain
	<i>Length</i>	
micron (μm)	0.00003937	inch
millimeter (mm)	0.03937	inch
centimeter (cm)	0.3937	inch
meter (m)	3.281	foot
	<i>Area</i>	
square centimeter (cm^2)	0.001076	square foot
	<i>Volume</i>	
liter (L)	0.264	gallon
milliliter (mL)	0.000264	gallon
	<i>Mass</i>	
gram (g)	0.03527	ounce, avoirdupois
kilogram (kg)	0.453	pound

1.0 INTRODUCTION

1.1 Background and Development of this Document

This illustrated field guide was developed from and is intended as a companion to an earlier report published by the U.S. Geological Survey (USGS) Biomonitoring Status and Trends (BEST) Program that described field procedures for assessing the exposure of fish to environmental contaminants (Schmitt and others, 1999). The earlier document incorporated information and procedures from numerous other sources, including Columbia Environmental Research Center and National Water Quality Assessment (NAWQA) Program SOPs, and study plans, reports, books, manuals, and reports from other studies (Lagler, 1956; Lagler and others, 1962; Smith, 1973; Hunn, 1988; Meyer and Barclay, 1990; Baker and others, 1997). The health assessments based on field observations were originally developed from the procedures of Goede (1989, 1996) as described by Goede and Barton (1990). The earlier document (Schmitt and others, 1999) was cross-referenced to Goede's (1988) color atlas of pathologies in salmonid fishes. Here we have made the field assessment procedures more generally applicable (that is, for use in a wider geographic area and for use by other programs and studies) by including photographs of other fishes to aid biologists in the identification of various grossly visible external and internal anomalies. However, the cross-references to Goede (1988) have been retained for use with salmonids and for pathologies for which photographs in other taxa were not available.

1.2 Scope and Intent of this Report

Together with the earlier document (Schmitt and others, 1999), this report describes procedures to be used for monitoring and assessing the exposure of fish to environmental contaminants and other stressors. We describe how to examine and handle freshly captured fish, and how to collect, store, and ship the tissues necessary for further examination. This report is not intended as a guidance document or protocol for selecting methods, nor does it contain information for interpreting study results based on the use of methods in the guide. The rationale for selecting this particular suite of methods, as well as information on the interpretation of findings, is presented elsewhere (Biomonitoring of Environmental Status and Trends, 1996; Schmitt and Dethloff, 2000; Meador and others, 1993). The procedures we describe are primarily post-fish collection; although information on preparing for and organizing a study and suggested methods for documenting the date, time, and location of collection are included, most of the actual procedures begin after fish have been collected. Procedures are speci-

fied for making observations by using photographs and collecting information and tissues; preserving, wrapping and packaging samples; numbering samples and recording data; and storing and shipping samples and records. We also provide instructions for documenting (see Appendix A-1) the type of equipment used to collect the fish, the duration of the fishing effort, and the location of the collection site. A list of suggested equipment and supplies is also provided. To the extent possible, the procedures conform to Good Laboratory Practices (U.S. Environmental Protection Agency, 1989); however, quality assurance and quality control issues are beyond the scope of this document. Depending on the purpose and design of the study, it may be necessary to utilize or develop additional project-specific protocols and standard operating procedures (SOPs) conforming to this guide, as well as a quality assurance plan. Collection locations and times, preferred taxa, exact numbers of samples, modifications or additions to standard procedures, and field and laboratory cooperators should be identified in the work/study plan or protocol under which the procedures described in this guide are used. This guide and its sample data forms may be photocopied or otherwise reproduced on waterproof paper for field use.

Fish collections conducted under the auspices of USGS monitoring programs (BEST and NAWQA) include observations of external anomalies. The BEST program, as well many smaller-scale research projects, also examine internal organs. Fish are often collected from areas where contaminants are present at concentrations that may affect the health of individual fish. Contaminants of concern include polycyclic aromatic hydrocarbons (PAHs), such as chrysene and phenanthrene; organochlorine pesticides (DDT, toxaphene); industrial compounds (polychlorinated biphenyls - PCBs, and polychlorinated dibenzo-*p*-dioxins); metals (mercury, lead); metalloids (arsenic, selenium); currently used pesticides (atrazine, propanil, chlorpyrifos); and pharmaceuticals. Nevertheless, it is important to note that this guide does not include specific diagnoses; rather, it provides more generic identifications of observable conditions. Diagnosis can **only** be accomplished through histopathology and other laboratory expertise.

The methods described in this report and in the previous document (Schmitt and others, 1999) have been used extensively by the authors. Nevertheless, the procedures may need to be altered by investigators using this guide to collect tissue types and quantities that meet the needs of different work/study plans or protocols. Corresponding changes may also need to be made in the lists of required equipment and supplies.

1.3 Typographic Conventions

Within this document, the following typographic conventions are used:

- Important actions, notes, and reminders are indicated in **bold** or *italics*.
- Information to be recorded is also indicated in **bold**.
- The cross symbol (✚) indicates a health- or safety-related item.

1.4 Animal Welfare

The procedures described in this guide conform to the American Society of Ichthyologists and Herpetologists (ASIH), American Fisheries Society (AFS), and American Institute of Fishery Research Biologists (AIFRB) “Guidelines for Use of Fishes in Field Research” (ASIH and others, 1988); and with all known SOPs and guidelines for the humane treatment and disposal of test organisms during culture and experimentation.

2.0 ROLES AND RESPONSIBILITIES

Generally, studies based on this illustrated field guide will have field and laboratory components; we describe only the field portions. Conducting or otherwise arranging for necessary laboratory analyses is usually the responsibility of the principal investigator, project chief, or study manager. Activities and responsibilities of field cooperators and personnel include: coordinating and conducting sample collections; ensuring that personnel are trained in the operation of electrofishing, global positioning system (GPS), and photographic equipment (which are all beyond the scope of this guide); conforming to all pertinent health, safety, certification (watercraft operation, electrofishing, and so forth); collection permit requirements (both state and federal collection permits and their required reporting and pre-notification); securing prior written permission to enter private lands; ensuring that boats, motors, trailers, and other equipment are properly cleaned after sampling (to thwart the transport of living organisms between waterways); and shipping samples and records to cooperators and laboratories. Consult the work/study plan to determine the species and number of specimens required; this information is necessary under the terms of many collection permits. Walsh and Meador (1998) present additional information that may be useful in the collection of fishes.

Note: The health and safety items presented here conformed to all regulations at the time this guide was prepared. However, regulations governing the handling and shipment of chemicals and samples and the use of certain types of equipment are subject to

change. It is the responsibility of the parties using this guide to ascertain and conform to these regulations.

Note: At least one representative of each field team should have documented firsthand experience in the conduct of the procedures described in this guide.

2.1 Landowner Permission

If travel across or sampling on private property is necessary, obtain permission from the landowner or a representative of the landowner, and have them sign and date a form prepared for that station (referred to as a Station Identification Form; see Appendix A-1 for an example) to indicate landowner consent in advance of each entry.

Note: If prior written permission cannot be obtained, do not enter!

2.2 Shipment of Samples and Records

Restrictions on shipping histopathology samples will depend on the fixative used. Check with shipping companies about samples in fixative—shipping by ground transport in properly labeled boxes will likely be required. Project participants may consider using Chain-of-Custody (COC) Forms when shipping or mailing samples and data, even if it is not required. An example of a COC form can be found in Schmitt and others (1999).

2.3 Shipment of Equipment and Supplies

When sampling multiple sites with multiple teams, the use of non-expendable equipment (that is, coolers, balances, and so forth) should be coordinated among cooperators. To expedite the flow of non-expendable equipment, it is important to plan schedules as far in advance as possible. This will help to ensure that the equipment reaches each team when they need it!

2.4 Determining the Age of Fish

Information on the age of each fish is important for interpreting the results of certain anomalies. This document does not specify procedures for determining the age of specimens collected, but does provide information on structures for age determination and their collection procedures. Techniques for aging fish are described by Tesch (1971), Jearld (1983), Blouin and Hall (1990), Frie (1982), Weisburg and Frie (1987) and in most fishery biology texts (for example, Lagler 1956; Neilson and Johnson, 1983; Kocovsky, personal communication).

2.5 Photographs and Videotape

Photographs or color slides of sampling sites and operations are desirable, both for presentations and as

a record. It is also advantageous to photographically record any lesions or other anomalies identified during the fish health assessment, as noted in the instructions.

Note: It is generally better (in terms of quality and expense) to take multiple photos than to duplicate slides. Videotape is an acceptable alternative to film.

2.6 Communication

Field biologists should have access to project coordinators/study directors in the event they need assistance. Pertinent telephone (including cellular telephone), FAX numbers and email addresses should be provided.

3.0 EQUIPMENT AND SUPPLIES

The equipment and supplies needed to conduct the procedures outlined in this guide are listed in Table 1. The number needed per station or per fish is indicated unless that number must be determined from the study plan. The size of sample containers may also need to be determined from the study plan. Meador and others (1993), and Walsh and Meador (1998) present additional useful information on the collection of fish; the latter also provide a list of suppliers and vendors of equipment and supplies.

4.0 RECORD KEEPING AND HOUSEKEEPING ITEMS

Housekeeping activities that should be performed throughout the sampling day are outlined in Box 1. Quality assurance measures, including activities to ensure proper record keeping, are outlined in Box 2.

5.0 GENERAL FIELD PROCEDURES

5.1 Before Leaving on a Collecting Trip

a) If time permits, pre-label enough labels, envelopes (Figure 1), and containers for the number of specimens you will be collecting given the specifications of the study plan. **Bring extra, unlabeled supplies.**

Note: It is also advantageous to label, group, and package the expendables needed for each fish prior to arrival on site. The identification numbers may vary with study plan; consult plan before packaging.

b) Pre-fill the 125-mL bottles with about 85 mL of fixative.

Note: The volumes suggested here are for 10% neutral buffered formalin. For other preservatives, different

tissue: preservative ratios may be necessary.

+ 10% neutral-buffered formalin is the preferred fixative because it can be shipped via ground transport. The fixative; however, may vary with the project; therefore, consult the study plan. Regardless of the fixative used, it should be handled safely (that is, in accordance with the MSDS). Fill containers under a hood or outdoors, and wear protective clothing (lab coat or long sleeves and pants; latex or vinyl gloves; and safety glasses, goggles, or face shield) to prevent eye and skin contact.

+ Some preservatives and fixatives are also flammable, as are acetone and ethanol. Consult the MSDS for these materials, and avoid extreme heat and ignition sources (that is, sparks and flames).

c) Check the equipment and supplies list (Table 1) to be certain all materials and equipment are present, and check the operation of all equipment (for example, balance) to ensure that it is functioning properly.

d) All equipment should be clean when it is taken into the field. Any material that will come in contact with specimens should be cleaned with cleaning agents that will not affect later analyses.

5.2 Procedures to be Followed Upon Arrival at a Station

The preferred minimum size of a sampling team is six individuals. Once at the station, do the following before you start sampling:

Divide the team into two groups (of at least three), if possible. It is suggested that one person in the fish-processing group be designated as the recorder for the duration of the sampling at any site. Remember the person recording has a critical job to assure all portions of the examination and data form(s) (see Appendix A-1 and A-2) are completed correctly.

Group 1, which includes the trained diagnostician and the recorder (Figure 2), should:

a) Initiate the Station Identification Form (see Appendix A-1) for the day's sampling by **recording the station number, date, station description, start time, and the names of the team members.** Measure and record on the Station Identification Form

Table 1. Suggested Equipment and Supplies.

Safety and Other Apparel		
Gloves	Disposable latex or vinyl (for fish processors)	assorted sizes
	Long-sleeved or rubber (for fish collectors)	3 pr.
	Work (for general use)	3 pr.
Raingear, boots, etc.		enough for all
Safety Glasses		3 pr.
Data Collection and Recording Supplies		
Camera and film, or camcorder and tape		1
Clipboards		2
Forms	Fish Health Examination Form	1 per fish
	Station Identification Form	1 per station
Pens	Ball-point	3
	Waterproof (fine-tipped)	3
Field Guide, study plan, field notebook		1 each
Waterproof paper with pre-printed labels		
Cleaning Supplies		
Acetone (preferably reagent grade, not crude)		0.5 L, for rinsing instruments
Acetone squirt bottle w/extra 28 mm lid for shipping and transporting		1
Alcohol wipes		50, for hand cleaning
Beaker		1, 100-mL, for acetone rinse
De-ionized water		4 L, for rinsing instruments
Garden sprayer or pump spray bottle		optional, for dispensing DI water
Plastic trash bags		number varies, for waste disposal
Fish Processing Supplies		
Aluminum foil		300 ft, heavy duty
Blunt instrument		1
Optional: Anesthetic [MS-222 (Finquel [®]), CO ₂ , clove oil] depending upon protocol		
Bottles, 125-mL polyethylene w/leak-proof tops		1 per fish, for histopathology samples
Ethanol, 100%		1.5 L; 95% may be used if necessary
Fixative (10% buffered formalin)		85 mL per fish, for histopathology samples
Scale envelopes		1 per fish, for scales or spines
Small towels or cloth diapers		1 per fish
Stainless steel pan for weighing fish < 2000 g		optional
Collecting and Processing Equipment and Related Materials		
120V AC power source (>1 amp)		1 inverter, generator, or outlet (optional)
Calibration weights		1 of appropriate mass for each balance
Dissecting tools		1 kit
Electrofishing boat, backpack shocker, or electric seine and related equipment		
Ground-Fault Interrupting (GFI) extension cord		1 optional, depending on balance(s)
GPS unit		1
Hand lens		1
Hanging balance, for large fish		1
Measuring board, mm		1
Portable electric balances (preferably DC)		capacity varies with target taxa
Tubs or live boxes		total no. varies with study plan and when boat has no livewell

Table 1. Suggested Equipment and Supplies--Continued.

Fish and Tissue Packaging	
Coolers	large (total no. varies with study plan, for cooling fish composite samples, etc.)
Cloth tags	1 per fish
Ice (wet, cubes or block)	50 lb
Mailing labels for samples	1 sheet
Shipping labels for samples	total no. varies with study plan
Miscellaneous Equipment and Supplies	
Cell phone	optional but recommended
Conductivity meter	for electrofishing
Duct tape	1 roll, for securing sharps containers, etc.
Field guide(s) or other reference(s) for identifying fish	
Fire extinguisher (dry chemical, type A, B, and C)	1
First-aid kit	1
Flashlights and other lights	optional
Kitchen (poultry) shears or scissors	1 pr.
Material Safety Data Sheets for all chemicals (fixative, acetone, ethanol, etc.)	1 each
Paper towels	1-2 rolls
Pliers	1 pr.
Portable table and chairs	optional
Shade canopy	optional
Thermometer or other instrument for measuring water temperature	1

the water temperature (°C) in the general area from which fish were collected.

b) If AC-powered equipment is to be used, provide 120-V AC, 60-cycle power for the electronic balance [that is, inverter and 12-V DC boat, vehicle, or trolling motor (1 amp minimum) battery; portable generator; electrofishing boat; or a grounded 120-V AC outlet] (Figures 3a–3c) or use a battery operated portable balance.

Portable work surfaces (for example, folding table, tailgate, cooler top) or indoor work areas should be set up to facilitate a dry, comfortable work area (Figures 3a–3c).

- + Important! The use of 120-V AC electrical power outdoors, especially around water, is potentially hazardous. The grounding requirements of portable power devices (that is, generators and inverters) vary; read and follow the instructions supplied with whatever device you use. Many portable generators are now equipped with ground-fault interrupting (GFI) outlets; if yours is so equipped, use**

them. If it is not, use an extension cord equipped with a GFI. In addition, use this type of extension cord whenever working with electrical power in the field.

- + The use of portable, engine-powered generators presents additional safety hazards - fire, burns, and fumes. Carry fuel only in approved containers, and allow the generator to cool before re-fueling to minimize fire hazards. In addition, an approved spark-arresting muffler may be required in some locales. To avoid fume hazards, do not use portable generators in buildings, vehicles, or other enclosed places.**

d) Set up and level the balances.

Note: Setting the balances up inside an empty cooler on a level spot works well. If it is windy or raining, close the lid between operations.

e) Power up the balance(s) and ascertain that it (they) is (are) operating properly by weighing the

Box 1. Suggested Housekeeping Activities, to be Performed as Needed.

- Cap the acetone squirt bottle and the marking pens when they are not in use.
- After each fish is processed, thoroughly wash all contact instruments and dissecting tools with de-ionized water and rinse them with acetone.

Box 2. Suggested Quality Assurance and Record Keeping Activities.

- Keep a logbook of the team's activities (when the team left, who was present and what each person did, etc.)
 - Make all entries in INK. Use a ballpoint pen that will write under all conditions on data-entry and other forms. FORMS SHOULD BE PRINTED ON WATERPROOF PAPER.
 - PRINT legibly.
 - Do not use ditto marks (“”) for observations that repeat on a series of lines. Instead, write the entry on the first and last applicable lines, and connect the observations with a single vertical line.
 - If you do not obtain a measurement (equipment broken, etc.), write an explanation in the comment field on the data sheet.
 - If you make a mistake, draw a SINGLE line through the incorrect entry (e.g. ~~CARP~~), and initial and date the correction. Then, indicate the nature of the error in the appropriate comment field on the data sheet.
 - Number sampling sites in accordance with the study plan under which an investigation is conducted. Each sampling site should have a unique identifier. Initiate a new Station Identification Sheet for each day that you sample at a site.
 - Number fish collected at a sampling site as instructed by the study plan. If no numbering system is detailed, fish should be numbered with a **unique** identifier (referred to as the fish identification number) that indicates the ID of the individual specimen, the sampling site from which it was collected, and the date of the collection. That same number will be used on all envelopes and containers used for that fish.
 - Initiate a new Fish Health Examination Form (see Appendix A-2 for an example) for each specimen. Record the species, sex, length, weight, results of the field health assessment procedures, numbers of tissue collected, and any further remarks or comments pertaining to that individual fish.
 - To eliminate possible bias in subsequent analyses, all samples bear the fish identification numbers, but no other markings.
 - If you photograph (or videotape) any anomalies (i.e. raised growths, lesions, parasites, etc.), use a previously prepared tag or scale envelope as a specimen identifier in each frame. There are spaces for recording the number of photos taken or the video footage shot in each section of the Fish Health Examination Form; filling them in will make it easier to annotate slides or tape later. It is easier for the recorder if you follow the order of the Fish Health Examination Form, which follows the order of this document.
- Note: If specimens that are designated as juvenile or indeterminate are collected, and gender identification will be made histologically at a later date, group and bag these specimens separately.*
- **Check and initial each Fish Health Examination Form to be certain that all observations have been made and recorded before proceeding to the next fish. Do not leave any blank fields on the data sheets unless specified by the study plan.**

appropriate calibration mass. **Record the make, model, and ID or serial number of the balance(s) and the “before” calibration weight(s)** on the Station Identification Form (Appendix A-1).

All weights should be recorded in grams and the recorder should confirm that the balance is in the correct mode at all times. Also, personnel working with the balances should ensure that any weigh boats or other equipment being used to hold fish are resting completely and solely on the weighing platform of the balance. Check the zero of the hanging balance, and

adjust if necessary using the thumb screw at the top of the cylinder.

f) Unpack the expendables (bags, tags, labels, and so forth; Figure 4), and label the containers (if not done already).

g) Fill a container (tub, bucket, cooler) with ambient water and pre-soak the diapers or towels to be used to handle the fish (to remove any detergents or other chemicals).




Figure 1. Tag and scale envelope labeled with a unique fish ID number.

- +** For protection against pathogens and parasites associated with either the fish or water, team members handling the fish and collecting tissues should wear disposable latex or vinyl gloves. The gloves should be replaced as necessary if they become torn or punctured, and disposed of properly. Hands should be washed with disposable alcohol wipes. In waters known or suspected to harbor *Pfiesteria* sp. or other pathogens, fish collectors and handlers should take extra precautions by wearing long gloves or sleeve protectors.



Figure 2. Diagnostician and recorder conducting a fish health assessment.



Figure 3a. An outdoor work area and equipment setup.



Figure 3b. An indoor work area and equipment setup.

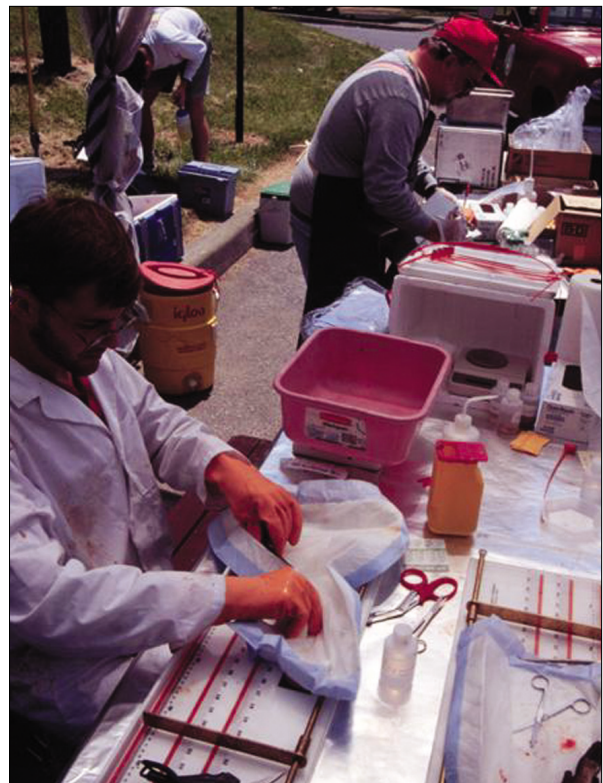

Figure 3c. An outdoor work area and equipment setup, with biologists processing fish.

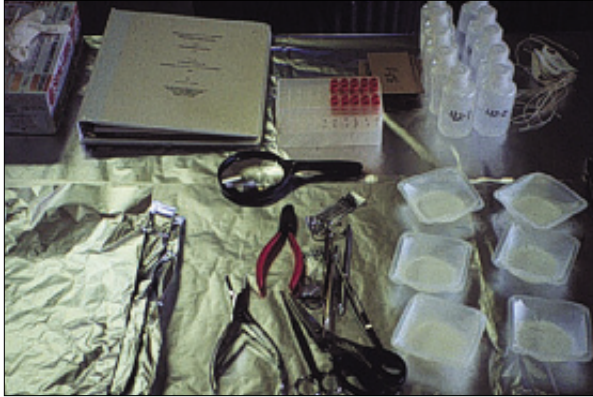

Figure 4. Layout of equipment and supplies.

Group 2 (fish collectors) should:

Obtain the Station Identification Form (Appendix A-1) and **record settings for the electrofishing equipment (in the General Comments) and location coordinates**. Then, initiate sampling (Figure 5). **Record the range of latitude and longitude sampled in degrees (000°) and decimal minutes (00.0000), the map datum (WGS84, NAD83, and so forth) and the stop time** when finished.

5.3 Collecting and Holding Fish

The target taxa and desired number of specimens should be found in the study plan for the specific project. The collection of larger, adult fish is encouraged because; 1) obtaining the necessary amounts of tissues for histopathology may be difficult with smaller fish; 2) the observations may be difficult to perform with small fish; and 3) older fish are exposed for longer periods of time and anomalies are more prevalent. The preferred collection methods are DC electrofishing (Figure 5), seining, or DC electric seining (the methods of capture that are least injurious to the fish); however, be certain that nets have not been chemically treated or used previously in heavily contaminated waters. Hook-and-line capture is also permissible. Trap-, gill-, or trammel-netting, and AC electrofishing



Figure 5. Biologists collecting fish using an electrofishing boat.

are not recommended because these methods are more injurious to the fish and can bias the quantitative health assessments. To complete the procedures described, **fish should be held alive**.

Note: Holding fish for prolonged periods in tanks or live wells with abrasive surfaces or in net pens can cause external lesions.

6.0 PROCESSING FISH

The actual processing of the fish begins here. The order in which the procedures are performed is important to ensure that activities conducted in one step do not compromise observations or tissues obtained in subsequent steps and that tissues with short holding times are collected as rapidly as possible. Consequently, the procedures that are described in the following sections and diagrammed in the accompanying flow chart should be performed in the order in which they are presented, which also conforms to the organization of the Fish Health Examination form upon which the observations are recorded.

6.1 Fish Processing (Flow Chart)

+ This is a reminder that personnel handling and dissecting the fish should wear gloves.

a) Prepare the work surface by covering it with a piece of foil (dull side up/shiny side down) large enough to wrap the fish you will be processing.

b) Secure a towel or diaper (from the soaking container) or use a disposable pad. Wring it dry, then tare it on the large balance. It may be useful to perform the necropsy using a diaper or pad to absorb fluids released from fish.

c) Secure a fish from the holding tank. Ascertain its condition and identify it to species. **Make a reasonably positive identification at this time**, using a guide to species names and abbreviations. Initiate a Fish Health Examination Form (Appendix A-2) for the fish by assigning the fish a unique ID number or use the pre-labeled number. **Record the Station ID number, date, fish ID number, and species** on the Fish Health Examination Form (Appendix A-2). If you are not sure of the fish species identification, note on the data form that you will confirm it at a later time.

Note: For fish nomenclature see Robins and others (1991).

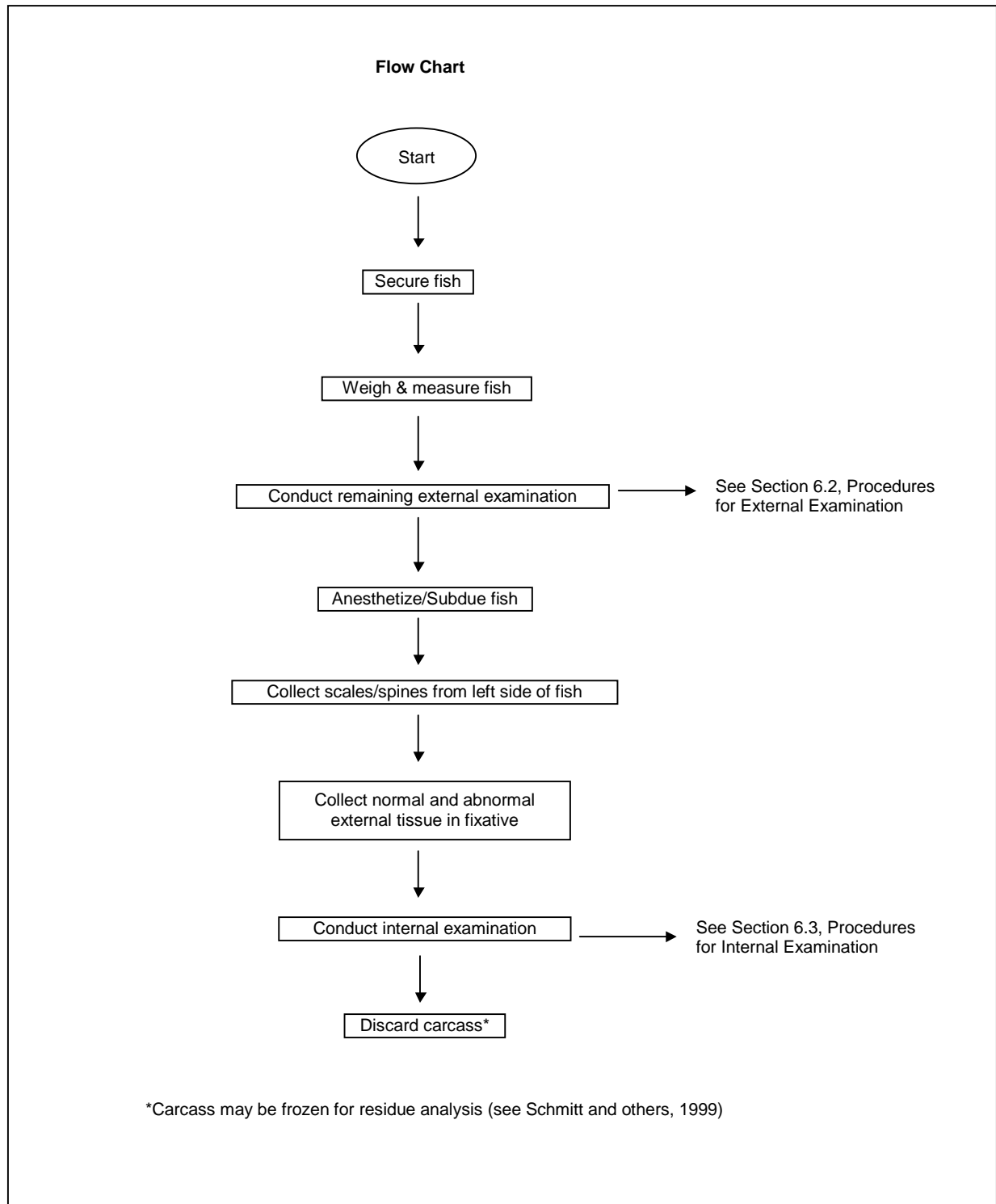
d) Place the fish, in its towel, on the previously tared electronic balance. If the fish is too heavy for the balance, unwrap it and weigh it on the hanging balance. A tared holding container (such as a stainless steel, plastic, or aluminum pan) can be used to weigh fish <2000 g on the larger capacity electronic balances.

e) Record the weight of the fish (± 1 g) **on the Fish**

Health Examination Form.

Note: Check the zero and the operational mode of the balance between each fish, and re-adjust or tare as necessary.

f) Unwrap the fish and measure it on the measuring board (total length, in millimeters; squeeze the caudal



fins together – Figures 6a and 6b).

g) **Record the total length (mm)** on the Fish Health Examination Form (See Figure 6a).

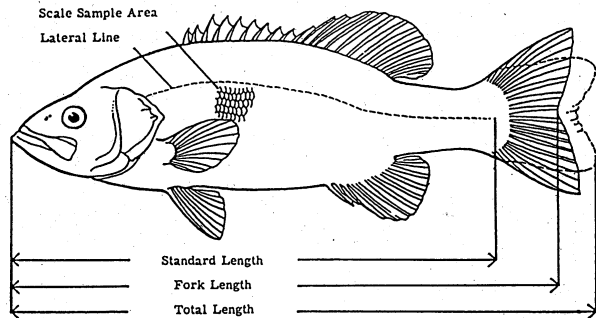
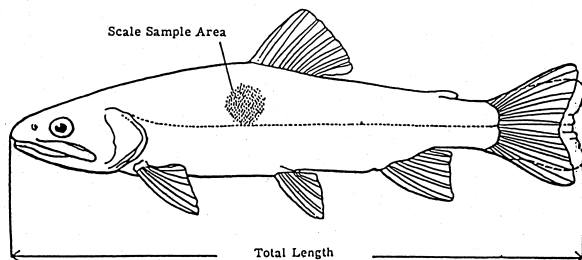


Figure 6a. Length measurements and scale sampling areas for spiny-rayed fish. From Lagler, *Freshwater Fishery Biology*, (1956) Wm. C. Brown Publishers, used with permission from the McGraw-Hill Companies.

h) Conduct the external examination of the head surface and the eyes at this time (per instructions under Section 6.2). **DO NOT remove anomalies** at this time - the fish has not been subdued.

i) To subdue fish, expose the anterior dorsal surface of the specimen and, with a blunt instrument, subdue the fish with a sharp blow to the rear of its head. Alternatively, and although these procedures are not described here, the fish may be anesthetized with tricaine methanesulfonate (MS-222; Fiquel[®]), carbon dioxide, or clove oil at recommended concentrations depending upon study plan or protocol.

j) If you have not already done so, **label a tag and a scale envelope (fish identification number;** Figure 1); use a permanent, waterproof felt-tipped pen and write in large, block letters. Use this label in any photographs or video footage taken.



Length measurements and scale sampling areas for
From Lagler (1956).

6.2 Procedures for External Examination

Begin the external observation (Figure 7) using photos and Fish Health External Examination Form (Appendix A-2). Within each section, be sure to **record all observations by marking (X) in all boxes on the data form that apply**. Recorded examinations of eyes, opercula, gills, and fins (if necessary, refer to the diagram of the external features of a fish located in Appendix B-1) may include marking both “normal” and deteriorated conditions since more than one structure is involved.

Note: Aesthetic observations are unnecessary.

Make a clear, precise mark for each data entry for the external examination. **Provide a brief description of the anomaly (that is, size, color, and so forth) in the spaces located in each section.** If the observation does not seem to fit any of the listed categories, **check “other” and describe your observations** in the indicated areas. **Record further remarks about listed categories** in the General Comments section. The general procedure during the external examination is to record all observations that apply, and to collect and preserve a sample of anything that appears abnormal. If an abnormal sample is collected, it is very helpful to the histopathologist to also collect and preserve some normal tissue of the same type. To

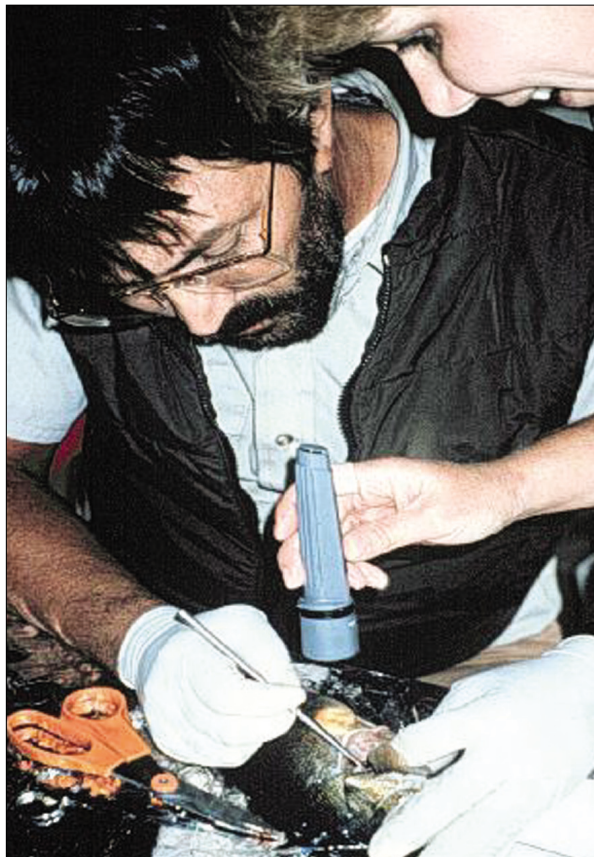

Figure 7. Biologists examining the external features of the fish.

ensure proper preservation, no piece of preserved tissue should be larger than 1-cm³; cut larger pieces to this size if necessary.

Note: This line is 1 cm long. _____

6.2.1 BODY SURFACE: Examine all surfaces for any anomalies (Figures 8–18). Remove them and place them in the labeled bottle of fixative. **Record anomaly type(s)** found by checking the appropriate blocks. **Describe any anomalies noted as “other”.** **Note the general location of all anomaly type(s) in the “other” field and record the number of pieces in fixative.**

Normal (Figure 8): No aberrations present on the body surface.



Figure 8. Normal body surface.

Raised growth (Figures 9a and 9b): On body surface; may be tumor but must be verified histopathologically.




Figure 9a. Raised growths present on body surface.



Figure 9b. Raised growths on body surface.

Reddened lesions (Figures 10a and 10b): Ulcers, abrasions, cuts, sores, and so forth.

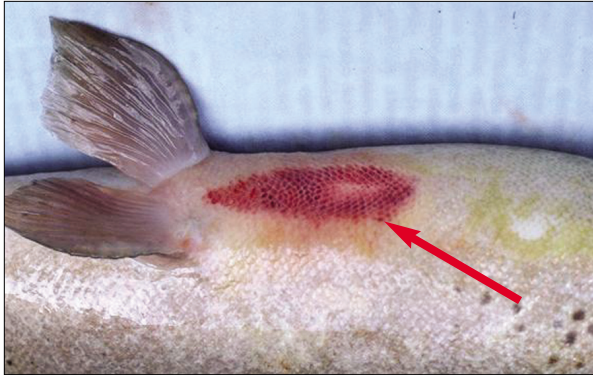

Figure 10a. Body surface lesion.

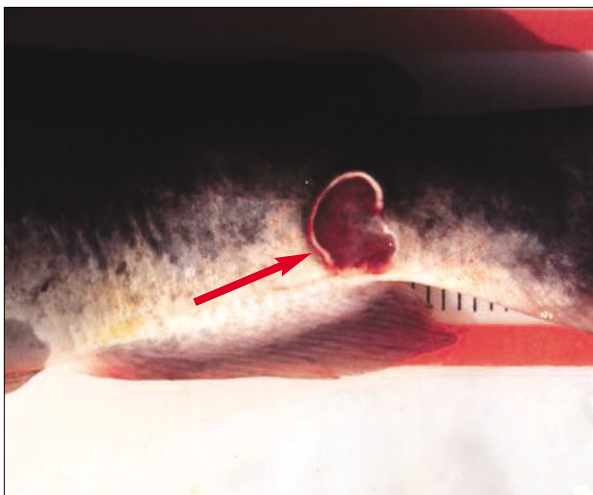


Figure 10b. Body surface lesion (ulcer).

Spinal Deformities (Figures 11a and 11b): Abnormal shape of the spine, backbone is not straight.



Figure 11a. Example of normal spine versus deformed.



Figure 11b. Examples of spine deformities.

Hemorrhagic Body (Figures 12a and 12b): Reddened (that is, bloody) area visible on the body surface.



Figure 12a. An example of hemorrhagic body observation.




Figure 12b. Hemorrhaging within the body surface.

Focal Discoloration (Figure 13): Abnormally darkened areas (dark spots, possible melanoma) present on the body surface.



Figure 13. Example of the presence of abnormal dark spots on the body surface.

Body Fungus (Figures 14a and 14b): Fungal growth on various parts of the body surface.



Figure 14a. Example of the appearance of body fungus.




Figure 14b. Body Fungus.

Parasites: The presence of white spots, leeches, black spots, or worms:

White Spots (Figure 15): Small white, raised areas on the fins and body surface, often protozoan parasites.



Figure 15. White spots on body surface.

Leeches (Figure 16): Visibly attached to body surface.




Figure 16. Leech attached to the dorsal fin.

Black spots (Figure 17): Small black spots distributed throughout the body surface.




Figure 17. Black spots.

Anchor Worm (Figure 18): Copepod



Figure 18. Anchor worm.

Other: Any observation that does not fit in the above; describe in spaces provided. **Record the condition of the Body Surface and the number of pieces in fixative.**

6.2.2 HEAD AND ORAL CAVITY: Anomalies associated with the anterior region of the fish including the head and oral cavity (lips), and barbels (Figures 19a–23c). Check all that apply:

Deformed Head (Figures 19a and 19b): Abnormal shape of the anterior portion of the fish (do not mistaken these malformations with those that may have been caused if the specimen was subdued with a blunt instrument).

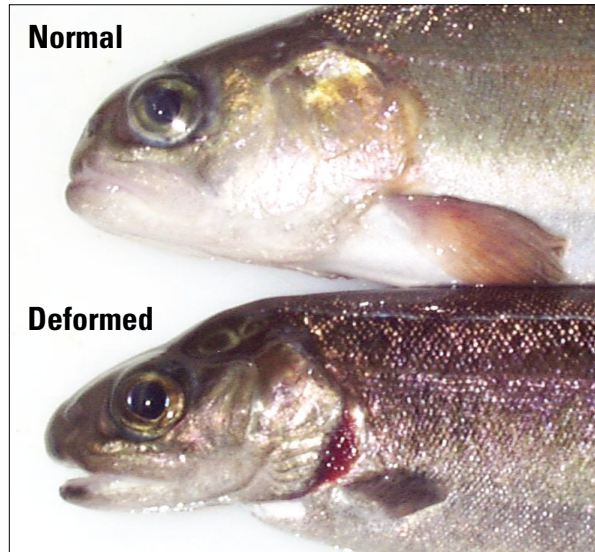


Figure 19a. Example of normal versus deformed head in rainbow trout (*Oncorhynchus mykiss*).



Figure 19b. Deformed head.

Upper and Lower Lip Growths (Figures 20a–20c): Raised growth on lateral or dorsal region of the lip or oral cavity (possible papilloma).



Figure 20a. Lower lip growth.

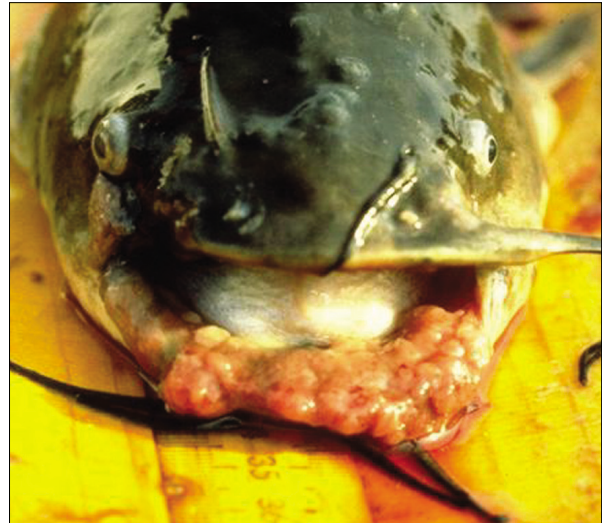

Figure 20b. Lower lip growth.



Figure 20c. Upper and lower lip growth.

Swollen Nare (Figure 21): Nostril with swelling or abnormal enlargement of the opening.



Figure 21. Swollen nare.

Stubbed Barbels: Barbels are clubbed, stubbed or shortened.

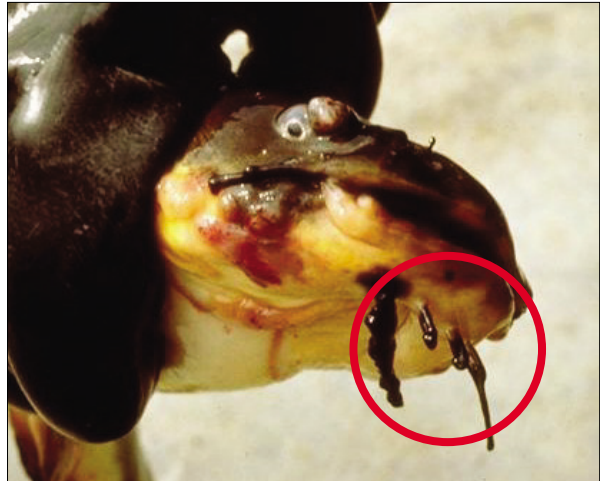

Figure 22b. Stubbed barbels.

Barbels (Figures 20a–20c):

Missing Barbels: Any number of barbels not present.

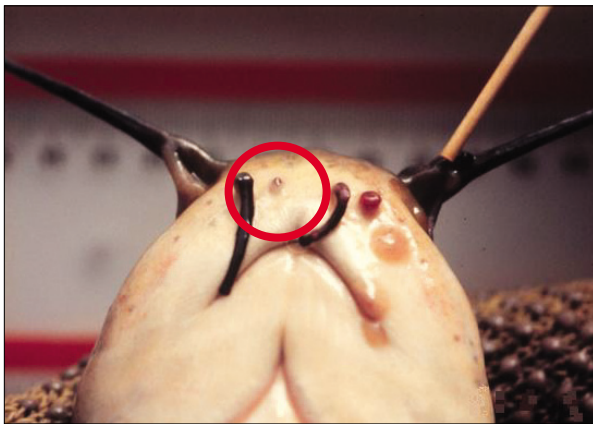


Figure 22a. Missing barbels.

Deformed Barbels: Growth of abnormally shaped barbels, possibly being forked or fused.

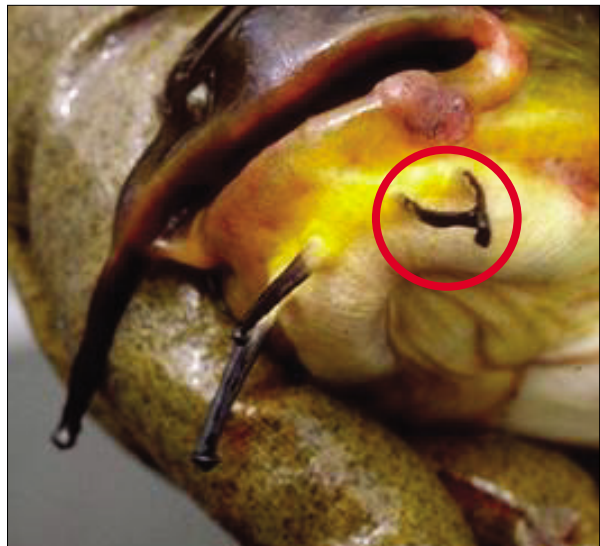


Figure 22c. Deformed barbels and lower lip growth.

Other (Figures 23a–23c): Abnormalities that do not fit any of the previous categories, that is, lesions, parasites, and so forth. Describe. **Record the condition of the Head/Oral Cavity and the number of pieces in fixative.**

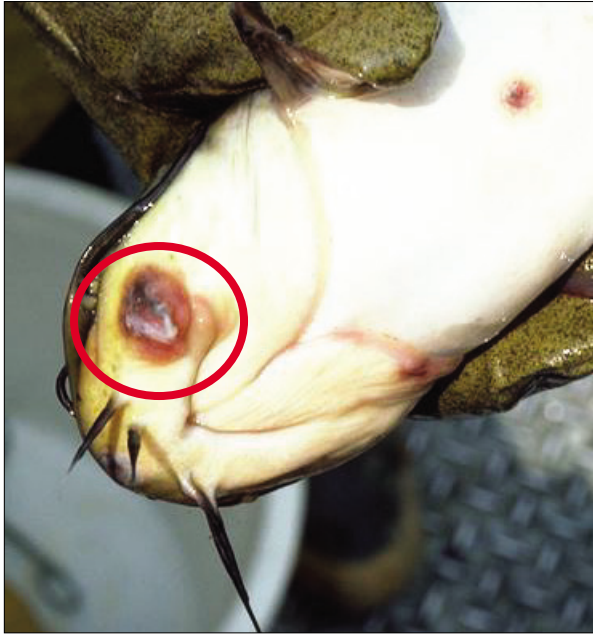

Figure 23a. Head lesion.

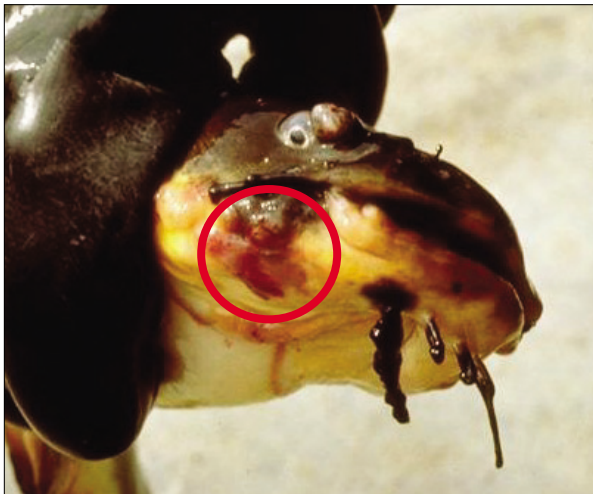

Figure 23b. Head lesion.

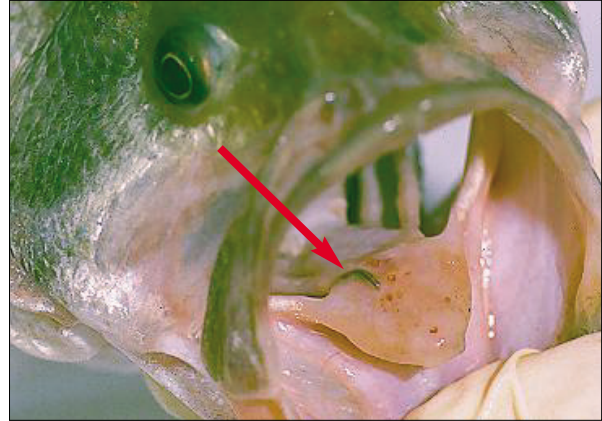


Figure 23c. Leech attached to the oral cavity.

6.2.3 EYES: The left and right eyes should be examined (Figures 24–29b) and scored separately, as follows (check all that apply):

Normal (Figure 24): No aberrations evident; eyes “clear”, not protruding, milky, opaque, or bloody.



Figure 24. Example of a normal eye.

Exophthalmia (Figures 25a and 25b): Swollen, protruding eye (also known as popeye).




Figure 25a. Example of exophthalmia; eye is protruding (otherwise known as popeye).



Figure 25b. An example of exophthalmia. Also an example of emboli (see Figure 29b).

Opaque (Figures 26a and 26b): Generally refers to opaque or cloudy eyes, or the appearance of cataracts. The nature of the opacity is not important here.



Figure 26a. Opaque or cloudy eye.

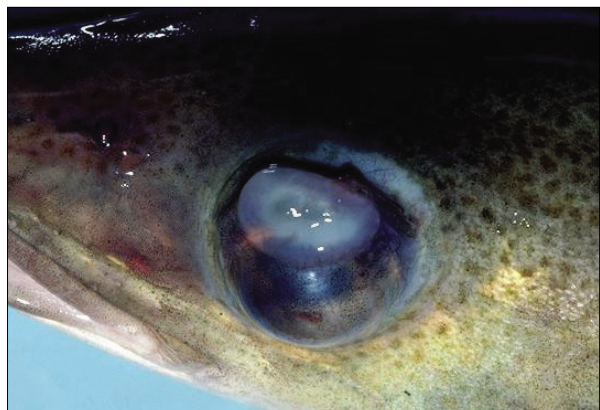

Figure 26b. Opaque eye.

Missing (Figures 27a and 27b): An eye appears to be missing from the fish. (*Note: It may be actually scarred over*).



Figure 27a. Missing eye.




Figure 27b. Missing eye.

Hemorrhagic eye (Figure 28): Characterized by the presence of blood in the eye(s).

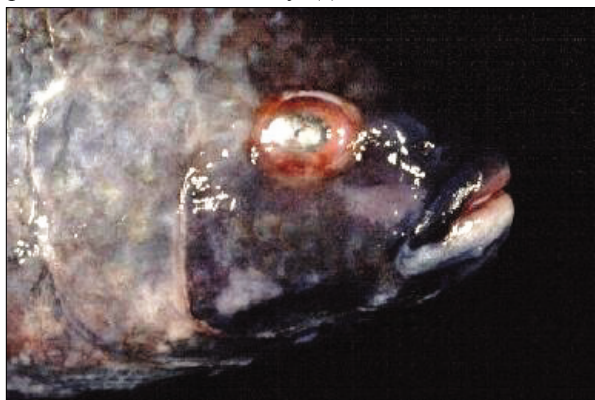


Figure 28. Hemorrhagic eye.

Emboli (Figures 29a and 29b): Gas bubbles visible within the eye.



Figure 29a. Emboli; visible gas bubbles within the eye.

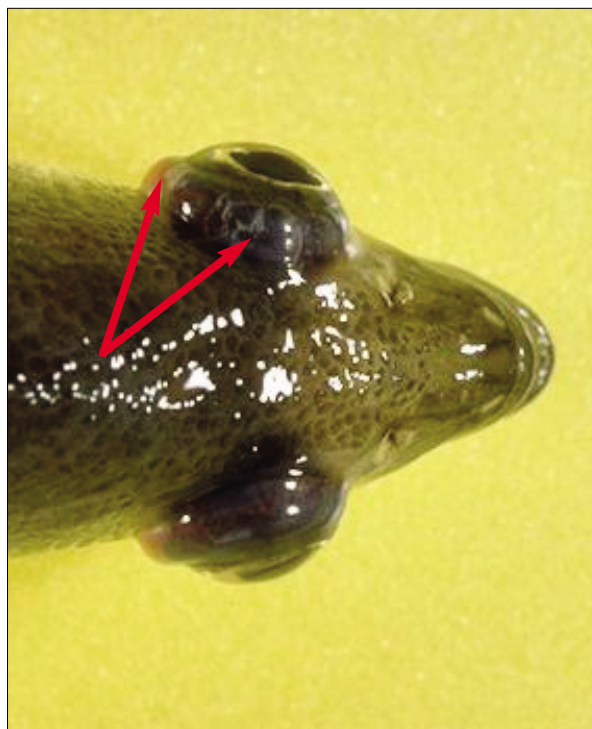


Figure 29b. Emboli, or gas bubbles present in the upper most (left) eye. This is also an example of popeye, both conditions should be marked on the Fish Health Examination Form.

Other: Any manifestations that do not “fit” the above (that is, parasites, spots, cuts, abrasions); describe.

Record the condition and number of pieces in fixative for each eye on the Fish Health Examination Form.

6.2.4 OPERCULA: It is necessary to only observe the degree of shortening of the opercular flaps (Figures 30a–33). Score the opercula according to the following criteria (check all that apply):

Normal (Figure 30a and 30b): No shortening of the opercular flaps; gills are completely covered.

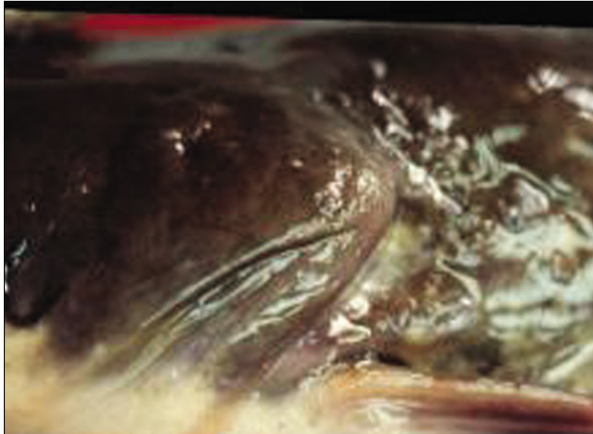


Figure 30a. Normal operculum.

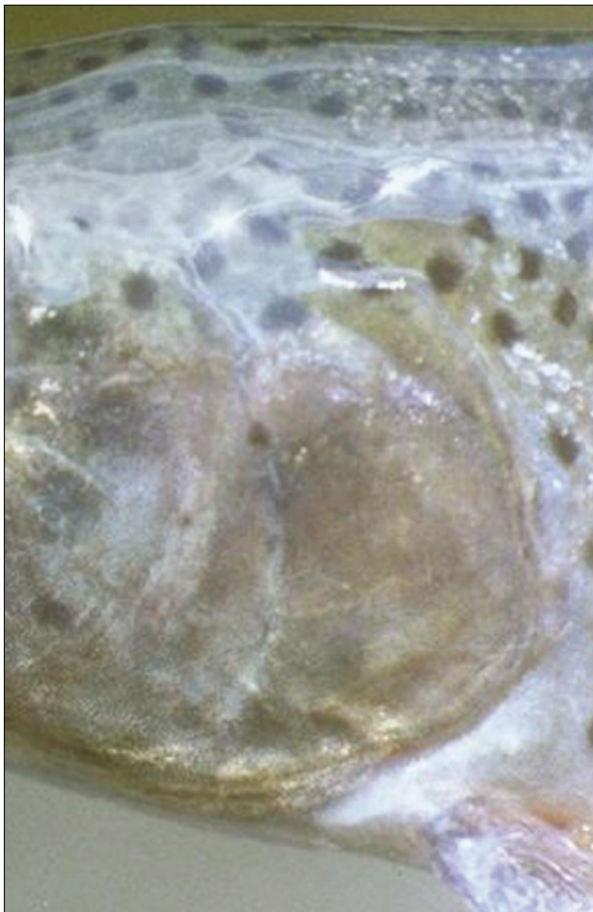


Figure 30b. Normal operculum.

Slight shortening (Figure 31): Slight shortening of the operculum with a very small portion of the gill exposed.



Figure 31. Slight shortening of the opercular flap.

Severe Shortening (Figure 32): Severe shortening of the opercula with a considerable portion of the gill exposed.

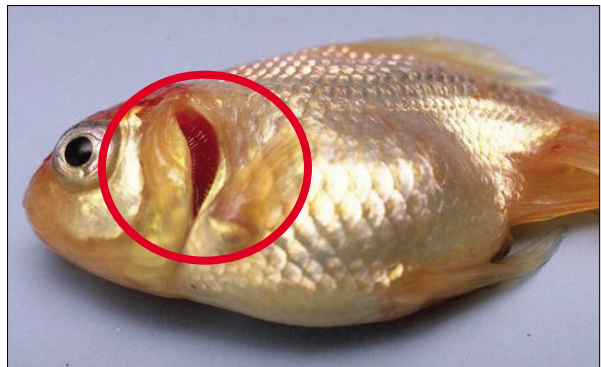


Figure 32. Example of severely shortened opercula, gills are clearly exposed.

Other (Figure 33): Any observation that does not fit above; describe. **Record the condition of the opercula and the number of pieces in fixative.**




Figure 33. Curled opercular flap, categorized as "other".

6.2.5 GILLS: The right and left gills are examined and evaluated separately (Figures 34–37b). Be careful when examining the gills. Gill structure and tissue can easily be affected by the manner in which the fish is handled during and after collection. Evaluate the gills as follows (check all that apply):

Normal (Figure 34): No apparent aberrations.

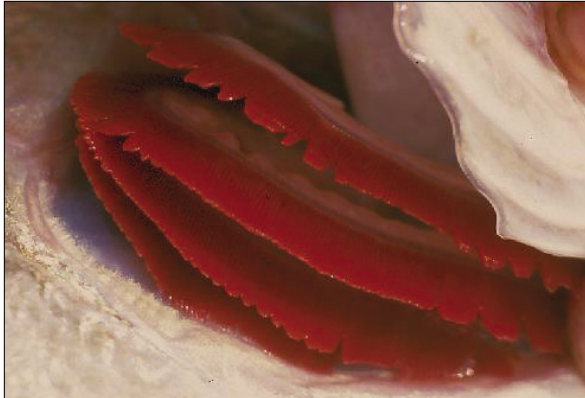

Figure 34. Normal gill; bright red with no apparent aberrations.

Frayed: This generally refers to actual erosion of the tips of the gill lamellae resulting in “ragged” appearing gills (Figure 35). Mere separation of gill lamellae can be interpreted as “frayed” but the condition may have caused by something as simple as the manner in which the gill was exposed by the investigator.

Marginate (Figure 35): A graphic description of a gill with a light discolored margin along the distal end or tips of the lamellae or filaments.

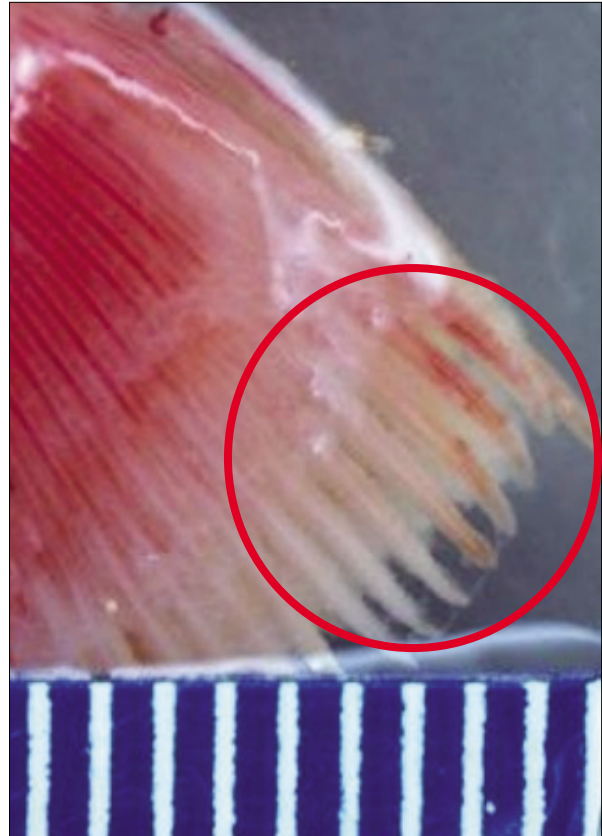

Figure 35. Marginate and frayed gill: discolored margin with ragged gill lamellae.

Pale (Figure 36): This refers to gills that are very light in color. Extreme anemia can discolor the gills to the point of being white. Severe bleeding can also result in somewhat pale gills. Gills begin to pale after death, which is common in fish taken from nets. All of this should be considered in making the observation.

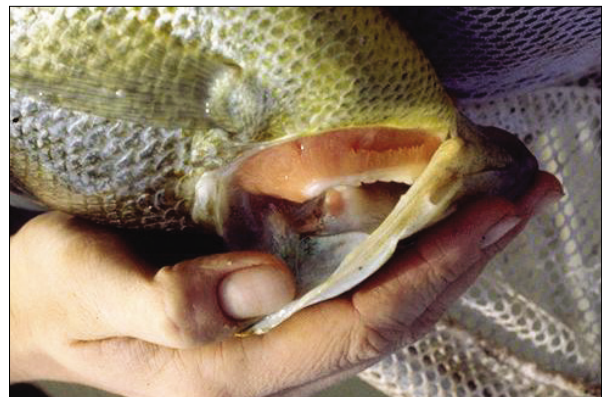

Figure 36. Example of pale gills.

Other (Figures 37a and 37b): Any observation that does not fit the above (that is, parasites, abnormal discoloration, and so forth); describe. **Record the condition and number of pieces in fixative for each gill.**

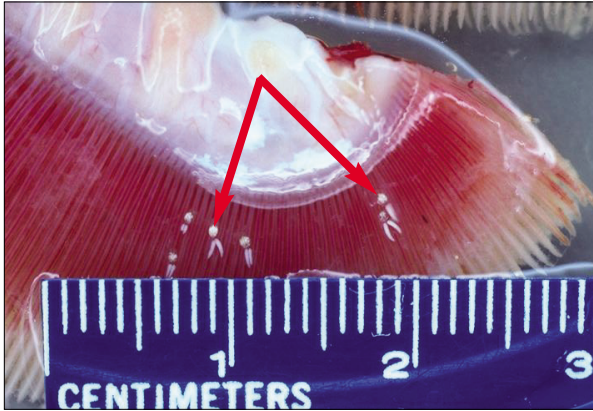


Figure 37a. Other (parasites); obvious parasites on the gills.

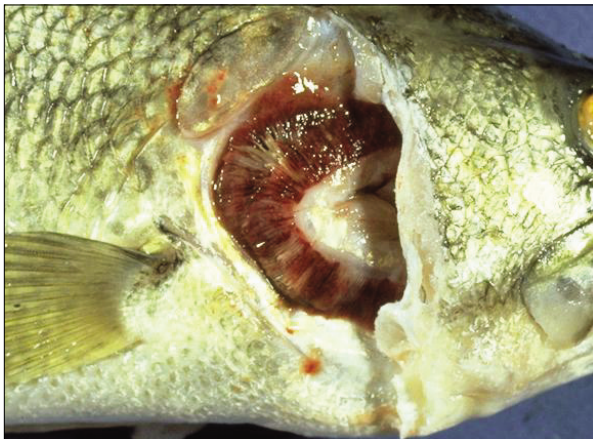

Figure 37b. Other; abnormal discoloration (mottled appearance) of the gills.

6.2.6 FINS: Eroded or “ragged” fins are a departure from normal condition and health. Previously eroded fins that are healed over and show no evidence of active erosion are considered normal in this assessment. The evaluation of fins is relative to the degree of active erosion in evidence. Fins are observed collectively. If only one fin is actively eroding or has other abnormalities, **record the observation and fin location**. If several fins are eroding with unequal severity, **check all that apply and note in the fin comments** which fins are abnormal (Figures 38–44b).

Note: Erosion usually involves both the fin membrane and rays, whereas fraying involves only the membrane.

Normal (Figure 38): No active erosion, fraying, or hemorrhage. This includes previously eroded fins that are completely healed over.



Figure 38. Normal fins, no abnormalities present such as fraying, erosion, or hemorrhaging.

Mild Erosion (Figures 39a and 39b): Active erosion but no evidence of hemorrhage or secondary infection.

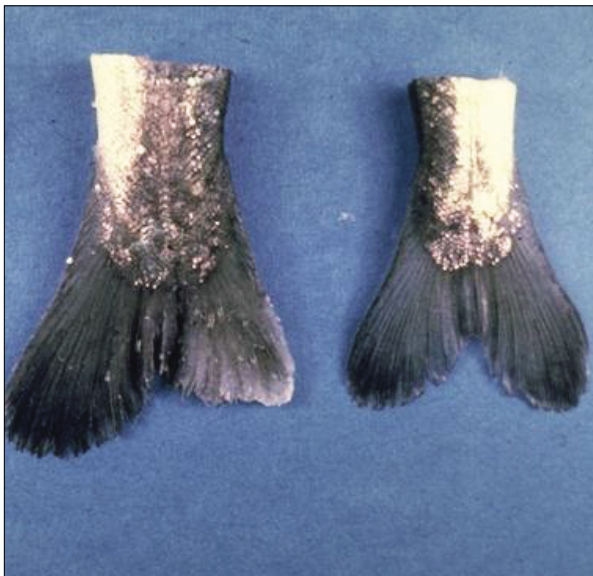

Figure 39a. Caudal fins displaying active mild erosion.




Figure 39b. Active fin erosion.

Severe Erosion (Figures 40a and 40b): Active erosion with hemorrhage and/or evidence of secondary erosion.

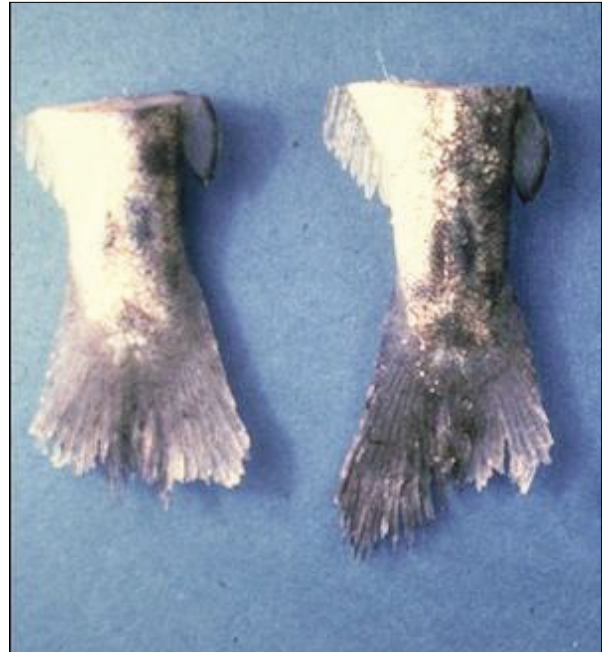

Figure 40a. Fins with severe erosion.

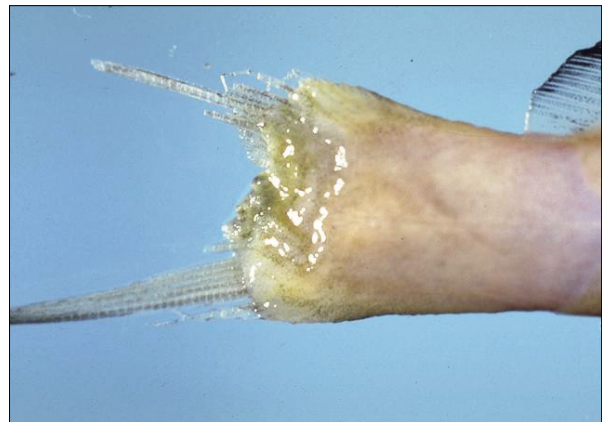


Figure 40b. Severe erosion of the caudal fin with a possible secondary infection.

Frayed (Figure 41): Margins of fins ragged or torn.



Figure 41. Caudal fin with frayed or ragged edges.

Hemorrhagic (Figures 42a and 42b): Reddened (that is, bloody) area visible within the intact fin.



Figure 42a. Fins with reddened or hemorrhagic areas.




Figure 42b. Hemorrhagic and frayed fins.

Emboli (Figure 43): Gas bubbles visible within the fin.

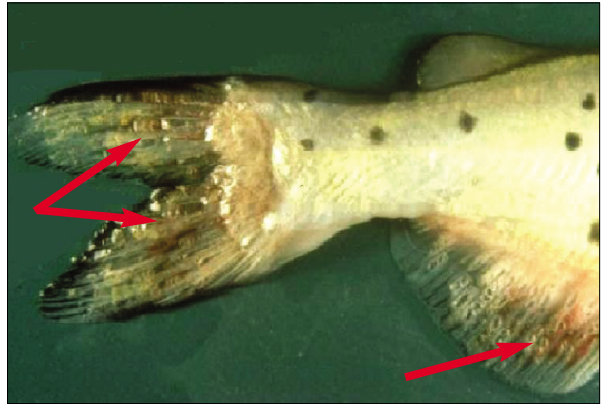


Figure 43. Visible gas bubbles (emboli) within the fins.

Other (Figures 44a and 44b): Any observation that does not fit above (that is, parasites, lesions, and so forth); describe.

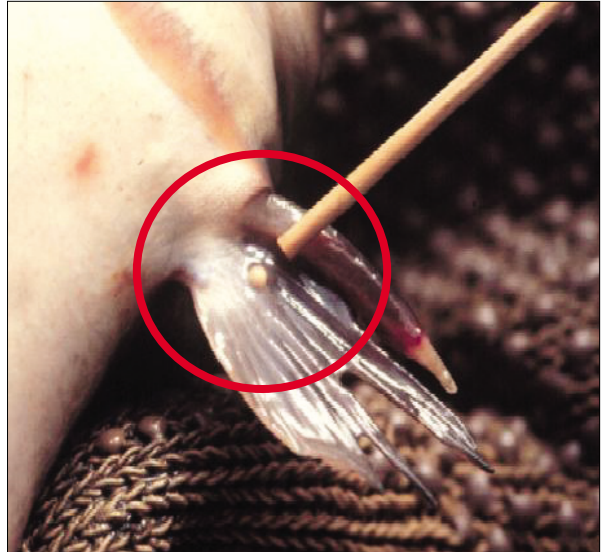


Figure 44a. Fin containing a nodule, categorized as "other".

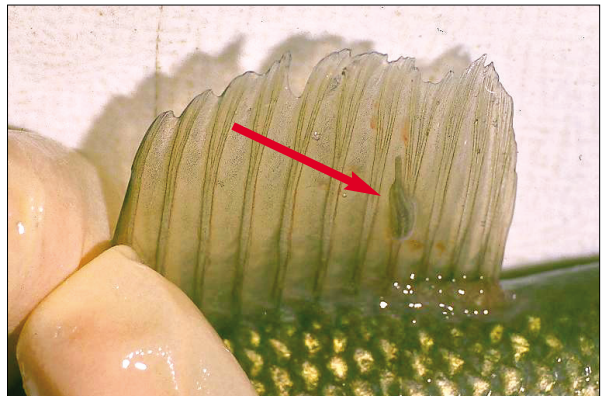


Figure 44b. Dorsal fin with leech, categorized as "other".

Record the condition or conditions that apply if one or more fins are affected. **Note the location of any condition** in the General Comments and the **number of pieces in fixative**.

6.3 PROCEDURES FOR INTERNAL EXAMINATION

Lay the subdued fish on the foil and open the abdominal cavity with a cut from the vent forward to the pectoral girdle; cut through or closely to one side of the pelvic girdle. Do **NOT** insert the scissors so far that the internal organs are damaged.

Reach into the anterior end of the abdominal cavity with one gloved finger and find the esophagus. Cut the esophagus with the scissors, and remove the entire viscera except for the kidneys, which will remain in the carcass (Figure 45). Use only gloved fingers and a blunt probe to free the internal organs from the carcass. Put the carcass aside (on the foil) while working with the excised internal organs (if necessary, refer to the diagrams of the internal features of spiny-rayed or soft-rayed fish located in Appendices B-2 and B-3).



Figure 45. Viscera removed from the fish for the purpose of conducting the internal examination.

6.3.1 LIVER, GALL BLADDER, AND BILE:

Although treated separately here and on the Fish Health Examination Form (Appendix A-2), the liver, gall bladder, and bile are examined and sampled together. If obtaining organ weight is part of the study plan, **record the liver weight (± 0.1 g or less)** on the Fish Health Examination Form.

6.3.1.1 LIVER: The appearance of the liver may be an artifact of the sampling; the observer should take that into consideration. Note that the appearance of the intact liver and gall bladder may, for example, vary with the length of time from collection to observation. It also depends on the extent of blood loss during sampling. Check all that apply (Figures 46–50b).

Normal Liver; Dark- to light-red color (Figure 46): Dark red is the normal color. However, the liver is a blood storage organ, and it may be a lighter red color after bleeding, but not so pale as to be classified as general discoloration or as tan. Color may also vary among species and taxa.



Figure 46. Normal liver, dark red in color.

Tan or “coffee with cream color” liver (Figure 47): Fatty liver; (that is, more or less uniformly light tan color).

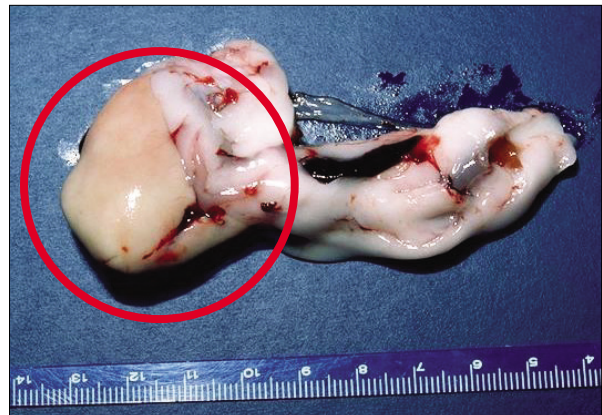


Figure 47. A tan, or “coffee with cream” color liver.

General discoloration (Figures 48a and 48b): Uniform color other than the above (gray is common); describe.

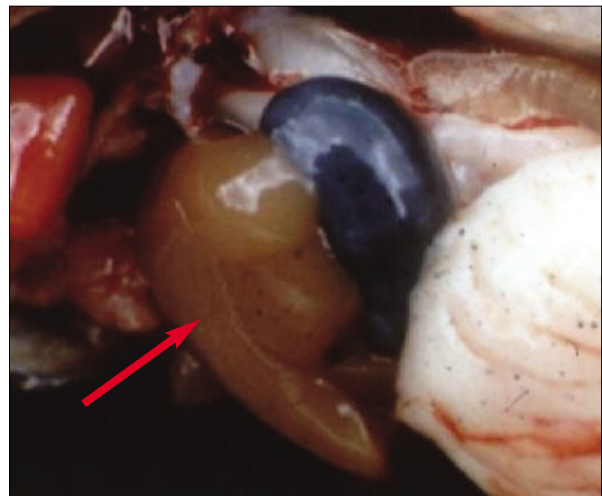


Figure 48a. Liver with general discoloration.

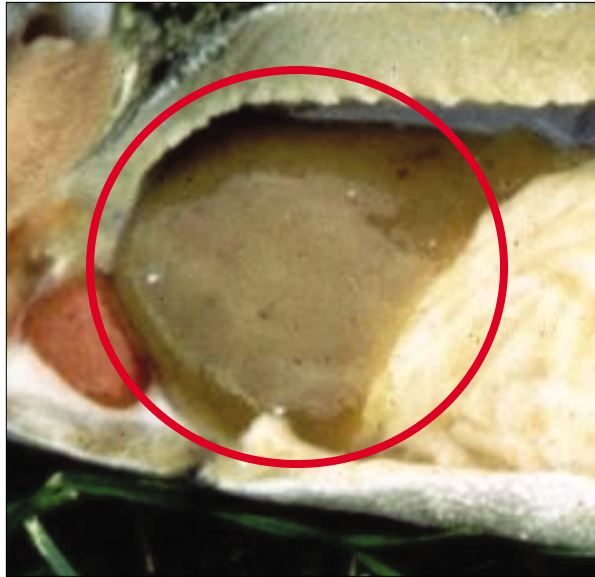

Figure 48b. Generally discolored liver.

Focal discoloration (Figure 49): Color change in part of the liver, giving it a mottled appearance; describe.

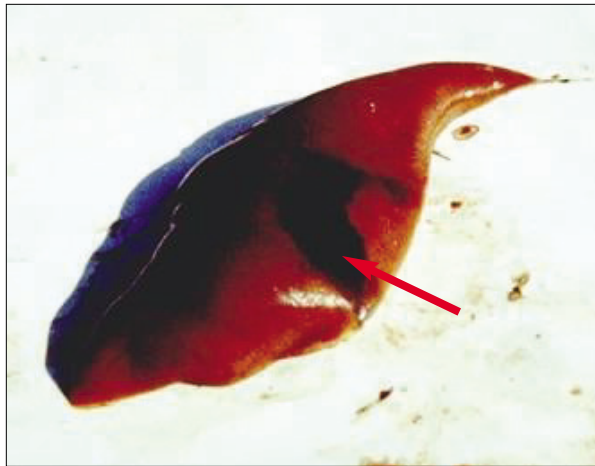


Figure 49. Liver with focal discoloration.

Nodules in liver (Figures 50a and 50b): Nodules (that is, white parasitic cysts or bacterial granulomas) and incipient nodules, such as those in hepatoma (dark blotches) or cholangioma (“popcorn” look); swollen areas.

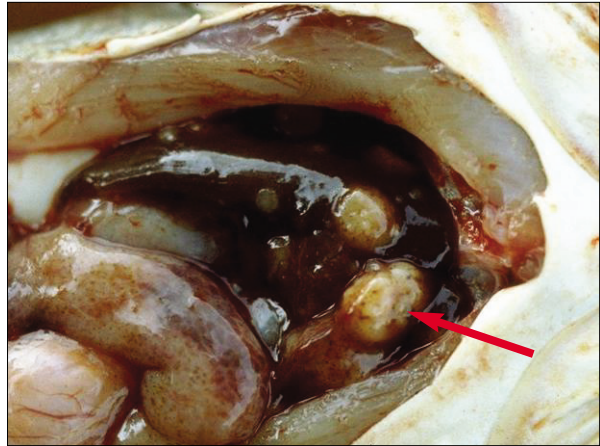


Figure 50a. Nodules in the liver.

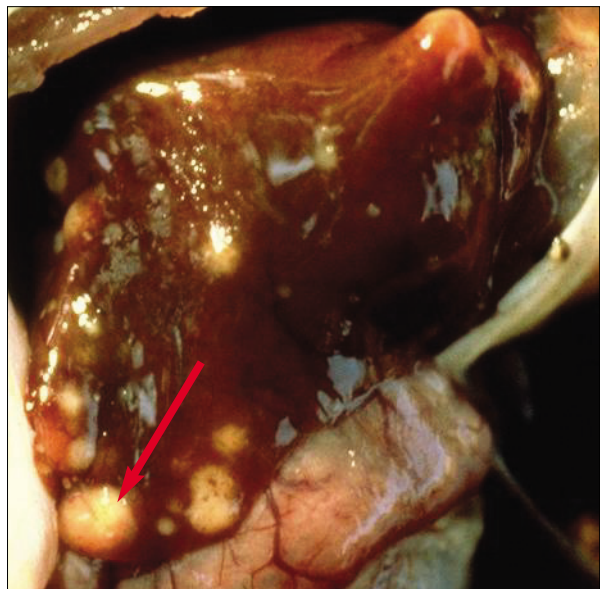


Figure 50b. Nodules in the liver.

Other: Aberration or deviation in the liver that does not fit into above scheme; describe.

Record the liver condition on the Fish Health Examination Form.

6.3.1.2 Liver Sample Collection: For fish **with** a discrete liver, use **acetone-rinsed scissors** to cut any grossly observable foci or lesions from the liver and put them into the fixative. If bile is not collected, **try not to puncture the gall bladder**.

For fish **without** a discrete liver, such as common carp (*Cyprinus carpio*) or sucker (Catostomidae), the procedure is analogous, but the liver is usually not removed. Upon completion of the visual observation, locate and inspect as many of the dispersed hepatic lobes as possible.

Note: Here, nodule refers to the dispersed liver organ, not to a pathological condition.

6.3.1.3 GALL BLADDER FULLNESS AND BILE COLOR:

The bile is observed indirectly through the observation of the gall bladder. The ranking scheme considers “fullness” of the bladder and degree of “green-ness” as follows (Figures 51–52b):

Bile color should be classified as:

Yellow or straw color;

Light green to grass green; or

Dark green or dark blue-green (Figure 51).

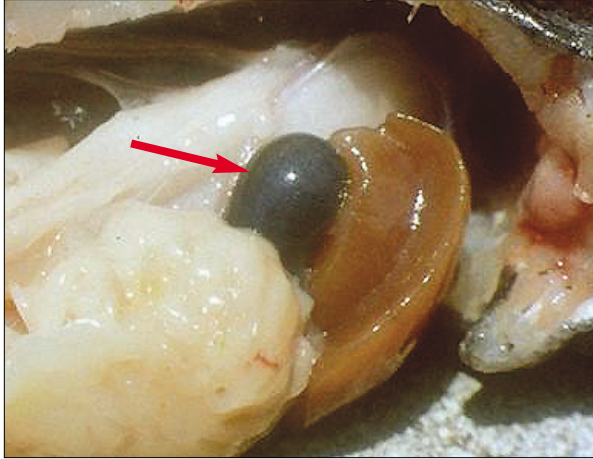


Figure 51. A normal gall bladder, which is full with dark green bile.

Gall Bladder fullness may be either:

Empty (Figures 52a and 52b) or nearly so;

Partly full; or

Full (Figure 51) or **distended**.

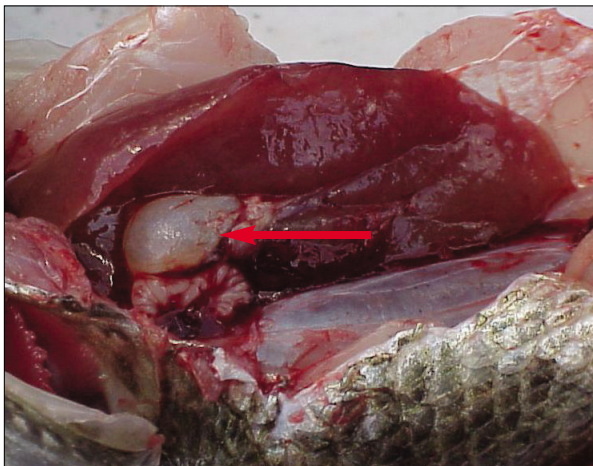


Figure 52a. Empty gall bladder.

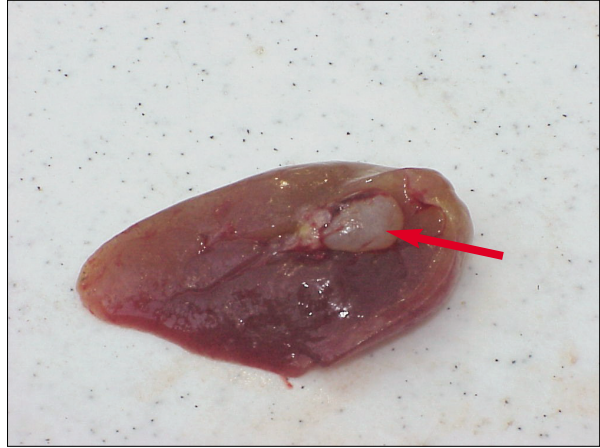

Figure 52b. Empty gall bladder.

Record the color of the bile and the fullness of the gall bladder on the Fish Health Examination Form.

Note: If bile color can be determined, bile is present and the gall bladder should be described as either “partly full” or “full”. If the gall bladder is empty, do not check a color.

6.3.2 GONADS: Locate the gonads (Figures 53–56) and determine the gender of the fish, if possible.

Note: The gross visible appearance of the gonads varies greatly among taxa and over the life of the fish. Generally, ovaries have a granular appearance and are yellow, orange, or pink; in contrast, testes are lighter in color (that is, whitish to yellow) and have a less granular appearance. An intersex condition (both) may also be observed. Some local experience with the species to be collected will be required before gender and reproductive stage can be accurately determined in the field.

Record the gender on both the front page of the Fish Health Examination Form (Appendix A-2) and within the Gonads section. Dissect the gonads from the viscera.

Record the gonadal stage (that is, ripe, spent, intermediate) on the Fish Health Examination Form. Ripe female fish frequently have distended abdomens and large, full gonads; ovaries contain many large eggs. If obtaining organ weight is part of the study plan, **record the gonad weight (± 0.1 g or less)** on the Fish Health Examination Form. Observe the condition of the gonads as follows:

Male (Figures 53a and 53b):

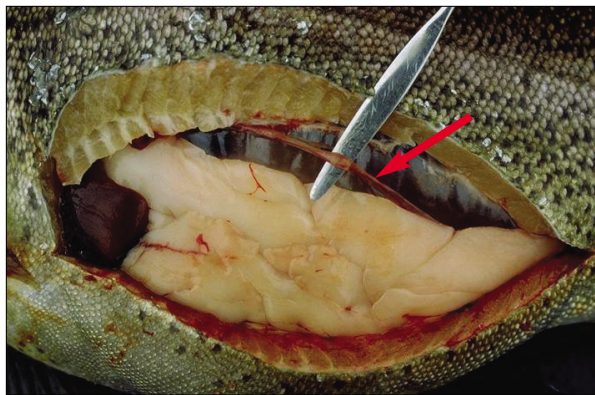


Figure 53a. Immature male gonads.

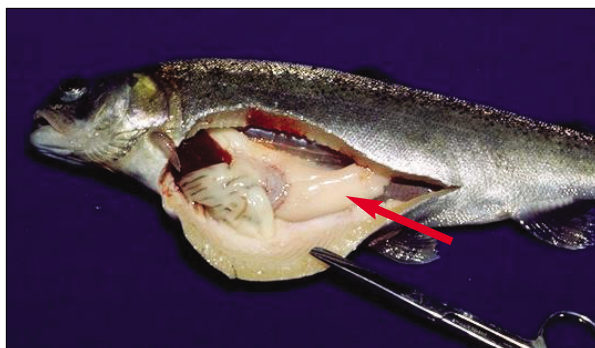


Figure 53b. Mature male gonads.

Female (Figures 54, 55a–55c)

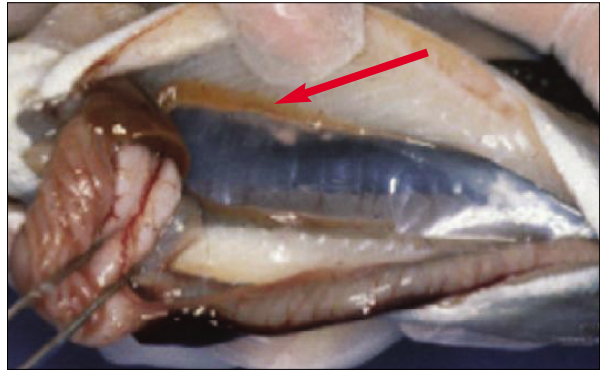


Figure 54. Immature female gonads.

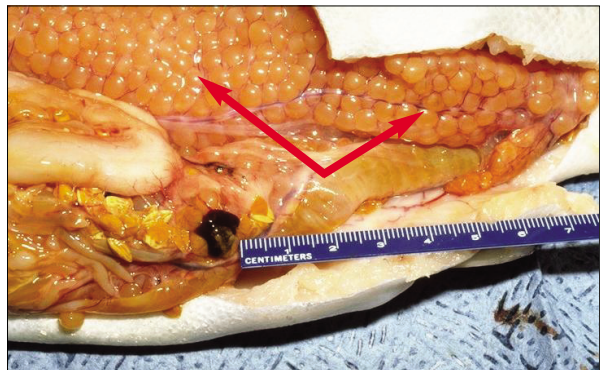


Figure 55a. Mature female gonads (salmonid).

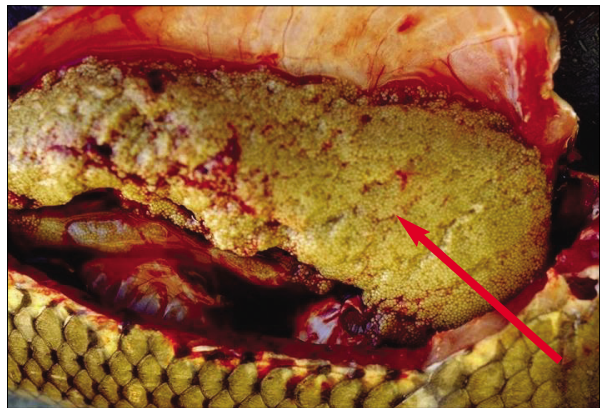

Figure 55b. Mature female gonads (common carp).

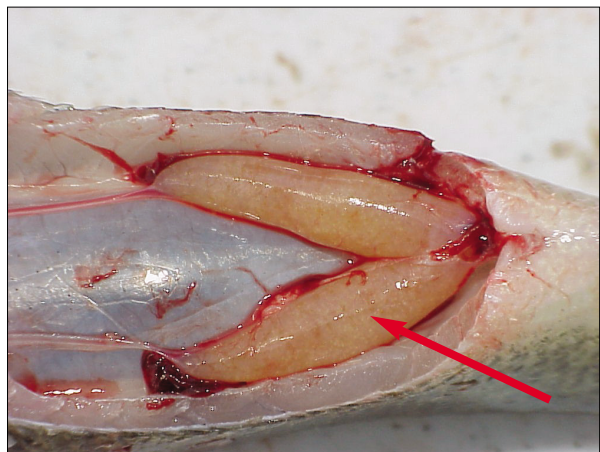


Figure 55c. Mature female gonads (*Micropterus* sp.)

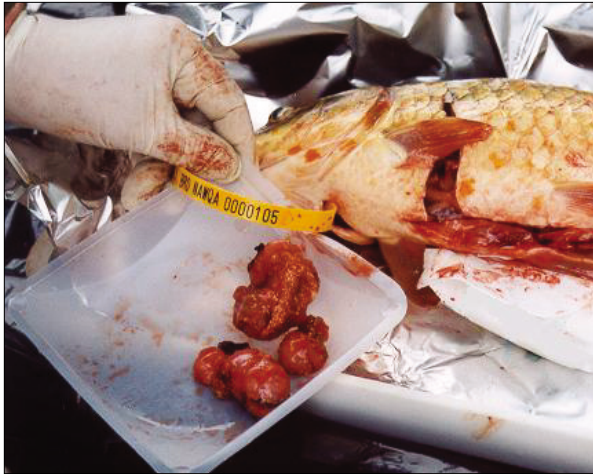Other-Gonads (Figure 56):

Figure 56. Large mass located in gonads, categorized as “other”.

Note any lesions, parasites, and so forth by checking “other” (preserve a sample), and describe.

Cut 1-cm pieces from the posterior end (bottom tips) of the gonads, and place a maximum of five gonad pieces in the fixative. If the gonad is small, preserve the entire organ.

Record the number of pieces in fixative.

6.3.3 SPLEEN: Locate the spleen and dissect it whole from the viscera. If obtaining organ weight is part of the study plan, **record the spleen weight (± 0.002 g)** on the Fish Health Examination Form (Appendix A-2). Observe the condition of the spleen (Figures 57a–59) as follows (check all that apply):

Normal:

Red to Black (Figure 57a and 57b): “Black” is actually a very dark red color; both conditions are considered normal.

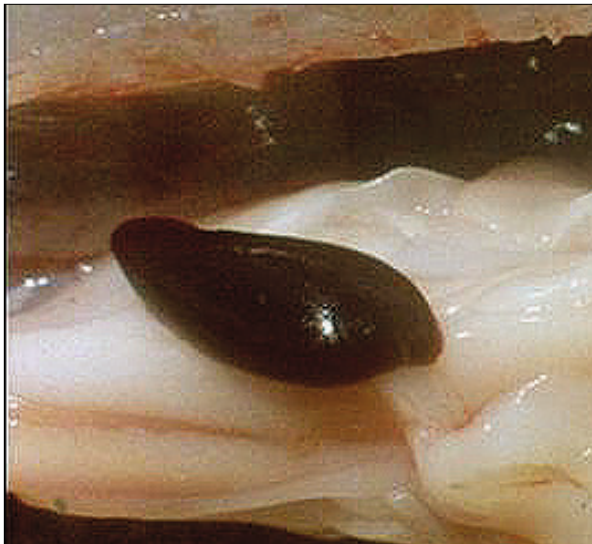

Figure 57a. Normal spleen, dark red in color with no apparent aberrations.

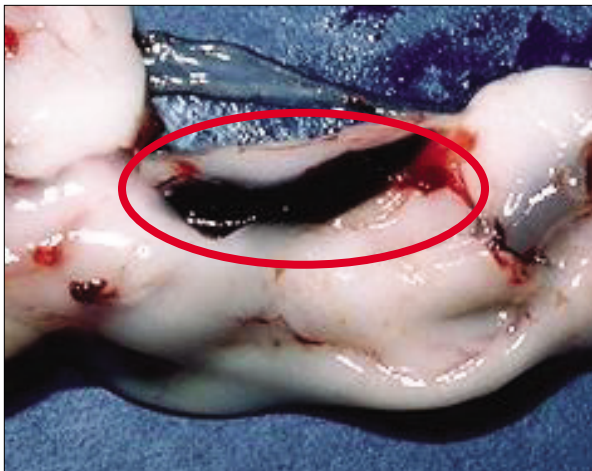


Figure 57b. Normal spleen.

Abnormal:

Granular (see Goede, 1988: photo 32): “Rough” appearance of the spleen.

Nodular (Figure 58): Manifests fistulas or nodules of varying sizes. These are often cysts, such as those caused by parasites or chronic mycobacterial infections.




Figure 58. Spleen sample containing nodules of various sizes.

Enlarged (Figure 59): The spleen can be significantly and noticeably enlarged or swollen.

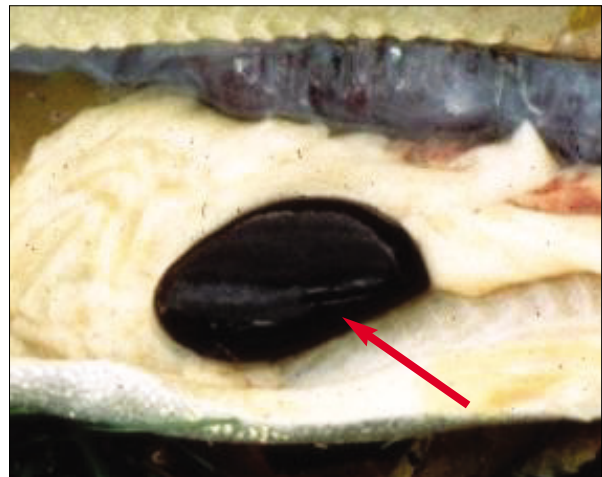


Figure 59. Example of an abnormally enlarged spleen.

Other: Occasionally there are grossly visible aberrations that do not fit any of the classes above. The spleen may be mottled gray, and some fishes may have very small spleens. These should be classified as “other” and described.

Record the spleen condition on the Fish Health Examination Form.

If the spleen is large (>0.8 g), cut it in half, and place one half in the fixative, and retain the other with the carcass. Otherwise, place the entire spleen in the fixative. **Record that the spleen in fixative was collected** on the Fish Health Examination Form.

6.3.4 KIDNEY(S): In some fishes (common carp, centrarchids), the anterior (head) and posterior (trunk) kidney are separate; in others (salmonids, ictalurids), they are continuous. We treat them as being together for examination, but separate for sample collection. Observe and sample both (Figures 60–63).

6.3.4.1 Posterior (Trunk) Kidney:

The trunk kidney is exposed by removing the layer of mesentery at the posterior dorsal border of the abdominal cavity, dorsal to the gas bladder. Observe its condition as follows (check all that apply on the Fish Health Examination Form, Appendix A-2).

Normal (Figure 60): Firm, dark red color lying relatively flat dorsally in the visceral cavity along the length of the ventral surface of the vertebral column.

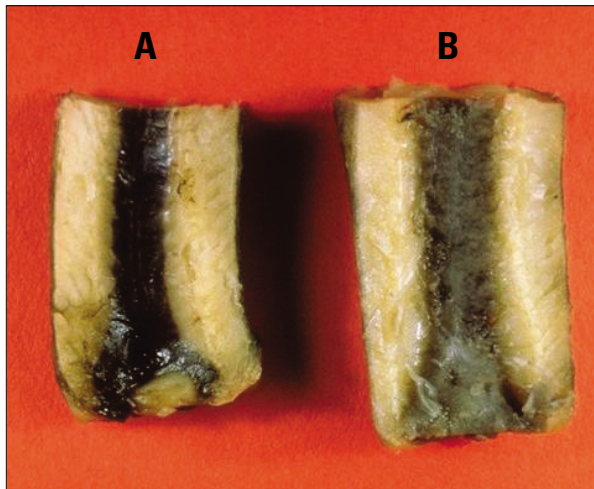


Figure 60. (A) normal kidney; (B) abnormal kidney which is mottled in appearance.

Abnormal:

Swollen (Figures 61–63): Wholly or partly enlarged or swollen;



Figure 61. Swollen kidney.

Mottled (Figures 62 and 63): Gray discoloration, mottled or “patchy” appearance, ranging from scattered patches of gray to mostly or totally gray discoloration;

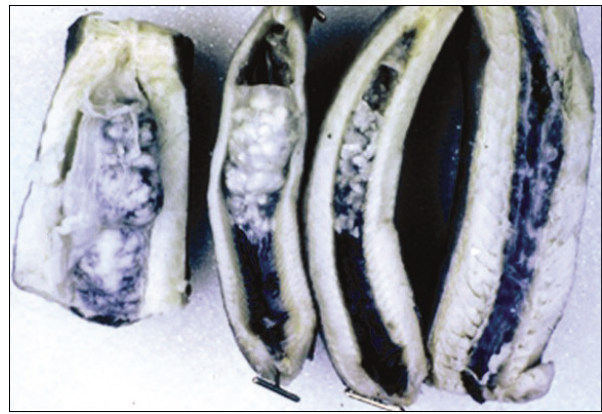


Figure 62. Examples of various aberrations found in the kidney.

Granular (Figures 61 and 62): The kidney has a “granular” or irregular surface which may be due to the presence of granulomas, hemorrhages, congestion or other causes. These areas are generally not hard and “gritty”;

Urolithiasis (see Goede, 1998: photos 38-40): Urolithic deposits are hard and “gritty”. This condition is also known as nephrocalcinosis and involves deposition of white or “cream-colored” amorphous mineral material in the tubules of the kidney. It can range in appearance from very small white spots to severe conditions with very large “serpentine” deposits.

Note: These sites of deposition are not to be confused with the Stannius bodies (corpora of Stannius), which are the white nodular tissues present in salmonid kidneys and which have an endocrine function. The Stannius bodies are generally not associated with the tubules and usually occur at the “edges” in an area about midway along the kidney. They appear more globular than do urolithic deposits.

Other (Figure 63): This is used to classify any aberrations that do not fit into the above scheme; describe.

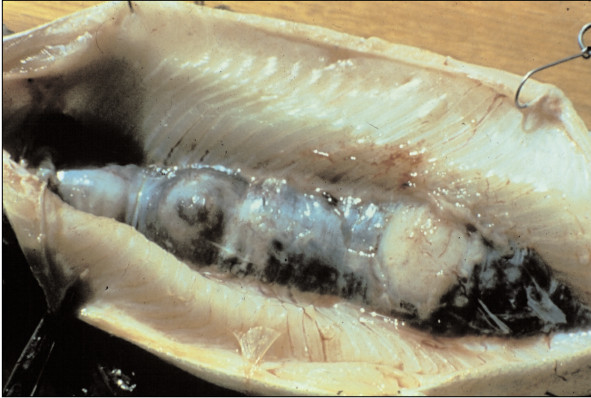


Figure 63. Abnormal kidney; enlarged, mottled, and “other” (white nodules).

Record the trunk kidney appearance on the Fish Health Examination Form.

Place at least one 1-cm piece of the trunk kidney in the fixative, and **record the number of pieces preserved** (if possible—fish kidney tends to fall apart) on the Fish Health Examination Form.

6.3.4.2 Anterior (Head) Kidney: In fishes with separate kidneys, the head kidney is located dorsal to the liver and may be viewed after the latter has been removed.

Record the head kidney appearance according to the criteria above; record observations in the anterior head kidney section of the Fish Health Examination Form (Appendix A-2).

Remove as much of the head kidney as you can (at least one 1-cm piece) and place it in fixative. **Record the number of pieces in fixative** (if possible) on the Fish Health Examination Form.

6.4 Scales or Spines

Collect a scale sample (most fishes) or pectoral fin spine (ictalurids) from the **left** side of the fish. If the left side is damaged (that is, scales or pectoral fin not present), collect from the right side.

Spiny-rayed fishes (bass, walleye, and so forth) – from the area of the appressed pectoral fin (Figure 6a).

Soft-rayed fishes (common carp, suckers, and so forth) – beneath the anterior portion of the dorsal fin, above the lateral line (Figure 6b).

Ictalurids (that is, catfishes) – entire **disarticulated** pectoral spine; cut away as much fin and flesh as possible. Be sure to get the base of the spine (that is, twist off like a chicken leg).

Note: These structures are included as representative because most fishery biologists have the training, experience, and equipment necessary to read them. Other hard structures (otoliths, opercular bones, vertebrae, and so forth) may be used if these structures are known to be valid indicators of age in the species you are working with and you have the capability to read them.

Place the scale or spine sample in a labeled scale envelope (Figure 1) and **allow to air-dry**. Store it until it can be read. **If scale envelopes are stored in a plastic bag, do not seal the bag. Record that the sample was collected and the side of the fish from which it was collected** on the Fish Health Examination Form (Appendix A-2).

6.5 Cleaning Equipment

Thoroughly rinse all contact surfaces (measuring board, table, and so forth) with tap or ambient water. Wash all dissecting equipment with de-ionized water, and follow with an acetone rinse.

Reminder: Acetone is flammable.

7.0 POST-COLLECTION AND PROCESSING PROCEDURES

7.1 Complete and Check Fish Health Examination and Station Identification Forms

Post-calibrate the balances by re-weighing the calibration masses, and **record the “After” calibration readings** on the Station Identification Form (Appendix A-1). Turn off the balance(s) and re-pack them in their case(s).

Important: The team leader checks the Fish Health Examination Forms and the Station Identification Forms again to be certain that all information has been recorded and is legible. Make sure each section (i.e. liver, gonad, spleen, etc.) has a box marked. Do not leave blanks within the examination form, mark ‘normal’ if no anomalies were found. Otherwise be sure that all observed anomalies are completely identified and appropriate boxes are marked. After each form has been reviewed and approved, it should be initialed in the “Reviewer’s Initials” box.

7.2 Clean-up

Properly dispose of used expendables. Thoroughly clean all work surfaces. Thoroughly clean and inspect all equipment used in the field to protect against the transportation of living organisms among waterways.

Note: Procedures for cleaning equipment are beyond the scope of this document and may vary among agencies, regions, states, and water bodies.

Pay particularly close attention to boats (including live wells), motors, trailers, and tubs used to hold fish. A stop at a car wash may be advantageous (be sure to rinse thoroughly with clean water). A garden sprayer or pump spray bottle containing a weak bleach solution can be used for a final rinse of all equipment. Tap water is sufficient for cleaning smaller equipment (pans, measuring boards, coolers, live boxes), followed by the bleach solution. Water should be used to rinse dissecting equipment and the weighing pans of electronic balances (be careful!). Give dissecting equipment a final acetone rinse.

8.0 UPON RETURN FROM THE FIELD

8.1 Photocopy and Mail Data Forms and Other Records

Field teams should make two copies of all data forms and field notes. The team leader should retain one set of copies and the notebook. The second set of copies and the original data forms should be sent to the project coordinator/study director and if needed, a completed COC form (see Schmitt and others, 1999). If the project coordinator/study director is a member of the field team, retain both the original data forms and field notes and at least one set of photocopies. For additional security, store the originals and copies in separate locations.

8.2 Ship Histopathology Samples

Before you ship these samples, top off the fixative and

check each bottle to be certain that the tops are tightly fastened. If needed, samples should be shipped with a completed COC form. **Check transport restrictions for your given fixative to determine the method of transportation and packaging instructions.**

8.3 Process Film

As soon as possible, **annotate your slides, photographs or videotape** – mark the station number, fish identification number (if applicable), and date.

8.4 Age Fish and Mail Age Data

Fish should be aged using the techniques developed for the structure (for example, scale, spine, otolith) that was collected. These techniques may vary with species. If the original data must be sent to a cooperating laboratory, original data forms should be shipped with a completed COC form. COC is optional if photocopied data forms are being shipped.

8.5 Thoroughly Clean Non-Expendable Equipment

Equipment and supplies should be cleaned as soon as possible after returning from the field. Do not use detergents or other cleaning agents that could damage specimens or bias laboratory analyses during the next sampling trip.

Reminder: Special care should be taken when cleaning equipment to ensure that no living organisms are transported from one waterway to the next.

9.0 ACKNOWLEDGMENTS

The authors wish to thank R. Goldstein, T. Bartish, and P. Baumann for their review of the document; P. Greene for assistance with data forms; M. Mac, D. Hardesty, B. Poulton, J. Morrison, C. Smith, B. Wissel, and Leetown Science Center for providing photographs and assisting with photographs. The photographs in this guide came from sources of known and in some cases unknown origin. We thank and acknowledge the efforts of all that contributed these photographs, which are the heart of this guide.

10.0 REFERENCES

- [ASIH] American Society of Ichthyologists and Herpetologists, [AFS] American Fisheries Society, [AIFRB] American Institute of Fishery Research Biologists, 1988, Guidelines for use of fishes in field research: Fisheries, v. 13, p. 16-23.
- Baker, J.R., Peck, D.V., and Sutton, D.W., 1997, Environmental Monitoring and Assessment Program Surface Waters, Field operations manual for lakes: U.S. Environmental Protection Agency, Report EPA/620/R-97/001.
- Biomonitoring of Environmental Status and Trends Program, 1996, Summary report from a workshop on selection of tier 1 bioassessment methods: U.S. Department of the Interior, National Biological Service, Information and Technology Report 7, 55 p.
- Blouin, M.A., and Hall, G.R., 1990, Improved method for sectioning pectoral spines of catfish for age determination: Journal of Freshwater Ecology, v. 5, p. 489-490.
- Frie, R.V., 1982, Measurement of fish scales and back-calculation of body lengths using a digitizing pad and microcomputer: Fisheries, v. 7, no. 6, p. 5-8.
- Goede, R.W., 1989, Fish health/condition assessment procedures: Utah Division of Wildlife Resources, Fisheries Experiment Station.
- 1996, Fish health/condition assessment procedures. Part 1 -- procedures manual: Utah Division of Wildlife Resources, Fisheries Experiment Station, 31 p.
- 1988, Fish health/condition assessment procedures. Part 2 -- a color atlas of necropsy classification categories: Utah Division of Wildlife Resources, Fisheries Experiment Station.
- Goede, R.W., and Barton, B.A., 1990, Organismic indices and an autopsy-based assessment as indicators of health and condition of fish, in Adams, S.M., ed., Biological indicators of stress in fish. American Fisheries Society Symposium 8: Bethesda, MD, American Fisheries Society, p. 93-108.
- Hunn, J.B., 1988, Field assessment of the effects of contaminants on fishes: U.S. Fish and Wildlife Service, Biological Report 18(19), 25 p.
- Jearld, A., Jr., 1983, Age determination, in Nielsen, L.A., and Johnson, D.L., eds., Fisheries techniques: Bethesda, MD, American Fisheries Society, p. 301-324.
- Lagler, K.F., 1956, Freshwater fishery biology: Dubuque, IA, Wm. C. Brown Company 421 p.
- Lagler, K.F., Bardach, J.E., and Miller, R.R., 1962, Ichthyology: New York, John Wiley & Sons, 545 p.
- Meador, M.R., Cuffney, T.F., and Gurtz, M.E., 1993, Methods for sampling fish communities as part of the National Water-Quality Assessment Program: U.S. Geological Survey, Open-File Report 93-104, 40 p.
- Meyer, F.P., and Barclay, L.A., 1990, Field manual for

- the investigation of fish kills: U.S. Fish and Wildlife Service, Resource Publication 177, 120 p.
- Nielson, L.A., and Johnson, D.L., 1983, Fisheries techniques: Bethesda, MD, American Fisheries Society, 468 p.
- Robins, C.R., Bond, C.E., Brooker, J. R., Lachner, E.A., Lea, R.N., and Scott, W.B., 1991, Common and scientific names of fishes from the United States and Canada: Bethesda, MD, American Fisheries Society, 183 p.
- Schmitt, C.J., Blazer, V.S., Dethloff, G.M., Tillitt, D.E., Gross, T.S., Bryant, W.L., Jr., DeWeese, L.R., Smith, S.B., Goede, R.W., Bartish, T.M., and Kubiak, T.J., 1999, Biomonitoring of Environmental Status and Trends (BEST) Program: field procedures for assessing the exposure of fish to environmental contaminants: U.S. Geological Survey, Biological Resources Division, Information and Technology Report 1999-0007, 68 p.
- Schmitt, C.J., and Dethloff, G.M., eds.2000, Biomonitoring of Environmental Status and Trends (BEST) program: selected methods for monitoring chemical contaminants and their effects in aquatic ecosystems: U.S. Geological Survey, Information and Technology Report 2000-0005, 81 p.
- Smith, L.S., 1973, Introductory anatomy and biology of selected fish and shellfish: Seattle, WA, University of Washington, College of Fisheries 128 p.
- Tesch, F.W., 1971, Age and growth, in Ricker, W.E., ed, Methods for assessment of fish production in fresh waters (2nd ed.): Oxford, England, Blackwell Scientific Publications, p. 98-130.
- U.S. Environmental Protection Agency, 1989, Toxic Substances Control Act (TSCA); good laboratory practice standards; final rule: EPA 40 CFR, Part 792.
- Walsh, S.J., and Meador, M.R., 1998, Guidelines for quality assurance and quality control of fish taxonomic data collected as part of the National Water-Quality Assessment Program: U.S. Geological Survey, Water-Resources Investigations Report 98-4239, 33 p.
- Wiesburg, S.G., and Frie, R.V., 1987, Linear models for the growth of fish, in Summerfelt, R.C., and Hall, G.E., eds., Age and growth of fish: Ames, IA, Iowa State University Press, p. 127-143.

Appendix A
Data Forms

Appendix A-1



STATION IDENTIFICATION FORM

STATION ID # _____ DATE ____/____/____

STATION DESCRIPTION (River and Location): _____

Water **TEMPERATURE** (°C):

Sampling **START** Time:

Sampling **STOP** Time:

LANDOWNER'S PERMISSION: _____ Date: _____
 _____ Date: _____

Team Leader: _____

Other Personnel:

_____	_____
_____	_____
_____	_____
_____	_____

GPS COORDINATES:

(Degrees – Minutes)

LATITUDE

LONGITUDE

(D)

(M)

(D)

(M)

MAP DATUM:

MAXIMUM: ____ - ____ . ____

____ - ____ . ____

MINIMUM: ____ - ____ . ____

____ - ____ . ____

BALANCE: (make and serial #)	MASS:	CALIBRATION:	
		Before	After

RECORDER'S INITIALS: _____

Appendix A-2



FISH HEALTH EXAMINATION FORM

DATE: ___/___/___ STATION ID# _____ FISH ID# _____

SPECIES: _____ Weight: _____(g) Length: _____(mm) Sex: _____

EXTERNAL EXAMINATION: (check all that apply)

<p>BODY SURFACE:</p> <input type="checkbox"/> normal <input type="checkbox"/> raised growth(s) <input type="checkbox"/> reddened lesion(s) <input type="checkbox"/> spinal deformities <input type="checkbox"/> hemorrhagic body <input type="checkbox"/> focal discoloration <input type="checkbox"/> body fungus <input type="checkbox"/> parasite(s) <i>specify:</i> <input type="checkbox"/> white spots <input type="checkbox"/> leech(es) <input type="checkbox"/> black spot(s) <input type="checkbox"/> Anchor worm(s) <input type="checkbox"/> OTHER <i>specify:</i> _____ _____ _____ # in fixative ____ # of photos ____	<p>HEAD and ORAL CAVITY:</p> <input type="checkbox"/> normal head <input type="checkbox"/> deformed head <input type="checkbox"/> upper lip growth <input type="checkbox"/> lower lip growth <input type="checkbox"/> swollen nare <p>BARBELS:</p> <input type="checkbox"/> normal <input type="checkbox"/> missing <input type="checkbox"/> stubbed <input type="checkbox"/> deformed <input type="checkbox"/> OTHER <i>specify:</i> _____ _____ _____ # in fixative ____ # of photos ____	<p>EYES:</p> <table style="width:100%; border: none;"> <tr> <td style="text-align: center; border: none;"><u>Left:</u></td> <td style="text-align: center; border: none;"><u>Right:</u></td> </tr> <tr> <td style="border: none;"><input type="checkbox"/> normal</td> <td style="border: none;"><input type="checkbox"/> normal</td> </tr> <tr> <td style="border: none;"><input type="checkbox"/> exophthalmic</td> <td style="border: none;"><input type="checkbox"/> exophthalmic</td> </tr> <tr> <td style="border: none;"><input type="checkbox"/> opaque</td> <td style="border: none;"><input type="checkbox"/> opaque</td> </tr> <tr> <td style="border: none;"><input type="checkbox"/> missing</td> <td style="border: none;"><input type="checkbox"/> missing</td> </tr> <tr> <td style="border: none;"><input type="checkbox"/> hemorrhagic</td> <td style="border: none;"><input type="checkbox"/> hemorrhagic</td> </tr> <tr> <td style="border: none;"><input type="checkbox"/> emboli</td> <td style="border: none;"><input type="checkbox"/> emboli</td> </tr> <tr> <td style="border: none;"><input type="checkbox"/> OTHER <i>specify:</i> _____</td> <td style="border: none;"><input type="checkbox"/> OTHER <i>specify:</i> _____</td> </tr> <tr> <td style="border: none;">_____</td> <td style="border: none;">_____</td> </tr> <tr> <td style="border: none;">_____</td> <td style="border: none;">_____</td> </tr> <tr> <td style="border: none;"># in fixative ____</td> <td style="border: none;"># in fixative ____</td> </tr> <tr> <td style="border: none;"># of photos ____</td> <td style="border: none;"># of photos ____</td> </tr> </table>	<u>Left:</u>	<u>Right:</u>	<input type="checkbox"/> normal	<input type="checkbox"/> normal	<input type="checkbox"/> exophthalmic	<input type="checkbox"/> exophthalmic	<input type="checkbox"/> opaque	<input type="checkbox"/> opaque	<input type="checkbox"/> missing	<input type="checkbox"/> missing	<input type="checkbox"/> hemorrhagic	<input type="checkbox"/> hemorrhagic	<input type="checkbox"/> emboli	<input type="checkbox"/> emboli	<input type="checkbox"/> OTHER <i>specify:</i> _____	<input type="checkbox"/> OTHER <i>specify:</i> _____	_____	_____	_____	_____	# in fixative ____	# in fixative ____	# of photos ____	# of photos ____
<u>Left:</u>	<u>Right:</u>																									
<input type="checkbox"/> normal	<input type="checkbox"/> normal																									
<input type="checkbox"/> exophthalmic	<input type="checkbox"/> exophthalmic																									
<input type="checkbox"/> opaque	<input type="checkbox"/> opaque																									
<input type="checkbox"/> missing	<input type="checkbox"/> missing																									
<input type="checkbox"/> hemorrhagic	<input type="checkbox"/> hemorrhagic																									
<input type="checkbox"/> emboli	<input type="checkbox"/> emboli																									
<input type="checkbox"/> OTHER <i>specify:</i> _____	<input type="checkbox"/> OTHER <i>specify:</i> _____																									
_____	_____																									
_____	_____																									
# in fixative ____	# in fixative ____																									
# of photos ____	# of photos ____																									

<p>OPERCULA:</p> <input type="checkbox"/> normal <input type="checkbox"/> slight shortening <input type="checkbox"/> severe shortening <input type="checkbox"/> OTHER <i>specify:</i> _____ _____ _____ # in fixative ____ # of photos ____
--

<p>GILLS:</p> <table style="width:100%; border: none;"> <tr> <td style="text-align: center; border: none;"><u>Left:</u></td> <td style="text-align: center; border: none;"><u>Right:</u></td> </tr> <tr> <td style="border: none;"><input type="checkbox"/> normal</td> <td style="border: none;"><input type="checkbox"/> normal</td> </tr> <tr> <td style="border: none;"><input type="checkbox"/> frayed</td> <td style="border: none;"><input type="checkbox"/> frayed</td> </tr> <tr> <td style="border: none;"><input type="checkbox"/> marginate</td> <td style="border: none;"><input type="checkbox"/> marginate</td> </tr> <tr> <td style="border: none;"><input type="checkbox"/> pale</td> <td style="border: none;"><input type="checkbox"/> pale</td> </tr> <tr> <td style="border: none;"><input type="checkbox"/> OTHER <i>specify:</i> _____</td> <td style="border: none;"><input type="checkbox"/> OTHER <i>specify:</i> _____</td> </tr> <tr> <td style="border: none;">_____</td> <td style="border: none;">_____</td> </tr> <tr> <td style="border: none;"># in fixative ____</td> <td style="border: none;"># in fixative ____</td> </tr> <tr> <td style="border: none;"># of photos ____</td> <td style="border: none;"># of photos ____</td> </tr> </table>	<u>Left:</u>	<u>Right:</u>	<input type="checkbox"/> normal	<input type="checkbox"/> normal	<input type="checkbox"/> frayed	<input type="checkbox"/> frayed	<input type="checkbox"/> marginate	<input type="checkbox"/> marginate	<input type="checkbox"/> pale	<input type="checkbox"/> pale	<input type="checkbox"/> OTHER <i>specify:</i> _____	<input type="checkbox"/> OTHER <i>specify:</i> _____	_____	_____	# in fixative ____	# in fixative ____	# of photos ____	# of photos ____
<u>Left:</u>	<u>Right:</u>																	
<input type="checkbox"/> normal	<input type="checkbox"/> normal																	
<input type="checkbox"/> frayed	<input type="checkbox"/> frayed																	
<input type="checkbox"/> marginate	<input type="checkbox"/> marginate																	
<input type="checkbox"/> pale	<input type="checkbox"/> pale																	
<input type="checkbox"/> OTHER <i>specify:</i> _____	<input type="checkbox"/> OTHER <i>specify:</i> _____																	
_____	_____																	
# in fixative ____	# in fixative ____																	
# of photos ____	# of photos ____																	

<p>FINS:</p> <input type="checkbox"/> normal <input type="checkbox"/> mild erosion <input type="checkbox"/> severe erosion <input type="checkbox"/> frayed <input type="checkbox"/> hemorrhagic <input type="checkbox"/> emboli <input type="checkbox"/> OTHER <i>specify:</i> _____ _____ _____ # in fixative ____ # of photos ____

Appendix A-2--Continued

INTERNAL EXAMINATION: (check all that apply)

<p>LIVER:</p> <p><input type="checkbox"/> normal (dark to light red)</p> <p><input type="checkbox"/> tan (coffee with cream)</p> <p><input type="checkbox"/> general discoloration</p> <p><input type="checkbox"/> focal discoloration</p> <p><input type="checkbox"/> nodules</p> <p><input type="checkbox"/> OTHER <i>specify:</i> _____</p> <p>_____</p> <p>_____</p> <p>Weight _____ (0.1g) <i>with gallbladder intact</i></p> <p># in fixative _____ # of photos _____</p>	<p>GALL BLADDER and BILE:</p> <p>Color:</p> <p><input type="checkbox"/> yellow</p> <p><input type="checkbox"/> light-grass green</p> <p><input type="checkbox"/> dark green to blue-green</p> <p><input type="checkbox"/> OTHER <i>specify:</i> _____</p> <p>_____</p> <p>_____</p> <p>_____</p> <p>Fullness:</p> <p><input type="checkbox"/> empty</p> <p><input type="checkbox"/> partly full</p> <p><input type="checkbox"/> full or distended</p> <p># in fixative _____ # of photos _____</p>
--	---

<p>GONADS:</p> <p>Gender:</p> <p><input type="checkbox"/> male</p> <p><input type="checkbox"/> female</p> <p><input type="checkbox"/> indeterminate</p>	<p>Stage:</p> <p><input type="checkbox"/> ripe</p> <p><input type="checkbox"/> spent</p> <p><input type="checkbox"/> intermediate</p>	<p><input type="checkbox"/> OTHER <i>specify:</i> _____</p> <p>_____</p> <p>Weight _____ (0.1g)</p> <p># in fixative _____ # of photos _____</p>
---	--	--

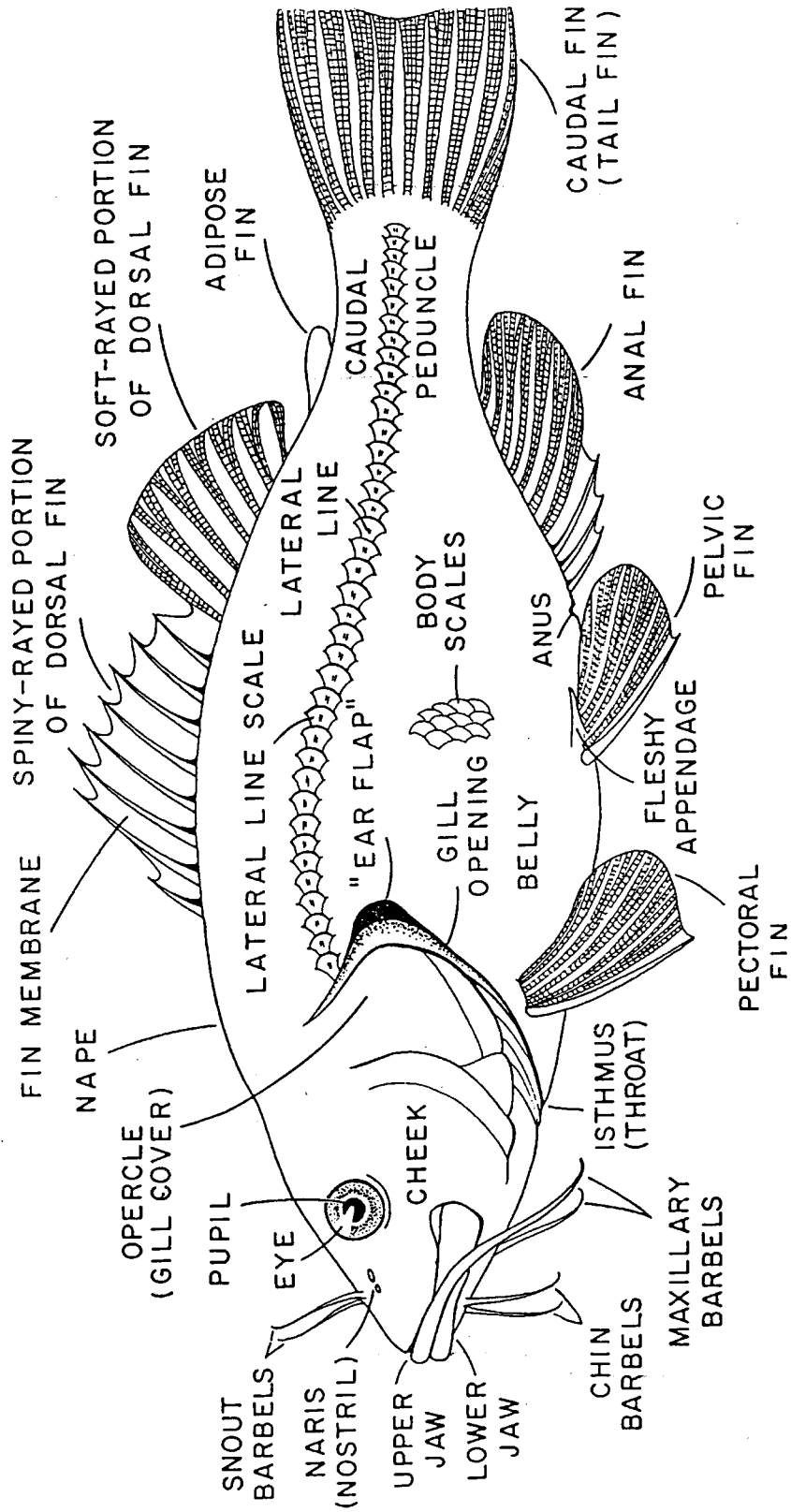
<p>SPLEEN:</p> <p><input type="checkbox"/> normal (red to black)</p> <p><input type="checkbox"/> granular</p> <p><input type="checkbox"/> nodular</p> <p><input type="checkbox"/> enlarged</p>	<p><input type="checkbox"/> OTHER <i>specify:</i> _____</p> <p>_____</p> <p>Weight _____ (0.002g)</p> <p># in fixative _____ # of photos _____</p>
---	--

<p>POSTERIOR (Trunk) KIDNEY:</p> <p><input type="checkbox"/> normal</p> <p><input type="checkbox"/> swollen</p> <p><input type="checkbox"/> mottled</p> <p><input type="checkbox"/> granular</p> <p><input type="checkbox"/> urolithiasis</p> <p><input type="checkbox"/> OTHER <i>specify:</i> _____</p> <p>_____</p> <p># in fixative _____ # of photos _____</p>	<p>ANTERIOR (Head) KIDNEY:</p> <p><input type="checkbox"/> normal</p> <p><input type="checkbox"/> swollen</p> <p><input type="checkbox"/> mottled</p> <p><input type="checkbox"/> granular</p> <p><input type="checkbox"/> urolithiasis</p> <p><input type="checkbox"/> OTHER <i>specify:</i> _____</p> <p>_____</p> <p># in fixative _____ # of photos _____</p>
--	--

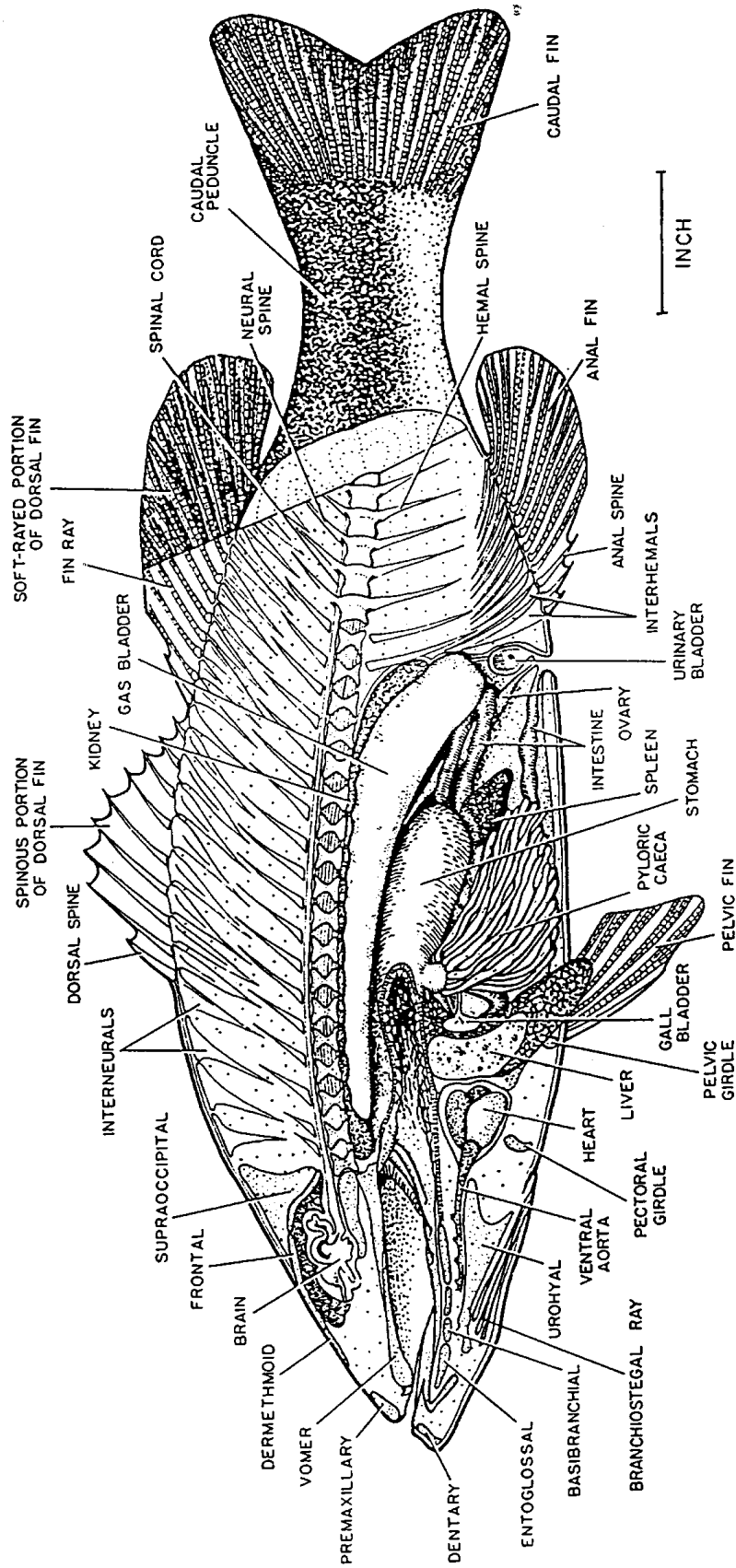
<p>GENERAL COMMENTS:</p> <p>_____</p> <p>_____</p> <p>_____</p> <p>_____</p> <p>_____</p> <p>_____</p> <p>_____</p>
--

<p><input type="checkbox"/> SCALES:</p> <p><i>side sampled:</i></p> <p><input type="checkbox"/> left</p> <p><input type="checkbox"/> right</p>	<p><input type="checkbox"/> SPINES:</p> <p><i>specify:</i> _____</p> <p>_____</p> <p><input type="checkbox"/> OTHER: _____</p>	<p>INITIALS:</p> <p>RECORDER: _____</p> <p>DISSECTOR: _____</p> <p>REVIEWER: _____</p>
---	---	---

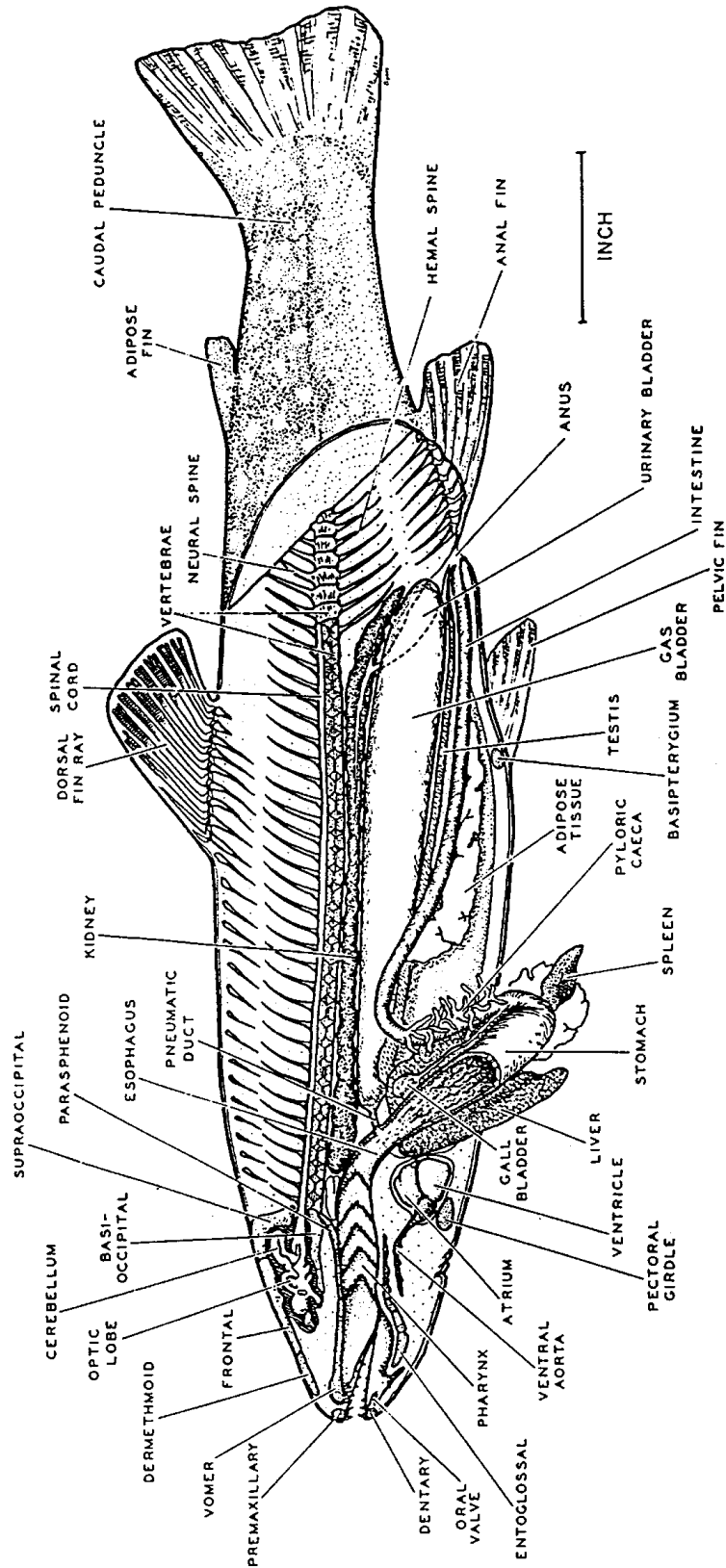
Appendix B
External and Internal Diagrams of Fish Anatomy



B-1. External features of a composite fish. From Humn (1988)



Anatomy of a spiny-rayed bony fish, the largemouth bass, *Micropterus salmoides*



Anatomy of a soft-rayed bony fish, the brook trout, *Salvelinus fontinalis*

REPORT DOCUMENTATION PAGE

Form Approved
OMB No. 0704-0188

Public reporting burden for this collection of information is estimated to average 1 hour per response, including the time for reviewing instructions, searching existing data sources, gathering and maintaining the data needed, and completing and reviewing the collection of information. Send comments regarding this burden estimate or any other aspect of this collection of information, including suggestions for reducing this burden, to Washington Headquarters Services, Directorate for Information Operations and Reports, 1215 Jefferson Davis Highway, Suite 1204, Arlington, VA 22202-4302, and to the Office of Management and Budget, Paperwork Reduction Project (0704-0188), Washington, DC 20503.

1. AGENCY USE ONLY (<i>Leave Blank</i>)	2. REPORT DATE September 2002	3. REPORT TYPE AND DATES COVERED Information and Technology Report	
4. TITLE AND SUBTITLE Illustrated Field Guide for Assessing External and Internal Anomalies in Fish		5. FUNDING NUMBERS	
6. AUTHOR(S) Stephen B. Smith, Anne P. Donahue, Robin Lipkin, Vicki S. Blazer, Christopher J. Schmitt, and Ronald W. Goede			
7. PERFORMING ORGANIZATION NAME(S) AND ADDRESS(ES) U.S. Department of the Interior U.S. Geological Survey, Biological Resources Division Columbia Environmental Research Center Columbia, MO 65201		8. PERFORMING ORGANIZATION REPORT NUMBER USGS/BRD/ITR--2002-0007	
9. SPONSORING/MONITORING AGENCY NAME(S) AND ADDRESS(ES) U.S. Department of the Interior U.S. Geological Survey Biological Resources Division Reston, VA 20192		10. SPONSORING/MONITORING AGENCY REPORT NUMBER	
11. SUPPLEMENTARY NOTES			
12a. DISTRIBUTION/AVAILABILITY STATEMENT Release unlimited. Available from the National Technical Information Service, 5285 Port Royal Road, Springfield, VA 22161 (1-800-553-6847 or 703-487-4650). Available to registered users from the Defense Technical Information Center, Attn: Help Desk, 8722 Kingman Road, Suite 0944, Fort Belvoir, VA 22060-2618 (1-800-225-3842 or 703-767-9050).		12b. DISTRIBUTION CODE	
13. ABSTRACT (<i>Maximum 200 words</i>) Procedures are described for processing fish for examination of external and internal anomalies and pathologies indicative of exposure to environmental contaminants and other perturbations. For the procedures described here, fish are captured (preferably by electrofishing) and held alive until processing (generally <1 h). Fish are weighed, measured, and necropsied, and a scale sample is obtained from for age determination. Information is given for the collection and preservation of tissue samples for histopathological analysis. Photographs of most abnormalities are included along with normal conditions for easier identification of external (oral, head, eye, gill, opercula, and fin) and internal (liver, spleen, gonad, and kidney) anomalies. The report also includes recommendations for record keeping, sample labeling, and shipping records, equipment, supplies, and samples. A list of suggested equipment and supplies for field processing is included as are instructions for cleaning equipment.			
14. SUBJECT TERMS: contaminants, fish health, external anomalies, internal anomalies, histopathology.		15. NUMBER OF PAGES 35 pages +appendices	
		16. PRICE CODE	
17. SECURITY CLASSIFICATION OF REPORT Unclassified	18. SECURITY CLASSIFICATION OF THIS PAGE Unclassified	19. SECURITY CLASSIFICATION OF ABSTRACT Unclassified	20. LIMITATION OF ABSTRACT Unlimited

