

Multidisciplinary investigation of stranded harbor porpoises (*Phocoena phocoena*) in Washington State with an assessment of acoustic trauma as a contributory factor (2 May – 2 June 2003)



S.A. Norman, S. Raverty, B. McLellan, A. Pabst, D. Ketten, M. Fleetwood, J.K. Gaydos, B. Norberg, L. Barre, T. Cox, B. Hanson, and S. Jeffries



U.S. Department of Commerce
National Oceanic and Atmospheric Administration
National Marine Fisheries Service

NOAA Technical Memorandum NMFS-NWR-34
October 2004

Multidisciplinary investigation of stranded harbor porpoises (*Phocoena phocoena*) in Washington State with an assessment of acoustic trauma as a contributory factor (2 May – 2 June 2003)

S.A. Norman, S. Raverty, B. McLellan, A. Pabst, D. Ketten, M. Fleetwood, J.K. Gaydos, B. Norberg, L. Barre, T. Cox, B. Hanson, and S. Jeffries

National Marine Fisheries Service – Northwest Region

**NOAA Technical Memorandum NMFS-NWR-34
October 2004**



U.S. Department of Commerce
Donald L. Evans, Secretary

National Oceanic and Atmospheric Administration
Vice Admiral Conrad C. Lautenbacher, Jr., USN (Ret.)
Under Secretary for Oceans and Atmosphere

National Marine Fisheries Service
William T. Hogarth, Assistant Administrator for Fisheries

Suggested citation:

Norman, S.A., Raverty, S., McLellan, B., Pabst, A., Ketten, D., Fleetwood, M., Gaydos, J.K., Norberg, B., Barre, L., Cox, T., Hanson, B., and Jeffries, S. 2004. Multidisciplinary investigation of stranded harbor porpoises (*Phocoena phocoena*) in Washington State with an assessment of acoustic trauma as a contributory factor (2 May – 2 June 2003). U.S. Dep. Commerce, NOAA Tech. Memo. NMFS-NWR-34, 120 p.

A copy of this report may be obtained from:

**National Marine Fisheries Service
Northwest Region
7600 Sand Point Way NE, Bldg. 1
Seattle, WA 98115**

**Office of Science and Technology
NMFS, NOAA
1315 East-West Highway, F/ST
Silver Spring, MD 20910**

Or online at:

http://www.nwr.noaa.gov/mmammals/NWR-34_porp_rep.htm

Abstract

Observations of altered behavior of marine mammals in the area of mid-range sonar use by the naval vessel *USS SHOUP* in the eastern Strait of Juan de Fuca and Haro Strait on 5 May 2003, prompted the National Marine Fisheries Service (NMFS) to conduct an in-depth investigation on the causes of harbor porpoise strandings. Fifteen stranded harbor porpoises were reported during the period of 2 May 2003 to 2 June 2003, an abnormally high number when compared to the average stranding rate of 6 per year recorded over the previous decade. Eleven of the stranded harbor porpoises were collected for this investigation.

NMFS assembled a multidisciplinary team to conduct extensive classical forensic necropsy examinations on the 11 specimens, followed by laboratory diagnostic and histological analyses and complemented by high resolution computerized tomography (CT) scans. Samples were taken for a variety of analyses including disease screening, parasitology, chemical contaminant and lipid analyses, aging studies, prey identification and domoic acid analysis. The gross and microscopic findings from the necropsy examinations, laboratory results, and the analysis of the CT image data for each specimen are provided. Information on the discovery and collection of the stranded porpoises, and a comparison of this with porpoise strandings over the previous ten years is also included in this report.

Over 70 percent of the specimens were in moderate to advanced states of decomposition which made interpretation of the cause of death difficult. The cause of death was determined for five of the 11 porpoises examined by the multidisciplinary team. Of these five animals, two were found to have suffered blunt force trauma, while illness (peritonitis, salmonellosis, pneumonia) was implicated in the remaining three cases. No cause of death could be determined for the remaining six animals. The examinations did not reveal definitive signs of acoustic trauma in any of the porpoises examined. The multidisciplinary team noted that lesions consistent with acoustic trauma can be difficult to interpret or obscured, especially in animals in advanced postmortem decomposition. Because many of the carcasses investigated were in moderate to poor condition, the possibility of acoustic trauma from exposure to mid-range sonar as a contributory factor in the mortality of any of the porpoises could not be ruled out.

TABLE OF CONTENTS

Abstract	iii
Introduction	1
Materials and Methods	2
Results	5
Summary of post mortem examinations and laboratory results.....	46
Discussion	50
Conclusion.....	55
Acknowledgments	55
Literature Cited.....	56
Glossary.....	59

FIGURES

Figure 1. Reported porpoise strandings in Washington State 2 May – 2 June 2003.....	62
--	----

TABLES

Table 1. Reported harbor porpoise strandings in Washington State - 2 May-2 June 2003.	63
Table 2. Freezer specifications used to store and transport porpoises prior to necropsy.	64
Table 3. Body composition of harbor porpoises examined during the necropsy session.....	65
Table 4. Summary of organochlorine concentrations in the blubber.	66
Table 5. Bacteriology results for harbor porpoise specimens.	67
Table 6. Trace mineral and vitamin A analyses of liver, kidney and vitreous humor.....	69
Table 7. Summary of post mortem findings of examined harbor porpoises	70
Table 8. Summary table of CT scan results	71
Table 9. Spatial distribution of harbor porpoise strandings in Washington State - 1992-2003.....	51
Table 10. Harbor porpoise stranding events in Washington State - 1992-2003 (April-June).	52

APPENDICES

Appendix A. Sample Level A stranding form and completed forms for this investigation.....	74
Appendix B. Level A stranding forms for stranded harbor porpoises 2 May – 2 June 2003.....	75
Appendix C. Porpoise investigation team members.....	94
Appendix D. CT Imaging reports	98
Appendix E. Phocoenid strandings in British Columbia, Canada (April-May 2003).....	114
Appendix F. List of harbor porpoise stranding events in Washington State 1992-2002.	115
Appendix G. Marine mammal stranding events in Washington St. (1 April – 30 June 2003). ..	119

INTRODUCTION

On 5 May 2003 the naval vessel *USS SHOUP* operated its tactical sonar system (AN/SQS-53C) during a military exercise, while transiting the eastern Strait of Juan de Fuca and Haro Strait between Vancouver Island (Canada) and San Juan Island (US). NMFS received reports from witnesses who observed behavioral changes in several species of marine mammals on 5 May. Within several days of the exercise, a number of harbor porpoise (*Phocoena phocoena*) carcasses were found beach cast around the eastern Strait of Juan de Fuca. The reports of behavioral changes by whales during the exercise and the appearance of the dead porpoises on shore prompted NMFS to initiate an investigation to assess the cause of the porpoise strandings, including an assessment of acoustic trauma as a possible contributing factor. The activities of the *USS SHOUP* and the details of the 5 May 2003 sonar exercise are described in a report released by the U.S. Navy on 9 February 2004 (United States Navy, 2004).

To assist with NOAA's investigation, members of the Northwest Marine Mammal Stranding Network (Stranding Network) initiated efforts to respond rapidly to porpoise stranding reports and to collect carcasses from the beach. During a one month period from 2 May 2003 to 2 June 2003, the Stranding Network received a total of 15 reports of stranded harbor porpoises found dead, on the shore or floating, in the Strait of Juan de Fuca, along the outer coast, and in the vicinity of Whidbey Island and San Juan Island, Washington State (Figure 1; Table 1). The Stranding Network recovered three of the 11 porpoises examined in this investigation prior to 5 May, three on 5 and 6 May and the remaining five during the subsequent weeks. NMFS also received video footage labeled "porpoises and Navy Sonar 25 April 03". In light of these reports, all carcasses collected were thoroughly examined for potential links to sonar or other acoustic activities, including carcasses collected prior to 5 May. Basic information (Level A data; Appendix A) was collected from all 15 strandings (Appendix B). Specimen parts (whole bodies or heads) were collected from 11 of the stranded harbor porpoises. The collected specimens were frozen for subsequent close examination in the laboratory to investigate the causes of death and determine whether physical evidence of sonar or acoustic related injuries was present. In addition to recordings made on 5 May, hydrophone operators submitted audio files of sounds they identified as sonar, dated 9 December 2002, 24 April 2003 and 4 May 2003.

The observations on 5 May were highly publicized and resulted in heightened public concern that naval sonar activity may have contributed to the porpoise deaths. NMFS met with representatives from the Navy to discuss the whale observations, the porpoise strandings, the activities of the *USS SHOUP*, and hydrophone recordings received. Specifically, witnesses reported seeing avoidance behaviors by southern resident killer whales (*Orcinus orca*) and a minke whale (*Balaenoptera acutorostrata*) "porpoising" from the area as the vessel approached. Researchers operating hydrophones in Haro Strait recorded acoustic signals identified as sonar. NMFS received additional reports from witnesses that the sonar sound was audible above water.

NMFS assembled a multidisciplinary team of scientists and experts to conduct forensic post mortem examinations and to analyze the data for evidence of acoustic impacts

(Appendix C). The team from federal and State agencies, universities and research institutions included marine biologists, veterinarians, veterinary pathologists, research scientists and anatomists specializing in neuroanatomy, life history and trauma. NMFS contracted a local medical imaging company to obtain high resolution CT scan images from the carcasses.

This report represents the gross and microscopic findings from the necropsy examinations on each of the 11 specimens, laboratory analyses, and the analysis of the CT images data for each specimen scanned. Information on the discovery and collection of the stranded porpoises, and a comparison of this with porpoise strandings over the previous eleven years, is also presented. A preliminary report on this porpoise investigation was released by NMFS on 9 February 2004 for scientific review. Comments received were distributed to the team for discussion. The preliminary report was revised to address the comments, resulting in this final report.

MATERIALS AND METHODS

Network participants investigated 15 reports of individual harbor porpoise strandings and collected whole carcasses or heads from 11 porpoises that could be located based on information from initial sighting reports. Responders noted body conditions ranging from fresh dead to advanced decomposition when the specimens were collected in the field and obtained photographs of some carcasses. Attempts were made to verify initial carcass condition as described by the individual(s) who initially reported the stranding. The elapsed time from earliest known report date to examination/collection by a stranding network participant ranged from hours to several days. Therefore, carcass condition codes on the date of initial observation did not always correlate with the condition code at time of necropsy. Level A data were collected, but additional detailed information (*e.g.*, time of day and position of animal) at initial observation was not documented in a standardized fashion due to varied individuals responding to the strandings.

Upon collection, specimens (carcasses/heads) were assigned a field identification number (Field ID) by the stranding network responder, tagged and transported either directly to Seattle or to local freezers where they were held frozen (-20° F degree) pending later processing and necropsy (see Table 2 for listing of freezer types and specifications). Frozen specimens were transported from field locations and to/from the scanning facility in a truck mounted chest freezer to avoid thawing. Ultimately all specimens were transferred to and held at the NMFS/Alaska Fisheries Science Center/National Marine Mammal Laboratory (NMML) walk-in freezer for examination. This freezer was the only one with available space at NOAA. As each stranding report was received by NMFS, it was assigned a unique NMFS Registration Number. Registration Numbers do not always correspond to the chronological order in which animals have stranded, as these numbers are assigned when the Level A Stranding Reports arrive at the NMFS office in Seattle. A new tag with the NMFS Registration Number was attached to each carcass, and this number became the sole ID number used to identify specimens throughout the imaging and necropsy procedures (Table 1). Once the carcasses were

frozen, NMFS staff avoided thawing and/or re-freezing during subsequent handling until the specimens were prepared for post mortem examination.

The multidisciplinary team identified appropriate equipment and determined the protocols for conducting high resolution computerized tomography (CT scanning) and necropsies of the carcasses. In addition, a number of scientists involved in ongoing porpoise studies were contacted regarding protocols for collecting samples for their studies. A blind study approach was implemented during scanning, necropsy examination and data collection. The original Field ID tag remained with the carcass, but was covered by a taped bag so that the investigative team had no access to date and locality information. This helped prevent bias by team members during their investigation regarding locality and timing of strandings in relation to the *USS SHOUP* activities.

Six whole carcasses and two heads were selected by NMFS for scanning based on the following criteria: (1) date of stranding; (2) locality of stranding; and (3) carcass condition. The specimens with the best carcass condition were selected for scanning and represented a range of dates before, during and after 5 May. The selected specimens were transported in a truck mounted chest freezer to a local medical imaging facility, scanned on 20 July 2003 and returned to the NMML freezer. Scans were obtained at the scanning facility and formatted as a series as transaxial head and body images in both soft and bone windows using a spiral scan protocol. All scans were conducted with the body in a prone position, rostrum first. Images provided had variable slice thicknesses of 1-8 mm in bone and soft tissue protocols. The majority of scans were performed at 120 kV/250 MA. At the time of analyses, reformatted images were also produced, comprising soft tissue and bony windows of the head and body with expanded views of the brain and ear in transaxial, sagittal and coronal planes to optimize ear and brain detail from the available images. Three-dimensional reconstructions of some head structures were also produced (see Figures 21 and 32).

Following the scanning, carcasses were sorted and selected for thawing prior to necropsy based upon carcass condition. The “freshest” appearing carcasses were thawed for examination first. It was not always possible to standardize the position (*e.g.* same side down every time) of the carcasses during thawing; however, an attempt was made to try and consistently necropsy each carcass with the right side of the animal facing down against the table top.

Gross examination

A total of 10 porpoises were necropsied (the 11th specimen-a head only [03NWR05003]-was scanned, but determined to be too decomposed to provide useful data or samples during necropsy). Two to four carcasses at a time were thawed overnight in an aluminum casket filled with cold tap water. Data were collected and recorded on the Specimen Record, Evaluation of Human Interaction, Phocoena Mass Dissection, Cetacean Body Surface Area, and Blubber Thickness/Mass data sheets for general body examination and the Marine Mammal Sensory Group Cetacean Necropsy Report for examination of heads

and auditory structures. Collection of samples was tracked on a separate data sheet. All tissue and fluid samples that could be analyzed were obtained.

Comprehensive classical forensic and necropsy examinations were performed on each animal, including screening for pathogens, disease states and traumatic injury. On 22 July, the first two carcasses were removed from the thawing water and post mortem examinations were conducted according to prearranged protocols. On 23 July, necropsies were performed on four carcasses. On 24 July, the remaining four carcasses were necropsied. The severed head of specimen number 03NWR05008 was necropsied on 23 July. Descriptions of carcass condition (freshness of the carcass – Table 1) and body condition (nutritional status of the animal – Table 3) are described for each animal examined. Carcass condition codes were assigned based upon the Smithsonian Institution's codes for carcass condition: live (Code 1); fresh/good condition (Code 2); fair/moderately decomposed (Code 3); and poor/advanced decomposition (Code 4) (Geraci and Lounsbury, 1993). Each score is subjective, and discrepancies between codes at time of stranding response and at time of necropsy can occur because of (1) individual differences in that scoring process and (2) the difference in condition between the inside and the outside of the carcass. Post mortem scavenging, freeze artifact and autolysis hindered gross and microscopic tissue analysis of most specimens. Some protocols for data collection and sampling were conducted only on specimens of sufficiently high quality carcass condition.

Histopathology

During the necropsy examination, entire organs or parts were removed from the carcass to a clean area for examination. Tissues and samples for diagnostics and histology were collected according to standard necropsy protocols, fixed/preserved for analysis and distributed to labs under MMPA Permit Number 932-1489 and CITES Permit 3US020950/9. Brains were extracted and examined. Only those of sufficient quality were sampled for histopathology.

Age determination

Teeth were extracted from each specimen for age determination by sectioning and counting of growth layer groups (to be performed at NMML).

Blubber Analysis

Full-thickness blubber samples were taken for chemical contaminant and lipid analyses using gas chromatography/mass spectrometry (GC/MS) for a wide suite of persistent organic pollutants (POP), including PCB congeners, DDTs, hexachlorobenzene and chlordane (Table 4). POPs were extracted from blubber samples using an accelerated solvent extractor (ASE) (Sloan *et al.*, in prep). Lipid concentrations of the blubber samples were determined gravimetrically by measuring total non-volatile extractable material (reported as percent total lipids) (Sloan *et al.*, in press).

Other analyses

Other analyses included polymerase chain reaction (PCR) for Morbillivirus, *Brucella* and *Mycoplasma*, fecal floatation and sedimentation examination for parasitology, domoic

acid analysis of intestinal contents, stomach prey species analysis, aerobic bacterial cultures (Table 5), analyses of vitreous for blood urea nitrogen (BUN), calcium, phosphorous and magnesium and trace mineral analyses and vitamin A of liver and kidney (Table 6). As with samples for bacteriology, the suitability of samples for virus isolation was directly related to their quality and the freshness of the carcass. Viral culture was attempted in all specimens examined.

Photography

Photographs were taken at the time of carcass discovery by several different responders or volunteers. In addition, photographs were taken by several necropsy team members as directed by the individual conducting the examination at a given station. Several different research protocols were addressed simultaneously and some protocols had a standard photo format while others did not. Photographs were also taken to supplement the gross notes by examiners.

RESULTS

All animals had some degree of congestion, or red discoloration of the meninges, calvarium or cerebral surface, and in some cases of all abdominal tissues. This staining was attributed to postmortem autolysis and repeated freeze-thaw effects. This artifact hampered all gross and histological evaluation. Based on standardized carcass decomposition categories for the U.S. National Stranding Network (Geraci and Lounsbury, 1993), three porpoises were Code 2 (fresh dead), six were Code 3 (moderate decomposition) and the rest in Code 4 (advanced decomposition) at the time of necropsy. Individual cases are presented here in chronological order of stranding and not by sequential NMFS Registration Number. For each animal, comprehensive body composition data are listed in Table 3. Skeletal remains were retained for further study and tissue samples were archived at the Armed Forces Institute of Pathology and the Animal Health Centre in Abbotsford, B.C., Canada.

03NWR05001

History

This harbor porpoise was discovered dead floating off of Neck Point on Shaw Island (Figure 1) on 2 May 2003, collected and transferred to the University of Washington/Friday Harbor Lab (UWFHL) freezer on San Juan Island. The carcass was subsequently transferred to the NOAA/National Marine Mammal (NMML-32) freezer on 2 July 2003. No photograph of this animal at stranding was available.

Gross Findings

An immature 136 cm total length, 39 kg female harbor porpoise (*Phocoena phocoena*) was presented dead, 24 July 2003, in good body and fair post mortem condition. Throughout the flanks, there was extensive scavenger damage with no evidence of human interaction. Within the blubber and hypodermis of the mid-dorsal region of the melon, rostradorsal quadrant of the left eye and right mandibular fat pads, there were multiple variably sized dark red foci. Multiple superficial contact abrasions and lacerations were noted in the skin above the left eye and lower lip.



Figure 2 – Right lateral photograph of the head of porpoise 03NWR05001 at time of necropsy (24 July 2003) (Photo: B. Hanson).

The ventral fascial musculature and blubber were degraded. The oral cavity and nares contained a moderate amount of dark red, serous fluid and the larynx appeared normal.

Nervous system: In the central nervous system, a small amount of clotted blood surrounded the basioccipital region, left inferior temporal area and cervical spinal cord. The cerebral meninges were diffusely dark red and there was a moderate amount of dark red fluid beneath the pia and dura mater. Within the peribullar space of the right ear, there was an extensive accumulation of dark red gelatinous material (clotted blood).

Respiratory System: Diffusely, the lungs were dark red, moist and glistening (congestion), with a small amount of stable red foam within the trachea and bronchi. Widely dispersed throughout the pulmonary parenchyma, there were a few 1mm white calcified parasitic nodules.

Digestive system: The pancreas was dull brown to red with mild periductular fibrosis.

There were no overt lesions within the cardiovascular, endocrine, hemolymphatic, urogenital or musculoskeletal systems.

CT Findings

Cranial, thoracic and abdominal images were analyzed.

Cranial soft tissues: All soft tissues of the head were in relatively poor condition with some separation of tissue layers and multiple air pockets. The fatty layers on the right side of the head were noticeably degenerated. The soft walled narial passages were poorly defined and collapsed, but the sinuses were normal with good pneumatization.

Intracranial/brain: All skull features were normal and the brain was intact. There were extensive regions of extravasated fluid with an HU rating of 27-40 compatible with blood in the skull base and basioccipital regions with minor accumulations in the temporal areas. Cranial scans suggested broad post mortem degenerative changes with poor preservation of most structures. The intracranial spaces had moderate to extensive areas of fluid accumulation, consistent with post mortem seepage and dependent pooling of blood. There were no well-defined areas of hemorrhage, but due to poor tissue quality, it was not possible to differentiate pre vs. post mortem blood deposits. A small area in the mid-melon region appeared to be contused. The mandibular structures and head musculature were largely autolyzed and poorly preserved. There was no evidence of well-demarcated hemorrhage or contusion within the brain.

Eyes: Both eyes were present; however, the left globe was collapsed and the lenses were displaced ventrally in both eyes.

Peribullar region: There was an extensive soft tissue mass in the left medial peribullar space that had irregular, but well-defined margins and attenuation values consistent with peribullar parasites. The sinuses were well pneumatized. There was also minor clotting in the retrobullar spaces bilaterally.

Internal auditory canal (IAC)/Acousto-Vestibular/Facial Nerve: The internal auditory canals were well-defined with no evidence of blood or other abnormal material.

Middle ear: The middle ear cavities were normal with intact and normally configured ossicles and round windows. A small moderate density mass at the right window was consistent with a minor blood clot.

Inner ear: The canals were symmetrical and normal in appearance. There was no evidence in the available scans of abnormal intracochlear blood or other cochlear compromise.

Post-cranial features: Fatty tissues throughout the body were poorly preserved. Thoracic scans showed partial congestion and atelectasis of the right and to a much lesser extent, left lungs. There were few small, discrete, high density inclusions in both lungs consistent with calcified parasitic granulomas.

Gross and Histologic Diagnoses

- 1). Cerebrum, meninges: Congestion, multifocal, moderate.
- 2). Liver: Hepatitis, portal, mild, multifocal with biliary ductular hyperplasia and periductular fibrosis.
- 3). Ear, peribullar (Gross diagnosis): Hemorrhage, moderate, focally extensive with intralesional nematode parasites.
- 4). Lung: Bronchopneumonia, granulomatous and eosinophilic, multifocal, mild, with few adult and larval nematodes.
- 5). Skin, right mandible, dorsal to left eye, and labia (Gross diagnosis): Abrasions, moderate, multifocal.

6). Hypodermis, midmandible and melon: Contusions, multifocal, moderate (Gross diagnosis).

Comments and Conclusions

Postmortem scavenging, autolysis and freeze artifact hampered histological evaluation of examined tissues. Overt pathologies consistent with acoustic trauma were not apparent. The cause of death of this animal could not be determined. The body condition was good and based on the axial muscle mass, was considered within normal range (Table 3). The most significant necropsy findings included an organized clot around the spinal cord and basioccipital region, midmandibular and midmelon contusions, and dark red fluid beneath the cerebral meninges. Although extravasated fluid compatible with blood was noted grossly and in CT scans, there were no well-defined areas of hemorrhage in the intracranial spaces. Poor tissue quality precluded making any conclusions about pre or post mortem hemorrhage or extravasation. These changes are likely due to perimortem agonal thrashing; however, antemortem physical trauma cannot be ruled out.

Multisystemic parasitism is a common finding in wild porpoises and when mild, as in this case, it is not usually clinically significant. The pulmonary nematodes were most likely *Halocercus* spp and the hepatobiliary change was likely due to *Campula* spp.

Microbiology isolated light mixed growth of *Pseudomonas* spp, alpha *Streptococcus* spp, nonhemolytic *Escherichia coli* and heavy growth of *Clostridium perfringens* from the intestine, and either light mixed or solitary growth of *Pseudomonas* spp, nonhemolytic *E. coli* or *Acinetobacter johnsonii* from multiple internal viscera (Table 5). No *Salmonella* spp were isolated from the small intestine. Based on the lack of significant attendant inflammatory infiltrate and with the extent of autolytic change in examined tissues, these bacteria were considered post mortem invaders. Fecal floatation and sedimentation were negative for parasites. There was no detectable domoic acid within ingesta as determined by solid phase extraction (SPE) and analysis by high pressure liquid chromatography (HPLC). PCR of pooled lung, lymph node, spleen and brain was negative for Morbillivirus and consensus *Brucella* spp and follow up viral culture on Mabin Darby and Vero cell lines was negative. Trace mineral and vitamin A analysis of the liver and kidney were within normal reference limits (Table 6).

03NWR05003

History

This porpoise was reported stranded at County Park on Dungeness Spit (Figure 1) on 4 May 2003. A non-veterinary primary responder performed a cursory gross examination of the carcass and determined that this animal was pregnant with a fetus presumed to be in the third trimester. Only the head and fetus were collected and frozen. A CT scan was performed on the head, but it was not examined further during the necropsy session due to advanced decomposition. No photograph of this animal at time of stranding was available.

CT Findings

Only cranial images were produced for this animal. The head was decapitated at the occiput and was heavily flensed.

Cranial soft tissues: The majority of soft tissues were removed on the right and dorsal surfaces of the head, including all dermis, fats, and musculature. The remaining tissues were in poor post mortem condition. The left mandibular fats, like the brain, had extensive areas of fissures and granular, crystalline regions that were indicative of freeze-thaw artifact that compromised the tissues. The narial passages were filled with high contrast material and could not be assessed. The sinuses were partially occluded with poor pneumatization.

Intracranial/brain: The skull was intact except for the right parietal region which was disrupted. A bone fragment penetrated deep into the right parietal and temporal lobes of the brain and lodged adjacent to the right lateral ventricle. The lack of brain density changes in this area suggested post mortem trauma. The brain was intact and had a uniform granular appearance, consistent with extensive freezer artifact and the effects of freeze-thaw cycles. The brain was severely autolyzed.

Eyes: The right eye was missing and the left globe was collapsed.

Peribullar region: The spaces were essentially normal bilaterally for an animal in this severe state of decomposition.

Internal auditory canal/Acousto-vestibular/Facial nerve: The internal auditory canals were normal with partial degeneration of cranial nerves VIII and VII.

Middle ear: The ossicles were intact and normally configured bilaterally, and the round and oval windows were intact.

Inner ear: The canals were symmetric and normal.

The head was mostly denuded of soft tissues, and the remaining tissues exhibited signs of freeze-thaw artifact which compromised tissue quality. There were broad post mortem degenerative changes with poor preservation of most structures. Although there was no evidence in these scans of abnormal intracochlear blood or other cochlear compromise, the poor state of preservation made conclusions about the health of these ears impossible.

03NWR05005

History

This harbor porpoise was initially observed on 4 May 2003 wrapped in a fishing net (Figure 3) on Jackson Beach, San Juan Island (Figure 1). The carcass was collected on 5 May and stored in the UWFHL freezer, then transferred to the NMML- 32 freezer on 2 July 2003.



Figure 3 – Porpoise 03NWR05005 showing initial presentation of animal entangled in a fishing net (4 May 2003) (Photo: Whale Museum).

Gross Findings

An immature 126 cm total length, 33.5kg (does not represent true body mass due to extensive scavenger damage and post-mortem condition) female harbor porpoise was presented dead, 24 July 2003, in good body and fair post mortem condition (Figure 4). The right side of the carcass had extensive scavenger damage that extended deep to the blubber and on the left dorsolateral aspect of the mid caudal peduncle, there were small superficial scavenger bite marks.



Figure 4 – Right lateral photograph of porpoise 03NWR05005 at time of necropsy (24 July 2003). Due to lack of cutaneous net impressions, the entanglement was considered post mortem. The loss and fissuring of skin along the lateral aspect of the flank is attributed to post mortem decomposition and desiccation (Photo: B. Hanson).

Tubercles were present along the leading edge of the dorsal fin. The right eye was absent and the right mandibular fat pad avulsed by scavenging. Throughout the head and fascial region, there were extensive cutaneous abrasions; the left mandibular fat and underlying mandibular and rostral periosteum and bone were dark red. The periosteum was widely separated from the body of the mandible.

Nervous system: The inner aspect of the calvarium and cerebral surface were diffusely dark red (Figure 5). At the level of the occipital condyles, the dorsolateral aspects of the spinal cord were invested with a moderate amount of dark red gelatinous material. A few nematodes were present in the left peribullar space with accompanying hemorrhage. No parasites were apparent in the contralateral peribullar space.

Digestive system: Within the porta hepatis, a sparse number of subcapsular bile ducts were variably dilated by trematodes interspersed within small to moderate amounts of black mucoid deposits. Serial sections of the pancreas disclosed mild periductular fibrosis. A small number of nematodes were noted within the first compartment of the stomach. There was a moderate amount of chyme throughout the mesenteric lymphatics.

Respiratory system: The left lung was mottled dark red to pink and slightly depressed with few intervening light pink areas. Pink froth was present within the lumen of major bronchi.

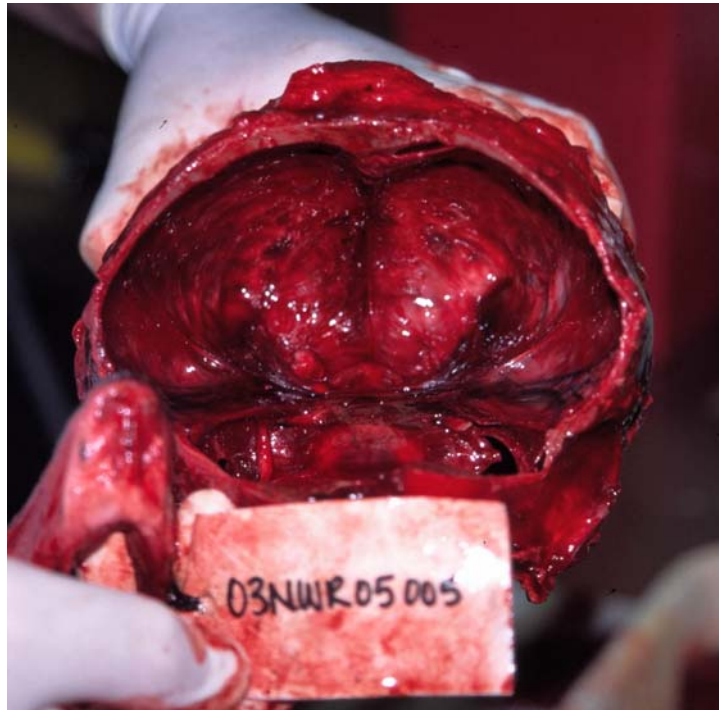


Figure 5 – Porpoise 03NWR05005 – The calvarium has been removed and the superficial aspect of the brain exposed. Note the diffuse red black discoloration of the superficial aspect of the brain. This change is associated with freeze artifact and post mortem decomposition (Photo: B. Hanson).

There were no apparent lesions within the cardiovascular, urogenital, hemolymphatic, musculoskeletal or endocrine systems.

CT Findings

This animal was not scanned.

Gross and Histologic Diagnoses

- 1). Cerebrum, meninges; mandibular fat pad; peri-spinal fat; larynx, fibroadipose tissue and periosteum: Congestion, multifocal, moderate.
- 2). Cerebrum: Meningoencephalitis, lymphocytic, multifocal, mild.
- 3). Liver: Cholangiohepatitis, granulomatous and eosinophilic, multifocal, moderate, with biliary ectasia, periductular fibrosis and many trematode eggs and adults.
- 4). Lung: Bronchopneumonia, granulomatous and eosinophilic, multifocal, mild, with many nematodes.
- 5). Peribullar space, left (Gross diagnosis): Hemorrhage, mild, focally extensive, with intralesional nematodes.

Comments and Conclusions

Autolysis, freeze artifact and post mortem scavenging impeded gross examination and microscopic assessment of multiple tissues. Although this animal was wrapped in a net on initial recovery, the lack of cutaneous (web) impressions suggests that this entanglement likely occurred post-, rather than antemortem. Based on Read and Murray (2000), animals caught in large-mesh multifilament net exhibit mutilated appendages; however, this animal did not exhibit any external signs of being caught in gear. The animal was robust and had no other evidence of trauma, which is consistent with, but not diagnostic of death in fishing gear. Therefore, the cause of death is uncertain. Cytology of the frozen lung airways failed to reveal any algae suggestive of agonal salt water aspiration. Based on a higher than normal blubber mass and despite slightly reduced axial muscle component this animal was graded in good body condition (Table 3). The extensive areas of cutaneous abrasion along the left side of the head were consistent with contact, movement along rough substrates, and scavenger attacks. Subjacent to the abraded areas, there was multifocally extensive congestion of left lateral jaw fats, consistent with an agonal or terminal process. The nares were clear with no sign of contusion or hemorrhage. The grossly noted discoloration of the brain and calverium was due to post mortem autolysis and freeze-thaw artifact within the superficial neuropil (Figure 5). There was no microscopic indication of acute hemorrhage in the examined brain sections. The mild meningoencephalitis was nonspecific and would not likely have been clinically significant. The multisystemic parasitism (retrobullar, hepatic, pulmonary and enteric) in this animal is commonly observed in wild harbor porpoises. The biliary parasites were most likely *Campula oblongata* and would not have contributed significantly to impaired liver function. The lungworm infection was low grade and likely due to *Halocercus* spp and the unilateral, peribullar nematodes were morphologically consistent with *Stenurus* spp. The gastric nematodes were most likely *Anisakis* spp. In published case reports of harbor porpoise parasitism, infection is commonly recognized (Raga *et al.*, 2002). Aerobic culture yielded light variable mixed growth of *Aeromonas hydrophila*, *Enterobacter* spp, *Pseudomonas* spp from multiple

internal viscera and heavy growth of *Clostridium perfringens* from the intestine (Table 5). No bacteria were isolated from the urine or kidney and fungal culture of the lung and lymph nodes was negative. Based on the extent of decomposition and lack of attendant inflammatory infiltrate in select tissues, these bacterial isolates were most likely post mortem invaders. With the exception of calcium values, trace mineral analysis of the liver and kidney proved within normal reference limits (Table 6). The increased liver calcium levels were likely due to dystrophic mineral deposition associated with the chronic cholangiohepatitis and the markedly reduced vitamin A values were presumably related to the extent of autolysis. Interpretation of the eye fluid analysis results was hindered due to the lack of available normal data in this species; based on extrapolation from terrestrial mammals, the calcium, magnesium, phosphorus and BUN appeared elevated and these increased values most likely represented post mortem change (bacterial overgrowth, putrefaction), blood contamination, or less likely, systemic homeostatic derangements associated with impaired renal function. The cause of death of this animal was not evident.

03NWR05006

History

This porpoise was found and collected at South Beach on San Juan Island (Figure 1) on 5 May 2003 and stored in the UWFHL freezer with subsequent transfer to the NMML-32 freezer on 2 July. No photograph of this animal at time of stranding was available.

Gross Findings

An adult 152 cm total length, 48.5 kg female harbor porpoise with moderate reproductive activity (corpora lutea in ovaries) was presented dead, 23 July 23, 2003, in moderate body (Table 4) and in very poor post mortem condition (Figure 6). The epidermis was missing throughout the ventrum and along the left flank. Extensive abrasions were present throughout the external surface of the head with gravel and debris filling the laryngeal cavity, esophagus and nares. The ventral fats and musculature of the head were degraded.

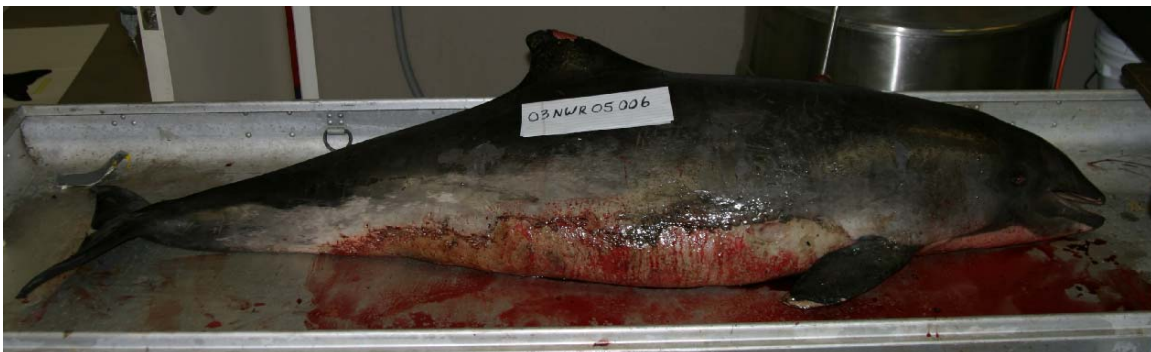

Figure 6 – Right lateral photograph of porpoise 03NWR05006 at time of necropsy (23 July 2003) (Photo: B. Hanson).

Nervous system: There was dark red fluid within the subdural space, and the basioccipital bone was dark red. Within the right retrobullar and peribullar spaces, there

was a moderate amount of dark red fluid. There was a moderate amount of congestion of the cerebrum with red discoloration of the surface and subdural pooling of dark red fluid.

Respiratory System: The lungs were homogeneously dark red (congestion), with a few scattered 1 mm hard white foci throughout the parenchyma. There was a small amount of red foam within the airways.

Cardiovascular System: There was a moderate amount of fat surrounding the coronary arteries.

Digestive System: There was a moderate amount of sand throughout the oral cavity. The pancreas and intestines are autolyzed. The liver had two firm, 2-3 cm, well delineated black to red areas on the capsule. Bile ducts in the underlying parenchyma were ectatic with thick walls. There were a few trematodes within the lumen. Within the nonglandular compartment of the stomach there was a 3 x 2 x 1 cm raised area with a few crateriform ulcers containing 30-40 attached nematode parasites (*Anisakis* spp) while the forestomach contained 2,000-3,000 free-floating nematodes.

Significant lesions were not apparent in the urogenital, endocrine, musculoskeletal and hemolymphatic systems.

CT Findings

Cranial, thoracic and abdominal images were analyzed.

Cranial soft tissues: A majority of tissue suites were intact, but in relatively poor condition. The right mandibular fats were well-defined, and the left lateral fats subjacent to the abraded skin had mid-low density regions suggestive of either congestion or extravasated blood.

Intracranial/brain: The skull appeared normal. The brain was intact, but subregions were poorly defined, suggesting moderate to severe autolysis. There were extensive areas of extravasated fluid with a HU density compatible with blood in the subarachnoid and subdural regions. As the meningeal divisions were poorly defined, determination of the precise fluid distribution was not possible.

Eyes: Both eyes were present; however, the left globe was collapsed and the lens was absent. In the right eye, the lens was displaced ventrally.

Right ear: There was an extensive soft tissue mass in the right dorsal peribullar space that was consistent with an organized clot. The internal auditory canal was well-defined with no evidence of blood or other abnormal material. Cranial nerves VIII and VII were normal. The middle ear cavity, ossicles and round window were normal (Figure 7). There was a minor blood deposit at the right round window.

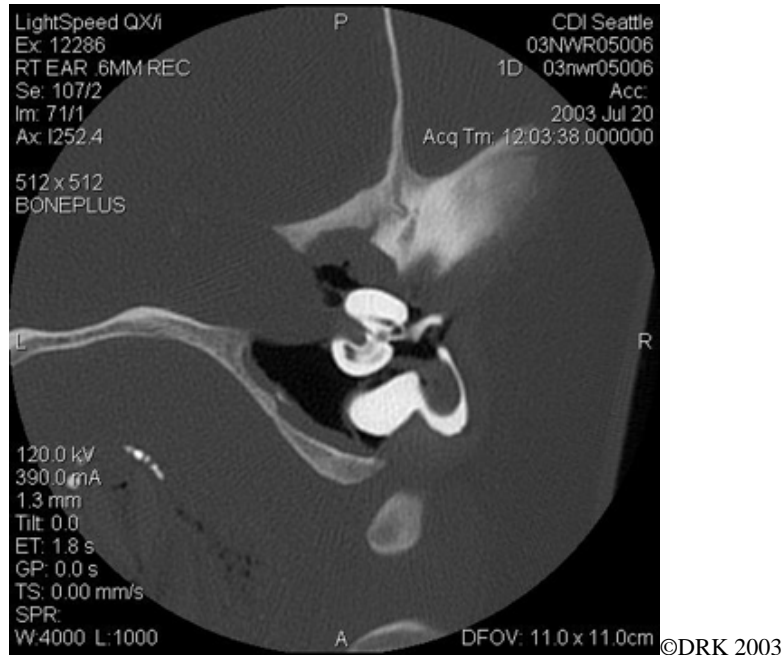


Figure 7 – CT scan image at level of ossicles of right rear (03NWR05006) (Image: D.R. Ketten).

Left ear: The peri and retrobullar spaces were normal. The left tympanic bone was possibly partially demineralized. The internal auditory canal was normal as were cranial nerves VIII and VII. The middle ear cavity, ossicles, and round and oval windows were normal.

Post-cranial features: There were extensive abrasions across most of the body. Thoracic scans showed both lungs were collapsed and congested, with the right lateral lung more compromised than the left. There were substantial numbers (50-100) of small, high density parasitic nodules which were most evident in the anterior lobes of both lungs.

Gross and Histologic Diagnoses

- 1). Colon: Colitis, subacute, multifocal, transmural, moderate, with peritonitis.
- 2). Lymph node: Lymphadenitis, subacute, multifocal, moderate, with lymphoid hyperplasia.
- 3). Lung: Bronchopneumonia, granulomatous and eosinophilic, multifocal, moderate, with many adult nematodes and larvae.
- 4). Forestomach: Gastritis, proliferative and ulcerative, lymphocytic and eosinophilic, focally extensive, moderate, with few adult nematodes.
- 5). Liver: Cholangiohepatitis, granulomatous and eosinophilic, multifocal, mild, with biliary ectasia, periductular fibrosis and many trematodes.
- 6). Ear, peribullar (Gross diagnosis): Hemorrhage, moderate, focally extensive with intralesional nematode parasites.

Comments and Conclusions

Although post mortem change hindered microscopic assessment of multiple tissues and precluded evaluation of select segments of bowel, death was likely attributed to

salmonella septicemia. *Salmonella Newport* Group C2 was cultured from the lung, hilar lymph node, kidney, spleen, liver, thymus, mesenteric lymph node and small intestine (Table 5). The pulmonary alterations observed in the right lung on thoracic CT scans were compatible with the gross and histological findings of bronchopneumonia. A review of the literature disclosed a small number of previous case reports of *Salmonella enterica* (antigenic formula 4,12:a:-) in harbor porpoises (*Phocoena phocoena*) in Scotland (Foster *et al*, 1999); however, salmonellosis is more commonly identified in sea otters, harbor seals and captive walruses (Calle *et al*, 1995; Thornton *et al*, 1998). In an overview of marine mammal disease surveillance findings in Los Angeles (Schroeder *et al*, 1973), there was a single case report of *Salmonella Newport* in a California sea lion and in a subsequent publication, this serotype was identified in one of four and two of 18 (the latter consisting of both *Newport* and *Montevideo*) California sea lions at a rehabilitation facility in 2002 (Smith *et al*, 2002). These bacteria are highly adapted to a number of human and animal hosts that may present with a wide variety of lesions, such as a gastroenteritis or generalized septicemia. The precise source of the bacteria in this case is unknown. Some serotypes of *Salmonella* are capable of survival and propagation in salinity as high as 3.5%. Based on the transmural inflammatory infiltrate within segments of intestine, infection was most likely *per os* with subsequent intestinal colonization, proliferation and invasion. PCR of pooled lung, lymph node, spleen and brain was negative for Morbillivirus and consensus *Brucella* spp and follow up viral culture on Mabin Darby and Vero cell lines was negative. Chemical analysis of the intestinal contents was negative for domoic acid. Histopathology confirmed the grossly noted pulmonary, hepatic and gastrointestinal parasitism and revealed an intermediate grade enteritis, lymphadenitis and peritonitis. Fecal floatation and sedimentation disclosed a moderate number of gastrointestinal nematodes and sedimentation was unremarkable for trematode parasites. This intensity of parasitism is commonly identified in porpoises. Due to the extent of post mortem decomposition and scavenging, an accurate assessment of the body condition could not be made (Table 3). Trace mineral and vitamin A analysis of the liver and kidney were within normal in house reference limits (Table 6). No overt lesions consistent with acoustic trauma were noted on the CT scans. Although there were no well-defined regions of hemorrhage in the intracranial spaces, the poor tissue quality precluded precise determination of deposition. The ears were poorly preserved, but essentially normal bilaterally.

03NWR05007

History

This porpoise was initially observed and collected at Dungeness Spit (Figure 1) on 6 May 2003, stored in the USFWS/Dungeness National Wildlife Refuge freezer and then transported to the NMML-32 freezer on 2 July 2003. No photograph of this animal at time of stranding was available.



Figure 8 – Left lateral photograph of porpoise 03NWR05007 at time of necropsy (22 July 2003) (Photo: J. Gaydos).

Gross Findings

A 145.5 cm total length, 38.5 kg, immature female harbor porpoise was presented 22 July 2003 in good physical condition. Initial carcass condition was coded as 4+, but the internal exam revealed that the deep tissues were in moderate post mortem condition (Figure 8). There were ample subcutaneous and abdominal adipose stores and the animal was well muscled (Table 3). Extending from the mid thoracic region to insertion of the peduncle, along the left ventrolateral aspect of the torso there was multifocally extensive post mortem scavenging. Along the left lateral aspect of the mid thoracic region, there were three small, well-circumscribed circular scars. Throughout the right flank, there was variably extensive subcutaneous congestion and dependant stasis. Along the dorsolateral aspects of the peduncle, there were multiple 0.6-0.8 cm diameter superficial aggregates of diatoms. On incision of the subcutaneous tissue adjacent to both mammary glands, approximately 2 ml of tan orange, glistening viscous material exuded and within the lumen of the main mammary ducts, there was a solitary 3-4 cm long nematode parasite. Within the perineum, a small number of nematodes were widely dispersed throughout the subcutis.

Respiratory system: The right and to a much lesser extent left lung lobes were mottled light pink with variably sized intervening, mildly depressed dark red areas. There was moderate visceral pleural fat accumulation. A small amount of stable pink froth was present within the bronchi.

Digestive system: Within the hilar region of the liver, there were moderate accumulations of trematode parasites. The glandular compartment of the stomach was contracted and empty. Along varying levels of the pancreas, between 5-35% of the ductules were circumscribed by thin to moderately thick margins of fibrous connective tissue.

There were no apparent lesions within the cardiovascular, urogenital, nervous, musculoskeletal, or hemolymphatic systems.

CT Findings

Cranial, thoracic and abdominal images were analyzed.

Cranial soft tissues: All the tissues were in moderate to poor condition. The nares and oral cavity were filled with high density material attributed to sediment and sand. Both sinuses were partially opacified with the right more compromised than the left and containing some relatively high density material.

Intracranial/brain: The skull, cerebellum and midbrain were normal in appearance. In the subtemporal region of the brain, there were mid to low density accumulations that were consistent with pooled extravasated blood (Figure 9).

Eyes: The left globe was enucleated, but the right was present.

Peribullar region: The regions were clear and well aerated bilaterally with well-defined ligaments.

Internal auditory canal/Acoustic-vestibular/Facial Nerve: No indication of blood or other abnormal material was present. Cranial nerves VIII and VII nerves were intact but degenerated.

Middle ear: The cavities, ossicles and round windows were normal bilaterally.

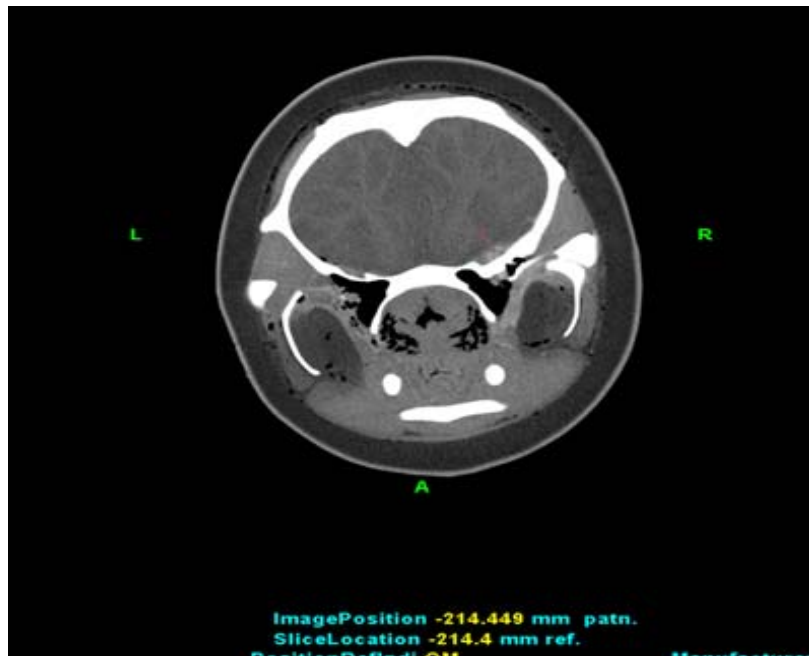


Figure 9 – CT scan image demonstrating mid to low density structures in the subtemporal region (03NWR05007) (Image: D.R. Ketten).

Inner ear: The canal structures were symmetrical and normal in appearance. In both ears, there were minor mid attenuation deposits consistent with intracochlear blood.

Post-cranial features: Thoracic scans showed that the cranioventral lung lobes were congested and collapsed bilaterally, with the right more extensively affected than the left.

Both lungs had multiple high density nodules or calcified cysts consistent with parasitic pneumonia.

Gross and Histologic Diagnoses

- 1). Cerebrum, meninges and larynx: Congestion, diffuse, moderate.
- 2). Heart: Myocarditis, granulomatous and eosinophilic, multifocal, mild.
- 3). Liver: Cholangiohepatitis, granulomatous and eosinophilic, multifocal, moderate, with biliary ectasia, periductular fibrosis and many trematode eggs.
- 4). Lung: Bronchopneumonia, granulomatous and eosinophilic, multifocal, mild, with nematode adults and larvae.
- 5). Mammary gland: Mastitis, lymphocytic and eosinophilic, chronic, multifocal, mild.
- 8). Pancreas: Fibrosis, periductular, mild, multifocal, chronic.
- 9). Skin, right flank: Dermatitis, mild, multifocal, chronic (resolving scars) (Gross diagnosis) with hypodermal nematode parasites.
- 10). Skin, left ventrolateral thorax: Laceration, mild, focal, subacute (Gross diagnosis)
- 11). Ear, intracochlear: Presumptive hemorrhage, mild, multifocal.

Comments and Conclusions

There were no overt lesions within the examined tissues that would account for the death or stranding of this animal. Close evaluation of the oropharyngeal, peribullar and periorbital spaces failed to reveal any lesions consistent with an acoustic related trauma, and microscopic assessment of the larynx disclosed only low-grade mucosal erosion and congestion. Gross examination disclosed multifocal areas of pulmonary congestion which may have accounted for the CT findings. The cause of the myocarditis is not evident. Parasitism is a consideration due to the eosinophilic inflammation. However, it is mild and likely clinically insignificant. The ears were normal bilaterally by CT scan with some increased density in the cochlear canal consistent with intracochlear blood. Gross examination of the nares did not reveal any luminal deposits and the composition of the high density foreign material detected by CT scan is unknown. The scars noted along the right lateral aspect of the cranial thoracic cavity likely represented a long past traumatic or infectious process and appeared restricted to the superficial dermis. Cytology of the punctate, orange mucoid cutaneous deposits revealed numerous diatoms. Epidermal diatoms have previously been reported in Dall's porpoises (*Phocoenoides dalli*) in the Northern Pacific Ocean and are considered incidental findings (Holmes *et al.*, 1993). Trace mineral and vitamin A analysis of the liver and kidney proved largely within normal reference limits (Table 6); increased liver calcium is likely related to post mortem mineral deposition or chronic inflammatory associated with the liver flukes. Examination of the aqueous humor disclosed significantly increased phosphorus and blood urea nitrogen relative to terrestrial animal values. Efforts are ongoing to determine normal reference values for small cetaceans and based on the lack of associated change within the examined tissue and degree of post mortem change, interpretation of these data is hindered; abnormalities with phosphorus levels may be associated with lactation or some other disease processes. Cytologic evaluation and bacterial culture of the grossly noted mammary gland discharge revealed abundant vacuolated and proteinaceous background with scattered exfoliated cuboidal and squamous epithelia, histiocytes, lymphocytes and fewer neutrophils with small numbers of extracellular cocci and bacilli.

Histopathology disclosed a low grade, chronic inflammatory process presumably due to intra- and periductular nematode parasites. These parasites were morphologically consistent with *Crassicauda* spp; although the intensity of infection may have interfered with normal lactation, this burden is not considered pathologically significant. The bile duct parasites were most likely *Campulla* spp and the lungworms were presumably *Halocercus* spp. Multisystemic parasitism is commonly identified within wild stranded harbor porpoises and in this animal, cumulatively would not have contributed significantly to antemortem morbidity. Fecal floatation and sedimentation were negative for parasites. Aerobic culture of the milk isolated light growth of nonhemolytic *Streptococcus* spp and light mixed growth of *Pseudomonas fluorescens* and *Enterobacter* spp from the lung (Table 5). Based on the extent of post mortem change and lack of significant inflammatory infiltrate, these bacteria were likely post mortem contaminants. Aerobic culture of multiple internal viscera, including brain, mammary gland, spleen, spinal cord, rectal swab, thymus and thoracic fluid, yielded light growth of *Enterobacter* spp with no bacteria isolated from the kidney, urine, or liver (Table 5). Special culture for fungi and *Salmonella* spp were negative. In two of six sections of pancreas, the fibrotic scores were 5 and 35 percent. Analysis of intestinal contents for domoic acid was negative.

03NWR05008

History

This animal was first reported stranded on 6 May 2003 on Discovery Trail at Ennis Creek (Figure 1). The head was removed, collected for examination and delivered to the NMML-32 freezer on 9 May 2003 (Figures 10 and 11). The remainder of the carcass re-floated and was later retrieved on 16 May.

Gross Findings

The head of this adult male was presented on 22 July 2003 in poor post mortem condition (Figure 12). Throughout the head, there was extensive deterioration of blubber and fat pads. The melon was clear. Within the superficial mandibular fat pads, there was variable congestion and the deep pads were clear. Multifocal blubber degeneration and autolysis was noted subjacent to bird scavenging. A moderate number of (7-10) teeth were missing from the right mandible. The right eye was ruptured and collapsed (scavenged) and the left eye was autolytic. The remainder of the porpoise, 146 cm truncated length, approximately 40 kg and with minimal reproductive activity, was presented 24 July 2003, in fair to moderate physical condition and poor post mortem state (Figure 13). The animal was fairly fleshed. Along the left lateral aspect of the mid thoracic and cranial abdominal region, there was focally extensive loss of the skin, blubber and scapula with maceration of the subjacent intercostal muscles. Within the inguinal region, there were a moderate number of subcutaneous and hypodermal calcified parasites.

Digestive system: Throughout the abdominal cavity, involving numerous loops of small intestine as well as the peritoneum and serosal surface of multiple viscera, there were



Figure 10 – Left lateral photograph of head of porpoise 03NWR05008 three days (9 May 2003) after initially reported stranded (Photo: Olympic Coast National Marine Sanctuary).



Figure 11 – Head-on photograph of left lateral side of porpoise 03NWR05008 three days (9 May 2003) after stranding was initially reported, demonstrating the extent of scavenger damage (Photo: Olympic Coast National Marine Sanctuary).



Figure 12 – Left lateral photograph of head of porpoise 03NWR05008 at time of necropsy (22 July 2003) (Photo: D. Ketten).



Figure 13 – The remainder of porpoise 03NWR05008 at time of necropsy (24 July 2003) (Photo: B. Hanson).

multifocally extensive adhesions which were readily reduced by digital manipulation; on exposed surface, the serosa was finely granular.

There was moderate enlargement of the mesenteric lymph nodes. Multifocally within the liver, bile ducts were dilated with thickened walls and contained trematodes.

Urogenital system: The kidneys were detached from the peritoneal surface and free within the dorsal peritoneal cavity. Within the right epididymis, immediately dorsal to the testes, there was a 2 cm diameter, firm, nodule with multiple adhesions to the surface of the testes; on incision, there were abundant amounts of pale yellow white mucoid material bound by a moderately thick capsule.

Respiratory system: Bilaterally, the lungs were collapsed and the dorsal visceral pleura overlaid by abundant amounts of small pebbles and stones. On incision of the trachea and extending throughout the virtually the entire length of the caudal bronchi, the lumen contained a moderate amount of small stones. Within the lumen of the nasopharynx and nares, there were a moderate number of nematode parasites.

Nervous system: At the level of cervical vertebrae 1 and 2 segmentally overlying the left ventral aspect of the spinal cord, there was a small amount of dark red gelatinous material. Interspersed within a small amount of blood, within the left peribullar region, there were moderate accumulations of nematodes. Smaller numbers of nematodes were noted in the right retrobullar area.

There were no apparent lesions within the musculoskeletal, hemolymphatic, cardiovascular, or endocrine systems.

CT Findings

Only cranial scans were conducted. The head was decapitated at the level of the occiput. Readings suggestive of degenerated tissues were observed as well as large deposits of high density material in the airways and esophagus, attributed to sand and sediment.

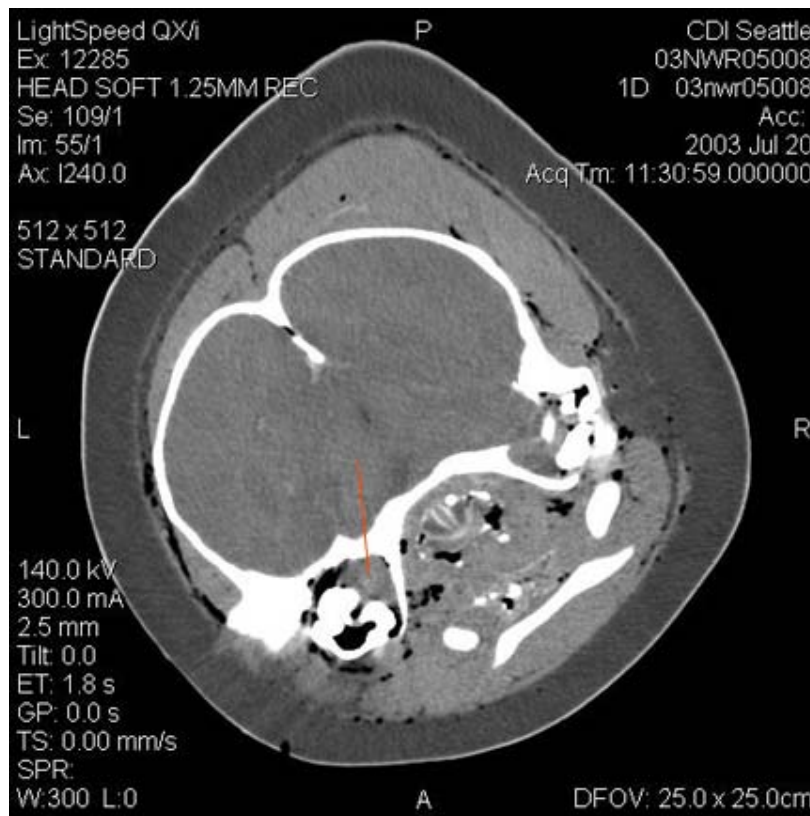


Figure 14 – CT scan image of 03NWR05008 at level of the tympano-periotic bone illustrating a tissue mass medial to the left tympano-periotic bone (orange arrow just below center of image) (Image: D.R. Ketten).

Cranial soft tissues: High density, mixed material occluded the lumen of the left and to a much lesser extent the right nares, particularly the left sac.

Intracranial/brain: The skull features were normal. The brain was relatively uniform in appearance, suggestive of poor preservation.

Eyes: The left eye was intact, and the right eye was present and the lens was displaced ventrally.

Peribullar region: The sinuses were generally clear bilaterally. A substantial, well-defined mass of tissue was present medial to the left tympano-periotic bone with a similar, but smaller mass, on the right which were both consistent with bundled parasites (Figure 14).

Internal auditory canal/Acousto-vestibular/Facial nerve: The IAC, retrobullar areas, and cranial nerves VIII and VII were normal bilaterally.

Middle ear: The cavities, ossicles, as well as round and oval windows were normal bilaterally.

Inner ear: The canals and intracochlear fluids were normal in both ears.

Gross and Histologic Diagnoses

- 1). Intestine; liver and kidney: Serositis and capsulitis, fibrinous, multifocal, mild, with many bacilli and few cocci.
- 2). Epididymis: Abscess, focal, moderate, chronic, with nematode eggs.
- 3). Liver: Cholangiohepatitis, granulomatous and eosinophilic, multifocal, moderate, with biliary ectasia, periductular fibrosis and many trematodes.
- 4). Lung: Bronchopneumonia, eosinophilic and granulomatous, multifocal, moderate, with nematodes.
- 5). Blubber, inguinal region: Steatitis, moderate, multifocal, granulomatous, chronic with intralesional parasites (Gross diagnosis).
- 6). Peribullar space: Hemorrhage, mild, focally extensive, with abundant intralesional nematodes (Gross diagnosis).

Comments and Conclusions

Profound post mortem decomposition impeded microscopic assessment of multiple tissues and precluded gross and microscopic assessment of the larynx and adjoining oropharyngeal tissue. The widespread serositis and peritonitis likely contributed to death of this animal. Lesions indicative of acoustic related injury were not evident. The CT analysis of this animal's brain, melon, skull, and ears was considered within normal limits for an animal of this code. Adequate nutritional assessment of this animal was hindered due to the extent of post mortem decomposition and scavenging (Table 3). Aerobic bacterial culture isolated light variable mixed growth of alpha *Streptococcus* spp, nonhemolytic *Escherichia coli*, *Enterobacter* spp and less frequently *Aeromonas hydrophila* from multiple internal viscera, including the epididymis (Table 5). Based on

the extent of putrefactive change, it was difficult to resolve the precise contribution of any of these bacteria to the grossly noted peritonitis. The possibility of post mortem bacterial overgrowth and loss of a more fastidious pathogen could not be discounted. Histopathology of the epididymal abscess revealed numerous larvated nematode ova interspersed within abundant amounts of mineral deposition that was peripherally circumscribed by dense bands of fibrous connective tissue. The ova were suggestive of *Crassicauda* spp and were considered an incidental finding. No significant pathogens were isolated by routine culture of the epididymis and the abscess was negative for *Brucella* spp by polymerase chain reaction. The hepatobiliary (*Campula* spp), peribullar (*Stenurus* spp), pulmonary (*Halocercus* spp), gastric (*Anisakis* spp) and subcutaneous (*Crassicauda* spp) parasitism are commonly observed in wild porpoises; no parasites were identified by fecal floatation or sedimentation. No fungi were isolated from lung tissue. Trace mineral and vitamin A analysis of the liver and kidney proved within normal reference limits (Table 6). The small amount of clotted blood surrounding the cervical spinal cord was likely associated with agonal struggling. The avulsed left eye and cutaneous defects within the fascial region were attributed to post mortem scavenging.

03NWR05010

History

This porpoise was initially reported stranded on 13 May 2003 at Admiralty Head on Whidbey Island (Figure 1). At the time, the carcass was fresh with little superficial damage, but blood was found in both eyes, the nares and oral cavity (Figure 15). On the morning of 14 May, a portion of the head and right side of the body were scavenged (Figure 16). The carcass was wrapped in plastic and transferred to NMML-32 that evening.

Gross Findings

An adult, 154 cm total length, approximately 55 kg, harbor porpoise was presented dead, 24 July 2003 in fair body condition. Initial carcass condition was coded as a 3+, but the internal exam revealed that the deep tissues were in a more advanced state of decomposition (code 4) (Figure 17). Throughout the ventrum, there was widespread bird damage. From the ventral aspect of the left mandible to the mid thoracic region, there is focally extensive loss of skin and blubber with exposure of the ribs and intracostal musculature (post mortem predation). Along the leading edges of the fluke and flippers, there was extensive loss of epidermis. There was a 10x12 cm dark red, edematous area on the left abdominal wall that extended from the blubber moderately deep into the underlying muscle. Both mandibular fat pads were stained red, the left darker than the right. Both peribullar sinuses contained hundreds of nematodes.

Nervous system: The left occipital crest was fractured. Along the fractured margins, the dura was dark red and separated from the underlying bone by dark red fluid. The internal surface of the calvarium and superficial aspect of the brain were diffusely dark red and the meninges were overlaid by a small amount of dark red fluid.

Respiratory system: The lungs were diffusely dark red and congested with rare 1 mm calcified white nodules. There was a small amount of dark red fluid in the airway.

Digestive system: Within the liver hilus, there were a few firm 1-2 cm diameter irregular subcapsular bile ducts that were moderately dilated by trematode parasites and black green tenacious material.



Figure 15 – Right dorsolateral photograph of initial stranding of porpoise 03NWR05010 on 13 May 2003 (Photo: S. Dubpernell).



Figure 16 – Right lateral photograph of 03NWR05010 the morning of 14 May 2003, showing extensive scavenger damage to head and thorax (Photo: S. Dubpernell).



Figure 17 – Right lateral photograph of 03NWR05010 at time of necropsy (24 July 2003) (Photo: B. Hanson).

Bile ducts within this area had thickened walls. The pancreas was autolyzed and there was no indication of periductular or interstitial fibrosis.

There were no apparent lesions within the urogenital, endocrine, hemolymphatic or cardiovascular systems.

CT Findings

This animal was not scanned.

Gross and Histologic Diagnoses

- 1). Bone, left occipital crest: Fracture, focally extensive, with hemorrhage (Gross diagnosis).
- 2). Adipose tissue, left mandibular fat pad; panniculus and skeletal muscle, left abdomen: Congestion, multifocal, moderate.
- 3). Adipose tissue: Atrophy, diffuse, mild.
- 4). Liver: Cholangiohepatitis, granulomatous and eosinophilic, multifocal, moderate, with biliary ectasia, periductular fibrosis and trematodes.
- 5). Lung: Bronchopneumonia, granulomatous and eosinophilic, multifocal, mild, with nematodes.
- 6). Ears, peribullar: Hemorrhage, moderate, focally extensive, with nematode parasites.

Comments and Conclusions

The most significant gross observation was the fractured left occipital crest with hemorrhage in the underlying tissues and left mandibular fat pad. Due to the lack of microscopic hemorrhage or inflammatory infiltrate, it was difficult to resolve whether this fracture was a post mortem event or incurred shortly before death, as there was insufficient time for a histological reaction to develop. The immediate cause of death is not evident; however, if this was a perimortem event, the trauma resulting in this fracture would have been sufficiently severe to account for the death of this animal. No overt lesions consistent with acoustic trauma were noted. The left abdominal subcutaneous hematoma was likely associated with blunt trauma. An adequate assessment of the nutritional status of this animal was not possible due to extent of post mortem decomposition (Table 3). The microscopically detected fat atrophy was indicative of a

negative energy balance. The peribullar parasites were morphologically consistent with *Stenurus* spp and the heavy burden would have presumably contributed to antemortem morbidity. In contrast, the parasitic pneumonia (most likely *Halocercus* spp) and cholangiohepatitis (presumably *Campula* spp) are considered low grade and incidental. The parasitic load from these latter two species is commonly observed in wild porpoises and presumably would not have contributed to antemortem morbidity. Fecal floatation and sedimentation were negative for parasites. There was no detectable domoic acid within ingesta as determined by SPE and analysis by HPLC. PCR of pooled lung, lymph node, spleen and brain was negative for Morbillivirus and consensus *Brucella* spp. Viral culture on Mabin Darby and Vero cell lines were negative. The pancreas was too autolyzed to score the extent of fibrosis. Trace mineral and vitamin A analysis of the liver and kidney were within normal reference limits (Table 6). Aerobic bacterial culture of the kidney, liver, mesenteric lymph node yielded light, mixed growth of *Enterococcus* spp, nonhemolytic *Escherichia coli*, and *Aeromonas hydrophila* (Table 5). There was moderate mixed growth of these bacteria in the spleen, lung and brain and heavy growth of *Enterococcus* spp and *Clostridium perfringens* from the small intestine. Based on the extent of autolysis and lack of attendant inflammatory infiltrate, these isolates are most likely due to post mortem overgrowth. There were no fungal pathogens isolated from the lung and special culture for *Salmonella* spp in the intestine was negative. Trace mineral analysis of the eye fluid (vitreous humor) revealed calcium levels of 7.7 mg/dl, magnesium of 20.79 mg/dl, a phosphorus of 64 mg/dl and a blood urea nitrogen of 57 mg/dl (Table 6). Although the BUN may appear elevated, the lack of established normal levels for healthy animals confounds interpretation of this data.

03NWR05011

History

The porpoise was first reported stranded at the high tide line on 16 May 2003 at Ediz Hook in Port Angeles (Figure 1), with blood coming from the eyes, nares, and oral cavity (Figure 18).

Gross Findings

An adult 136.5 cm total length, 37 kg female harbor porpoise was presented dead 23 July 2003, in good nutritional and fair post mortem condition with extensive scavenger damage (Figure 19). Throughout the left dorsolateral aspect of the head there was extensive subcutaneous hemorrhage. There were bilateral fractures and disarticulations of the zygomatic arches, parallel transverse and comminuted fractures of the left mandible, and multiple rostral skull base, including frontal bone and prefrontal fractures frequently admixed with substantial amounts of acute hemorrhage or overlaid by variably sized blood clots (Figure 20). Intercalated between the oral mucosa and palatine lobes and occluding the pterygoid sinus there was marked hemorrhage. Frank hemorrhage was within the lumen of the trachea, bronchi, deep within the nares, esophagus and oropharynx. The vasculature appeared prominent in the blubber and nuchal fat. There were focal abrasions on the rostral mandible and maxilla and small healed cutaneous lacerations along the leading edge of the dorsal fin, left fluke lobe and mid dorsal region of the caudal peduncle.



Figure 18 – Left ventral view of porpoise 03NWR05011 at time of initial discovery (16 May 2003) (Photo: Olympic Coast National Marine Sanctuary).



Figure 19 – Ventral photograph of 03NWR05011 at time of necropsy (23 July 2003) (Photo: B. Hanson).

Nervous system: Adjacent to the cranial fractures, there was extensive epi and subdural hemorrhage and the entire surface of the brain was dark red. In the left ear, there were numerous peribullar nematodes.

Cardiovascular and endocrine systems: Tissue surrounding the thyroid gland and thymus was dark red and moderately edematous. There was approximately 7 ml of dark red fluid within the pericardial sac.

Respiratory System: There was a moderate amount of dark red fluid within the trachea. The lungs were uniformly dark red, with rare 1mm white calcified parasitic nodules and there was approximately 75 ml of dark red fluid within the thoracic cavity.

Digestive System: The pancreas was light red to pink and a minimal amount of fibrosis surrounded the pancreatic duct. Diffusely, there was a moderate amount of chyme within

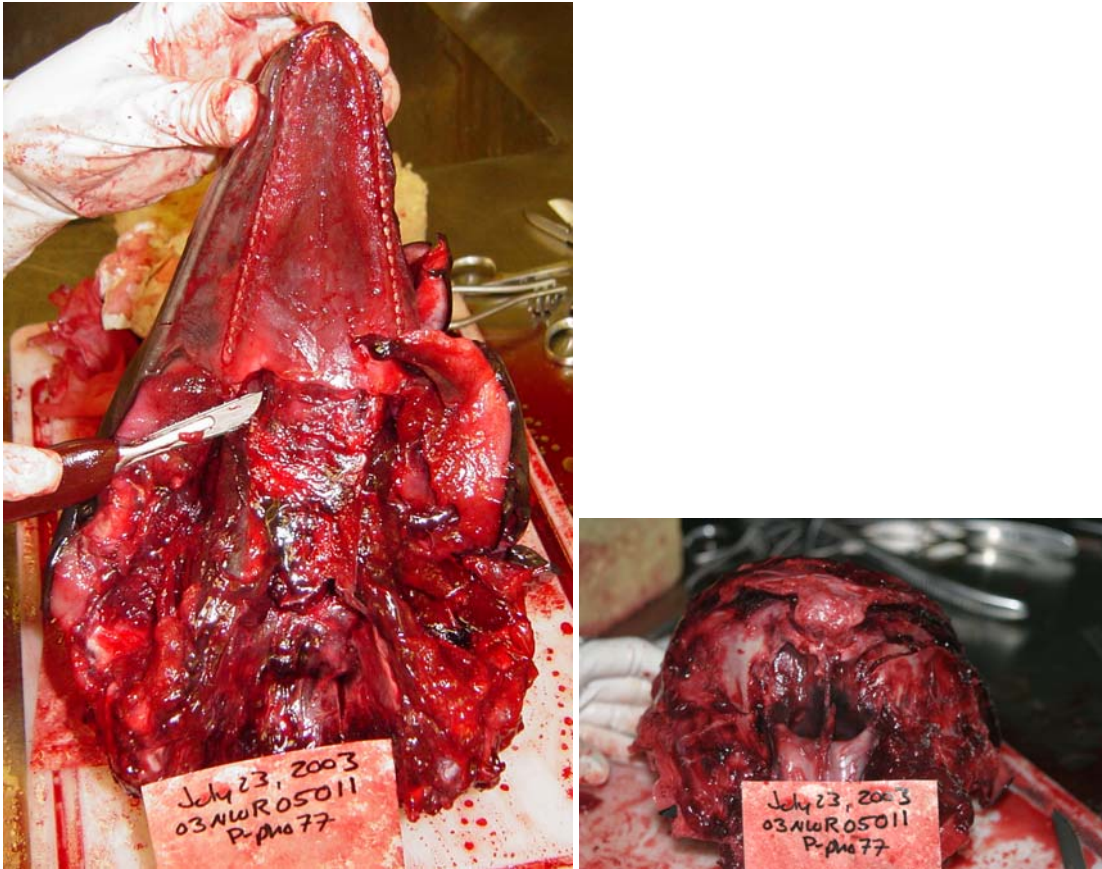


Figure 20 – Photographs of the ventral (left) and caudal (right) aspects of the skull of 03NWR05011 demonstrating multiple fractures (Photos: D. Ketten – left; B. Hanson – right).

the mesenteric lymphatics. There was a small amount of dark green to brown ingesta throughout the intestines.

There were no apparent lesions within the urogenital or hemolymphatic systems.

CT Findings

Cranial, thoracic and abdominal images were analyzed. The animal was in generally poor condition, and had extensive trauma evident particularly on the surface and within the head.

Cranial soft tissues: There were multiple areas of abrasions with the most compromised areas rostral. Sand or similar material was present throughout the mucosal and cutaneous surfaces of the head, particularly in the left dorsal nasal sac. There were extensive areas of contusion consistent with cranial trauma.

Intracranial/brain: The entire skull was severely compromised by multiple fractures, including longitudinal and comminuted fractures of the skull base, right occipital, left temporal, left parietal, left squamosal, frontal and left mandibular bones, with multiple skull fragments displaced (Figures 21 and 22). The left mandible had two longitudinal

fractures, three parallel fractures and one laterally displaced chip. The brain was homogenous, suggesting it was severely compromised as a result of the trauma inflicted on the skull.

Eyes: Both were present but collapsed.

Right ear: The peribullar areas and middle ears were normal. Bilaterally, the inner ears contained blood in the apical and middle turns.

Left ear: Blood was found in the apical and middle turns of the inner ear. The peribullar space contained two tissue masses: one an organized clot and the other a mass medial to the left tympano-periotic bone, with a similar mass within the middle ear cavity.

Multiple, small, dense spheroids within these soft tissue masses were most likely calcified parasitic bodies. There was also a tympanic bone fracture in the left lateral wall.

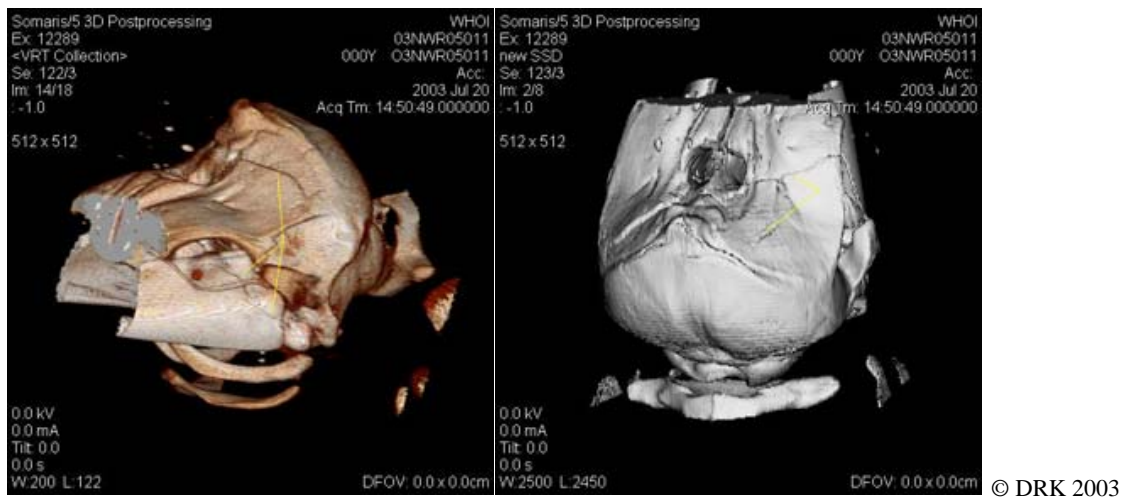

Figure 21 – A lateral 3D view (left) of 03NWR05011 showing the mandibular and frontal fractures (yellow arrows). The dorsal 3D view (right) shows a right frontal and maxillary fracture (yellow arrows) (Illustrations: D.R. Ketten).

Post-cranial features: The internal organs were partially autolyzed with some evidence of freeze-thaw artifacts within the liver. The lungs were congested and atelectatic with the right slightly more affected than the left. An ice block was evident in the right bronchus (Figure 23). Several dense foci within the trachea were attributed to sand or parasitic inclusions.

Cause of death: Given that the evidence from the histology shows the fractures were pre or perimortem, the CT evidence shows extensive fractures to be consistent with a blunt or blast trauma that would likely have resulted in immediate or rapid death.

Gross and Histologic Diagnoses

- 1). Cranium, rostral skull base, mandible, zygomatic arches, and frontal bones: Fractures, comminuted, severe, closed with variable displacement and hemorrhage (Gross diagnosis).
- 2). Adipose tissue, near mandibular fracture: Congestion, multifocal, mild.
- 3). Spinal cord and peripheral nerve: Hemorrhage, multifocal, mild.

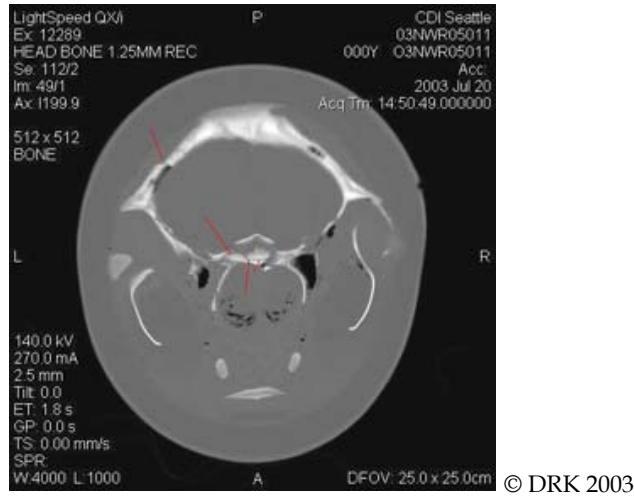


Figure 22 - A 2D cross section of 03NWR05011 demonstrating multiple fractures disrupting the brain case (orange arrows) (Image: D.R. Ketten).

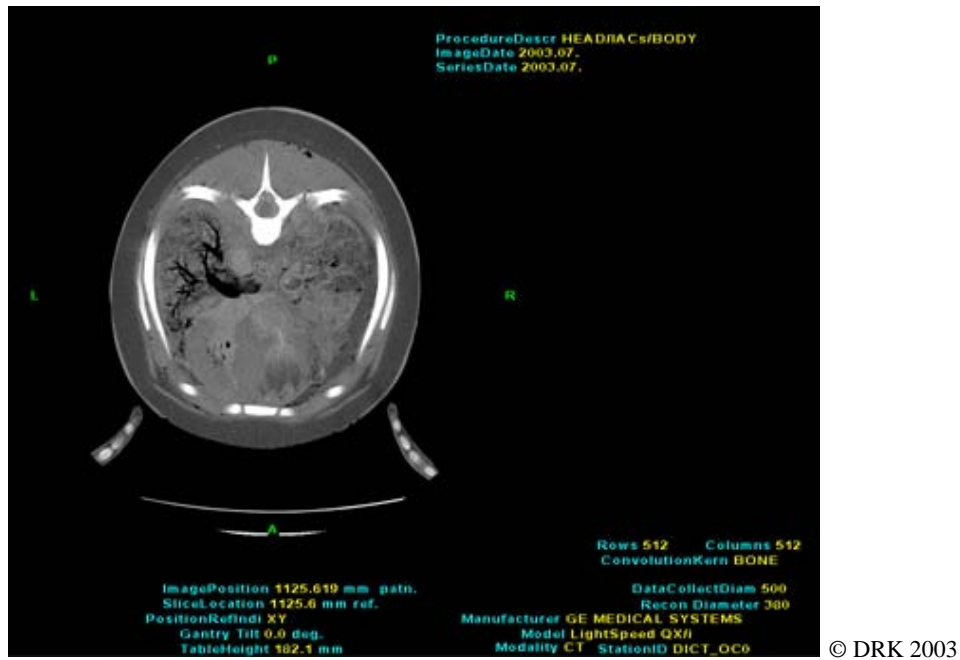


Figure 23 – A CT scan image of 03NWR05011 at the level of the right bronchus demonstrating an ice block (Image: D.R. Ketten).

- 4). Lung: Bronchopneumonia, granulomatous and eosinophilic, multifocal, mild, with few adult nematodes.
- 5). Liver: Cholangiohepatitis, granulomatous and eosinophilic, multifocal, moderate, with biliary ectasia, periductular fibrosis and trematodes.
- 6). Pancreas: Fibrosis, periductular, multifocal, moderate.
- 7). Thymus: Edema, interlobular, multifocal, mild.
- 8). Ear, peribullar (Gross diagnosis): Hemorrhage, moderate, focally extensive with intralesional nematode parasites.
- 9). Ear, intracochlear: Presumptive hemorrhage, mild, multifocal.

Comments and Conclusions

Profound autolysis and freeze artifact hampered histopathology. The most significant findings were the skull and mandibular fractures, with grossly noted hemorrhage within the adjacent tissue. Post mortem changes hindered microscopic assessment of the adjoining fascia and periosteum and hampered precise determination of whether this trauma may have been incurred ante- or postmortem. If inflicted antemortem, the severity of the physical trauma would have been sufficiently severe to account for the loss of this animal. Detection of frank hemorrhage within the lumen of the nares and cochlea, as well as free blood within the trachea, bronchi, esophagus and calverium is suggestive of antemortem blunt trauma that presumably was inflicted by a predator, conspecific, or some other means. The tracheal and esophageal submucosal congestion was likely an agonal or terminal process possibly related to dependent hypostasis. Based on comparison within normal reference values, this animal was in good body condition (Table 3). Aerobic bacterial culture of the liver, thymus, spleen, mesenteric lymph node and urine isolated small numbers of *Enterococcus* spp. In the kidney and spinal cord, there was mixed light growth of *Enterococcus* spp and nonhemolytic *Escherichia coli* and heavy growth of *Clostridium perfringens* from the small intestine and colon (Table 5). No fungi were isolated by special culture of the lung or *Salmonella* spp from the intestine. Negative staining electron microscopy of the conjunctiva disclosed numerous mixed bacteria which are not considered pathologically significant and there were no discernible viral particles. There was insufficient cerebrospinal fluid to assay for canine distemper virus by serology. PCR of pooled lung, lymph node, spleen and brain was negative for Morbillivirus and consensus *Brucella* spp and follow up viral culture on Mabin Darby and Vero cell lines was negative. There is a possibility of reduced pathogen viability associated with post mortem decomposition and freezing. Urinalysis of post mortem urine disclosed dark yellow cloudy urine with a specific gravity of 1025 and protein of 300. No nitrates, ketones, bilirubin, casts, crystals, urobilinogen, mucus, bacteria, fat or white blood cells were detected. There were 1-2 white blood cells, 0-1 red blood cells per high powered field and large numbers of transitional epithelia. Trace mineral and vitamin A analysis of the liver and kidney proved within normal reference limits (Table 6). The hepatobiliary (*Campula* spp), pulmonary (*Halocercus* spp) and gastric (*Anisakis* spp) parasitism is commonly observed in wild porpoises; no parasites were identified by fecal floatation or sedimentation.

3NWR05019

History

This animal was reported stranded on 17 May 2003 at Lagoon Point on Whidbey Island (Figure 1). After examination of the animal at the site, it was wrapped in plastic to prevent further scavenging and moved above the high tide line (Figure 24). The carcass was transferred to the NMML-32 freezer on the evening of 17 May.

Gross Findings

A 138 cm total length, 37.5 kg immature female harbor porpoise was presented dead, 24 July 2003, in moderate body condition. Initial carcass code was coded as a 3, but the internal exam revealed that the deep tissues were in poor post mortem condition (Figure 25). The porpoise was moderately well fleshed. In the right eye, the aqueous humor was diffusely dark red and translucent and a small amount of dark red fluid oozed from the ventral conjunctiva on manipulation of the head. The left eye was absent and the conjunctiva was eroded and irregular (post mortem scavenging). At the level of the right commissure, there was a moderate amount of periosteal edema and congestion of the mandibular body. Sand and debris were found in the nares. Throughout the ventrolateral aspect of the torso, there is extensive fissuring and loss of skin with only small remnants of intact epidermis evident. The left side of the carcass had extensive bird damage.



Figure 24 – Right ventrolateral photograph of porpoise 03NWR05019 at time of initial discovery (17 May 2003) (Photo: S. Berta).

Nervous system: In both the right and left inner ears, there were moderate peribullar accumulations of nematode parasites. Within the rostroventral region of the calverium, immediately below and elevating the periosteum, there was moderate accumulation of dark red subdural fluid.



Figure 25 – Right lateral photograph of porpoise 03NWR05019 at time of necropsy (24 July 2003), demonstrating poor post mortem condition (Photo: B. Hanson).

Respiratory system: At the midlevel of the right lung lobe, moderately deep within the parenchyma, there was a 2x2 cm, pale tan yellow moderately firm nodule that eccentrically entrapped two dilated bronchioles; there was mild to moderate enlargement of the adjoining hilar lymph nodes which were pale grey brown and glistening on sectioned surface. Widely dispersed throughout the lung parenchyma, there were a moderate number of 1mm calcified parasite nodules.

Digestive system: Within the dorsomedial aspect of the hilar region of the liver as well as along the distal limit and to a much lesser extent, midlevel of the right liver lobe, immediately below and slightly elevating the liver capsule, there were small numbers of dilated biliary ductules with moderate numbers of trematode parasites interspersed within variable amounts of black mucoid deposits. There was minimal pancreatic periductular fibrosis and the mesenteric lymphatics were distended with chyme.

There were no apparent lesions within the hemolymphatic, cardiovascular, musculoskeletal, integumentary, urogenital or endocrine systems.

CT Findings

This animal was not scanned.

Gross and Histologic Diagnoses

- 1). Lung: Bronchopneumonia, moderate, multifocal, granulomatous and eosinophilic, subacute with bronchiectasis and many nematode adults and larvae.
- 2). Liver: Cholangiohepatitis, granulomatous and eosinophilic, mild, multifocal, with biliary ectasia and duct hyperplasia.
- 3). Dura, base near cerebellum and left base of cranium: Congestion, moderate, diffuse.
- 4). Peribullar space: Hemorrhage, peri and retrobullar, mild with intralesional nematode parasites (Gross diagnosis).

Comments and Conclusions

Autolysis, freeze artifact and extensive post mortem scavenging prohibited gross evaluation of multiple tissues and hindered microscopic assessment of select tissues.

Subdural and subarachnoid fluids were grossly noted in the brain. The cause of death of this animal was not determined. Due to the extent of post mortem decomposition, lesions consistent with acoustic trauma could not be excluded. The hepatic trematodiasis, colitis and verminous pneumonia were considered low grade and clinically insignificant. The pulmonary nodule noted grossly was an area of verminous pneumonia. The bile duct parasites were most likely *Campula* spp and the lungworms were presumably *Halocercus* spp. Trace mineral analysis of the eye (vitreous humor) fluid revealed calcium levels of 8 mg/dl, magnesium of 10.4 mg/dl, phosphorus of 46 mg/dl and a blood urea nitrogen of 52.1 mg/dl. Although the BUN appeared elevated, the lack of established normal levels for healthy animals confounded interpretation of this data (Table 6). Bacterial culture of the spleen, lumbar lymph node, kidney and liver yielded light mixed growth of *Aeromonas hydrophila* and *Psychrobacter* spp and moderate to heavy growth of these isolates from the lung, brain and spinal cord. No *Salmonella* spp were recovered from the intestine and fungal culture of the lung were negative (Table 5). Based on the extent of post mortem change and lack of attendant inflammatory infiltrate, the heavy growth of *Clostridium perfringens* was attributed to post mortem proliferation. Fecal floatation and sedimentation were negative for parasites and there was no detectable domoic acid within ingesta as determined by SPE and analysis by HPLC.

PCR of pooled lung, lymph node, spleen and brain was negative for Morbillivirus and consensus *Brucella* spp and follow up viral culture on Mabin Darby and Vero cell lines was negative. Trace mineral and vitamin A analysis of the liver and kidney proved within normal reference limits (Table 6).

03NWR05012

History

This specimen was reported on the morning of 20 May 2003 floating off False Bay, San Juan Island (Figure 1), was collected by a whale watch boat operator before noon and delivered to Snug Harbor Marina. The specimen appeared to be in very fresh condition when first observed. Externally, there was no evidence of net entanglement or trauma, except for bleeding from the left eye where birds had pecked away some of the tissue. The carcass was transported around noon to the UWFHL freezer (Figure 26). By mid-afternoon it was returned to the freezer at the Center for Whale Research due to insufficient space at the UWFHL freezer. The evening of 30 June 2003 it was taken to the NMML-4 freezer.

Gross Findings

A 123 cm total length, 30 kg immature male harbor porpoise was presented dead, 23 July 2003, in good nutritional condition. The initial carcass condition was coded as a 2, but the internal exam revealed that the deep tissues were in a fair to moderate post mortem state (Figure 27). The animal was moderately well fleshed (Table 3). Within the dorsal aspect of the head, caudolateral margins of the nares, sub- and intermandibular skin, and bilaterally involving the mandibular fat pads, there was variably extensive congestion of the blubber and subjacent skeletal musculature. The melon was normal and the oral cavity was clear.



Figure 26 – Left lateral photograph of porpoise 03NWR05012 on day of initial report (20 May 2003) (Photo: Center for Whale Research).



Figure 27 – Left lateral photograph of porpoise 03NWR05012 at time of necropsy (23 July 2003) (Photo: B. Hanson).

There was no evidence of deep contusions associated with either mandible. The oropharyngeal mucosa was diffusely dark red. Immediately below the epiglottis and circumferentially involving the goose beak (larynx) mucosa, as well as extending along multiple contiguous laryngeal folds, there was moderate to marked submucosal congestion (Figure 28). Throughout the ventrolateral aspect of the mandible, there were scattered, superficial cutaneous aggregates of diatoms. Within the hypodermis of the perineum, there were multiple granulomas with parasitic tracts and intralesional nematodes. The left eye was punctured and collapsed. Along the distal limit of the right flipper, lower lip and mandible, there were scattered punctate ulcers frequently bound by red brown margins. There were multiple healed rake marks along the right ventral peduncle.

Nervous System: The inner surface of the calvarium was diffusely stained purple to red. There was a large amount of dark red fluid within the cranial cavity. A small amount of dark red fluid was below the meninges and the superficial aspect of the brain was suffused dark red. The dura and the border of bone at the posterior fossae had irregular borders. Both peribullar spaces had substantial burdens of parasites interspersed within moderate amounts of acute hemorrhage. Parasites were also present within the subtemporal region of the cranial vault.

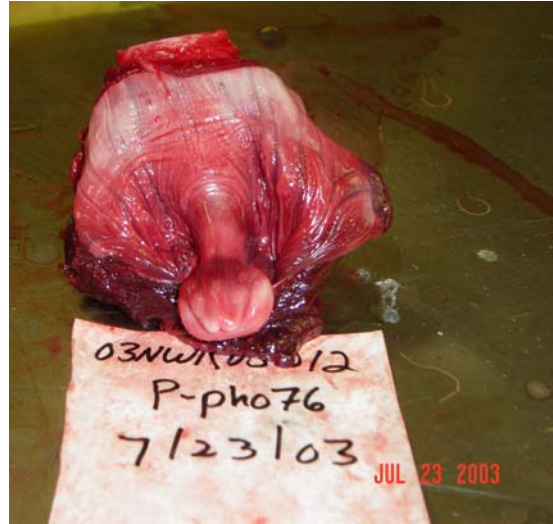
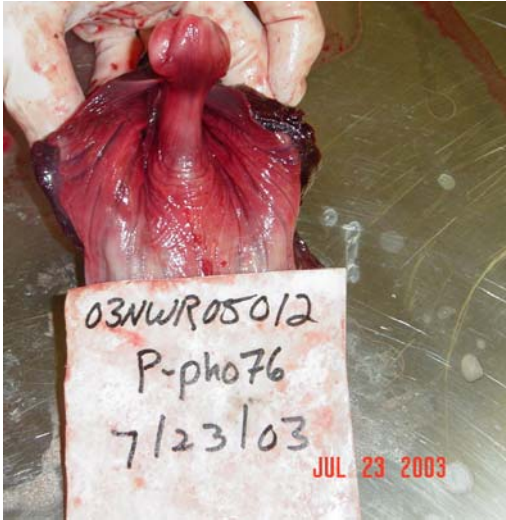
Figure 28 – Two photographs of the larynx of 03NWR05012 demonstrating localized submucosal congestion (Photos: D. Ketten).

Along the lower left margin of the medulla oblongata and spinal cord at the levels of cervical vertebrae 1 and 2, the meninges were overlaid by a small amount of dark red gelatinous material (clot).

Respiratory System: The right lung was diffusely dark red. The left lung was mottled light pink with intervening, slightly depressed and mildly firmer dark red areas. A small amount of dark red froth was within the bronchi and trachea. There were rare 1mm, white, firm, parasitic aggregates widely dispersed throughout the pulmonary parenchyma.

Digestive System: Within the hilar region of the liver there were a small number of dilated bile ducts that contained multiple flukes interspersed within moderate amounts of dark black green tenacious material. There was a moderate amount of green brown ingesta throughout the intestines. A small number of nematodes overlaid or were interdigitated within the mucosa of the forestomachs. There was mild periductular fibrosis noted within the pancreas.

There were no significant lesions within the cardiovascular, musculoskeletal, urogenital, hemolymphatic or endocrine systems.

CT Findings

This animal was in moderate to poor condition. This was a young juvenile, based on size, relatively low skull mineralization and incompletely ossified cranial sutures.

Cranial soft tissues: A majority of the airways and associated spaces were compromised by fluid and foam deposits. The left sinus was opacified and contained both fluid and foam. The blubber layer was thin, but well-defined.

Intracranial/brain: A complex mass was bilaterally juxtaposed to the subtemporal entry

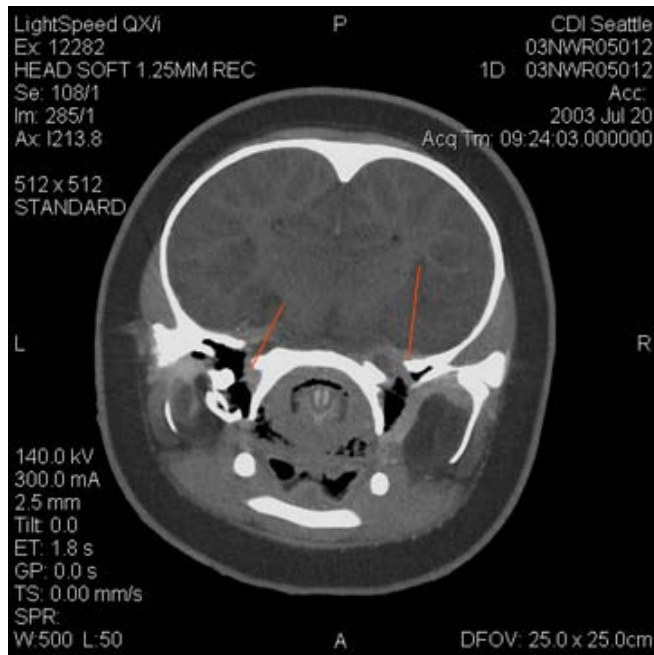


Figure 29 – A CT scan image of 03NWR05012 at the level of the subtemporal entry points of cranial nerves VII and VIII demonstrating a soft tissue mass juxtaposed to the entry points (orange arrows) (Image: D.R. Ketten).

points of cranial nerves VII and VIII (Figure 29). The masses were irregularly shaped and most consistent with a mixture of fats and blood and degenerate parasite aggregates.

Eyes: The right was normal. The left eye was collapsed with an associated, well-organized orbital clot.

Right ear: Aside from some moderate density masses in the medial peribullar region and middle ear, the right peribullar areas were normal. Although the middle ear structures were intact and normal, there were large soft tissue masses suggestive of nematode infestations. The inner ear was normal.

Left ear: The left peribullar areas, were normal with moderate density masses in the medial peribullar region and middle ear. The middle ear contained more soft tissue nematode aggregates than the right ear. The medial ear and inner ear structures were normal.

Post-cranial features: Both lungs were congested and atelectatic with the right more extensively affected at all levels than the left. A soft tissue deposit, with an inconsistent appearance suggestive of a mixture of foamy, sero-sanguinous material, extended from the larynx to the mid trachea.

Gross and Histologic Diagnoses

- 1). Brain, meninges, ventral cerebral hemispheres and diencephalon: Congestion, moderate, diffuse.
- 2). Skin, sub and inter-mandibular; adipose tissue, right upper mandible; spinal cord;

pharynx; and larynx: Congestion, minimal to moderate, focally extensive.

3). Ear, retro and peribullar: Hemorrhage, moderate, bilateral with florid intralesional nematode parasites (Gross diagnosis).

4). Liver: Cholangiohepatitis, granulomatous and eosinophilic, focally extensive, moderate, with biliary ectasia, bile duct hyperplasia, periductular fibrosis and many trematodes.

5). Lung: Pneumonia, granulomatous and eosinophilic, multifocal, mild with few nematodes.

6). Skin, multiple sites: Granulomas, multiple with parasitic tracts and intralesional nematodes.

7). Skin, lip, mandible, and flippers: Ulcers, mild to moderate, multifocal (Gross diagnosis).

8). Ear, peribullar (Gross diagnosis): Hemorrhage, moderate, focally extensive with intralesional nematode parasites.

Comments and Conclusions

Post mortem autolysis, freeze artifact and scavenging impeded gross evaluation of multiple organs and hindered microscopic assessment of selected tissues. The cause of death was not evident. No overt lesions consistent with acoustic trauma were observed. Pronounced congestion throughout the head and oropharyngeal mucosa was presumably due to dependent hypostasis. Based on measurements of blubber and axial skeletal muscle mass, this animal was considered moderately well fleshed (Table 3). The blood clot overlying the spinal cord was attributed to agonal or terminal thrashing at the time of stranding. The peribullar (presumptive *Stenurus* spp) and subcutaneous parasitism due to *Crassicauda* spp was more intense in this individual than examined cohorts. On CT image analysis, the most significant finding was intracranial parasitic invasion from the retrobullar regions through enlarged subtemporal apertures for the cranial nerves VII and VIII. The relatively low bone density of the cranium and incomplete cranial sutures are consistent with an immature animal. The burden of lungworms (presumptive *Halocercus* spp) and liver flukes (*Campula* spp) were not considered pathologically significant. Sections of skin disclosed superficial phytoplankton morphologically consistent with *Navicula* spp. Diatoms have previously been reported in north Pacific porpoises and are generally considered incidental findings (Holmes *et al.*, 1993). Although the precise cause of the cutaneous ulcers was unknown, agonal scavenging was a prime consideration. Aerobic bacterial culture yielded light mixed growth of alpha *Streptococcus* spp and nonhemolytic *Escherichia coli* from the lung and kidney with light growth of alpha *Streptococcus* spp from the mediastinal lymph node. A few colonies of *E. coli* were isolated from the spinal cord and there were no bacteria recovered from the liver or spleen (Table 5). Fungal culture of the lung was negative and no *Salmonella* spp were isolated from the small intestine. The heavy growth of *Clostridium perfringens* was attributed to post mortem proliferation. The extent of autolysis suggested that the remaining isolates were due to post mortem overgrowth. Fecal floatation and sedimentation were negative for parasites. Tissue culture of pooled lung, lymph node and spleen on Mabin Darby and Vero cell lines was negative and PCR for Morbillivirus and *Brucella* spp was unremarkable. Negative staining electron microscopy of the conjunctiva and cutaneous ulcers failed to reveal any discernible pathogens. Ingesta was

processed by strong anion exchange (SAX) solid phase extraction (SPE) cartridges followed by analysis by HPLC with UV detection at 242 nm and was negative for domoic acid. Trace mineral analysis of the liver and kidney were within normal reference limits and interpretation of the eye calcium (5.3 mg/dl), magnesium (5.24 mg/dl), phosphorus (40 mg/dl) and blood urea nitrogen (mg/dl) values is hindered due to the lack of established normal values; in cattle adequate or normal values are calcium: 6.0-7.5 mg/dl, magnesium: 1.90 mg/dl and phosphorus 1.3-3.0 mg/dl (Table 6).

03NWR06005

History

This porpoise was found stranded and collected at 20:00 hr on 2 June 2003 (Figure 30) at Long Beach (Figure 1) and delivered to the NMML-32 freezer on 3 June 2003.

Gross Findings

An adult 146 cm total length, 39 kg reproductively quiescent male harbor porpoise was presented dead, 21 July 2003, in poor body condition. Initial carcass code was coded as a 2, but the internal exam revealed that the deep tissues were in moderate post mortem condition (code 3) (Figure 31). There were minimal visceral and scant nuchal adipose stores and the animal was poorly muscled. Rostral to the melon and randomly within the subcutaneous tissue along the entire length of the torso, there were extensive parasitic tracks, granulomas and nematodes within the hypodermis and, occasionally along deep fascial planes. Throughout the left ventrolateral margin of the pharynx and along the lateral aspect of ribs 2-4 and the cranial third to one-half of the scapula there was multifocally extensive, acute subcutaneous edema and hemorrhage. There were no apparent contusions in the melon. A small amount of red fluid exuded from the oral cavity. There was a small abrasion on the lower mandibular tip.

Respiratory and hemolymphatic systems: At the midlevel of the left lung, deep in the parenchyma, there was a large, 8-10 cm diameter, pale tan yellow moderately firm nodule which peripherally entrapped a small number of markedly ectatic bronchioles that were occluded by dense aggregates of nematode parasites.

Within more normal adjoining parenchyma, there were multiple bronchioles and bronchi that contained variable numbers of nematodes. There was marked enlargement of the regional (mediastinal, hilar and pleural) lymph nodes that on sectioned surface were pale tan yellow, firm, and glistening. Large numbers of nematodes were located within the lumen of the trachea, larynx and nares. There was no foam or blood within the lumen of the nares.

Digestive system: Within the nonglandular compartment of the stomach, there were multiple proliferative and superficially ulcerative nodules and randomly throughout the glandular compartment, there were a small number of punctuate, erosions and ulcerations and trematodes. The small intestine was diffusely inflated with gas and multifocally contained a moderate amount of dark green black, particulate to fluid ingesta. Along the entire length of the large intestine, there was marked smooth muscle hypertrophy and



Figure 30 – Right lateral photograph of 03NWR06005 at stranding site (2 June 2003) (Photo: Cascadia Research Collective).



Figure 31 – Right lateral photograph of porpoise 03NWR06005 at time of necropsy (21 July 2003) (Photo: B. Hanson).

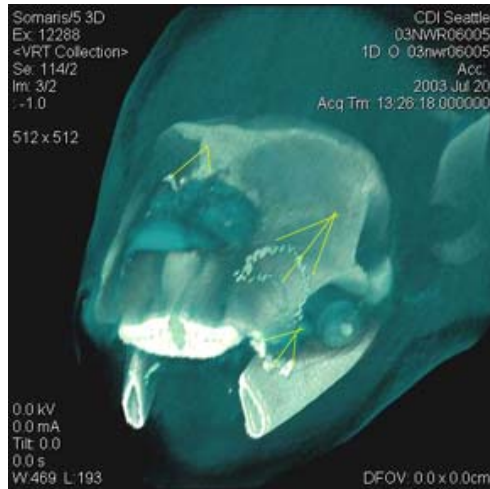attendant stenosis of the colonic lumen. Within the hilar region of the liver, there were multiple bile ducts that were moderately dilated by trematode parasites and dark green black tenacious material. Pronounced tooth wear was evident throughout the upper and lower arcades.

Nervous system: Bilaterally, within the medial and dorsal peribullar region, there were massive accumulations of nematode parasites (estimate 700 each). Diffusely, the surface of the brain was dark red black and there was variable congestion of the meningeal vasculature.

There were no apparent lesions within the cardiovascular, endocrine, urogenital or musculoskeletal systems.

CT Findings

Cranial soft tissues: The head was intact with normal soft tissue configurations. On the left side there was a convoluted, calcified nematode track that extended nearly 120 mm (Figure 32). There were numerous fibrotic or heavily calcified nodules in almost every major tissue suite of the head. There were substantial cystic deposits in the peri-esophageal tissues as well.



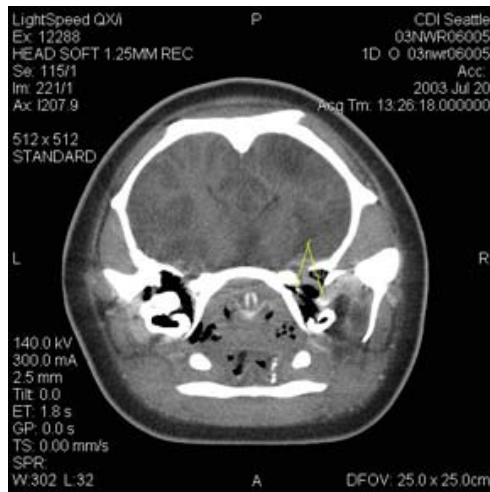
© DRK 2003

Figure 32 – A three-dimensional reconstruction of the head of 03NWR06005 demonstrating the outer surface of the head (blue) with the underlying skull and contoured, calcified parasitic inclusions (white patches with yellow arrows indicating major deposits) (Illustration: D.R. Ketten).

Intracranial/brain: The cranial structures were unremarkable.

Eyes: Both eyes were intact.

Ears: Bilaterally, there was extensive parasitism with substantial calcified inclusions in the peribullar and middle ear tissues (Figure 33). The epithelium of the medial wall of the left retrobullar space was distended. The inner ears were normal bilaterally.



© DRK 2003

Figure 33 – A CT scan image of 03NWR06005 at the level of the peribullar spaces demonstrating a peribullar mass (yellow arrows) with inclusions similar to those seen in Figure 32, as well as calcified cysts in the esophagus (Image: D.R. Ketten).

Post-cranial features: The most remarkable features were extensive calcified parasitic tracts affecting most tissues. There were long, convoluted, calcified threads, several

millimeters in diameter distributed throughout the blubber and musculature of the abdomen. The kidneys were well-defined and contained para-sagittal fibrotic masses. The lungs had extensive clouding bilaterally that paralleled the bronchial tree. This process was more apparent and extensive in the left lung. The right lung airways contained foamy exudate and pooled fluid that extended to the larynx (Figure 34).

Dorsal to the right bronchus of the middle lung lobe, there was a mass effect. Discrete opacified lesions were dispersed throughout both lungs.

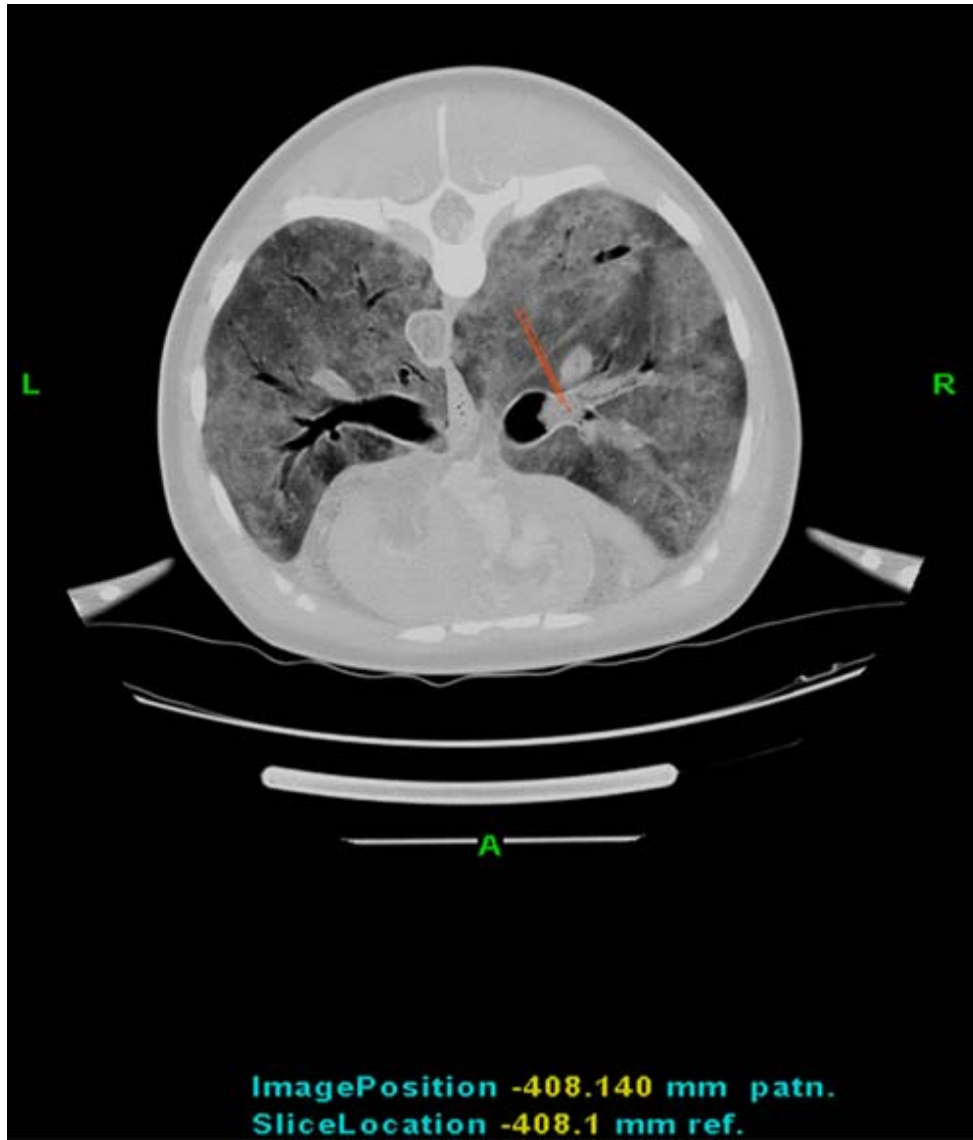Gross and Histologic Diagnoses

- 1). Carcass: Emaciation, marked, generalized (Gross diagnosis).
- 2). Lung: Bronchopneumonia, severe, multifocal, granulomatous and eosinophilic, necrotizing, with bronchiectasis and massive bronchiolar and alveolar accumulation of nematode parasites with florid intralesional fungal hyphae.
- 3). Lymph nodes, mediastinal, hilar and pleural: Lymphadenitis, subacute, multifocal, mild with lymphoid hyperplasia.
- 4). Ear, peribullar: Hemorrhage, marked, focally extensive, with massive accumulation of parasitic nematodes (Gross diagnosis).
- 5). Colon, smooth muscle: Hypertrophy, marked, segmental, with submucosal edema and chronic colitis.
- 6). Skin, generalized: Cellulitis and dermatitis, moderate to marked, multifocal, random, granulomatous chronic with mineral deposition and nematode parasites.
- 7). Liver: Cholangiohepatitis, moderate, multifocal to coalescing, chronic with biliary ductular hyperplasia, ectasia, periductular fibrosis and intraluminal trematodes.

Comments and Conclusions

Postmortem autolysis and freeze artifact hampered histopathology. The most significant lesions were extensive parasitic and mycotic bronchopneumonia, generalized emaciation (Table 3) and colonic smooth muscle hypertrophy. These lesions were profound and cumulatively would have resulted in significant antemortem morbidity and the death of this animal. No overt lesions associated with acoustic trauma were noted. CT image analysis confirmed the extensive calcified parasites particularly within the blubber, fascial planes, retrobullar regions, kidneys, biliary tree, and lungs. Based on experience with previous strandings, this parasitism was considered exceptional, even for this species of odontocetes in which parasites are commonly found. In marine mammals, pulmonary mycotic infections are typically associated with either localized immunosuppression or generalized debility (Reidarson *et al*, 2001). In this case, the emaciation and other disease processes may have been contributory factors. The fungal infection was likely acquired by inhalation of aerosolized conidia and there was no apparent extrapulmonary fungal involvement within the examined tissues. The lung parasites were likely *Halocercus* spp. The regional lymphadenitis and lymphoid hyperplasia were sequelae to the pneumonia. Histopathology of the grossly thickened segments of large intestine disclosed pronounced hypertrophy of the muscularis with variable accumulation of edema fluid and scattered foci of chronic inflammation within the overlying mucosa. Similar changes along varying levels of the small intestine has

been reported in a number of animal species and has been associated with impactions, strictures, stenosis, adhesions, tumors or spastic contractions.



© DRK 2003

Figure 34 – A CT scan image of 03NWR06005 at the level of the lungs demonstrating an accumulation of foamy exudate (orange arrows) and pooled fluid that extended into the larynx (Image: D.R. Ketten).

In this porpoise, there were no apparent predisposing lesions, consequently the hypertrophic change was considered idiopathic. The intensity and distribution of the hypodermal (presumptive *Crassicauda* spp), gastrointestinal (*Anisakis* spp) and peribullar (likely *Stenurus* spp) parasites was enhanced in this relative to other stranded animals and may be secondary to profound debilitation. Fecal floatation and sedimentation were negative for parasites. The subcutaneous edema and hemorrhage noted within the thoracic region was likely due to localized agonal or terminal trauma (blunt impact). Urinalysis disclosed a specific gravity of 1.012, pH of 6.0 and protein of 300. Cytology

of the urine disclosed abundant numbers of transitional epithelia, scattered crystal fragments, and small numbers of leukocytes and extracellular cocci. The red and white blood cell count ranged from 0-1 per high-powered field and there was a large amount of amorphous debris. Trace mineral analysis was within normal in house reference limits and there was profound depletion of liver, vitamin A levels (Table 6). Due to the extent of emaciation, this may have represented dietary deficiency, although post mortem deterioration and loss could not be discounted. Vitamin A has been cited as a marker for immune function, and it is interesting to speculate that reduced levels may have been a factor in the pulmonary mycosis in this animal. PCR on pooled lung, lymph node, spleen and brain was negative for consensus and marine mammal variant *Brucella* spp and Morbillivirus and positive for Mollicutes, including *Ureaplasma* spp and *Mycoplasma* spp. At present, the contribution of these bacteria to antemortem morbidity in marine mammals is unknown. No viruses were isolated on Vero or Mabin Darby cell lines and negative staining electron microscopy of the conjunctiva was unremarkable. The light mixed growth of *Raoultella terrigena* and *Moraxella* spp from multiple internal viscera was not considered pathologically significant and there was no growth from the abdominal fluid, vent or atrioventricular valve (Table 5). The lack of significant fungi isolation from the lung may have been due to reduced viability associated with freezing and thawing of the tissues. No *Salmonella* spp were isolated from the small intestine and the heavy growth of *Clostridium perfringens* was attributed to post mortem proliferation. Ingesta was processed by SAX solid phase extraction cartridges followed by analysis by HPLC with UV detection at 242 nm and was negative for domoic acid. Interpretation of the eye calcium (5.8 mg/dl), magnesium (4.94 mg/dl), phosphorus (51 mg/dl) and blood urea nitrogen (59.8 mg/dl) values was hindered due to the lack of established normal values, in cattle adequate or normal values are calcium: 6.0-7.5 mg/dl, magnesium: 1.90 mg/dl and phosphorus 1.3-3.0 mg/dl with BUN serum values between 9-16 mg/dl (Table 6).

SUMMARY OF POST MORTEM EXAMINATIONS AND LABORATORY RESULTS

Pathology

Freeze artifact and moderate to advanced post mortem decomposition in five of the 11 animals significantly hindered pathologic and forensic evaluation of tissues for acoustic trauma as well as other disease processes. In addition, four of these animals had variably extensive percutaneous or deep muscle scavenge lesions. In three of five poorly preserved porpoises, significant diagnoses included salmonella septicemia (03NWR05006), fibrinous peritonitis (03NWR05008) and occipital fractures (03NWR05010). In better preserved animals, there was a single case of peri-mortem cranial fractures (03NWR05011) and one case of necrotizing pneumonia (03NWR06005). No significant findings were identified in the five remaining necropsied porpoises (03NWR05003 was scanned but not necropsied).

Within virtually all examined heads, there was diffuse dark red discoloration of the internal surface of the skull and surface of the brain with scattered submeningeal accumulation of dark red black fluid (as seen in Figure 5). Close evaluation of multiple

sections of brain and periosteum failed to reveal any lesions consistent with acute hemorrhage; the grossly noted discoloration and accumulation of dark red fluid was not associated with acute hemorrhage and was most likely due to liquefactive and autolytic changes. Along the dorsolateral aspect and occasionally circumferentially investing the cranial cervical spinal cord and basioccipital region of the hindbrain, there was variable accumulation of either acute hemorrhage or hematoma formation (in 03NWR05001, 03NWR05005, 03NWR05008, 03NWR05011 and 03NWR05012) (Table 7). Acute retrobullar and peribullar hemorrhage frequently mixed with moderate and more rarely, marked accumulations of nematode parasites, were noted in eight of ten necropsied animals (03NWR05001, 03NWR05005, 03NWR05008, 03NWR05010, 03NWR05011, 03NWR05012, 03NWR05019 and 03NWR06005). With the exceptions of 03NWR05012, in which parasites were disproportionately heavy and extended into the calverium, and in case 03NWR06005, parasitic infections were considered within normal limits for wild porpoises.

Definitive signs consistent with more commonly observed human-related mortality such as fishery related injuries, gunshot, or ingestion of marine debris were not found in any of the animals examined. Cavitory lesions consistent with *in vivo* nitrogen gas bubble formation were not visible in any of the organs as reported in other strandings associated with use of military sonar (Jepson *et al.*, 2003).

CT Scans

Image analysis was conducted on seven intact carcasses and a single decapitated head (Table 8; Appendix D). Post mortem decomposition ranged from moderate to advanced with many tissues exhibiting freeze-thaw artifact. In five of eight samples, the skull was intact with no significant lesions noted within the brain. The grossly noted traumas in cases 03NWR05010 and 03NWR05011 are consistent with CT findings. In case 03NWR05003, due to the lack of density change within the temporal and parietal regions of the brain, a penetrating bone fragment (shard) that was reported on CT was considered a post mortem phenomenon. In case 03NWR05012, comparative low bone density and incompletely ossified cranial sutures were attributed to immaturity, rather than malnutrition or other disease processes. In this animal, there was pronounced enlargement of cranial nerve VII and VIII apertures, which presumably facilitated intracranial parasitic invasion from the peribullar into the subtemporal regions. In six of eight pairs of ears examined, there was uni- and occasionally bilateral peribullar parasitism frequently invested with variable amounts of blood deposits, in case 03NWR06005 with middle ear involvement. The precise contribution of these parasitic burdens to stranding in more severely affected animals is unknown. In case 03NWR05005, 03NWR05011, and possibly 03NWR05007, the intracochlear hemorrhage appears to be independent of peribullar parasitism and most likely reflects a sequel to trauma or some other entity and may be an artifact of postmortem migration and pooling. With the exception of case 03NWR05003 and 03NWR05007, the acousto-vestibular and facial nerves were intact and well defined. The etiopathogenesis of the degenerative changes noted in these two cases is likely related to post mortem change and freeze artifact. The middle ears of virtually all the examined heads appeared normal with

discrete middle ear spaces, intact ossicles, round and oval windows, and well defined normally distributed corpus cavernosum.

Body Composition

Detailed morphometric analysis and comparison with established reference values (McLellan *et al*, 2002) revealed that five of six animals analyzed (03NWR05001, 03NWR05005, 03NWR05008, 03NWR05011, and 03NWR05012) were within normal body condition and one animal (03NWR06005) was severely emaciated. Mild emaciation or mild cachexia was noted in 03NWR05008 and 03NWR05001. Extensive post mortem scavenging precluded body composition assessment in the remaining four whole animals; minimum estimates of total body mass were determined and are listed in Table 3.

Parasitology

Parasites have been implicated in strandings of several species of cetaceans, particularly where infection affected the ears, brain or auditory nerves, or was so overwhelming that an animal developed severe pneumonia or enteritis (Geraci and St. Aubin, 1987; Morimitsu *et al.*, 1987). Although fecal floatation and sedimentation were unremarkable within each of the examined porpoises, histopathology confirmed the verminous pneumonia and biliary trematodiasis in all 10 examined carcasses, subcutaneous nematodiasis in four of 10 (03NWR05007, 03NWR05008, 03NWR05012 and 03NWR06005) and gastrointestinal helminthiasis in four of 10 porpoises (03NWR05005, 03NWR05006, 03NWR05012 and 03NWR06005). The relative intensity and distribution of gastrointestinal parasites in this case series was consistent with previous studies. The trematodes noted within the stomach of 03NWR05007 likely originated from the hepatobiliary tree and were refluxed from the duodenum. The lack of discernible ova or parasites within ingesta may be due to intermittent shedding, post mortem decomposition or some other factor(s). The peribullar (presumptive *Stenurus* spp) and subcutaneous parasitism due to *Crassicauda* spp in 03NWR05012 was more intense in this individual than examined cohorts. The intensity and distribution of the hypodermal (presumptive *Crassicauda* spp), gastrointestinal (*Anisakis* spp) and peribullar (likely *Stenurus* spp) parasites was enhanced in 03NWR06005 relative to other stranded animals and may be secondary to profound debilitation. The cutaneous diatoms noted in 03NWR05007 and 03NWR05012 were considered incidental findings of limited pathologic significance.

Virology and Ancillary Molecular Studies

Pooled lung, lymph node, spleen and brain were evaluated for dolphin morbillivirus by PCR and all cases were negative. Tissue culture on Mabin Darby and Vero cell lines failed to reveal any cytopathic effect in all 10 cases. In select cases, negative staining electron microscopy of conjunctival and oral mucosal scrapes failed to reveal any virus like particles. Aspirates of the epididymal abscess in case 03NWR05008 were negative by PCR for marine mammal variant and universal *Brucella* spp and the intralesional parasitic ova were considered significant. In case 03NWR06005, cerebrospinal fluid had a titer of 1:16 for canine distemper by virus neutralization. Due to the extent of blood

contamination and hemolysis, this result was interpreted as a false positive. Follow up PCR for canine distemper was negative and immunohistochemistry of representative lung sections for Morbillivirus were unremarkable. This case was positive by PCR for Mollicutes, which are considered secondary to impaired respiratory defenses associated with the profound necrotizing pneumonia.

Blubber Analysis

Blubber samples were collected from eight animals (Table 4). Percent lipid values ranged from 44-83%, which are similar to those reported previously for blubber of harbor porpoises stranded off the west coast of the U.S. (Calambokidis and Barlow, 1991). Concentrations of POPs were comparable to levels previously reported in West Coast harbor porpoises (Calambokidis and Barlow, 1991; Jarman *et al.*, 1996), and were much lower than those reported in presumably “healthy” harbor porpoises incidentally caught in a gill-net fishery off the northwest Atlantic coast (Tilbury *et al.*, 1997). The concentration of POPs in the harbor porpoises in this investigation were also significantly lower than that of a Southern Resident killer whale that stranded in Long Beach, Washington in April 2002 (NMFS/Northwest Fisheries Science Center, Environmental Conservation Division, unpub. data).

Bacteriology

Aerobic culture from multiple internal viscera of all 10 porpoises yielded pure to mixed, variable growth of 16 different species of bacteria with three cases that had no bacterial growth from select tissues (Table 5). Due to the lack of attendant inflammatory infiltrate, the *Clostridium perfringens* isolates from each of the 10 animals is attributed to post mortem overgrowth, and the most significant growth was the *Salmonella Newport* Group C2, from case 03NWR05006. *Escherichia coli* (non-hemolytic) was isolated from five cases, and alpha *Streptococcus* spp from four.

Trace Mineral and Vitamin A analysis

Trace mineral and vitamin A analysis of liver and kidney, with the exception of select samples, proved within normal limits (Table 6). Marginal increased liver magnesium were noted in three animals (03NWR05001, 03NWR05008, and 03NWR05011). These increased levels were not considered pathologically significant and increased calcium values in two porpoises (03NWR05005 and 03NWR05007) were considered secondary to dystrophic mineralization associated with the hepatobiliary trematodiasis. There was moderate reduction in liver vitamin A levels in one sample (03NWR05001), with no detectable levels in two additional animals (03NWR05005 and 03NWR06005). Due to the extent of post mortem change, it is difficult to resolve whether these reduced values represent post mortem degradation or hypovitaminosis A. Although there were no microscopic lesions consistent with vitamin A deficiency, the possibility of reduced levels and impaired immune function, particularly in case 03NWR06005, cannot be entirely discounted.

Stomach Prey Preliminary Analysis

Six of 10 examined stomachs lacked ingesta. Only scant fish bones, otoliths and squid beaks were identified in those animals with gastric contents. No freshly consumed prey

or prey tissue remains were present in any of the stomachs. A cursory examination of the otoliths and squid beaks during the preliminary sorting process revealed common prey items such as Pacific whiting (*Merluccius productus*) or pollock (*Theragra chalcogramma*), herring (*Clupea harengus pallasii*), sanddab (*Citharichthys sordidus*), an as yet unidentified sculpin (Cottidae) and market squid (Cephalopoda). No unusual prey remains were encountered, and the large number of empty stomachs and absence of freshly consumed prey is typical of findings over the last five years for evaluation of the stomach contents of stranded porpoises from the Pacific Northwest (W. Walker, pers comm.).

Pending Analyses

Detailed analysis of prey species and age determination from extracted teeth will be completed at the National Marine Mammal Laboratory, Seattle, Washington. Analyses of the behavioral reactions of marine mammals in response to sonar activities on 5 May 2003 will be conducted independently from this report. In addition, evaluation of exposure levels and cumulative effects from the sonar activities on marine mammals will be conducted separately.

DISCUSSION

The Stranding Network receives reports mostly from private citizens about stranded porpoises found on beaches or floating in the near-shore waters of Washington State in all months of the year. The number of reports received is subject to change according to beach attendance and public motivation/interest in responding to strandings. Stranding response in Washington State has increased in the past few years in part due to implementation of the Central Puget Sound Marine Mammal Stranding Network on Whidbey and Camano Islands in the late 1990s and through funding to support stranding network operations from the NMFS John H. Prescott Marine Mammal Rescue Assistance Grant Program.

Harbor porpoises are found along outer coastal beaches and around the inland waters of the state (Calambokidis *et al.*, 1987; Calambokidis *et al.*, 1997). The number of porpoise stranding events fluctuates annually and seasonally and varies by area. The majority of reported porpoise stranding events are dead animals and the number of animals reported varies seasonally and from year to year.

During the one month period from 2 May – 2 June, 2003, the Stranding Network received reports of 14 harbor porpoises dead on the beach, or floating along the outer coast, in the Strait of Juan de Fuca, and in the vicinity of Whidbey and San Juan Islands, in Washington. Several months following the investigation an additional report was submitted with information about a dead stranded harbor porpoise observed on 25 May on Lopez Island, bringing the total number of reports to 15. Of the 15 harbor porpoises, 13 animals stranded in the inland waters (*e.g.* east of the Pacific entrance to the Strait of Juan de Fuca) and two on the outer coast. In addition to the 15 harbor porpoises, one dead Dall's porpoise (*Phocoenoides dalli*) washed ashore briefly at Fidalgo Island on 14 May then was swept away by the tide (Figure 1, 03NWR05035). Dead porpoises were

also reported north of the U.S./Canada border, but were investigated separately (Appendix E).

Historically, spatial distribution of reported harbor porpoise stranding events has been highest in three main areas of the state where response effort and/or harbor porpoise density is greatest: (1) the San Juan Archipelago where there is both a high response effort and high density of porpoises; (2) Long Beach Peninsula where there is high population of private citizens during the summer months; and (3) the northwest corner of the state where there is high response effort. Between 1992 and 2002, there were 53 reports (80%) from the inland waters, compared to 13 reports from the outer coastal beaches (Table 9).

Table 9. Spatial distribution of harbor porpoise stranding events in Washington State for all months of the year (1992 –2003).

	<u>Inland waters</u>	<u>Outer coast</u>	<u>Totals</u>
<u>Year</u>			
1992	2	8	10
1993	6	2	8
1994	4	0	4
1995	5	0	5
1996	0	0	0
1997	2	0	2
1998	5	0	5
1999	2	0	2
2000	4	2	6
2001	14	1	15
2002	9	0	9
2003	19	6	25

Figure 1 shows the spatial distribution of the strandings of the animals included in this report. A majority (87%; n = 13) of harbor porpoise strandings took place in inland waters compared to the outer coast. More specifically, the inland water strandings were reported in three counties: (1) San Juan County (n = 5); (2) eastern Clallam County (n = 5); and (3) Island County (n = 3). All the strandings took place in May except one which occurred during the first week of June.

From January 1992 through December 2002, 66 harbor porpoise stranding events (in two of the reports, two animals stranded for a total of 68 individuals) were confirmed and/or investigated by members of the Network (NMFS, unpublished data – Appendix E). Annually, harbor porpoise stranding reports range from a low of zero in 1996 to a high of 15 in 2001 (Table 10). The mean yearly stranding event rate for harbor porpoises from

1992-2002 was 6.0 per year (SD = 6.1). In 2003, 25 stranded harbor porpoise events were reported. There was a significant difference between the number of harbor porpoise stranding events reported in 2003 compared to the mean number of stranding events reported over the previous 11 years ($\chi^2 = 28.15$, d.f. = 10, $p = 0.002$). When interpreting statistical analysis of stranding reports it is important to note that the sample size of reported porpoise strandings are relatively small and there are biases (*e.g.* variable geographic coverage, experience of responder) involved in the way data is collected by a predominantly volunteer stranding network.

Temporally, 27 (41%) of the total harbor porpoise strandings between 1992 and 2002 coincided with the late spring and early summer months (April - June) and ranged from a low of zero in 1996 to eight in 2001 (Table 10). Eight stranding events took place in April (30%), 16 in May (59%) and 3 in June (11%). The number of harbor porpoise strandings during April – June, 2003 was double the number reported in the previous highest year (2001). There was a significant difference between the number of harbor porpoise stranding events reported in April – May 2003 compared to the mean number of stranding events reported during the same months over the previous 11 years ($\chi^2 = 22.33$, d.f. = 10, $p = 0.014$). While this investigation focused on harbor porpoises that stranded in the time period surrounding the 5 May *USS SHOUP* activities, all marine mammal strandings which occurred from 1 April – 30 June (Appendix G) were also reviewed to look for any unusual stranding patterns.

Table 10. Harbor porpoise stranding events in Washington State 1992 – 2003 (April – June).

	April	May	June	Total		Total number events for year	Percent of annual stranding
Year							
1992	0	2	0	2		10	20
1993	1	2	1	4		8	50
1994	0	1	0	1		4	25
1995	2	0	0	2		5	40
1996	0	0	0	0		0	0
1997	0	1	0	1		2	50
1998	2	0	0	2		5	40
1999	0	1	0	1		2	50
2000	1	0	0	1		6	17
2001	1	7	0	8		15	53
2002	1	2	2	5		9	56
2003	1	14	1	16		25	64

Intensive post mortem examination and ancillary testing on 11 of the 15 harbor porpoises that stranded between 2 May and 2 June 2003 did not reveal any definitive signs of acoustic trauma that could be associated with the 5 May 2003 active mid-range tactical

sonar system used by the *USS SHOUP* or other reported acoustic events. Over 70 percent of the porpoises examined were graded by the team as moderate to advanced post mortem decomposition at the time of necropsy. A presumptive or definitive cause of death could be determined for five of 11 animals examined (Table 7). Of these five animals, there were two cases of agonal or perimortem blunt force trauma, a single case of fibrinous peritonitis, one porpoise with salmonellosis, and one with a profound necrotizing pneumonia. The examinations did not reveal any definitive signs of acoustic trauma in any of the porpoises examined. Inner ear trauma or noise-induced hearing loss could not be ruled out due to the condition of the carcasses. The multidisciplinary team noted that lesions consistent with acoustic trauma can be difficult to interpret or obscured, especially in animals in advanced post mortem decomposition.

Although, to the best of our knowledge, lesions associated with acoustic trauma have not been previously documented in harbor porpoises, sonar related strandings and pathology have been observed in other species. In March 2000, a multispecies mass stranding of 17 cetaceans (*Ziphius cavirostris*, *Mesoplodon densirostris*, *Balaenoptera acutorostrata*, *Stenella frontalis*) was discovered in the Bahamas (U.S. Depart. of Commerce and Secretary of the Navy, 2001). During the Bahamas event, stranded animals were found up to 36 hours after naval sonar deployment with most animals reported as live beachings within 12 hours of transit of multiple ships. Seven of the animals were known to have died and ten animals were returned to the water alive. In contrast, there were no live strandings of Washington porpoises, and animals were recovered sporadically throughout the entire month. From an epidemiologic perspective, the sample size is too small and biased to infer a specific relationship with respect to sonar usage and subsequent strandings.

The May 2003 increase in harbor porpoise strandings may be coincidental, biased by increased reporting efforts, and/or unrelated to sonar use. Observations of the May 5 sonar activities were highly publicized which could have resulted in increased awareness and reporting of porpoise strandings. In addition to the sonar activities on 5 May, hydrophone operators submitted audio files of sounds, they identified as sonar, dated 9 December 2002, 24 April 2003 and 4 May 2003. NMFS also received video footage labeled “porpoises and Navy Sonar 25 April 03”. There were, however, no reported strandings in December 2002 and only one harbor porpoise was reported stranded but not collected in April 2003. This could be biased by less intensive carcass monitoring and recovery efforts or other unknown factors. Prior to any publicity following 5 May, the Stranding Network, as part of its usual activities, was engaged in recovering stranded porpoises. Three of the 11 porpoises examined for cause of death in this investigation were recovered prior to 5 May, three on 5 and 6 May and the remaining five during the subsequent weeks. Clearly the sonar exercises of the *USS SHOUP* on 5 May could not have affected the animals collected prior to 5 May. However, in light of other reported events, all carcasses were thoroughly examined for possible links to sonar or other acoustic activities regardless of the date collected.

Determining the cause of death in an animal can be affected by various factors including carcass decomposition, handling, transport, and lack of clear or consistent gross or

microscopic findings, as well as the lack of validated (standardized) species specific diagnostic assays. In previous strandings associated with sonar, significant gross findings included acute hemorrhage within the inner ear, subarachnoid space, and lateral ventricles (U.S. Depart of Commerce and Secretary of the Navy, 2001). In a recent case report of stranded cetaceans in the Canary Islands, multisystemic intravascular microcavitations and emphysema formation were consistently observed (Jepson *et al.*, 2003). In this porpoise investigation, the pathologies that were consistently identified within the examined harbor porpoises were related to post mortem change, freezing artifact, or were not considered sufficiently severe to account for the loss of these animals. Although seven porpoises were assigned a condition code of 2 (fresh) at time of initial observation, by the time the animals were collected, stored and then necropsied, most carcasses had undergone significant post mortem decomposition (Table 1).

Overlying the basi-occipital and cranial cervical regions of the spinal cord of five porpoises, as well as involving the retrobullar and peribullar spaces of seven individuals in this investigation, there was variable degrees of hemorrhage, with some hematoma formation (03NWR05001, 03NWR05005, 03NWR05008, 03NWR05011, 03NWR05012). Although these anatomic regions may be considered predilection sites for acoustic-related injury, in this case series, the hemorrhage and hematoma formation is most consistent with agonal thrashing associated with stranding, or intralesional nematode parasites. There was no consistent evidence of retrobullar, extra-ocular (two of eight examined animals), nor ventricular hemorrhage in the brain. Based on histopathology, the grossly noted submeningeal dark red fluid was considered unassociated with acute hemorrhage and more likely represented post mortem and cyclic freeze-thaw artifact. In one of nine animals, circumferentially involving the sub-epiglottic mucosa, there was moderate submucosal congestion with variable extravascular accumulation of proteinaceous material. Additional recuts and special stains failed to conclusively demonstrate hemoglobin and due to the extent of post mortem change, the precise nature of this material is unknown.

In this investigation, due to the number of people involved in responding to, collecting, transporting and thawing the carcasses, it was not possible to maintain a standardized approach to track body position or orientation during each of these procedures. Further, individual animals were stored in freezers of different types including frost-free freezers, which have freeze-thaw cycles, that were also considered a potential source for free blood or hemorrhagic artifact. Therefore, definitive differentiation amongst congestion, hypostasis, and red staining of tissues found during necropsy examinations (antemortem versus perimortem injury or post mortem dependent pooling) was hindered. The reddened tissue discoloration observed in all the animals was considered to be related to a combination of freezer artifact and autolytic (liquefactive) change.

In animals that present with no historical information or prior clinical evaluation and in advanced stages of autolysis, the precise cause of death cannot always be determined. Over the course of the last 4-5 years, a precise cause of death has not been determined in approximately 50% of necropsied animals from southern British Columbia and northern Washington State (S. Raverty, unpub. data). Post mortem decomposition or insufficient

time from the initial insult to development of histologically or grossly definitive lesions may hamper precise determination of a cause of death. Due to the state of decomposition and the very nature of strandings which provide only snapshots of information in the life of an animal, comprehensive biological data on all important factors and acute or chronic disease state in any of these animals was not available.

CONCLUSION

Based on the stranding profile for the years 1992 to 2002, the number of harbor porpoise strandings in 2003 represented a statistically significant greater number of strandings than in previous years. Likewise, there was a significant difference between the numbers of harbor porpoise stranding events reported in April – May 2003 compared to the mean number of stranding events reported during the same months over the previous 11 years. No common cause for the increased number of harbor porpoise strandings observed in Washington State from 2 May – 2 June 2003 was found. A presumptive cause of death was determined for five of 11 harbor porpoises that were examined and/or scanned. Lesions consistent with or diagnostic for acoustic trauma were not identified in any of the 11 porpoises that were examined. The multidisciplinary team noted that lesions consistent with acoustic trauma can be difficult to interpret or obscured, especially in animals in advanced post mortem decomposition. The possibility of acoustic trauma as a contributory factor in the mortality of the porpoises examined could not be ruled out. Very little is known about acoustic trauma as a mortality factor in cetaceans and further investigation into its pathogenesis and impact is warranted. Furthermore, efforts to support the prompt and systematic search and recovery of stranded marine mammal carcasses in the region may benefit future such investigations, should they occur.

ACKNOWLEDGMENTS

Many individuals contributed to the porpoise stranding investigation and this report. Foremost, we would like to thank the respective institutions of each team member for enabling their participation in this investigation. The Northwest Marine Mammal Stranding Network responded to stranding reports and assisted with collecting data and samples for the investigation. We appreciate the tireless efforts of this predominantly volunteer network to assist us in this investigation and our stranding program. We also wish to thank a number of individuals and programs for their support. Marianne Tomita, NWR provided invaluable technical assistance in preparing the report. The National Marine Mammal Laboratory provided generous use of freezer space and access to their necropsy facilities. The Marine Mammal Health and Stranding Response Program supported travel of the Scientific Investigation Team members. Bill Walker provided gastrointestinal parasite and prey identification. Gina Ylitalo conducted contaminant analyses. CT scans were conducted at the Center for Diagnostic Imaging in Mountlake Terrace, WA. Joe Scordino, Deputy Regional Administrator, Northwest Region, NOAA, provided advice and guidance throughout the investigation and preparation of this report.

A number of scientists provided valuable comments on the preliminary report including Roger Gentry, Brandon Southall, Tom Lipscomb, Dick Stroud, Pete Schroeder, and Ken Balcomb.

LITERATURE CITED

- Calambokidis, J. and Barlow, J. 1991. Chlorinated hydrocarbon concentrations and their use for describing population discreteness in harbor porpoises in Washington, Oregon, and California. In: Marine mammal strandings in the United States. Reynolds III, J.E. and Odell, D.K. (Eds.). Proceedings of the Second Marine Mammal Stranding Workshop, 3-5 December 1987, Miami, FL, pp. 101-110. U.S. Dep. Commerc., NOAA Tech. Rep. 98.
- Calambokidis, J., Steiger, G.H., and J.C. Cabbage. 1987. Marine mammals in the southwestern Strait of Juan de Fuca: natural history and potential impacts of harbor development in Neah Bay. Final report prepared by Cascadia Research Collective, Olympia, WA, for the Seattle District, Army Corps of Engineers, Seattle, WA, Contract No. DACW67-85-M-0046, 103 p.
- Calambokidis, J., Osmek, S., and Laake, J.L. 1997. Survey report for the 1997 aerial surveys for harbor porpoise and other marine mammals of Oregon, Washington, and British Columbia outside waters. Cascadia Research Collective, Olympia, Washington, USA. 36pp.
- Calle, P.P., Stetter, M.D., Cook, R.A., McClave, C.A., and Massucci, S. 1995. Enteric salmonellosis of captive Pacific walrus (*Odobenus rosmarus divergens*), in *Proceedings of the 26th Annual Workshop of the International Association of Aquatic Animal Medicine*, 92-93.
- Foster, G., Patterson, I.A., and Munro, D.S. 1999. Monophasic group B Salmonella species infecting harbour porpoises (*Phocoena phocoena*) inhabiting Scottish coastal waters. *Veterinary Microbiology* 65(3):227-231.
- Gearin, P.J., Melin, S.R., DeLong, R.L., Kajimura, H. and Johnson, M.A. 1994. Harbor porpoise interactions with a Chinook salmon set-net fishery in Washington State. *Report of the International Whaling Commission* (special issue) 15:427-438.
- Geraci, J.R. and St. Aubin, D.J. 1987. Effects of parasites on marine mammals. *International Journal for Parasitology* 17:407-414.
- Geraci, J.R. and Lounsbury, V.J. 1993. Specimen and data collection. Pp. 175-228 in *Marine Mammals Ashore: A Field Guide for Strandings*, Geraci, J.R. and Lounsbury, V.J. (Eds.). Texas A&M Sea Grant Program, Galveston. 305pp.
- Holmes, R.W, Nagasawa, S and Takano, H. 1993. The morphology and geographic distribution of epidermal diatoms of the Dall's porpoise (*Phocoenoides dalli*) in the northern Pacific ocean. *Bulletin of the National Science Museum, Tokyo, Series B* 19(1):1-18.
- Jarman, W.M., Norstrom, R.J., Muir, D.C.G., Rosenberg, B., Simon, M. and Baird, R.W. 1996. Levels of organochlorine compounds, including PCDDs and PCDFs, in

- the blubber of cetaceans from the West Coast of North America. *Marine Pollution Bulletin* 32:426-436.
- Jepson, P.D., Arbelo, M., Deaville, R., Patterson, I.A.P., Castro, P., Baker, J.R., Degollada, E., Ross, H.M., Herráez, P., Pocknell, A.M., Rodríguez, F., Howie, F.E., Espinosa, A., Reid, R.J., Jaber, J.R., Martín, V., Cunningham, A.A. and Fernández, A. 2003. Gas-bubble lesions in stranded cetaceans. *Nature* 425: 575.
- McLellan, W.A., Koopman, H.N., Rommel, S.A., Read, A.J., Potter, C.W., Westgate, A.J. and Pabst, D.A. 2002. Ontogenetic allometry and body composition of harbour porpoises (*Phocoena phocoena*, L.) from the western North Atlantic. *Journal of Zoology, London* 257(4):457-472.
- Morimitsu, T., Nagai, T., Ide, M., Kawano, H., Naichuu, A., Koono, M. and Ishii, A. 1987. Mass stranding of odontocete caused by parasitogenic eight cranial neuropathy. *Journal of Wildlife Diseases* 23:586-590.
- Raga, J., Aznar, F., Balbuena, J. and Fernandez, M. 2002. Parasites. Pp 867-876 in *Encyclopedia of marine mammals*, first edition, Perrin, W.F., Würsig, B. and Thewissen, J.G. (Eds.). Academic Press, San Diego, CA. 1414 pp.
- Read, A. J. and Murray, K.T. 2000. Gross evidence of human-induced mortality in small cetaceans. NOAA Technical Memorandum NMFS-OPR-15. 21pp.
- Reidarson, T.H., McBain, J.F., Dalton, L.M. and Rinaldi, M.G. 2001. Mycotic diseases. Pp. 337-355 in *Handbook of marine mammal diseases*, second edition, Dierauf, L.A. and Gulland, F.M.D. (Eds.). CRC Press, Boca Raton, FL. 1063 pp.
- Schroeder, R.J., Delli Ouadre, C.A., McIntyre, R.W., and Walker, W.A. 1973. Marine mammal disease surveillance program in Los Angeles County. *Journal of the American Veterinary Medical Association* 163(6): 580-581.
- Sloan, C.A., Brown, D.W., Pearce, R.W., Boyer, R.H., Bolton, J.L., Burrows, D.G., Herman, D.P. and Krahn, M.M. In press. Determining aromatic hydrocarbons in sediments and tissues using accelerated solvent extraction and gas chromatography/mass spectrometry. *In: Aquatic Toxicology-Volume 2*, Ostrander, G.K. (Ed.). CRC Press, Boca Raton, FL.
- Smith, W.A, Mazet, J.A. and Hirsh, D.C. 2002. Salmonella in California wildlife species: prevalence in rehabilitation centers and characterization of isolates. *Journal of Zoo and Wildlife Medicine* 33(3):228-235
- Thornton, S.M., Nolan, S. and Gulland, F.M.D. 1998. Bacterial isolates from California sea lions (*Zalophus californianus*), harbor seals (*Phoca vitulina*) and northern elephant seals (*Mirounga angustirostris*) admitted to a rehabilitation center along the central California coast. *Journal of Zoo and Wildlife Medicine* 29:171-176.

Tilbury, K.L., Stein, J.E., Meador, J.P., Krone, C.A. and Chan, S.-L. 1997. Chemical contaminants in harbor porpoise (*Phocoena phocoena*) from the north Atlantic coast: tissue concentrations and intra- and inter-organ distribution. *Chemosphere* 34(9/10):2159-2181.

United State Department of Commerce and the Secretary of the Navy. 2001. Joint Interim Report: Bahamas Marine Mammal Stranding Event of 15-16 March 2000. 59 pp.

United States Navy. 2004. Report on the Results of the Inquiry into Allegations of Marine Mammal Impacts surrounding the Use of Active Sonar by USS SHOUP (DDG 86) in the Haro Strait on or about 5 May 2003. 52pp.

GLOSSARY

Agonal: Occurring at the moment of or just before death.

Antemortem: Before death.

Anterior: Situated in front of or in the forward part of an organ, toward the head end of the body.

Atelectasis: The collapse of part or all of a lung by blockage of the air passages (bronchus or bronchioles), or by very shallow breathing.

Autolyzed: Enzymatic, bacterial or self-digestion of cells or tissues after death.

Avulsed: Torn off from.

Basioccipital: Pertaining to the back of the skull or head.

Commensal: Living in a state of commensalism which is a relation between two kinds of organisms in which one obtains food or other benefits from the other without damaging or benefiting it.

Comminuted: Reduced to small particles.

Computerized tomography: The creation of an image displaying anatomic information, created by a computer synthesis of x-ray transmission data obtained in several different directions in a given plane.

Congestion: Excessive or abnormal accumulation of fluid (e.g., blood) in a tissue or organ.

Contusion: An injury of a part without a break in the skin; a bruise.

Diffuse: Widely distributed.

Dura mater: The outermost (and toughest) of the three membranes (meninges) covering the brain and spinal cord.

Ectatic: Distended or dilated.

Edema: An abnormal infiltration and excess accumulation of serous fluid in connective tissue.

Erythema: Abnormal redness of the skin due to vascular congestion and hyperemia.

Etiology: The cause(s) or origin of a disease.

Extravasation: A discharge or escape, as of blood, from a vessel into the tissues.

Fascia: A band or sheet of fibrous tissue deep to the skin.

Florid: In full bloom; occurring in fully developed form.

Fibrosis: The formation of a scar.

Gross findings: Observations of organs and tissues that are visible to the naked eye.

Hemorrhage: The escape of blood from the vessels (often associated with an organized clot). The effect of hemorrhage depends on the rate, volume and location of the bleeding.

Histological findings: The branch of anatomy that deals with the minute structure, composition, and function of these tissues (histopathological findings: the histology of diseased tissues).

Hypostasis: The gravitational settling of blood in the dependent parts of an organ or body.

Imbibe: Absorb a liquid (such as blood).

Inferior: Situated below, or directed downward; used in reference to the lower surface of an organ or structure.

Inguinal: Of, relating to, or found in the groin.

Lesion: Wound, injury, or pathological change in a tissue.

Lividity: Discoloration of dependent parts due to the gravitation of blood.

Morbidity: Condition of being diseased or sick.

Morphology: The science of the form and structure of organisms, organs and tissues.

Necrosis: The sum of the morphological changes indicative of cell degeneration and death and caused by a complex disruption and progression of subcellular processes. It may affect groups of cells or part of a structure or an organ.

Parenchyma: The functional elements of an organ (as distinguished from its framework, or stroma).

Pathology: The branch of science concerned with all aspects of disease, especially the essential nature of disease, with special reference to the structural and functional changes in tissues and organs of the body which cause or are caused by disease.

Per os: By mouth.

Peribullar: Around the bullae, the tissues and space surrounding the bony housing of the ear.

Perimortem: Around the time of death.

Peritonitis: Refers to inflammation of the peritoneum, a membrane that covers the surfaces of both the organs that lie in the abdominal cavity and the inner surface of the abdominal cavity itself.

Perivascular: Situated around a vessel.

Petechial: Characterized by pinpoint, nonraised, well delineated, purplish red spots caused by intradermal or submucosal bleeding.

Pia mater: The innermost of the three membranes (meninges) covering the brain and spinal cord.

Post mortem: After death.

Posterior: Situated in back of, or in the back part of, or affecting the back part of a structure.

Pulmonary: Pertaining to the lungs.

Purulent: Containing, consisting of, or being pus.

Sequela: A consequence of disease or injury.

Serosa: An enclosing thin membrane.

Significant finding: A finding that would be expected to have a nontrivial negative impact on the health of an animal.

Subcutaneous: Beneath the skin (includes the epidermis and dermis [blubber]).

Superior: Situated above, or directed upward.

Vitreous humor: Fluid contained within the eye.

Figure 1. Reported porpoise strandings in Washington State 2 May - 2 June 2003
(Courtesy of B. Hanson)

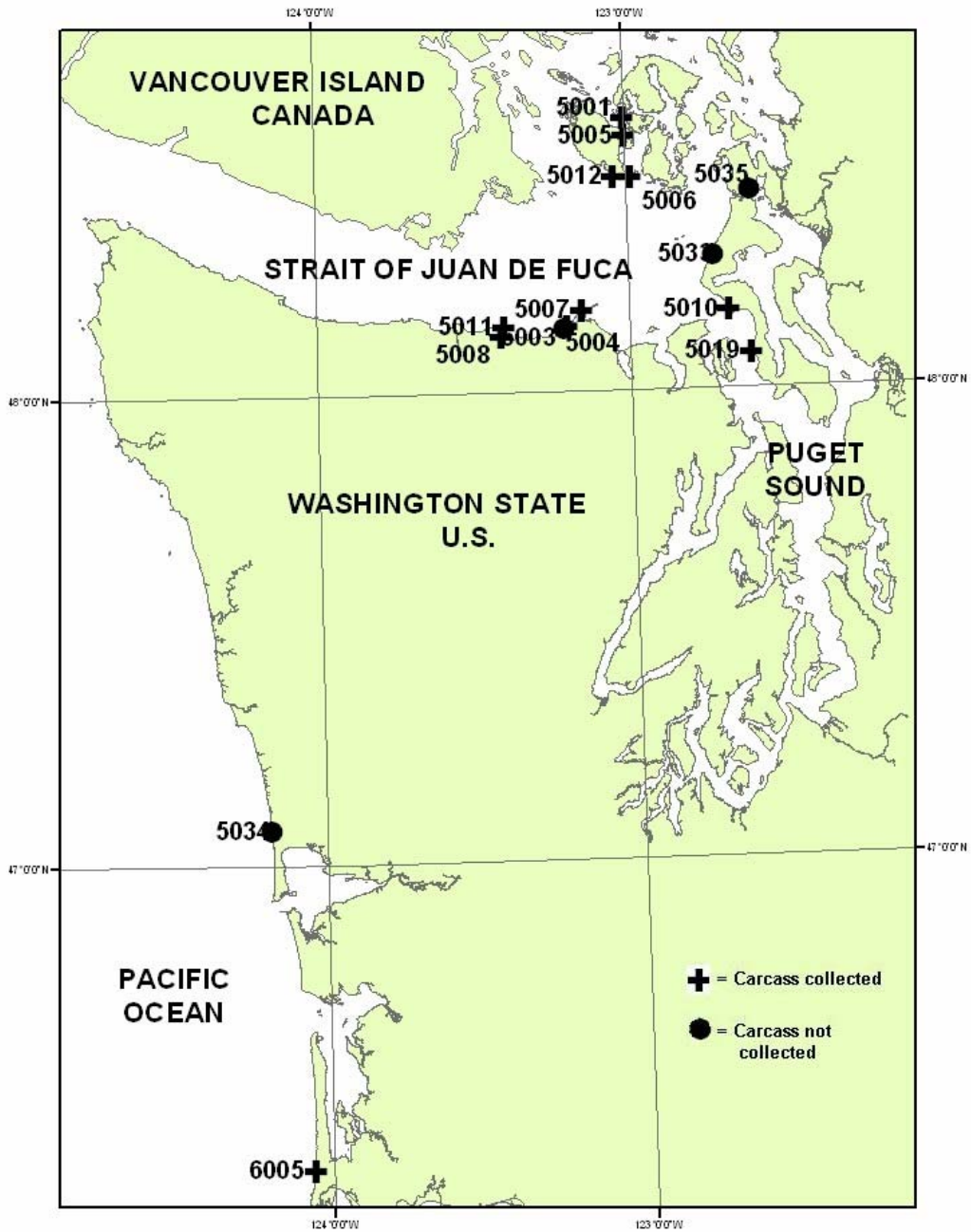


Table 1. Reported harbor porpoise stranding events in Washington State – 2 May to 2 June 2003.

Date of initial observation	Location	County	Initial carcass condition	Field ID	Registration number	Sex	Date collected	CT Scan 7/20/03	Necropsy date	Carcass condition code at necropsy	Cause of death
5/2/2003	Neck Point, Shaw Island	San Juan	2	2003-SJ006	03NWR05001	F	5/2/2003	yes	7/23/2003	3	Not determined
5/4/2003	County Park, Dungeness Spit	Clallam	4	DNG-03-002	03NWR05003	F	05/08/03 head & fetus collected	yes	N/E	4+	N/E
5/4/2003	County Park, Dungeness Spit	Clallam	4	N/E	03NWR05004	U	not collected	no	N/E	N/E	N/E
5/4/2003	Jackson Beach, San Juan Island	San Juan	3	2003-SJ007	03NWR05005	F	5/5/2003	no	7/24/2003	3	Not determined
5/5/2003	South Beach, San Juan Island	San Juan	3	2003-SJ008	03NWR05006	F	5/5/2003	yes	7/23/2003	3	Salmonella septicemia
5/6/2003	Dungeness Spit	Clallam	2	DNG-03-001	03NWR05007	F	5/6/2003	yes	7/22/2003	2+	Not determined
5/6/2003	Ennis Creek, Discovery Trail	Clallam	3	OCNMS03Pp01	03NWR05008	M	5/6/2003	yes	7/23/03-head; 7/24/03-body	4	Not determined (peritonitis maybe contributory)
5/12/2003	West Beach, Whidbey Island	Island	unknown	N/E	03NWR05033	U	not collected	no	N/E	N/E	N/E
5/12/2003	Ocean City	Grays Harbor	3	N/E	03NWR05034	U	not collected	no	N/E	N/E	N/E
5/13/2003	Admiralty Head, Whidbey Island	Island	2	WIC051303SD	03NWR05010	M	5/13/2003	no	7/24/2003	3+	Not determined (likely occipital base fracture)
5/16/2003	Ediz Hook, Port Angeles	Clallam	2	OCNMS03Pp02	03NWR05011	F	5/16/2003	yes	7/23/2003	3	Cranial fractures
5/17/2003	Lagoon Point, Whidbey Island	Island	2	WIE051703SB	03NWR05019	F	5/17/2003	no	7/23/2003	3	Not determined
5/20/2003	Eagle Point, San Juan Island	San Juan	2	2003-SJ009	03NWR05012	M	5/20/2003	yes	7/23/2003	2	Not determined
5/25/03	Flint Beach, SJI	San Juan	4	2003-SJ020	03NWR05046	U	not collected	No	N/E	N/E	N/E
6/2/2003	Long Beach	Pacific	2	CRC-490	03NWR06005	M	6/2/2003	yes	7/22/2003	2	Bronchopneumonia

2 = fresh, 3 = moderate decomposition, 4 = advanced decomposition

Table 2. Freezer type and specifications used to store and transport harbor porpoise carcasses prior to necropsy.

Manufacturer/Model	Type (top-load/chest vs. walk-in)	Location	Cycle type	Carcass Number(s)
Kalt Thermoguard	Walk-in	NOAA/National Marine Mammal Lab (Building 4)	Frost-free (-20 - 0 F)	03NWR05012
Horeco (model unknown)	Walk-in	NOAA/National Marine Mammal Lab (Building 32)	Frost-free	All specimens
Kenmore 11233	Top-load	University of Washington/Friday Harbor Laboratory	Manual defrost	03NWR05001 03NWR05005 03NWR05006
Kenmore (model unknown)	Top-load	Center for Whale Research	Manual defrost	03NWR05012
Kenmore 13551	Top-load	NOAA/Office of Protected Resources	Manual defrost	03NWR05001 03NWR05003 03NWR05006 03NWR05007 03NWR05008 03NWR05011 03NWR05012 03NWR06005
Kenmore 67519231796	Top-load	USFWS/Dungeness National Wildlife Refuge	Manual defrost	03NWR05007

Table 3. Body composition of harbor porpoises (*Phocoena phocoena*) examined at necropsy. Comparative “normal” data are from Atlantic harbor porpoises presented in McLellan *et al.* (2002).

ID #	Sex	TL (cm)	TBM (kg)	Blubber mass (kg)	"Normal" blubber mass (kg)	Blubber /TBM (%)	"Normal" blubber /TBM (%)	Axial muscle mass (kg)	"Normal" axial muscle mass (kg)	Axial muscle /TBM (%)	"Normal" axial muscle /TBM (%)	Notes
03NMR05001	F	136	39*	N/E	10.88 +/- 1.17	CBD	29.47 +/- 3.16	7.39	8.44 +/- 1.94	CBD	21.65 +/- 2.41	Scavenger damage limited blubber and % analyses
03NWR05005	F	126	33.5*	13.59	10.88 +/- 1.18	CBD	29.47 +/- 3.17	6.44	8.44 +/- 1.95	CBD	21.65 +/- 2.41	Axial muscle mass within normal range
03NWR05006	F	152	48.5*	N/E		CDB		N/E		CBD		Blubber mass higher than normal
03NWR05007	F	145.5	38.5*	N/E				7.56	**8.44 +/- 1.95			Axial muscle mass slightly below normal range
03NWR05008	M	146	N/E	N/E	12.79 +/- 1.69	CBD	24.69 +/- 2.46	N/E	11.54 +/- 1.76	CBD	24.59 +/- 2.03	Severe decomposition
03NWR05010	M	154	N/E	N/E		CBD		N/E		CBD		Severe decomposition and scavenger damage
03NWR05011	F	136.5	37*	12.72	10.88 +/- 1.18	CBD	29.47 +/- 3.17	6.70	8.44 +/- 1.95	CBD	21.65 +/- 2.41	Scavenger damage limited % analyses
												Blubber mass higher than normal
												Axial muscle mass within normal range
03NWR05019	F	138	37.5*	N/E		CBD		N/E		CBD		Decomposition and scavenger damage
03NWR05012	M	123	30	9.15	10.00 +/- 1.70	29.7	29.62 +/- 2.04	5.36	6.98 +/- 1.19	17.9	20.06 +/- 2.04	Total mass of this specimen slightly below that of normal range for immature males (34.7 +/- 4.5 kg)
												Blubber within normal range
												Axial muscle below normal range
03NWR06005	M	146	39	8.98	12.79 +/- 1.69	23.03	24.69 +/- 2.46	8.08	11.54 +/- 1.76	20.71	24.59 +/- 2.03	Total mass of this specimen below that of normal range for mature males (47.1 +/- 4.9 kg)
												Blubber mass, axial muscle mass and
												Axial muscle/TBM(%) below normal range

If scavenger damage precluded collecting blubber and/or axial mass on both sides, reported values represent 2 times the value for a single side. Blubber and axial muscles are bilaterally symmetric (McLellan *et al.* 2002).

* = Minimum estimate of total body mass (TBM) due to tissue loss or carcass decomposition. TL = Total length CBD = Could not be determined

Table 4. Concentrations of selected persistent organic pollutants measured in blubber of harbor porpoises stranded at various sites in Washington State (May – June 2003).

Registration number	Sex	Age class†	Length (cm)	Carcass condition	Percent lipid	ng/g, wet weight			ng/g, lipid weight						
						β-HCH	HCB	∑CHLDS	∑DDTs	∑PCBs	β-HCH	HCB	∑CHLDS	∑DDTs	∑PCBs
03NWR05005	F	Immature	126	Mod. dec.§	74	400	430	1,200	5,600	5,900	540	580	1,600	7,600	8,000
03NWR05001	F	Immature	136	Fresh	68	190	190	560	2,300	2,600	280	280	820	3,400	3,800
03NWR05011	F	Immature	137	Fresh	75	240	210	640	3,100	3,000	320	280	850	4,100	4,000
03NWR05019	F	Immature	138	Fresh	75	230	270	670	2,700	3,700	310	360	890	3,600	3,600
03NWR05006	F	Immature	152	Mod. dec.§	83	270	280	730	3,400	3,400	330	340	880	4,100	4,100
03NWR05007	F	Immature	146	Fresh	70	330	330	980	4,400	5,800	470	470	1,400	6,300	8,300
03NWR05012	M	Immature	123	Fresh	69	310	250	880	3,800	4,500	450	360	1,300	5,500	6,500
					<i>Overall immature mean ± SE</i>	<i>280 ± 29</i>	<i>280 ± 33</i>	<i>810 ± 92</i>	<i>3,600 ± 460</i>	<i>4,100 ± 540</i>	<i>390 ± 41</i>	<i>380 ± 44</i>	<i>1,100 ± 130</i>	<i>4,900 ± 640</i>	<i>5,500 ± 850</i>
03NWR06005	M	Adult	146	Fresh	44	250	39	1,200	5,700	6,800	570	89	2,700	13,000	15,000

¶Results of analyses from Environmental Conservation Division, NWFSC, NMFS, Seattle, WA

†Age class of each animal estimated from length data using information from Gearin PJ, Melin SR, DeLong RL, Kajimura H, Johnson MA (1994)

§Mod. dec. = moderately decomposed

Table 5. Bacteriology results for harbor porpoise specimens.

Bacteria Isolated	03NWR05001	03NWR05005	03NWR05006	03NWR05007
<i>Acinetobacter sp.</i>			kidney, thymus, mesenteric l.n.	
<i>Actinetobacter johnsonii</i>	thymus, thoracic fluid			
<i>Aeromonas hydrophila</i>		spleen, thymus, lung, spinal cord, liver, hilar l.n., mediastinal l.n.		
<i>Clostridium perfringens</i>	small intestine	intestine	small intestine	small intestine
<i>Enterobacter sp.</i>		spleen, thymus, spinal cord, liver, hilar l.n., mediastinal l.n.		brain, mammary gland, spleen, spinal cord, thymus, hemothorax, mesenteric l.n., lung
<i>Enterococcus sp.</i>				
<i>Escherichia coli - non hemolytic</i>	small intestine, thymus, spleen, kidney, liver, mesenteric l.n.			
<i>Moraxella sp.</i>				
<i>Proteus sp.</i>	mesenteric l.n.			
<i>Pseudomonas sp.</i>	small intestine, thymus, spleen, mediastinal l.n., lung, mesenteric l.n., spinal cord	spleen, liver, hilar l.n.		
<i>Pseudomonas flourescens</i>				lung
<i>Psychrobacter sp.</i>				
<i>Raoultella terrigena</i>				
<i>Salmonella newport Group C2</i>			Hilar l.n., kidney, lung, spleen, liver, thymus, mesenteric l.n., small intestine	
<i>Streptococcus (non-hemolytic)</i>				mammary milk
<i>Streptococcus sp.(alpha)</i>	small intestine	intestine		
no bacteria isolated		kidney, urine		

Table 5. Bacteriology results for harbor porpoise specimens.

Bacteria Isolated	03NWR05008	03NWR05010	03NWR05011	03NWR05019	03NWR05012	03NWR06005
<i>Acinetobacter</i> sp.						
<i>Actinetobacter johnsonii</i>						
<i>Aeromonas hydrophila</i>		liver, kidney, mesenteric l.n., lung, brain, spleen		spleen, lumbar l.n., kidney, liver, brain, spinal cord, lung, pericolic l.n., small intestine		
<i>Clostridium perfringens</i>	small intestine	small intestine	small intestine, colon	small intestine	small intestine	large intestine
<i>Enterobacter</i> sp.	lungs, spleen, mesenteric l.n., epididymis abscess					
<i>Enterococcus</i> sp.		liver, kidney, mesenteric l.n., lung, brain, spleen, small intestine	liver, thymus, spleen, mesenteric l.n., urine, kidney, lung, spinal cord			
<i>Escherichia coli</i> - non hemolytic	kidney, lungs, mesenteric l.n.	liver, kidney, mesenteric l.n., lung, brain, spleen, small intestine	kidney, lung, spinal cord, small intestine, colon		spinal cord, lung, kidney, small intestine	
<i>Moraxella</i> sp.						prescapular l.n., brain, kidney, spleen
<i>Proteus</i> sp.						
<i>Pseudomonas</i> sp.						
<i>Pseudomonas fluorescens</i>						
<i>Psychrobacter</i> sp.				spleen, lumbar l.n., kidney, liver, brain, sp. cord, lung, pericolic l.n., small intestine		
<i>Raoultella terrigena</i>						liver, prescapular l.n., brain, mesenteric l.n., spleen, lung, liver swab, kidney
<i>Salmonella newport</i> Group C2						
<i>Streptococcus</i> (non-hemolytic)	liver					
<i>Streptococcus</i> sp.(alpha)	kidney, lungs, spleen, mesen. l.n., sm. int. epididymis abscess				mediastinal l.n., lung, kidney	
no bacteria isolated					liver, spleen	abdominal fluid

Table 6. Trace mineral and Vitamin A analyses of liver, kidney and vitreous humor.

	03NWR 05001	03NWR 05005	03NWR 05006	03NWR 05007	03NWR 05008	03NWR 05010	03NWR 05011	03NWR 05012	03NWR 05019	03NWR 06005	Reference range (Porpoise and dolphin)
LIVER											
Se (ppm)	2.98	1.99	1.6	4.24	12.43	5.93	2.11	2.92	3.19	10.56	0.90-38.0
Cu (ppm)	8	5	8	6.3	10.2	5.9	9	12	12.6	12.9	4.0-60.0
Zn (ppm)	59	25	40	27	36	47	62	41	56	84	22-120
Fe (ppm)	307	221	212	230	261	278	210	225	228	236	130-300
Mn (ppm)	5.8	3.8	4.6	3.5	5.7	5	6.5	4.9	4.8	5.5	1.0-10.0
Pb (ppm)	<2	<2	<2	<2	<2	<2	<2	<2	<2	<2	<1.0
Cd (ppm)	0.2	<0.2	<0.2	<0.2	0.3	0.3	<0.2	<0.2	<0.2	0.6	<0.1-12.0
Ca (ppm)	92	314	49	302	78	96	133	65	39	46	38-200
Mg (ppm)	330	166	192	203	410	511	260	219	194	210	130-280
Vit A (mcg/g)	120	51	714	340	355	1011	520	800	298	<5	250-3000
Retinol (mcg/g)	82	35	457	219	172	710	318	419	186	<3	
Retinol palmitate (mcg/g)	46	16	256	120	183	301	202	381	112	<3	
KIDNEY											
Cu (ppm)	3.3	4.1	4	5.9	4.8	4.1	4.2	6.2	5.3	3.8	3.0-7.9
Zn (ppm)	24	27	26	26	25	28	28	29	26	25	16-44
Fe (ppm)	146	115	158	112	215	151	123	106	159	69	90-150
Mn (ppm)	1.5	1.5	1.7	1.6	2.5	1.4	1.5	1.5	1.6	1.6	1.0-3.0
Pb (ppm)	<2	<2	<2	<2	<2	<2	<2	<2	<2	<2	<1.0
Cd (ppm)	0.5	0.2	0.6	0.5	1.1	0.9	0.2	0.5	0.4	2.4	0.08-72.0
Ca (ppm)	154	79	179	148	323	98	167	134	127	160	60-150
Mg (ppm)	371	152	251	193	351	137	193	170	280	185	120-240
VITREOUS											Reference range (cattle)
Ca (mg/dl)		8.8		6.4		7.7		5.3	8	5.8	6.0-7.5
Mg (mg/dl)		10.32		7.04		20.79		5.24	10.4	4.94	1.9
P (mg/dl)		37		72		64		40	46	51	1.9-2.7
BUN (mg/dl)		54.5		73.9		57		113.4	52.1	59.8	9-16(serum)

Bold type indicates value(s) outside of reference range.

Table 7. Summary of post mortem findings in harbor porpoises stranded in Washington State (2 May – 2 June 2003).

Field Number	03NWR05001	03NWR05005	03NWR05006	03NWR05007	03NWR05008	03NWR05010	03NWR05011	03NWR05012	03NWR05019	03NWR06005
Findings										
Human interaction						MC*	MC*			
Emaciation					+ IF	+ IF				+++ MC
Fractures										
Occipital bone						++ MC				
Cranium							++++ LC			
Inner ears										
Intracochlear hemorr.				+ IF						
Peribullar hemorrhage	++ IF	+ IF	++ MC		+ IF	+ IF		++ MC		+++ MC
Salmonellosis			++ LC							
Spinal cord										
Clot formation	+ IF	++ IF			+ IF		+ IF			
Skin										
Diatoms				+ IF				+ IF		
Lung										
Pneumonia										++++ LC
Colon										
Hypertrophy										++++ MC
Abdominal Cavity										
Peritonitis/serositis			+ MC							
Epididymis										
Abscess					+ IF					
Parasites										
Lung worm	+ IF	+ IF	++ IF	+ IF	++ IF	+ IF	+ IF	+ IF	++ IF	+++ MC
Biliary	+ IF	++ IF	+ IF	++ IF	++ IF	+ IF	++ IF	++ IF	++ IF	+++ IF
Subcutaneous				+ IF	++ IF					+++ IF
Gastrointestinal		+ IF	+++ IF							+++ IF
Peribullar	/+ F	+ IF			++/+ IF	++/+ IF	++/+ IF	+++/+ (MC)	++/+ IF	+++/+ IF
Intracranial								+++ (MC)		

left/right side of animal

Legend: Severity of condition
+ mild
++ moderate
+++ marked
++++ severe

Contribution to death of animal
LC Likely the cause of death
MC May be the cause of death/May have contributed to death
IF Incidental finding (not linked to cause of death)
* Speculative - could be due to predation.

Table 8. Summary table of CT scan results.

Anatomic Site	Case Number	
	03NWR05001	03NWR05003
Ears		
Peribullar regions		
left	extensive parasitism and good pneumatization	Aerated and normal
right	clot formation and good pneumatization	Aerated and normal
Internal Auditory Canal		
left	well defined and intact	canals normal
right	well defined and intact	canals normal
Acou-to-Vestibular/Fascial Nerve		
left	intact and well defined	partially degenerate nerves
right	intact and well defined	partially degenerate nerves
Middle ear		
left	no significant findings, distinct middle ear spaces and well defined corpus cavernosum	Aerated, retracted corpus cavernosum, intact ossicles, round and oval windows
right	no significant findings, distinct middle ear spaces and well defined corpus cavernosum	Aerated, retracted corpus cavernosum, intact ossicles, round and oval windows
Inner ear		
left	canals symmetric and normal	symmetric and apparently normal canals
right	canals symmetric and normal	symmetric and apparently normal canals

Table 8. Summary table of CT scan results.

Anatomic Site	Case Number	
	03NWR05006	
Ears		03NWR05007
Peribullar regions		
left	well aerated and normal	clear and well aerated, well defined suspensory ligament
right	dorsal retrobullar space, extensive hemorrhage	clear and well aerated, well defined suspensory ligament
Internal Auditory Canal		
left	no evidence of hemorrhage or parasitism, left tympanic bone partially demineralized	no evidence of blood or abnormal material
right	intact and well defined canal	no evidence of blood or abnormal material
Acousto-Vestibular/Facial Nerve		
left	internal auditory canal well defined	intact, but in some sections, degenerative change evident
right	intact and well defined	intact, but in some sections, degenerative change evident
Middle ear		
left	normal with distinct middle ear space and well defined corpus cavernosum, round and oval windows normal	distinct air spaces, well defined corpus cavernosum, normal ossicles and round windows
right	normal with distinct middle ear space and well defined corpus cavernosum	distinct air spaces, well defined corpus cavernosum, normal ossicles and round windows
Inner ear		
left	no significant findings	canals symmetric and normal, possible intracochlear blood
right	no significant findings	canals symmetric and normal, possible intracochlear blood

Table 8. Summary table of CT scan results

Anatomic Site	Case Number			
	03NWR05008			03NWR06005
Ears				
Peribullar regions				
left	two masses (organized clot and moderate parasitism) and bone fractures	generally clear, well aerated, substantial parasitism	intact, moderate density parasitic masses and no other significant findings	extensive parasitism
right	no significant findings	generally clear, well aerated, moderate parasitism	intact and no significant findings	extensive parasitism
Internal Auditory Canal				
left	no significant findings	normal and unremarkable	intact and no significant findings	no significant findings
right	no significant findings	normal and unremarkable	intact and no significant findings	no significant findings
Acousto-Vestibular/Fascial Nerve				
left	no significant findings	normal	intact and no significant findings	no significant findings
right	no significant findings	normal	intact and no significant findings	no significant findings
Middle ear				
left	no significant findings	clearly delineated air spaces and well defined corpus cavernosum	intact and no significant findings	extensive parasitism
right	no significant findings	clearly delineated air spaces and well defined corpus cavernosum	intact and no significant findings	extensive parasitism
Inner ear				
left	in apical and middle turns, blood	symmetric and normal, normal intracochlear fluid	normal, no evidence of blood or other intracochlear abnormalities	no significant findings
right	in apical and middle turns, blood	symmetric and normal, normal intracochlear fluid	normal, no evidence of blood or other intracochlear abnormalities	no significant findings

Appendix A. – Level A stranding form

MARINE MAMMAL STRANDING REPORT - LEVEL A DATA

FIELD # _____ NMFS REGIONAL # _____ (NMFS USE) NATIONAL DATABASE# _____ (NMFS USE)

COMMON NAME: _____ GENUS: _____ SPECIES: _____

EXAMINER Letterholder: _____

Name: _____ Affiliation: _____

Address: _____ Phone: _____

<p>LOCATION</p> <p>State: _____ County: _____</p> <p>City: _____</p> <p>Locality Details: _____</p> <p>Latitude: _____ N</p> <p>Longitude: _____ W</p>	<p>OCCURRENCE DETAILS MS#: _____ (NMFS USE)</p> <p>Mass Stranding: <input type="checkbox"/> YES <input type="checkbox"/> NO # Animals: _____</p> <p>Signs of Human Interaction: <input type="checkbox"/> YES <input type="checkbox"/> NO <input type="checkbox"/> Could not be Determined (CBD)</p> <p>(Check one or more) <input type="checkbox"/> 1. Boat Collision <input type="checkbox"/> 3. Fishery Interaction</p> <p><input type="checkbox"/> 2. Shot <input type="checkbox"/> 4. Other Human Interaction: _____</p> <p>How determined: <input type="checkbox"/> External Exam <input type="checkbox"/> Internal Exam <input type="checkbox"/> Not Examined</p> <p>Other Causes: <input type="checkbox"/> YES <input type="checkbox"/> NO <input type="checkbox"/> CBD Describe: _____</p>
---	---

<p>DATE OF INITIAL OBSERVATION</p> <p>Year: _____ Month: _____ Day: _____</p> <p>STATUS (Check ONE)</p> <p><input type="checkbox"/> 1. Alive <input type="checkbox"/> 4. Advanced Decomposition</p> <p><input type="checkbox"/> 2. Fresh Dead <input type="checkbox"/> 5. Mummified/Skeletal</p> <p><input type="checkbox"/> 3. Moderate Decomposition <input type="checkbox"/> 6. Dead - Condition Unknown</p>	<p>DATE OF EXAMINATION (LEVEL- A) <input type="checkbox"/> Not Able to Examine</p> <p>Year: _____ Month: _____ Day: _____</p> <p>CONDITION (Check ONE)</p> <p><input type="checkbox"/> 1. Alive <input type="checkbox"/> 4. Advanced Decomposition</p> <p><input type="checkbox"/> 2. Fresh Dead <input type="checkbox"/> 5. Mummified/Skeletal</p> <p><input type="checkbox"/> 3. Moderate Decomposition <input type="checkbox"/> 6. Dead - Condition Unknown</p>
---	--

<p>INITIAL LIVE ANIMAL DISPOSITION (Check one or more)</p> <p><input type="checkbox"/> 1. Left at Site <input type="checkbox"/> 5. Euthanized at Site</p> <p><input type="checkbox"/> 2. Immediate Release at Site <input type="checkbox"/> 6. Died at Site</p> <p><input type="checkbox"/> 3. Relocated <input type="checkbox"/> 7. Transferred to Rehabilitation</p> <p><input type="checkbox"/> 4. Disentangled <input type="checkbox"/> 8. Died during Transport</p> <p><input type="checkbox"/> 9. Other</p> <p>CONDITION (Check ONE)</p> <p><input type="checkbox"/> 1. Sick <input type="checkbox"/> 3. Apparently Healthy <input type="checkbox"/> 5. Other</p> <p><input type="checkbox"/> 2. Injured <input type="checkbox"/> 4. Out of Habitat</p> <p>Date: _____ Rehabilitation Facility: _____</p> <p>Comments: _____</p>	<p>MORPHOLOGICAL DATA</p> <p>SEX (Check ONE) AGE CLASS (Check ONE)</p> <p><input type="checkbox"/> 1. Male <input type="checkbox"/> 1. Adult <input type="checkbox"/> 4. Pup/Calf</p> <p><input type="checkbox"/> 2. Female <input type="checkbox"/> 2. Subadult <input type="checkbox"/> 5. Unknown</p> <p><input type="checkbox"/> 3. Unknown <input type="checkbox"/> 3. Yearling</p> <p>Straight Length: _____ <input type="checkbox"/> cm <input type="checkbox"/> in <input type="checkbox"/> actual <input type="checkbox"/> estimate</p> <p>Weight: _____ <input type="checkbox"/> kg <input type="checkbox"/> lb <input type="checkbox"/> actual <input type="checkbox"/> estimate</p> <p>PHOTOS/VIDEOS TAKEN: <input type="checkbox"/> YES <input type="checkbox"/> NO</p> <p>Disposition: _____</p>
--	--

<p>TAG DATA</p> <table style="width: 100%; border-collapse: collapse;"> <thead> <tr> <th style="text-align: left;">ID #</th> <th style="text-align: left;">Color</th> <th style="text-align: left;">Type * Placement</th> <th style="text-align: left;">Applied</th> <th style="text-align: left;">Present</th> </tr> </thead> <tbody> <tr> <td>_____</td> <td>_____</td> <td>(Circle ONE) D DF L LF LR RF RR</td> <td><input type="checkbox"/></td> <td><input type="checkbox"/></td> </tr> <tr> <td>_____</td> <td>_____</td> <td>D DF L LF LR RF RR</td> <td><input type="checkbox"/></td> <td><input type="checkbox"/></td> </tr> <tr> <td>_____</td> <td>_____</td> <td>D DF L LF LR RF RR</td> <td><input type="checkbox"/></td> <td><input type="checkbox"/></td> </tr> </tbody> </table> <p>* D = Dorsal, DF = Dorsal Fin, L = Lateral Body LF = Left Front, LR = Left Rear, RF = Right Front, RR = Right Rear</p>	ID #	Color	Type * Placement	Applied	Present	_____	_____	(Circle ONE) D DF L LF LR RF RR	<input type="checkbox"/>	<input type="checkbox"/>	_____	_____	D DF L LF LR RF RR	<input type="checkbox"/>	<input type="checkbox"/>	_____	_____	D DF L LF LR RF RR	<input type="checkbox"/>	<input type="checkbox"/>	<p>WHOLE CARCASS DISPOSAL (Check one or more)</p> <p><input type="checkbox"/> 1. Left at site <input type="checkbox"/> 4. Rendered <input type="checkbox"/> 7. Unknown</p> <p><input type="checkbox"/> 2. Buried <input type="checkbox"/> 5. Sunk</p> <p><input type="checkbox"/> 3. Towed <input type="checkbox"/> 6. Frozen for Later Examination</p> <p>SPECIMEN DISPOSITION (Check one or more)</p> <p><input type="checkbox"/> 1. Scientific collection</p> <p><input type="checkbox"/> 2. Educational collection</p> <p><input type="checkbox"/> 3. Other: _____</p> <p>Comments: _____</p> <p>NECROPSIED <input type="checkbox"/> YES <input type="checkbox"/> NO Date: _____</p> <p>NECROPSIED BY: _____</p>
ID #	Color	Type * Placement	Applied	Present																	
_____	_____	(Circle ONE) D DF L LF LR RF RR	<input type="checkbox"/>	<input type="checkbox"/>																	
_____	_____	D DF L LF LR RF RR	<input type="checkbox"/>	<input type="checkbox"/>																	
_____	_____	D DF L LF LR RF RR	<input type="checkbox"/>	<input type="checkbox"/>																	

NOAA Form 89-864 (rev. 6-01) OMB No. 0648-0178; Expires May 31, 2004

PLEASE USE THE BACK SIDE OF THIS FORM FOR ADDITIONAL REMARKS

Appendix B. – Level A stranding forms for stranded harbor porpoises 2 May – 2 June 2003

MARINE MAMMAL STRANDING REPORT

NW-2003-1000774
SID# (NMFS USE)

FIELD NO.: 2003-5J004 NMFS REGISTRATION NO.: 03NW05001
COMMON NAME: Harbor porpoise GENUS: Phocoena SPECIES: phocoena
EXAMINER: J. Gaydos Agency: The Whale Museum Phone: 360 378-4710
Address: PO Box 945 Friday Harbor WA

To Submit 7/20

LOCATION State: WA County: San Juan City: _____ Locality Details: _____ Floating off Neck Pt., Shaw Island *Latitude: _____ N *Longitude: _____ W	TYPE OF OCCURRENCE Mass Stranding: <input type="checkbox"/> Yes <input checked="" type="checkbox"/> No # Animals _____ Human Interaction: <input type="checkbox"/> Yes <input type="checkbox"/> No <input checked="" type="checkbox"/> ? Check one: <input type="checkbox"/> 1. Boat Collision <input type="checkbox"/> 2. Shot <input type="checkbox"/> 3. Fishery Interaction <input type="checkbox"/> 4. Other _____ How determined: _____ Other Causes (if known): _____
--	---

DATE OF INITIAL OBSERVATION: Yr. 2003 Mo. 5 Day 2 CONDITION: Check one: <input type="checkbox"/> 1. Alive <input checked="" type="checkbox"/> 2. Fresh dead <input type="checkbox"/> 3. Moderate decomp. <input type="checkbox"/> 4. Advanced decomp. <input type="checkbox"/> 5. Mummified <input type="checkbox"/> ?. Unknown	DATE OF EXAMINATION: Yr. 2003 Mo. 5 Day 2 CONDITION: Check one: <input type="checkbox"/> 1. Alive <input checked="" type="checkbox"/> 2. Fresh dead <input type="checkbox"/> 3. Moderate decomp. <input type="checkbox"/> 4. Advanced decomp. <input type="checkbox"/> 5. Mummified <input type="checkbox"/> ?. Unknown
--	--

LIVE ANIMAL — Condition and Disposition: Check one or more: <input type="checkbox"/> 1. Released at site <input type="checkbox"/> 2. Sick <input type="checkbox"/> 3. Injured <input type="checkbox"/> 4. Died <input type="checkbox"/> 5. Euthanized <input type="checkbox"/> 6. Rehabilitated and released <input type="checkbox"/> ?. Unknown Transported to: _____ <input type="checkbox"/> Died <input type="checkbox"/> Released Date: _____	TAGS APPLIED?: <input type="checkbox"/> Yes <input checked="" type="checkbox"/> No TAGS PRESENT?: <input type="checkbox"/> Yes <input checked="" type="checkbox"/> No <table border="0"> <tr> <td></td> <td>Dorsal</td> <td>Left</td> <td>Right</td> </tr> <tr> <td>Tag No.(s):</td> <td>_____</td> <td>_____</td> <td>_____</td> </tr> <tr> <td>Color(s):</td> <td>_____</td> <td>_____</td> <td>_____</td> </tr> <tr> <td>Type:</td> <td>_____</td> <td>_____</td> <td>_____</td> </tr> <tr> <td>Placement</td> <td></td> <td>Front/Rear</td> <td>Front/Rear</td> </tr> </table>		Dorsal	Left	Right	Tag No.(s):	_____	_____	_____	Color(s):	_____	_____	_____	Type:	_____	_____	_____	Placement		Front/Rear	Front/Rear
	Dorsal	Left	Right																		
Tag No.(s):	_____	_____	_____																		
Color(s):	_____	_____	_____																		
Type:	_____	_____	_____																		
Placement		Front/Rear	Front/Rear																		

CARCASS — Disposition: Check one: <input type="checkbox"/> 1. Left at site <input type="checkbox"/> 2. Buried <input type="checkbox"/> 3. Towed <input checked="" type="checkbox"/> 4. Sci. collection: (see below) <input type="checkbox"/> 5. Edu. collection: (see below) <input type="checkbox"/> 6. Other _____ <input type="checkbox"/> ?. Unknown NECROPSIED? <input checked="" type="checkbox"/> Yes <input type="checkbox"/> No 7/23/03	MORPHOLOGICAL DATA: Sex — Check one: <input type="checkbox"/> 1. Male <input checked="" type="checkbox"/> 2. Female Immature <input type="checkbox"/> ?. Unknown Straight Length: 136 _____ <input type="checkbox"/> cm <input type="checkbox"/> in <input type="checkbox"/> est *Weight 39 _____ <input type="checkbox"/> kg <input type="checkbox"/> lb <input type="checkbox"/> est PHOTOS TAKEN? <input checked="" type="checkbox"/> Yes * <input type="checkbox"/> No * during necropsy
---	--

REMARKS: Collected for necropsy. Stored in FTL freezer

DISPOSITION OF TISSUE/SKELETAL MATERIAL: _____

6/23/03

To scan 7/2
To rotten

MARINE MAMMAL STRANDING REPORT - LEVEL A DATA

FIELD #: DN6-03-002 NMFS REGIONAL #: 03NWROS003 NATIONAL DATABASE #: NW-2003-1000776

COMMON NAME: porpoise GENUS: _____ SPECIES: _____

EXAMINER: _____ Letterholder: _____

Name: Pam Sanguinetti Affiliation: USFWS

Address: 33 S. Barr Rd Port Angeles WA 98362 Phone: 360 457 8451

LOCATION		OCCURRENCE DETAILS		MS#: _____
State: <u>WA</u>	County: <u>Clallam</u>	Mass Stranding: <input type="checkbox"/> YES <input checked="" type="checkbox"/> NO	# Animals: _____	(NMFS USE)
City: <u>Sequim</u>	Locality Details: <u>1 mile S of Dungeness Spit</u>	Signs of Human Interaction: <input type="checkbox"/> YES <input type="checkbox"/> NO <input checked="" type="checkbox"/> Could Not be Determined (CBD)		
Latitude: <u>48° 08' 19.9" N</u>	Longitude: <u>123° 11' 52.6" W</u>	(Check one or more) <input type="checkbox"/> 1. Boat Collision <input type="checkbox"/> 3. Fishery Interaction		
		<input type="checkbox"/> 2. Shot <input type="checkbox"/> 4. Other Human Interaction: _____		
		How determined: <input type="checkbox"/> External Exam <input type="checkbox"/> Internal Exam <input type="checkbox"/> Not Examined		
		Other Causes: <input type="checkbox"/> YES <input type="checkbox"/> NO <input type="checkbox"/> CBD Describe: _____		

DATE OF INITIAL OBSERVATION	DATE OF EXAMINATION (LEVEL A) <input type="checkbox"/> Not Able to Examine
Year: <u>2003</u> Month: <u>05</u> Day: <u>04</u>	Year: <u>2003</u> Month: <u>05</u> Day: <u>18</u>

STATUS (Check ONE)	CONDITION (Check ONE)
<input type="checkbox"/> 1. Alive <input type="checkbox"/> 4. Advanced Decomposition	<input type="checkbox"/> 1. Alive <input checked="" type="checkbox"/> 4. Advanced Decomposition
<input type="checkbox"/> 2. Fresh Dead <input type="checkbox"/> 5. Mummified/Skeletal	<input type="checkbox"/> 2. Fresh Dead <input type="checkbox"/> 5. Mummified/Skeletal
<input checked="" type="checkbox"/> 3. Moderate Decomposition <input type="checkbox"/> 6. Dead - Condition Unknown	<input type="checkbox"/> 3. Moderate Decomposition <input type="checkbox"/> 6. Dead - Condition Unknown

INITIAL LIVE ANIMAL DISPOSITION (Check one or more)	MORPHOLOGICAL DATA
<input type="checkbox"/> 1. Left at Site <input type="checkbox"/> 5. Euthanized at Site	SEX (Check ONE) <input type="checkbox"/> 1. Male <input checked="" type="checkbox"/> 2. Female <input type="checkbox"/> 3. Unknown
<input type="checkbox"/> 2. Immediate Release at Site <input type="checkbox"/> 6. Died at Site	AGE CLASS (Check ONE) <input checked="" type="checkbox"/> 1. Adult <input type="checkbox"/> 4. Pup/Calf
<input type="checkbox"/> 3. Relocated <input type="checkbox"/> 7. Transferred to Rehabilitation	<input type="checkbox"/> 2. Subadult <input type="checkbox"/> 5. Unknown
<input type="checkbox"/> 4. Disentangled <input type="checkbox"/> 8. Died During Transport	<input type="checkbox"/> 3. Yearling
<input type="checkbox"/> 9. Other	

CONDITION (Check ONE)	Straight Length: <u>200</u> <input checked="" type="checkbox"/> cm <input type="checkbox"/> in <input type="checkbox"/> actual <input checked="" type="checkbox"/> estimate
<input type="checkbox"/> 1. Sick <input type="checkbox"/> 3. Apparently Healthy <input type="checkbox"/> 5. Other	Weight: _____ <input type="checkbox"/> kg <input type="checkbox"/> lb <input type="checkbox"/> actual <input type="checkbox"/> estimate
<input type="checkbox"/> 2. Injured <input type="checkbox"/> 4. Out of Habitat	

Date: _____ Rehabilitation Facility: _____

Comments: _____

PHOTOS/VIDEOS TAKEN: YES NO ATTACHED

Disposition: _____

TAG DATA	WHOLE CARCASS DISPOSAL (Check one or more)
ID# Color Type *Placement (Circle One) Applied Present	<input checked="" type="checkbox"/> 1. Left at Site <input type="checkbox"/> 4. Rendered <input type="checkbox"/> 7. Unknown
D DF L LF LR RF RR <input type="checkbox"/> <input type="checkbox"/>	<input type="checkbox"/> 2. Buried <input type="checkbox"/> 5. Sunk
D DF L LF LR RF RR <input type="checkbox"/> <input type="checkbox"/>	<input type="checkbox"/> 3. Towed <input type="checkbox"/> 6. Frozen for Later Examination
D DF L LF LR RF RR <input type="checkbox"/> <input type="checkbox"/>	
D DF L LF LR RF RR <input type="checkbox"/> <input type="checkbox"/>	

SPECIMEN DISPOSITION (Check one or more)

1. Scientific Collection CT scan only of head

2. Educational Collection

3. Other: _____

Comments: Removed head/fetus*

gave to Brad - NMFS

*D=Dorsal; DF=Dorsal Fin; L=Lateral Body
LF=Left Front; LR=Left Rear; RF=Right Front; RR=Right Rear

NECROPSIED YES NO Date: _____

NECROPSIED BY: _____

6/23/03

MARINE MAMMAL STRANDING REPORT - LEVEL A DATA

FIELD # DN6 03 003 NMFS REGIONAL 03NDRO5004 NATIONAL DATABASE # 1103-10007

COMMON NAME: harbor porpoise GENUS: Phocoena SPECIES: phocoena

EXAMINER: _____ Letterholder: _____
 Name: Pam Sanguinetti Affiliation: U.S. Fish & Wildlife Service
 Address: 33 S. Barr Rd Port Angeles WA 98302 Phone: 360 457 8451

LOCATION State: <u>WA</u> County: <u>Clallam</u> City: <u>Sequim</u> Locality Details: <u>2 miles south of Hungeness Spit Pass</u> Latitude: _____ N Longitude: _____ W	OCCURRENCE DETAILS Mass Stranding: <input type="checkbox"/> YES <input checked="" type="checkbox"/> NO # Animals: _____ (NMFS USE) Signs of Human Interaction: <input type="checkbox"/> YES <input type="checkbox"/> NO <input type="checkbox"/> Could Not be Determined (CBD) (Check one or more) <input type="checkbox"/> 1. Boat Collision <input type="checkbox"/> 3. Fishery Interaction <input type="checkbox"/> 2. Shot <input type="checkbox"/> 4. Other Human Interaction: _____ How determined: <input type="checkbox"/> External Exam <input type="checkbox"/> Internal Exam <input type="checkbox"/> Not Examined Other Causes: <input type="checkbox"/> YES <input type="checkbox"/> NO <input type="checkbox"/> GBD Describe: _____
---	--

DATE OF INITIAL OBSERVATION Year: <u>2003</u> Month: <u>5</u> Day: <u>4</u> <u>By Refuge visitors</u> STATUS (Check ONE) <input type="checkbox"/> 1. Alive <input checked="" type="checkbox"/> 4. Advanced Decomposition <u>Described as scavenged</u> <input type="checkbox"/> 2. Fresh Dead <input type="checkbox"/> 5. Mummified/Skeletal <input type="checkbox"/> 3. Moderate Decomposition <input type="checkbox"/> 6. Dead - Condition Unknown	DATE OF EXAMINATION (LEVEL A) <input checked="" type="checkbox"/> Not Able to Examine Year: _____ Month: _____ Day: _____ <u>could not locate</u> CONDITION (Check ONE) <input type="checkbox"/> 1. Alive <input type="checkbox"/> 4. Advanced Decomposition <input type="checkbox"/> 2. Fresh Dead <input type="checkbox"/> 5. Mummified/Skeletal <input type="checkbox"/> 3. Moderate Decomposition <input type="checkbox"/> 6. Dead - Condition Unknown
---	---

INITIAL LIVE ANIMAL DISPOSITION (Check one or more) <input type="checkbox"/> 1. Left at Site <input type="checkbox"/> 5. Euthanized at Site <input type="checkbox"/> 2. Immediate Release at Site <input type="checkbox"/> 6. Died at Site <input type="checkbox"/> 3. Relocated <input type="checkbox"/> 7. Transferred to Rehabilitation <input type="checkbox"/> 4. Disentangled <input type="checkbox"/> 8. Died During Transport <input type="checkbox"/> 9. Other CONDITION (Check ONE) <input type="checkbox"/> 1. Sick <input type="checkbox"/> 3. Apparently Healthy <input type="checkbox"/> 5. Other <input type="checkbox"/> 2. Injured <input type="checkbox"/> 4. Out of Habitat Date: _____ Rehabilitation Facility: _____ Comments: _____	MORPHOLOGICAL DATA SEX (Check ONE) AGE CLASS (Check ONE) <input type="checkbox"/> 1. Male <input type="checkbox"/> 1. Adult <input type="checkbox"/> 4. Pup/Calf <input type="checkbox"/> 2. Female <input checked="" type="checkbox"/> 2. Subadult <input type="checkbox"/> 5. Unknown <input type="checkbox"/> 3. Unknown <input type="checkbox"/> 3. Yearling Straight Length: _____ <input type="checkbox"/> cm <input type="checkbox"/> in <input type="checkbox"/> actual <input type="checkbox"/> estimate Weight: _____ <input type="checkbox"/> kg <input type="checkbox"/> lb <input type="checkbox"/> actual <input type="checkbox"/> estimate PHOTOS/VIDEOS TAKEN: <input checked="" type="checkbox"/> YES <input checked="" type="checkbox"/> NO Disposition: <u>described as smaller than And animal - ? < 84cm</u>
---	--

TAG DATA <table border="1" style="width: 100%; border-collapse: collapse;"> <thead> <tr> <th>ID#</th> <th>Color</th> <th>Type</th> <th>*Placement (Circle One)</th> <th>Applied</th> <th>Present</th> </tr> </thead> <tbody> <tr> <td>_____</td> <td>_____</td> <td>_____</td> <td>D DF L LF LR RF RR</td> <td><input type="checkbox"/></td> <td><input type="checkbox"/></td> </tr> <tr> <td>_____</td> <td>_____</td> <td>_____</td> <td>D DF L LF LR RF RR</td> <td><input type="checkbox"/></td> <td><input type="checkbox"/></td> </tr> <tr> <td>_____</td> <td>_____</td> <td>_____</td> <td>D DF L LF LR RF RR</td> <td><input type="checkbox"/></td> <td><input type="checkbox"/></td> </tr> </tbody> </table>	ID#	Color	Type	*Placement (Circle One)	Applied	Present	_____	_____	_____	D DF L LF LR RF RR	<input type="checkbox"/>	<input type="checkbox"/>	_____	_____	_____	D DF L LF LR RF RR	<input type="checkbox"/>	<input type="checkbox"/>	_____	_____	_____	D DF L LF LR RF RR	<input type="checkbox"/>	<input type="checkbox"/>	WHOLE CARCASS DISPOSAL (Check one or more) <input checked="" type="checkbox"/> 1. Left at Site <input type="checkbox"/> 4. Rendered <input type="checkbox"/> 7. Unknown <input type="checkbox"/> 2. Buried <input type="checkbox"/> 5. Sunk <input type="checkbox"/> 3. Towed <input type="checkbox"/> 6. Frozen for Later Examination SPECIMEN DISPOSITION (Check one or more) <input type="checkbox"/> 1. Scientific Collection <input type="checkbox"/> 2. Educational Collection <u>not collected</u> <input type="checkbox"/> 3. Other: _____ Comments: _____
ID#	Color	Type	*Placement (Circle One)	Applied	Present																				
_____	_____	_____	D DF L LF LR RF RR	<input type="checkbox"/>	<input type="checkbox"/>																				
_____	_____	_____	D DF L LF LR RF RR	<input type="checkbox"/>	<input type="checkbox"/>																				
_____	_____	_____	D DF L LF LR RF RR	<input type="checkbox"/>	<input type="checkbox"/>																				

ADDITIONAL COMMENTS: _____
 *D=Dorsal; DF=Dorsal Fin; L=Lateral Body
 LF=Left Front; LR=Left Rear; RF=Right Front; RR=Right Rear
 NECROPSIED YES NO Date: _____
 NECROPSIED BY: _____

6/23/03

MARINE MAMMAL STRANDING REPORT

NW-2003-1000778
SID#

(NMFS USE)

FIELD NO.: 2003-SJ007 NMFS REGISTRATION NO.: 03NWRO5005
 COMMON NAME: Harbor Porpoise GENUS: Phocoena SPECIES: phocoena
 EXAMINER Name: R. Osborne Agency: The Whale Museum Phone: 360 378-4710
 Address: PO Box 945 Friday Harbor WA

LOCATION State: <u>WA</u> County: <u>San Juan</u> City: _____ Locality Details: _____ <u>Jackson Beach</u> <u>San Juan Island</u> *Latitude: _____ N *Longitude: _____ W	TYPE OF OCCURRENCE Mass Stranding: <input type="checkbox"/> Yes <input checked="" type="checkbox"/> No # Animals <u>1</u> Human Interaction: <input checked="" type="checkbox"/> Yes <input type="checkbox"/> No <input checked="" type="checkbox"/> ? Check one: <input type="checkbox"/> 1. Boat Collision <input type="checkbox"/> 2. Shot <input checked="" type="checkbox"/> 3. Fishery Interaction <input type="checkbox"/> 4. Other _____ How determined: <u>Tangled in Fishing Net</u> Other Causes (if known): _____
--	---

DATE OF INITIAL OBSERVATION: Yr. <u>2003</u> Mo. <u>5</u> Day <u>4</u> CONDITION: Check one: <input type="checkbox"/> 1. Alive <input type="checkbox"/> 2. Fresh dead <input checked="" type="checkbox"/> 3. Moderate decomp. <input type="checkbox"/> 4. Advanced decomp. <input type="checkbox"/> 5. Mummified <input type="checkbox"/> ? Unknown	DATE OF EXAMINATION: Yr. <u>2003</u> Mo. <u>5</u> Day <u>5</u> CONDITION: Check one: <input type="checkbox"/> 1. Alive <input type="checkbox"/> 2. Fresh dead <input checked="" type="checkbox"/> 3. Moderate decomp. <input type="checkbox"/> 4. Advanced decomp. <input type="checkbox"/> 5. Mummified <input type="checkbox"/> ? Unknown
--	--

LIVE ANIMAL — Condition and Disposition: Check one or more: <input type="checkbox"/> 1. Released at site <input type="checkbox"/> 2. Sick <input type="checkbox"/> 3. Injured <input type="checkbox"/> 4. Died <input type="checkbox"/> 5. Euthanized <input type="checkbox"/> 6. Rehabilitated and released <input type="checkbox"/> ? Unknown Transported to: _____ <input type="checkbox"/> Died <input type="checkbox"/> Released Date: _____	TAGS APPLIED?: <input type="checkbox"/> Yes <input type="checkbox"/> No TAGS PRESENT?: <input type="checkbox"/> Yes <input type="checkbox"/> No <table style="width: 100%; border-collapse: collapse;"> <tr> <td></td> <td style="text-align: center;">Dorsal</td> <td style="text-align: center;">Left</td> <td style="text-align: center;">Right</td> </tr> <tr> <td>Tag No.(s):</td> <td>_____</td> <td>_____</td> <td>_____</td> </tr> <tr> <td>Color(s):</td> <td>_____</td> <td>_____</td> <td>_____</td> </tr> <tr> <td>Type:</td> <td>_____</td> <td>_____</td> <td>_____</td> </tr> <tr> <td>Placement</td> <td></td> <td style="text-align: center;">Front/Rear</td> <td style="text-align: center;">Front/Rear</td> </tr> </table>		Dorsal	Left	Right	Tag No.(s):	_____	_____	_____	Color(s):	_____	_____	_____	Type:	_____	_____	_____	Placement		Front/Rear	Front/Rear
	Dorsal	Left	Right																		
Tag No.(s):	_____	_____	_____																		
Color(s):	_____	_____	_____																		
Type:	_____	_____	_____																		
Placement		Front/Rear	Front/Rear																		

CARCASS — Disposition: Check one: <input type="checkbox"/> 1. Left at site <input type="checkbox"/> 2. Buried <input type="checkbox"/> 3. Towed <input checked="" type="checkbox"/> 4. Sci. collection: (see below) <input type="checkbox"/> 5. Edu. collection: (see below) <input type="checkbox"/> 6. Other _____ <input type="checkbox"/> ? Unknown NECROPSIED? <input checked="" type="checkbox"/> Yes <input type="checkbox"/> No <u>7/24/03</u>	MORPHOLOGICAL DATA: Sex — Check one: <input type="checkbox"/> 1. Male <i>immature</i> <input checked="" type="checkbox"/> 2. Female <input type="checkbox"/> ? Unknown Straight Length: <u>126</u> <input checked="" type="checkbox"/> cm <input type="checkbox"/> in <input type="checkbox"/> est *Weight <u>33.5</u> <input checked="" type="checkbox"/> kg <input type="checkbox"/> lb <input type="checkbox"/> est PHOTOS TAKEN? <input checked="" type="checkbox"/> Yes <input type="checkbox"/> No
--	--

REMARKS: Collected for Necropsy. Stored in FHL freezer.

DISPOSITION OF TISSUE/SKELETAL MATERIAL: _____

6/23/03

MARINE MAMMAL STRANDING REPORT

NW-2003-100779

SID# (NMFS USE)

FIELD NO.: 2003-SJ008 NMFS REGISTRATION NO.: 03NWR05006

TO SCAN 7/20

COMMON NAME: Harbor porpoise GENUS: Phocoena SPECIES: phocoena

EXAMINER Name: Whale Museum Agency: Phone:

Address:

LOCATION State: WA County: San Juan City: Locality Details: <u>South Beach,</u> <u>San Juan Island</u> *Latitude: N *Longitude: W	TYPE OF OCCURRENCE Mass Stranding: <input type="checkbox"/> Yes <input checked="" type="checkbox"/> No # Animals <u>1</u> Human Interaction: <input type="checkbox"/> Yes <input type="checkbox"/> No <input checked="" type="checkbox"/> ? Check one: <input type="checkbox"/> 1. Boat Collision <input type="checkbox"/> 2. Shot <input type="checkbox"/> 3. Fishery Interaction <input type="checkbox"/> 4. Other How determined: Other Causes (if known):
---	---

DATE OF INITIAL OBSERVATION: Yr. 2003 Mo. 5 Day 5 CONDITION: Check one: <input type="checkbox"/> 1. Alive <input type="checkbox"/> 2. Fresh dead <input checked="" type="checkbox"/> 3. Moderate decomp. <input type="checkbox"/> 4. Advanced decomp. <input type="checkbox"/> 5. Mummified <input type="checkbox"/> ? Unknown	DATE OF EXAMINATION: Yr. 2003 Mo. 5 Day 5 CONDITION: Check one: <input type="checkbox"/> 1. Alive <input type="checkbox"/> 2. Fresh dead <input checked="" type="checkbox"/> 3. Moderate decomp. <input type="checkbox"/> 4. Advanced decomp. <input type="checkbox"/> 5. Mummified <input type="checkbox"/> ? Unknown
---	---

LIVE ANIMAL — Condition and Disposition: Check one or more: <input type="checkbox"/> 1. Released at site <input type="checkbox"/> 2. Sick <input type="checkbox"/> 3. Injured <input type="checkbox"/> 4. Died <input type="checkbox"/> 5. Euthanized <input type="checkbox"/> 6. Rehabilitated and released <input type="checkbox"/> 7. Unknown Transported to: <input type="checkbox"/> Died <input type="checkbox"/> Released Date:	TAGS APPLIED?: <input type="checkbox"/> Yes <input checked="" type="checkbox"/> No TAGS PRESENT?: <input type="checkbox"/> Yes <input checked="" type="checkbox"/> No <table border="0"> <tr> <td></td> <td>Dorsal</td> <td>Left</td> <td>Right</td> </tr> <tr> <td>Tag No.(s):</td> <td>_____</td> <td>_____</td> <td>_____</td> </tr> <tr> <td>Color(s):</td> <td>_____</td> <td>_____</td> <td>_____</td> </tr> <tr> <td>Type:</td> <td>_____</td> <td>_____</td> <td>_____</td> </tr> <tr> <td>Placement</td> <td></td> <td>Front/Rear</td> <td>Front/Rear</td> </tr> </table>		Dorsal	Left	Right	Tag No.(s):	_____	_____	_____	Color(s):	_____	_____	_____	Type:	_____	_____	_____	Placement		Front/Rear	Front/Rear
	Dorsal	Left	Right																		
Tag No.(s):	_____	_____	_____																		
Color(s):	_____	_____	_____																		
Type:	_____	_____	_____																		
Placement		Front/Rear	Front/Rear																		

CARCASS — Disposition: Check one: <input type="checkbox"/> 1. Left at site <input type="checkbox"/> 2. Buried <input type="checkbox"/> 3. Towed <input checked="" type="checkbox"/> 4. Sci. collection: (see below) <input type="checkbox"/> 5. Edu. collection: (see below) <input type="checkbox"/> 6. Other <input type="checkbox"/> ? Unknown NECROPSIED? <input checked="" type="checkbox"/> Yes <input type="checkbox"/> No 7/23/03	MORPHOLOGICAL DATA: Sex — Check one: <input type="checkbox"/> 1. Male <input checked="" type="checkbox"/> 2. Female <input type="checkbox"/> ? Unknown <i>adult</i> Straight Length: <u>152 cm</u> <input checked="" type="checkbox"/> cm <input type="checkbox"/> in <input type="checkbox"/> est *Weight <u>48.5 kg</u> <input checked="" type="checkbox"/> kg <input type="checkbox"/> lb <input checked="" type="checkbox"/> est PHOTOS TAKEN? <input checked="" type="checkbox"/> Yes* <input type="checkbox"/> No <i>*during necropsy</i>
---	---

REMARKS: collected for necropsy. Stored in FHL freezer.

DISPOSITION OF TISSUE/SKELETAL MATERIAL:

6/23/03

MARINE MAMMAL STRANDING REPORT - LEVEL A DATA

yes
7/22/03

copy sent
7/22/03

FIELD #: DNG 03 001 NMFS REGIONAL #: 03NWR05007 NATIONAL DATABASE #: NW-2003-100071
 COMMON NAME: harbor porpoise GENUS: Phocaena SPECIES: phocaena
 EXAMINER: _____ Letterholder: _____
 Name: Pam Sanguinetti Affiliation: U.S. Fish & Wildlife Service
 Address: 33 S. Barr Rd Port Angeles WA 98362 Phone: 360 457 8451

LOCATION State: <u>WA</u> County: <u>Clallam</u> City: <u>Sequim</u> Locality Details: <u>Dungeness National Wildlife Refuge</u> Latitude: <u>48°10'21.4"</u> N Longitude: <u>123°09'08.8"</u> W	OCCURRENCE DETAILS Mass Stranding: <input type="checkbox"/> YES <input checked="" type="checkbox"/> NO # Animals: _____ (NMFS USE) Signs of Human Interaction: <input type="checkbox"/> YES <input type="checkbox"/> NO <input checked="" type="checkbox"/> Could Not be Determined (CBD) (Check one or more) <input type="checkbox"/> 1. Boat Collision <input type="checkbox"/> 3. Fishery Interaction <input type="checkbox"/> 2. Shot <input type="checkbox"/> 4. Other Human Interaction: _____ How determined: <input type="checkbox"/> External Exam <input type="checkbox"/> Internal Exam <input type="checkbox"/> Not Examined Other Causes: <input type="checkbox"/> YES <input type="checkbox"/> NO <input type="checkbox"/> CBD Describe: _____
--	---

DATE OF INITIAL OBSERVATION Year: <u>03</u> Month: <u>05</u> Day: <u>06</u> STATUS (Check ONE) <input type="checkbox"/> 1. Alive <input type="checkbox"/> 4. Advanced Decomposition <input checked="" type="checkbox"/> 2. Fresh Dead <input type="checkbox"/> 5. Mummified/Skeletal <input type="checkbox"/> 3. Moderate Decomposition <input type="checkbox"/> 6. Dead - Condition Unknown	DATE OF EXAMINATION (LEVEL A) <input type="checkbox"/> Not Able to Examine Year: <u>03</u> Month: <u>05</u> Day: <u>06</u> CONDITION (Check ONE) <input type="checkbox"/> 1. Alive <input type="checkbox"/> 4. Advanced Decomposition <input checked="" type="checkbox"/> 2. Fresh Dead <input type="checkbox"/> 5. Mummified/Skeletal <input type="checkbox"/> 3. Moderate Decomposition <input type="checkbox"/> 6. Dead - Condition Unknown
---	---

INITIAL LIVE ANIMAL DISPOSITION (Check one or more) <input type="checkbox"/> 1. Left at Site <input type="checkbox"/> 5. Euthanized at Site <input type="checkbox"/> 2. Immediate Release at Site <input type="checkbox"/> 6. Died at Site <input type="checkbox"/> 3. Relocated <input type="checkbox"/> 7. Transferred to Rehabilitation <input type="checkbox"/> 4. Disentangled <input type="checkbox"/> 8. Died During Transport <input type="checkbox"/> 9. Other CONDITION (Check ONE) <input type="checkbox"/> 1. Sick <input type="checkbox"/> 3. Apparently Healthy <input type="checkbox"/> 5. Other <input type="checkbox"/> 2. Injured <input type="checkbox"/> 4. Out of Habitat Date: _____ Rehabilitation Facility: _____ Comments: _____	MORPHOLOGICAL DATA SEX (Check ONE) AGE CLASS (Check ONE) <input type="checkbox"/> 1. Male <input checked="" type="checkbox"/> 1. Adult <input type="checkbox"/> 4. Pup/Calf <input checked="" type="checkbox"/> 2. Female <input checked="" type="checkbox"/> 2. Subadult <input type="checkbox"/> 5. Unknown <input type="checkbox"/> 3. Unknown <input type="checkbox"/> 3. Yearling Straight Length: <u>145.5</u> <input checked="" type="checkbox"/> cm <input type="checkbox"/> in <input checked="" type="checkbox"/> actual <input type="checkbox"/> estimate Weight: <u>38.5</u> <input checked="" type="checkbox"/> kg <input type="checkbox"/> lb <input checked="" type="checkbox"/> actual <input type="checkbox"/> estimate PHOTOS/VIDEOS TAKEN: <input checked="" type="checkbox"/> YES <input type="checkbox"/> NO Disposition: _____
---	--

6/23/03

TAG DATA <table border="1" style="width: 100%; border-collapse: collapse;"> <thead> <tr> <th>ID#</th> <th>Color</th> <th>Type</th> <th>*Placement (Circle One)</th> <th>Applied</th> <th>Present</th> </tr> </thead> <tbody> <tr> <td>_____</td> <td>_____</td> <td>_____</td> <td>D DF L LF LR RF RR</td> <td style="text-align: center;"><input type="checkbox"/></td> <td style="text-align: center;"><input type="checkbox"/></td> </tr> <tr> <td>_____</td> <td>_____</td> <td>_____</td> <td>D DF L LF LR RF RR</td> <td style="text-align: center;"><input type="checkbox"/></td> <td style="text-align: center;"><input type="checkbox"/></td> </tr> <tr> <td>_____</td> <td>_____</td> <td>_____</td> <td>D DF L LF LR RF RR</td> <td style="text-align: center;"><input type="checkbox"/></td> <td style="text-align: center;"><input type="checkbox"/></td> </tr> </tbody> </table>	ID#	Color	Type	*Placement (Circle One)	Applied	Present	_____	_____	_____	D DF L LF LR RF RR	<input type="checkbox"/>	<input type="checkbox"/>	_____	_____	_____	D DF L LF LR RF RR	<input type="checkbox"/>	<input type="checkbox"/>	_____	_____	_____	D DF L LF LR RF RR	<input type="checkbox"/>	<input type="checkbox"/>	WHOLE CARCASS DISPOSAL (Check one or more) <input type="checkbox"/> 1. Left at Site <input type="checkbox"/> 4. Rendered <input type="checkbox"/> 7. Unknown <input type="checkbox"/> 2. Buried <input type="checkbox"/> 5. Sunk <input type="checkbox"/> 3. Towed <input checked="" type="checkbox"/> 6. Frozen for Later Examination SPECIMEN DISPOSITION (Check one or more) <input checked="" type="checkbox"/> 1. Scientific Collection <input type="checkbox"/> 2. Educational Collection <input checked="" type="checkbox"/> 3. Other: <u>given to Brad Hansen, NOAA for Necropsy</u> Comments: _____ NECROPSIED <input checked="" type="checkbox"/> YES <input type="checkbox"/> NO Date: _____ NECROPSIED BY: <u>7/22/03</u>
ID#	Color	Type	*Placement (Circle One)	Applied	Present																				
_____	_____	_____	D DF L LF LR RF RR	<input type="checkbox"/>	<input type="checkbox"/>																				
_____	_____	_____	D DF L LF LR RF RR	<input type="checkbox"/>	<input type="checkbox"/>																				
_____	_____	_____	D DF L LF LR RF RR	<input type="checkbox"/>	<input type="checkbox"/>																				

*D=Dorsal; DF=Dorsal Fin; L=Lateral Body
 LF=Left Front; LR=Left Rear; RF=Right Front; RR=Right Rear

MARINE MAMMAL STRANDING REPORT - LEVEL A DATA

To Scan 7/2
yes

FIELD #: OCNMS013 Pp 01 NMFS REGIONAL #: 15NWRO5008 NATIONAL DATABASE #: NW-2003-100781

COMMON NAME: Harbor Porpoise GENUS: Phocoena SPECIES: phocoena

EXAMINER Name: Mary Sue Brancato Letterholder: _____
Affiliation: Olympic Coast National Marine Sanctuary
Address: 115 E Railroad, Port Angeles WA Phone: 360 457-6622 x20

LOCATION State: <u>WA</u> County: <u>Clallam</u> City: <u>Port Angeles</u> Locality Details: <u>On Discovery trail east of MP 2 at river delta/bridge.</u> Latitude: _____ N Longitude: _____ W		OCCURRENCE DETAILS Mass Stranding: <input type="checkbox"/> YES <input checked="" type="checkbox"/> NO # Animals: _____ Signs of Human Interaction: <input type="checkbox"/> YES <input checked="" type="checkbox"/> NO <input type="checkbox"/> Could Not be Determined (CBD) (Check one or more) <input type="checkbox"/> 1. Boat Collision <input type="checkbox"/> 3. Fishery Interaction <input type="checkbox"/> 2. Shot <input type="checkbox"/> 4. Other Human Interaction: _____ How determined: <input checked="" type="checkbox"/> External Exam <input type="checkbox"/> Internal Exam <input type="checkbox"/> Not Examined Other Causes: <input type="checkbox"/> YES <input type="checkbox"/> NO <input type="checkbox"/> CBD Describe: _____	
---	--	---	--

DATE OF INITIAL OBSERVATION Year: <u>2003</u> Month: <u>5</u> Day: <u>26</u> STATUS (Check ONE) <input type="checkbox"/> 1. Alive <input type="checkbox"/> 4. Advanced Decomposition <input type="checkbox"/> 2. Fresh Dead <input type="checkbox"/> 5. Mummified/Skeletal <input checked="" type="checkbox"/> 3. Moderate Decomposition <input type="checkbox"/> 6. Dead - Condition Unknown	DATE OF EXAMINATION (LEVEL A) <input type="checkbox"/> Not Able to Examine Year: _____ Month: _____ Day: _____ CONDITION (Check ONE) <input type="checkbox"/> 1. Alive <input type="checkbox"/> 4. Advanced Decomposition <input type="checkbox"/> 2. Fresh Dead <input type="checkbox"/> 5. Mummified/Skeletal <input type="checkbox"/> 3. Moderate Decomposition <input type="checkbox"/> 6. Dead - Condition Unknown
--	--

INITIAL LIVE ANIMAL DISPOSITION (Check one or more) <input type="checkbox"/> 1. Left at Site <input type="checkbox"/> 5. Euthanized at Site <input type="checkbox"/> 2. Immediate Release at Site <input type="checkbox"/> 6. Died at Site <input type="checkbox"/> 3. Relocated <input type="checkbox"/> 7. Transferred to Rehabilitation <input type="checkbox"/> 4. Disentangled <input type="checkbox"/> 8. Died During Transport <input type="checkbox"/> 9. Other CONDITION (Check ONE) <input type="checkbox"/> 1. Sick <input type="checkbox"/> 3. Apparently Healthy <input type="checkbox"/> 5. Other <input type="checkbox"/> 2. Injured <input type="checkbox"/> 4. Out of Habitat Date: _____ Rehabilitation Facility: _____ Comments: _____	MORPHOLOGICAL DATA SEX (Check ONE) AGE CLASS (Check ONE) <input checked="" type="checkbox"/> 1. Male <input checked="" type="checkbox"/> 1. Adult <input type="checkbox"/> 4. Pup/Calf <input type="checkbox"/> 2. Female <input type="checkbox"/> 2. Subadult <input type="checkbox"/> 5. Unknown <input type="checkbox"/> 3. Unknown <input type="checkbox"/> 3. Yearling Straight Length: <u>146</u> <input checked="" type="checkbox"/> cm <input type="checkbox"/> in <input checked="" type="checkbox"/> actual <input type="checkbox"/> estimate Weight: <u>40</u> <input checked="" type="checkbox"/> kg <input type="checkbox"/> lb <input type="checkbox"/> actual <input checked="" type="checkbox"/> estimate PHOTOS/VIDEOS TAKEN: <input checked="" type="checkbox"/> YES <input type="checkbox"/> NO Disposition: <u>cut off head & froze for scanning. delivered by Pelly Ramirez to NMFS - Brad Hanson</u>
---	---

TAG DATA <table border="1"> <thead> <tr> <th>ID#</th> <th>Color</th> <th>Type</th> <th>*Placement (Circle One)</th> <th>Applied</th> <th>Present</th> </tr> </thead> <tbody> <tr> <td></td> <td></td> <td></td> <td>D DF L</td> <td><input type="checkbox"/></td> <td><input type="checkbox"/></td> </tr> <tr> <td></td> <td></td> <td></td> <td>LF LR RF RR</td> <td><input type="checkbox"/></td> <td><input type="checkbox"/></td> </tr> <tr> <td></td> <td></td> <td></td> <td>D DF L</td> <td><input type="checkbox"/></td> <td><input type="checkbox"/></td> </tr> <tr> <td></td> <td></td> <td></td> <td>LF LR RF RR</td> <td><input type="checkbox"/></td> <td><input type="checkbox"/></td> </tr> <tr> <td></td> <td></td> <td></td> <td>D DF L</td> <td><input type="checkbox"/></td> <td><input type="checkbox"/></td> </tr> <tr> <td></td> <td></td> <td></td> <td>LF LR RF RR</td> <td><input type="checkbox"/></td> <td><input type="checkbox"/></td> </tr> </tbody> </table> <p>*D=Dorsal; DF=Dorsal Fin; L=Lateral Body LF=Left Front; LR=Left Rear; RF=Right Front; RR=Right Rear</p>	ID#	Color	Type	*Placement (Circle One)	Applied	Present				D DF L	<input type="checkbox"/>	<input type="checkbox"/>				LF LR RF RR	<input type="checkbox"/>	<input type="checkbox"/>				D DF L	<input type="checkbox"/>	<input type="checkbox"/>				LF LR RF RR	<input type="checkbox"/>	<input type="checkbox"/>				D DF L	<input type="checkbox"/>	<input type="checkbox"/>				LF LR RF RR	<input type="checkbox"/>	<input type="checkbox"/>	WHOLE CARCASS DISPOSAL (Check one or more) <input checked="" type="checkbox"/> 1. Left at Site <u>except head</u> <input type="checkbox"/> 4. Rendered <input type="checkbox"/> 7. Unknown <input type="checkbox"/> 2. Buried <input type="checkbox"/> 5. Sunk <input type="checkbox"/> 3. Towed <input type="checkbox"/> 6. Frozen for Later Examination SPECIMEN DISPOSITION (Check one or more) <input checked="" type="checkbox"/> 1. Scientific Collection <input type="checkbox"/> 2. Educational Collection <input type="checkbox"/> 3. Other: _____ Comments: <u>Timing near Canadian Navy Test Flus collected for scanning.</u> NECROPSIED <input checked="" type="checkbox"/> YES <input type="checkbox"/> NO Date: <u>head 7/22/03 body 7/23/03</u> NECROPSIED BY: _____
ID#	Color	Type	*Placement (Circle One)	Applied	Present																																						
			D DF L	<input type="checkbox"/>	<input type="checkbox"/>																																						
			LF LR RF RR	<input type="checkbox"/>	<input type="checkbox"/>																																						
			D DF L	<input type="checkbox"/>	<input type="checkbox"/>																																						
			LF LR RF RR	<input type="checkbox"/>	<input type="checkbox"/>																																						
			D DF L	<input type="checkbox"/>	<input type="checkbox"/>																																						
			LF LR RF RR	<input type="checkbox"/>	<input type="checkbox"/>																																						

6/23/03

ADDITIONAL REMARKS

ADDITIONAL IDENTIFIER:

First called in by woman (Janine at AA Acupuncture center) when she saw it on Tuesday 5/6 - took her awhile to find right contact. She contacted the Sanctuary on 5/9/03.

DISCLAIMER

These data should not be used out of context or without verification. This should be strictly enforced when reporting signs of human interaction data.

DATA ACCESS FOR LEVEL A DATA

Upon written request, certain fields of the Level A Data Sheet will be released to the requestor provided that the requestor credit the stranding network and the National Marine Fisheries Service. The National Marine Fisheries Service will notify the contributing stranding network members that these data have been requested and the intent of use. All other data will be released to the requestor provided that the requestor obtain permission from the contributing stranding network and the National Marine Fisheries Service.

PAPERWORK REDUCTION ACT INFORMATION

Public reporting burden for the collection of information is estimated to average 20 minutes per response, including the time for reviewing instructions, searching existing data sources, gathering and maintaining the data needed, and completing and reviewing the collection of information. Send comments regarding this burden estimate or any other aspect of the collection of information, including suggestions for reducing the burden to: Chief, Marine Mammal Conservation Division, Office of Protected Resources, NOAA Fisheries, 1315 East-West Highway, Silver Spring, Maryland 20910. Notwithstanding any other provision of the law, no person is required to respond to, nor shall any person be subjected to a penalty for failure to comply with, a collection of information subject to the requirements of the Paperwork Reduction Act, unless the collection of information displays a currently valid Office of Management and Budget (OMB) Control Number.



MARINE MAMMAL STRANDING REPORT - LEVEL A DATA

FIELD #: 03-GH-159 NMFS REGIONAL #: 03NWROS034 NATIONAL DATABASE #: NW-2003-102845
(NMFS USE) (NMFS USE)

COMMON NAME: Harbor Porpoise GENUS: Phocoena SPECIES: phocoena

EXAMINER Name: Cascadia Research Letterholder: _____ Affiliation: _____
 Address: _____ Phone: _____

LOCATION

State: WA County: Grays Harbor
 City: Ocean City
 Locality Details: _____

Latitude: _____ N
 Longitude: _____ W

OCCURRENCE DETAILS

Mass Stranding: YES NO # Animals: 1 MS#: _____
(NMFS USE)

Signs of Human Interaction: YES NO Could Not be Determined (CBD)
 (Check one or more) 1. Boat Collision 3. Fishery Interaction
 2. Shot 4. Other Human Interaction: _____

How determined: External Exam Internal Exam Not Examined
 Other Causes: YES NO CBD Describe: _____

DATE OF INITIAL OBSERVATION

Year: 03 Month: 05 Day: 12

STATUS (Check ONE)

1. Alive 4. Advanced Decomposition
 2. Fresh Dead 5. Mummified/Skeletal
 3. Moderate Decomposition 6. Dead - Condition Unknown

DATE OF EXAMINATION (LEVEL A) Not Able to Examine

Year: _____ Month: _____ Day: _____

CONDITION (Check ONE)

1. Alive 4. Advanced Decomposition
 2. Fresh Dead 5. Mummified/Skeletal
 3. Moderate Decomposition 6. Dead - Condition Unknown

INITIAL LIVE ANIMAL DISPOSITION (Check one or more)

1. Left at Site 5. Euthanized at Site
 2. Immediate Release at Site 6. Died at Site
 3. Relocated 7. Transferred to Rehabilitation
 4. Disentangled 8. Died During Transport
 9. Other

CONDITION (Check ONE)

1. Sick 3. Apparently Healthy 5. Other
 2. Injured 4. Out of Habitat

Date: _____ Rehabilitation Facility: _____

Comments: _____

MORPHOLOGICAL DATA

SEX (Check ONE) **AGE CLASS (Check ONE)**

1. Male 1. Adult 4. Pup/Calf
 2. Female 2. Subadult 5. Unknown
 3. Unknown 3. Yearling

Straight Length: _____ cm in actual estimate
 Weight: _____ kg lb actual estimate

PHOTOS/VIDEOS TAKEN: YES NO

Disposition: _____

6/26/09

TAG DATA

ID#	Color	Type	*Placement (Circle One)	Applied	Present
_____	_____	_____	D DF L LF LR RF RR	<input type="checkbox"/>	<input type="checkbox"/>
_____	_____	_____	D DF L LF LR RF RR	<input type="checkbox"/>	<input type="checkbox"/>
_____	_____	_____	D DF L LF LR RF RR	<input type="checkbox"/>	<input type="checkbox"/>

*D=Dorsal; DF=Dorsal Fin; L=Lateral Body
 LF=Left Front; LR=Left Rear; RF=Right Front; RR=Right Rear

WHOLE CARCASS DISPOSAL (Check one or more)

1. Left at Site 4. Rendered 7. Unknown
 2. Buried 5. Sunk
 3. Towed 6. Frozen for Later Examination

SPECIMEN DISPOSITION (Check one or more)

1. Scientific Collection
 2. Educational Collection
 3. Other: not collected

Comments: _____

NECROPSIED YES NO Date: _____
 NECROPSIED BY: _____

MARINE MAMMAL STRANDING REPORT - LEVEL A DATA

FIELD #: 03-IS-160 NMFS REGIONAL #: 03NWR05033 NATIONAL DATABASE #: NW-2003-102845?
(NMFS USE) (NMFS USE)

COMMON NAME: Harbor Porpoise GENUS: Phocoena SPECIES: phocoena

EXAMINER: _____ Letterholder: _____

Name: W's V Beach Watchers Affiliation: _____

Address: _____ Phone: _____

LOCATION State: <u>WA</u> County: <u>Island</u> City: _____ Locality Details: <u>West Beach</u> <u>Whidbey Isl.</u> Latitude: _____ N Longitude: _____ W	OCCURRENCE DETAILS Mass Stranding: <input type="checkbox"/> YES <input checked="" type="checkbox"/> NO # Animals: <u>1</u> MS#: _____ Signs of Human Interaction: <input type="checkbox"/> YES <input type="checkbox"/> NO <input checked="" type="checkbox"/> Could Not be Determined (CBD) (Check one or more) <input type="checkbox"/> 1. Boat Collision <input type="checkbox"/> 3. Fishery Interaction <input type="checkbox"/> 2. Shot <input type="checkbox"/> 4. Other Human Interaction: _____ How determined: <input type="checkbox"/> External Exam <input type="checkbox"/> Internal Exam <input checked="" type="checkbox"/> Not Examined Other Causes: <input type="checkbox"/> YES <input type="checkbox"/> NO <input checked="" type="checkbox"/> CBD Describe: _____																								
DATE OF INITIAL OBSERVATION Year: <u>03</u> Month: <u>05</u> Day: <u>12</u> STATUS (Check ONE) <input type="checkbox"/> 1. Alive <input type="checkbox"/> 4. Advanced Decomposition <input type="checkbox"/> 2. Fresh Dead <input type="checkbox"/> 5. Mummified/Skeletal <input type="checkbox"/> 3. Moderate Decomposition <input checked="" type="checkbox"/> 6. Dead - Condition Unknown	DATE OF EXAMINATION (LEVEL A) <input checked="" type="checkbox"/> Not Able to Examine Year: _____ Month: _____ Day: _____ CONDITION (Check ONE) <input type="checkbox"/> 1. Alive <input type="checkbox"/> 4. Advanced Decomposition <input type="checkbox"/> 2. Fresh Dead <input type="checkbox"/> 5. Mummified/Skeletal <input type="checkbox"/> 3. Moderate Decomposition <input type="checkbox"/> 6. Dead - Condition Unknown																								
INITIAL LIVE ANIMAL DISPOSITION (Check one or more) <input type="checkbox"/> 1. Left at Site <input type="checkbox"/> 5. Euthanized at Site <input type="checkbox"/> 2. Immediate Release at Site <input type="checkbox"/> 6. Died at Site <input type="checkbox"/> 3. Relocated <input type="checkbox"/> 7. Transferred to Rehabilitation <input type="checkbox"/> 4. Disentangled <input type="checkbox"/> 8. Died During Transport <input type="checkbox"/> 9. Other CONDITION (Check ONE) <input type="checkbox"/> 1. Sick <input type="checkbox"/> 3. Apparently Healthy <input type="checkbox"/> 5. Other <input type="checkbox"/> 2. Injured <input type="checkbox"/> 4. Out of Habitat Date: _____ Rehabilitation Facility: _____ Comments: _____	MORPHOLOGICAL DATA SEX (Check ONE) AGE CLASS (Check ONE) <input type="checkbox"/> 1. Male <input type="checkbox"/> 1. Adult <input type="checkbox"/> 4. Pup/Calf <input type="checkbox"/> 2. Female <input type="checkbox"/> 2. Subadult <input checked="" type="checkbox"/> 5. Unknown <input checked="" type="checkbox"/> 3. Unknown <input type="checkbox"/> 3. Yearling Straight Length: _____ <input type="checkbox"/> cm <input type="checkbox"/> in <input type="checkbox"/> actual <input type="checkbox"/> estimate Weight: _____ <input type="checkbox"/> kg <input type="checkbox"/> lb <input type="checkbox"/> actual <input type="checkbox"/> estimate PHOTOS/VIDEOS TAKEN: <input type="checkbox"/> YES <input checked="" type="checkbox"/> NO Disposition: _____																								
TAG DATA <table border="1" style="width: 100%; border-collapse: collapse;"> <thead> <tr> <th>ID#</th> <th>Color</th> <th>Type</th> <th>*Placement (Circle One)</th> <th>Applied</th> <th>Present</th> </tr> </thead> <tbody> <tr> <td>_____</td> <td>_____</td> <td>_____</td> <td>D DF L LF LR RF RR</td> <td style="text-align: center;"><input type="checkbox"/></td> <td style="text-align: center;"><input type="checkbox"/></td> </tr> <tr> <td>_____</td> <td>_____</td> <td>_____</td> <td>D DF L LF LR RF RR</td> <td style="text-align: center;"><input type="checkbox"/></td> <td style="text-align: center;"><input type="checkbox"/></td> </tr> <tr> <td>_____</td> <td>_____</td> <td>_____</td> <td>D DF L LF LR RF RR</td> <td style="text-align: center;"><input type="checkbox"/></td> <td style="text-align: center;"><input type="checkbox"/></td> </tr> </tbody> </table> <p><small>*D=Dorsal; DF=Dorsal Fin; L=Lateral Body LF=Left Front; LR=Left Rear; RF=Right Front; RR=Right Rear</small></p>	ID#	Color	Type	*Placement (Circle One)	Applied	Present	_____	_____	_____	D DF L LF LR RF RR	<input type="checkbox"/>	<input type="checkbox"/>	_____	_____	_____	D DF L LF LR RF RR	<input type="checkbox"/>	<input type="checkbox"/>	_____	_____	_____	D DF L LF LR RF RR	<input type="checkbox"/>	<input type="checkbox"/>	WHOLE CARCASS DISPOSAL (Check one or more) <input checked="" type="checkbox"/> 1. Left at Site <input type="checkbox"/> 4. Rendered <input checked="" type="checkbox"/> 7. Unknown <input type="checkbox"/> 2. Buried <input type="checkbox"/> 5. Sunk <input type="checkbox"/> 3. Towed <input type="checkbox"/> 6. Frozen for Later Examination SPECIMEN DISPOSITION (Check one or more) <input type="checkbox"/> 1. Scientific Collection <input type="checkbox"/> 2. Educational Collection <input type="checkbox"/> 3. Other: _____ Comments: <u>not collected</u> NECROPSIED <input type="checkbox"/> YES <input checked="" type="checkbox"/> NO Date: _____ NECROPSIED BY: _____
ID#	Color	Type	*Placement (Circle One)	Applied	Present																				
_____	_____	_____	D DF L LF LR RF RR	<input type="checkbox"/>	<input type="checkbox"/>																				
_____	_____	_____	D DF L LF LR RF RR	<input type="checkbox"/>	<input type="checkbox"/>																				
_____	_____	_____	D DF L LF LR RF RR	<input type="checkbox"/>	<input type="checkbox"/>																				

6/2/04

MARINE MAMMAL STRANDING REPORT - LEVEL A DATA

FIELD #: WIC 051303SD NMFS REGIONAL #: 03NWR05010 NATIONAL DATABASE #: NW-2003-1000783
(NMFS USE) (NMFS USE)
 COMMON NAME: HARBOR PORPOISE GENUS: PHOCOENA SPECIES: PHOCOENA
 EXAMINER: _____ Letterholder: MATT KLOPF NAVY BIOLOGIST
 Name: STUDY DUBPERNELL Affiliation: USA ISLAND COUNTY MMSU
 Address: 1224 NIMITE DR COUPEVILLE WA 98239 Phone: 360-678-3765

LOCATION State: <u>WA</u> County: <u>ISLAND</u> City: <u>COUPEVILLE</u> Locality Details: <u>FORT CASEY STATE PARK ± 1/2 WAY BETW STAIR CASES AT POINT + GUN EMPLACEMENT</u> Latitude: <u>Admiralty Head</u> N Longitude: _____ W	OCCURRENCE DETAILS Mass Stranding: <input type="checkbox"/> YES <input checked="" type="checkbox"/> NO # Animals: _____ Signs of Human Interaction: <input type="checkbox"/> YES <input type="checkbox"/> NO <input checked="" type="checkbox"/> Could Not be Determined (CBD) <small>(Check one or more)</small> <input type="checkbox"/> 1. Boat Collision <input type="checkbox"/> 3. Fishery Interaction <input type="checkbox"/> 2. Shot <input checked="" type="checkbox"/> 4. Other Human Interaction: <u>POSSIBLE</u> How determined: <input checked="" type="checkbox"/> External Exam <input type="checkbox"/> Internal Exam <input type="checkbox"/> Not Examined Other Causes: <input type="checkbox"/> YES <input type="checkbox"/> NO <input type="checkbox"/> CBD Describe: _____
---	---

DATE OF INITIAL OBSERVATION Year: <u>2003</u> Month: <u>5</u> Day: <u>13</u> STATUS (Check ONE) <input type="checkbox"/> 1. Alive <input type="checkbox"/> 4. Advanced Decomposition <input checked="" type="checkbox"/> 2. Fresh Dead <input type="checkbox"/> 5. Mummified/Skeletal <input type="checkbox"/> 3. Moderate Decomposition <input type="checkbox"/> 6. Dead - Condition Unknown	DATE OF EXAMINATION (LEVEL A) <input type="checkbox"/> Not Able to Examine Year: <u>2003</u> Month: <u>5</u> Day: <u>13</u> CONDITION (Check ONE) <input type="checkbox"/> 1. Alive <input type="checkbox"/> 4. Advanced Decomposition <input checked="" type="checkbox"/> 2. Fresh Dead <input type="checkbox"/> 5. Mummified/Skeletal <input type="checkbox"/> 3. Moderate Decomposition <input type="checkbox"/> 6. Dead - Condition Unknown
--	--

INITIAL LIVE ANIMAL DISPOSITION (Check one or more) <input type="checkbox"/> 1. Left at Site <input type="checkbox"/> 5. Euthanized at Site <input type="checkbox"/> 2. Immediate Release at Site <input type="checkbox"/> 6. Died at Site <input type="checkbox"/> 3. Relocated <input type="checkbox"/> 7. Transferred to Rehabilitation <input type="checkbox"/> 4. Disentangled <input type="checkbox"/> 8. Died During Transport <input type="checkbox"/> 9. Other CONDITION (Check ONE) <input type="checkbox"/> 1. Sick <input type="checkbox"/> 3. Apparently Healthy <input type="checkbox"/> 5. Other <input type="checkbox"/> 2. Injured <input type="checkbox"/> 4. Out of Habitat Date: _____ Rehabilitation Facility: _____ Comments: _____	MORPHOLOGICAL DATA SEX (Check ONE) AGE CLASS (Check ONE) <input checked="" type="checkbox"/> 1. Male <input checked="" type="checkbox"/> 1. Adult <input type="checkbox"/> 4. Pup/Calf <input checked="" type="checkbox"/> 2. Female <input type="checkbox"/> 2. Subadult <input type="checkbox"/> 5. Unknown <input type="checkbox"/> 3. Unknown <input type="checkbox"/> 3. Yearling Straight Length: <u>154cm</u> <input type="checkbox"/> cm <input checked="" type="checkbox"/> in <input checked="" type="checkbox"/> actual <input type="checkbox"/> estimate Weight: <u>55</u> <input checked="" type="checkbox"/> kg <input checked="" type="checkbox"/> lb <input checked="" type="checkbox"/> actual <input checked="" type="checkbox"/> estimate PHOTOS/VIDEOS TAKEN: <input checked="" type="checkbox"/> YES <input type="checkbox"/> NO Disposition: <u>DIGITAL PHOTOS AVAILABLE ADMIRALTY HEAD LIGHTHOUSE. ALSO FROM RESPONDER</u>
---	--

TAG DATA <table style="width: 100%; border-collapse: collapse;"> <thead> <tr> <th>ID#</th> <th>Color</th> <th>Type</th> <th>*Placement (Circle One)</th> <th>Applied</th> <th>Present</th> </tr> </thead> <tbody> <tr> <td><u>0</u></td> <td></td> <td></td> <td>D DF L LF LR RF RR</td> <td style="text-align: center;"><input type="checkbox"/></td> <td style="text-align: center;"><input type="checkbox"/></td> </tr> <tr> <td></td> <td></td> <td></td> <td>D DF L LF LR RF RR</td> <td style="text-align: center;"><input type="checkbox"/></td> <td style="text-align: center;"><input type="checkbox"/></td> </tr> <tr> <td></td> <td></td> <td></td> <td>D DF L LF LR RF RR</td> <td style="text-align: center;"><input type="checkbox"/></td> <td style="text-align: center;"><input type="checkbox"/></td> </tr> </tbody> </table>	ID#	Color	Type	*Placement (Circle One)	Applied	Present	<u>0</u>			D DF L LF LR RF RR	<input type="checkbox"/>	<input type="checkbox"/>				D DF L LF LR RF RR	<input type="checkbox"/>	<input type="checkbox"/>				D DF L LF LR RF RR	<input type="checkbox"/>	<input type="checkbox"/>	WHOLE CARCASS DISPOSAL (Check one or more) <input type="checkbox"/> 1. Left at Site <input type="checkbox"/> 4. Rendered <input type="checkbox"/> 7. Unknown <input type="checkbox"/> 2. Buried <input type="checkbox"/> 5. Sunk <input type="checkbox"/> 3. Towed <input type="checkbox"/> 6. Frozen for Later Examination SPECIMEN DISPOSITION (Check one or more) <input checked="" type="checkbox"/> 1. Scientific Collection <input type="checkbox"/> 2. Educational Collection <input type="checkbox"/> 3. Other: _____ Comments: _____ NECROPSIED <input checked="" type="checkbox"/> YES <input type="checkbox"/> NO Date: <u>7/24/03</u> NECROPSIED BY: _____
ID#	Color	Type	*Placement (Circle One)	Applied	Present																				
<u>0</u>			D DF L LF LR RF RR	<input type="checkbox"/>	<input type="checkbox"/>																				
			D DF L LF LR RF RR	<input type="checkbox"/>	<input type="checkbox"/>																				
			D DF L LF LR RF RR	<input type="checkbox"/>	<input type="checkbox"/>																				

*D=Dorsal; DF=Dorsal Fin; L=Lateral Body
 LF=Left Front; LR=Left Rear; RF=Right Front; RR=Right Rear

6/23/03

EDIE HOOK - HP w/ Head

yes to scan 7/20

MARINE MAMMAL STRANDING REPORT - LEVEL A DATA

FIELD #: OCNMS03 P 02 NMFS REGIONAL #: 03NWRO5011 NATIONAL DATABASE #: NW-2003-1000784

COMMON NAME: TALBOUR PORPOISE GENUS: PHOCOENA SPECIES: PHOCOENA

EXAMINER Name: LIAM ANDRUM Letterholder: _____ Affiliation: OLYMPIC COAST NAT. MARINE SANCTUARY

Address: 115 E. RAILROAD AVE SUITE 301 Phone: 360 457-6672
PORT ANGELES WA

LOCATION State: <u>WA</u> County: <u>CLALLAM</u> City: <u>PORT ANGELES</u> Locality Details: <u>EDIE HOOK</u> <u>NORTH SIDE</u> <u>NEAR COAST GUARD EATE</u> Latitude: _____ N Longitude: _____ W	OCCURRENCE DETAILS Mass Stranding: <input type="checkbox"/> YES <input checked="" type="checkbox"/> NO # Animals: <u>1</u> Signs of Human Interaction: <input type="checkbox"/> YES <input checked="" type="checkbox"/> NO <input type="checkbox"/> Could Not be Determined (CBD) (Check one or more) <input type="checkbox"/> 1. Boat Collision <input type="checkbox"/> 3. Fishery Interaction <input type="checkbox"/> 2. Shot <input type="checkbox"/> 4. Other Human Interaction: _____ How determined: <input checked="" type="checkbox"/> External Exam <input type="checkbox"/> Internal Exam <input type="checkbox"/> Not Examined Other Causes: <input type="checkbox"/> YES <input type="checkbox"/> NO <input type="checkbox"/> CBD Describe: _____
	IMS#: _____ (NMFS USE)

DATE OF INITIAL OBSERVATION Year: <u>03</u> Month: <u>05</u> Day: <u>16</u>	DATE OF EXAMINATION (LEVEL A) <input type="checkbox"/> Not Able to Examine Year: _____ Month: _____ Day: _____
STATUS (Check ONE) <input type="checkbox"/> 1. Alive <input type="checkbox"/> 4. Advanced Decomposition <input checked="" type="checkbox"/> 2. Fresh Dead <input type="checkbox"/> 5. Mummified/Skeletal <input type="checkbox"/> 3. Moderate Decomposition <input type="checkbox"/> 6. Dead - Condition Unknown	CONDITION (Check ONE) <input type="checkbox"/> 1. Alive <input type="checkbox"/> 4. Advanced Decomposition <input type="checkbox"/> 2. Fresh Dead <input type="checkbox"/> 5. Mummified/Skeletal <input type="checkbox"/> 3. Moderate Decomposition <input type="checkbox"/> 6. Dead - Condition Unknown

INITIAL LIVE ANIMAL DISPOSITION (Check one or more) <input type="checkbox"/> 1. Left at Site <input type="checkbox"/> 5. Euthanized at Site <input type="checkbox"/> 2. Immediate Release at Site <input type="checkbox"/> 6. Died at Site <input type="checkbox"/> 3. Relocated <input type="checkbox"/> 7. Transferred to Rehabilitation <input type="checkbox"/> 4. Disentangled <input type="checkbox"/> 8. Died During Transport <input type="checkbox"/> 9. Other	MORPHOLOGICAL DATA SEX (Check ONE) AGE CLASS (Check ONE) <input type="checkbox"/> 1. Male <input checked="" type="checkbox"/> 1. Adult <input type="checkbox"/> 4. Pup/Calf <input checked="" type="checkbox"/> 2. Female <input type="checkbox"/> 2. Subadult <input type="checkbox"/> 5. Unknown <input type="checkbox"/> 3. Unknown <input type="checkbox"/> 3. Yearling Straight Length: <u>141</u> <input checked="" type="checkbox"/> cm <input type="checkbox"/> in <input checked="" type="checkbox"/> actual <input type="checkbox"/> estimate Weight: <u>37</u> <input checked="" type="checkbox"/> kg <input type="checkbox"/> lb <input checked="" type="checkbox"/> actual <input type="checkbox"/> estimate PHOTOS/VIDEOS TAKEN: <input checked="" type="checkbox"/> YES <input type="checkbox"/> NO Disposition: _____
---	--

TAG DATA <table border="1"> <thead> <tr> <th>ID#</th> <th>Color</th> <th>Type</th> <th>*Placement (Circle One)</th> <th>Applied</th> <th>Present</th> </tr> </thead> <tbody> <tr> <td></td> <td></td> <td></td> <td>D DF L</td> <td><input type="checkbox"/></td> <td><input type="checkbox"/></td> </tr> <tr> <td></td> <td></td> <td></td> <td>LF LR RF RR</td> <td><input type="checkbox"/></td> <td><input type="checkbox"/></td> </tr> <tr> <td></td> <td></td> <td></td> <td>D DF L</td> <td><input type="checkbox"/></td> <td><input type="checkbox"/></td> </tr> <tr> <td></td> <td></td> <td></td> <td>LF LR RF RR</td> <td><input type="checkbox"/></td> <td><input type="checkbox"/></td> </tr> <tr> <td></td> <td></td> <td></td> <td>D DF L</td> <td><input type="checkbox"/></td> <td><input type="checkbox"/></td> </tr> <tr> <td></td> <td></td> <td></td> <td>LF LR RF RR</td> <td><input type="checkbox"/></td> <td><input type="checkbox"/></td> </tr> </tbody> </table>	ID#	Color	Type	*Placement (Circle One)	Applied	Present				D DF L	<input type="checkbox"/>	<input type="checkbox"/>				LF LR RF RR	<input type="checkbox"/>	<input type="checkbox"/>				D DF L	<input type="checkbox"/>	<input type="checkbox"/>				LF LR RF RR	<input type="checkbox"/>	<input type="checkbox"/>				D DF L	<input type="checkbox"/>	<input type="checkbox"/>				LF LR RF RR	<input type="checkbox"/>	<input type="checkbox"/>	WHOLE CARCASS DISPOSAL (Check one or more) <input type="checkbox"/> 1. Left at Site <input type="checkbox"/> 4. Rendered <input type="checkbox"/> 7. Unknown <input type="checkbox"/> 2. Buried <input type="checkbox"/> 5. Sunk <input type="checkbox"/> 3. Towed <input checked="" type="checkbox"/> 6. Frozen for Later Examination SPECIMEN DISPOSITION (Check one or more) <input checked="" type="checkbox"/> 1. Scientific Collection <input type="checkbox"/> 2. Educational Collection <input type="checkbox"/> 3. Other: _____ Comments: _____ NECROPSIED <input checked="" type="checkbox"/> YES <input type="checkbox"/> NO Date: <u>7/23/03</u> NECROPSIED BY: _____
ID#	Color	Type	*Placement (Circle One)	Applied	Present																																						
			D DF L	<input type="checkbox"/>	<input type="checkbox"/>																																						
			LF LR RF RR	<input type="checkbox"/>	<input type="checkbox"/>																																						
			D DF L	<input type="checkbox"/>	<input type="checkbox"/>																																						
			LF LR RF RR	<input type="checkbox"/>	<input type="checkbox"/>																																						
			D DF L	<input type="checkbox"/>	<input type="checkbox"/>																																						
			LF LR RF RR	<input type="checkbox"/>	<input type="checkbox"/>																																						

ADDITIONAL REMARKS

ADDITIONAL IDENTIFIER: _____

LENGTH (CENTER OF FLUKE TO TIP OF SNOUT ALONG SIDE)

141 CM

- BLOOD Oozing FROM EYES, BLOWHOLE + MOUTH
- VENTRAL SIDE ~~W~~ MULTIPLE SCRAPS - PROBABLY GULL DAMAGE
- STRANDED HIGH ON INTERTIDAL

DISCLAIMER

These data should not be used out of context or without verification. This should be strictly enforced when reporting signs of human interaction data.

DATA ACCESS FOR LEVEL A DATA

Upon written request, certain fields of the Level A Data Sheet will be released to the requestor provided that the requestor credit the stranding network and the National Marine Fisheries Service. The National Marine Fisheries Service will notify the contributing stranding network members that these data have been requested and the intent of use. All other data will be released to the requestor provided that the requestor obtain permission from the contributing stranding network and the National Marine Fisheries Service.

PAPERWORK REDUCTION ACT INFORMATION

Public reporting burden for the collection of information is estimated to average 20 minutes per response, including the time for reviewing instructions, searching existing data sources, gathering and maintaining the data needed, and completing and reviewing the collection of information. Send comments regarding this burden estimate or any other aspect of the collection of information, including suggestions for reducing the burden to: Chief, Marine Mammal Conservation Division, Office of Protected Resources, NOAA Fisheries, 1315 East-West Highway, Silver Spring, Maryland 20910. Notwithstanding any other provision of the law, no person is required to respond to, nor shall any person be subjected to a penalty for failure to comply with, a collection of information subject to the requirements of the Paperwork Reduction Act, unless the collection of information displays a currently valid Office of Management and Budget (OMB) Control Number.



MARINE MAMMAL STRANDING REPORT - LEVEL A DATA

FIELD # WIEGSTR035B NMFS REGIONAL #: 03NWR05019 NATIONAL DATABASE #: NW-2003-1000819
 COMMON NAME: Harbor Porpoise GENUS: Phocoena SPECIES: phocoena
 EXAMINER: _____ Letterholder: Matt Klope
 Name: Susan Berta (Glynn Schmid) Affiliation: Ocea Network / Beach Watchers
 Address: 2403 S. North Bluff, Greenbank WA 98253 Phone: 360-678-3451

LOCATION State: <u>WA</u> County: <u>Island</u> City: <u>Greenbank</u> Locality Details: <u>Lagoon Pt, on beach in front of 245 Westcliff Dr</u> Latitude: _____ N Longitude: _____ W	OCCURRENCE DETAILS Mass Stranding: <input type="checkbox"/> YES <input checked="" type="checkbox"/> NO # Animals: _____ Signs of Human Interaction: <input type="checkbox"/> YES <input checked="" type="checkbox"/> NO <input type="checkbox"/> Could Not be Determined (C&D) (Check one or more) <input type="checkbox"/> 1. Boat Collision <input type="checkbox"/> 3. Fishery Interaction <input type="checkbox"/> 2. Shot <input type="checkbox"/> 4. Other Human Interaction: _____ How determined: <input checked="" type="checkbox"/> External Exam <input type="checkbox"/> Internal Exam <input type="checkbox"/> Not Examined Other Causes: <input type="checkbox"/> YES <input type="checkbox"/> NO <input type="checkbox"/> CBD Describe: _____
---	---

DATE OF INITIAL OBSERVATION Year: <u>03</u> Month: <u>05</u> Day: <u>17</u> STATUS (Check ONE) <input type="checkbox"/> 1. Alive <input type="checkbox"/> 4. Advanced Decomposition <input checked="" type="checkbox"/> 2. Fresh Dead <input type="checkbox"/> 5. Mummified/Skeletal <input type="checkbox"/> 3. Moderate Decomposition <input type="checkbox"/> 6. Dead - Condition Unknown	DATE OF EXAMINATION (LEVEL A) <input type="checkbox"/> Not Able to Examine Year: <u>03</u> Month: <u>05</u> Day: <u>17</u> CONDITION (Check ONE) <input type="checkbox"/> 1. Alive <input type="checkbox"/> 4. Advanced Decomposition <input checked="" type="checkbox"/> 2. Fresh Dead <input type="checkbox"/> 5. Mummified/Skeletal <input type="checkbox"/> 3. Moderate Decomposition <input type="checkbox"/> 6. Dead - Condition Unknown
---	---

INITIAL LIVE ANIMAL DISPOSITION (Check one or more) <input type="checkbox"/> 1. Left at Site <input type="checkbox"/> 5. Euthanized at Site <input type="checkbox"/> 2. Immediate Release at Site <input type="checkbox"/> 6. Died at Site <input type="checkbox"/> 3. Relocated <input type="checkbox"/> 7. Transferred to Rehabilitation <input type="checkbox"/> 4. Disentangled <input type="checkbox"/> 8. Died During Transport <input type="checkbox"/> 9. Other CONDITION (Check ONE) <input type="checkbox"/> 1. Sick <input type="checkbox"/> 3. Apparently Healthy <input type="checkbox"/> 5. Other <input type="checkbox"/> 2. Injured <input type="checkbox"/> 4. Out of Habitat Date: _____ Rehabilitation Facility: _____ Comments: _____	MORPHOLOGICAL DATA SEX (Check ONE) AGE CLASS (Check ONE) <input type="checkbox"/> 1. Male <input checked="" type="checkbox"/> 1. Adult <input type="checkbox"/> 4. Pup/Calf <input checked="" type="checkbox"/> 2. Female <input type="checkbox"/> 2. Subadult <input type="checkbox"/> 5. Unknown <input type="checkbox"/> 3. Unknown <input type="checkbox"/> 3. Yearling Straight Length: <u>138 cm</u> <input type="checkbox"/> cm <input checked="" type="checkbox"/> in <input type="checkbox"/> actual <input type="checkbox"/> estimate Weight: <u>54</u> <input checked="" type="checkbox"/> kg <input type="checkbox"/> lb <input checked="" type="checkbox"/> actual <input type="checkbox"/> estimate PHOTOS/VIDEOS TAKEN: <input checked="" type="checkbox"/> YES <input type="checkbox"/> NO <u>digital photos & video</u> Disposition: <u>Brad Hansen picked up specimen the evening of 5/17/03, brought to NMML for further examination</u>
---	--

TAG DATA <table border="1" style="width: 100%; border-collapse: collapse;"> <thead> <tr> <th>ID#</th> <th>Color</th> <th>Type</th> <th>*Placement (Circle One)</th> <th>Applied</th> <th>Present</th> </tr> </thead> <tbody> <tr> <td>_____</td> <td>_____</td> <td>_____</td> <td>D DF L LF LR RF RR</td> <td style="text-align: center;"><input type="checkbox"/></td> <td style="text-align: center;"><input type="checkbox"/></td> </tr> <tr> <td>_____</td> <td>_____</td> <td>_____</td> <td>D DF L LF LR RF RR</td> <td style="text-align: center;"><input type="checkbox"/></td> <td style="text-align: center;"><input type="checkbox"/></td> </tr> <tr> <td>_____</td> <td>_____</td> <td>_____</td> <td>D DF L LF LR RF RR</td> <td style="text-align: center;"><input type="checkbox"/></td> <td style="text-align: center;"><input type="checkbox"/></td> </tr> </tbody> </table> <p>*D=Dorsal; DF=Dorsal Fin; L=Lateral Body LF=Left Front; LR=Left Rear; RF=Right Front; RR=Right Rear</p>	ID#	Color	Type	*Placement (Circle One)	Applied	Present	_____	_____	_____	D DF L LF LR RF RR	<input type="checkbox"/>	<input type="checkbox"/>	_____	_____	_____	D DF L LF LR RF RR	<input type="checkbox"/>	<input type="checkbox"/>	_____	_____	_____	D DF L LF LR RF RR	<input type="checkbox"/>	<input type="checkbox"/>	WHOLE CARCASS DISPOSAL (Check one or more) <input type="checkbox"/> 1. Left at Site <input type="checkbox"/> 4. Rendered <input type="checkbox"/> 7. Unknown <input type="checkbox"/> 2. Buried <input type="checkbox"/> 5. Sunk <input type="checkbox"/> 3. Towed <input checked="" type="checkbox"/> 6. Frozen for Later Examination SPECIMEN DISPOSITION (Check one or more) <input checked="" type="checkbox"/> 1. Scientific Collection <input type="checkbox"/> 2. Educational Collection <input type="checkbox"/> 3. Other: Comments: <u>Brought to NMML by Brad Hansen to be necropsied with other recent porpoise specimens</u> NECROPSIED <input checked="" type="checkbox"/> YES <input type="checkbox"/> NO Date: <u>7/24/03</u> NECROPSIED BY: _____
ID#	Color	Type	*Placement (Circle One)	Applied	Present																				
_____	_____	_____	D DF L LF LR RF RR	<input type="checkbox"/>	<input type="checkbox"/>																				
_____	_____	_____	D DF L LF LR RF RR	<input type="checkbox"/>	<input type="checkbox"/>																				
_____	_____	_____	D DF L LF LR RF RR	<input type="checkbox"/>	<input type="checkbox"/>																				

6/30/03

ADDITIONAL REMARKS

ADDITIONAL IDENTIFIER: _____

The call came in at 8³⁰ am, Lynn Schmid & I responded at approx. 10 am. No visible cause of death, freshly dead specimen. Brad Hansen was called to collect specimen, due to high number of porpoise strandings & coincident Naval sonar exercises. After measuring & examination, we wrapped the specimen in a tarp to protect from predation by eagles, & moved it above the high tide line. Brad picked it up that evening.

DISCLAIMER

These data should not be used out of context or without verification. This should be strictly enforced when reporting signs of human interaction data.

DATA ACCESS FOR LEVEL A DATA

Upon written request, certain fields of the Level A Data Sheet will be released to the requestor provided that the requestor credit the stranding network and the National Marine Fisheries Service. The National Marine Fisheries Service will notify the contributing stranding network members that these data have been requested and the intent of use. All other data will be released to the requestor provided that the requestor obtain permission from the contributing stranding network and the National Marine Fisheries Service.

PAPERWORK REDUCTION ACT INFORMATION

Public reporting burden for the collection of information is estimated to average 20 minutes per response, including the time for reviewing instructions, searching existing data sources, gathering and maintaining the data needed, and completing and reviewing the collection of information. Send comments regarding this burden estimate or any other aspect of the collection of information, including suggestions for reducing the burden to: Chief, Marine Mammal Conservation Division, Office of Protected Resources, NOAA Fisheries, 1315 East-West Highway, Silver Spring, Maryland 20910. Notwithstanding any other provision of the law, no person is required to respond to, nor shall any person be subjected to a penalty for failure to comply with, a collection of information subject to the requirements of the Paperwork Reduction Act, unless the collection of information displays a currently valid Office of Management and Budget (OMB) Control Number.



MARINE MAMMAL STRANDING REPORT

NW-2003-100785

SID# _____ (NMFS USE)

FIELD NO.: 2003-SJ009 NMFS REGISTRATION NO.: 03NWRO5012
 COMMON NAME: Harbor Porpoise GENUS: Phocoena SPECIES: phocoena
 EXAMINER Name: R. Osborne/K. Balcomb Agency: The Whale Museum Phone: 360 378-4710
 Address: P.O. Box 945 Friday Harbor WA 98250

*To scan 7/20
425*

LOCATION State: <u>WA</u> County: <u>San Juan</u> City: _____ Locality Details: <u>Eagle Pt.,</u> <u>West side</u> <u>San Juan Island</u> <u>floating</u> *Latitude: _____ N *Longitude: _____ W	TYPE OF OCCURRENCE Mass Stranding: <input type="checkbox"/> Yes <input checked="" type="checkbox"/> No # Animals <u>1</u> Human Interaction: <input type="checkbox"/> Yes <input type="checkbox"/> No <input checked="" type="checkbox"/> ? Check one: <input type="checkbox"/> 1. Boat Collision <input type="checkbox"/> 2. Shot <input type="checkbox"/> 3. Fishery Interaction <input type="checkbox"/> 4. Other _____ How determined: _____ Other Causes (if known): _____
---	---

DATE OF INITIAL OBSERVATION: Yr. <u>2003</u> Mo. <u>5</u> Day <u>20</u> CONDITION: Check one: <input type="checkbox"/> 1. Alive <input checked="" type="checkbox"/> 2. Fresh dead <input type="checkbox"/> 3. Moderate decomp. <input type="checkbox"/> 4. Advanced decomp. <input type="checkbox"/> 5. Mummified <input type="checkbox"/> 7. Unknown	DATE OF EXAMINATION: Yr. <u>2003</u> Mo. <u>5</u> Day <u>20</u> CONDITION: Check one: <input type="checkbox"/> 1. Alive <input checked="" type="checkbox"/> 2. Fresh dead <input type="checkbox"/> 3. Moderate decomp. <input type="checkbox"/> 4. Advanced decomp. <input type="checkbox"/> 5. Mummified <input type="checkbox"/> 7. Unknown
--	--

LIVE ANIMAL — Condition and Disposition: Check one or more: <input type="checkbox"/> 1. Released at site <input type="checkbox"/> 2. Sick <input type="checkbox"/> 3. Injured <input type="checkbox"/> 4. Died <input type="checkbox"/> 5. Euthanized <input type="checkbox"/> 6. Rehabilitated and released <input type="checkbox"/> 7. Unknown Transported to: _____ <input type="checkbox"/> Died <input type="checkbox"/> Released Date: _____	TAGS APPLIED?: <input type="checkbox"/> Yes <input checked="" type="checkbox"/> No TAGS PRESENT?: <input type="checkbox"/> Yes <input checked="" type="checkbox"/> No <table style="width: 100%; border-collapse: collapse;"> <tr> <td></td> <td style="text-align: center;">Dorsal</td> <td style="text-align: center;">Left</td> <td style="text-align: center;">Right</td> </tr> <tr> <td>Tag No.(s):</td> <td>_____</td> <td>_____</td> <td>_____</td> </tr> <tr> <td>Color(s):</td> <td>_____</td> <td>_____</td> <td>_____</td> </tr> <tr> <td>Type:</td> <td>_____</td> <td>_____</td> <td>_____</td> </tr> <tr> <td>Placement</td> <td></td> <td style="text-align: center;">Front/Rear</td> <td style="text-align: center;">Front/Rear</td> </tr> </table>		Dorsal	Left	Right	Tag No.(s):	_____	_____	_____	Color(s):	_____	_____	_____	Type:	_____	_____	_____	Placement		Front/Rear	Front/Rear
	Dorsal	Left	Right																		
Tag No.(s):	_____	_____	_____																		
Color(s):	_____	_____	_____																		
Type:	_____	_____	_____																		
Placement		Front/Rear	Front/Rear																		

6/23/03

CARCASS — Disposition: Check one: <input type="checkbox"/> 1. Left at site <input type="checkbox"/> 2. Buried <input type="checkbox"/> 3. Towed <input checked="" type="checkbox"/> 4. Sci. collection: (see below) <input type="checkbox"/> 5. Edu. collection: (see below) <input type="checkbox"/> 6. Other _____ <input type="checkbox"/> 7. Unknown NECROPSIED? <u>7/23/03</u> <input checked="" type="checkbox"/> Yes <input type="checkbox"/> No	MORPHOLOGICAL DATA: Sex — Check one: <input checked="" type="checkbox"/> 1. Male <i>immature</i> <input type="checkbox"/> 2. Female <input type="checkbox"/> 7. Unknown Contour: _____ Straight Length: <u>123</u> cm <input type="checkbox"/> in <input type="checkbox"/> est *Weight <u>30</u> kg <input type="checkbox"/> lb <input type="checkbox"/> est PHOTOS TAKEN? <input checked="" type="checkbox"/> Yes <input type="checkbox"/> No Girth _____ in _____ est
---	--

REMARKS: Towed by Whale-watch operator to Snug Harbor, Ken Balcomb picked up animal and stored it in Center for Whale Research (CWR) freezer

DISPOSITION OF TISSUE/SKELETAL MATERIAL: _____

MARINE MAMMAL STRANDING REPORT

NW-2003-1002228
SID# (NMFS USE)

FIELD NO.: 2003-SJ020 NMFS REGISTRATION NO.: 03NWR05046
COMMON NAME: Harbor porpoise GENUS: Phocoena SPECIES: phocoena
EXAMINER Name: J. Knight Agency: The Whale Museum Phone: (360) 378-4710
Address: PO Box 945 Friday Harbor WA 98250

LOCATION State: <u>WA</u> County: <u>San Juan</u> City: _____ Locality Details: <u>Flint Beach, Lopez Island</u> *Latitude: _____ N *Longitude: _____ W	TYPE OF OCCURRENCE Mass Stranding: <input type="checkbox"/> Yes <input checked="" type="checkbox"/> No # Animals <u>1</u> Human Interaction: <input type="checkbox"/> Yes <input type="checkbox"/> No <input type="checkbox"/> ? Check one: <input type="checkbox"/> 1. Boat Collision <input type="checkbox"/> 2. Shot <input type="checkbox"/> 3. Fishery Interaction <input type="checkbox"/> 4. Other _____ How determined: _____ Other Causes (if known): _____
---	---

DATE OF INITIAL OBSERVATION: Yr. <u>2003</u> Mo. <u>5</u> Day <u>25</u> CONDITION: Check one: <input type="checkbox"/> 1. Alive <input type="checkbox"/> 2. Fresh dead <input type="checkbox"/> 3. Moderate decomp. <input checked="" type="checkbox"/> 4. Advanced decomp. <input type="checkbox"/> 5. Mummified <input type="checkbox"/> ? Unknown	DATE OF EXAMINATION: Yr. _____ Mo. _____ Day _____ CONDITION: Check one: <input type="checkbox"/> 1. Alive <input type="checkbox"/> 2. Fresh dead <input type="checkbox"/> 3. Moderate decomp. <input type="checkbox"/> 4. Advanced decomp. <input type="checkbox"/> 5. Mummified <input type="checkbox"/> ? Unknown
--	--

LIVE ANIMAL — Condition and Disposition: Check one or more: <input type="checkbox"/> 1. Released at site <input type="checkbox"/> 2. Sick <input type="checkbox"/> 3. Injured <input type="checkbox"/> 4. Died <input type="checkbox"/> 5. Euthanized <input type="checkbox"/> 6. Rehabilitated and released <input type="checkbox"/> ? Unknown Transported to: _____ <input type="checkbox"/> Died <input type="checkbox"/> Released Date: _____	TAGS APPLIED?: <input type="checkbox"/> Yes <input type="checkbox"/> No TAGS PRESENT?: <input type="checkbox"/> Yes <input type="checkbox"/> No Dorsal Left Right Tag No.(s): _____ Color(s): _____ Type: _____ Placement Front/Rear Front/Rear
---	---

3/17/04

CARCASS — Disposition: Check one: <input checked="" type="checkbox"/> 1. Left at site <input type="checkbox"/> 2. Buried <input type="checkbox"/> 3. Towed <input type="checkbox"/> 4. Sci. collection: (see below) <input type="checkbox"/> 5. Edu. collection: (see below) <input type="checkbox"/> 6. Other _____ <input type="checkbox"/> ? Unknown NECROPSIED? <input type="checkbox"/> Yes <input type="checkbox"/> No	MORPHOLOGICAL DATA: Sex — Check one: <input type="checkbox"/> 1. Male <input type="checkbox"/> 2. Female <input type="checkbox"/> ? Unknown Straight Length: _____ <input type="checkbox"/> cm <input type="checkbox"/> in <input type="checkbox"/> est *Weight _____ <input type="checkbox"/> kg <input type="checkbox"/> lb <input type="checkbox"/> est PHOTOS TAKEN? <input type="checkbox"/> Yes <input type="checkbox"/> No
---	--

REMARKS: Dead on beach. Scavenged by eagles

DISPOSITION OF TISSUE/SKELETAL MATERIAL: _____

recog 5/10
7/22

1 SE
CT done

MARINE MAMMAL STRANDING REPORT - LEVEL A DATA

FIELD #: CRC 490 NMFS REGIONAL #: 03NWRO6005 NATIONAL DATABASE #: NW-2003-100106
 COMMON NAME: Harbor Porpoise GENUS: P. SPECIES: phocoena
 EXAMINER: _____ Letterholder: _____
 Name: Cascadia Research Affiliation: _____
 Address: _____ Phone: _____

LOCATION State: <u>WA</u> County: <u>Pacific</u> City: <u>Long Beach</u> Locality Details: _____ Latitude: _____ N Longitude: _____ W	OCCURRENCE DETAILS Mass Stranding: <input type="checkbox"/> YES <input type="checkbox"/> NO # Animals: <u>1</u> Signs of Human Interaction: <input type="checkbox"/> YES <input checked="" type="checkbox"/> NO <input checked="" type="checkbox"/> Could Not be Determined (CBD) (Check one or more) <input type="checkbox"/> 1. Boat Collision <input type="checkbox"/> 3. Fishery Interaction <input type="checkbox"/> 2. Shot <input type="checkbox"/> 4. Other Human Interaction: _____ How determined: <input checked="" type="checkbox"/> External Exam <input type="checkbox"/> Internal Exam <input type="checkbox"/> Not Examined Other Causes: <input type="checkbox"/> YES <input type="checkbox"/> NO <input checked="" type="checkbox"/> CBD Describe: _____
	MS#: _____ (NMFS USE)

DATE OF INITIAL OBSERVATION Year: <u>03</u> Month: <u>06</u> Day: <u>02</u> STATUS (Check ONE) <input type="checkbox"/> 1. Alive <input type="checkbox"/> 4. Advanced Decomposition <input checked="" type="checkbox"/> 2. Fresh Dead <input type="checkbox"/> 5. Mummified/Skeletal <input type="checkbox"/> 3. Moderate Decomposition <input type="checkbox"/> 6. Dead - Condition Unknown	DATE OF EXAMINATION (LEVEL A) <input type="checkbox"/> Not Able to Examine Year: <u>03</u> Month: <u>06</u> Day: <u>02</u> CONDITION (Check ONE) <input type="checkbox"/> 1. Alive <input type="checkbox"/> 4. Advanced Decomposition <input checked="" type="checkbox"/> 2. Fresh Dead <input type="checkbox"/> 5. Mummified/Skeletal <input type="checkbox"/> 3. Moderate Decomposition <input type="checkbox"/> 6. Dead - Condition Unknown
---	---

INITIAL LIVE ANIMAL DISPOSITION (Check one or more) <input type="checkbox"/> 1. Left at Site <input type="checkbox"/> 5. Euthanized at Site <input type="checkbox"/> 2. Immediate Release at Site <input type="checkbox"/> 6. Died at Site <input type="checkbox"/> 3. Relocated <input type="checkbox"/> 7. Transferred to Rehabilitation <input type="checkbox"/> 4. Disentangled <input type="checkbox"/> 8. Died During Transport <input type="checkbox"/> 9. Other CONDITION (Check ONE) <input type="checkbox"/> 1. Sick <input type="checkbox"/> 3. Apparently Healthy <input type="checkbox"/> 5. Other <input type="checkbox"/> 2. Injured <input type="checkbox"/> 4. Out of Habitat Date: _____ Rehabilitation Facility: _____ Comments: _____	MORPHOLOGICAL DATA SEX (Check ONE) <input checked="" type="checkbox"/> 1. Male <input type="checkbox"/> 2. Female <input type="checkbox"/> 3. Unknown AGE CLASS (Check ONE) <input checked="" type="checkbox"/> 1. Adult <input type="checkbox"/> 4. Pup/Calf <input checked="" type="checkbox"/> 2. Subadult <input type="checkbox"/> 5. Unknown <input type="checkbox"/> 3. Yearling Straight Length: <u>146</u> <input checked="" type="checkbox"/> cm <input type="checkbox"/> in <input checked="" type="checkbox"/> actual <input type="checkbox"/> estimate Weight: <u>39</u> <input checked="" type="checkbox"/> kg <input type="checkbox"/> lb <input checked="" type="checkbox"/> actual <input type="checkbox"/> estimate PHOTOS/VIDEOS TAKEN: <input checked="" type="checkbox"/> YES <input type="checkbox"/> NO Disposition: <u>NWR office</u>
---	--

TAG DATA <table border="1"> <thead> <tr> <th>ID#</th> <th>Color</th> <th>Type</th> <th>*Placement (Circle One)</th> <th>Applied</th> <th>Present</th> </tr> </thead> <tbody> <tr> <td>_____</td> <td>_____</td> <td>_____</td> <td>D DF L LF LR RF RR</td> <td><input type="checkbox"/></td> <td><input type="checkbox"/></td> </tr> <tr> <td>_____</td> <td>_____</td> <td>_____</td> <td>D DF L LF LR RF RR</td> <td><input type="checkbox"/></td> <td><input type="checkbox"/></td> </tr> <tr> <td>_____</td> <td>_____</td> <td>_____</td> <td>D DF L LF LR RF RR</td> <td><input type="checkbox"/></td> <td><input type="checkbox"/></td> </tr> </tbody> </table> <p>*D=Dorsal; DF=Dorsal Fin; L=Lateral Body LF=Left Front; LR=Left Rear; RF=Right Front; RR=Right Rear</p>	ID#	Color	Type	*Placement (Circle One)	Applied	Present	_____	_____	_____	D DF L LF LR RF RR	<input type="checkbox"/>	<input type="checkbox"/>	_____	_____	_____	D DF L LF LR RF RR	<input type="checkbox"/>	<input type="checkbox"/>	_____	_____	_____	D DF L LF LR RF RR	<input type="checkbox"/>	<input type="checkbox"/>	WHOLE CARCASS DISPOSAL (Check one or more) <input type="checkbox"/> 1. Left at Site <input type="checkbox"/> 4. Rendered <input type="checkbox"/> 7. Unknown <input type="checkbox"/> 2. Buried <input type="checkbox"/> 5. Sunk <input type="checkbox"/> 3. Towed <input checked="" type="checkbox"/> 6. Frozen for Later Examination SPECIMEN DISPOSITION (Check one or more) <input checked="" type="checkbox"/> 1. Scientific Collection <input type="checkbox"/> 2. Educational Collection <input type="checkbox"/> 3. Other: _____ Comments: _____ NECROPSIED <input checked="" type="checkbox"/> YES <input type="checkbox"/> NO Date: <u>7/22/03</u> NECROPSIED BY: _____
ID#	Color	Type	*Placement (Circle One)	Applied	Present																				
_____	_____	_____	D DF L LF LR RF RR	<input type="checkbox"/>	<input type="checkbox"/>																				
_____	_____	_____	D DF L LF LR RF RR	<input type="checkbox"/>	<input type="checkbox"/>																				
_____	_____	_____	D DF L LF LR RF RR	<input type="checkbox"/>	<input type="checkbox"/>																				

Appendix C. – Investigation team members with affiliations and expertise.

Investigation Team Leaders -

Darlene Ketten

Biology Department
Woods Hole Oceanographic Institution
Woods Hole MA 02543 USA

Dr. Ketten is a marine biologist and neuroanatomist specializing in how behavior is linked to sensory system structure and function. She holds joint appointments as a senior scientist in the biology department of Woods Hole Oceanographic Institution and as assistant professor in Otolaryngology at Harvard Medical School. Her current work focuses on underwater sound reception and hearing mechanisms of marine mammals and research on the diagnostic and mechanistic analysis of pathology, trauma and disease of the ears and ear region. In addition to basic research, Dr. Ketten provides specialty forensic analyses of the head and neck for NMFS investigations in stranded animals. Dr. Ketten has served on federal advisory boards and panels on hearing, bioacoustics, acoustic trauma, cochlear implant policy and procedures, marine mammal acoustics and ocean noise for the National Institute of Health, National Institutes of Deafness and Communication Disorders, NIH Consensus Development Conferences, the National Academy of Sciences, the Marine Mammal Commission, Minerals Management Service, NATO, Office of Naval Research and NMFS.

William A. McLellan

University of North Carolina, Wilmington
601 S. College Dr.
Wilmington, NC 28403

Bill is a Research Scientist at the University of North Carolina at Wilmington. Mr. McLellan is the North Carolina State Stranding Coordinator and the Large Whale Mortality Team Leader for the mid-Atlantic and recently received the NOAA Environmental Hero Award in recognition of outstanding efforts to respond and investigate stranded marine mammals throughout the nation.

Ann Pabst

University of North Carolina, Wilmington
601 S. College Dr.
Wilmington, NC 28403

Dr. Pabst is a Professor in Biological Sciences at the University of North Carolina at Wilmington. Her work on the bio-mechanics of small cetacean skin and blubber combines the principles of mechanical engineering with the study of organismal form and function using quantitative morphological techniques, image analysis, and mechanical tests.

Both McLellan and Pabst have over 20 years of experience working with dead stranded and live cetaceans. Harbor porpoises have been a focal species for this team - they have necropsied over 250 porpoises during their research. Their current focus, on the functional morphology of cetaceans is specific to locomotion and thermoregulation but extends also to the functional development of muscle, skeleton and skin.

Additional team members-

Stephen Raverty

Ministry of Agriculture Food and Fisheries
1767 Angus Campbell Rd.
Abbotsford, British Columbia
V3G 2M3
Canada

Dr. Raverty is a board-certified, veterinary pathologist with the Ministry of Agriculture, Food and Fisheries in Abbotsford, British Columbia and over the previous 5 years has participated in the post mortem examination and disease outbreak investigations of stranded marine mammals off the coast of British Columbia and more recently within Washington state.

Michelle Fleetwood

Armed Forces Institute of Pathology
6825 16th St. NW
Washington, DC 20306

Dr. Fleetwood, DVM, Chief, Consultation Branch, Department of Veterinary Pathology, Armed Forces Institute of Pathology. She is a Diplomate of the American College of Veterinary Pathologists.

Joseph K. Gaydos

SeaDoc Society
UC Davis Wildlife Health Center
982 Deer Harbor Rd.
Eastsound, WA 98245

Dr. Gaydos is a wildlife veterinarian and the staff scientist for the SeaDoc Society (UC Davis Wildlife Health Center). He is a veterinarian and has a PhD in wildlife diseases. He resides on Orcas Island, Washington State and has worked with Rich Osborne of the Whale Museum for the past year on a project determining the causes of death for stranded marine mammals in San Juan County, Washington.

Steve Jeffries

Washington Department of Fish and Wildlife
Marine Mammal Program
7801 Phillips Rd. SW
Tacoma, WA 98498

Mr. Jeffries is a Research Scientist with State of Washington Department of Fish and Wildlife's Marine Mammal Investigation unit. Primary response center for Northwest Marine Mammal Stranding Network. Extensive experience with examining marine mammals from regional fishery bycatch and strandings in Northwest. Primary response center for marine mammal strandings in Washington since 1980.

Tara Cox

Marine Mammal Commission

4340 East-West Highway, Room 905
Bethesda, MD 20814

Dr. Cox is Assistant Scientific Program Director, Marine Mammal Commission

Dyanna Lambourn

Washington Department of Fish and Wildlife
Marine Mammal Program
7801 Phillips Rd. SW
Tacoma, WA 98498

Ms. Lambourn is a Wildlife Biologist with the Marine Mammal Investigation Program of the Washington Department of Fish and Wildlife.

Brad Hanson

Northwest Fisheries Science Center
2725 Montlake Blvd. East
Seattle, WA 98112-2097

Dr. Hanson is a biologist with the Marine Mammal Program, Northwest Fisheries Science Center, NMFS.

Brent Norberg

Lynne Barre

Stephanie Norman

NOAA/NMFS
NWR/Protected Resources Division
7600 Sand Point Way, NE
Building 1
Seattle, WA 98115

Mr. Norberg is the Northwest Regional Marine Mammal Stranding Coordinator with the Protected Resources Division, Northwest Regional Office, NMFS.

Ms. Barre is a Marine Mammal Specialist with the Protected Resources Division, Northwest Regional Office, NMFS.

Dr. Norman is a Marine Mammal Veterinarian with the Protected Resources Division, Northwest Regional Office, NMFS.

Scott Cramer

Biology Department

Woods Hole Oceanographic Institution

Woods Hole MA 02543 USA

Mr. Cramer is a research assistant in Dr. Ketten's laboratory.

Appendix D. CT scan results

HARVARD MEDICAL SCHOOL
DEPARTMENT OF OTOLGY AND LARYNGOLOGY
HEAD AND NECK IMAGING SERVICE
MASSACHUSETTS EYE AND EAR INFIRMARY
BOSTON, MASSACHUSETTS 02114



CT Imaging Report to NOAA Fisheries, NW Office, Seattle, Washington

Submitted to: Dr. Brent Norberg

Provided by: D.R. Ketten, Ph.D., Dir., Head and Neck Imaging Service, MEEI; Senior Scientist, WHOI

NOTE:

This report is based on images provided by Center for Diagnostic Imaging (CDI), Mountlake Terrace, Washington, the scan facility contracted by NOAA Fisheries for imaging these cases, and for one case, by an auxiliary center, First Imaging Diagnostics (FID). Additional, multi-plane reformats, magnifications of basic scans, and 3D reconstructions were obtained through post-scan processing of the original image files on the Volume Zoom scanner at WHOI Ocean Imaging Center (WHOI OIC) in conjunction with the MEEI Head and Neck Imaging Service and the Harvard Medical School Dept. of Otolgy and Laryngology (MEEI/HMS).

The original image files produced by CDI and FID used conventional human bone and soft tissue protocols and windowing that provide good general images but are sub-optimal for some specialized odontocete cranial structures or for detection of inner ear abnormalities in marine mammals because of extreme tissue densities and differences in contiguous tissue suites. Consequently, reformats were performed in all cases in order to provide image sets that are consistent with both human UHR temporal bone and cranial exams as well as with preferential imaging protocols established by the WHOI facility to maximize the information that could be obtained from this scan series. Each series or set of scans consists of 30 to 70 images. Consequently for each animal, between 200 and 1000 images were reviewed.

Observations provided in the following report focus on cranial anatomy as the area of expertise for this service. Additional analyses are reported for post-cranial regions and organs in some cases but should not be considered to be a comprehensive analysis for those body regions. All observations are necessarily limited based on the original protocols employed as image files cannot be optimized retrospectively for any tissue. Scan numbers in this report refer to image position numbers in the original series for ease of reference in all cases.

Copies of images and the reports of results provided here may be distributed only with permission of this office. All data and images from the WHOI/HMS facility are to be treated with a level of confidentiality strictly consistent with the HIPAA guidelines.

These scans and related reports are confidential and should be retained by the requesting agency. Data and findings included in this report are confidential, proprietary and produced only for release to the requesting agency and participants of the official necropsy team. WHOI OIC reformatted images and reconstructions are

copyrighted and carry all conventional restrictions for use. Do not distribute this report or related images to third parties without first contacting this office for releases.

Raw scan data were retained by the original scan facility; images were distributed on CD formatted for auto-display. Reformatted high-resolution images produced by WHOI OIC were archived on CD and MO disks and are available in DICOM, tiff, or jpg formats. If additional images or projections are required for this case, please contact Dr. Ketten at the WHOI address listed at the end of the report.

re: P-pho79-03NWR05001

Species *Phocoena phocoena*

Imaging Analysis Requested by: B. Norberg, NOAA Fisheries

Scan date: 20 July 2003; reformats obtained August-November 2003

WHOI Scan technician(s): J. Arruda

Scan Analyses: D.R. Ketten

Report Dictation Date: Preliminary 23 July 2003; final 15 November 2003

Scan Parameters

Primary scans were obtained by Center for Diagnostic Imaging and formatted as a series of transaxial head and body images in both soft and bone windows using a spiral scan protocol. All primary scans were obtained with the body placed prone, rostrum first.

Nine primary image sets were provided by CDI. CDI primary scans were imaged with variable image slice thicknesses of 1-8 mm in bone and soft tissue protocols. The majority of scans were obtained at 120 kV/250 MA. At WHOI OIC, 10 reformatted sets were produced, comprising soft tissue and bony windows of the head and body with expanded views of the brain and ear in transaxial, sagittal and coronal planes to obtain detail from each ear region. Three-dimensional reconstructions were also produced of some head structures.

History

No details on the history of this animal were available at the time scans were reviewed.

General Observations

Cranial, thoracic, and abdominal images are provided. Bright signals that appear on the surface of the animal are likely to be sand or other similar material

Cranial Soft Tissues

All soft tissues of the head are in relatively poor condition with some separation of tissue layers and multiple air pockets ranging from minor to multiple cm. spaces consistent with dissection by gaseous decomposition of the tissues post-mortem.

Extensive external ridging on the transaxial images suggests there are superficial scrapes consistent with abrasions on the beach or scavenger damage.

The fatty layers on the right side of the head are noticeably degenerated.

The soft-walled narial passages are poorly defined and collapsed.

Sinuses are normal with good pneumatization.

The melon has a relatively uniform attenuation, suggesting moderate decomposition although it retains a fundamentally fatty attenuation signature. There is one region of slightly increased attenuation near the core that is consistent with a small contusion but the degenerative quality of all tissues makes a definitive statement from attenuation impossible for this case.

Intracranial/Brain

All skull features are normal.

The brain is intact. There are extensive regions of extravasated blood in the skull base and basioccipital regions with minor poolings in the temporal areas. This conclusion is based on

HU readings of 27 to 40 and on the fluid, pooled appearance of the deposits. By contrast, fresh clotted blood would have a reading >60. There is no evidence of well demarcated hemorrhage or contusion within any brain region. Meningeal suspensory fibers and vessel tracks are intact and visible traversing the subarachnoid spaces.

There is little differentiation of the cortical layers in the soft tissue scans, suggesting moderate to severe autolysis.

The ventricles are poorly defined and likely reduced by freezing.

Eyes

Both eyes are present. The left globe is collapsed. The lens is displaced ventrally in both eyes (IP 484.5-500.5). There is little differentiation of the external and internal regions of the globe bilaterally indicating that both eyes are compromised with the left in poorer condition than the right.

Ears

Peribullar region

There is an extensive soft tissue mass in the left medial peribullar space that has irregular but well defined margins and attenuation values consistent with peribullar parasites. The retrobullar spaces have minor clotting bilaterally but are otherwise normal bilaterally with good pneumatization.

Internal Auditory Canal (IAC)/Acousto-Vestibular/Facial Nerve

The internal auditory canals are well defined. There is no evidence of blood or other abnormal material within either IAC. VIIIth and VIIth nerves are intact bilaterally and well defined.

Middle Ear

The middle ear cavities are normal with distinct middle ear air spaces bilaterally and a well-defined corpus cavernosum. All ossicles are intact and normally configured bilaterally. The round window is normal bilaterally. There is a small moderate density mass at the right round window consistent with a minor clot.

Inner Ear

The canals are symmetrical and normal in appearance. There is no evidence in these scans of abnormal intracochlear blood or other cochlear compromise, however, submillimeter images are required to confirm this observation.

Post-cranial Features

Superficially, there are ridges on the ventral and lateral left surfaces suggestive of epidermal abrasions. Fatty tissues throughout the body are particularly poorly preserved.

Thoracic scans show both lungs are partially consolidated with the right lung more compromised than the left. Relatively rapid consolidation is consistent with post-mortem response in marine mammals. However, there are clear abnormalities suggestive of pneumonia and possibly an infectious congestive processes consistent with a premortem pathologic lung condition. It is recommended that lung tissues be examined histologically to determine the exact source of increased densities in this case.

Abnormal features include positive air bronchiogram signs that are consistent with segmental pneumonia in the superior and lateral lobes of the right lung. Exudate is visible in the right pleural space. There are extensive regions of consolidation paralleling the right bronchi and bronchioles. The right bronchial mucosa is thickened. This is particularly evident at the first division of the bronchi.

There are relatively few small, discrete, high density inclusions in both lungs. These are most evident in the right middle lobe (35-50) and are consistent with calcified, parasitic and cystic formations.

The abdominal scans show extensive air throughout the gut. There are multiple regions of disorganized tissue margins, suggesting that there is diffuse parenchymal degeneration in most organs.

Summary

The scans suggest the animal is an adult in a moderate to poor state of preservation. Abnormal lung scans suggestive of pneumonia that is particularly evident in the right lung. Abdominal scans show a patent but unoccupied GI-tract and poor organ preservation. Cranial scans suggest broad post-mortem degenerative changes with poor preservation of most structures. The intracranial spaces have moderate to extensive areas of extravasated blood, consistent with post-mortem seepage and migration. There are no well-defined regions of hemorrhage, but the poor tissue quality makes any conclusion about pre-post mortem deposition difficult. The ears are essentially normal bilaterally. There is a small area in the mid-melon region that appears to be contused; the mandibular structures are largely autolyzed and poorly defined on the scans. Head musculature is intact but poorly preserved.

Cause of Death

Indeterminate: Cause of death cannot be determined from the scan-based information available to date.

Additional Comments

No additional comments or recommendations.

Subject ID

re: P-pho79-03NWR05003

Species *Phocoena phocoena*

Imaging Analysis Requested by: B. Norberg, NOAA Fisheries

Scan date: 20-23 July 2003 with reformats obtained August-November 2003

WHOI Scan technician(s): J. Arruda

Scan Analyses: D.R. Ketten

Report Dictation Date: 15 September, 2003

Scan Parameters

Primary scans were obtained by CDI and formatted as a series of transaxial head images in both soft and bone windows using a spiral scan protocol. All scans were obtained with head prone, rostrum first.

Raw attenuation data were retained by CDI. Image sets were transferred to NOAA Fisheries for analysis by copying onto CD with a WinPacs system. These image files were subsequently reformatted as needed into additional views at the WHOI OIC.

Two scout and four primary image sets plus magnified reformats were produced by CDI and WHOI, comprising soft tissue and bony windows of the head with variable spacings of 1-5 mm and expanded views of the brain and ear in transaxial, sagittal and coronal planes to obtain detail from each ear region. Three-dimensional reconstructions were also produced of some head structures.

History

No details on the history of this animal were available at the time scans were reviewed.

General Observations

Cranial images only are available. The head was decapitated at the occiput and is heavily flensed. It was scanned within wrappings. There is extensive dense material (HU 1000-1500) coating the head and filling the nares, suggesting that this animal was injected with contrast material or may have been soaked in some dense, high contrast fluid.

Cranial Soft Tissues

The majority of soft tissue was removed on the right and dorsal surfaces of the head from the posterior margin of the head forward to the level of the juncture of the nasal and premaxillary bones. All dermis, fats, and musculature are removed from this and the sublingual areas.

The right mandible is abraded, probably as a result of the flensing procedure. All remaining soft tissues of the head are in poor condition. The remaining left mandibular fats, like the

brain, show extensive areas of fissures and granular, crystalline regions that are indicative of freeze-thaw cycles that compromised the tissues. There are also extensive air pockets in the fatty tissues bilaterally. These are most pronounced in the right inner mandibular fats. As noted above, the narial passages are filled with high contrast material and cannot be assessed.

Sinuses are partially occluded with poor pneumatization. The left sinus has moderately dense material coating the medial wall.

Intracranial/Brain

The skull is intact except for the right parietal region which is disrupted and from which a section has been displaced penetrating the brain on the right. The shard is a 13.8X6.6X8 mm wedge of bone penetrating the right parietal and temporal lobes and lodged near the right lateral ventricle. The lack of tissue density changes in the area suggests this is a post mortem trauma.

The brain is intact but has a uniform, granular appearance that suggests it has extensive freezing artifact and has been subjected to several freeze-thaw cycles. Lobe structures are poorly defined. There is little differentiation of the cortical layers in the soft tissue scans, suggesting moderate to severe autolysis. The ventricles are poorly defined and likely reduced by freezing. Because of extensive degeneration, no useful assessment can be made of the premortem condition of the brain.

Eyes

The right eye is missing. The left is collapsed and there are extensive retro-ocular air pockets.

Ears

Peribullar region

The peribullar spaces are aerated and generally normal bilaterally for an animal in this poor preservation state.

Internal Auditory Canal (IAC)/Acousto-Vestibular/Facial Nerve

The internal auditory canals are normal. The VIIIth and VIIth nerves are intact bilaterally and well defined. Both appear smaller than average and are likely partially degenerated.

Middle Ear

The middle ear cavities have aerated middle ear air spaces bilaterally. The corpus cavernosum is present but retracted bilaterally. All ossicles are intact and normally configured bilaterally. The round window and oval windows are intact

Inner Ear

The canals are symmetrical and normal in appearance. There is no evidence in these scans of abnormal intracochlear blood or other cochlear compromise; however, the poor state of preservation makes conclusions about the health of these ears impossible.

Post-cranial Features

No post-cranial scans were provided.

Summary

The scans of this head suggest the animal was an adult in a poor state of preservation. The head is largely denuded with most of the soft tissues missing on the right. The residual tissues, particularly the fats and brain have granular, crystalline characters that are indicative of freeze-thaw changes compromising tissue quality. The right side of the skull is compromised and a portion of the parietal bone penetrates the brain.

There are broad post-mortem degenerative changes with poor preservation of most structures. The ears are essentially normal bilaterally. There are extensive areas on the surface of the head and in the narial passages that are consistent with high density sedimentary deposition or contrast agent injection.

Cause of Death

Indeterminate: Cause of death cannot be determined from the scan-based information available to date.

Additional Comments

No additional comments or recommendations.

re: P-pho79-03NWR05006

Phocoena phocoena

WHOI Case Number:

Imaging Analysis Requested by: B. Norberg, NOAA Fisheries

Scan date: 20-23 July 2003 with reformats obtained August-November 2003

WHOI Scan technician(s): J. Arruda

Scan Analyses: D.R. Ketten

Report Dictation Date: 15 September, 2003

Scan Parameters

Primary scans were obtained by Center for Diagnostic Imaging and formatted as a series of transaxial head and body images in both soft and bone windows using a spiral scan protocol. All primary scans were obtained in with the body placed prone, rostrum first.

Seven primary and two scout image sets were provided by CDI. CDI scans were imaged with variable image slice thicknesses of 1-8 mm in bone and soft tissue protocols. The majority of scans were obtained at 120 kV/250 MA. At WHOI OIC, 10 reformatted sets were produced, comprising soft tissue and bony windows of the head and body with expanded views of the brain and ear in transaxial, sagittal and coronal planes to obtain detail from each ear region. Three-dimensional reconstructions were also produced of some head structures.

History

No details on the history of this animal were available at the time scans were reviewed.

General Observations

Scans are provided for an intact animal. Cranial, thoracic, and abdominal images are provided. There are extensive regions over the entire animal of bright signals with irregular shapes that suggest it is heavily coated in sand or other similar substrate material.

Cranial Soft Tissues

All soft tissues are in relatively poor condition but the majority of tissue suites are intact. The head has extensive superficial and internal deposits of gravel, sediment, or sand. There are extensive patches of irregular surface ridging consistent with superficial abrasions, particularly along the left consistent with abrasions on the beach or scavenger damage.

The nares are filled with high density objects, likely gravel and debris, in the upper regions. The blubber appears to be in average to poor condition with mottled areas of variable densities, consistent with postmortem degeneration.

The right mandibular fats are well-defined considering the other head tissues. The left lateral fats show mid-low density regions consistent with diffuse or mild contusions or extravasated blood. These areas underlie the abraded areas

Intracranial/Brain

All skull features are normal.

The brain is intact but tissue layers are not well-defined. There are extensive regions of extravasated blood in the subarachnoid and subdural regions but the divisions are poorly defined and therefore precise distributions cannot be given. There is little differentiation of

the cortical grey vs. white matter layers in the soft tissue scans, suggesting moderate to severe autolysis.

Eyes

Both eyes are present. The left globe is collapsed and the lens is missing. The lens is displaced ventrally in the right eye.

Ears

Right ear

There is an extensive soft tissue mass in the right dorsal retrobullar space that has irregular attenuation values of 50-60, consistent with an organized clot. The suspensory ligaments are intact.

The internal auditory canal is well defined. There is no evidence of blood or other abnormal material within the IAC. VIIIth and VIIth nerves are intact and well defined. .

The middle ear cavity is normal with distinct middle ear air spaces and a well-defined corpus cavernosum. All ossicles are intact and normally configured (see IP 168-175). The round window is normal. There is a small moderate density reading intracochlear at the right round window consistent with a minor blood deposit. .

Left Ear

The left peri and retrobullar spaces are well aerated and normal in appearance. There is no evidence of extensive parasitism or other compromised regions. The left tympanic bone has a moderately low density for this species and is possibly partially demineralized.

The internal auditory canal is well defined. There is no evidence of blood or other abnormal material within the IAC. VIIIth and VIIth nerves are intact and well defined. .

The middle ear cavity is normal with distinct middle ear air spaces and a well-defined corpus cavernosum. All ossicles are intact and normally configured (see IP 168-175). The round and oval windows are normal.

Post-cranial Features

Superficially, there are extensive abrasions across most of the body, with large deposits of sediment, including invasion of the rectum. The ventral surface has extensive cuts as does the left side of the body.

Thoracic scans show both lungs are consolidated with the right lateral lung more compromised than the left.

There are substantial numbers (50-100) of small,, high density inclusions in both lungs. These are most evident in the anterior or apical lobe and are consistent with calcified, parasitic and cystic nodules. The right bronchus and trachea have distinct deposits of foamy material that is likely to represent sero-sanguinous material.

The abdominal scans show extensive air throughout the intestine. The colon is poorly preserved. The liver is degraded.

Summary

The scans suggest the animal is an adult in a moderate to poor state of preservation. Thoracic scans show the right lung with moderate to extensive areas of consolidation. Both lungs have high density nodules suggestive of parasitic or other chronic infections. The right lung is more compromised than the left, with fluid and foamy deposits in the airways. Abdominal scans show a patent but unoccupied GI-tract and poor organ preservation.

Cranial scans suggest broad post-mortem degenerative changes with poor preservation of most structures. The intracranial spaces have moderate to extensive areas of extravasated blood, consistent with post-mortem seepage and migration. There are no well-defined regions of hemorrhage, but the poor tissue quality makes any conclusion about pre-post mortem deposition difficult. The ears are essentially normal bilaterally but poorly preserved.

Cause of Death

Indeterminate: Cause of death cannot be determined from the scan-based information available to date.

Additional Comments

No additional comments or recommendations.

Subject ID

re: P-pho79-03NWR05007

Species *Phocoena phocoena*

Imaging Analysis Requested by: B. Norberg, NOAA Fisheries

Scan date: 20-23 July 2003 with reformats obtained August-November 2003

WHOI Scan technician(s): J. Arruda

Scan Analyses: D.R. Ketten

Report Dictation Date: 17 September, 2003

Scan Parameters

Primary scans were obtained by Center for Diagnostic Imaging and formatted as a series of transaxial head and body images in both soft and bone windows using a spiral scan protocol. All primary scans were obtained in with the body placed prone, rostrum first. Nine primary and two scout image sets were provided by CDI. CDI primary scans were imaged with variable image slice thicknesses of 1-8 mm in bone and soft tissue protocols. The majority of scans were obtained at 120 kV/260 MA. At WHOI OIC, 10 reformatted sets were produced, comprising soft tissue and bony windows of the head and body with expanded views of the brain and ear in transaxial, sagittal and coronal planes to obtain detail from each ear region. Three-dimensional reconstructions were also produced of some head structures.

History

No details on the history of this animal were available at the time scans were reviewed.

General Observations

Cranial, thoracic and abdominal images were provided.

Cranial Soft Tissues

All tissues are in moderate to poor condition with the notation that some blubber areas show evidence of very poor condition with separation of tissue layers and extensive air inclusions that are particularly evident at the blubber and muscular interface. This suggests dissection by gaseous decomposition of the tissues

The nares and oral cavity are filled with high density material that is likely to be sand or sediment. The throat region has intramuscular inclusions that are less dense which may be either partially calcified parasitic cysts or lower density sediments that migrated into the subcutaneous areas post mortem.

Both sinus areas are partially opacified with the right being more compromised than the left and containing some relatively high density material.

Intracranial/Brain

All skull features are normal.

The brain is intact with moderate preservation. The soft tissue images show distinctive arborification of the sublayers within the cerebral hemispheres. The insulae are not well defined but they are detectable as are most of the grey and white matter interfaces.

The ventricles are reduced or collapsed but are consistent with normal post-mortem appearance in this species. The cerebellum and mid-brain are intact with normal appearance. There is a complexly shaped, mid to low density structure in the subtemporal region (IP -216 to -220) with HU values ranging -17 to 44. These readings are consistent with pooled extravasated blood but are somewhat lower than an organized clot.

Eyes

The left globe is enucleated and the ocular cavity is filled with fluid and clotting. The right eye is present but has intra-globular air.

Ears

Peribullar region

The peribullar areas are clear and well aerated bilaterally with well-defined suspensory ligaments. Scan IP -226.949 shows a diffuse mid-density region with HU values of 54-84, consistent with a minor clot or contused muscle and fats.

Internal Auditory Canal (IAC)/Acousto-Vestibular/Facial Nerve

There is no indication of blood or other abnormal material within either IAC. VIIIth and VIIth nerves are intact bilaterally but poorly defined in some sections suggesting there is tissue degeneration.

Middle Ear

The middle ear cavities are normal with distinct middle ear air spaces bilaterally and a well-defined corpus cavernosum. All ossicles are intact and normally configured bilaterally. The round window is normal bilaterally.

Inner Ear

The canals are symmetrical and normal in appearance. The internal auditory canals are well defined. There are minor mid attenuation deposits in the inner ears bilaterally that suggest intracochlear blood in part of the canals (IP -254.449 and -216.949), however, only 1.2 mm scans are available and submillimeter images are required to confirm this observation.

Post-cranial Features

Fatty tissues throughout the body are particularly poorly preserved. The blubber at the thoracic level particularly shows extensive fissuring suggestive of post-mortem autolytic breakdown of the tissues. These effects are more profound and extensive on the left than right sides.

Thoracic scans show both lungs are partially consolidated with the right lung considerably more extensively affected than the left and with the apices and middle lobes bilaterally having the greatest areas of apparent congestion. Both lungs also have multiple high density nodules or calcified cysts.

The abdominal scans show extensive air throughout the intestine. The colon is normal in appearance and contains compacted feces.

Summary

The scans suggest the animal is an adult in a moderate to poor state of preservation. Abnormal lung scans are not definitive for premortem disease; histologic evaluation may be useful. Abdominal scans show a patent but largely unoccupied GI-tract although some waste products are evident in the most posterior segments..

Cranial scans suggest moderate post-mortem degenerative changes. The brain and intracranial spaces are normal with one relatively defined area of possible extravasated blood in the basioccipital and subtemporal areas. The ears are normal bilaterally with some intracochlear regions of increased density that may represent intracochlear blood. The peribullar and middle ear spaces are normal. The cranial sinus are abnormal with distention of the mucosa and some foreign material.

Cause of Death

Indeterminate: Cause of death cannot be determined from the scan-based information available to date.

Additional Comments

No additional comments or recommendations.

Subject ID

re: P-pho79-03NWR05008

Species *Phocoena phocoena*

Imaging Analysis Requested by: B. Norberg, NOAA Fisheries

Scan date: 20-23 July 2003 with reformats obtained August-November 2003

WHOI Scan technician(s): J. Arruda

Scan Analyses: D.R. Ketten

Report Dictation Date: 17 September, 2003

Scan Parameters

Primary scans were obtained by Center for Diagnostic Imaging and formatted as a series of transaxial head images in both soft and bone windows using a spiral scan protocol. All primary scans were obtained in with the body placed prone, rostrum first.

Four primary and two scout image sets were provided by CDI. CDI primary scans were imaged with variable image slice thicknesses of 1-8 mm in bone and soft tissue protocols. The majority of scans were obtained at 120 kV/260 MA. At WHOI OIC, 10 reformatted sets were produced, comprising soft tissue and bony windows of the head with expanded views of the brain and ear in transaxial, sagittal and coronal planes to obtain detail from each ear region. Three-dimensional reconstructions were also produced of some head structures.

History

No details on the history of this animal were available at the time scans were reviewed.

General Observations

Cranial images only were provided. The head was decapitated at the level of the occipital bone and is partially flensed in the posterior areas. There are multiple and diffuse areas of mid-range readings suggesting pockets of degenerated tissues, and air pockets are common at the fat and muscle interfaces. Large deposits of high density material are evident in the airways and esophagus.

Cranial Soft Tissues

All soft tissues of the head are present with the exception of the most posterior sections. There is some increased mass effect anterior to the frontals consistent with high density, mixed material filling the nares and particularly the left sacs (HU ~1300). There is a granular appearance to virtually all tissues as well as multiple areas of poor preservation. The melon is unremarkable.

The nares and oral cavity are filled with high density material that is likely to be sand or sediment.

Intracranial/Brain

All skull features are normal.

The brain is intact but is otherwise unremarkable. The relatively uniform appearance suggest that it is poorly preserved.

Eyes

The left eye is intact but has an air pocket within the globe located in the superior posterior quadrant. The right eye is present with the lens displaced ventrally.

Ears

Peribullar region

The peribullar areas are generally clear and well aerated bilaterally with well-defined suspensory ligaments. There is a substantial, well-defined mass of tissue medial to the left tympano-periotic bone (IP-262.5) and a similar but smaller mass on the right (IP -227.5). HU values (ranges of -4.67 to -10) are most consistent with bundled parasites

Internal Auditory Canal (IAC)/Acousto-Vestibular/Facial Nerve

The IAC. VIIIth and VIIth nerves, and retrobullar areas are normal and unremarkable bilaterally. (See IP -229 to -235).

Middle Ear

The middle ear cavities are normal bilaterally with clearly delineated middle ear air spaces and a well-defined corpus cavernosum. All ossicles are intact and normally configured bilaterally. The round and oval windows are normal bilaterally.

Inner Ear

The canals are symmetrical and normal in appearance. The intracochlear attenuations are consistent with normal cochlear fluids.

Post-cranial Features

No postcranial scans were provided.

Summary

The scans suggest the animal is an adult in a poor state of preservation. Foreign material is evident on the surface and within the airways and esophagus. The brain, melon, skull, and ears are basically normal for an animal in this state of preservation.

Cause of Death

Indeterminate: Cause of death cannot be determined from the scan-based information available to date.

Additional Comments

No additional comments or recommendations.

Subject ID

re: P-pho79-03NWR05011

Species *Phocoena phocoena*

Imaging Analysis Requested by: B. Norberg, NOAA Fisheries

Scan date: 20-23 July 2003 with reformats obtained August-November 2003

WHOI Scan technician(s): J. Arruda

Scan Analyses: D.R. Ketten

Report Dictation Date: 17 September, 2003

Scan Parameters

Primary scans were obtained by Center for Diagnostic Imaging and formatted as a series of transaxial head and body images in both soft and bone windows using a spiral scan protocol. All primary scans were obtained in with the body placed prone, rostrum first.

Eleven primary and two scout image sets were provided by CDI. CDI primary scans were imaged with variable image slice thicknesses of 1-8 mm in bone and soft tissue protocols. The majority of scans were obtained at 120 kV/260 MA. At WHOI OIC, 10 reformatted sets were produced, comprising soft tissue and bony windows of the head with expanded views of the brain and ear in transaxial, sagittal and coronal planes to obtain detail from each ear region. Three-dimensional reconstructions were also produced of some head structures.

History

No details on the history of this animal were available at the time scans were reviewed.

General Observations

The animal is in generally poor condition but most remarkably has extensive trauma evident, particularly on the surface and within the head.

Cranial Soft Tissues

All soft tissues of the head are present. There are multiple areas of abrasion with the most compromised areas rostral. Large patches of the epidermis are clearly missing. Sand or similar material (HU>800) is present throughout much of the head and is particularly copious in the left superior nasal sac. There are extensive areas of contusion consistent with the cranial traumas described below.

Intracranial/Brain

The entire skull is severely compromised by multiple fractures, including longitudinal and comminuted fractures of the skull base, right occipital, left temporal, left parietal, left squamosal, frontal and left mandibular bones, with multiple skull elements displaced. (see IP -199.9 to -184.0 plus attached 3D reconstruction.)

The left mandible has 2 longitudinal fractures, 3 parallel fractures and one laterally displaced chip (see IP -197.4 to -179.9)

The brain is essentially homogenous and likely to be severely compromised as a result of the traumas evident in the fractures noted above..

Eyes

Both eyes are present but deflated.

Ears**Right ear**

The right peribullar areas are generally clear and well aerated with well-defined suspensory ligaments. All middle ear structures appear essentially normal. The inner ear contains blood in the apical and middle turns.

Left ear

The left inner ear contains blood in the apical and middle turns. The peribullar space. Contains two notable tissue masses: one is an organized clot; the other is a mass medial to the left tympano-periotic bone with a similar mass within the middle ear cavity. There are multiple, small, dense spheroids within these soft tissue masses that are likely to be calcified parasitic bodies. (IP -109.7 to -188.2). There is also a tympanic bone fracture evident on the left lateral wall (IP -213.2)

Post-cranial Features

There is extensive air throughout the gastro-intestinal system. Scans at IP -815.6 to -845.6 show ventral left contusions and possible hemorrhagic areas. The internal organs are partially autolyzed with distinctive granulated appearance notable in the liver that is consistent with cyclic freeze-thaw artifacts.

The lungs are consolidated with patent airways. An ice block is evident in the rt bronchus (IP 1125.6) and trachea (1155.6). The right lung shows slightly more extensive consolidation than the left. There are several dense foci within the trachea that are likely to be sand or parasitic inclusions.

Summary

The scans suggest the animal is an adult in a moderate to poor state of preservation. The most significant findings are the extensive fractures compromising the brain case and jaws of this animal. The intracochlear blood and left ear clots are consistent with the fractures and with broad, direct, high impact blunt trauma with most extensive damage to the left jaw and left cranium. The fracture pattern suggests an oblique, slightly dorsal impact. However, determination of direction and point of impact can be better determined by examination and comparison of the fracture field with soft tissue damage patterns of the entire head.

Cause of Death

Indeterminate: Cause of death cannot be determined from the scan-based information available to date, however, if correlative evidence is found on dissection that indicates the fractures were pre or peri-mortem they are consistent with a blunt trauma incident that was sufficient to kill the animal virtually immediately.

Additional Comments

No additional comments or recommendations.

Subject ID

re: P-pho79-03NWR05012

Species *Phocoena phocoena*

Imaging Analysis Requested by: B. Norberg, NOAA Fisheries

Scan date: 20-23 July 2003 with reformats obtained August-November 2003

WHOI Scan technician(s): J. Arruda

Scan Analyses: D.R. Ketten

Report Dictation Date: 19 September, 2003

Scan Parameters

Primary scans were obtained by Center for Diagnostic Imaging and formatted as a series of transaxial head and body images in both soft and bone windows using a spiral scan protocol. All primary scans were obtained in with the body placed prone, rostrum first.

Five primary and two scout image sets were provided by CDI. CDI primary scans were imaged with variable image slice thicknesses of 1-8 mm in bone and soft tissue protocols. The majority of scans were obtained at 120 kV/260 MA. At WHOI OIC, 10 reformatted sets were produced, comprising soft tissue and bony windows of the head with expanded views of the brain and ear in transaxial, sagittal and coronal planes to obtain detail from each ear region. Three-dimensional reconstructions were also produced of some head structures.

History

No details on the history of this animal were available at the time scans were reviewed.

General Observations

The animal is in moderate to poor condition. Based on its size, relatively low skull mineralization and incompletely ossified cranial sutures, it is a young juvenile..

Cranial Soft Tissues

The head is intact with generally normal soft tissue configurations. The majority of the airways and associated spaces are compromised by fluid and foam deposits. The left sinus is opacified and contains both fluid and foam. The cranial musculature appears normal. The blubber layer is well defined but thin.

Intracranial/Brain

The cranium has a relatively low density and the sutures are poorly ossified, consistent with an immature animal. All neural apertures are larger than normal in an adult. The most remarkable feature is a complex mass bilaterally juxtaposed to the subtemporal entry points of the VIIth and VIIIth nerves (IP -213.759). The masses are irregularly shaped with involuted and elevated margins, and the HU values range from 0-40. In combination with the complex shape, these values are most consistent with a mixture of fats and blood and represent either multiple clots or degenerated parasitic bundles. Considering the proximity of the ears and the presence of parasites in the ear regions adjacent to these spaces, the latter is the most likely case.

Eyes

The right eye is normal. The left eye is collapsed with an associated, well-organized orbital clot .

Ears**Right ear**

The right peribullar areas are generally normal with some moderate density masses in the medial peribullar region and middle ear. The peribullar spaces are otherwise well aerated with well-defined suspensory ligaments. All middle ear structures are intact and normal although there are large soft tissue masses suggestive of nematode infestations common to this species. The inner ear is normal with no evidence of blood or other intracochlear abnormalities.

Left ear

The left peribullar areas, like the right, are generally normal with moderate density masses in the medial peribullar region and middle ear. The middle ear structures are intact and normal. The soft tissue masses are more extensive in the left ear. The inner ear is normal with no evidence of blood or other intracochlear abnormalities.

Post-cranial Features

There is extensive air throughout the gastro-intestinal system. The intestinal loops are well defined on even the lateral scout images, suggesting well preserved intestinal structure. Both lungs are consolidated with the right lung more extensively compromised at all levels compared to the left. The trachea contains mid to low attenuation soft tissue deposit (HU-45.6) with an inconsistent appearance suggesting that it is mixture of foamy, sero-sanguinous material. This material extends from the larynx to the mid trachea.

Summary

The scans suggest the animal is a juvenile in a moderate to poor state of preservation. The most significant findings are intra-tracheal fluid, lung consolidation, and extensive peribullar parasitic masses that extend intracranially. Extravasated pooled blood is associated with the parasitic masses. Intracranial invasion was likely possible because of the exceptionally large aperture for the VIIth and VIIIth nerves and the relatively low density of the cranium. The cranial sutures are also incomplete, which is, again suggestive of a young and possibly poorly nourished animal. All other structures are essentially normal.

Cause of Death

Indeterminate: Cause of death cannot be determined from the scan-based information available. .

Additional Comments

No additional comments or recommendations.

Subject ID

re: P-pho79-03NWR06005

Species *Phocoena phocoena*

Imaging Analysis Requested by: B. Norberg, NOAA Fisheries

Scan date: 20-23 July 2003 with reformats obtained August-November 2003

WHOI Scan technician(s): J. Arruda

Scan Analyses: D.R. Ketten

Report Dictation Date: 19 September, 2003

Scan Parameters

Primary scans were obtained by Center for Diagnostic Imaging and formatted as a series of transaxial head and body images in both soft and bone windows using a spiral scan protocol. All primary scans were obtained in with the body placed prone, rostrum first. Eleven primary and five scout image sets were provided by CDI. CDI primary scans were imaged with variable image slice thicknesses of 1-8 mm in bone and soft tissue protocols. The majority of scans were obtained at 120 kV/260 MA. At WHOI OIC, 10 reformatted sets were produced, comprising soft tissue and bony windows of the head with expanded views of the brain and ear in transaxial, sagittal and coronal planes to obtain detail from each ear region. Three-dimensional reconstructions were also produced of some head structures.

History

No details on the history of this animal were available at the time scans were reviewed.

General Observations

The animal is in moderate to poor condition. It is a rather typical adult animal with one notable feature: there are extensive, filiform, calcified parasites throughout the entire body. .

Cranial Soft Tissues

The head is intact with generally normal soft tissue configurations. On the left side there is a convoluted, calcified nematode track that extends nearly 120 mm (see accompanying 3D image) There are also numerous fibrotic or heavily calcified nodules found in virtually every major tissue suite in the head, including the ventral, sublingual musculature, the right sphenoid sinus, and the musculature proximal to the melon and maxillary bones. There are substantial cystic deposits in the peri-esophageal tissues as well. This is an exceptional parasitic burden, even for this species of odontocete, in which parasites are fairly common. .

Intracranial/Brain

The cranial structures are unremarkable. The brain is intact with moderately defined structure. There is no evidence of hemorrhage or pooled fluids.

Eyes

Both eyes are intact with evidence of periocular clots.

Ears

As with the other head structures, there is evidence of extensive parasitic infiltration of the peribullar and middle ear tissues bilaterally. Both ears have extensive masses in the retrobullar spaces and, somewhat unusually, there are substantial calcified inclusions associated with these masses (see IP -20791; soft tissue HU 17.99; calcified spheroid HU 170-200). The medial wall of the left ear retrobullar space has a distended epithelium that may be evidence of active inflammation. The inner ear anatomies are normal bilaterally.

Post-cranial Features

There are some minor freeze fractures evident in the flippers and flukes and superficial abrasions. .Most organs are intact and generally normal in appearance with the notation that as in the head structures, the most remarkable features post cranially are extensive calcified parasitic tracks affecting most tissues. There are long, convoluted, calcified threads, several mm. in diameter distributed throughout the blubber and musculature of the abdomen. One notable bundle parallels the ventral surface of the penis and plunges into the blubber –muscle interface.

The kidneys are well-defined but have fibrotic masses near the midline. (IP -663.140). Intestines are inflated but intact. There is a relatively dense signal from diffuse material in the stomach.

The lungs have extensive clouding bilaterally that parallels the bronchial tree, but there is not uniform consolidation, suggesting better postmortem lung preservation than in most of the animals examined. The clouding is more apparent and extensive in the left lung (IP-448.14). The right lung (IP -408.14) has an accumulation of foamy exudate and some pooled fluid that extends into the larynx. The right lung also shows evidence of mass lesions in the right lingual and right middle lobe dorsal to the right bronchus. Both the right and left lung have spotty opacified regions throughout. The heart has a moderate density mass associated with the right ventricle.

There

Summary

The scans suggest the animal is an adult in a moderate state of preservation. The most significant findings are extensive calcified parasites present throughout the body. Most major organs appear compromised or are likely to be secondarily stressed by the exceptional parasitic burden of this animal. Further, based on the extent of calcified inclusions, this is a long-standing pathology. There are multiple, extensive, calcified parasitic strands that are primarily found at the blubber and muscle interfaces. The ears are similarly infested with soft and calcified inclusions. The kidneys, gall bladder and heart have minor mass effects but

these may be within normal limits of this species. With the exception of those notations, the principal organs are otherwise essentially normal in appearance on these scans.

Cause of Death

Indeterminate: Cause of death cannot be determined from the scan-based information available. .

Additional Comments

No additional comments or recommendations.

Respectfully submitted,



Darlene R. Ketten, Ph.D.
Asst. Professor
Harvard Medical School
Department of Otology and Laryngology
Research Director
Massachusetts Eye and Ear Infirmary
Head and Neck Imaging Service
Office 617-573-4083

Senior Scientist
Biology Department
Woods Hole Oceanographic Institution
office: 508-289-2731
fax: 508-457-2028
email: dketten@whoi.edu

Appendix E. Phocoenid strandings in British Columbia, Canada (April – May 2003).

Date of Initial Observation	Location	Case Number	Species	Gender	Comments
4/22/2003	Clover Point	2767	Harbor porpoise	M	head and limbs amputated; NSF
4/29/2003	Willow Beach	2768	Dall's porpoise	M	cryptococcosis
5/1/03	Esquimalt, Vancouver Island, BC	2769	Harbor porpoise	M	fetus, marked meconium aspiration
5/2/03	Seabird Point, Discovery Island, BC	03NWR05032	Harbor porpoise	U	not collected
5/21/03	Bamfield, Vancouver Island, BC	2770	Dall's porpoise	F	cryptococcosis

Appendix F. List of harbor porpoise (*Phocoena phocoena*) stranding events in Washington State 1992-2002.

Initial Date	City	State	Field ID Number	Number of Animals	Sex	Length (cm)	Examiner
5/14/1992	La Push	WA	RCF282	1	M	89	National Marine Mammal Lab (NMML)
5/26/1992	Neah Bay	WA	RCF 284	2	M	133	NMML
7/5/1992	Long Beach	WA	HP92-07-05	1	M	75*	Marine Animal Resource Center (MARC)
8/22/1992	La Conner	WA	HP92-08-22	1	M	136	MARC
10/4/1992	Long Beach peninsula	WA	RLH 005	1	M	155	NMML
10/4/1992	Long Beach peninsula	WA	RLH 013	1	M	147	NMML
10/4/1992	Long Beach peninsula	WA	KMM 043	1	M	144	NMML
10/4/1992	Long Beach peninsula	WA	KMM 049	1	M	152	NMML
10/9/1992	Long Beach peninsula	WA	JCC 002	1	M	144	NMML
10/23/1992	Squaxin Island	WA	JCC-004	1	M		Public
1/30/1993	Belfair	WA	HP93-01-30	1	M	181	MARC
2/14/1993	Moclips	WA	MARC93-022	1	U	120*	MARC
4/5/1993	San Juan Island	WA	PJG-126	1	M	153	NMML
5/2/1993	Lopez Island	WA		1	M	130*	Whale Museum
5/21/1993	Port Angeles	WA	SDO-93-010	1	M	133	NMML

* - estimated length

Appendix F. List of harbor porpoise (*Phocoena phocoena*) stranding events in Washington State 1992-2002.

Initial Date	City	State	Field ID Number	Number of Animals	Sex	Length (cm)	Examiner
6/17/1993	Ocean Shores	WA		1	U	120*	Public
8/21/1993	Brown Island	WA	PJG-130	1	U	105*	NMML
9/22/1993	Tacoma	WA	MARC93-279	1	F	94*	MARC
5/2/1994	San Juan Island	WA		1	M	125	Whale Museum
7/25/1994	San Juan Island	WA	SJ078-94	1	F	80	Whale Museum
8/1/1994	San Juan Island	WA	SJ099-94	1	U		Whale Museum
8/3/1994	Lopez Island	WA	SJ100-94	1	F		Whale Museum
4/17/1995	Orcas Island	WA	SJ-002-95	1	M	135	Whale Museum
4/19/1995	Lopez Island	WA	SJ003-95	2	F	178	Whale Museum
8/20/1995	Orcas Island	WA	SJ045-95	1	F	75	Whale Museum
10/24/1995	San Juan Island	WA	SJ066-95	1	F	107.5	Whale Museum
10/29/1995	San Juan Island	WA	SJ067-95	1	U	92.5	Whale Museum
5/11/1997	San Juan Island	WA	SJ017-97	1	U	135*	Whale Museum
9/14/1997	San Juan Island	WA	SJ096-97	1	U	135*	Public
4/8/1998	Anacortes	WA		1	M	127	NMML
4/30/1998	Shaw Is.	WA		1	U	0	Public
7/17/1998	Waldron Island	WA		1	U	50*	U.S. Coast Guard
8/8/1998	San Juan Island	WA	1998-SJ015	1	F	90*	Whale Museum
11/22/1998	San Juan Island	WA		1	F	177.5*	Whale Museum
3/11/1999	Pt. Roberts	WA	MBHPp99001	1	M	44*	Public
5/21/1999	Friday Harbor	WA	1999-SJ005	1	M	152	Whale Museum

* - estimated length

Appendix F. List of harbor porpoise (*Phocoena phocoena*) stranding events in Washington State 1992-2002.

Initial Date	City	State	Field ID Number	Number of Animals	Sex	Length (cm)	Examiner
1/29/2000	San Juan Island	WA	2000SJO01	1	F	140*	Whale Museum
3/17/2000	Ocean Shores	WA	MMP00-10	1	F	176	Washington Department of Fish and Wildlife
3/29/2000	Lopez Island	WA	2000-SJ017	1	U	107.5	Whale Museum
4/14/2000	San Juan Island	WA	2000SJ007	1	U		Public
8/12/2000	Rialto Beach	WA	MBHPp20001	1	M	116	Park Ranger
8/29/2000	Bellingham	WA		1	F	143	NMFS Enforcement
1/7/2001	Port Angeles	WA	Dng-01-002	1	M	155	National Marine Fisheries Service (NMFS)
4/27/2001	Strait of Juan de Fuca	WA	001-01	1	F	132.5	M. Klope
5/2/2001	Lopez Island	WA	2001-SJ002	1	F	142.5	Whale Museum
5/2/2001	Port Townsend	WA		1	U	120*	NMML
5/3/2001	San Juan Island	WA	2001-SJ003	1	F	130	Whale Museum
5/10/2001	San Juan Island	WA	2001-SJ004	1	F	135*	Whale Museum
5/13/2001	Sequim	WA	Dng-01-004	1	F	1010	NMML
5/17/2001	Port Angeles	WA		1	M	135	NMML
5/26/2001	San Juan Island	WA	2001-SJ005	1	U		Whale Museum
7/9/2001	Mountain View	WA		1	U	135*	NMFS Enforcement
7/12/2001	Ocean Shores	WA	CRC - 478	1	M	85	Cascadia Research
7/31/2001	San Juan Island	WA	2001-SJ041	1	F	155	Whale Museum

* - estimated length

Appendix F. List of harbor porpoise (*Phocoena phocoena*) stranding events in Washington State 1992-2002.

Initial Date	City	State	Field ID Number	Number of Animals	Sex	Length (cm)	Examiner
8/16/2001	Port Townsend	WA		1	U	75*	Olympic Coast National Marine Sanctuary (OCNMS)
12/25/2001	Orcas Island	WA	2001-SI059	1	M	117.5	Whale Museum
12/27/2001	Shaw Island	WA	2001-SI060	1	M	132	Whale Museum
1/15/2002	Whidbey Island	WA	001-02	1	U		M. Klope
3/12/2002	Port Angeles	WA		1	M	130	OCNMS
4/27/2002	Samish Island	WA		1	M	128	NMML
5/15/2002	San Juan Island	WA	2002-SI004	1	F	165	Whale Museum
5/30/2002	Lopez Island	WA	2002-SI033	1	M	146	Whale Museum
6/15/2002	Lopez Island	WA	2002-SI006	1	M	162.5	Whale Museum
6/16/2002	Crescent Bay	WA		1	M	132.5	Public
8/6/2002	Shaw Island	WA	2002-SI025	1	U	97.5*	Whale Museum
8/25/2002	Point Roberts	WA	01/03278	1	F	172	S. Raverty

* - estimated length

Appendix G. Marine mammal stranding events reported in Washington State (April – June 2003).

Initial Date	Species	Number Animals	City	State	Field ID Number	Registration Number	Sex	Length (cm)	Examiner
4/2/2003	HARBOR SEAL	1	Belfair	WA	03-MA-009	03NWR04001	U	N/E	Public
4/8/2003	HARBOR SEAL	1	Bainbridge Island	WA	03-KP-010	03NWR04002	U	122	Public
4/11/2003	HARBOR SEAL	1	Vashon Island	WA	03-KG-012	03NWR04004	U	152	Public
4/14/2003	HARBOR SEAL	1	Kingston	WA	03-KP-011	03NWR04003	U	91	Public
4/14/2003	HARBOR SEAL	1	San Juan Island	WA	2003-SJ004	03NWR04007	U	N/E	Whale Museum
4/16/2003	UNSPECIFIED SEA LION	1	Ocean Park	WA	03-PA-014	03NWR04008	M	198	Public
4/16/2003	HARBOR SEAL	1	San Juan Island	WA	2003-SJ097	03NWR04020	F	168	Whale Museum
4/19/2003	HARBOR PORPOISE	1	South Sand Point	WA	03-CM-015	03NWR04009	U	N/E	National Park Service
4/21/2003	UNSPECIFIED SEA LION	1	County Line Park	WA	03-WA-013	03NWR04006	U	N/E	Public
4/23/2003	CALIFORNIA SEA LION	1	Sucia Island	WA	2003-SJ005	03NWR04010	M	N/E	Whale Museum
4/26/2003	HARBOR SEAL	2	Ocean Shores	WA	03-GH-016	03NWR04011	F	122	Public
5/2/2003	HARBOR PORPOISE	1	Shaw Island	WA	2003-SJ006	03NWR05001	F	136	Whale Museum
5/3/2003	CALIFORNIA SEA LION	1	Whidbey Island	WA	WIC050503SD	03NWR05002	M	236	WSU/Island County Beachwatchers
5/4/2003	HARBOR PORPOISE	1	Sequim	WA	DNG-03-002	03NWR05003	F	200	USFWS
5/4/2003	HARBOR PORPOISE	1	Sequim	WA	DNG-03-003	03NWR05004	U	84	USFWS
5/4/2003	HARBOR PORPOISE	1	San Juan Island	WA	2003-SJ007	03NWR05005	F	126	Whale Museum
5/5/2003	HARBOR PORPOISE	1	San Juan Island	WA	2003-SJ008	03NWR05006	F	152	Whale Museum
5/6/2003	HARBOR PORPOISE	1	Sequim	WA	DNG-03-001	03NWR05007	F	146	USFWS
5/9/2003	HARBOR PORPOISE	1	Port Angeles	WA	OCNMS03Pp01	03NWR05008	M	146	Olympic Coast National Marine Sanctuary
5/11/2003	UNSPECIFIED SEA LION	1	Point No Point	WA	03-KP-017	03NWR05009	U	N/E	Public
5/12/2003	HARBOR PORPOISE	1	Ocean City	WA	03-GH-159	03NWR05034	U	N/E	Cascadia Research Collective
5/12/2003	HARBOR PORPOISE	1	Whidbey Island	WA	03-IS-160	03NWR05033	U	N/E	WSU/Island County Beachwatchers
5/13/2003	HARBOR PORPOISE	1	Whidbey Island	WA	WIC051303SD	03NWR05010	M	160	WSU/Island County Beachwatchers
5/14/2003	DALL'S PORPOISE	1	Fidalgo Island	WA	03-SK-161	03NWR05035	U	N/E	Public/Whale Museum

Appendix G. Marine mammal stranding events reported in Washington State (April – June 2003).

5/16/2003	HARBOR PORPOISE	1	Port Angeles	WA	OCNMS03Pp02	03NWR05011	F	141	Olympic Coast National Marine Sanctuary
5/17/2003	HARBOR PORPOISE	1	Whidbey Island	WA	WIE051703SB	03NWR05019	F	137	WSU/Island County Beachwatchers
5/18/2003	CALIFORNIA SEA LION	1	Yellow Island	WA	2003-SJ016	03NWR05043	U	N/E	Whale Museum
5/20/2003	UNSPECIFIED SEA LION	1	Waldron Island	WA	2003-SJ017	03NWR05044	U	N/E	Whale Museum
5/20/2003	HARBOR SEAL	1	Lopez Island	WA	2003-SJ099	03NWR05045	U	N/E	Whale Museum
5/20/2003	HARBOR PORPOISE	1	San Juan Island	WA	2003-SJ009	03NWR05012	M	123	Whale Museum
5/22/2003	HARBOR SEAL	1	Ruby Beach	WA	03-JE-018	03NWR05013	U	N/E	National Park Service
5/25/2003	HARBOR PORPOISE	1	Lopez Island	WA	2003-SJ020	03NWR05046	U	N/E	Whale Museum
5/27/2003	HARBOR SEAL	1	Orcas Island	WA	2003-SJ012	03NWR05042	F	N/E	Whale Museum
5/27/2003	CALIFORNIA SEA LION	1	Whidbey Island	WA	03-IS-019	03NWR03014	U	N/E	Public
5/31/2003	HARBOR SEAL	1	Birch Bay	WA	03-WH-022	03NWR05017	U	112	Public
5/31/2003	NORTHERN ELEPHANT SEAL	1	Forks/Kalaloch	WA	03-JE-021	03NWR05016	U	320	National Park Service
5/31/2003	HARBOR SEAL	1	San Juan Island	WA	2003-SJ018	03NWR05047	M	174	Whale Museum
6/2/2003	HARBOR PORPOISE	1	Long Beach	WA	CRC-490	03NWR06005	M	141	Cascadia Research Collective
6/3/2003	HARBOR SEAL	1	Lopez Island	WA	2003-SJ019	03NWR06031	U	N/E	Whale Museum
6/12/2003	HARBOR SEAL	1	Blaine	WA	03-WH-064	03NWR06014	M	84	Public
6/13/2003	HARBOR SEAL	1	Moclips	WA	03-GH-024	03NWR06002	U	61	Public
6/16/2003	HARBOR SEAL	1	Copalis	WA	03-GH-025	03NWR06003	U	N/E	Public
6/16/2003	UNSPECIFIED TOOTHED WHALE	1	Ocean Shores	WA	03-GH-027	03NWR06004	U	152	Public
6/17/2003	CALIFORNIA SEA LION	1	San Juan Island	WA	2003-SJ021	03NWR06032	M	225	Whale Museum
6/17/2003	HARBOR SEAL	1	Lummi Island	WA	03-WH-072	03NWR06019	M	74	Public
6/21/2003	UNSPECIFIED PORPOISE	1	San Juan Island	WA	2003-SJ022	03NWR06033	U	N/E	Whale Museum
6/21/2003	ODONTOCETE	1	Ocean Shores	WA	03-GH-027	03NWR06004	U	150	Public
6/24/2003	HARBOR SEAL	1	San Juan Island	WA	2003-SJ023	03NWR06034	U	120	Whale Museum
6/24/2003	GRAY WHALE	1	Mt. Vernon	WA	CRC-496	03NWR06029	U	520	Cascadia Research
6/29/2003	HARBOR SEAL	1	Patos Island	WA	2003-SJ024	03NWR06030	M	78	Whale Museum
6/29/2003	UNSPECIFIED SEA LION	1	Lopez Island	WA	2003-SJ025	03NWR06035	U	N/E	Whale Museum
6/30/2003	HARBOR SEAL	1	Lopez Island	WA	2003-SJ026	03NWR06037	U	N/E	Whale Museum