

Preclinical vCJD after blood transfusion in a PRNP codon 129 heterozygous patient

Alexander H Peden, Mark W Head, Diane L Ritchie, Jeanne E Bell, James W Ironside



Lancet 2004; 264: 527-29

See [Comment](#) page 477

We report a case of preclinical variant Creutzfeldt-Jakob disease (vCJD) in a patient who died from a non-neurological disorder 5 years after receiving a blood transfusion from a donor who subsequently developed vCJD. Protease-resistant prion protein (PrP^{res}) was detected by western blot, paraffin-embedded tissue blot, and immunohistochemistry in the spleen, but not in the brain. Immunohistochemistry for prion protein was also positive in a cervical lymph node. The patient was a heterozygote at codon 129 of *PRNP*, suggesting that susceptibility to vCJD infection is not confined to the methionine homozygous *PRNP* genotype. These findings have major implications for future estimates and surveillance of vCJD in the UK.

National Creutzfeldt-Jakob Disease Surveillance Unit, Division of Pathology, School of Molecular and Clinical Medicine, University of Edinburgh, Western General Hospital, Edinburgh EH4 2XU, UK (A H Peden PhD, M W Head PhD, D L Ritchie BSc, Prof J E Bell FRCPath, Prof J W Ironside FRCPath)

Correspondence to: Prof James W Ironside james.ironside@ed.ac.uk

In 2003, an elderly patient in the UK was diagnosed with variant Creutzfeldt-Jakob disease (vCJD) that seemed to have been transmitted by a transfusion of non-leucodepleted red cells from a patient who developed vCJD after the donation.¹ The same investigation also reported 17 individuals alive in December, 2003, who had received labile blood components from donors who subsequently developed vCJD.¹ We report an autopsy detection of a preclinical case of vCJD infection, which appears to have been transmitted by blood transfusion in one of this cohort.

In 1999, an elderly patient received a unit of non-leucodepleted red blood cells from a donor who developed symptoms of vCJD 18 months after donation. The donor died in 2001 and vCJD was confirmed after autopsy. The recipient died 5 years after receiving the transfusion, with no evidence of a neurological disorder. Medicolegal instruction for autopsy was issued. The immediate cause of death was a ruptured abdominal aortic aneurysm. We are bound by a medicolegal restriction regarding disclosure of the patient's age, sex, and geographical location.

We assessed samples of frozen brain, spinal cord, dorsal root ganglion, lymphoid tissues, and muscle for the presence of protease-resistant prion protein (PrP^{res}) by western blot with phosphotungstic acid precipitation and the monoclonal antibody 3F4.² Immunohistochemistry and paraffin-embedded tissue blotting was done on protease-treated tissue sections from a wide range of tissues, with a panel of four antibodies raised against different epitopes of prion protein (PrP).³ Restriction fragment length polymorphism analysis of DNA extracted from frozen brain material identified the patient as being heterozygous (methionine/valine) at codon 129 of the prion protein gene (*PRNP*). Consent for full sequence analysis of *PRNP* had not been obtained. Western blot analysis showed the presence of PrP^{res} in spleen (figure 1). The mobility and glycoform ratio of the signals in spleen were similar to those seen in spleen from patients with clinical vCJD and in vCJD brain diluted in non-CJD spleen (figure 1), and were distinct from those described in a subset of sporadic CJD cases, usually with a relatively lengthy clinical

illness.² We found that PrP^{res} positivity by this method was a consistent feature of four autopsy specimens of spleen from patients who had vCJD, but was absent from a series of nine spleens from controls without CJD (data not shown).

The brain (1337 g) showed only age-related changes, with no pathological features of vCJD. PrP^{res} was undetectable in the brain and spinal cord by western blotting, paraffin embedded tissue blotting, and immunohistochemistry. Immunoreactivity for PrP was found in a few germinal centres in the spleen, in a pattern consistent with staining of follicular dendritic cells (figure 2, A). The number of positive follicles was far lower than in clinical cases of vCJD, with a less aggregated accumulation of immunoreactivity.³ Immunoreactivity for PrP was also found in a germinal centre within a cervical lymph node, with similar pattern of positivity to that noted in the spleen (figure 2, B). PrP^{res} was not detectable by western

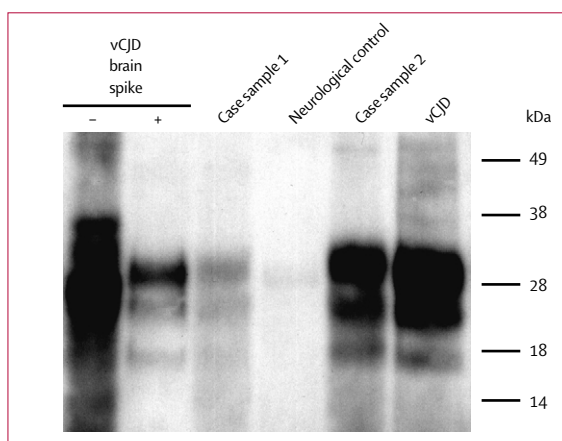


Figure 1: PrP^{res} analysis of spleen by western blot

Two samples of the patient's spleen were compared with spleen samples from a control with non-CJD neurological disease and from a patient with vCJD, and with vCJD brain homogenate (10 µg) diluted in non-CJD spleen, with (+) or without (-) proteinase K digestion. Every lane represents the phosphotungstate precipitate from 50 mg wet weight of spleen. Horizontal lines indicate positions of molecular weight markers. Amounts of PrP^{res} in eight samples of spleen from the patient were undetectable in two samples (not shown), intermediate in five (sample 1), and similar to those found in the spleen of a patient with vCJD at autopsy in one (sample 2).

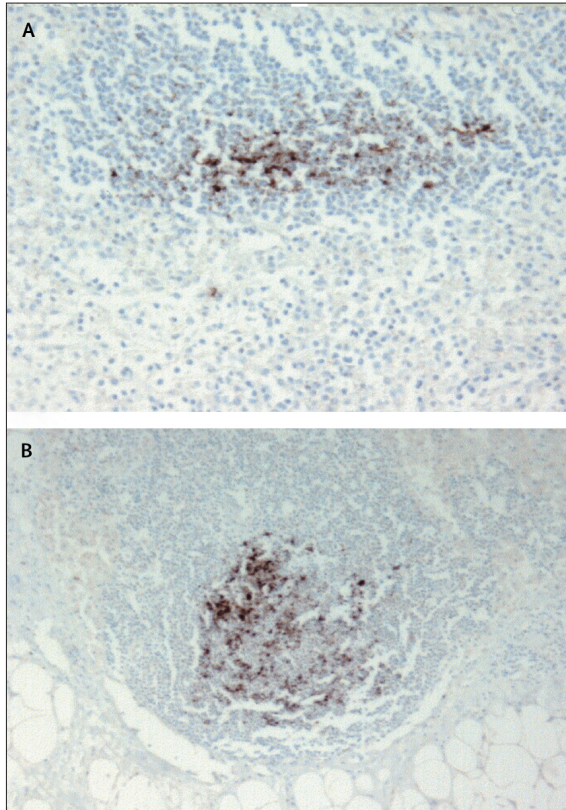


Figure 2: PrP in germinal centres within the spleen and cervical lymph node
Germinal centres are labelled (brown) with the anti-PrP antibodies 3F4 in spleen (A) and 12F10 in a cervical lymph node (B) in a pattern similar to that noted in the follicular dendritic cell network, with less aggregated positivity than in cases of clinical vCJD. Original magnifications (A) $\times 20$ and (B) $\times 10$.

blotting in samples of tonsil, another cervical lymph node, dorsal root ganglion, and muscle; neither was it detected in the lymphoid follicles within the tonsil, appendix, and large intestine by immunohistochemistry.

This is the first recorded case in the UK of autopsy detection of preclinical vCJD infection. We have previously shown preclinical PrP immunoreactivity in germinal centres within appendix tissue from two patients who underwent appendectomy 8 months and 2 years before the onset of vCJD.⁴ The patterns of PrP accumulation within the germinal centres in the spleen and cervical lymph node in the present case were similar to those seen in three surgically removed appendices from a large anonymised retrospective study, suggesting that these findings might also represent preclinical vCJD infection.⁴

Our findings also show that vCJD infection can be confirmed by western blot analysis of PrP^{res} in an individual who is a heterozygote at codon 129 of *PRNP*.^{1,3} This finding has major implications for future estimations of numbers of vCJD cases in the UK, since individuals with this genotype constitute the largest genetic subgroup in the population.⁴ This subgroup

might have a different incubation period after exposure to either primary infection by the bovine spongiform encephalopathy (BSE) agent or secondary infection by blood transfusion. A very lengthy incubation period might explain why no clinical cases of vCJD have yet been observed in this subgroup. Such preclinical cases might also represent a source of iatrogenic infection themselves, either by blood donation or by contamination of surgical instruments coming into contact with lymphoid tissues, even in the absence of infectivity in the brain.

This patient was a UK resident and might therefore have had dietary exposure to the BSE agent. However, the chance of observing vCJD transmission in the absence of a transfusion infection in a second recipient of blood from a donor with vCJD must be far less likely than the 1 in 15 000 to 1 in 30 000 chance for the first reported case.¹ PrP^{res} was not detected in the nine patients without CJD used as negative controls in this study, and in a previous study we and others did not detect PrP accumulation in lymphoid tissues in 56 cases of other forms of human prion disease and in 85 non-CJD cases.⁵ The restriction of PrP^{res} to the spleen and cervical lymph node (but not the tonsil or gut-associated lymphoid tissue) in this case is consistent with an intravenous rather than oral route of exposure. It is also possible that the *PRNP* codon 129 genotype might affect the distribution of PrP^{res} in tissues.

This case highlights the need for continuing surveillance for CJD in the UK, and strongly reinforces the role of the autopsy in the investigation and diagnosis of both clinical and preclinical forms of human prion disease.

Conflict of interest statement

None declared.

Contributors

A H Peden did biochemical analysis and photography, and contributed to drafting of the manuscript. M W Head did biochemical analysis, and contributed to the drafting of the manuscript. D L Ritchie did histological analysis and photography, and contributed to the drafting of the manuscript. J E Bell did the autopsy, provided the autopsy data, and contributed to the drafting of the manuscript. J W Ironside did the histological analysis and coordinated the preparation and drafting of the manuscript.

Acknowledgments

We are grateful to the Transfusion Medicine Epidemiology Review study (C A Llewelyn, P E Hewitt, J MacKenzie, R G Will) for identifying the case in this report and for provision of data. We thank Matthew Bishop and Kelly Connolly for genetic analysis, and Suzanne Lowrie for expert technical assistance. The National Creutzfeldt-Jakob Disease Surveillance Unit is funded by the UK Department of Health and the Scottish Executive. A H Peden is funded by the EC TSELAB Project (ref QLK2-CT-2002-81523). This work is part of the EU NeuroPrion project (FOOD-CT-2004-506579 (NOE) subproject: PRIOGEN). The funding sources had no input into the design of this study, the collection, analysis, and interpretation of data, the writing of the report, or the decision to submit the paper for publication.

References

- 1 Llewelyn CA, Hewitt PE, Knight RS, et al. Possible transmission of variant Creutzfeldt-Jakob disease by blood transfusion. *Lancet* 2004; **363**: 417–21.

- 2 Glatzel M, Abela E, Maissen M, Aguzzi A. Extraneural pathologic prion protein in sporadic Creutzfeldt-Jakob disease. *N Engl J Med* 2003; **349**: 1812–20.
- 3 Head MW, Ritchie D, Smith N, et al. Peripheral tissue involvement in sporadic, iatrogenic, and variant Creutzfeldt-Jakob disease: an immunohistochemical, quantitative, and biochemical study. *Am J Pathol* 2004; **164**: 143–53.
- 4 Hilton DA, Ghani A, Conyers L, et al. Prevalence of lymphoreticular prion protein accumulation in UK tissue samples. *J Pathol* 2004; **203**: 733–39.
- 5 Hilton DA, Sutak J, Smith MEF, et al. Specificity of lymphoreticular accumulation of prion protein for variant Creutzfeldt-Jakob disease. *J Clin Pathol* 2004; **57**: 300–02.

Effectiveness of leucoreduction for removal of infectivity of transmissible spongiform encephalopathies from blood

Luisa Gregori, Nancy McCombie, Douglas Palmer, Paul Birch, Samuel O Sowemimo-Coker, Antonio Giulivi, Robert G Rohwer

In 1999, the UK implemented universal leucoreduction as a precaution against transmission of variant Creutzfeldt-Jakob disease by transfusion of domestic blood or red blood cells. We aimed to assess how effectively leucoreduction reduced infectivity of transmissible spongiform encephalopathies (TSEs) in blood. 450 mL of whole blood collected and pooled from scrapie-infected hamsters was leucoreduced with a commercial filter. Blood cell concentrations were quantified, and infectivity titres measured. Blood cell recovery and white blood cell removal complied with American Association of Blood Banks standards. Leucofiltration removed 42% (SD 12) of the total TSE infectivity in endogenously infected blood. Leucoreduction is necessary for the removal of white-cell-associated TSE infectivity from blood; however, it is not, by itself, sufficient to remove all blood-borne TSE infectivity.

Transmissible spongiform encephalopathies (TSEs) are fatal CNS infections that can incubate asymptotically for a decade or more in human beings before the appearance of clinical disease. People in the asymptomatic phase of variant Creutzfeldt-Jakob disease (vCJD) appear healthy and donate blood with the same frequency as any healthy person. Transmission of vCJD by transfusion was recently recognised in Great Britain.¹ To reduce the risk of transfusion transmission of such diseases in human beings, the UK implemented universal leucoreduction of donated blood in 1999. This measure was based on the expectation that infectivity would be associated with white blood cells.² However, findings in blood from infected mice and hamsters suggested otherwise; at least 40% of the infectivity was plasma-associated, suggesting that leucoreduction would not eliminate infectivity (Rohwer laboratory, unpublished).³ Other investigations showed no loss of infectivity when small amounts of TSE-infected plasma were passed through scaled-down filters.⁴ Similarly, no significant removal of abnormal prion protein was detected when units of human whole blood, spiked with a microsomal fraction from TSE-infected brain, were passed through leucoreduction filters from any of the four major suppliers.⁵ Because of reservations about the relevance of these experiments, none of these findings aroused concern.

We investigated the effectiveness of leucoreduction in removal of TSE infectivity from a human-sized unit of pooled hamster blood. To ensure that the 150 hamsters needed for a 450 mL blood pool were at the same symptomatic stage of disease (wobbling gait and head bobbing) for each of two separate experiments, 400 weanling golden Syrian hamsters (Harlan, Madison,

WI, USA) were inoculated intracranially with 50 μ L of brain homogenate containing about 250 infectious dose₅₀ (ID₅₀) of hamster-adapted scrapie-strain 263K. A low dose of infectivity was used to preclude re-isolation of the inoculum in the blood. This animal protocol was approved by the University of Maryland Institutional Animal Care and Use Committee.

We obtained two pools of blood from the hamsters, one at 106 days and one at 111 days after inoculation. Under carbon dioxide anaesthesia, 3.5 mL of blood was drawn from the right ventricle into 0.5 mL of CP2D anticoagulant. Care was taken not to touch any other tissue. Only perfect bleeds containing 12.5% CP2D with no visible clots were pooled.

Two in-line leucofiltration systems from Pall Corporation (Port Washington, NY, USA) were evaluated. We selected the Leukotrap WB collection set for the infectivity study because filtration and component separation of hamster blood was fully compliant with American Association of Blood Banks (AABB)⁶ specifications, and required only two titrations for interpretation. The Leukotrap RC-PL system



Lancet 2004; **264**: 529–31

Veterans Affairs Maryland Health Care System, VA Medical Center, University of Maryland at Baltimore, 10 North Greene Street, Baltimore, MD 21201, USA (L Gregori PhD, R G Rohwer PhD); Health Canada, Center for Infectious Disease Prevention and Control, Ottawa, ON, Canada (N McCombie RN, A Giulivi MD); Canadian Blood Services, Ottawa, ON, Canada (D Palmer MSc, P Birch MLT); Pall Corporation, Port Washington, NY, USA (S O Sowemimo-Coker PhD)

Correspondence to: Dr Robert G Rohwer rohrwer@umaryland.edu

	Volume (mL)*	White blood cells†		Red blood cells, total (% of total)	Platelets, total (% of total)
		Total (% of total)	Log ₁₀ reduction		
Whole blood	448.5	2.1 × 10 ⁹ (100%)	0	3.7 × 10 ¹² (100%)	1.4 × 10 ¹¹ (100%)
Leucoreduced blood	424.2	3.0 × 10 ⁸ (0.15%)	2.9	3.6 × 10 ¹² (100%)	1.5 × 10 ¹¹ (100%)
Plasma	179	3.0 × 10 ⁵ (0.02%)	3.8	0 (0%)	1.1 × 10 ¹⁰ (8%)
Red blood cells + AS3	305.9	2.0 × 10 ⁸ (0.15%)	3	3.1 × 10 ¹² (86%)	1 × 10 ¹¹ (71%)

*Volume measurements were obtained by weight using experimentally determined densities of whole hamster blood, 1.04 g/mL. †Values are average of at least three separate microscopic determinations using a haemocytometer and by flow cytometric measurements with white cells stained with propidium iodide. AS3 is a preservative and stabiliser.

Table 1: Blood component cell numbers and volumes before and after leucoreduction