

NATURAL DISEASE

Epizootic Vacuolar Myelinopathy of the Central Nervous System of Bald Eagles (*Haliaeetus leucocephalus*) and American Coots (*Fulica americana*)

N. J. THOMAS, C. U. METEYER, AND L. SILEO

US Geological Survey, Biological Resources Division, National Wildlife Health Center, Madison, WI

Abstract. Unprecedented mortality occurred in bald eagles (*Haliaeetus leucocephalus*) at DeGray Lake, Arkansas, during the winters of 1994–1995 and 1996–1997. The first eagles were found dead during November, soon after arrival from fall migration, and deaths continued into January during both episodes. In total, 29 eagles died at or near DeGray Lake in the winter of 1994–1995 and 26 died in the winter of 1996–1997; no eagle mortality was noted during the same months of the intervening winter or in the earlier history of the lake. During the mortality events, sick eagles were observed overflying perches or colliding with rock walls. Signs of incoordination and limb paresis were also observed in American coots (*Fulica americana*) during the episodes of eagle mortality, but mortality in coots was minimal. No consistent abnormalities were seen on gross necropsy of either species. No microscopic findings in organs other than the central nervous system (CNS) could explain the cause of death. By light microscopy, all 26 eagles examined and 62/77 (81%) coots had striking, diffuse, spongy degeneration of the white matter of the CNS. Vacuolation occurred in all myelinated CNS tissue, including the cerebellar folia and medulla oblongata, but was most prominent in the optic tectum. In the spinal cord, vacuoles were concentrated near the gray matter, and occasional swollen axons were seen. Vacuoles were uniformly present in optic nerves but were not evident in the retina or peripheral or autonomic nerves. Cellular inflammatory response to the lesion was distinctly lacking. Vacuoles were 8–50 μm in diameter and occurred individually, in clusters, or in rows. In sections stained by luxol fast blue/periodic acid–Schiff stain, the vacuoles were delimited and transected by myelin strands. Transmission electron microscopy revealed intramyelinic vacuoles formed in the myelin sheaths by splitting of one or more myelin lamellae at the intra-periodic line. This lesion is characteristic of toxicity from hexachlorophene, triethyltin, bromethalin, isonicotinic acid hydrazide, and certain exotic plant toxins; however, despite exhaustive testing, no etiology was determined for the DeGray Lake mortality events. This is the first report of vacuolar myelinopathy associated with spontaneous mortality in wild birds.

Key words American coot; bald eagle, birds, central nervous system, *Fulica americana*; *Haliaeetus leucocephalus*; intramyelinic edema; vacuolar myelinopathy

Unexplained deaths of federally protected wildlife are routinely investigated by the US Department of Interior's National Wildlife Health Center (NWHC), where causes of more than 4,000 bald eagle (*Haliaeetus leucocephalus*) deaths have been documented over more than 20 years. Wild bald eagle mortality events usually involve one or two individuals, corresponding with the solitary habits of this predatory bird, but communal roosting in the winter or group attraction to food sites, such as carrion, occasionally lead to clusters of mortality. Large scale group deaths of bald eagles in the past have been of toxic etiology (NWHC, unpublished data).

Although bald eagles rarely are year-round residents in Arkansas, an estimated 1,000 eagles from nesting

sites in the northern USA and Canada spend the winter there from November to March. Wintering eagles congregate around the lakes and rivers that contain the eagles' primary diet of fish, but they may also range widely over land to opportunistically prey or scavenge on birds and mammals. One winter concentration site is DeGray Lake, a 14,000-acre reservoir formed in 1972 after dam construction on the Caddo River near Arkadelphia in southwestern Arkansas. During the winters of 1994–1995 and 1996–1997, 30–65% of the eagle population wintering at DeGray Lake may have died. Despite exhaustive diagnostic examinations and analyses for the historic causes of bald eagle mortality in the USA, no etiology was identified for the DeGray Lake episodes.

An estimated 8,000 American coots (*Fulica americana*) migrate onto DeGray Lake 2–4 weeks prior to the arrival of the bald eagles each fall. This gregarious, ducklike member of the family Rallidae frequents open fresh or brackish water throughout North and Central America. Coots dabble or graze near shore to feed on vegetation, insects, crustaceans, mollusks, and small fish and to acquire grit to assist in grinding their food. In the winter of 1996–1997, approximately 5% of the coots on DeGray Lake displayed neurologic signs, including incoordination in flight and leg paresis. Bald eagles at DeGray Lake were seen preying on coots. The bald eagles from both episodes and the euthanatized clinically affected coots had a striking microscopic lesion characterized by noninflammatory spongy degeneration of the white matter of the central nervous system. No previous reports have included the occurrence of this lesion in spontaneous avian mortality or morbidity events. In this report, we describe the first known occurrence of a spongiform myelinopathy of unknown etiology in two species of wild birds.

Case History

Twenty-nine bald eagles were found dead or dying in the vicinity of DeGray Lake, Arkansas, from 23 November 1994 to 15 January 1995. An additional 26 eagles were found dead or ill at DeGray Lake or at nearby Lakes Ouachita or Hamilton from 16 November 1996 to 25 January 1997. No eagle deaths were noted during the same winter months in 1995–1996 or in the 22-year history of this man-made reservoir, however, in March 1996 one moderately autolyzed eagle was suspected to have a condition similar to that of the early winter mortalities. Eagles were observed overflying perches or colliding with rock escarpments. Three impaired eagles died within 24 hours of capture.

American coots at DeGray Lake during January 1995 were described as reluctant to fly and uncoordinated. Normal coot behavior was noted during the winter of 1995–1996. Beginning on 6 November 1996, biologists observed neurologic signs in approximately 5% of the coots that had recently arrived to winter on the lake. Specifically, affected coots were reluctant to fly, wobbled in flight, and had a staggering gait on land. Captured affected coots ate readily, but their clinical signs progressed or showed no improvement in 72 hours. Dead coots were not generally found in the wild despite frequent field surveillance. The majority of the coot population migrated further south in early December 1996, and observations of sick birds declined to negligible by mid-December.

No clinical signs or unusual mortality were observed in other species of wild birds or mammals present in the DeGray Lake area during winter 1996. Deaths in other wildlife ($n = 15$, including 12 avian and one mammalian species) were due to various unrelated causes. Five bald eagles were found dead or dying at other sites in Arkansas during the DeGray mortality events. Four of these eagles died from lead poisoning and one from thoracic trauma.

five sick coots, routine serum chemistry panels performed on four eagles and one coot, serum bile acids of one eagle, and blood ammonia levels of two eagles and three coots were within normal limits for birds.

Necropsy

Twenty-four bald eagle carcasses, five from winter 1994–1995 and 19 from winter 1996–1997, were refrigerated and shipped to the NWHC (Madison, WI) for necropsy. Two additional eagles were shipped frozen during the winter 1996–1997 episode. Eighteen of the 26 eagles (69%) were females. Sixteen of the 26 (62%) eagles of both sexes were in immature or subadult plumage.

During November and December 1996, 77 American coots at DeGray Lake were determined by field personnel to be clinically abnormal and were euthanatized by cervical dislocation or gunshot for diagnostic evaluation. The carcasses were shipped to the NWHC, where complete necropsies were performed on 55 birds, and brains only were evaluated on the remainder. Of the coots that received necropsies, 51 of 55 (93%) were male and 31 of 55 (56%) were subadult, based on the presence of the bursa of Fabricius.

Postmortem examinations of refrigerated birds were done within 1–4 days of collection or death. At necropsy, tissue samples were collected for various toxicologic tests (Table 1). Samples of brain, bone marrow, liver, bile, lung, air sac, spleen, heart, pericardium, kidney, intestine, or oronasal mucosa from 15 eagles and 11 coots were collected for routine aerobic bacterial culture at 37 C on 5% sheep blood agar and eosin–methylene blue agar (DIFCO Laboratories, Detroit, MI). Nine eagles and 13 coots were sampled (brain, spinal cord, lung, spleen, blood, heart, liver, intestine, or oral or nasal mucosa) for virus isolation attempts in muscovy duck embryo fibroblast cell culture or embryonated chicken eggs.^{8,18} Heart blood was collected from seven eagles and 10 coots for assay in a mouse protection test for the toxins of botulism types C, D, and E.¹⁷ Gastrointestinal tracts from four eagles were collected for standard parasitologic examination. Brain or spinal cord from two eagles and two coots were screened for scrapie-associated fibrils by electron microscopy at the Wyoming Veterinary Diagnostic Laboratory (Laramie, WY).

Light microscopy

The entire or one-half of the brain from 26 eagles and 77 coots was fixed for light microscopy by immersion in 10% buffered formalin. The brains from 28 coots were fixed in formalin in the field within 10 minutes of euthanasia; brains of the remaining birds were fixed at necropsy. Samples of spinal cord from 21 eagles and five coots and peripheral nerve from 19 eagles and four coots were similarly fixed. Additional formalin-fixed samples included heart, lung, liver, kidney, spleen, skeletal muscle, adrenal gland, thyroid gland, intestine, gonad, and thymus from most eagles and pancreas, bursa of Fabricius, bone marrow, gall bladder, parathyroid gland, skin, trachea, oral or nasal mucosa, and gastric tract from several of the eagles. Eyes from 13 eagles were immersed in Bouin's fixative for 24 hours and then further fixed in 70% ethanol before sectioning.

Table 1. Toxicologic screening tests performed on tissues from bald eagles and American coots that died in the DeGray Lake area of Arkansas during the winters of 1994–1995 and 1996–1997.

Assay	No Birds Tested		Tissue	Result (range)*	Laboratory†
	Eagles	Coots			
Lead	26		Liver	NSL (ND–1.1 ppm)	NWHC
Thallium	2	1	Liver	ND	NWHC
Strychnine	1		Liver	ND	NWHC
Cyanide	1		Blood	ND	NWHC
	1		Brain	ND	
Arsenic	4		Liver	ND	WAHL
Mercury	8	8	Liver	NSL (0.06–9.3 ppm)	WAHL, HES
Nitrate, nitrite	3		Blood	ND	WAHL
Vitamin A	3		Liver	NSL (50–52 ppm)	WAHL
Vitamin E	3		Liver	NSL (0.6–6.6 ppm)	WAHL
Sodium fluoroacetate	1		Liver	ND	VDLND
	1		Kidney	ND	
Anticoagulant rodenticides‡	1		Liver	NC	IADL
Microcystin, saxitoxin, neo-saxitoxin	3		Liver	ND	FRI
Bromethalin	5		Fat	ND	LVDMI
	3		Liver	ND	
	2		Stomach contents	ND	
Triethyltin/butyltin	5	3	Liver	ND	GERG
Inorganic tin	2		Liver	ND	SPAL
Metals§	4		Liver	NSL§	SPAL
	3	2	Liver	NSL§	MAHDL
Organochlorine compounds#	4		Brain	NSL	MAHDL
Cholinesterase activity	8		Brain	NSL	NWHC
Fumonisin exposure	3	3	Liver	ND	NVSL
Gas chromatography/mass spectrometry	4		Brain	NSL	MAHDL
	3		Fat	NSL	
	2		Liver	NSL	
	2		Stomach contents	NSL	
Liquid chromatography/mass spectrometry	1		Liver	NSL	RTI

* NSL = no significant levels, ND = not detected, ppm = parts per million, wet weight, NC = not confirmed at ≤ 10 parts per billion

† FRI = Food Research Institute, University of Wisconsin, Madison, WI. GERG = Geochemical and Environmental Research Group, Texas A&M University, College Station, TX, HES = Hazelton Environmental Services, Madison, WI, IADL = Illinois Animal Disease Laboratory, Centralia, IL, LVDMI = Laboratories of Veterinary Diagnostic Medicine, University of Illinois, Urbana, IL, MAHDL = Michigan Animal Health Diagnostic Laboratory, Lansing, MI, NVSL = USDA, National Veterinary Services Laboratory, Ames, IA, NWHC = National Wildlife Health Center, Madison, WI, RTI = Research Triangle Institute, Research Triangle Park, NC, SPAL = Soil and Plant Analysis Laboratory, University of Wisconsin–Extension, Madison, WI, VDLND = Veterinary Diagnostic Laboratory, North Dakota State University, Fargo, ND, WAHL = Wisconsin Animal Health Laboratory, Madison, WI

‡ Including fumarin, racumin, warfarin, coumachlor, difenacoum, brodifacoum, pindone, valone, chlorophacinone, bromadiolone, 4-OH warfarin, 6-OH warfarin, 7-OH warfarin, 8-OH warfarin

§ Arsenic, cadmium, chromium, cobalt, copper, iron, lead, manganese, molybdenum, nickel, selenium, zinc

|| Antimony, barium, boron, calcium, magnesium, mercury, phosphorus, potassium, sodium, and thallium

Aldrin, alpha-BHC, beta-BHC, O,P'-DDD, P,P'-DDD, P,P'-DDE, O,P'-DDT, P,P'-DDT, dieldrin, endrin, heptachlor, heptachlor epoxide, lindane (gamma-BHC), and nonachlor

tinely processed for paraffin embedment, sectioned at 5 μ m, and stained with hematoxylin and eosin (HE). At least three transverse or sagittal sections of each eagle brain and a minimum of one transverse section of coot brain were examined. At least one section each of cervical and thoracic spinal cord were examined. Selected sections of eagle brain, spinal cord, nerve, and eye were stained with luxol fast blue/periodic acid–Schiff or by a modified Bielschowsky's method for nerve fibers. Three paraffin-embedded eagle brain sections were immunohistochemically stained for glial fibrillary acidic protein (GFAP) using the avidin–biotin–peroxidase complex

method with diaminobenzidine as chromagen (Dako Corp., Carpinteria, CA) and Gill's hematoxylin as the counterstain. A 1:500 dilution of rabbit polyclonal antibody reacting with GFAP (ABC-Elite, Vector Laboratories, Burlingame, CA) was applied to sections that had undergone 0.1% trypsin enzymatic digestion for 8 minutes at 25 C followed by application of swine anti-rabbit biotinylated antibody (Dako).

Electron microscopy

Specimens for electron microscopy were collected from the optic tectum of two coots and the optic tectum and spinal

cord of two eagles and immersed in Karnovsky's fixative. Formalin-fixed optic tectum and spinal cord from a third eagle were also used for electron microscopy. Tissues were stored in 0.1 M phosphate buffer, postfixed in 1% osmium tetroxide, stained with 2% uranyl acetate, and embedded in Epon Araldite. Semithin 1- μ m sections were stained with toluidine blue and used to evaluate tissue orientation by light microscopy. Ultrathin sections were stained with lead citrate and examined using a Philips 410 transmission electron microscope.

Results

Gross and laboratory findings

There were no consistent gross abnormalities in the bald eagles or the American coots. The birds were generally in good body condition, as evaluated by subcutaneous and abdominal fat deposits and pectoral muscle depth. However, most eagle stomachs contained no recent ingesta; gastric contents were thick green fluid, occasionally incorporating small gray feathers or fish bones and scales. Coots generally had a small amount of sand in the ventriculus. Subdural and extradural hemorrhage surrounded the upper thoracic spinal cord of one eagle, and petechiae were present in the medulla oblongata at the level of the foramen magnum of two eagles.

No significant infectious agents or botulism toxins were detected in laboratory tests. Toxicologic analyses detected no compounds above detection limits or in toxic concentrations (Table 1).

Light microscopy

All eagles examined and 62/77 (81%) coots had widespread, bilaterally symmetrical vacuolation of the white matter of the central nervous system (Fig. 1). Vacuolation was consistently seen in the white matter of the spinal cord in eagles and at all levels of the brain including the cerebellar folia and medulla oblongata of both species. The severity of vacuolation ranged from mild to marked among birds and among tissue locations in individual birds, but vacuolation was most severe in the optic tectum of all birds. The stratum opticum and stratum album centrale of the optic tectum were uniformly affected (Fig. 2). Spongy change was obvious at the junctions between white and gray matter where vacuoles indicated the myelinated fibers radiating through the neuropil. Vacuoles were present in the optic nerves to the level of the sclera but were not evident in the retina or peripheral

or autonomic nerves. No retinal abnormalities were present.

The vacuolation in the eagles' spinal cords was generally subtle and was concentrated near the junction with the gray matter (Fig. 3). In longitudinal sections of spinal cord or myelinated tracts in the brain the vacuoles were often aligned in rows along the bundles of myelinated fibers. The vacuoles ranged widely in size, but most were 8–50 μ m in diameter and circular or oval. Vacuoles occurred singly or in multiloculated clusters with thin myelin strands forming divisions within clusters (Fig. 4). Vacuoles were usually vacant, but occasionally membranous debris was visible within them.

With Bielschowsky's stain, greatly swollen spinal axons appeared focally compressed by vacuoles. Other axons were often deflected around large vacuoles (Fig. 5). Solitary cells with positive cytoplasmic staining for GFAP were widely scattered in the white matter. However, in the stratum album centrale in one of three eagles, hypertrophied reactive astrocytes were noted.

In contrast to the striking vacuolation of the white matter, other elements of the central nervous system were well preserved. No inflammatory cell infiltration was evident in the parenchyma, and rare inflammatory cells were found in the meninges of only three eagles. Macrophages were seen rarely within vacuoles in the spinal cord. Perivascular spaces were mildly dilated in affected areas. In 17/26 (65%) eagles, small peracute hemorrhages were clustered in the ventral thalamus near the infundibulum (10/17), in the medulla oblongata at the level of the foramen magnum (6/17), or at both sites (1/17). Hemorrhages were present in the medulla oblongata of several coots euthanatized by cervical dislocation. No consistent microscopic lesions were present in other organs. However, peracute hemorrhage was present in the myocardium of 12/24 (50%) eagles, and 9/24 (38%) eagles had hyaline degeneration or fibrinoid necrosis of the tunica media in one to four coronary arterioles or small muscular arteries.

Ultrastructural findings

Ultrastructural lesions were similar in the brains and spinal cords of the five birds examined. The vacuoles observed by light microscopy were intramyelinic blebs (Fig. 6). The perimeters of vacuoles were composed of one or more myelin lamellae, formed by separation

→

Fig. 1. Optic chiasm, transverse section; bald eagle. Severe vacuolation of the white matter beneath intact gray matter of the hypothalamus. HE. Bar = 400 μ m

Fig. 2. Optic tectum, transverse section, bald eagle. Prominent vacuolation in the stratum opticum (arrow) and stratum album centrale (arrowhead). Note sparing of the intervening gray matter. Luxol fast blue/periodic acid–Schiff. Bar = 400 μ m

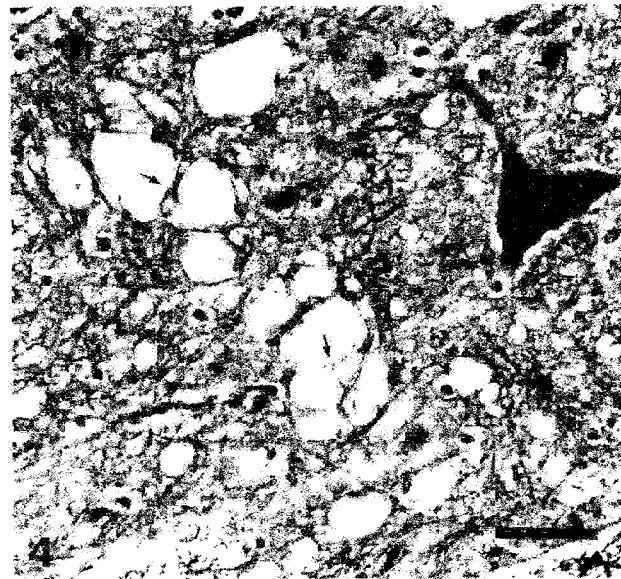
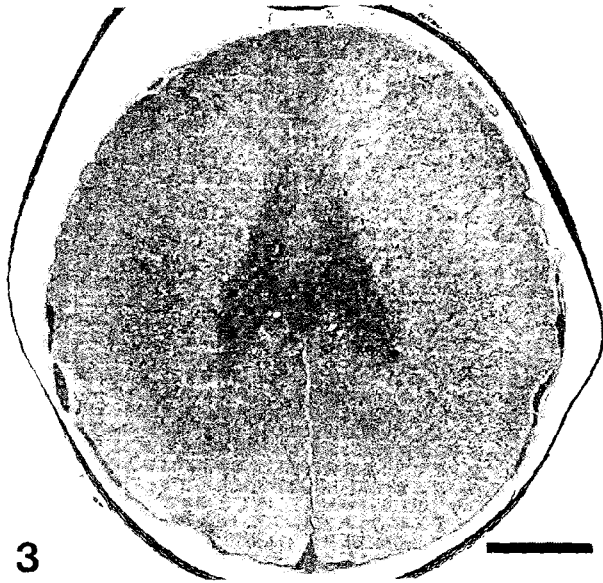
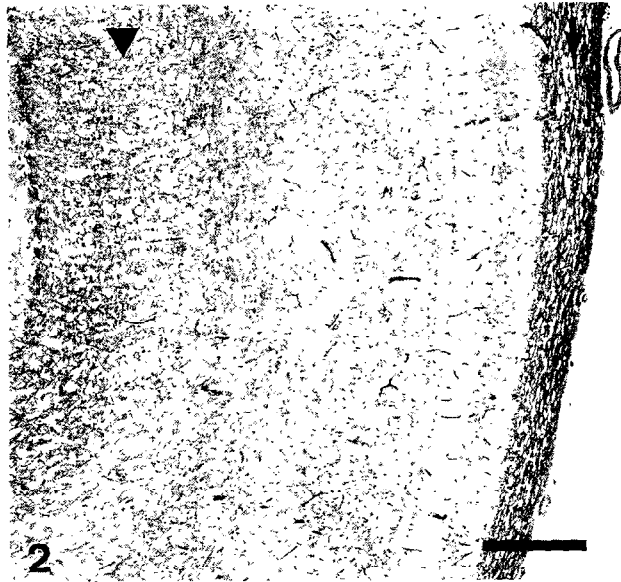



Fig. 3. Thoracic spinal cord; bald eagle. Spongy change in the spinal cord white matter. Note the concentration of vacuoles adjacent to the gray matter. Luxol fast blue/periodic acid-Schiff. Bar = 650 μ m

Fig. 4. Medulla oblongata, bald eagle. A cluster of vacuoles of various sizes is divided by delicate myelin strands (arrows). Luxol fast blue/periodic acid-Schiff. Bar = 40 μ m.

Fig. 5. Thoracic spinal cord; bald eagle. A swollen axon is focally compressed by vacuoles (arrow). Other axons are deflected around vacuoles (arrowhead). Note bilateral constriction at a normal node of Ranvier (open arrowhead). Bielschowsky's stain. Bar = 40 μ m.

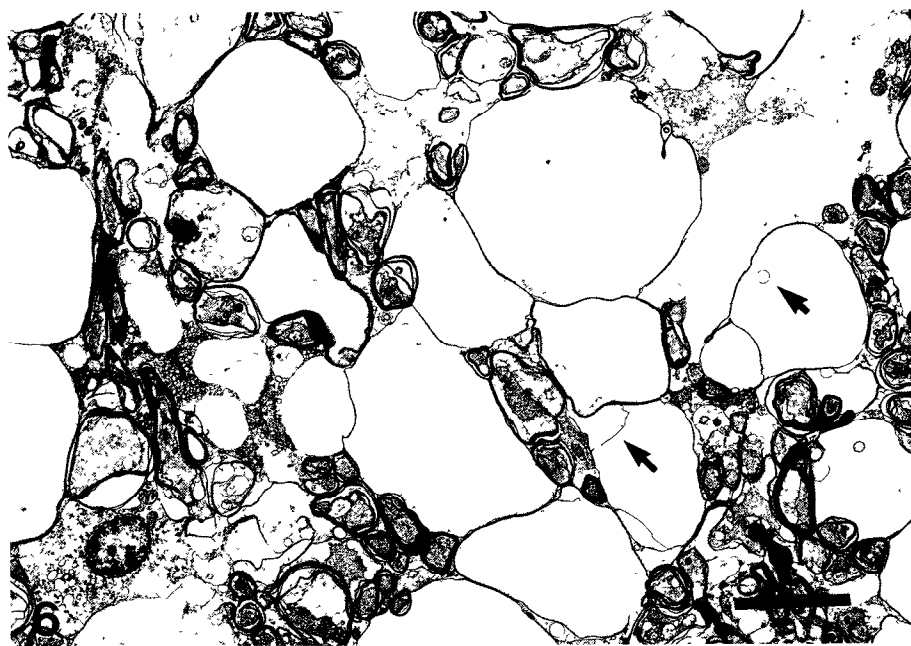


Fig. 6. Transmission electron micrograph. Optic tectum; bald eagle. Multiple myelin-bound vacuoles. Note that vacuoles are empty with the exception of thin strands or rings of disassembled myelin (arrows). Bar = 6 μ m.

of the lamellae at the intraperiodic line (Fig. 7). Fine electron-dense deposits clung to myelin lamellae whenever splitting had occurred.

Separation had occurred in multiple lamellae of the same sheath to create groups of adjacent vacuoles. Large vacuoles were difficult to trace to the sheath of origin because they were pressed outward against multiple adjacent sheaths. The myelin partitions between adjacent intramyelinic vacuoles were sometimes frayed or broken. Large vacuoles were usually vacant, but some contained eccentrically located axons or amorphous granular or membranous debris. The splitting in some sheaths assumed the pattern of microvesiculation, forming a lacework around the axon. In longitudinal sections, axons could be seen to be focally compressed by large vacuoles or by clusters of small vacuoles in the periaxonal space (Fig. 8).

Discussion

Bald eagles and American coots in the vicinity of DeGray Lake, Arkansas, displayed an unusual central nervous system lesion characterized by diffuse spongiform myelinopathy, compatible with intramyelinic edema. The lesion differed from common inflammatory conditions by its striking lack of cell infiltrates and relative preservation of other neural elements. This spongiform change in eagles and coots also distinctly differed from the transmissible spongiform encephalopathies of mammals and humans. In contrast to transmissible spongiform diseases in which vacuolation predominates in gray matter, the spongiform

change in affected birds from the DeGray Lake region was clearly confined to the white matter of the central nervous system.^{7,24,25} The lesion was also readily distinguished from the white matter artifact that occurs in autolyzed avian nervous tissue by the relative severity of vacuolation in comparison with good cell preservation, the presence of swollen axons in the spinal cord, and electron microscopic confirmation of intramyelinic vacuoles that formed as myelin lamellae split at the intraperiodic line.

The finding of spongiform degeneration of central nervous system myelin correlates well with the clinical signs of incoordination and paresis that were observed in sick coots and eagles. The potentially reversible nature of this degenerative lesion corresponds with field observations of morbidity but minimal mortality in coots; however, the eagles' high fatality rate is not readily explained. Hemorrhages in eagles at sites vulnerable to mechanical trauma at the sella turcica and foramen magnum may indicate unusual friability or brain swelling in this species. Further clarification of the pathogenesis will necessarily await experimental reproduction of the condition, at which time factors such as cerebrospinal fluid pressure or intracellular edema can be evaluated.

Spongiform myelinopathy has not been described in association with spontaneous mortality events in wild or domestic birds in the past. In domestic and laboratory mammals or human beings, this lesion is characteristic of certain progressive congenital conditions, metabolic disorders, or acute toxicities. Familial spon-




Fig. 7. Transmission electron micrograph. Optic tectum, American coot. Multiple vacuoles in the myelin sheath of a disfigured axon (ax). Bar = 2.5 μm . Inset. Higher magnification of vacuole boundary (arrow). Note separation of myelin lamellae at the intraperiodic line. Bar = 0.1 μm .

giform myelin disorders have been reported in young Labrador Retrievers and silver foxes (*Vulpes vulpes*) or as conditions such as Canavan's disease (autosomal recessive) or adult-onset leukodystrophy (autosomal dominant) in humans, and complex metabolic disorders include maple syrup urine disease of cattle or humans, hyperglycinemia, vitamin B₁₂ deficiency, hepatic encephalopathy, or severe uremia.^{1,2,6,10,12,19,20} Spongiform myelinopathy that occurs acutely and without other systemic involvement, as in these epizootics, is more characteristic of toxicity. Hexachlorophene, triethyltin, bromethalin, halogenated salicylanilide anthelmintics, cuprizone, isonicotinic acid hydrazide (INH), and certain nonnative plants in the genera *Stypanandra* and *Heliocrysum* are reported to produce intramyelinic vacuoles as a primary toxic effect in mammals.^{3,4,9,13,14,16,21-23} Ducks experimentally dosed with triethyltin or INH developed a similar lesion when intoxicated.^{5,11,15} A toxic agent has not been identified in association with this spontaneous occurrence in eagles

and coots. Eagle tissues were rigorously tested but yielded negative results for residues of the toxic agents known to produce spongiform myelinopathies in mammals and for a wide variety of unrelated poisons that have caused other eagle deaths.

The uncertain etiology of these events poses a serious dilemma for wildlife managers who are unable to prevent additional losses in a valuable wildlife resource. The field circumstances surrounding these episodes is the most likely source of guidance for further investigations into the etiology of spontaneous vacuolar myelinopathy in eagles and coots. The two species that were involved in these events belong to different taxonomic orders and differ in food preferences and habitat use, and yet other wild bird and mammal species at the site appeared unaffected. The predator-prey relationship between eagles and coots or their coincident use of the same aquatic environment could be the important link. The seasonal pattern in reoccurrence of these events may be a product of the migratory chro-

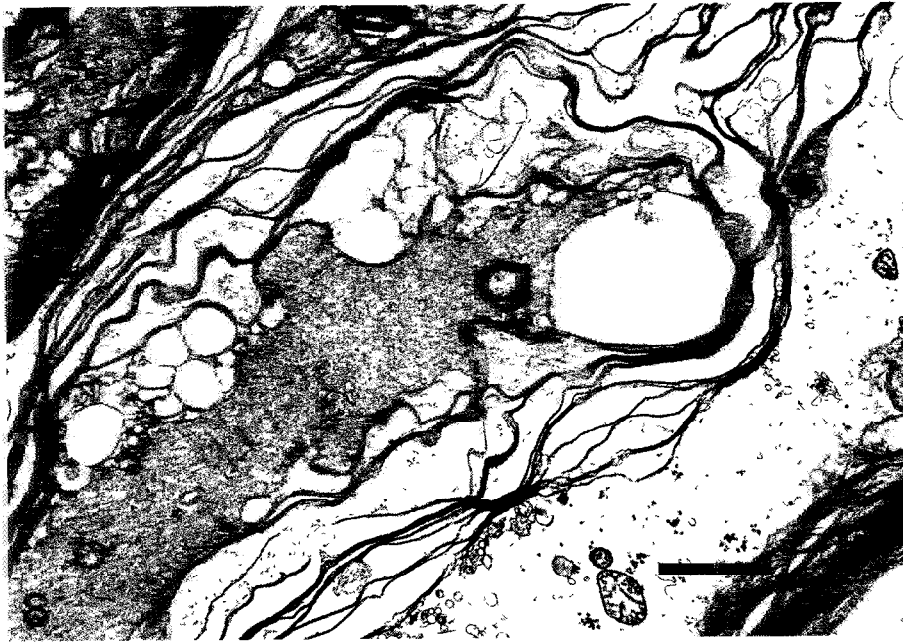

Fig. 8. Transmission electron micrograph. Spinal cord; bald eagle. Note the microvesiculation of myelin lamellae and focal compression of an axon. Bar = 2.25 μ m.

nology of the two species. However, the apparent synchronization of the occurrence in both time and place suggests that somewhat predictable opportunities for prospective study exist.

Acknowledgements

We thank Dr. Gabriele ZuRhein, School of Medicine, University of Wisconsin–Madison, for consultation and valuable advice, Dr. Kimberli Miller for characterization of the field circumstances, NWHC staff who performed microbial and toxicologic assays, Jackie Schultz for technical assistance in immunohistochemistry, the many cooperators who consulted on histopathology or performed screening tests, and the biologists of the Arkansas Game and Fish Department and members of the Arkansas Eagle Mortality Task Force for their collaboration in this investigation.

References

- 1 Agamanolis DP, Potter JL, Herrick MK, Sternberger NH: The neuropathology of glycine encephalopathy: a report of five cases with immunohistochemical and ultrastructural observations. *Neurology* **32**:975–985, 1982
- 2 Agamanolis DP, Victor M, Harris JW, Hines JD, Chester EM, Kark JA: An ultrastructural study of subacute combined degeneration of the spinal cord in vitamin B₁₂-deficient rhesus monkeys. *J Neuropathol Exp Neurol* **37**:273–299, 1978
- 3 Blakemore WF: Observations on oligodendrocyte degeneration, the resolution of status spongiosus and remyelination in cuprizone intoxication in mice. *J Neurocytol* **1**:413–426, 1972
- 4 Blakemore WF, Palmer AC, Noel PRB: Ultrastructural changes in isoniazid-induced brain oedema in the dog. *J Neurocytol* **1**:263–278, 1972
- 5 Carlton WW, Kreutzberg G: Isonicotinic acid hydrazide-induced spongy degeneration of the white matter in the brains of Pekin ducks. *Am J Pathol* **48**:91–105, 1966
- 6 Cho DY, Leipold HW: Experimental spongy degeneration in calves. *Acta Neuropathol (Berl)* **39**:115–127, 1977
- 7 DeArmond SJ, Prusiner SB: Etiology and pathogenesis of prion diseases. *Am J Pathol* **146**:785–811, 1995
- 8 Docherty DE, Slota PG: Use of muscovy duck embryo fibroblasts for the isolation of viruses from wild birds. *J Tissue Cult Methods* **11**:165–170, 1988
- 9 Dorman DC, Zachary JF, Buck WB: Neuropathologic findings of bromethalin toxicosis in the cat. *Vet Pathol* **29**:139–144, 1992
- 10 Eldridge R, Anayiotos CP, Schlesinger S, Cowen D, Bever C, Patronas N, McFarland H: Hereditary adult-onset leukodystrophy simulating chronic progressive multiple sclerosis. *N Engl J Med* **311**:948–953, 1984
- 11 Fleming WJ, Hill EF, Momot JJ: Toxicity of trimethyltin and triethyltin to mallard ducklings. *Environ Toxicol Chem* **10**:255–260, 1991
- 12 Hagen G, Blakemore WF, Bjerkås I: Ultrastructural findings in spongy degeneration of white matter in silver foxes (*Vulpes vulpes*). *Acta Neuropathol (Berl)* **80**:590–596, 1990
- 13 Huxtable CR, Dorling PR, Slatter DH: Myelin oedema, optic neuropathy and retinopathy in experimental *Stypandra imbricata* toxicosis. *Neuropathol Appl Neurobiol* **6**:221–232, 1980
- 14 Jubb KVF, Huxtable CR: The nervous system. In: *Pathology of Domestic Animals*, ed. Jubb KVF, Kennedy PC, and Palmer N, 4th ed., vol. 1, pp. 375–380. Academic Press, San Diego, CA, 1993
- 15 Lampert PW, Schochet SS: Electron microscopic obser-

- vations on experimental spongy degeneration of the cerebellar white matter. *J Neuropathol Exp Neurol* **27**:210–220, 1968
- 16 Prozesky L, Pienaar JG Amaurosis in sheep resulting from treatment with rafoxanide. *Onderstepoort J Vet Res* **44**:257–260, 1977
- 17 Quorstrup ER, Sudheimer RL: Detection of botulism toxin in the blood stream of wild ducks. *J Am Vet Med Assoc* **102**:264–266, 1943
- 18 Senne DA Virus propagation in embryonating eggs *In: A Laboratory Manual for the Isolation and Identification of Avian Pathogens*, ed Purchase HG, Arp LH, Dommuth CH, and Pearson JE, pp. 176–181. American Association of Avian Pathologists, Kennet Square, PA, 1989
- 19 Shimada A, Kuwamura M, Awakura T, Umcmura T, Yamane Y Spongiform degeneration of the brain associated with uremia in an aged coyote (*Canis latrans*). *Vet Pathol* **31**:484–487, 1994
- 20 Summers BA, Cummings JF, de Lahunta A. *Veterinary Neuropathology*, pp. 208–350. Mosby-Year Book, St. Louis, MO, 1995
- 21 Towfighi J Hexachlorophene *In: Experimental and Clinical Neurotoxicology*, ed. Spencer PS and Schaumburg HH, pp. 440–455. Williams & Wilkins, Baltimore, MD, 1980
- 22 Van der Lugt JJ, Olivier J, Jordaan P: Status spongiosis, optic neuropathy, and retinal degeneration in *Helichrysum argyrosphaerum* poisoning in sheep and a goat. *Vet Pathol* **33**:495–502, 1996
- 23 Watanabe I: Organotins (triethyltin) *In: Experimental and Clinical Neurotoxicology*, ed. Spencer PS and Schaumburg HH, pp. 545–557. Williams & Wilkins, Baltimore, MD, 1980
- 24 Williams ES, Young S: Neuropathology of chronic wasting disease of mule deer (*Odocoileus hemionus*) and elk (*Cervus elaphus nelsoni*). *Vet Pathol* **30**:36–45, 1993
- 25 Wood JLN, McGill IS, Done SH, Bradley R: Neuropathology of scrapie a study of the distribution patterns of brain lesions in 222 cases of natural scrapie in sheep, 1982–1991 *Vet Rec* **140**:167–174, 1997