



NOAA TECHNICAL MEMORANDUM

NMFS-SEFSC-82

GUIDE TO SEA TURTLE VISCERAL ANATOMY

BY


WILLIAM E. RAINEY

NOVEMBER 1981

REPRINTED

FEBRUARY 1994

**U.S. DEPARTMENT OF COMMERCE
NATIONAL OCEANIC AND ATMOSPHERIC ADMINISTRATION
NATIONAL MARINE FISHERIES SERVICE
SOUTHEAST FISHERIES SCIENCE CENTER
75 VIRGINIA BEACH DRIVE
MIAMI, FL 33149**



NOAA TECHNICAL MEMORANDUM

NMFS-SEFSC-82

GUIDE TO SEA TURTLE VISCERAL ANATOMY

BY

WILLIAM E. RAINEY

This Technical Memorandum series is used for documentation and timely communication of preliminary results, interim reports, or similar special-purpose information. Although the Memoranda are not subject to complete formal review, editorial control, or detailed editing, they are expected to reflect sound professional work.

**U.S. DEPARTMENT OF COMMERCE
Ronald H. Brown, Secretary**

**NATIONAL OCEANIC AND ATMOSPHERIC ADMINISTRATION
James N. Baker, Under Secretary For Oceans And Atmosphere**

**NATIONAL MARINE FISHERIES SERVICE
Nancy A. Foster, Acting Assistant Administrator For Fisheries**

NOTICE

The National marine Fisheries Service (NMFS) does not approve, recommend, or endorse and proprietary product or material mentioned in this publication. No reference shall be made to NMFS, or to this publication furnished by NMFS, in any advertising or sales promotion which would indicate or imply that NMFS approves, or endorses any proprietary product or proprietary material mentioned herein or which has as its purpose any intent or cause directly or indirectly the advertised product to be used or purchased because of NMFS publication.

THIS REPORT SHOULD BE CITED AS FOLLOWS:

Rainey, W.E. 1981. Guide to sea turtle visceral anatomy. NOAA Technical Memorandum NMFS-SEFSC-82, 82pp.

COPIES MAY BE OBTAINED BY WRITING:

**National Marine Fisheries Service
Miami Laboratory
Sea Turtle Program
75 Virginia Beach Drive
Miami, FL 33149**

or

**National Technical Information Service
5285 port Royal Road
Springfield, VA 22161**

CONTENTS

Preface	i
Introduction	1
Data recording	2
Sampling	4
General recommendations for dissection	8
Sources of additional information	10
Using the figures	10
Figures 1 - 10 <u>Chelonia mydas</u> juvenile female	12
Figures 11 - 23 <u>Caretta caretta</u> juvenile male	32
Figures 24 - 27 <u>Lepidochelys olivacea</u> posthatchling	58
Figures 28 - 29 <u>Dermochelys coriacea</u> hatchling	66
Figures 30 - 31 <u>L. olivacea</u> adult female reproductive tract	70
Figure 32 <u>C. mydas</u> male and female gonads	74
Bibliography	76
Equipment and supplies	79
Index	80

PREFACE

Dead sea turtles drift ashore at least occasionally along most tropical and temperate seacoasts. In some areas, such as the southeastern United States, this is a common occurrence. For most beachgoers, a large, dead animal evokes strong curiosity at long range and revulsion up close. For the person prepared to probe beneath the surface, these animals are a valuable, unexploited source of information on the natural history of sea turtles and on factors currently affecting their survival.

This guide describes and illustrates the major visceral organs of sea turtles. It is designed primarily to aid nonspecialists in obtaining biological and ecological data through dissection of salvaged animals. Initial sections outline data recording, sampling methods and comment on dissection procedure. The core of the guide is a series of photographs showing stages in the dissection of several species and sizes of sea turtles. These are accompanied by detailed legends describing dissection methods and the exposed organs.

I thank R. Jones, D.M. Magor, M. Mendonca, L. Ogren, D. Owens, E.D. Pierson, M.H. Wake and R.E. Wolke for reviewing portions of the manuscript. D. Blair offered advice on parasite preservation. F. Berry, S. Braddon, K. Cliffton, P. Licht, W. Pringle, P.R. Witham, D. Worth and others assisted in obtaining salvaged specimens for dissection which were handled under U.S. Fish and Wildlife Service Permits PRT2-1125, PRT2-4481 and Florida Department of Natural Resources permit TP-70.

This guide was prepared by the author for the Southeast Fisheries Center, National Marine Fisheries Service, under Purchase Order NA-79-GF-A-118. Reference to trade names does not imply endorsement by the National Marine Fisheries Service.

Introduction

The seven species of sea turtles recognized worldwide are grouped in two families:

Family Cheloniidae

<u>Chelonia mydas</u>	Green
<u>Chelonia depressa</u>	Flatback
<u>Eretmochelys imbricata</u>	Hawksbill
<u>Caretta caretta</u>	Loggerhead
<u>Lepidochelys olivacea</u>	Olive ridley
<u>Lepidochelys kempfi</u>	Kemp's ridley

Family Dermochelyidae

<u>Dermochelys coriacea</u>	Leatherback
-----------------------------	-------------

All of these species except the flatback are encountered at least rarely in U.S. waters. Species in the Family Cheloniidae have hard bony shells covered with scutes. The sole member of the other family, the leatherback, has skin rather than scutes covering its body and the bony shell is much reduced. The position and gross appearance of the major visceral organs in all sea turtle species are similar, but the fundamental division of the group into two families is also reflected in their internal anatomy. Differences among the hard shelled turtles are small, but the subdivided stomach and other features of the leatherback digestive tract are very distinctive.

In addition to differences among species, there are also size, sex, and season-related anatomical variations which should be kept in mind when identifying internal structures. Although general form and location are usually sufficient to identify major organs in any size turtle, not all organs change in size at the same rate during growth. The thymus gland, for example, is relatively large in hatchling and juvenile turtles, but is absent or much reduced in adults. In mature animals, which grow very slowly if at all, seasonal changes associated with reproductive activity cause obvious variations in the size of gonads and the amount of body fat.

Especially when conducted systematically over time at a number of localities, dissection and analysis of samples from salvaged sea turtles can yield information on:

Anatomy and anatomical variation, particularly developmental and seasonal changes.

Diet, parasite load and epibiota in relation to species, size class, locality, and season.

Relative rates and causes of mortality for different species and size classes of turtles along with seasonal and geographic variations in the mortality patterns.

The condition of a salvaged specimen sets an upper limit on the information it will yield. Although a fresh specimen is ideal, it is often possible to gain considerable information (species, size, sex if adult, broken bones or other evidence of trauma, etc.) from weeks-old weathered carcasses if they have not been too badly scattered by scavengers. Resistant parts of prey and other ingesta (e.g., plastic debris) found within the body cavity can indicate diet if adequate care is taken to distinguish material that might have been introduced by wave action after death.

Data recording

A critical aspect of any scientific investigation is complete and systematic recording of data in a fashion which facilitates analyses, both by the original investigators and, subsequently, by other interested persons. For every turtle examined the basic information discussed below should be recorded in a catalog which is later duplicated so there is no chance of loss. (DeBlase and Martin, 1981, give detailed recording methods for mammals.) In addition, a standardized format for actual dissections should be designed for local circumstances to remind investigators what information and samples are to be taken.

Number

Each specimen should be assigned an individual number. Many numbering systems are possible, but for simplicity, people often sequentially number all specimens collected during their lifetime. The collector's initials and the specimen number appear on all related samples, notes, and data sheets.

Locality

It is particularly important to describe localities as precisely as possible in relation to permanent features recorded on publicly available maps or charts (e.g., U.S. Geological Survey 7.5' topographic maps or NOAA charts). Include the state, county and sufficient details in the catalog so that someone could relocate the site. It may be useful to include a sketch map in your notes. If you record latitude and longitude (at least to the nearest minute), check the numbers carefully, since experience indicates that errors are common.

Date

Indicate the date the specimen was acquired, writing out the date completely (e.g., 13 October 1981, not 13/10/81). Also include in your notes the date of death (or when the specimen was first observed) and the date of dissection.

Species identification

Relatively intact specimens of sea turtles can be readily identified to species on the basis of external features, primarily the numbers of scales and scutes on the head and body. Key external features differentiating sea turtle species are indicated in the illustrations (see Fig. 1,2,11, 24,28), but not all species are shown so it is assumed that the reader has a separate species identification guide. Photographs which clearly show the general form and scute boundaries of the carapace, plastron and

head will permit identification and are useful for recording injuries and coloration. The skull alone is also sufficient for identification.

Sex

During sexual maturation males develop distinctive external characters, such as an elongate tail (see discussions in Fig. 2,21), but immature males are not readily distinguishable from females. While for each species there is a carapace length above which one can generally assume that animals retaining a short tail are female, the wide range in size at maturity, even within one population, argues for determining sex by directly examining the reproductive organs during dissection (see Fig. 10,22,30,32). In animals near hatchling size (see Fig. 27) microscopic examination of gonad tissue is required. Always note how sex was determined.

External measurements and weight

At least three body measurements are usually taken. Measure carapace length along the dorsal midline from the anterior edge of the nuchal scute to the most posterior extension of the carapace (see Fig 1). Take carapace width at the maximum edge-to-edge width perpendicular to the body midline. Plastron length is measured along the ventral midline from anterior to posterior edge (see Fig. 2). It is desirable to have both straightline (taken with rigid calipers) and over-the-curve measurements (using a flexible tape measure), but note the method(s) used. Hatchlings should be measured to 1.0 mm and adults to 0.5 cm, if possible. When a suitable support and scales are available, whole body weight should be taken on recently dead turtles. Decomposing carcasses may lose weight through leakage of fluid or dessication (the latter also occurs during prolonged frozen storage).

While moving the turtle to take measurements, it is usually convenient to also examine and note the following items:

Carcass condition

Describe the extent to which the specimen has degraded since death (foul odor, bloating by trapped gas, skin sloughing, appendages fallen off, etc.). Bloating or dessication can create an impression of being fat or very thin, respectively, but in fresh specimens it should be possible to roughly evaluate the nutritional state before death. Animals stressed by reproductive migrations, dormancy, illness or injury may deplete their nutrient reserves and appear wasted. There may be hollows extending into the body around the limb bases, loose skin, a thin neck and a sunken plastron. (A notably flexible, somewhat concave plastron is normal for mature males, but they do not typically appear gaunt.)

Injuries and lesions

Examine, measure and describe with sketches or photographs any external abnormalities, both recent and healed. Try to distinguish (by probing and later dissection) between wounds to the living animal and damage after death by scavengers. Particularly with presumed propellor wounds, measure the maximum depth of the cuts, as well as their length and spacing to aid in estimating the size of the propellor. Examine the surface on injuries for distinctive marks, tooth or metal fragments, etc. which might indicate their origin. Note broken bones. Check the trailing

edges of the limbs for tags or possible tagging scars. Prominent fibrous skin tumors, commonly occupied by leeches, occur on the green turtle (and perhaps other species) worldwide (Raj and Penner, 1962).

Epibiota

The external surfaces of sea turtles may be occupied by a diverse array of fouling organisms, both plant and animal. Some of them can directly affect, or at least indicate, a turtle's state of health. Though their impact has not been studied, parasitic leeches are commonly found (see Davies, 1978, and Raj and Penner, 1962, on leech morphology) and may accumulate in enormous numbers in wounds. Most barnacles encrust the exterior of the turtle apparently relatively harmlessly, but some penetrate and deform the shell (see Monroe and Limpus, 1979, for barnacle identification). The typical amount of fouling differs among sea turtle species and localities, but abnormally heavy barnacle fouling (including overgrowth of the eyes) is often marked on injured or weakened animals.

The ecological and geographic ranges of fouling organisms and their distribution over a turtle's body can provide information on the turtle's prior behavior and habitat. For example, on torpid turtles trawled off Florida in the winter, barnacles on portions of the body were covered with mud, dead and blackened, suggesting burial in the sediment, while those on apparently exposed areas were living. This and other evidence strongly suggested extended winter dormancy (Carr, Ogren and McVea, 1980).

When examining the distribution of fouling organisms, check carefully around the eyes, the anus and in the mouth (see Fig. 4). Beached or floating carcasses may be attacked by amphipods and other invertebrate scavengers which are not part of the normal epifauna.

Sampling

After an animal dies tissue degradation begins rapidly, at first from release of the animal's own enzymes and subsequently by the action of decomposing microorganisms. Different preservation methods which slow down or stop these processes affect the structure and biochemistry of tissue, so it is important to consider in advance how samples will be analysed. Several basic methods are given below, but, whenever possible, persons responsible for special analyses should be contacted in advance regarding techniques.

Tissue collection

Samples of solid tissues should be removed in chunks, rather than shreds to preserve structure and slow biochemical degradation. Using a sharp blade, instead of scissors, reduces crushing.

Owens and Ruiz (1980) give detailed directions for collecting blood and cerebrospinal fluid from the neck and head of living turtles without injury. With freshly dead animals the method suggested for collecting cerebrospinal fluid is probably appropriate, but uncontaminated blood may be obtained during dissection by inserting a large bore needle and syringe into the heart chambers. Samples of other body fluids (peri-

cardial fluid, synovial fluid in joint capsules, etc.) can be taken similarly. In moribund or very recently dead turtles in which the blood is still fluid, addition of anticoagulants (e.g., heparin at 10 units/ml blood) allows separation of plasma and cellular components by centrifuging or letting it stand several hours, preferably on ice or under refrigeration. If blood in the heart chambers is clotted, centrifuging the clotted material will often recover some serum. In most salvaged animals (certainly in those which have been frozen), all the blood cells will have broken open and separation is no longer possible, but the hemolysed whole blood may be usable for some biochemical studies (see below).

Labelling

Each sample container should have a waterproof label or tag bearing the collector's initials, a specimen number and the tissue type(s). Mark those samples which are sterile. Labels written directly on glass or plastic will often rub off. For rigid containers, an external tape label (with adhesive known to be unaffected by low temperatures, such as medical adhesive tape) is usually satisfactory, but test solvent-type marking inks for durability. With plastic bags, a waterproof label placed in with the sample where it can be read is best, unless contamination is a problem. In that case, tape or wire the label to the bag or place it in an outer bag. Label containers before they are wet or cold. If necessary, a permanent label can be scribed in rigid plastic with a sharp probe.

Analyses using frozen samples

Freezing physically fixes tissue components in place, usually without damaging biochemical activity. Turtles frozen whole are suitable for gross dissection and most bulk chemical analyses, but the slow growth of ice crystals during freezing of large masses of tissues ruptures cells and makes them unsuitable for detailed microscopical studies.

Biochemical genetics. Try to collect at least 10 ml of blood, separating it into plasma and packed cells, or serum and clot, if possible. However, lysed whole blood is also usable. (If collected when very fresh, whole blood or separate fractions can also yield information useful in assessing the health of the animal; consult a clinical laboratory for advice.)

Also collect 5-10 g chunks each of skeletal muscle, heart, liver, kidney and small intestine. Cut with reasonably clean implements and avoid contaminating the sample with body fluids or foreign debris. Then keep cool and freeze as soon as possible in a tightly closed plastic bag or vial labelled with specimen number and tissue type. The most convenient plastic sample bags are Whirlpak™ which are sterile and have a wire closure attached. While most tissue components are stable at deep freeze temperatures (-15 to -20°C), some will continue to breakdown slowly even at -70°C.

If solid tissues are taken from an uncontaminated surface in a freshly dead animal and placed directly in a sterile container (with instruments rinsed with 70% alcohol, passed through a flame, or otherwise sterilized) and frozen promptly, preferably at -70°C, they can be used for virus culture.

Elemental composition (including heavy metals). Tissue samples should be 50 g or larger, if possible, and in single chunks so that they can be trimmed later in the laboratory to remove surface contaminants. Plastic or stainless steel collecting implements should be carefully cleaned. The samples should be placed in a labelled, preweighed Whirlpak™ or plastic vial, weighed again to at least 0.1 g accuracy and frozen at -20°C. Record these weights in your catalog with other data on this specimen. It is necessary to weigh the tissue samples before storage because the amounts of metals or hydrocarbons (see below) may be reported as concentrations based on the weight of wet tissue and samples frequently lose water during frozen storage. If it is intended to detect very low elemental concentrations, additional precautions to avoid contamination become necessary and a specialist should be consulted.

Hydrocarbon composition (including pesticides). Collect 50 g or larger chunks of fat, liver, and muscle with stainless steel implements rinsed, before taking each tissue, with analytical grade acetone. (Do not breathe solvent vapor or allow it to contact skin.) If specially cleaned containers are not available, preweigh a piece of heavy duty aluminum foil; wrap the tissue completely in the foil and weigh it before labelling and freezing. Do not allow the sample to contact soap, plastics, rubber or other potential contaminants. Foil degrades slowly during frozen storage in contact with tissue, so avoid holding samples more than a few months.

All of these analyses are best conducted with samples taken promptly from a reasonably fresh animal (no odor of decay or bloating). Attempts to recover live virus may not be worthwhile after decomposition is obvious, but considerable useful chemical information can be obtained until visceral organs begin to lose their gross structure. If these areas are beginning to liquefy, many proteins will have degraded and it is usually not worth collecting for biochemical genetic surveys.

Heavy metals and many hydrocarbons are not directly affected by decay, but there may be losses or changes in tissue distribution. Consequently, samples should not be collected from badly decayed carcasses to obtain baseline data on tissue concentration, but instances of severe contamination might still be detected.

Studies using chemical fixation

Gross anatomy and histology. Chemical fixatives are the first step in the most common field methods of preparing tissue for structural study, both at the cellular and organ level. Fixatives, however, may denature or extract biologically important molecules, so they are not normally used for the bulk biochemical analyses discussed above. Humason (1979) describes the preparation of many special purpose fixatives, but 10% Formalin (made by adding 1 part concentrated Formalin to 9 parts tap water or sea water) is the most generally suitable and easily accessible. The gross form of organs, relations of tissue layers, and the internal structure of cells are adequately fixed for light microscopy. Unless buffered, Formalin becomes acidic, gradually

decalcifies bones and penetrates tissue more slowly. Acid accumulation can be decreased most easily by adding an excess of magnesium or calcium carbonate (even marble chips), but adding more soluble buffers (3.5g anhydrous sodium acid phosphate and 6.5g anhydrous disodium phosphate/liter dilute Formalin) is preferable.

Penetration of fixatives into tissue is slow (especially if the skin is intact) and decomposition continues in unfixed areas. With entire organs or other large tissue masses, carefully inject them or cut into tissue to increase the surface area exposed to fixative. Rapid, complete fixation is only obtained with small blocks or slices of tissue (maximum measurement of about 0.5 cm in at least one dimension). Label these samples carefully, because the appearance of tissue may change considerably during fixation. Adequate labels and notes permit the tissue, its position, and any lesions or other features to be identified later. To reduce dilution by tissue fluids, the volume of fixative should be ten times the volume of tissue and, for entire organs the tissue should remain in fixative at least a week. For transportation after fixation, excess liquid can be drained off and the specimen transported wet in a sealed plastic bag.

Formalin is a potent mucous membrane irritant and should be used with gloves in a well ventilated area, preferably in a fume hood, or with a respirator equipped with suitable scrubber cartridges. Recent studies suggest that Formalin causes cancer in laboratory rats continuously exposed to high vapor concentrations.

The quality of chemically fixed specimens can be no better than the initial condition of the tissue. At warm temperatures the cells lining the stomach, for example, are badly damaged within minutes after blood stops circulating. The details of cellular structure of the visceral organs will not be preserved unless tissues are fixed or refrigerated within a few hours of death, but general features of tissue organization will persist longer.

Digestive tract contents. When freezing is impractical, bulk samples can be fixed and stored in formalin after weighing, but the use of buffered formalin is particularly important, because sea turtle diets frequently contain calcified items such as mollusc shells which could be damaged by storage in acidic formalin.

Internal parasites. Macroscopic parasites are best fixed for 5-30 seconds in 19:1 glacial acetic acid to concentrated Formalin, before storing them in 70% alcohol. 10% Formalin can be used, but parasites tend to curl (making identification difficult) unless killed with hot water and individually flattened with small weights on filter paper before fixing. Large samples of a single type of parasite are not necessary; it is preferable to fix a few carefully, describing their location and preserving associated lesions, if any, in Formalin.

Epibiota. All organisms living on the exterior of sea turtles can be fixed and stored at least temporarily in 10% buffered Formalin, but, if possible, crustaceans (including barnacles) are best placed

directly in 70% alcohol.

Microbiology and tissue culture

Sterile culture can recover microbes, including pathogens, and living cells of turtle tissues for subsequent growth and laboratory study if appropriate samples are taken within a few hours (sometimes more, depending on ambient temperature) of death. Procedures for bacteria, fungi and other microbes vary, but normally involve applying a swab or other sterile implement to an uncontaminated surface of a lesion or other area of interest and placing it in a sterile storage container or applying it to selective growth media. (One way to create an uncontaminated surface is to sear the surface of the organ with a hot spatula, then expose fresh tissue in that area by cutting with a sterile blade.) Viruses are usually cultured from frozen tissues as noted earlier, but can be collected in this fashion. Disposable supplies and kits for microbiological sampling are widely available and should be obtained with instructions from the microbiologist examining the material. Preparation of tissue cultures is similar, but is undertaken only for special purposes (e.g., chromosome banding). Sections of fixed tissues, smears of body fluids and solid tissue impressions air-dried on microscope slides are also useful for detection and classification of microorganisms. Enlist or consult a specialist for techniques.

Skeletal preparation

While it is possible to recover skeletal material from specimens which are buried or allowed to weather on the beach, losses of smaller elements are common and the bone itself may be substantially degraded. If fairly fresh specimens are manually stripped of large masses of tissue (especially fat) good preparations can be obtained by any of several methods outlined by Hildebrand (1968). Sea turtle skeletons, notably leatherbacks, usually require repeated degreasing in an organic solvent.

General recommendations for dissection

Health and sanitation

Dissecting a large sea turtle is an inescapably messy task and the odor of even fresh turtle fat will persist on skin and porous materials such as cloth after washing. Thus use of gloves, plastic aprons or other impermeable, easily disinfected (or discarded) superficial shields over conventional protective clothing reduces the difficulties of cleaning up. Disposable latex gloves are suitable for examination, but should be covered by heavier neoprene gloves when making extensive cuts on large animals. These provide some protection from cutting implements, bone fragments, etc. Do not allow two people to cut on the same carcass without extreme caution. Have spare gloves and a first aid kit and treat injuries promptly.

Captive sea turtles have been known to harbor microorganisms potentially pathogenic to humans (Brock, et al. 1976; Keymer, 1978). The incidence of human pathogens in wild sea turtles is unknown, but use appropriate care when dissecting even apparently healthy animals. Their normal gut flora may well contain bacteria pathogenic to humans if ingested.

Depending on local health regulations, tissue discarded during dissection is probably best buried if it cannot be eliminated through an organized carcass disposal system.

Procedure

Specimens, especially when fresh, should be examined as soon as possible after they are discovered. Refrigeration slows tissue breakdown, but freezing, as noted earlier, makes some studies impossible. Dissection is easiest in a laboratory with the animal on an elevated bench with adequate lighting, running water, a drain and a vacuum suction line to remove body fluids, but preparation will aid in getting maximum information with minimum difficulty from dissections conducted on an open beach. If two people are available, one should record data, label samples, and take photographs while the other dissects. Particularly on the beach, keep equipment and supplies organized and moderately clean on a sheet of plastic or in some other fashion that avoids their being lost in the viscera, or covered with sand.

During dissection the animal should be resting on its back (see Fig. 2), braced so that it does not move inconveniently. With large animals, crushed ice (or sand) can be molded to the contour of the carapace. It may be necessary to pin or tape the limbs of small animals to avoid movement. Sea turtle skin and cartilage, especially when sandy or encrusted with barnacles, dulls knives rapidly. For large animals, it is most convenient to have extra knives and a sharpening stone.

The appropriate time to take blood, pericardial fluid, and microbiological samples is usually shortly after the plastron is removed, before contamination becomes widespread. In a very fresh carcass, samples of tissues which degrade rapidly can also be taken for histology, but cut as few structures as possible. It is usually much easier to understand relationships and detect anomalies if the organs have not been detached. Organ systems should be examined in place, then removed intact for weighing, measuring and sampling.

The viscera are in partial hydrostatic suspension in the body cavity. When excess fluid is drained off, the intestines of specimens which have decomposed somewhat or have been frozen and thawed may rupture and spill their contents even when manipulated gently. Hard material in the gut (such as mollusc shells) makes this more likely. With frozen carcasses, this problem can sometimes be circumvented by dissecting out the digestive tract while the contents are partially frozen.

The colors of relatively fresh, unfixed tissues are described in some of the figure legends. In partially decomposed carcasses tissues are usually darker and less easily differentiated by color. Tissues darken during dissection even if kept on ice, so photographs should be taken soon after an organ is exposed. Holding tissues in water, physiological saline or fixing solutions makes them more opaque and reduces color contrasts.

Particularly in fresh specimens, examine, describe and fix samples from both apparently normal and anomalous tissues, including those affected by external wounds or lesions. Although pathology per se may not be an investigator's primary interest, some idea of the cause of death is needed to assess significance of other data (e.g., does reproductive condition in a specimen reflect normal seasonal variation or result from chronic illness?).

Data on organ weights from fresh specimens are valuable to establish norms, but time may not permit weighing all organs. In addition to the intact carcass, measure and weigh at least the reproductive organs (testes, epididymides, ovaries, oviducts). In females, weigh and measure the diameter of samples of the larger follicles and estimate or count how many follicles exist in different size groups. Describe the distribution and condition of eggs in the oviduct. Fix samples of ovary or testis and epididymis for microscopy. (Owens, 1980, includes much useful commentary on sea turtle reproductive organs, especially observations on changes in follicles after ovulation.)

Macroscopic internal parasites may be encountered virtually anywhere in the body, but are most likely to be observed in the digestive tract (both attached to the lining and hidden in abscesses in the wall), in the pancreatic and bile ducts, in the respiratory tract including the nasal passages, in the circulatory system (especially the heart chambers and visceral blood vessels) and in the bladder and cloaca. Collect and hold parasites in vials of seawater for later fixation.

Sources of additional information

The topical bibliography includes both references mentioned in the text and other useful background material in English. There is little recent literature on the gross anatomy of sea turtles. For access to overviews on the comparative anatomy of reptilian organs and organ systems, many chapters from the Biology of the Reptilia edited by Gans and Parsons are listed. Most of these include only scattered references to sea turtles.

Using the figures

Because each dissection relies, at least partly, on dissection techniques and comparative anatomical information presented in previous sequences, the reader should review all of them at least once, regardless of the species they are examining themselves. Most figures illustrate what is seen at a particular stage in dissecting a whole animal so adjacent elements of several organ systems may be seen simultaneously. To examine information on a particular organ or system consult the index.

In order to help in describing the location of structures in the body a few terms are reviewed here:

- Dorsal refers to the upper surface of the animal in its normal position in life and ventral refers to the lower surface. In a sea turtle the dorsal and ventral surfaces of the body are the carapace and plastron, respectively (see Fig. 1,2).

- Longitudinal features extend parallel to the long axis of the body part being discussed; this usually means parallel to the vertebral column.
- Transverse features cut across the long axis of the body or body part.
- Structures on the midline or long axis of a structure are median; those close to the midline are medial.
- Features away from the midline are lateral.
- These terms are frequently used for relative position. For example, the heart is dorsal to the plastron, but ventral to the lungs.
- Right and left in subsequent descriptions are based on the body orientation of the animal. Since the photographs usually show the animal resting on its carapace (which is still its dorsal surface even though it is turned over), the animal's right will be on the left side of the figure.

Figure 1. Chelonia mydas juvenile female.

The normal carapace scute pattern for the green turtle and hawksbill includes an anterior median nuchal scute (N) and five median vertebral scutes (V1 - V5) with four costal scutes (C1 - C4) and twelve marginal scutes (M1 - M12) on each side. Variations in scute number are reasonably common.

The combination of a single pair of elongate prefrontal scales (PF) on the head and four costal scutes normally distinguishes a green turtle from any other sea turtle in U.S. waters.

C1 - C4. costal scutes
N. nuchal scute
M1 - M12. marginal scutes
PF. prefrontal scales
V1 - V5. vertebral scutes




Figure 1.

Figure 2. C. mydas juvenile female.

In the bony-shelled sea turtles (Family Cheloniidae), the major paired plastral scutes from front to rear are the gular (G), humeral (H), pectoral (Pe), abdominal (Ab), femoral (F), and anal (An). There may also be a median anterior scute, the intergular (Int), and a median posterior scute, the postanal (Pa). On the bridges which join the plastron to the carapace are a series of three or four inframarginal scutes (IF1 - IF4) which contact the ventral portion of the marginal scutes (M5 - M8). Posterior and lateral to the last inframarginal (IF4 in this species) is a small inguinal scute (Ing) which may be subdivided into yet smaller scutes.

On or near the inguinal scute is a slit-like pore (p), the external opening of the inguinal Rathke's gland (see Fig. 3). Depending on the age and species, sea turtles also have one or more Rathke's gland pores in the axillary region (Ax). The function of these glands is not known, but their secretions may repel predators of young turtles and possibly serve for chemical communication among individuals. The number of inframarginal scutes and the distribution of Rathke's gland pores are used for species identification (see Fig. 11, 25, 28). Depending on the species, cheloniid turtles have one or two claws (C) on the anterior margin of each limb. In adult females and immatures of both sexes the claws are short and relatively straight. In mature males they develop into stout, curved hooks used for clasping the female's shell during copulation.

To remove the plastron after examining the mouth and throat (see Fig. 4, 5), cut along its margin through the skin and cartilagenous bridges (following the seam between the marginal and inframarginal scutes), as shown by the black and white dashes. Do not insert the knife deeper than necessary to cut through the cartilage, as internal organs may be damaged. If the axillary and inguinal Rathke's glands are of interest, cut medial to the pore to leave the duct to the gland intact (see Fig. 3, 14).

Ab.	abdominal scute	IF1 - IF4.	inframarginal scutes
An.	anal scute	Ing.	inguinal scute
Ax.	axillary region	Int.	intergular scute
C.	claw	M5 - M8	marginal scutes
F.	femoral scute	p.	Rathke's gland pore
G.	gular scute	Pa.	postanal scute
H.	humeral scute	Pe.	pectoral scute




Figure 2.

Figure 3. C. mydas juvenile female. Open arrows on scale bars point anteriorly.

A. In the green turtle the anterior pore (1) of Rathke's glands in the axillary region is ventral to the seam between the third and fourth marginal scutes (M3, M4). On hatchlings it is near the midpoint of the ventral margin of M4. The main axillary pore (2) is ventral to the seam between M4 and M5. Other species of cheloniid turtles usually have no more than one pore (at position 2) in the axillary region (see Fig. 11, 25, 28).

B. The inguinal Rathke's gland pore (3) is on or near the inguinal scute, ventral to the seam between M8 and M9. The leatherback and both species of ridley usually lack inguinal pores (see Fig. 11, 25, 28).

- | | |
|------------|---------------------------------------|
| 1. | anterior axillary Rathke's gland pore |
| 2. | posterior axillary pore |
| 3. | inguinal pore |
| M3 - M9. | marginal scutes |
| IF1 - IF4. | inframarginal scutes |

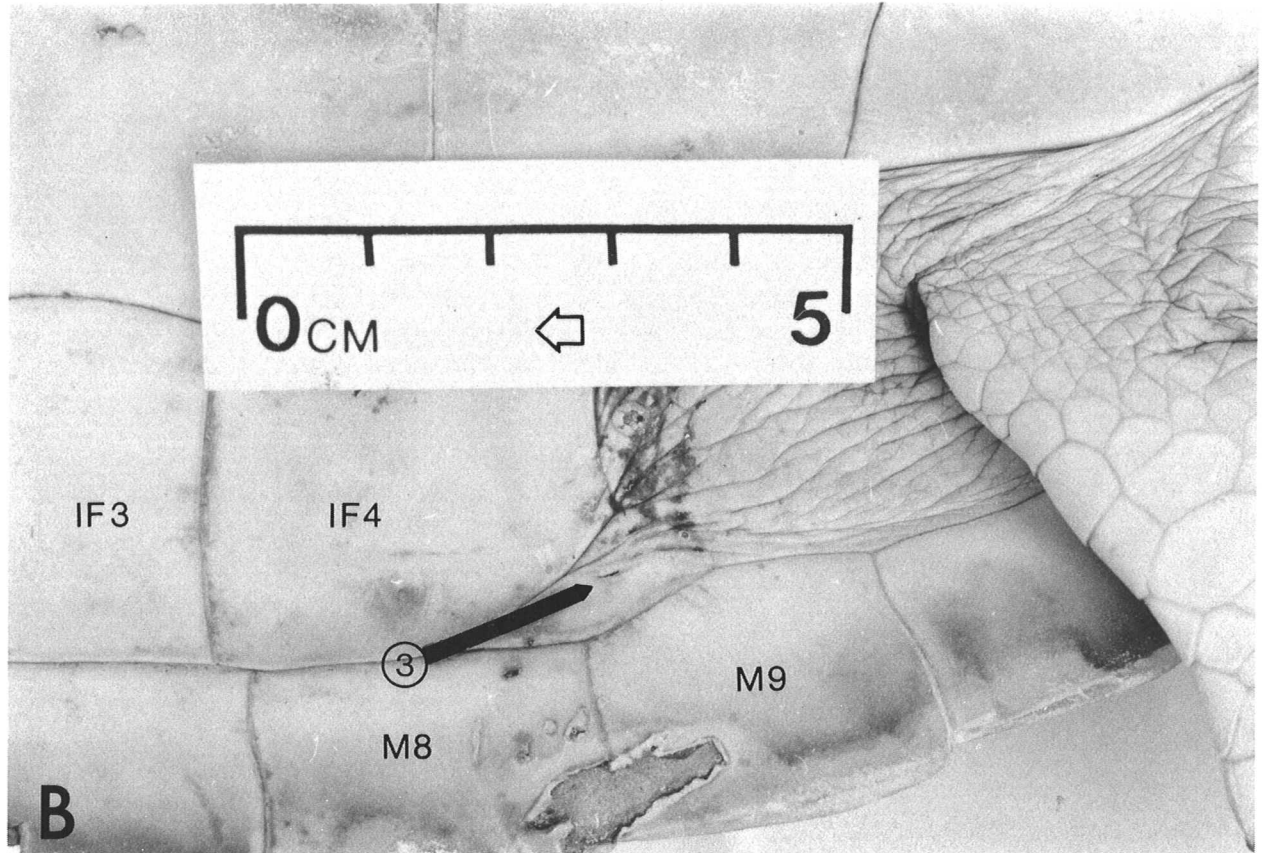
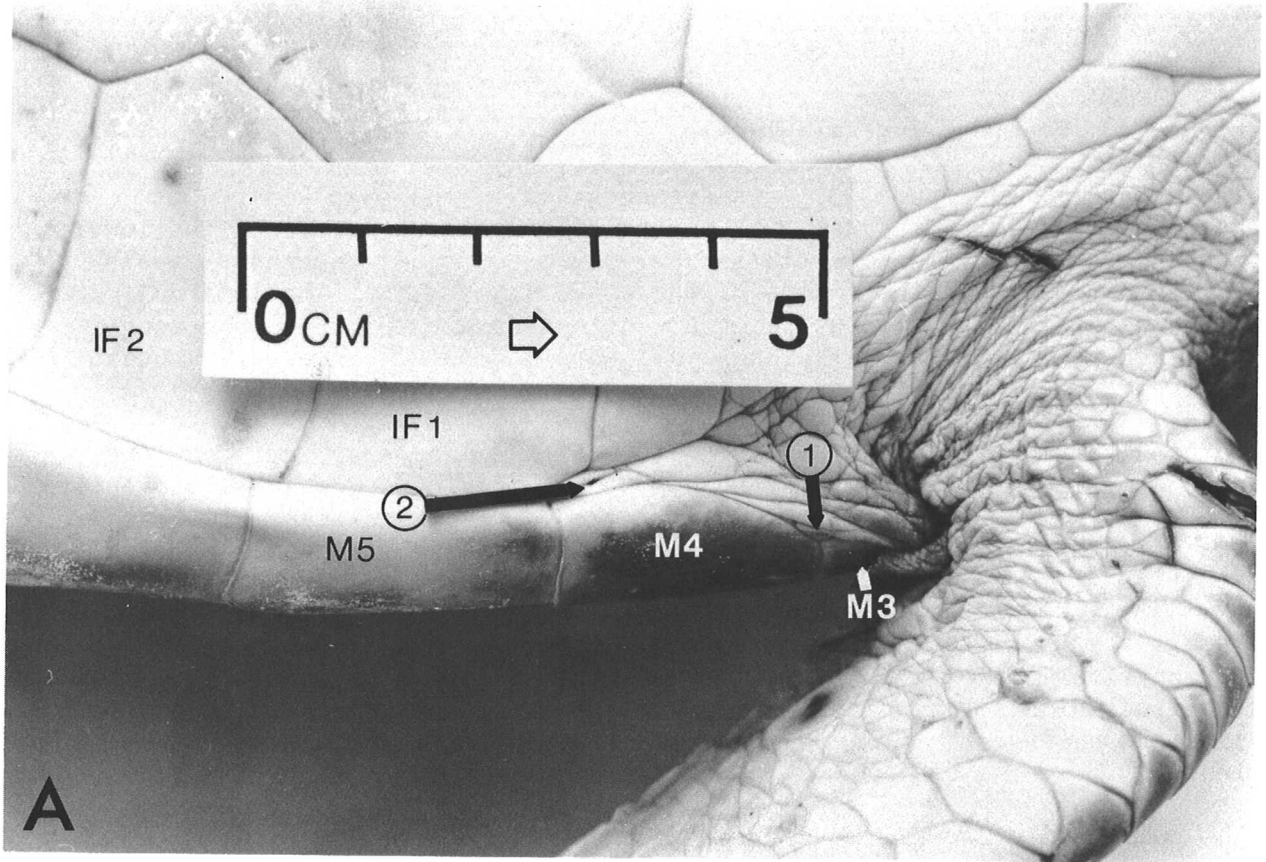


Figure 3.

Figure 4. C. mydas juvenile female.

The upper (1) and lower (3) jaws are sheathed in the same keratinous material that forms the carapace scutes. The lateral margin of the lower jaw sheath in the green turtle is serrate (see near 3) and these 'teeth' fit into grooves on the inside of the upper jaw sheath. The internal surfaces of the jaw sheaths in other cheloniids are thickened and rough but lack serrations. Leatherback jaws have a smooth, sharp-edged sheath (see Fig. 28).

To open the mouth beyond the normal gape as was done here, cut cautiously at the muscles in the angle of the jaw until the lower jaw is sufficiently free. It may be necessary to pry open the jaws to gain access to this area (if this proves too difficult, the mouth can be entered from below; see Fig. 5).

In all sea turtles, the tongue (4) is short, broad and closely attached to the floor of the mouth over most of its length. The glottis (5), a longitudinal slit immediately posterior to the tongue, is a valve controlling the passage of air into the underlying larynx and ultimately the lungs.

The paired internal narial openings (2) in the roof of the mouth connect by short, but complex tubes to the external nares or nostrils. Spongy erectile tissue surrounds the nasal passages close to the external nares. When underwater, these tissues can engorge with blood and close the passage to the mouth. In cheloniid turtles the internal nares are partly closed by a flap with one or more sharply-pointed papillae (near 2). In the leatherback the internal nares are placed more anteriorly, the nasal passages are shorter, and there are no papillae. Except for the jaw sheaths, the lining of the mouth in cheloniids appears smooth. The leatherback mouth has a few posteriorly directed spines which increase in number toward the esophagus.

The openings of the eustachian tubes which connect to the middle ear cavities are inconspicuous slits in the side of the throat posterior to the angle of the jaw. The slit may be on a slight prominence and can be located with a small blunt probe after rinsing the area free of debris. There are no lachrymal ducts.

Two organisms which live in sea turtle mouths are small, mobile, amphipod crustaceans (known from green turtles) and barnacles embedded in the throat tissue (occasional in loggerheads and leatherbacks).

1. upper jaw sheath
2. internal nares
3. lower jaw sheath
4. tongue
5. glottis

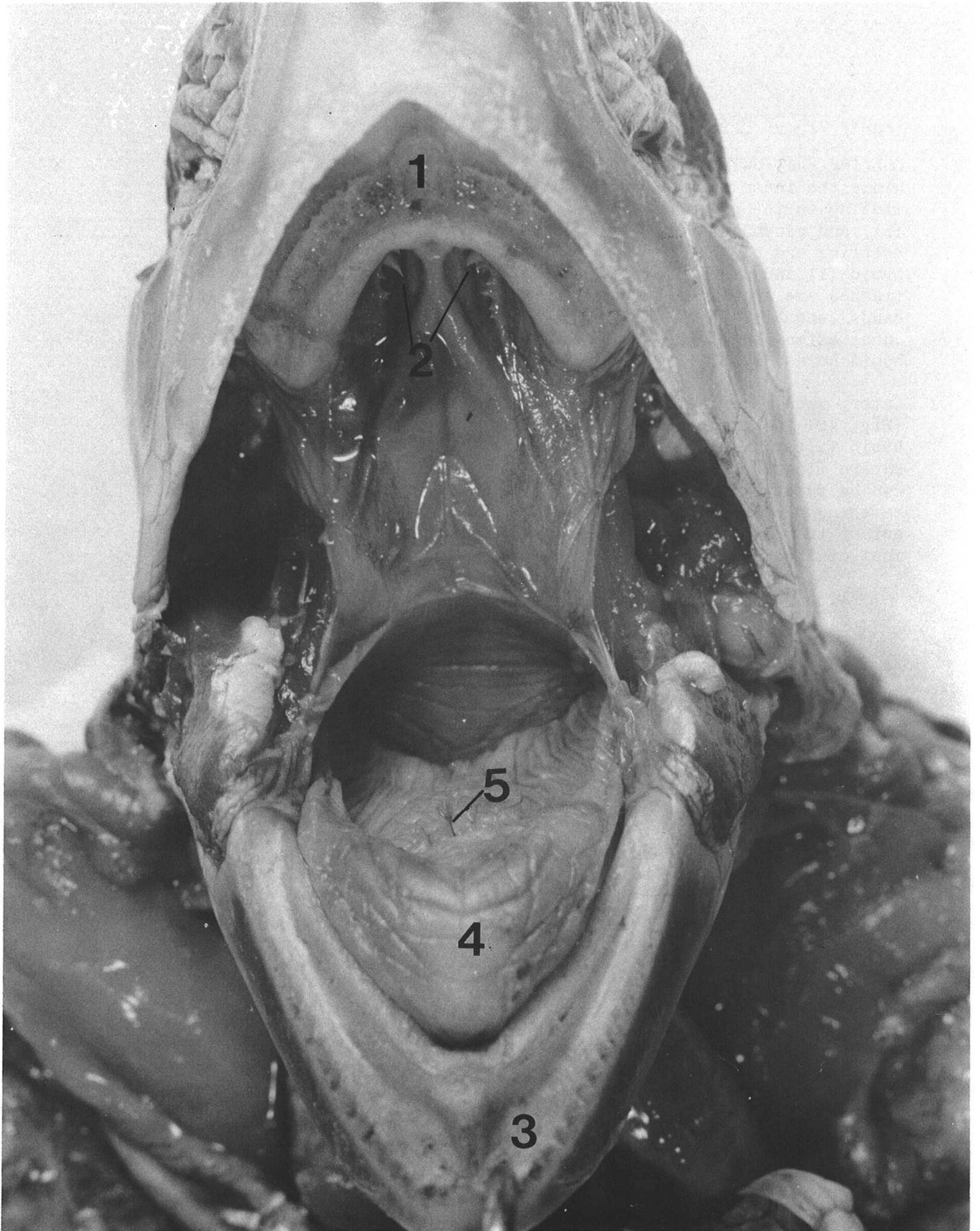


Figure 4.

Figure 5. C. mydas juvenile female

Cutting shallowly through the skin and ventral muscles of the neck along the inner margins of the lower jaw and posteriorly along the midline to the plastron exposes the hyoid apparatus (1-4), trachea (5), and esophagus (6). The larynx, a cartilagenous chamber at the anterior end of the trachea, is attached to the dorsal surface of the hyoid (1) and is not visible here. The thin, resilient walls of the trachea are supported by cartilage rings, evident here as transverse bands (see Fig. 26). The lingual process (4) is an anterior cartilagenous extension of the hyoid which supports the tongue. The paired hyoid horns (2, 3) link the hyoid to the neck and skull muscles.

Later, when removing the digestive (see Fig. 17) or respiratory tracts (Fig. 20) the trachea and esophagus can be cut off posterior to the hyoid (after tying off the esophagus with a cord). Alternatively, the entire floor of the mouth (with the hyoid still connected to the trachea) can be detached by cutting along the inner margins of the lower jaw, severing the esophagus at its origin and dissecting the hyoid horns out of the neck muscles. The latter approach also permits examining most of the mouth without forcing the jaws open.

- | | | | |
|----|----------------------------|----|-----------------------------|
| 1. | hyoid (cartilage and bone) | 4. | lingual process (cartilage) |
| 2. | hyoid horn (largely bone) | 5. | trachea |
| 3. | hyoid horn (cartilage) | 6. | esophagus |

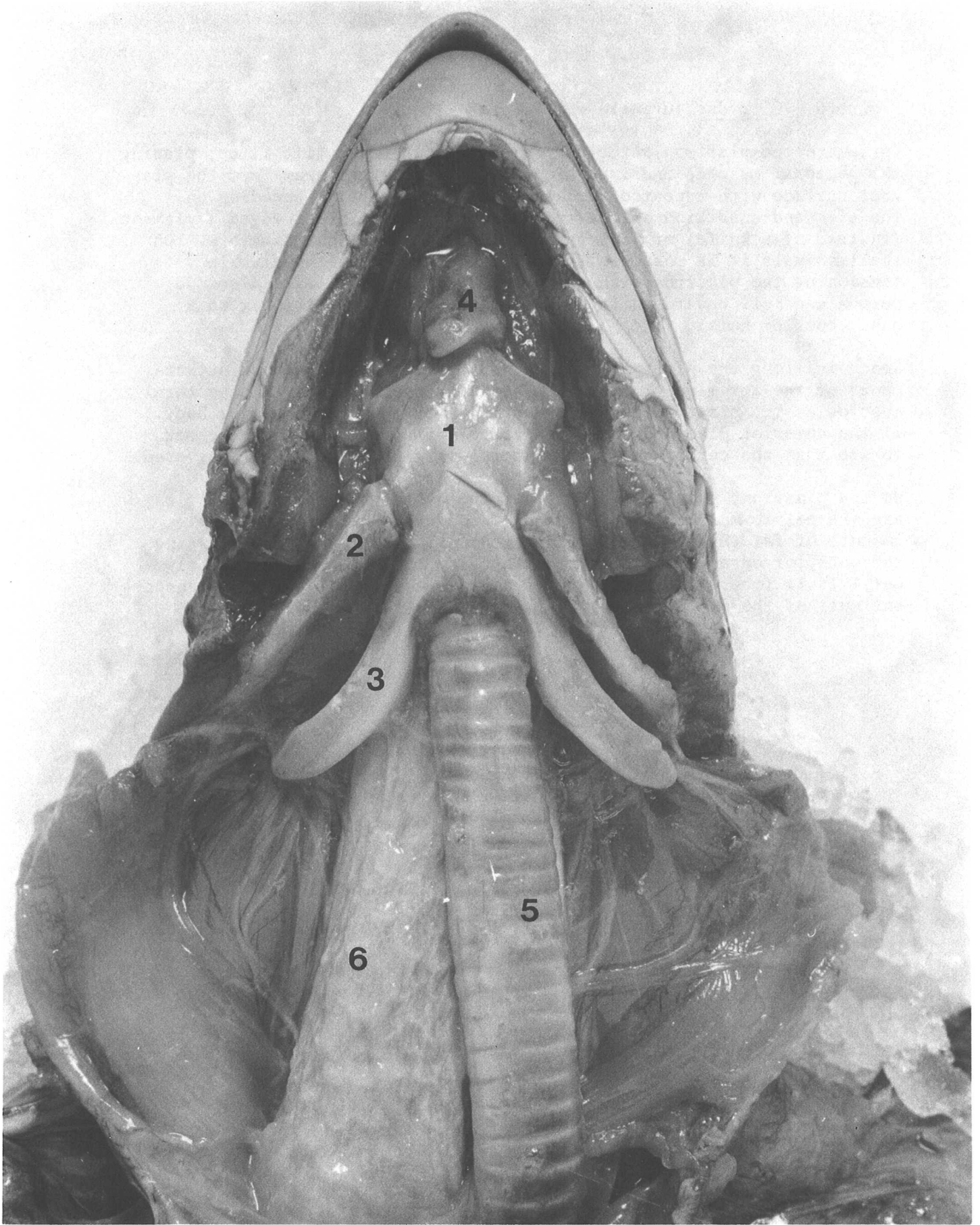


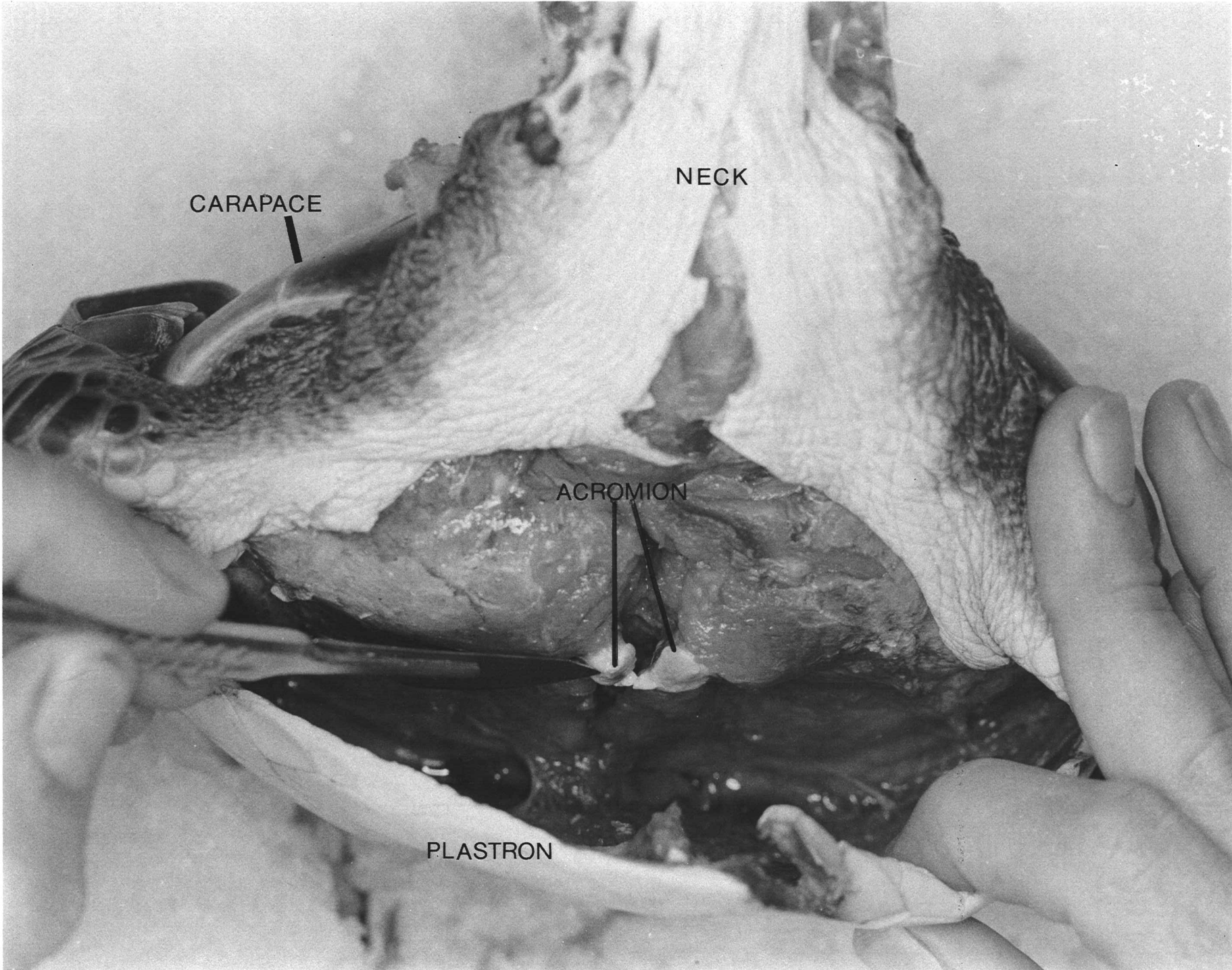
Figure 5.

Figure 6. C. mydas juvenile female.

To remove the plastron after its margin is cut free, lift it up, placing the pectoral muscles under tension, and dissect them away from the plastral surface with repeated strokes of a sharp knife. Depending on the size and condition of the turtle, the use of a blunt-edged implement (instead of a knife) or just tension may be equally satisfactory. On small animals it is possible to cut or probe with one hand while tensioning the plastron with the other. On larger animals a second person can pull upward on the anterior edge of the plastron with a hand, hook or hoist.

Reach in along the plastral midline and cut the cartilagenous attachments of the acromion processes. Then continue detaching the pectoral muscles as the plastron is pulled up and away from the anterior body. If the anterior plastron is not relatively free at this point, check to see that the cartilage at the lateral margins is completely severed.

On the plastron, posterior to the attachments of the pectoral muscles, are the pelvic muscles (Fig. 7) and, in older animals, substantial amounts of fat (Fig. 12). Continue tensioning the muscles by tilting the anterior edge of the plastron away from the body and posteriorly until it is free. In small animals avoid puncturing the thin, transparent wall of the distended urinary bladder ventral to the pelvis.



CARAPACE

NECK

ACROMION

PLASTRON

Figure 6.

Figure 7. C. mydas juvenile female.

In cutting the plastron free, it will usually be necessary to cut through the axillary and inguinal buttresses (B) of the plastral bones which extend through the cartilage of the bridge toward the marginal bones. Normally a sharp, strong knife is sufficient to cut these, but a serrate blade or saw may ease the task in large animals.

The right side of the body has the pectoral muscles (3) intact, as they appear after the plastron is removed. On the left side the muscles have been removed, exposing the ventral bones of the pectoral girdle. The medial tip of the acromion process of the scapula (4) and the tip of the coracoid (6) are joined by a sheet of connective tissue. The joint (5) between the pectoral girdle and the humerus (equivalent to the human shoulder) is partly exposed, along with the esophagus (1) and trachea (2). The boundary between pelvic (7) and pectoral muscles is shown by the dashed white line. This turtle has very little body fat (compare Fig. 12).

- | | | | |
|----|--------------------|----|--------------------|
| 1. | esophagus | 6. | coracoid |
| 2. | trachea | 7. | pelvic muscles |
| 3. | pectoral muscles | B. | lateral buttresses |
| 4. | acromion processes | | |
| 5. | shoulder socket | | |

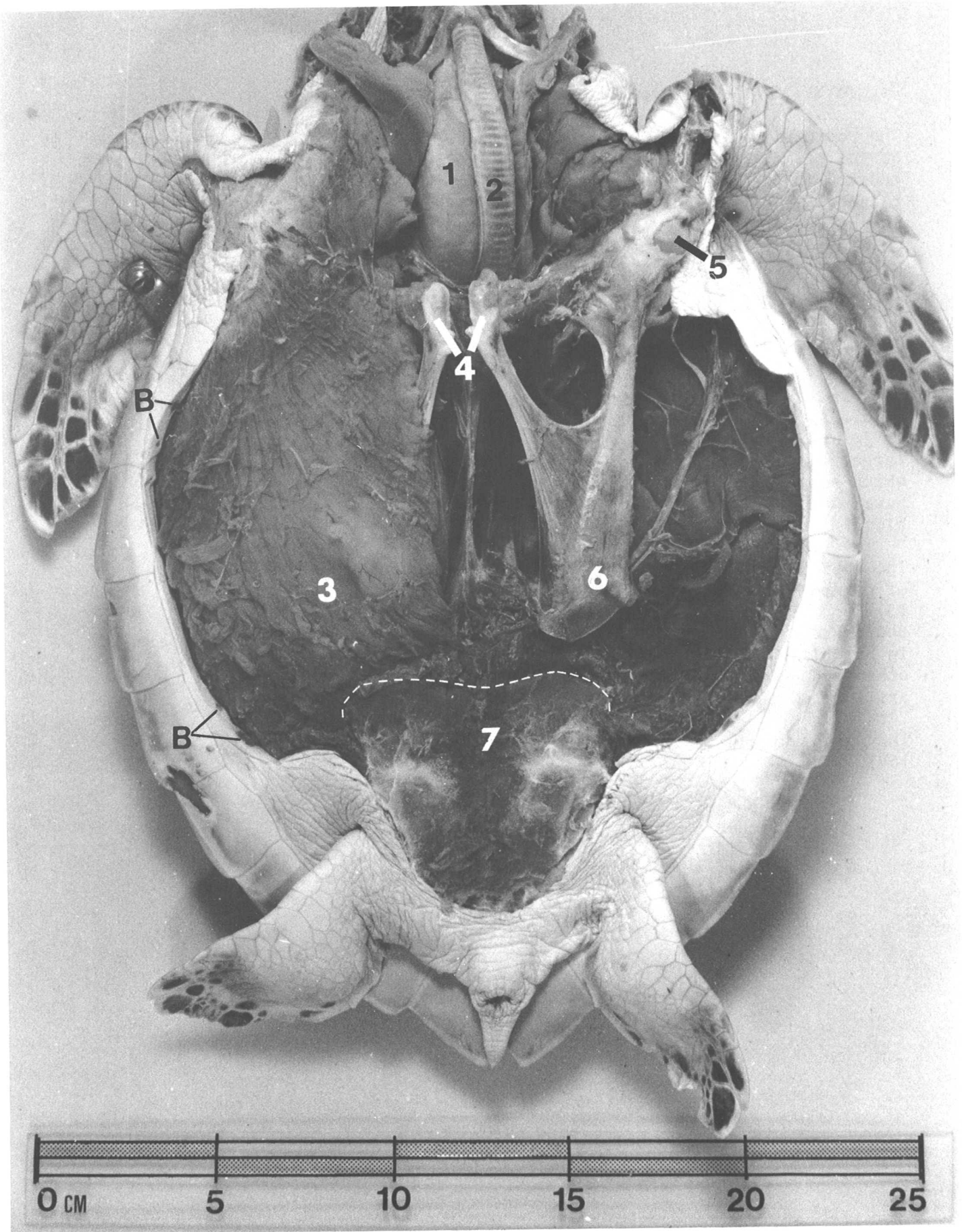


Figure 7.

Figure 8. C. mydas juvenile female.

The pectoral girdles have been pulled anteriorly and the ventral surface of the pericardial sac (see Fig. 12B) enclosing the heart has been removed to expose the heart chambers. At the base of the neck the trachea (2) divides to form two similar air conduits, the bronchi, which lead dorsally to the lungs. The leatherback differs from the cheloniid turtles in that the trachea is divided into two parallel air passages by a thin interior wall for some distance anterior to the separation of the bronchi. The right bronchus (7) can be seen just above the right atrium (6) of the heart. The smaller left atrium (8) is largely obscured (see Fig. 9).

Three major arteries emerge from the thick-walled ventricle (5). On the left is the pulmonary artery (9) running dorsally to the lungs. In the middle is the left aorta (10) which loops dorsally and posteriorly. It is joined near the vertebral column by the right aorta which is here largely obscured by its ventral branch, the brachiocephalic artery (11), which supplies blood to the head and shoulder regions. Sea turtles have sphincters on the pulmonary arteries which probably restrict blood flow to the lungs while submerged.

The thyroid gland (3) is a firm, round, translucent red body in a web of connective tissue just anterior to the major arteries (see Fig. 13, 26). The greyish-pink, lobular thymus glands (4) are lateral to the thyroid on each side (see Fig. 13, 26). The thymus gland is apparent in hatchlings and juveniles but is apparently absent in adults. Two other endocrine glands, the parathyroids and the ultimobranchial bodies are located near the thymus, but are very small and difficult to locate.

The esophagus (1) passes dorsal to the division of the bronchi (see Fig. 15B).

- | | | | |
|----|--------------|-----|------------------------|
| 1. | esophagus | 7. | right bronchus |
| 2. | trachea | 8. | left atrium |
| 3. | thyroid | 9. | pulmonary artery |
| 4. | thymus | 10. | left aorta |
| 5. | ventricle | 11. | brachiocephalic artery |
| 6. | right atrium | | |

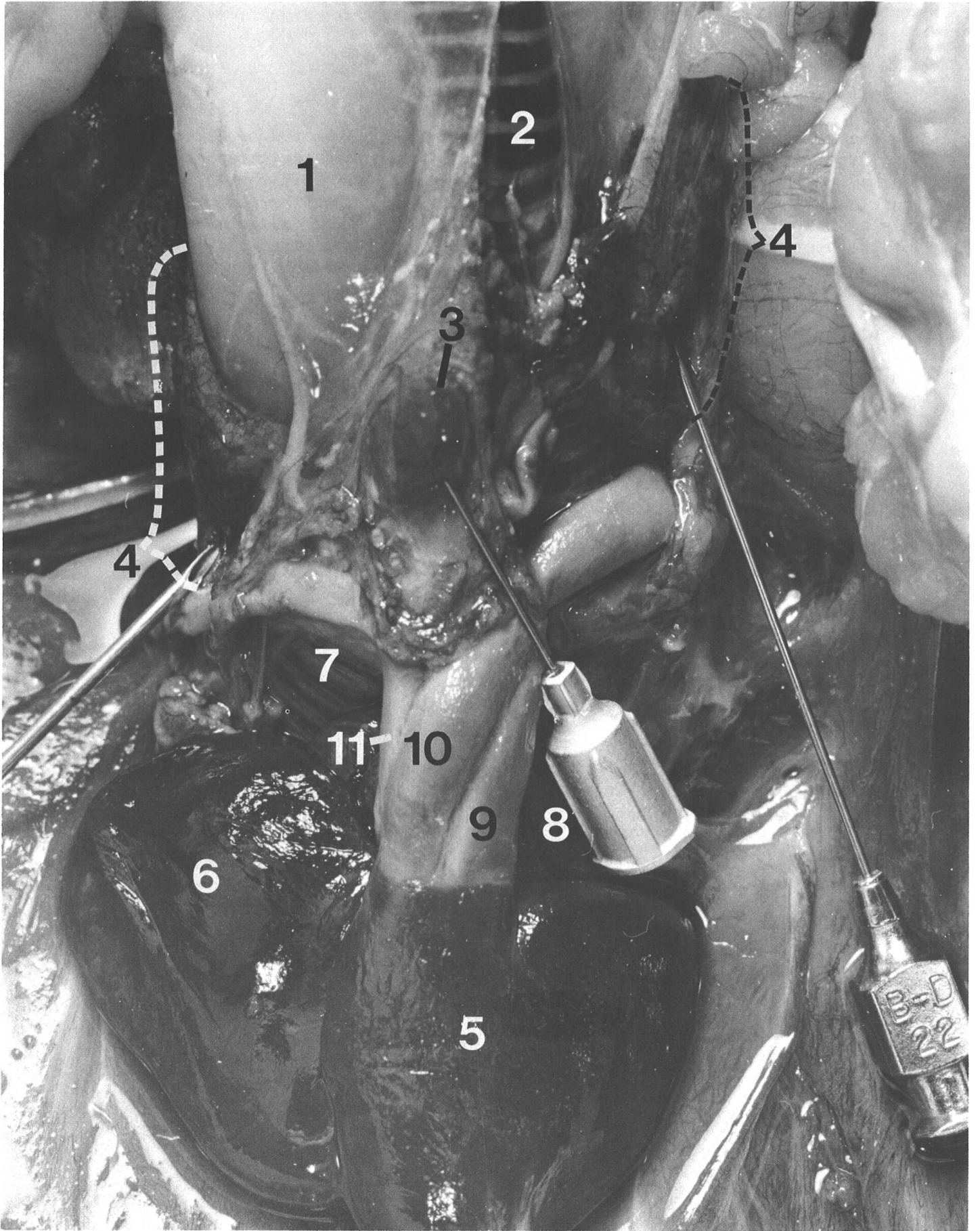


Figure 8.

Figure 9. C. mydas juvenile female.

On the right side the pectoral girdle and limb were removed together by first cutting the skin along the anterior margin of the carapace dorsal to the limb and severing the lateral attachments of the pectoral muscles along the carapace margins. Then, while lifting the posterior tip of the coracoid (Fig. 7) toward the head, the dorsal attachments of the pectoral muscles were cut at the surface of the carapace. Finally, the entire girdle was freed by cutting the cartilagenous attachment of the scapula to the carapace, near the base of the neck. An alternative procedure was used on the left side. The shoulder joint was disarticulated and the girdle removed leaving the limb in place. Removing the girdles may disturb the position of the major vessels of the heart and adjacent glands (Fig. 8), so it is best to examine them first.

The ventral peritoneum (9), a connective tissue sheet covering the body cavity (see Fig. 12), was cut anteriorly and pulled back to expose the digestive tract. The esophagus (1) extends dorsally into the body and turns left under the heart (3) to join the stomach (4, 5). The expanded, anterior portion of the stomach (4) continues posteriorly along the left margin of the body, narrows gradually, then turns back on itself (5) to join the small intestine (6). The tip of the hypodermic needle marks the pyloric valve separating the stomach and small intestine (see Fig. 18).

The left lobe (7) of the reddish-brown liver is closely attached to the inner curvature of the stomach. The larger right lobe (8) occupies much of the right half of the body cavity. The two lobes are connected by a narrow isthmus containing liver and connective tissue and the hepatic duct (see Fig. 16).

Posterior to the liver, the intestines are rather loosely suspended from the dorsal body wall by a transparent sheet of connective tissue, the mesentery (see Fig. 17). Consequently, the position and appearance of the intestines can change as the amount and position of food in it varies.

- | | | | |
|----|------------------|----|---------------------|
| 1. | esophagus | 6. | small intestine |
| 2. | trachea | 7. | left lobe of liver |
| 3. | heart | 8. | right lobe of liver |
| 4. | anterior stomach | 9. | peritoneum |
| 5. | pyloric stomach | | |

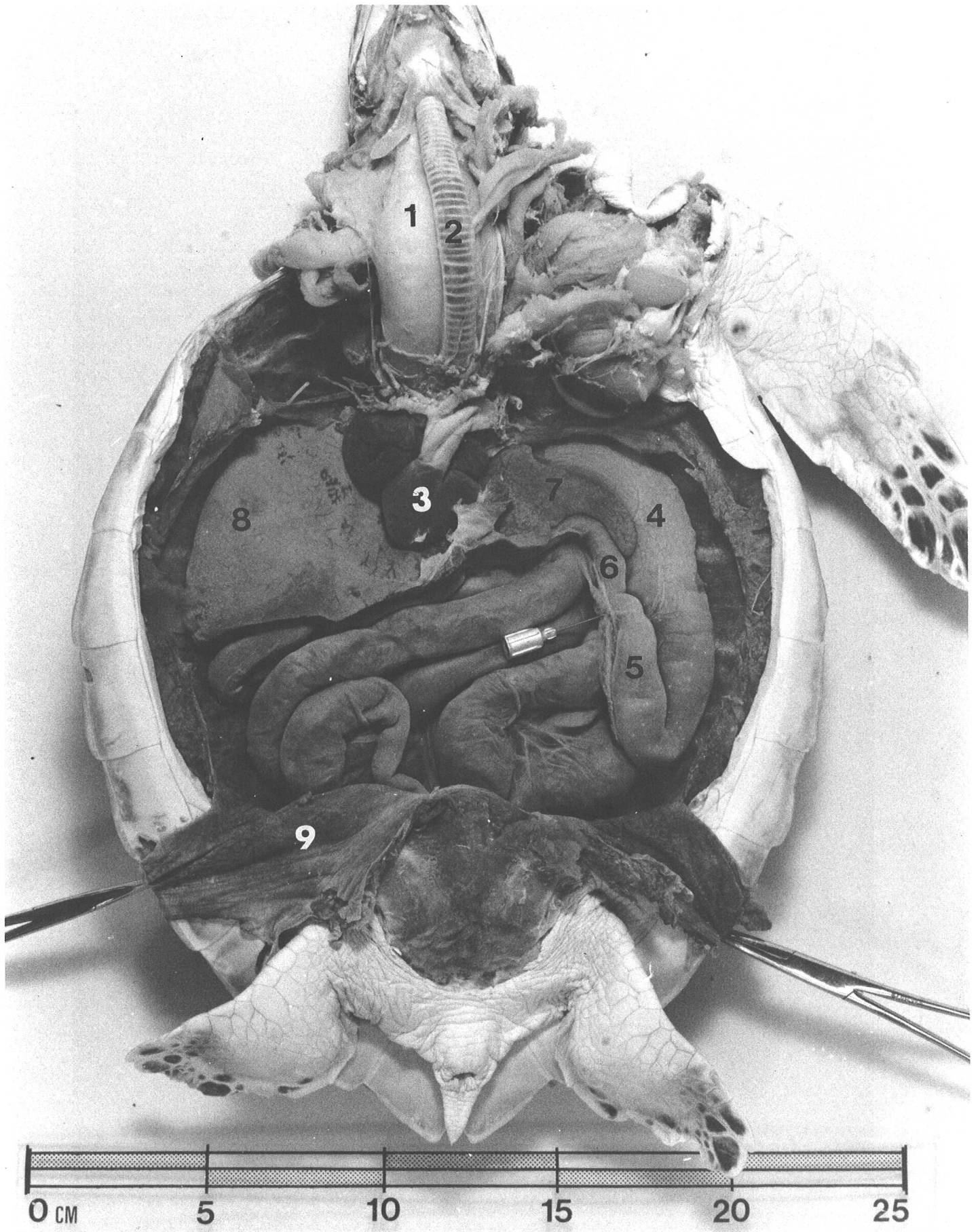


Figure 9.

Figure 10. C. mydas juvenile female.

The digestive tract has been pulled aside so that only the junction (2) between the stomach and esophagus and the posterior large intestine (8) are visible. The urinary bladder (9) rests ventral to the entry of the large intestine into the cloaca (see Fig. 23).

The dorsoventrally-flattened bronchi (1) enter the lungs (3, 4) near their anterior medial margins and continue posteriorly through the lung tissue giving off branches at right angles and gradually decreasing in diameter. The lungs are attached dorsally to the carapace lining over most of their area. In this juvenile both lungs have a small, free lateral margin that apparently is absent in larger individuals (see Fig. 20).

The paired ovaries (7) in this immature animal are inconspicuous, elongate, membranous structures attached to the dorsal peritoneum posterior to the lungs (and ventral to the kidneys, see Fig. 22). The paired, undeveloped oviducts (5, 6) are fine white tubes attached to the peritoneum by a transparent ribbon of connective tissue. The oviducts extend from small papillae (see Fig. 30, 31) inside the cloaca (posterior to position 5b) to near the anterior end of the lung (5a). The tip of the hypodermic needle rests on the oviduct. The free lateral margin of the right lung covers the adjacent oviduct (at 6), but the smaller left lung does not.

- | | | | |
|----|----------------------|----|---------------------------|
| 1. | bronchi | 6. | right oviduct |
| 2. | esophageal sphincter | 7. | ovaries |
| 3. | right lung | 8. | posterior large intestine |
| 4. | left lung | 9. | urinary bladder |
| 5. | left oviduct | | |

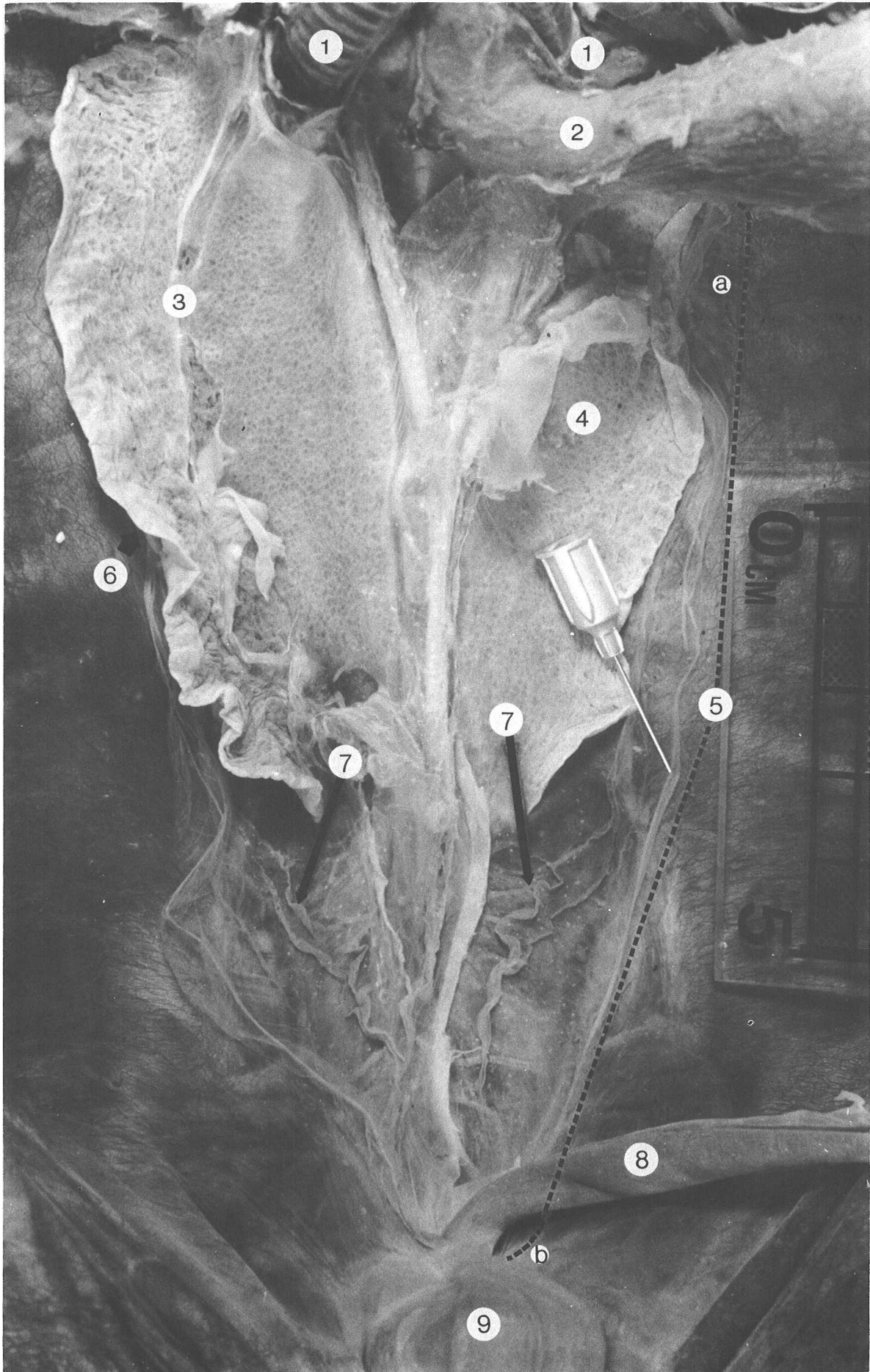


Figure 10.

Figure 11. Caretta caretta juvenile male.

A. The normal loggerhead pattern for carapace scutes differs from the green turtle (see Fig. 1) in having a small, additional costal scute (C1) anteriorly, so that there are five costals on each side. Kemp's ridley has the same dorsal scute pattern as the loggerhead, but the carapace scutes of the olive ridley are usually subdivided, producing higher counts (see Fig. 24).

The numerous white spots on the carapace are barnacles, largely Chelonibia testudinaria. These or other fouling organisms occur on all sea turtle species, but are particularly common on loggerheads.

B. The normal plastral scute pattern of the loggerhead differs from other cheloniids in having only three inframarginals (IF1 - IF3). Both axillary and inguinal Rathke's gland pores are present at least on young loggerheads, but the pores may be obscured by fouling organisms.

Ab.	abdominal scute	Int.	intergular scute
An.	anal scute	M1 - M12.	marginal scutes
C1 - C5.	costal scutes	N.	nuchal scute
F.	femoral scute	p.	Rathke's gland pore
G.	gular scute	Pe.	pectoral scute
H.	humeral scute	V1 - V5.	vertebral scutes
IF1 - IF3.	inframarginal scutes		


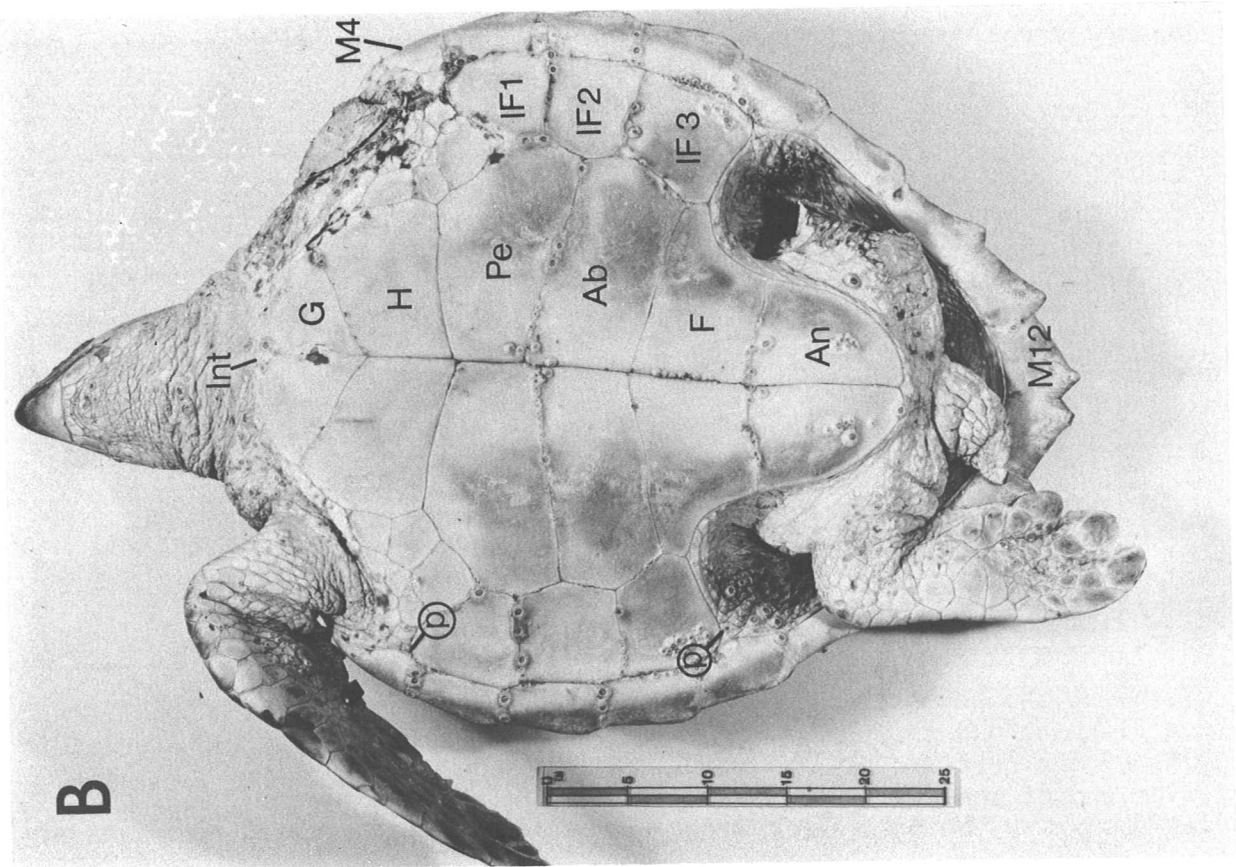


Figure 11.

Figure 12. C. caretta juvenile male.

A. With the plastron removed, the ventral pectoral (3) and pelvic (5) muscles are exposed along with large deposits of yellow-green fat (4) at the lateral margins of the body. The tips of the acromion processes (1) and the overlapping, cartilagenous tips of the coracoids (2) are visible near the body midline. The tip of the hemostat is inserted under the free margin of the right coracoid.

1. acromion processes
2. medial tip of coracoid
3. pectoral muscles
4. fat deposits
5. pelvic muscles

B. Removing the pectoral girdles exposes the ventral surface of both the pericardial sac and the peritoneum enclosing the body cavity. The lateral margins of the pericardial sac join the peritoneum (at 3). Near the anterior end of the heart are thin webs of connective tissue with fat bodies obscuring the position of the thyroid gland (near tip of 2). Lateral to the thyroid on each side are the thymus glands (1, see Fig. 13). Removal of the muscles also exposes more extensively the fat lining the lateral margins of the carapace (4, lateral to the dashed, black lines) and extending transversely across the body (5) on the peritoneum anterior to the pelvic muscles. Additional small fat deposits occur among pectoral muscle groups and along the sides of the neck.

1. thymus
2. fat in thyroid region
3. lateral junction of pericardial sac and peritoneum
4. fat lining carapace
5. fat on peritoneum

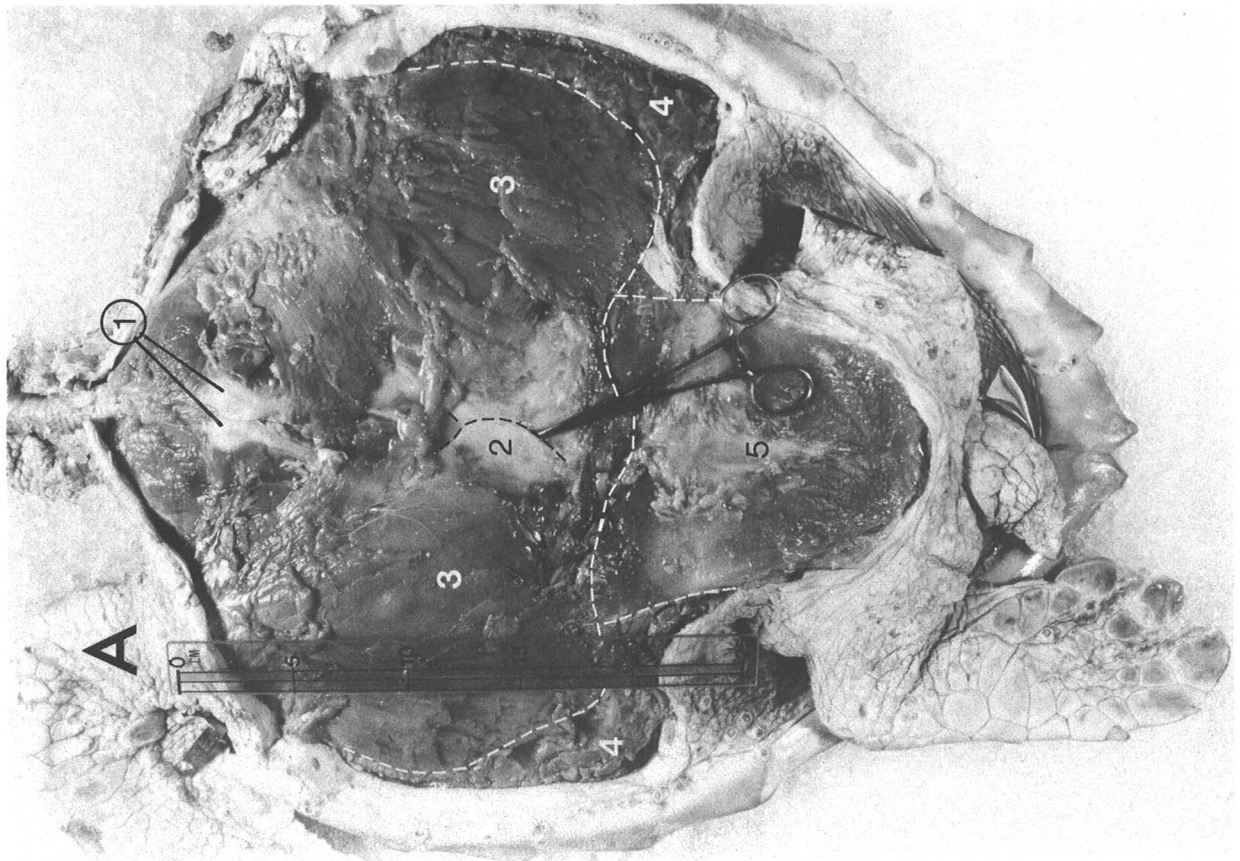
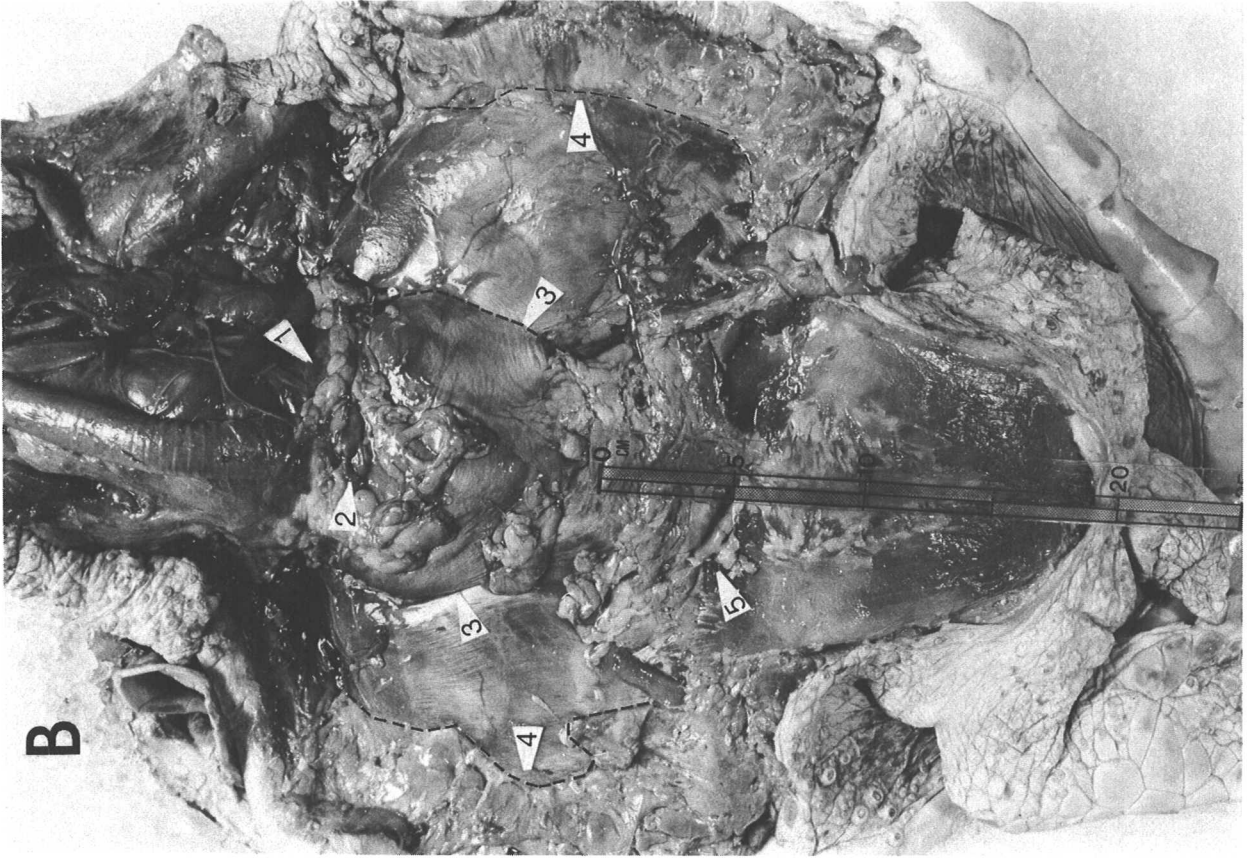

Figure 12.

Figure 13. C. caretta juvenile male.

A. The trachea (1), posterior hyoid horn (2), esophagus (3), and heart enclosed in the pericardial sac (6) delimit the position of the thyroid (4) and thymus glands (5), here outlined by white dashes. In fresh specimens the translucent red color of the thyroid is distinctive, but loose connective tissue with yellow fat bodies may cover it.

- | | | | |
|----|----------------------|----|-----------------|
| 1. | trachea | 4. | thyroid |
| 2. | posterior hyoid horn | 5. | thymus |
| 3. | esophagus | 6. | pericardial sac |

B. The pinkish-grey, lobular thymus (1) differs considerably in color and texture when fresh from the adjacent yellow, lobular fat (2) and the darker, green fat (3) which lines the carapace. The color distinctions fade when tissues decay or are exposed to air.

1. thymus
2. yellow fat bodies near heart
3. green fat lining lateral carapace


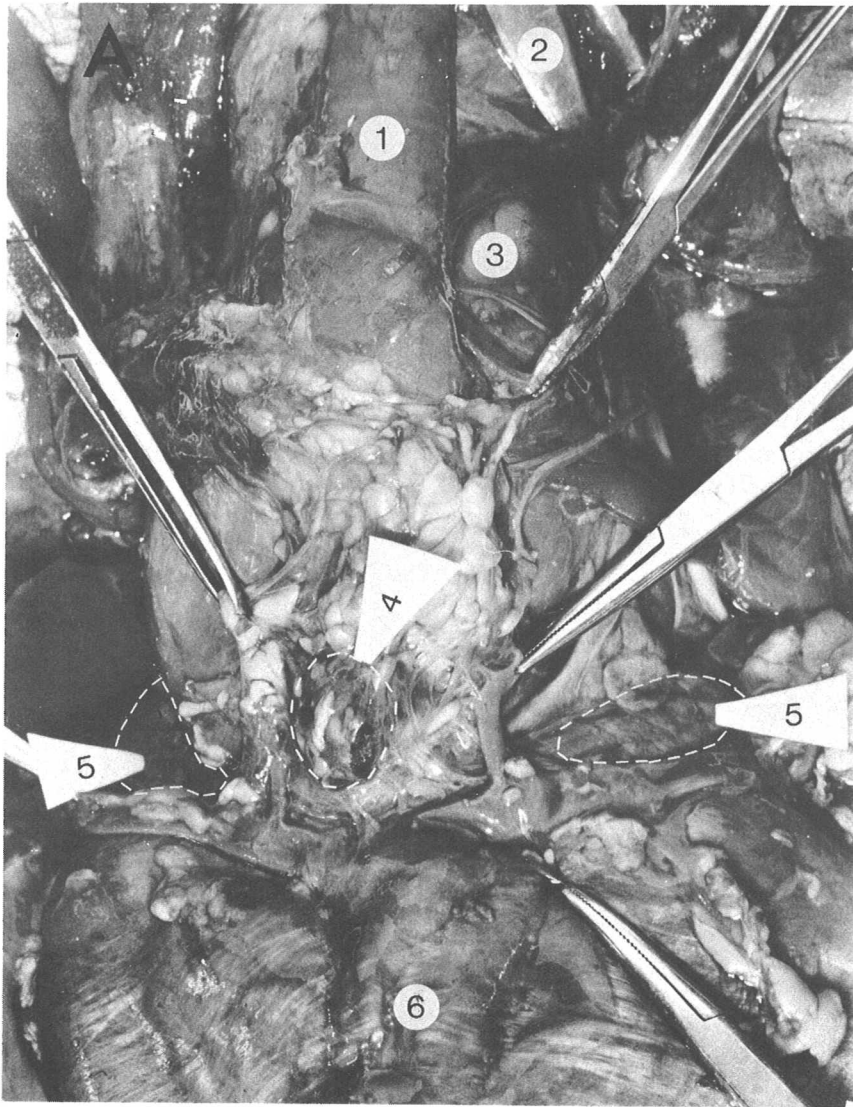


Figure 13.

Figure 14. C. caretta juvenile male. Open arrow on scale bar points anteriorly.

The duct (1) of the right axillary Rathke's gland extends from a pore on the plastral surface (Ax) through the cartilage of the bridge (path of duct marked by fine dashed line) to the body of the gland (2). The gland is lateral to the peritoneum enclosing the body cavity and is concealed in the layer of fat lining the margin of the shell. The fat has been dissected away from the anterior portion of the gland; the heavy dashed line indicates the shape of the gland under the remaining fat. In hatchlings the glands are more evident, both because they are relatively larger and because they are not obscured by fat (see Fig. 25).

1. duct of Rathke's gland
2. body of gland
- Ax. axillary surface of plastron

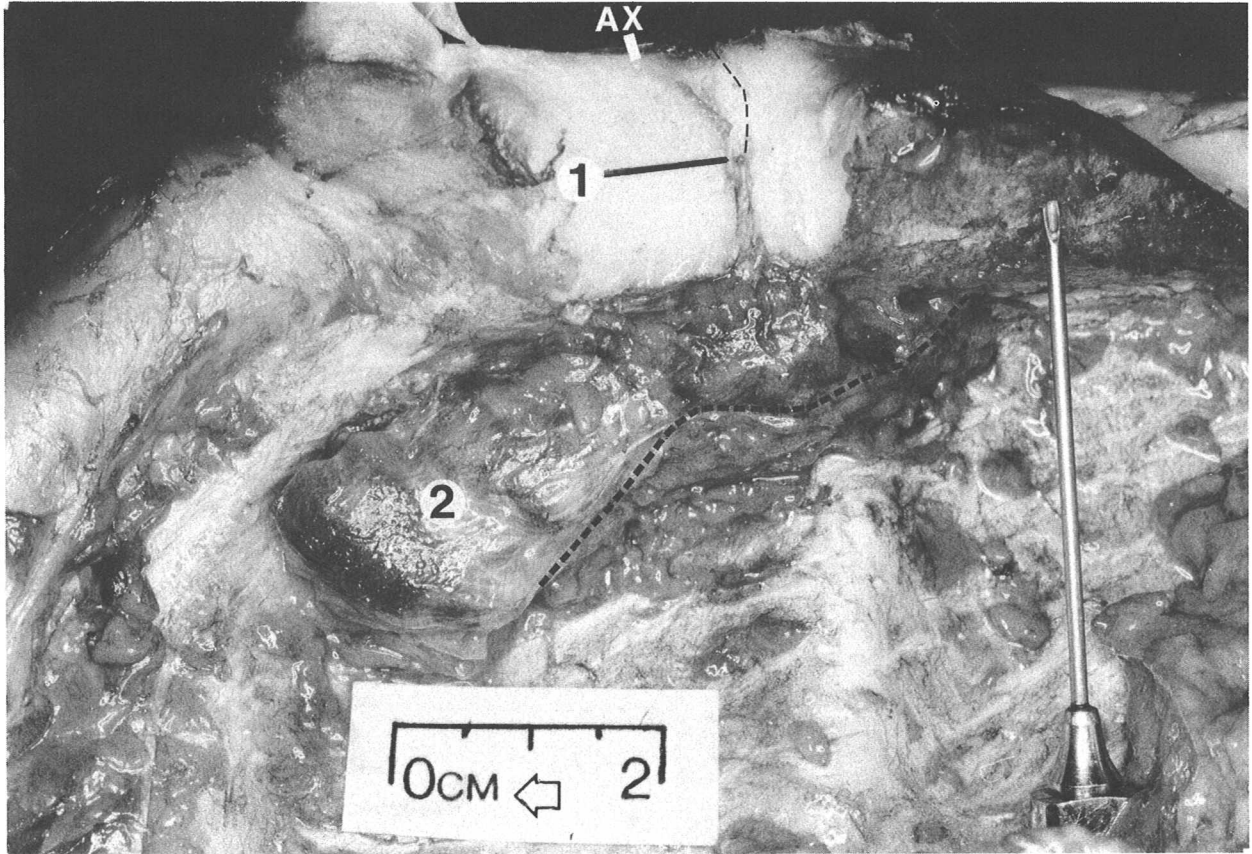


Figure 14.

Figure 15. C. caretta juvenile male. Open arrow on scale bar points anteriorly.

A. The ventral pericardial sac and peritoneum are removed exposing the left (1) and right (2) atria and ventricle (3) of the heart, the stomach (4), liver (5) and intestines (6). One hemostat (marked A) touches the connective tissue cord joining the posterior tip of the ventricle to the pericardial sac. The dorsal surface of the pericardial sac is largely fused with the connective tissue encapsulating the liver; the major trunk veins pass through the anterior edge of the liver.

- | | | | |
|----|--------------|----|------------|
| 1. | left atrium | 4. | stomach |
| 2. | right atrium | 5. | liver |
| 3. | ventricle | 6. | intestines |

B. The esophagus (2) passes dorsal to the right bronchus (1), turns left, and constricts at its junction with the stomach (3). The junction is obscured here by the left anterior tip of the liver (5) which crosses the gut and is attached dorsally to the left lung (see same area in Fig. 15A). Most of the lateral margin of the left lobe of the liver is joined to the stomach by mesentery (4).

- | | | | |
|----|----------------|----|--------------------|
| 1. | right bronchus | 4. | mesentery |
| 2. | esophagus | 5. | left lobe of liver |
| 3. | stomach | | |

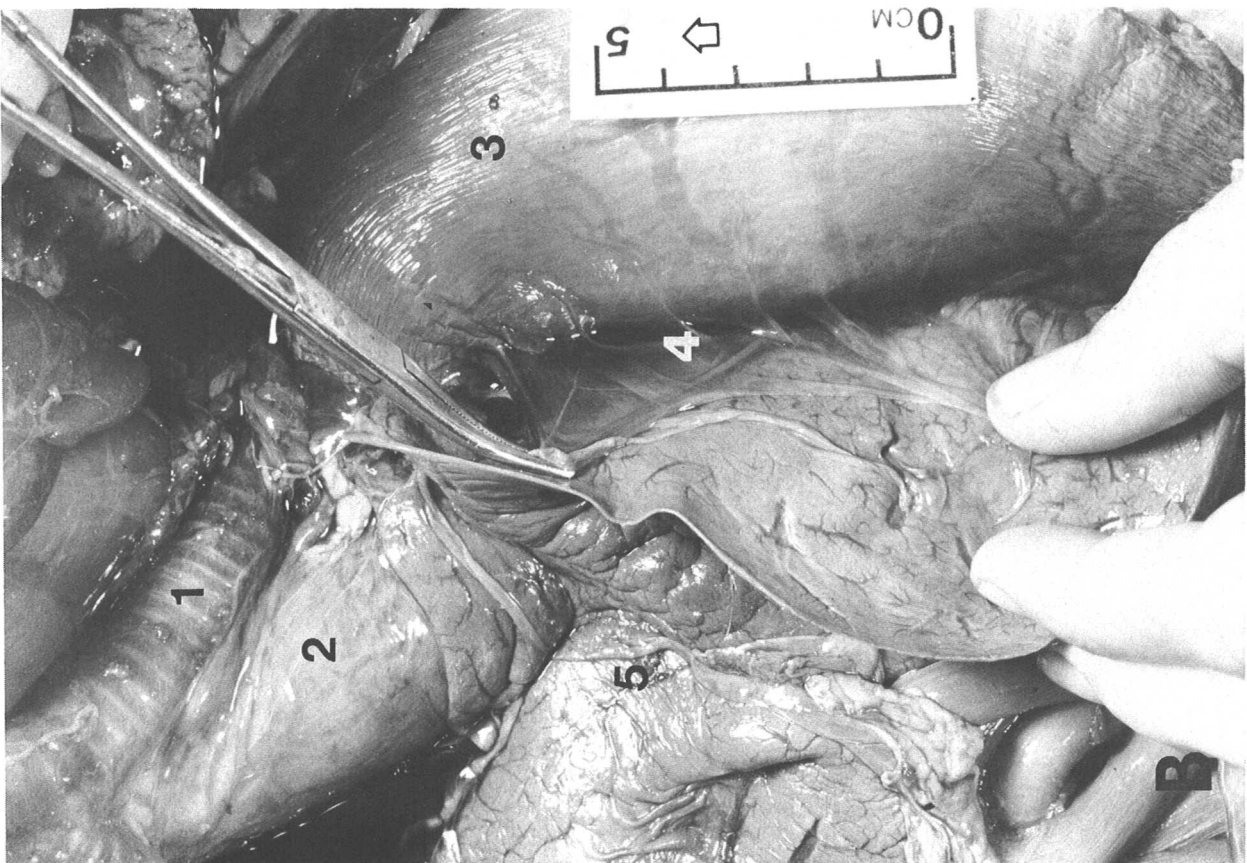
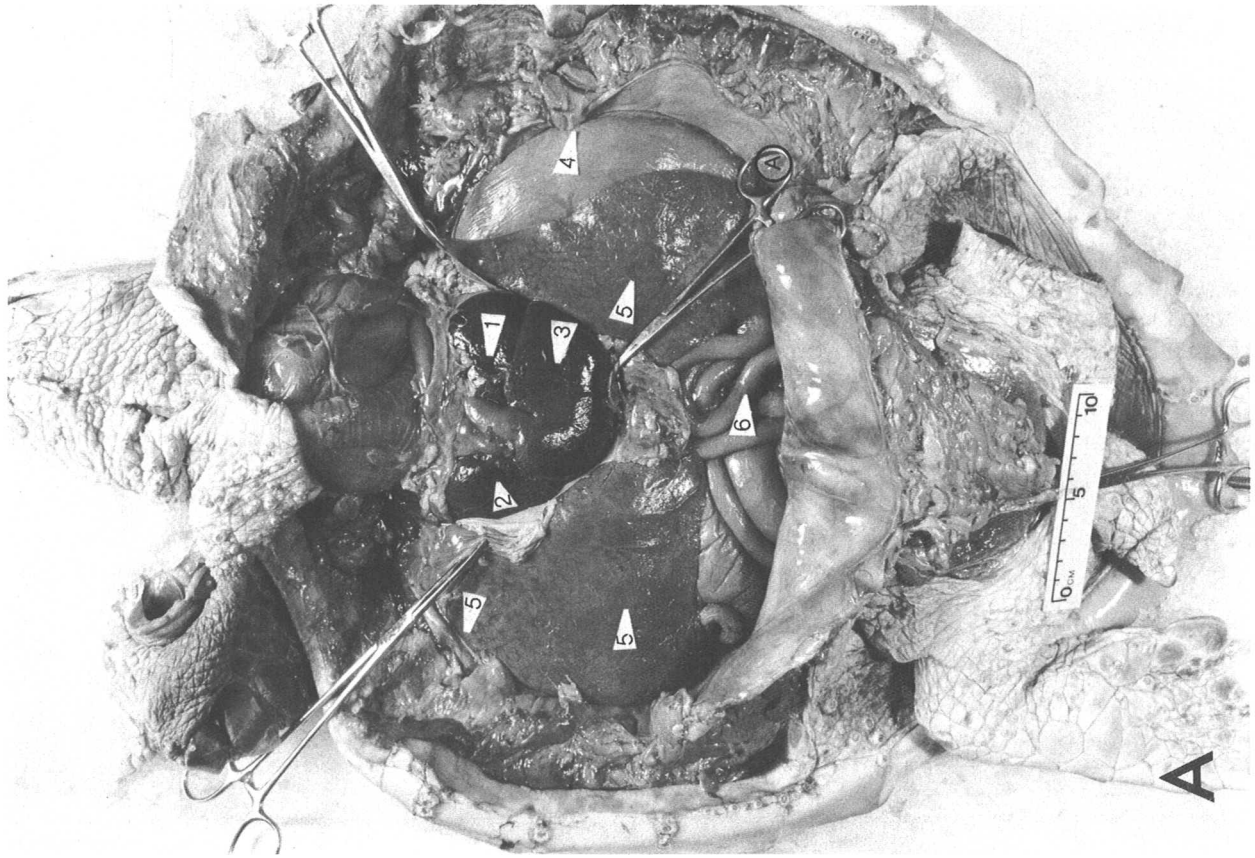


Figure 15.

Figure 16. C. caretta juvenile male. Open arrow points anteriorly.

A. The posterior margin of the liver (2) is pulled anteriorly to expose the gall bladder (1, outlined in white dashes) on the posterior face of the right lobe. The gall bladder may either be largely embedded in the liver (as in the green turtle, loggerhead and Kemp's ridley) or partially free (as in the hawksbill). A very short cystic duct from the gall bladder joins the hepatic duct from the left lobe to form a common bile duct which enters the wall of the small intestine (4). In the loggerhead this duct is also short and discharges bile into the intestine adjacent to the gall bladder, but in the leatherback the duct continues posteriorly along the intestine for some distance.

The position of the rest of the intestines (5) has not been disturbed.

1. gall bladder
2. liver
3. stomach
4. anterior small intestine
5. intestine

B. The stomach (1) has been partially cut free dorsally from the left lung (8) and both the stomach and small intestine are pulled anteriorly to expose the junction between them (2). In this species there is no distinct valve at the pylorus (see Fig. 18, 19). The pancreas (3, outlined by dashed black line) is an irregular band of off-white glandular tissue running along the small intestine on the mesentery. In cheloniids the pancreas extends from the vicinity of the pylorus to the region of the gall bladder (5). In hatchling leatherbacks it does not extend much anterior to the bile duct.

A lobe of the pancreas extends onto the intestinal mesentery (7) and approaches or surrounds the spleen (6), a compact, rounded, dark-red organ (see Fig. 27). Ribbons of yellow fat may parallel blood vessels in the sheets of mesentery. A duct or ducts from the pancreas drain into the anterior small intestine.

- | | |
|------------------------|-------------------------|
| 1. stomach | 5. gall bladder |
| 2. pylorus | 6. spleen |
| 3. pancreas | 7. intestinal mesentery |
| 4. right lobe of liver | 8. left lung |

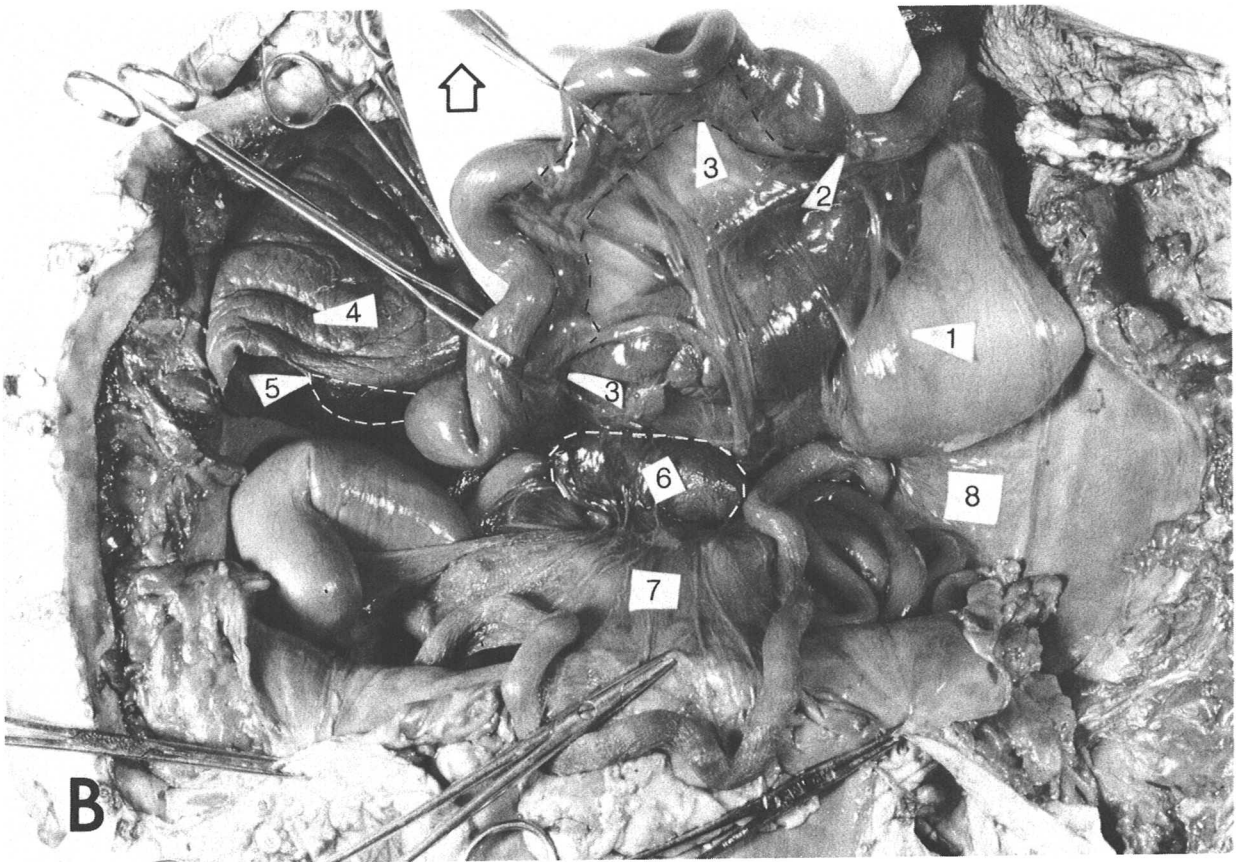
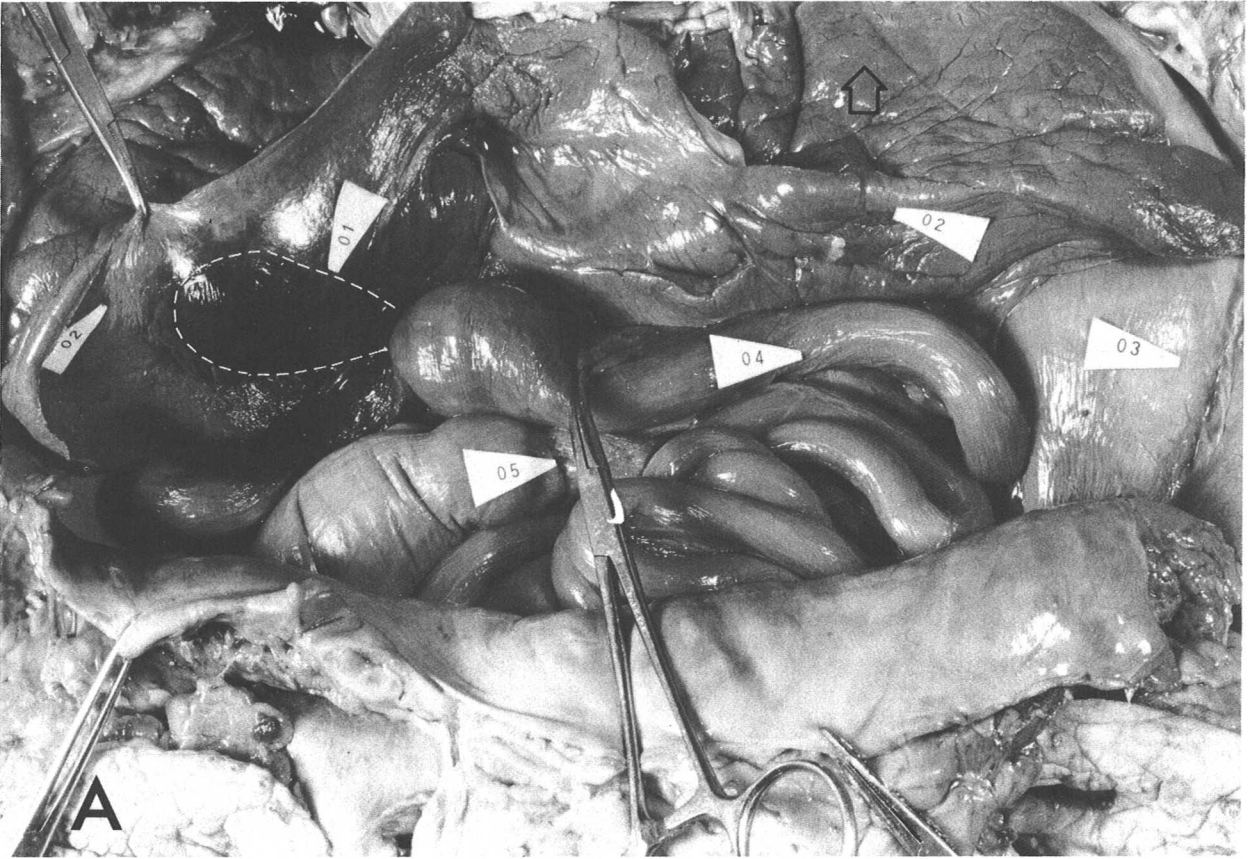


Figure 16.

Figure 17. C. caretta juvenile male.

White arrows show the path of food through the digestive tract, here dissected out leaving the intestinal mesenteries largely intact. Food passes from the esophagus (1) to the stomach (2) and from there into the small intestine (3) at the pylorus (P). The posterior margins of the left (4) and right (5) lobes of the liver are closely attached to the small intestine from near the pylorus to the vicinity of the gall bladder (7). The pancreas (6) is a relatively inconspicuous band of tissue which darkens quickly on exposure and may be difficult to identify. The spleen (8, not part of the digestive system) is located at the base of the intestinal mesentery in cheloniids, but may be on the mesentery close to the intestine in the leatherback.

In cheloniid turtles the small intestine has relatively constant diameter throughout its length, except where temporarily distended by a food mass. A short portion of the leatherback small intestine just posterior to the pyloric valve is permanently expanded into a pouch.

The small intestine is typically separated from the large intestine (9) by a muscular ileocecal valve (I), but its development varies among species. In the loggerhead the valve is only a slight, irregular thickening of the muscular wall of the gut. The leatherback small intestine discharges through a distinct valve into the much larger diameter anterior large intestine. Apparently only in the leatherback, there is a small, lateral pouch, the caecum, extending from the large intestine wall near the valve. A short segment of the green turtle large intestine adjacent to the ileocecal valve is dilated into a fermentation chamber which is sometimes also referred to as a caecum.

The posterior end of the gut (10) was cut off inside the body cavity close to the junction with the cloaca (see Fig. 23).

- | | | | |
|----|---------------------|-----|-----------------|
| 1. | esophagus | 7. | gall bladder |
| 2. | stomach | 8. | spleen |
| 3. | small intestine | 9. | large intestine |
| 4. | left lobe of liver | 10. | cut end of gut |
| 5. | right lobe of liver | I. | ileocecal valve |
| 6. | pancreas | P. | pylorus |

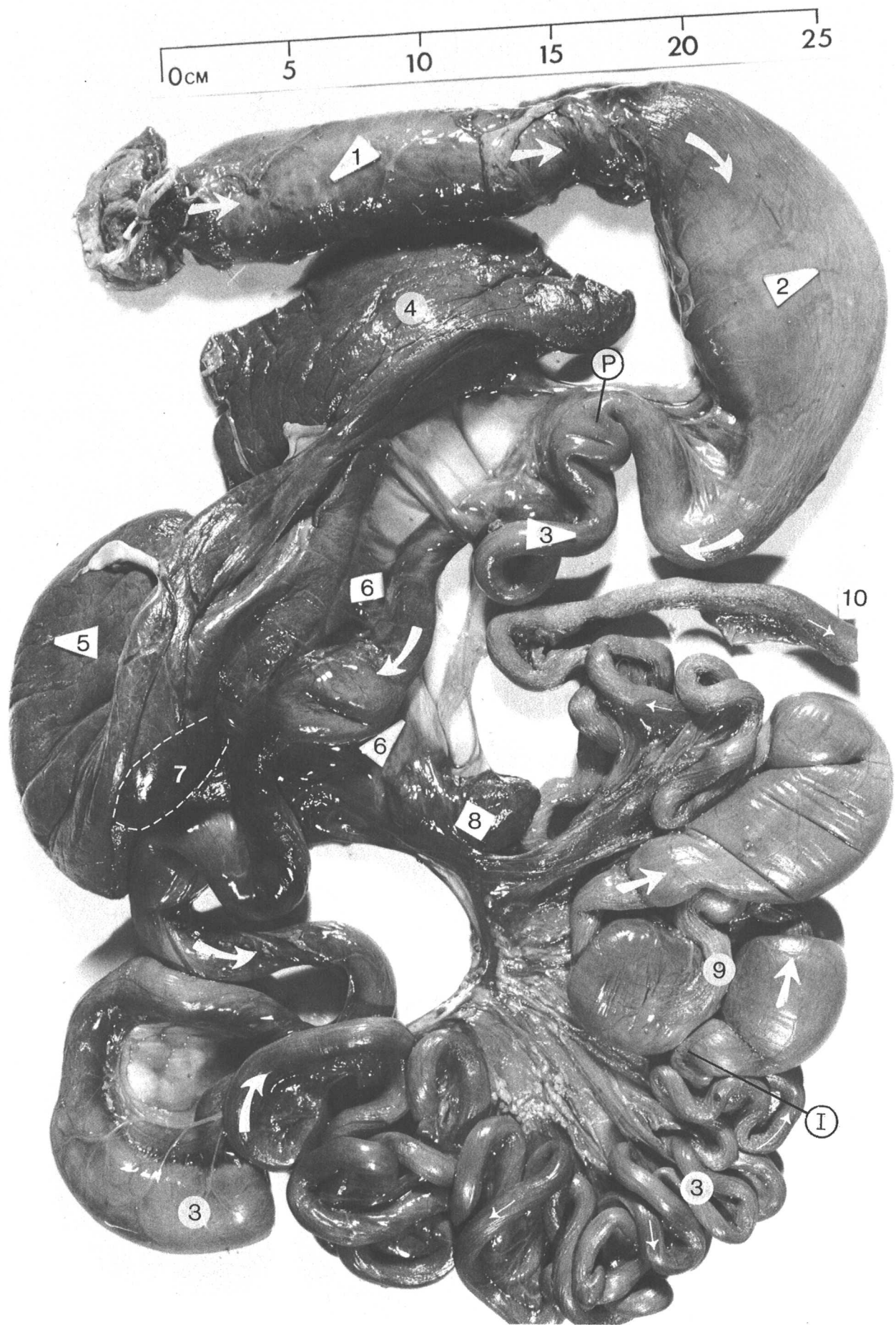

Figure 17.

Figure 18. C. caretta juvenile male.

The internal surface of the digestive tract is shown here with enlarged views of some segments in Figure 19. The esophagus (1) of all species is lined with sharply-pointed, posteriorly-directed papillae. In chelonids the papillae usually have a single point, but some papillae in the leatherback have multiple tips.

Anteriorly, the stomach (2) is an expanded, thick-walled sac with a smooth lining. The stomach narrows and its muscular wall thins posteriorly. In the loggerhead there is no obvious muscular valve at the pylorus (P) separating the stomach and small intestine (3). However, there is a distinct change in texture from the broad longitudinal folds of the stomach to a 'net' created by many, fine zigzag folds in the intestine. The folds gradually straighten posteriorly and the net pattern is lost. The transition to a pattern of fewer, more distinct longitudinal ridges in the large intestine (6) is also gradual, but the indistinct muscular valve (I) separating the intestines is marked internally by irregularities in the longitudinal pattern.

Where the large intestine is distended by masses of food (B), the wall stretches and the internal texture disappears. In the small intestine similar stretching does not obliterate the pattern.

- | | | | |
|----|-----------------|----|-----------------|
| 1. | esophagus | 5. | gall bladder |
| 2. | stomach | 6. | large intestine |
| 3. | small intestine | I. | ileocecal valve |
| 4. | pancreas | P. | pylorus |

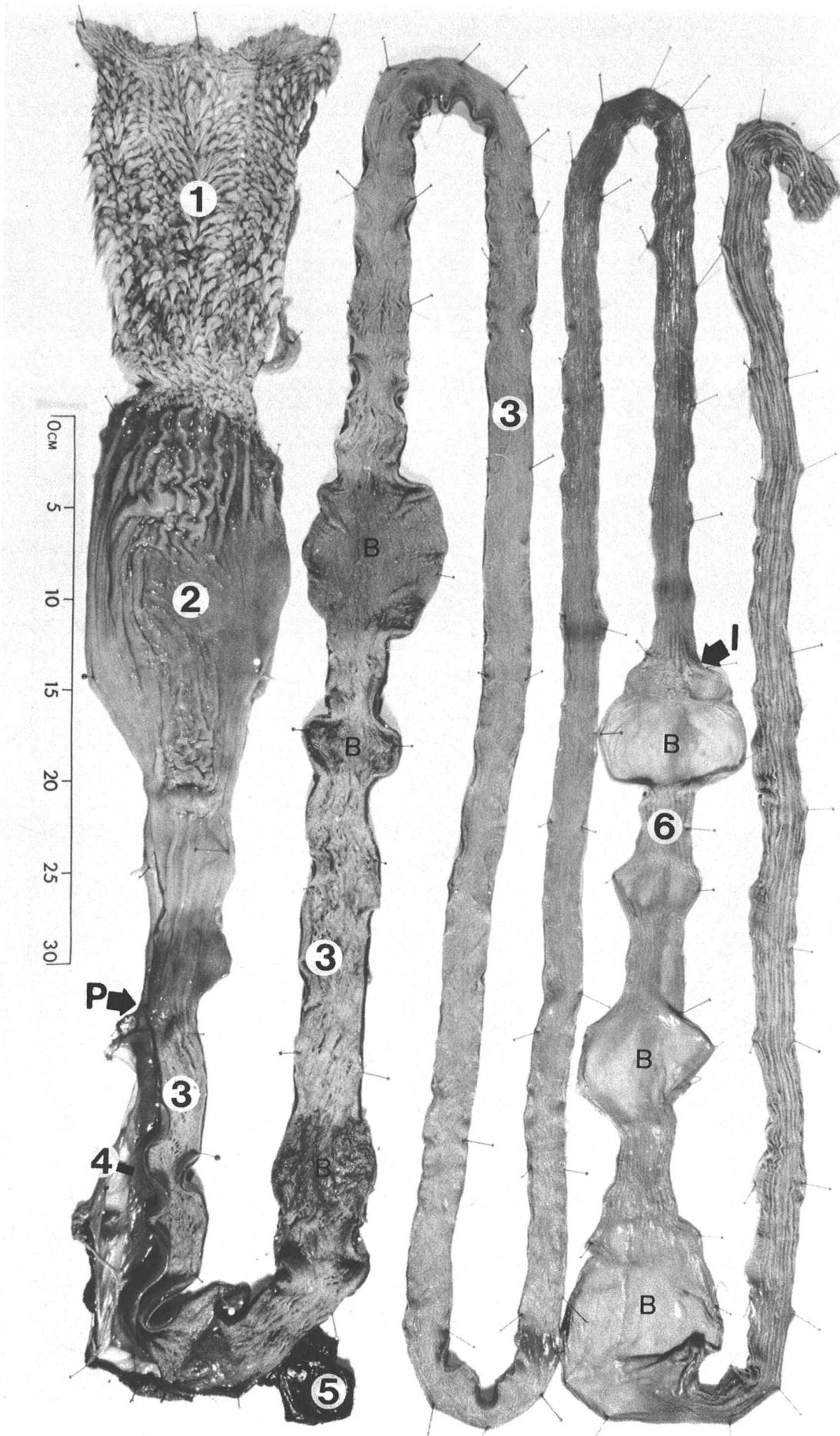


Figure 18.

Figure 19. C. caretta juvenile male. Approximately two times life size.

Posteriorly, the sharply-pointed papillae which line most of the esophagus (1) are replaced by a wrinkled, longitudinally folded surface which is, in turn, replaced by a narrower band of smaller, more rounded papillae, only some of which bear spines at the tips. There is an abrupt transition to the smooth, low folds of the stomach mucosa (2).

The smooth surface of the pyloric region of the stomach (3) appears to grade rapidly into the net-like pattern of zigzag, longitudinal folds of the anterior small intestine (4). The posterior small intestine (5) has many, fine, straight, longitudinal folds. The gross appearance of the large intestine (6) is dominated by a few, large, longitudinal folds.

- | | | | |
|----|------------------|----|---------------------------|
| 1. | esophagus | 4. | anterior small intestine |
| 2. | anterior stomach | 5. | posterior small intestine |
| 3. | pyloric stomach | 6. | posterior large intestine |


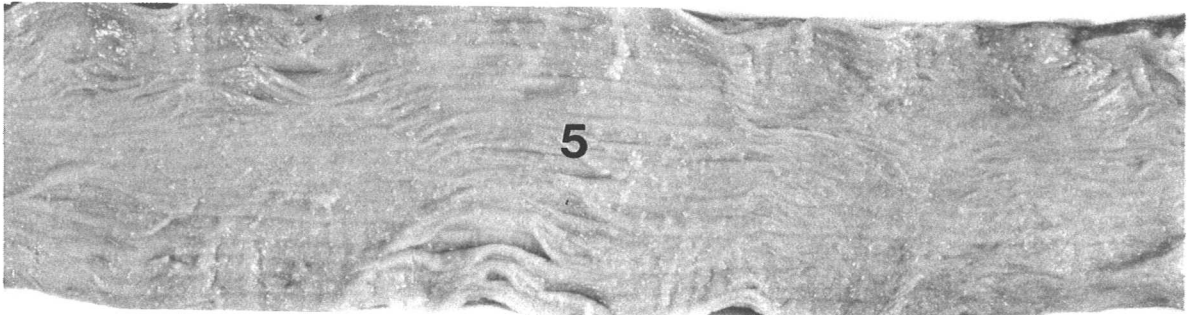
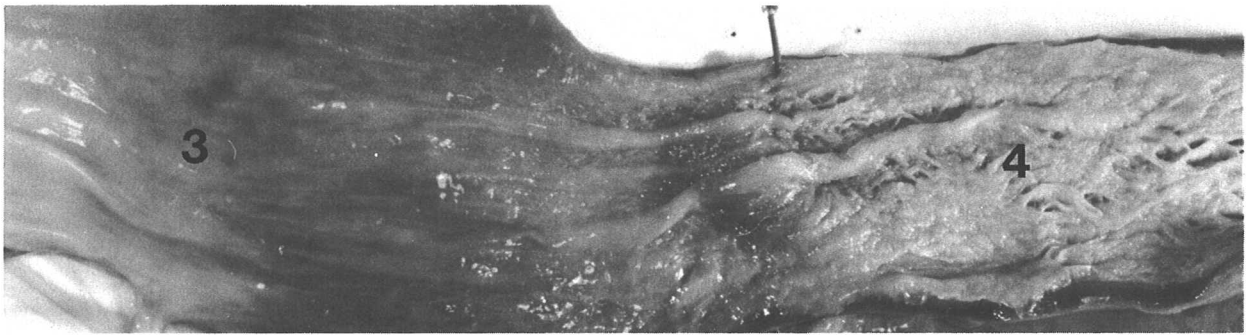
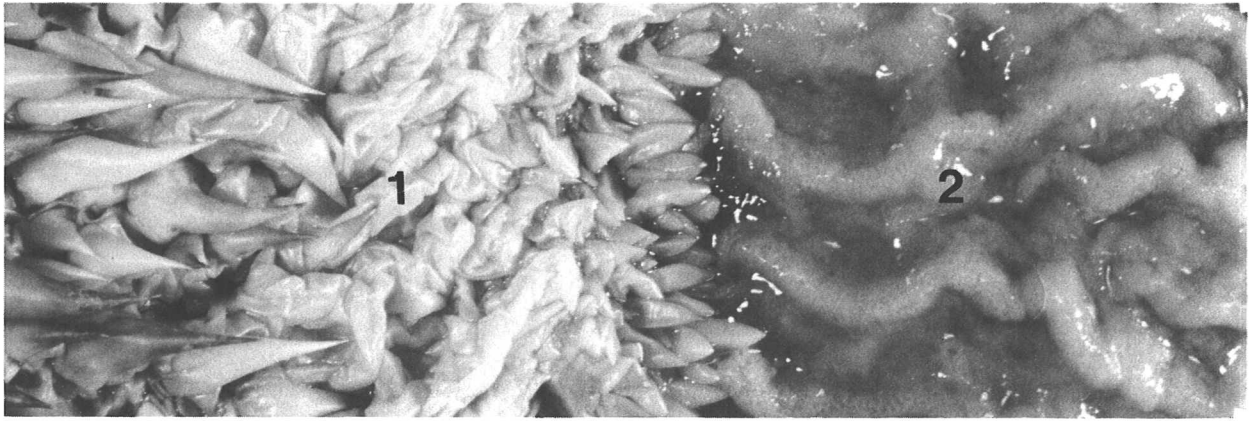


Figure 19.

Figure 20. C. caretta juvenile male.

A. If the liver is cut free from the stomach (2) and from its dorsal attachment to the right lung (4), the digestive tract can be left largely attached and be pulled to the left (in fresh specimens) to examine the right gonad (6, an immature testis) posterior to the lung. Lateral to the gonad and running anteriorly along the lateral margin of the lung is a thin ribbon of connective tissue carrying the rudimentary oviduct (5). The oviduct is present at hatching in both sexes and develops extensively in females as they mature (see Fig. 10, 30). In males, where it lacks any apparent function, it is commonly retained, but is poorly developed.

The medial margin of the right lung adjacent to the vertebrae is marked by a black dashed line. The position of the esophagus (1), stomach, and spleen (3) have not been disturbed.

- | | | | |
|----|-----------|----|---------|
| 1. | esophagus | 4. | lung |
| 2. | stomach | 5. | oviduct |
| 3. | spleen | 6. | testis |

B. The digestive tract has been removed and the lungs (2) have been inflated with air introduced through the trachea and bronchi (1). The lungs cover much of the medial lining of the carapace, extending from the base of the neck to the anterior tips of the kidneys (see Fig. 22). In this specimen, there is no free margin to the lungs as seen in the juvenile green turtle (Fig. 10). Immediately lateral to the paired, yellowish testes (tip of 4 on the left testis) are the reddish epididymides (tip of 6 on the right epididymis). The urinary bladder (5) is a single, medial sac attached to the ventral surface of the cloaca. The pelvis and associated muscles (7) obscure the cloaca.

- | | | | |
|----|----------------|----|------------------|
| 1. | right bronchus | 5. | urinary bladder |
| 2. | lung | 6. | right epididymis |
| 3. | left oviduct | 7. | pelvic muscles |
| 4. | left testis | | |

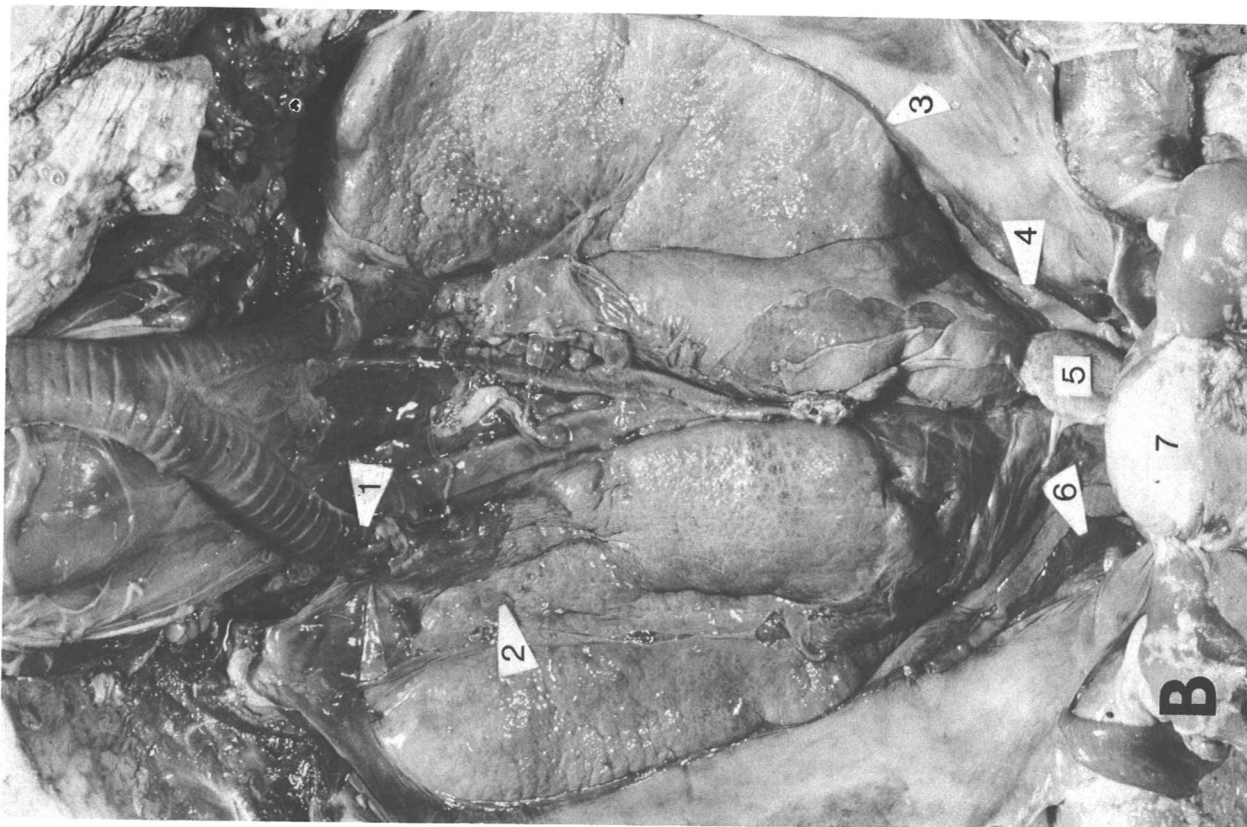


Figure 20.

Figure 21. C. caretta juvenile male.

A. The ventral bones of the pelvis (3) have been stripped of muscle, exposing part of the head of the femur in the hip joint (4). The anterior tips of the testes (1) extend slightly beyond the pelvis and the posterior tips of the kidneys (2) can be seen lateral to the pelvis. The paired kidneys lie immediately lateral to the vertebral column, outside the body cavity between the dorsal peritoneum and the carapace lining.

The posterior large intestine (not visible) and the cloaca (5) pass dorsal to the pelvis through the arch formed by the bones attaching the pelvis to the carapace. In this immature male (and all age females) the anus (6) lies near the carapace margin. In a mature male the tail is much enlarged and longer so that the anus is in line with the posterior tips of the rear limbs when they are extended alongside the tail.

- | | | | |
|----|-------------|----|-----------|
| 1. | left testis | 4. | hip joint |
| 2. | kidneys | 5. | cloaca |
| 3. | pelvis | 6. | anus |

B. Having removed the pelvis by detaching it at the carapace, the relations of the rudimentary oviduct (1), testis (2), epididymis (3), posterior large intestine (4, cut off just above cloaca) and bladder (6) to the cloaca (5) can be seen more clearly. Feces, urine, and gonadal products all pass out of the body through the cloaca and anus.

When the pelvis need not be kept intact for skeletal preparation, it is easier to obtain access to the cloaca by cutting the pelvis along its ventral midline with a saw. Skinning the ventral surface of the tail and carefully freeing the posterior cloaca makes it possible to remove the entire urogenital system intact.

- | | | | |
|----|-----------------|----|-----------------|
| 1. | oviduct | 5. | cloaca |
| 2. | testis | 6. | urinary bladder |
| 3. | epididymis | 7. | anus |
| 4. | large intestine | | |

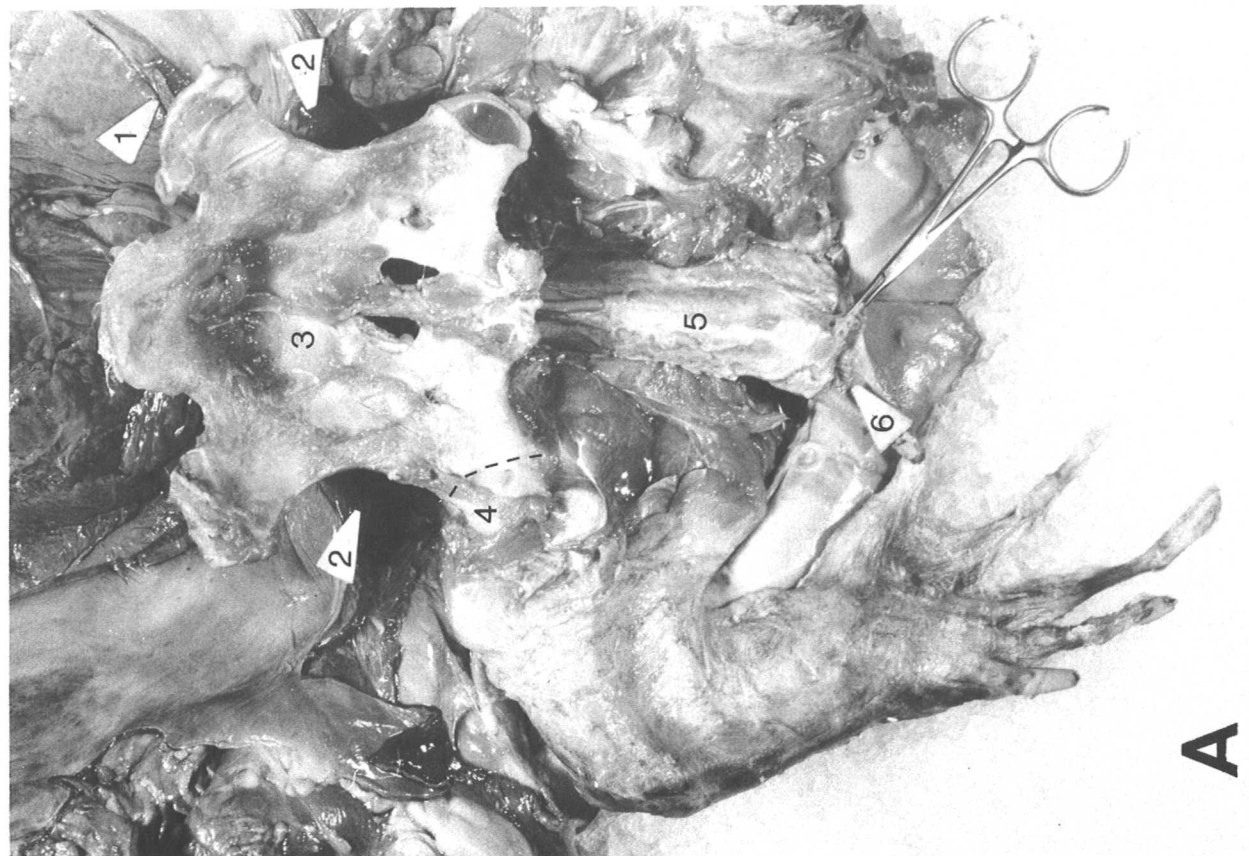
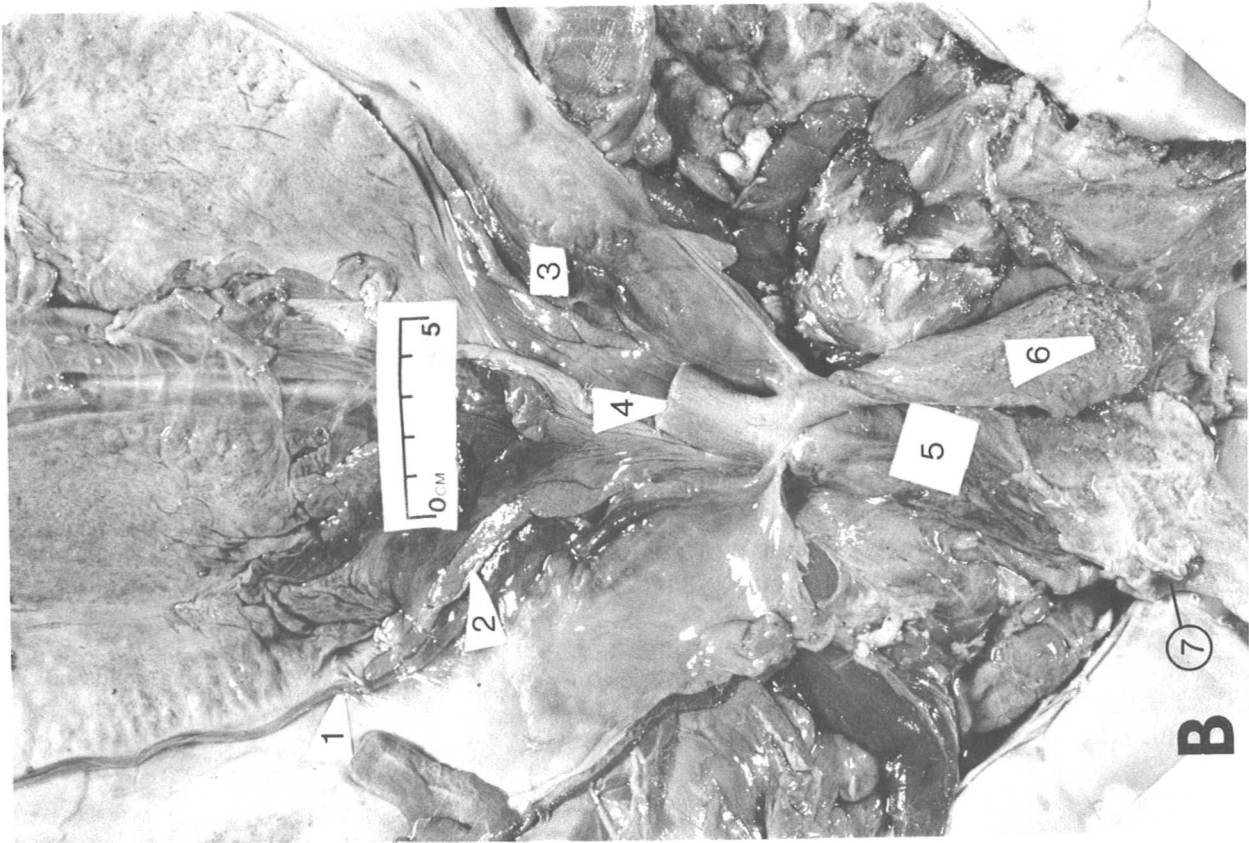

Figure 21.

Figure 22. C. caretta juvenile male. Open arrow on scale bar points anteriorly.

Immediately posterior to the tip of the right lung (5) is the kidney (1). The translucent white connective tissue of the dorsal peritoneum has been stripped off the posterior end of the kidney exposing its dark-red, lobular tissue. The immature testis (at tip of 3) and laterally adjacent epididymis (posterior end at tip of 2) are closely attached to the peritoneum covering the kidney (compare Fig. 32). The rudimentary oviduct (at tip of 4), a flattened, white tube, extends anteriorly along the lateral margin of the lung, but is often not continuous near the testis in males.

On each kidney an inconspicuous adrenal gland (tip of 6) is located medial to the gonad. It is cut open to show the pale, yellowish-white glandular tissue in the connective tissue capsule (one report indicates that the loggerhead adrenal is at least sometimes continuous across the body midline). In hatchlings the adrenal is a more obvious, but less discrete mass of light-colored tissue near the body midline on the anterior ventral surface of the kidneys.

- | | | | |
|----|------------|----|---------|
| 1. | kidney | 4. | oviduct |
| 2. | epididymis | 5. | lung |
| 3. | testis | 6. | adrenal |

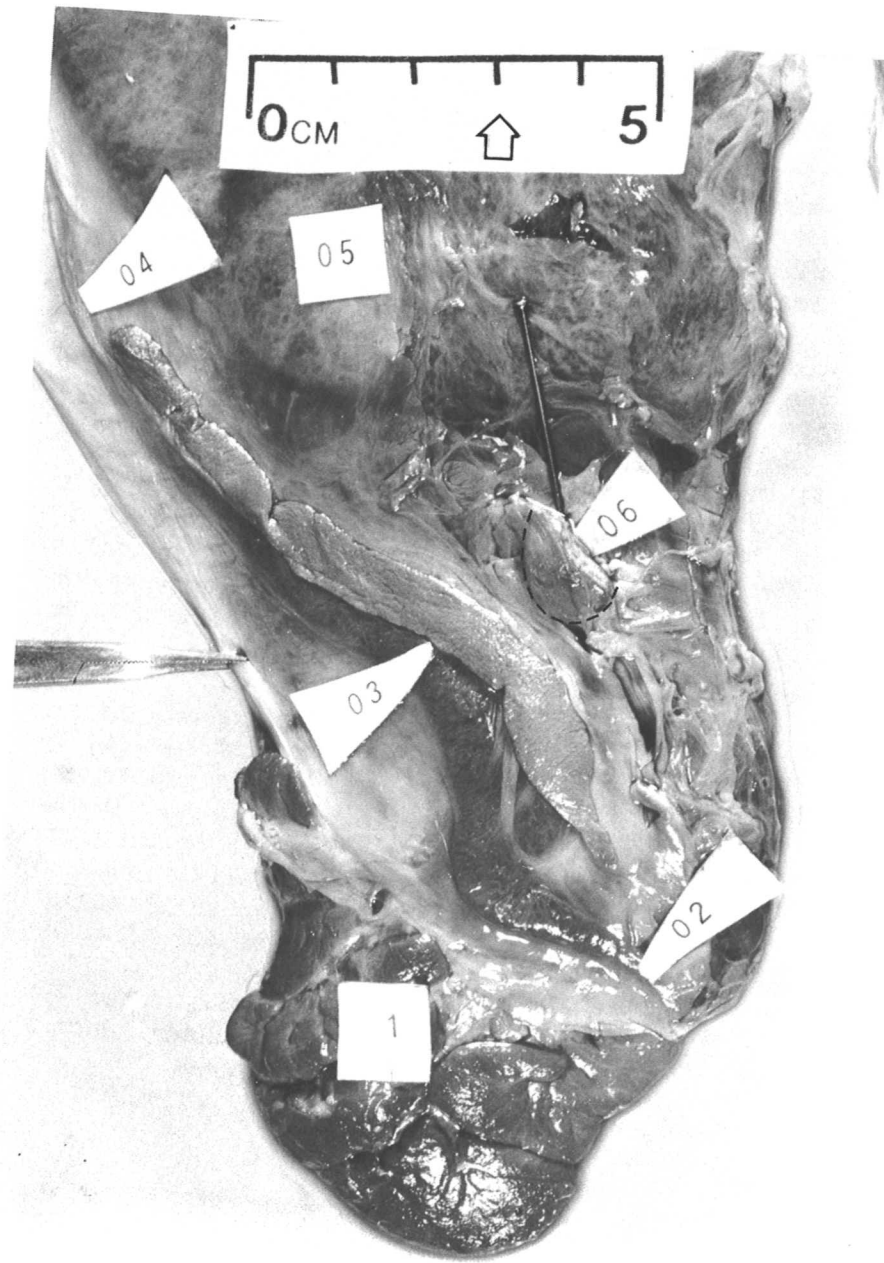

Figure 22.

Figure 23. *C. caretta* juvenile male. Open arrow on scale bar points anteriorly.

The cloaca is cut open from the anus (near the lower margin of the photo) anteriorly along the dorsal midline, exposing the penis (1, 2) on the ventral midline. The junction of the large intestine (7) and the cloaca is split longitudinally, and the intestine is laid out as flaps on each side. The longitudinal folds of the intestinal lining stop abruptly at the muscular valve separating the cloaca. The cut extends ventrally past the intestine to the base of the urinary bladder (4), exposing the interior of the urogenital sinus, an anterior, ventral chamber of the cloaca.

Urine from the kidneys, and semen bearing sperm from the testes (6, immature here, see Fig. 32) pass in separate small ducts through the sheet of connective tissue (5) leading from the kidney to the cloaca. Both ducts from one side of the body discharge through a single urogenital papilla (3) in the lateral wall of the urogenital sinus. On the tip of the papilla is a small, round opening through which urine passes (to be temporarily stored in the urinary bladder). Medially near the base of the papilla is a larger slit-like opening for gonadal products. This aperture is closed in at least some immatures, perhaps does not normally open until sexual maturity. In mature females the entire papilla is enlarged, allowing the passage of eggs (see Fig. 31).

The two parts of the penis labelled here are the bulbous glans (1) which forms the tip of the organ when it is extruded through the anus, and two parallel ridges of erectile tissue (2). The groove between them conducts semen during copulation. The penis in this immature male is grossly similar to equivalent structures present in the female cloaca. The penis presumably develops differentially along with external, male characteristics (enlarged claws and tail) at maturation, but little is currently known about the pattern of sexual development.

- | | | | |
|----|---------------------|----|------------------------------------|
| 1. | glans penis | 5. | path of ureter
and gonadal duct |
| 2. | erectile tissue | 6. | testis |
| 3. | urogenital papillae | 7. | large intestine |
| 4. | urinary bladder | | |

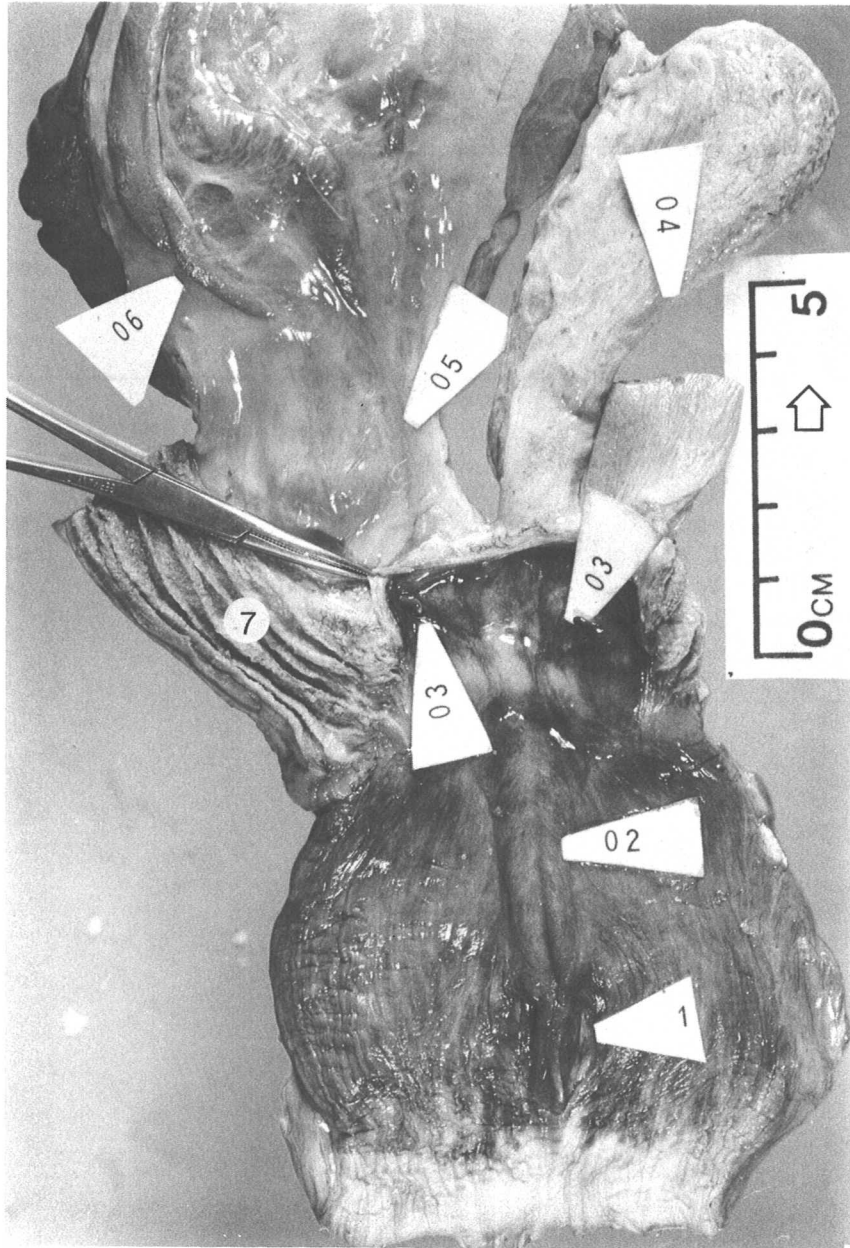



Figure 23.

Figure 24. Lepidochelys olivacea posthatchling.

A. The carapace-scute pattern of the olive ridley is the most variable among sea turtle species. This posthatchling individual happens to have a pattern similar to the loggerhead, but subdivision of the scutes and consequently higher counts are more typical. Kemp's ridley normally has a pattern similar to this specimen and is not highly variable.

B. The plastral scute pattern of both ridley species includes four inframarginals (IF1 - IF4) with Rathke's gland pores at their posterior edges (see Fig. 25). Ridleys also commonly lack an intergular scute. This individual has a large, divided postanal scute, an unusual feature.

Ab.	abdominal scute	IF1 - IF4.	inframarginal scutes
An.	anal scute	M1 - M12.	marginal scutes
C.	claw	N.	nuchal scute
C1 - C4.	costal scutes	Pa.	postanal scute
F.	femoral scute	Pe.	pectoral scute
G.	gular scute	V1 - V5.	vertebral scutes
H.	humeral scute		



A

B


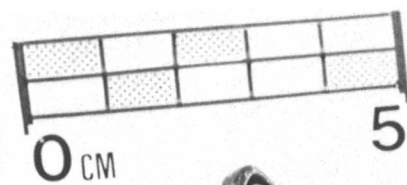


Figure 24.

Figure 25. L. olivacea posthatchling.

A. The pores of Rathke's glands (light spots marked by solid black arrows) are located on the posterior margin of the axillary scute adjacent to the fifth marginal scute (M5) and at the posterior margin of each inframarginal scute (IF1 - IF4). The axillary pore position is similar in other cheloniid turtles, but inframarginal pores normally occur only in ridleys.

IF1 - IF4. inframarginal scutes
M5 - M9. marginal scutes

B. The anterior and lateral margins of the plastron have been cut free and pulled posteriorly to expose the rows of Rathke's glands (1) adhered to the plastron. In life, the glands fill the empty spaces (2) at the lateral margins of the body. Though these glands are evident in adult ridleys, they make up a much greater proportion of total body weight in hatchlings. The mid-ventral heart (3), left lateral stomach (4), and ventral portions of the pectoral girdle (5, 6) are also exposed. The medial tips of the acromion processes (5) of the scapulae were attached anteriorly to the plastron (see Fig. 5), but the medial tips of the coracoids (6) are free.

1.	Rathke's glands	4.	stomach
2.	position of glands	5.	acromion process
3.	heart	6.	coracoid

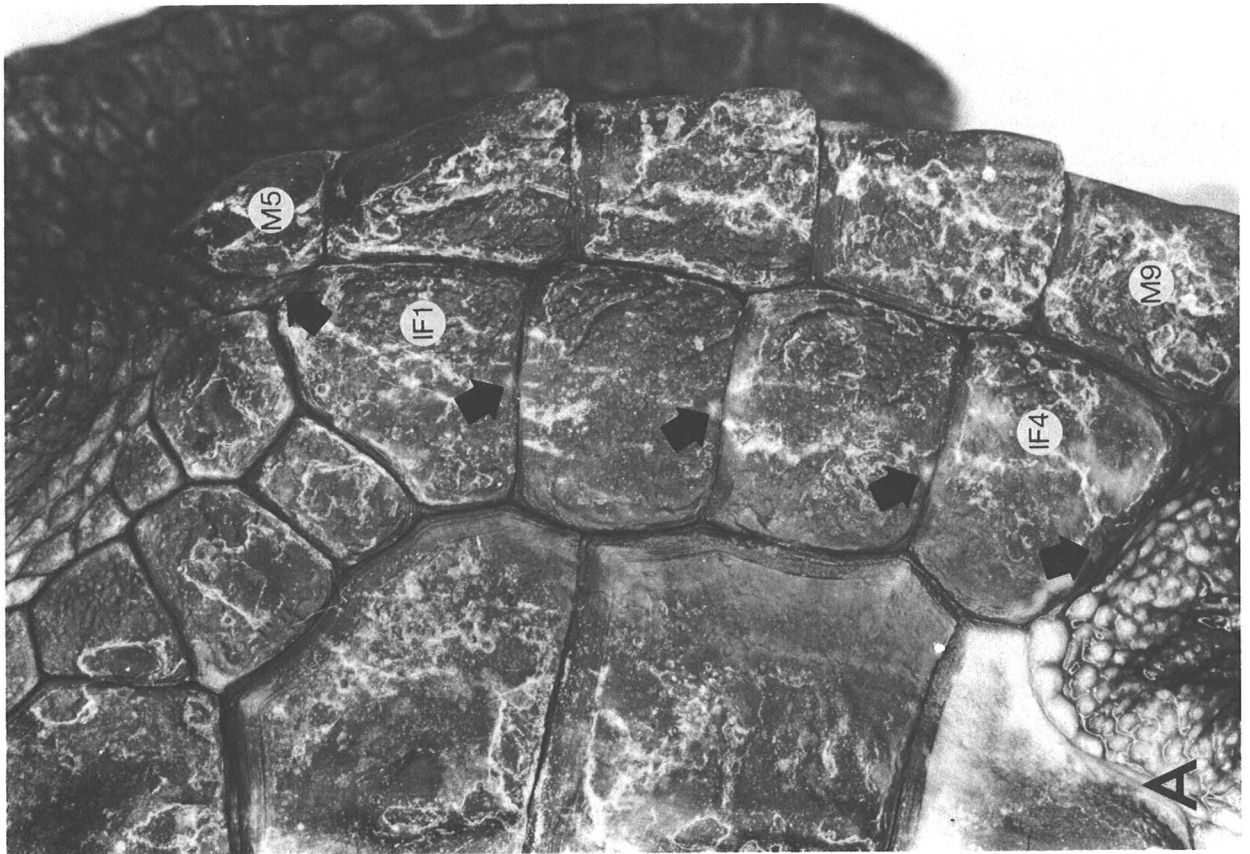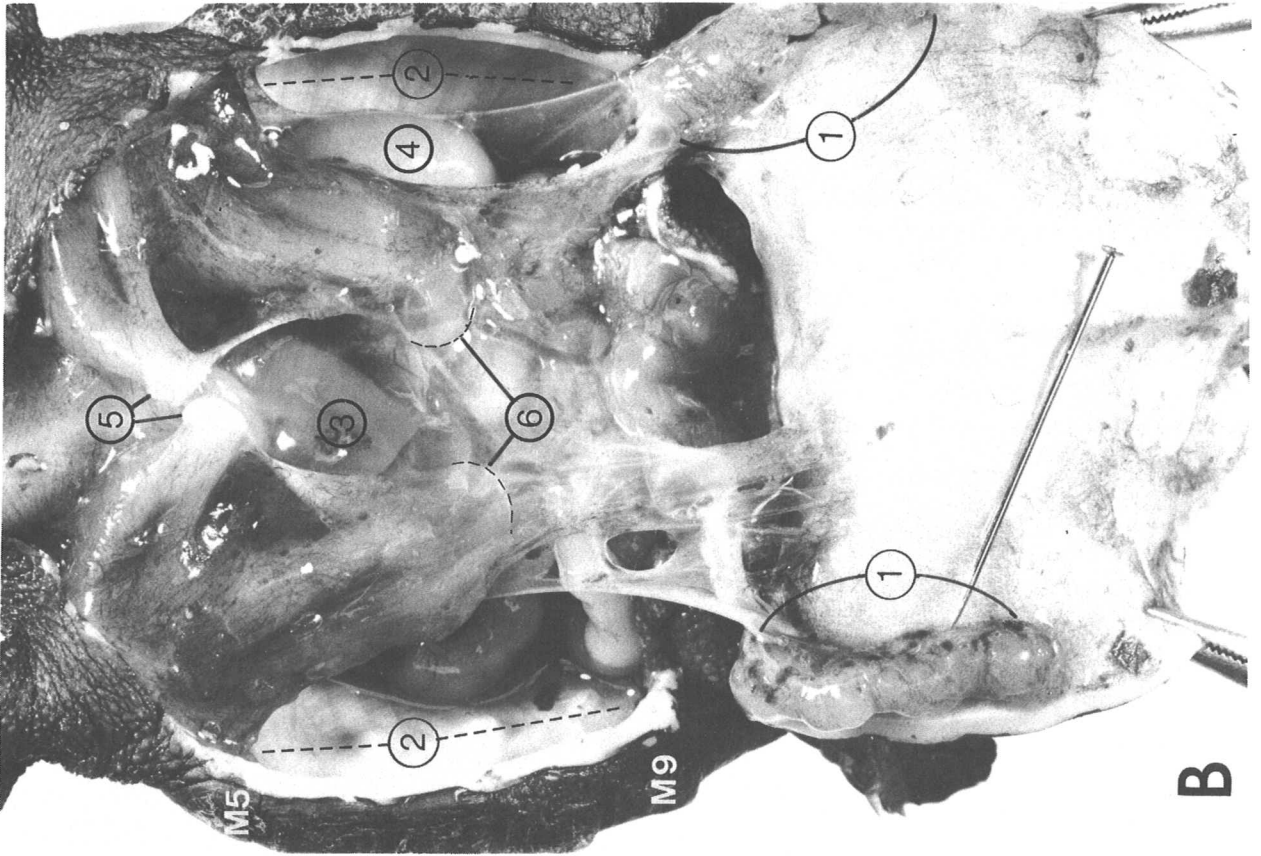


Figure 25.

Figure 26. L. olivacea posthatchling.

A. The single, median thyroid gland (1) is a round, translucent-red body which lies slightly anterior to the heart (3, see Fig. 8). The paired thymus glands (2) are distinct, lobular, white bodies anterior and lateral to the heart. The heart has been pulled to the right, exposing the division (4) of the trachea into the bronchi. In hatchlings the trachea and bronchi are transparent except for the cartilage support rings. The pericardial sac enclosing the heart is extensively attached dorsally (at 5) to the connective tissue envelope of the liver.

1. thyroid
2. thymus
3. heart
4. junction of trachea and bronchi
5. attachments of pericardial sac

B. The heart and shoulder girdle (1) have been pulled anteriorly to expose the digestive tract. The left lobe of the liver (3) is attached to the inner curvature of the stomach (4). The gall bladder (6, outlined by dashed white line) is embedded in the posterior margin of the right lobe of the liver (2) and discharges bile into the anterior small intestine (5). Part of the intestine has been pulled posteriorly to expose the spleen (7) on the mesentery. The pelvis (8) obscures the posterior gut and gonads.

- | | |
|------------------------|--------------------|
| 1. pectoral girdles | 5. small intestine |
| 2. right lobe of liver | 6. gall bladder |
| 3. left lobe of liver | 7. spleen |
| 4. stomach | 8. pelvis |

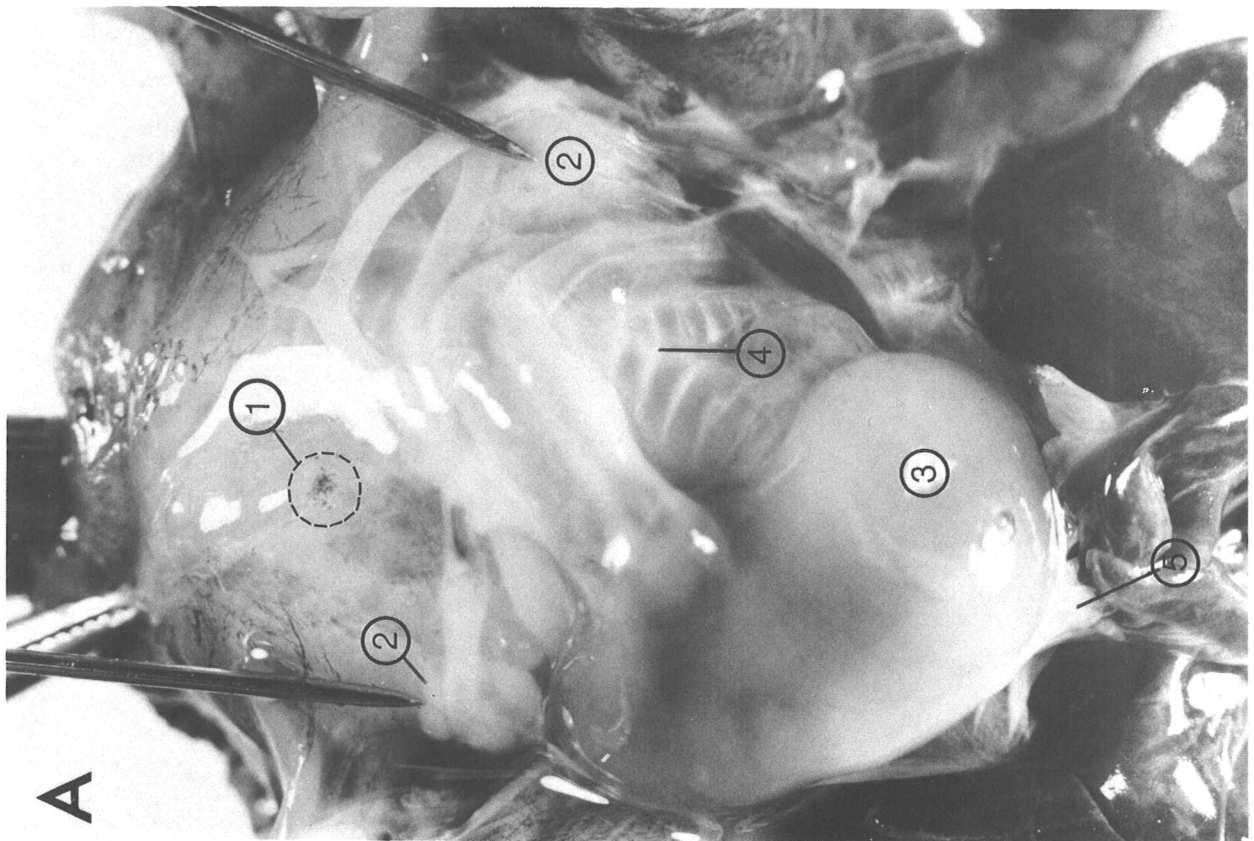
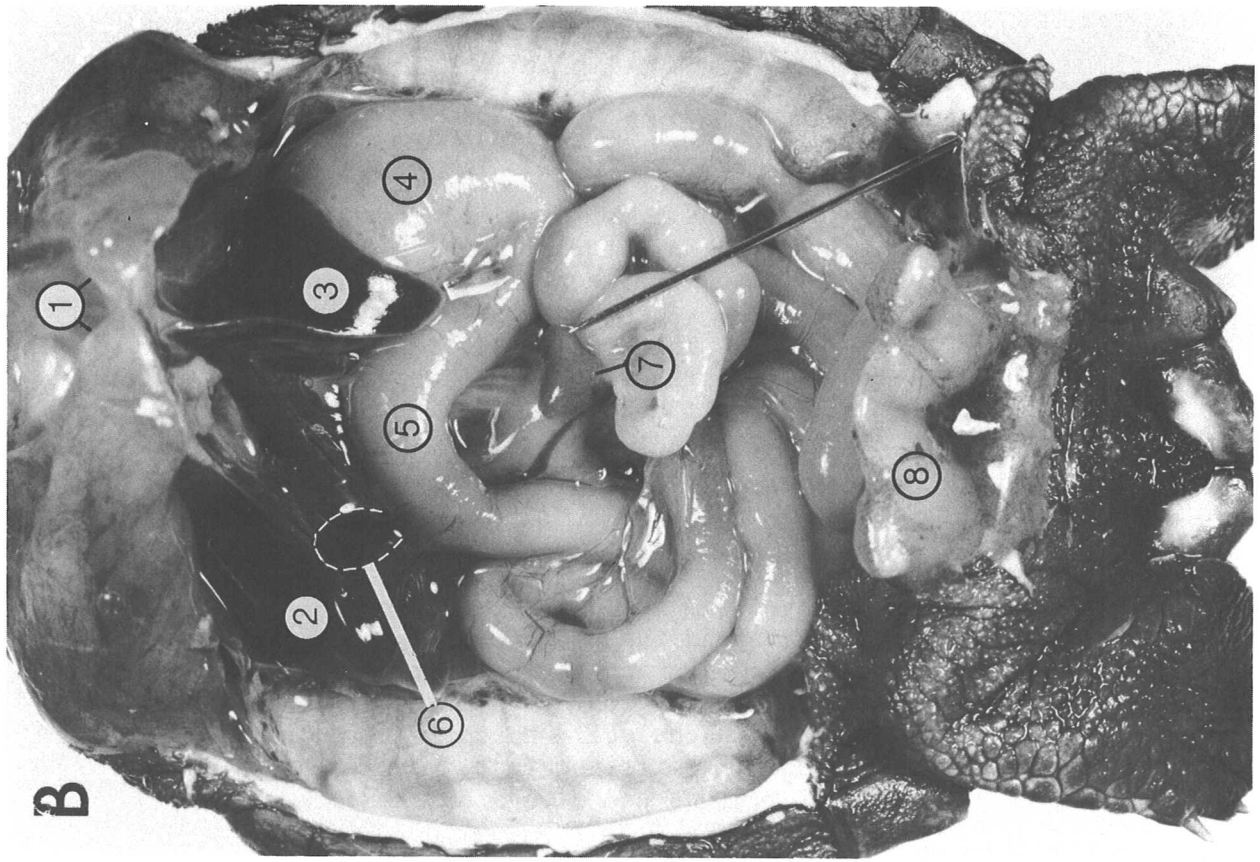


Figure 26.

Figure 27. L. olivacea posthatchling.

A. The pectoral girdles, heart and liver have been removed to expose the trachea (1), bronchi (2), and an anterior portion of the right lung (3). The esophagus (4) passes between the bronchi and constricts slightly at its junction with the stomach (5). The pancreas is an irregular, cream-colored, narrow ribbon of tissue extending along the anterior margin of the small intestine (9) from the pylorus (6) to near the former position (8) of the gall bladder. A thin lobe of pancreatic tissue extends out onto the intestinal mesentery to partially envelope the spleen (7, see Fig. 16).

B. The pelvis has been removed and the digestive tract pulled anteriorly to expose the urogenital organs and the posterior tip of the left lung (3). There is no layer of fat obscuring the bony structure of the carapace lateral to the lung as would be present in a larger juvenile or adult (see Fig. 12, 20A). Fat in cheloniid hatchlings and small juveniles is typically found as irregular, semitransparent, grey to black masses in the axillary and inguinal regions and alongside the neck.

The posterior segment of the large intestine (10) runs along the body midline and discharges into the cloaca (11). The gonads (15) of hatchlings are thin, whitish strands closely attached to the peritoneum covering the ventral surface of the red kidneys (14). In animals this small, it is not possible to determine the sex by gross dissection (see Fig. 32). Urine produced by the kidneys flows through a small tube in the strand of tissue (13) connecting the kidney and cloaca and is stored in the bladder (12, see Fig. 23).

- | | | | |
|----|---------------------------|-----|---------------------------|
| 1. | trachea | 9. | anterior small intestine |
| 2. | bronchi | 10. | posterior large intestine |
| 3. | lung | 11. | cloaca |
| 4. | esophagus | 12. | urinary bladder |
| 5. | stomach | 13. | ureter |
| 6. | pylorus | 14. | kidney |
| 7. | spleen | 15. | gonad |
| 8. | posterior end of pancreas | | |

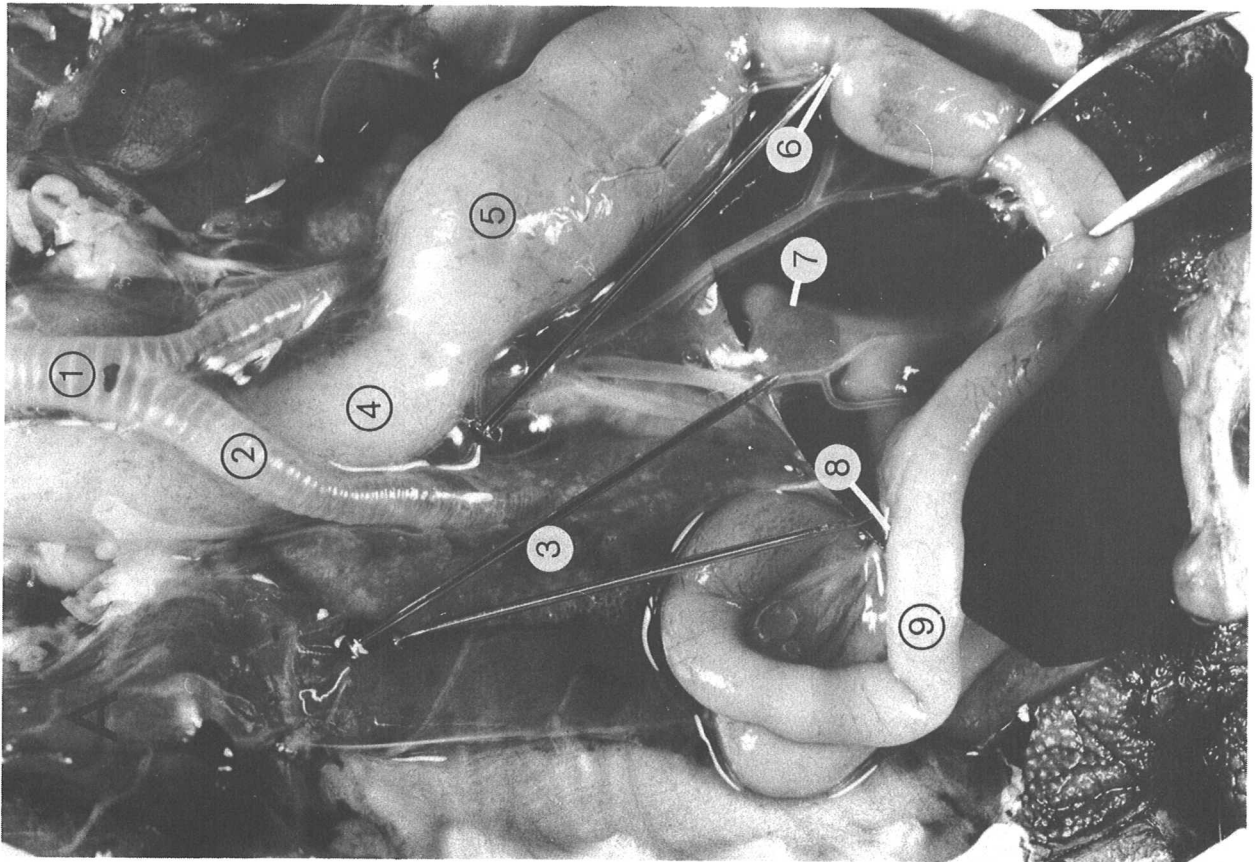
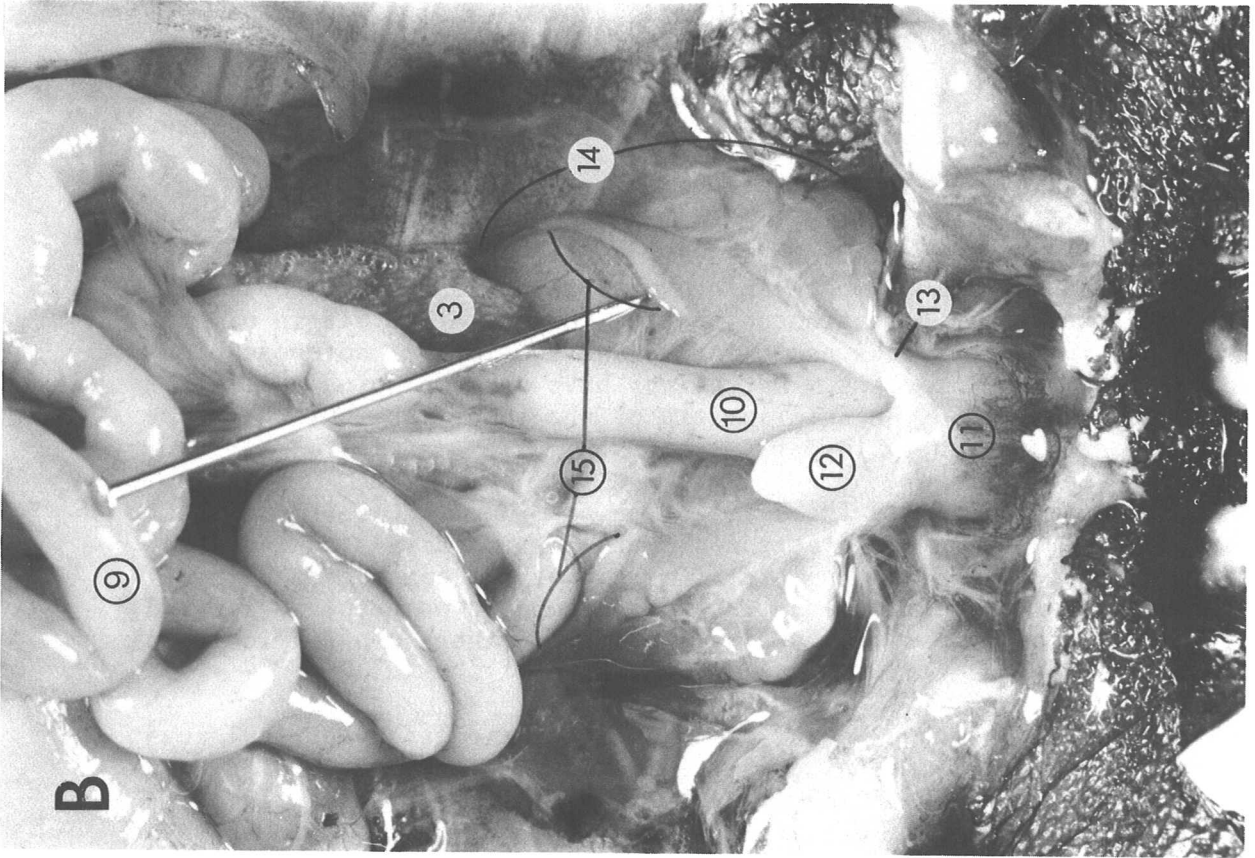


Figure 27.

Figure 28. Dermochelys coriacea hatchling. Approximately life size.

The leatherback lacks the large scutes which cover the carapace and plastron of other sea turtles. The bodies of hatchlings are covered with small scales which are lost over several months. Older turtles, including adults, have smooth skin over the entire body, except for the hard, keratinized sheaths on the jaw margins. The margin of the upper jaw in leatherbacks has a median and two lateral notches which create two prominent cusps. Hatchlings have a sharp spine (S) on the tip of each cusp and the anterior tip of the lower jaw, but these are also absent in slightly larger juveniles.

In both young and adults there are seven prominent keels (K) on the carapace and five on the plastron. Posterior and dorsal to the front limbs on each side near the lateral margin of the carapace are three or four Rathke's gland pores. The most prominent pore (p) is located at the anterior end of the marginal keel; the others are difficult to locate.

In this animal, which died the day after hatching, the umbilical scar (U) on the plastral midline (ventral to the yolk sac, see Fig. 29) has not completely closed. Some leatherback hatchlings have vestigial claws on the limbs like cheloniid turtles (see Fig. 24, 26), but these are absent in adults.

- K. keel
- p. Rathke's gland pore
- S. spine
- U. umbilical scar



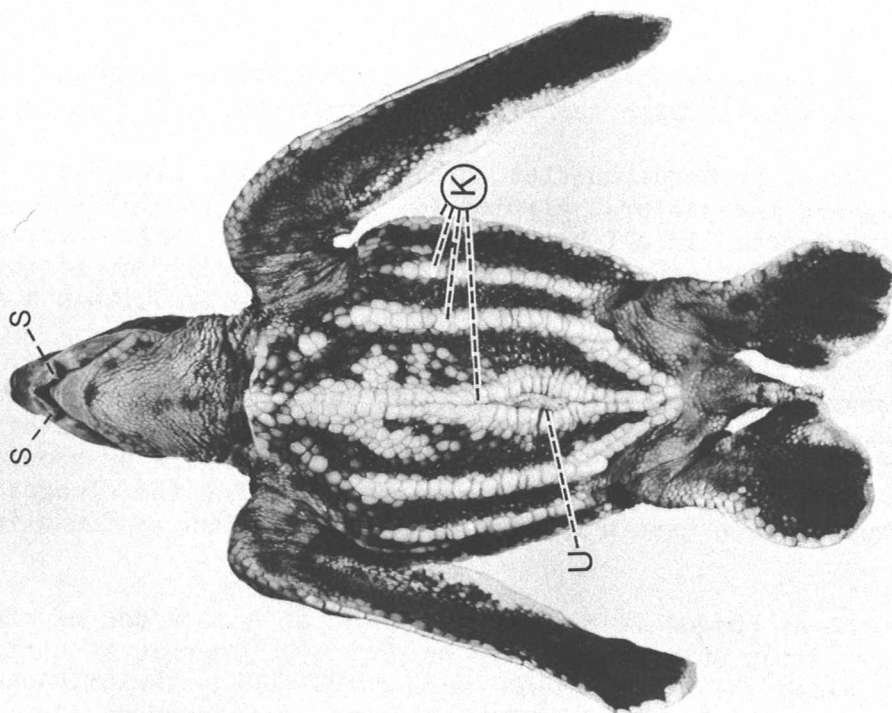



Figure 29.

Figure 29. *D. coriacea* hatchling. Small, open arrows indicate the path of food through the digestive tract.

A. The plastron, pectoral muscles, heart and ventral peritoneum have been removed and the pectoral girdles (1, 2) pulled laterally to expose the digestive tract. In all hatchling sea turtles a large, yellow sac of stored yolk (3) attached to the intestine is a prominent feature of the viscera. This temporary nutrient store is absorbed within a few weeks after hatching.

The leatherback esophagus (5) is very long and the stomach has two distinct parts, a globular anterior chamber (6) and a tubular posterior segment which is partly subdivided into smaller chambers by about twelve transverse ridges. The mesenteries supporting the elongated esophagus and stomach have a more complex pattern than is found in cheloniids.

Anteriorly the esophagus is broad and exposed on both sides of the trachea (4). After passing dorsally between the bronchi, it continues posteriorly along the body midline, then turns back anteriorly and left around the globular stomach, finally entering it anteromedially. The left lobe of the liver (7) which covers the posterior esophagus and stomach ventrally has been lifted anteriorly and to the right. The anterior small intestine (9) which normally lies along the posterior border of the left liver lobe is pulled out of place. The right lobe of the liver (7), the lung (10), posterior small intestine (11), large intestine (12), inguinal fat bodies (13) and pelvic muscles (14) are in place. Hatchling leatherbacks differ from cheloniids in having much larger, discrete lenticular, yellow-white fat bodies in the axillary and inguinal regions.

B. Both the left lobe of the liver (7) and the mesenteric sac containing the posterior esophagus (5) and the stomach (6, 15) have been pulled anteriorly to expose the tubular stomach (15) against the dorsal surface of the globular stomach.

- | | | | |
|----|---------------------|-----|---------------------------|
| 1. | acromion process | 9. | anterior small intestine |
| 2. | coracoid | 10. | lung |
| 3. | yolk sac | 11. | posterior small intestine |
| 4. | trachea | 12. | large intestine |
| 5. | esophagus | 13. | fat bodies |
| 6. | globular stomach | 14. | pelvic muscles |
| 7. | left lobe of liver | 15. | tubular stomach |
| 8. | right lobe of liver | | |

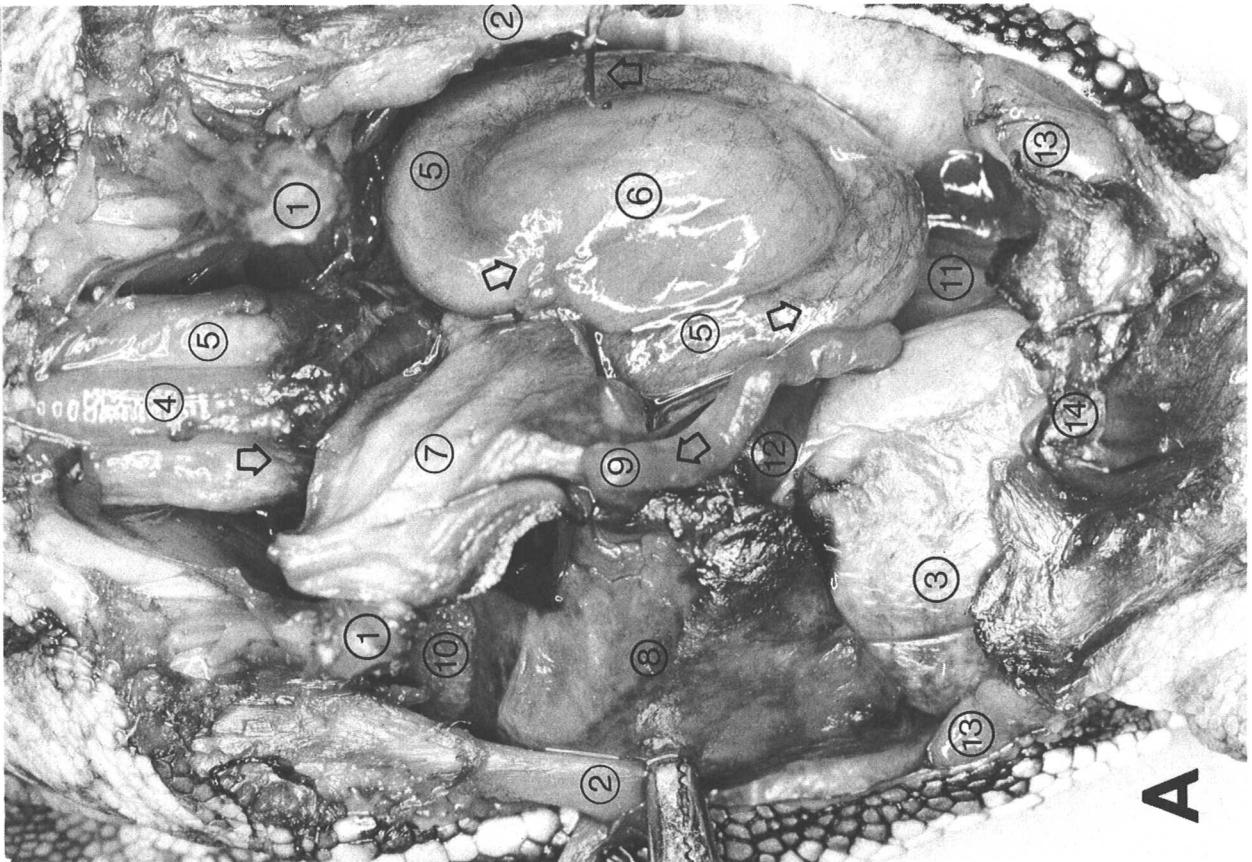
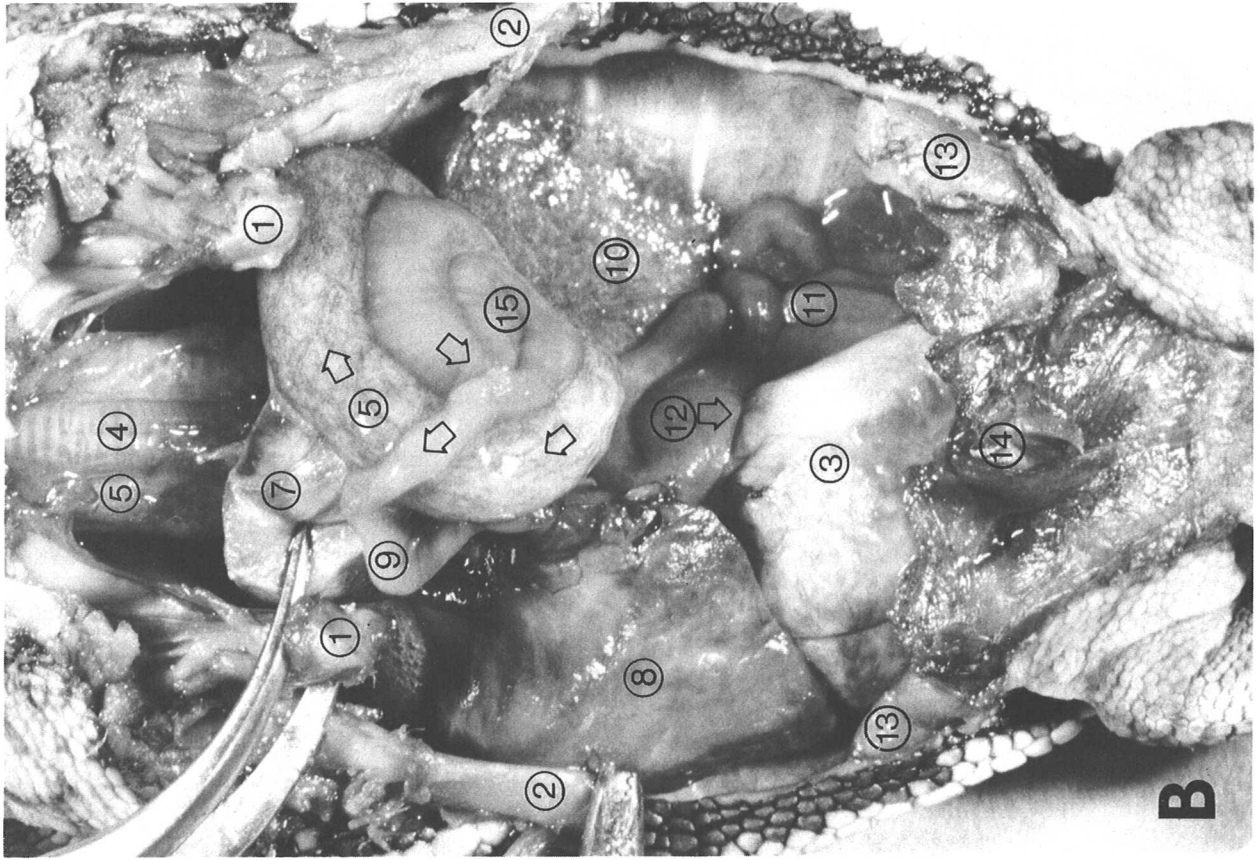


Figure 29.

Figure 30. L. olivacea adult female reproductive tract.

The right ovary and oviduct and the posterior cloaca have been cut away from this mature female reproductive tract (compare Fig. 10), but the supporting mesenteries on the left side are largely intact. The left ovary (2) is quiescent; the largest follicles (4), round bodies which nurture developing eggs, are less than 1 cm. in diameter (see Fig. 32).

After being released from a mature follicle, the egg enters the oviduct (3) through the thin-walled funnel (5) anterior to the ovary; the small, open arrows mark its subsequent path. Numerous transverse folds give the anterior oviduct a pleated appearance. Posteriorly the wall is much thicker and more muscular, but it thins when the oviduct stretches to a length of several meters to accommodate large numbers of eggs prior to nesting.

The anterior cloaca has been cut along the dorsal midline and flattened out to expose the urogenital papillae (6) within the urogenital sinus (see Fig. 23). Eggs enter the cloaca from the oviducts through openings on the medial surface of the papillae (see Fig. 31 for details). The bladder (7) stores urine discharged into the sinus through inconspicuous, round openings on the lateral surfaces of the papillae. The tip of the left papilla has been pulled anteriorly to expose the urinary opening (8).

- | | | | |
|----|-------------------|----|---------------------------|
| 1. | cloaca | 6. | urogenital papillae |
| 2. | ovary | 7. | urinary bladder |
| 3. | oviduct | 8. | urinary opening |
| 4. | follicle | 9. | posterior large intestine |
| 5. | funnel of oviduct | | |

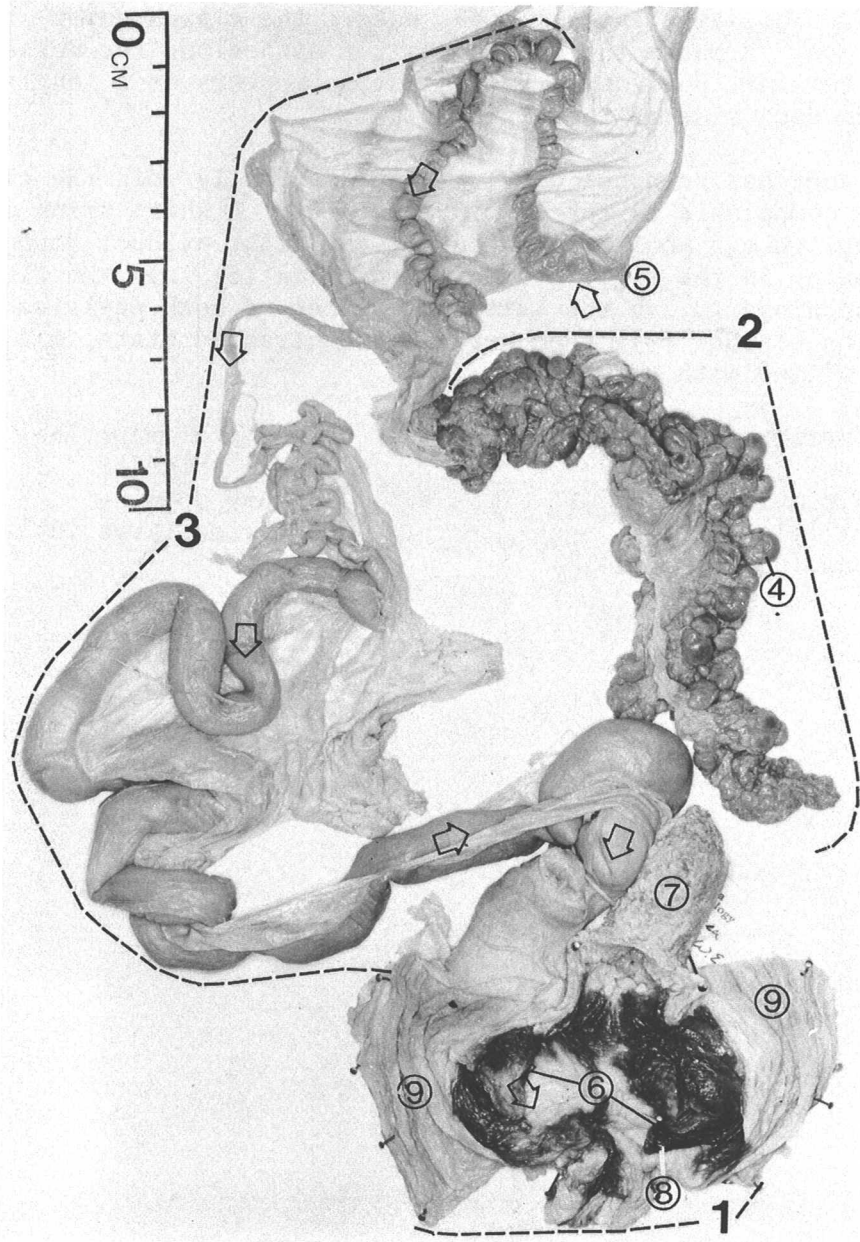


Figure 30.

Figure 31. L. olivacea adult female reproductive tract. Open arrow on scale bar points anteriorly.

The mature female anterior cloaca of Fig. 30 is enlarged to show details of the urogenital sinus. Much of the lining of the cloaca is darkly pigmented, including the posterior portions absent in this specimen (see Fig. 23). The large intestine (9) enters the cloaca dorsal to the urogenital sinus. Because the cloaca was cut open along the dorsal midline, the terminal portion of the intestine appears as a longitudinally-ridged flap on each side of the sinus.

The right oviduct has been cut away; it would normally join the cloaca in a position comparable to the left oviduct (3). A white arrow marks the path a shelled egg would follow out of the right oviduct through the basal opening in the right urogenital papilla (6) into the cloaca. The urinary openings (8) on the lateral surfaces of both papillae are concealed. The bladder (7), seen here in a contracted state, may enlarge greatly when filled with urine.

- | | | | |
|----|-------------------|----|---------------------------|
| 1. | anterior cloaca | 6. | urogenital papillae |
| 2. | ovary | 7. | urinary bladder |
| 3. | left oviduct | 8. | urinary opening |
| 4. | follicle | 9. | posterior large intestine |
| 5. | funnel of oviduct | | |

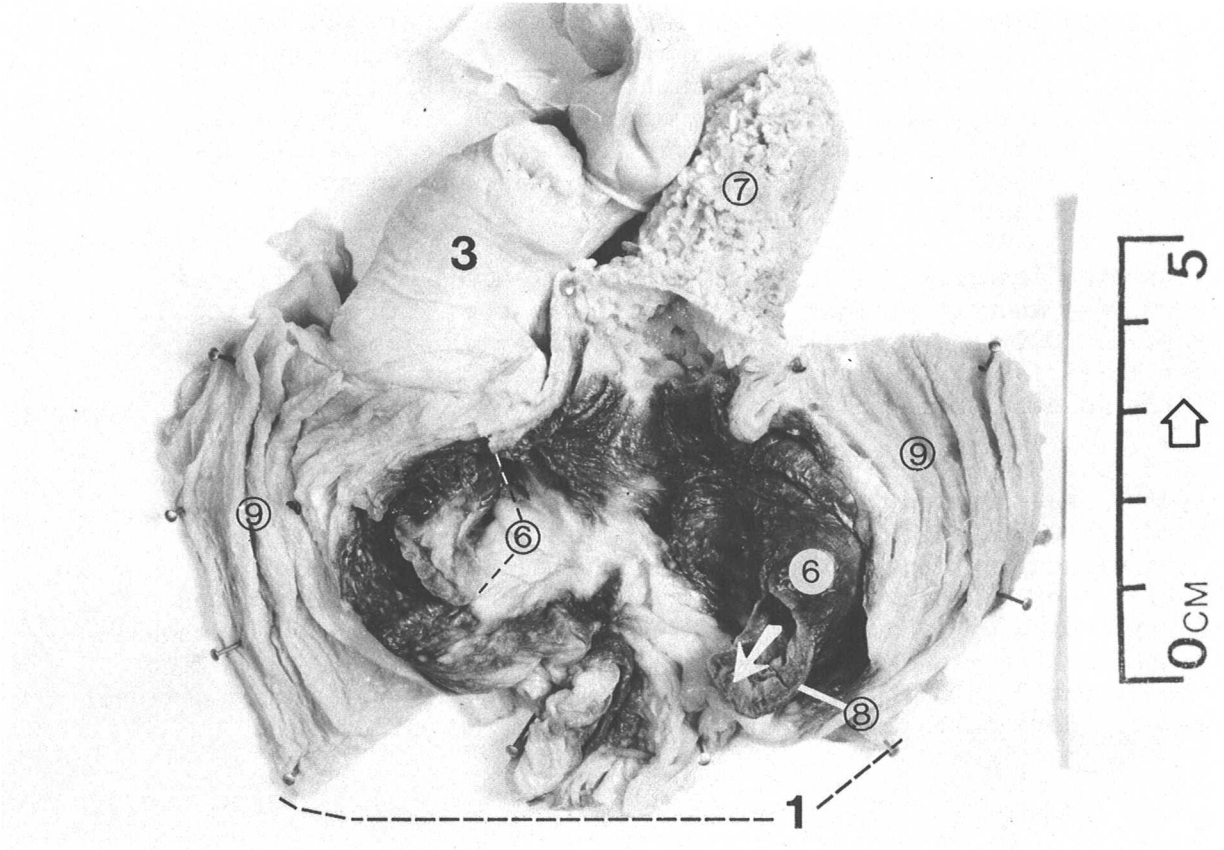


Figure 31.

Figure 32. C. mydas male (1-2) and female (3-5) gonads. Gonads 1-4 are life size; gonad 5 is 0.6X.

The gonads of hatchling sea turtles require microscopic examination to determine the sex, but naked-eye inspection should be sufficient to sex individuals with carapace lengths down to at least 30 cm. Ovaries are membranous, folded, often partly transparent structures enclosing spherical, white to yellow follicles (see Fig. 10, 30). Testes are light-colored, elongate, solid organs with a relatively uniform surface texture (see Fig. 22).

Gonads 1 and 2 are testes from immature males with carapace lengths of 49 and 64 cm. respectively. Testes of mature male green turtles are grey-pink, sausage-shaped bodies usually at least twice as long as specimen 2 and more nearly round in cross-section. If substantial amounts of developed sperm are present in the testis or epididymis (white when fresh), the tissues will usually be swollen and milky fluid can be expressed from a cut surface.

Ovaries from immature females with carapace lengths of 61.5 (3) and 68.5 cm. (4) show increasing average follicle size with increasing body size. Only a few follicles in 3 exceed 1 mm. diameter, but in 4 larger follicles are quite numerous (black lines mark an individual follicle in each specimen).

Gonad 5 is an ovary from an apparently mature female (86 cm. C.L.), collected away from any probable nesting site, but showing follicular enlargement which suggests she would nest in the upcoming season. Ovaries of nesting females may contain several hundred enlarging follicles over ten grams in weight and, with the oviducts distended with developing eggs, occupy a large part of the body cavity. Seasonal (not necessarily annual) cycles of gonadal development and regression can be expected for both male and female sea turtles, but much additional systematic data collection is needed to define the pattern.


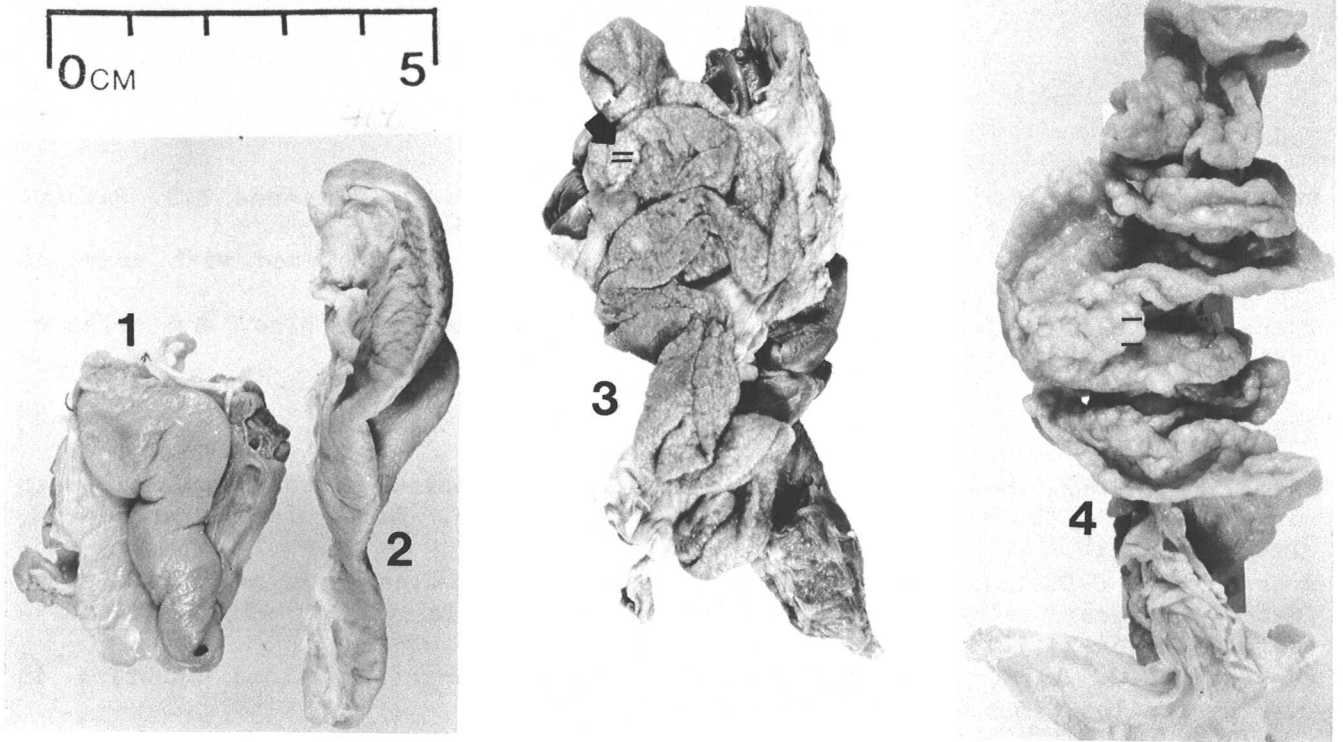


Figure 32.

Bibliography

Blood

- Dessauer, H.C. 1970. Blood chemistry of reptiles. In C. Gans and T.S. Parsons (eds.). *Biology of the Reptilia* 3:1-91. Academic Press, New York.
- Frair, W. 1977. Sea turtle red blood cell parameters correlated with carapace lengths. *Comp. Biochem. Physiol.* 56A:467-472.
- Owens, D.W., and G.J. Ruiz. 1980. New methods of obtaining blood and cerebrospinal fluid from marine turtles. *Herpetologica* 38(1):17-20.

Circulatory system

- Adams, W.E. 1962. The carotid sinus-carotid body problem in the Chelonia (with a note on the foramen of Panizza in *Dermodochelys*). *Arch. Int. Pharmacodyn.* 139(1-2):25-37.
- Greer, A.E., J.D. Lazell, and R.M. Wright. 1973. Anatomical evidence for a counter-current heat exchanger in the leatherback turtle (*Dermodochelys coriacea*). *Nature* 244(5412):181.
- Sapsford, C.W. 1978. Anatomical evidence for intracardiac blood shunting in marine turtles. *Zool. Afr.* 13(1):57-62.

Digestive system

- Luppa, H. 1977. Histology of the digestive tract. In C. Gans and T.S. Parsons (eds.). *Biology of the Reptilia* 6:225-313. Academic Press, New York.
- Parsons, T. S., and J.E. Cameron. 1977. Internal relief of the digestive tract. In C. Gans and T.S. Parsons (eds.). *Biology of the Reptilia* 6:159-223. Academic Press. New York.

Endocrine glands

- Owens, D.W., and C.L. Ralph. 1978. The pineal-paraphyseal complex of sea turtles, I. Light microscopic studies. *J. Morphol.* 158(2):169-180.
- Miller, M.R., and M.D. Lagios. 1970. The pancreas. In C. Gans and T.S. Parsons (eds.). *Biology of the Reptilia* 3:319-346. Academic Press, New York.
- Gabe, M. 1970. The adrenal. In C. Gans and T.S. Parsons (eds.). *Biology of the Reptilia* 3:263-318. Academic Press, New York.
- Clark, N.B. 1970. The parathyroid. In C. Gans and T.S. Parsons (eds.). *Biology of the Reptilia*. 3:235-262. Academic Press, New York.
- Lynn, W.G. 1970. The thyroid. In C. Gans and T.S. Parsons (eds.). *Biology of the Reptilia* 3:201-234. Academic Press, New York.

Externally secreting glands

- Cowan, F.B.M. 1973. The homology of cranial glands in turtles with special reference to the nomenclature of 'salt glands.' *J. Morphol.* 141:157-170.
- Ehrenfeld, J.G., and D.W. Ehrenfeld. 1973. Externally secreting glands of freshwater and sea turtles. *Copeia* 1973(2):305-314.
- Peaker, M., and J.L. Linzell. 1975. Salt glands in birds and reptiles. Cambridge University Press, London.

Gross Anatomy

- Ashley, L.M. 1962. Laboratory anatomy of the turtle. W.C. Brown Co., Dubuque.
- Burne, R.H. 1905. Notes on the muscular and visceral anatomy of the leathery turtle. Proc. Sci. Mtgs. Zool. Soc. London 1:291-324.
- Dunlap, C.E. 1955. Notes on the visceral anatomy of the giant leatherback turtle (Dermochelys coriacea Linnaeus). Bull. Tulane Med. Faculty 14(2):55-69.
- Wake, M.H.(ed.) 1979. Hyman's comparative vertebrate anatomy, 3rd edition. University of Chicago Press. Chicago.

Lymphatic system

- Bockman, D.E. 1970. The thymus. In C. Gans and T.S. Parsons (eds.). Biology of the Reptilia 3:111-134. Academic Press, New York.

Parasites and fouling organisms

- Barnard, J. L. 1967. A new genus of Galapagan amphipod inhabiting the buccal cavity of the sea-turtle, Chelonia mydas. In Proceedings of Symposium on Crustacea, Ernakulam, 1965. Marine Biological Station of India. Part 1, p. 119-125. Bangalore Press.
- Blair, D.W. [1979, MS] Parasitic flatworms (Platyhelminthes: Classes Digenea and Aspidogastrea) of sea turtles, with emphasis on those of Australia. Dept. of Biology, Univ. of Canterbury, Christchurch, New Zealand.
- Carr, A.F., L. Ogren, and C. McVea. 1980. Apparent hibernation by the Atlantic loggerhead turtle Caretta caretta off Cape Canaveral, Florida. Biol. Cons. 19(1980-81):7-14.
- Davies, R.W. 1978. Morphology of Ozobranchus margoi(Apaty) (Hirudinoidea), a parasite of marine turtles. J. Parasitol. 64(6): 1092-1096.
- Monroe, R., and C.J. Limpus. 1979. Barnacles on turtles in Queensland waters with descriptions of three new species. Mem. Qld. Mus. 19:197-223.
- Raj, P.J.S., and L.R. Penner. 1962. Concerning Ozobranchus branchiatus (Menzies) (Piscicolidae: Hirudinea) from Florida and Sarawak. Trans. Am. Microscop. Soc. 81(4):364-371.

Pathology

- Brock, J.A., R.M. Nakamura, A.Y. Miyhara and E.M.M. Chang. 1976. Tuberculosis in Pacific green sea turtles, Chelonia mydas. Trans. Amer. Fisher. Soc. 105(4): 564-566.
- Keymer, I.F. 1978. Diseases of chelonians 2. Necropsy survey of terrapins and turtles. Vet. Rec. 103(26):577-582.

Respiratory system

- Parsons, T.S. 1968. Variation in the choanal structure of recent turtles. Can. J. Zool. 46(6): 1235-1263.
- Tenny, S.M., D. Bartlett, J.P. Farber, and J.E. Remmers. 1974. Mechanics of the respiratory cycle in the green turtle (Chelonia mydas). Resp. Physiol. 22:361-368.
- Walker, W.F. 1959. Closure of the nostrils in the Atlantic loggerhead and other sea turtles. Copeia 1959(3):257-259.

Sensory systems

- Baird, T.L. 1970. The anatomy of the reptilian ear. In C. Gans and T.S. Parsons (eds.). Biology of the Reptilia. 2:193-275. Academic Press, New York.
- Parsons, T.S. 1970. The nose and Jacobson's organ. In C. Gans and T.S. Parsons (eds.). Biology of the Reptilia. 2:99-197. Academic Press, New York.
- Underwood, G. 1970. The eye. In C. Gans and T.S. Parsons (eds.). Biology of the Reptilia 2:1-97. Academic Press, New York.
- Wever, E.G. 1978. The reptilian ear. Princeton University Press. Princeton.

Skeleton and muscles

- Rhodin, A.G.J., J.A. Ogden, and G.J. Contogoe. 1981. Chondrosseous morphology of Dermodochelys coriacea, a marine reptile with mammalian skeletal features. Nature 290: 244-246.
- Schumacher, G.H. 1973. The head muscles and hyolaryngeal skeleton of turtles and crocodilians. In C. Gans and T.S. Parsons (eds.). Biology of the Reptilia. 4:101-199. Academic Press, New York.
- Walker, W.F. 1973. The locomotor apparatus of testudines. In C. Gans and T.S. Parsons (eds.). Biology of the Reptilia. 4:1-99. Academic Press, New York.

Tissue preservation and specimen preparation

- DeBlase, A.F., and R.E. Martin. 1981. A manual of mammalogy, 2nd edition. W.C. Brown & Co., Dubuque.
- Hildebrand, M. 1968. Anatomical preparations. University of California Press. Berkeley.
- Humason, G.L. 1979. Animal tissue techniques, 4th edition. W.H. Freeman & Co. San Francisco.

Urogenital system

- Fox, H. 1977. The urogenital system of reptiles. In C. Gans and T.S. Parsons (eds.). Biology of the Reptilia. 6:1-157. Academic Press, New York.
- Owens, D.W. 1980. The comparative reproductive physiology of sea turtles. Amer. Zool. 20(3):549-564.
- Aitken, R.N.C., S.E. Solomon, and E.C. Amoroso. 1976. Observations on the histology of the ovary of the Costa Rican green turtle, Chelonia mydas L. J. Exper. Mar. Biol. Ecol. 24(2):189-204.
- Zug, G.P. 1966. The penial morphology and relationships of cryptodiran turtles. Occas. Pap. Mus. Zool. U. Mich. 647:1-24.
- Yntema, C.L., and N. Mrosovsky. 1980. Sexual differentiation in hatchling loggerheads (Caretta caretta) incubated at different controlled temperatures. Herpetologica 36(1):33-36.

Equipment and supplies

This list is recommended for field dissection of moderately large, fresh animals. Smaller implements and measuring devices would obviously be appropriate for posthatchlings. Quantities of supplies must also be scaled to the undertaking.

Measurement and recording

2 meter tape measure, 1mm graduations
 1-2 meter calipers, 0.5cm graduations
 dial caliper, at least 1mm graduations
 steelyard or spring scale, 200kg capacity
 block and tackle
 lightweight weighing tripod
 spring scale or pan balance, 20 kg capacity (for weighing organs)
 camera and film
 notebook with waterproof paper, data formats
 pen with permanent carbon ink (Higgins Eternal™ or equivalent)

Dissection

knife with 10cm straight edge
 sharpening stone
 large scapel handle and heavy duty disposable blades
 hacksaw
 stevedore's hook
 blunt probes of various sizes
 blunt tip and pointed scissors
 hemostats
 forceps with serrate and smooth tips
 soft cord (for tying off gut)
 bucket
 disposable latex examination gloves
 heavy neoprene gloves
 plastic apron and other protective clothing
 paper towels
 plastic film
 disinfectant solution

Sampling

aluminum foil or specially-cleaned containers (for chemical analyses)
 assorted sizes of heavy weight plastic bags with closures
 Whirlpaks™ or other small sterile bags or containers
 screw cap polypropylene storage vials (for body fluids)
 10% neutral buffered formalin
 70% ethanol or 50% isopropanol
 for preserving epifauna
 waterproof tape, labels and tags
 insulating foam box with ice or dry ice
 fine point indelible solvent-type pens
 syringes and needles (sterile for body fluid samples,
 nonsterile for fixative)
 anticoagulant (heparin concentrate, 500 units/ml solution, or equivalent)

INDEX

The figure legends only are indexed below by figure number, not page number.

acromion process	6,7,12,25,29
adrenal	22
adult	2,6-8,10,20,21,23,25,27,28,30-32
anus	21,23
aorta	8
artery	
brachiocephalic	8
pulmonary	8
atrium (of heart)	8,15
axillary region	2,3,7,11,14,25,27,29
barnacles	4,11
bile duct	16
bridge	2,6,7,14
bronchus	8,10,15,20,26,27,29
buttress (of plastral bone)	7
caecum	17
carapace	1,9,11,12,13,20,21,24,27,28,32
<u>Caretta caretta</u>	4,11-24
<u>Chelonia mydas</u>	1-11,16,17,20,32
<u>Chelonibia testudinaria</u>	11
circulatory system	8,15
(see also heart,aorta,artery)	
claw	2,23,24,28
cloaca	10,17,20,21,23,27,30,31
coracoid	7,9,12,25,29
crustacean	4
<u>Dermodochelys coriacea</u>	3,4,8,16-18,28,29
digestive system	5,9,10,15-19,26,27,29
(see also anus,caecum,cloaca, esophagus,gall bladder, intestine,liver,mouth, pancreas, stomach)	
ear	4
egg	30,31,32
endocrine system	
(see also adrenal, ovary, parathyroid, testis, thyroid, ultimobranchial)	
epididymis	20-22,32
<u>Eretmodochelys imbricata</u>	1,16
esophagus	4,5,7-10,13,15,17-20,27,29
eustachian tube	4
external anatomy	1-3,11,24,25,28
fat	6,7,12-14,16,27,29
femur	21
follicle	30,32
gall bladder	16-18,26,27
glottis	4

gonad	20,22,26,27,32
(see also ovary,testis)	
green turtle	1-11,16,17,20,32
hatchling	3,8,14,16,20,22,25-29,32
hawksbill	1,16
heart	8,9,12,13,15,25-27,29
humerus	7
hyoid	5,13
ileocecal valve	17,18
inguinal region	2,3,7,11,27,29
intestine	9,10,15-19,21,23,26,27,29,30,31
jaw	4,5,28
juvenile	1-27,32
keel	28
kidney	10,20-23,27
larynx	4,5
leatherback	3,4,8,16-18,28,29
<u>Lepidochelys kempfi</u>	11,16,24
<u>Lepidochelys olivacea</u>	11,24-27,30,31
lingual process	5
liver	9,15-17,20,26,27,29
loggerhead	4,11-24
lung	4,8,10,15,16,20,22,27,29
lymphatic system	
(see thymus)	
mesentery	9,15-17,26,27,29,30
mouth	2,4,5
muscle	
neck	5
pectoral	6,7,9,12,29
pelvic	6,7,12,20,21
nares	4
ovary	10,30,32
oviduct	
female	10,20,30,31
residual in male	20-22
pancreas	16-18,27
papilla	
esophageal	18,19
narial	4
urogenital	10,23,30,31
parathyroid	8
pectoral girdle	6,7-9,12,25-27,29
pelvic girdle	6,7,12,20,21,26,27
penis	23
pericardial sac	8,9,12,13,15,26
peritoneum	9,10,12,14,15,21,22,27,29
plastron	2,5,6,12,14,24,25,28,29
pore (of Rathke's gland)	2,3,11,14,24,25,28
axillary	3,11,14,25
inframarginal	24,25
inguinal	3,11
pylorus	9,16-18,27
Rathke's gland	2,3,11,14,24,25,28

respiratory system (see also bronchus, glottis, lungs, nares, trachea)	4,5,8,10,15,20,22,26,27,29
ridley	3
Kemp's	11,16,24
olive	11,24-27,30,31
scale	28
prefrontal	1
scapula	6,7,9,12,25
scute	1,2,3,11,24,25,28
abdominal	2,11,24
anal	2,11,24
axillary	25
costal	1,11,24
femoral	2,11,24
gular	2,11,24
humeral	2,11,24
inframarginal	2,3,11,24,25
inguinal	2,3
intergular	2,11,24
marginal	1-3,11,24,25
nuchal	1,11,24
pectoral	2,11,24
postanal	2,24
vetebral	1,11,24
sex determination	2,20-23,27,32
spleen	16,17,20,26,27
stomach	9,10,15-20,25-27,29
tail	21,23
testis	20-23,30,32
thymus	8,12,13,26
thyroid	8,12,13,26
tongue	4,5
trachea	5,7-9,13,20,26,27,29
ultimobranchial body	8
umbilical scar	28
ureter	23,27
urinary bladder	6,10,20,21,23,27,30,31
urogenital papilla (see papilla)	
urgenital sinus	23,30,31
urogenital system (see also cloaca,epidi- dymis,follicle, kidney, ovary, oviduct,papilla, testis, ureter, urinary bladder)	10,20-23,27,30-32
ventricle (of heart)	8,15
vertebra	20
yolk	29