

Imaging the Addicted Human Brain

Modern imaging techniques enable researchers to observe drug actions and consequences as they occur and persist in the brains of abusing and addicted individuals. This article presents the five most commonly used techniques, explains how each produces images, and describes how researchers interpret them. The authors give examples of key findings illustrating how each technique has extended and deepened our knowledge of the neurobiological bases of drug abuse and addiction, and they address potential clinical and therapeutic applications.

Joanna S. Fowler, Ph.D.¹

Nora D. Volkow, M.D.²

Cheryl A. Kassed, Ph.D., M.S.P.H.³

Linda Chang, M.D.⁴

¹Brookhaven National Laboratory
Upton, New York

²National Institute on Drug Abuse
Bethesda, Maryland

³Thomson Medstat
Washington, D.C.

⁴John A. Burns School of Medicine,
University of Hawaii at Manoa, and the
Queen's Medical Center, Honolulu, Hawaii

Scientific advances over the last quarter century have established that drug addiction is a chronic brain disease (Leshner, 1997). Key evidence for this view consists of images of people's brains taken during or following drug exposures. Brain imaging studies have provided information on drugs' neurobiological effects, helped explain the causes and mechanisms of vulnerability to drug abuse, and yielded important insights into abusers' subjective experiences and behaviors, including their struggles in recovery. Clinicians may one day—perhaps sooner rather than later—use brain imaging to assess addiction, to assign patients to appropriate care interventions, and to monitor response to therapy.

The five primary brain imaging techniques—structural magnetic resonance imaging (MRI), functional MRI, magnetic resonance spectroscopy (MRS), positron emission tomography (PET), and single photon emission computed tomography (SPECT)—reveal different aspects of brain structure or function (Table 1). Individually, the techniques yield knowledge of brain anatomy and tissue composition; biochemical, physiological, and functional processes; neurotransmitter activity; energy utilization and blood flow; and drug distribution and kinetics. Together and in combination with other research techniques, they inform a multidimensional understanding of the complex disease that is drug abuse and addiction.

STRUCTURAL MRI

What It Tells

Structural MRI provides information on the location, shapes, and sizes of the brain's various regions and subregions (Figure 1). It also can demonstrate the presence of abnormal tissue and changes in tissue composition.

What It Shows

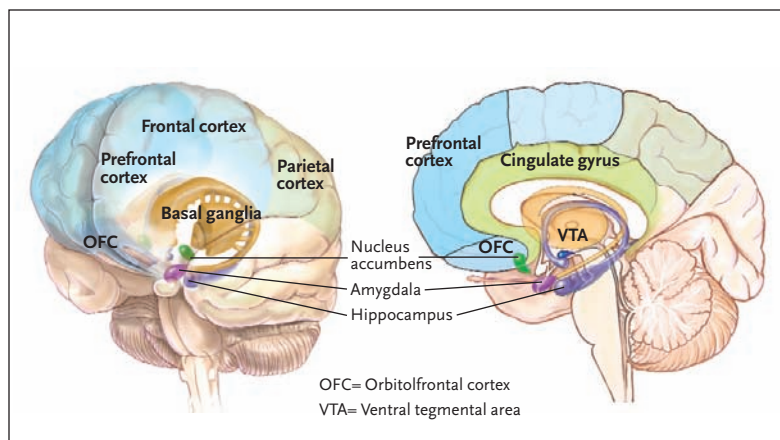
A structural MRI image is a picture of water molecules in a cross section or area of the brain. The technique takes advantage of the fact that different types of tissues contain different amounts of water. For example, of the two types of tissues that make up most of the brain, gray matter, which comprises mostly cell nuclei, is roughly 80 percent water, while white matter, which consists mainly of connecting fibers between cells, is about 70 percent water (Neeb, Zilles, and Shah, 2005). Structural MRI images show these differences in the water content as different tones of gray. To make structures of interest stand out better, scientists often use contrast agents to heighten the differences. Scientists reading an MRI can readily distinguish gray and white matter and other types of tissue—both normal, such as blood vessels, and abnormal, such as tumors—by their different shading and contrast with surrounding areas (Figure 2).

How It Works

An MRI machine can be compared to a camera, but one that registers radiofrequency energy reflected from the hydrogen atoms in water molecules instead of light from visible objects. The machine itself supplies the radiofrequency energy, somewhat analogous to the way a camera flashbulb bounces light off a scene and then captures the reflected light on film.

First, the machine generates a powerful magnetic field that pulls the protons at the centers of all the brain's hydrogen atoms into alignment, like tops all spinning straight up on their points (Figure 2). Next, the machine emits a brief pulse of radiofrequency energy. The pro-

FIGURE 1. Major brain regions with roles in addiction



The prefrontal cortex is the focal area for cognition and planning. The ventral tegmental area (VTA) and nucleus accumbens (NAc) are key components of the brain's reward system. The VTA, NAc, amygdala, and hippocampus are major components of the limbic system, which coordinates drives, emotions, and memories.

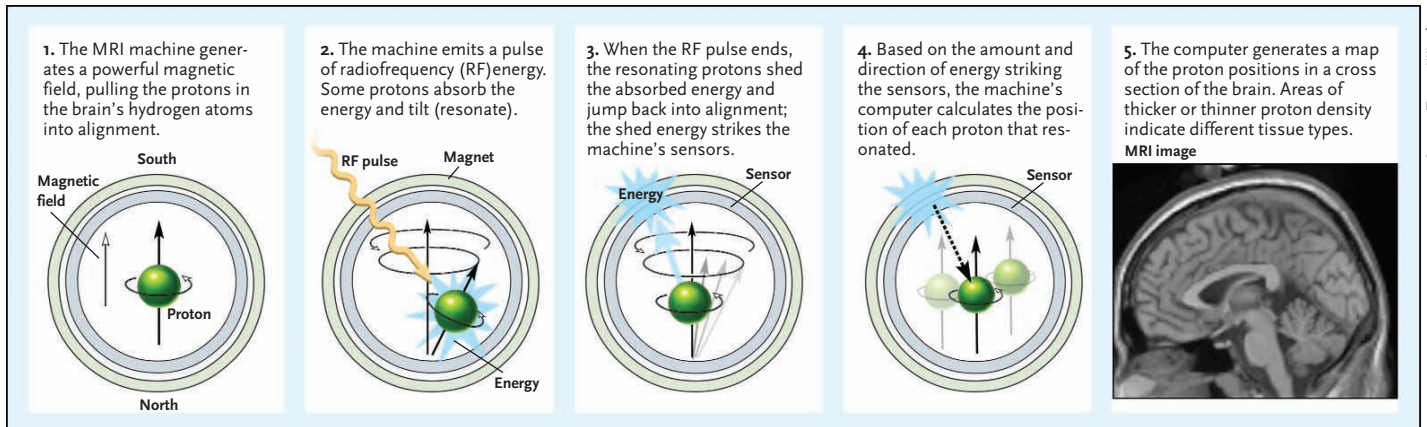
tons absorb this additional energy, which causes some of them to “resonate”—that is, to realign at an angle oblique to the magnetic field, like tops spinning on a tilt. For the fraction of a second that the pulse lasts, this subset of protons holds on to the energy. When the pulse ends, they shed it.

The machine's detection apparatus and computers pinpoint the source of every packet of emitted energy—in other words, the location of each hydrogen atom that resonated. Even though all protons do not resonate, enough do—out of the tens of billions in the brain—so that registering all their locations in the image produces a highly detailed map of the brain's tissues and structures.

TABLE 1. Brain imaging techniques used in drug abuse research

IMAGING TECHNIQUE	Structural magnetic resonance imaging (MRI)	Functional magnetic resonance imaging (fMRI)	Magnetic resonance spectroscopy (MRS)	Positron emission tomography (PET)	Single photon emission computed tomography (SPECT)
PRINCIPAL APPLICATIONS	Map tissue morphology, composition	Visualize changes in oxygenation and blood flow associated with brain activities	Measure cerebral metabolism, physiological processes involving specific brain chemicals; detect drug metabolites	Quantify biochemical and pharmacological processes, including glucose metabolism; drug distribution and kinetics; receptor-ligand interaction; enzyme targeting	Measure receptor-ligand interaction, physiological function, biochemical and pharmacological processes

FIGURE 2. Making a magnetic resonance image



© 2007 Terese Winslow

Insights From Structural MRI

Structural MRI studies have demonstrated that chronic drug exposure can enlarge or shrink some regions of the brain. These findings have helped scientists home in on the regions where drugs exert important effects. They often serve as starting points for further investigations, using other research tools and techniques, to determine the reasons for the volume changes and their consequences for individuals' thinking, feeling, and behavior.

Volume Changes in Frontal Cortex

The frontal cortex is a brain region that supports logical thinking, goal setting, planning, and self-control. Numerous MRI studies have documented that addictive drugs cause volume and tissue composition changes in this region and that these changes are likely associated with abusers' cognitive and decisionmaking problems.

Polysubstance effects: A structural MRI study found that individuals with a history of abusing multiple substances have smaller prefrontal lobes than matched controls (Liu et al., 1998). This finding adds to growing evidence associating prefrontal abnormalities with abuse of various substances (Stapleton et al., 1995; Volkow et al., 1991). Using structural MRI, Schlaepfer and colleagues (2006) found that chronic substance abusers' frontal lobe tissues contained a lower proportion of white matter than those of matched controls. Similar white matter deficits have been found in individuals with other psychiatric disorders that tend to co-occur with substance abuse (Schlaepfer et al., 2006).

Stimulants: Kim and colleagues (2005) documented a reduction in gray matter density in the right middle

frontal cortex of abstinent methamphetamine abusers (Figure 3). Lower density correlated with more errors on the Wisconsin Card Sorting Task, which tests a person's ability to switch mental gears. Gray matter was closer to normal in individuals who had been abstinent for more than 6 months than in others with a shorter period of abstinence. In another structural MRI study, cocaine abusers who had been abstinent for 20 days exhibited reduced gray matter density in regions of the frontal cortex. No differences were found with respect to white matter density (Matochik et al., 2003).

Alcohol: Investigators using structural MRI have reported diminished cortical gray matter, most prominently in the prefrontal cortex (PFC), in alcoholic patients in treatment (Pfefferbaum et al., 1998). In another study, researchers showed that alcohol-dependent individuals had reduced whole brain, prefrontal cortical, and parietal cortical gray matter compared with controls (Fein et al., 2002).

Two studies have shown alcoholics' frontal cortex and other structures beginning to recover their normal volumes within weeks of stopping drinking (Bendszus et al., 2001; Pfefferbaum et al., 1995; see also O'Neill, Cardenas, and Meyerhoff, 2001). For a good review on brain imaging in alcoholism, see Mann et al., (2001).

Volume Changes in Other Brain Structures

Several structural MRI studies have shown enlargement of the brain's basal ganglia in cocaine-dependent (Jacobsen et al., 2001) and methamphetamine-dependent (Chang et al., 2005a; Jernigan et al., 2005) subjects compared with healthy subjects. This is similar to enlarged basal ganglia structures seen in schizophrenic patients who

have been treated with typical antipsychotic medications (Gur et al., 1998). Because typical antipsychotics and psychostimulants both lead to occupation of dopamine receptors in the basal ganglia—the former directly and the latter indirectly, through releasing dopamine—these findings suggest the dopamine and basal ganglia structures are involved in the psychoses that occur in schizophrenia and in psychostimulant abuse.

An analysis of MRI images disclosed that a group of chronic methamphetamine abusers had severe gray matter deficits in the cingulate, limbic, and paralimbic cortices. They also had smaller hippocampi than nonabusers of drugs. The hippocampus is a key site for memory storage, and the volume decrements correlated with poorer performance on a word recall test (Thompson et al., 2004).

Another MRI study indicated that the amygdala, a brain structure that helps shape our emotional responses to experiences, is relatively small in children of alcoholics (Hill et al., 2001). This finding might be a clue to the brain sources of vulnerability to alcohol abuse disorders.

FUNCTIONAL MRI

What It Tells

Researchers read functional MRI images as maps of cellular activity levels in a cross section or area of the brain. In functional MRI studies, researchers compare multiple images, which may be of a single individual or different individuals.

Studies of a single individual taken under varying conditions—for example, at rest and then working on a puzzle, or before and after taking a drug—enable researchers to map which brain regions he or she activates to perform mental tasks (e.g., puzzle solving) or in response to experiences or chemical exposures. Studies of individuals from different groups—for example, drug-addicted and nonaddicted—can reveal differences in the brain regions the two groups use to perform identical tasks or respond to stimuli or exposures.

What It Shows

What a functional MRI machine actually detects are changes in the local magnetic field that occur as a result of changes in the ratio of oxygenated to deoxygenated hemoglobin in arterial blood vessels in specific brain regions during a cognitive task. The rationale for interpreting these changes as cellular activity is that cells in the brain, like those elsewhere in the body, use oxygen as fuel. As they increase their activity, they increase their

demand for oxygen, and the arterial blood vessels respond by delivering more oxygenated hemoglobin to the region.

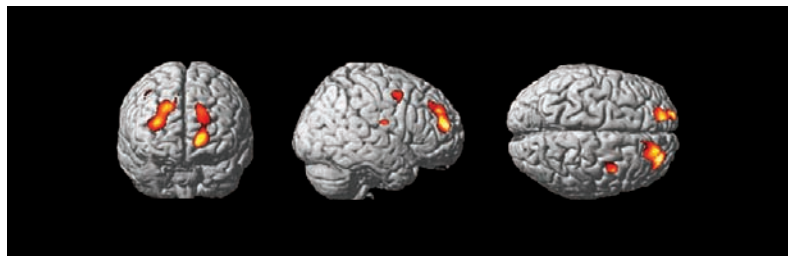
How It Works

Like structural MRI, functional MRI produces images by applying a magnetic field and detecting radiofrequency energy from the protons in water molecules. However, functional MRI exploits two additional facts, one biological and one physical:

- Biologically, the more oxygen that cells in a region utilize, the more oxygen-carrying hemoglobin molecules will be found in the blood vessels responsible for supplying them.
- Physically, hemoglobin molecules that have oxygen molecules attached to them and those that do not exert measurably different effects on the magnetic properties of surrounding tissues.

By tuning the magnets and energy pulses of the MRI machine to capture these differences, researchers produce images in which differences in oxygen content show up as variations in tone or color. This is called blood oxygen level dependent, or BOLD, contrast.

FIGURE 3. MRI: Methamphetamine reduces gray matter



The yellow and red area in the central brain view indicates reduced gray matter density in the right middle frontal cortex (Kim et al., 2005). The same deficit is shown from other perspectives in the flanking views.

Insights From Functional MRI

The differences in brain activity patterns revealed by functional MRI provide invaluable information on a range of issues. Studies have correlated regional brain patterns in response to taking a drug with vulnerability to drug abuse, addictive symptoms and behaviors, and long-term cognitive capacity.

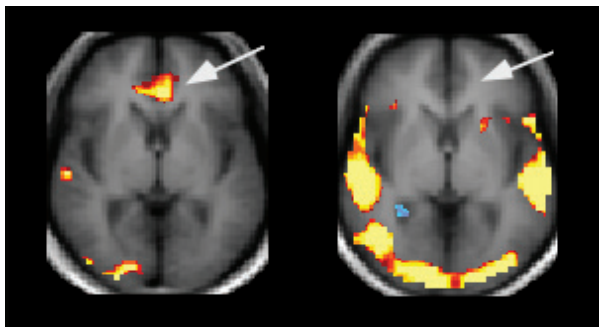
Stimulant Effects Correlate With Brain Activity in Several Areas

Researchers have used functional MRI to obtain detailed information about the roles of different brain areas in producing cocaine-induced euphoria and subsequent craving. In one investigation, volunteers given an infu-

sion of cocaine reported a drug rush during the brief period when a set of areas, including the caudate (an area of the basal ganglia), cingulate, and most of the lateral PFC showed higher levels of activity. The participants' reports of craving commenced when the euphoria subsided and persisted as long as a different set of brain areas—including the nucleus accumbens (NAc)—remained activated (Breiter et al., 1997; Breiter and Rosen, 1999). Two more recent studies also saw correlations between craving and NAc activity, although—possibly because of differences in study methods—the “high” was associated with decreased rather than increased brain activity in regions including the NAc, inferior frontal/orbitofrontal gyrus, and anterior cingulate. Craving correlated positively with activity in these regions (Kufahl et al., 2005; Risinger et al., 2005).

Other functional MRI studies have demonstrated that cocaine-addicted individuals' vulnerability to cocaine-related cues has a neurological basis. For example, Wexler and colleagues (2001) documented activation of the anterior cingulate cortex, a region associated with emotional processing, while cocaine-addicted subjects watched videotapes containing cocaine-associated cues, even if they did

FIGURE 4. Functional MRI: The brain's response to cocaine cues



Arrows point to the anterior cingulate area, which is activated (yellow) in cocaine-addicted patients (left) but not in healthy volunteers (right) (Wexler et al., 2001).

during the cocaine cue tapes, suggesting that their ability to control their cue responses was inhibited. Research with functional MRI has linked chronic stimulant abusers' cognitive impairments to drug-related alterations in brain activation. In one study, methamphetamine dependence and poor decisionmaking correlated with reduced activation in the PFC (Paulus et al., 2002). In another, investigators discovered that chronic cocaine abusers had abnormally low levels of activity in midline areas of the anterior cingulate that are crucial for cognitive and behavioral control (Kaufman et al., 2003).

Genes Affect Responses to Drugs and Vulnerability to Abuse

Innovative functional MRI studies recently have begun to explore the role of genes in drug abuse. In one, a gene variation that affects the metabolism of neurotransmitters, including dopamine and norepinephrine, appeared to influence the brain's response to amphetamine (Mattay et al., 2003). A similar functional MRI study discovered that individuals with a particular variation in the serotonin transporter gene experienced greater activation in the amygdala, a region associated with fear and anxiety, in response to fearful stimuli (Hariri et al., 2002). This genetic variation could increase sensitivity to stress and heighten vulnerability to drug abuse.

MAGNETIC RESONANCE SPECTROSCOPY

What It Tells

In addition to creating structural and functional maps of the brain, magnetic resonance technology can be used to detect and measure important chemical contents within the brain. To be visible in an MRS image, a chemical must respond in a unique way to magnetization and energy stimulation, and it must be present in relatively high concentrations (in the millimolar range).

What It Shows

MRS scans reveal the location and concentrations of target chemicals in the brain tissues (Ross, Kreis, and Ernst, 1992). Among chemicals naturally present in the brain, two that can be studied with MRS include N-acetylaspartate (NAA), which researchers use as a gauge of neuronal cell health (Birken and Oldendorf, 1989), and myo-inositol, which is primarily present in support cells, called glia (Brand, Richter-Landsberg, and Leibfritz, 1993), and thus provides an index of the health of glial cells. Other molecules that can be detected easily are choline compounds, which are involved in the turnover of cell membranes, and creatine compounds, which are important for cells' energy maintenance. Among substances of abuse that penetrate the brain after being ingested or administered, alcohol is readily apparent with MRS (Hetherington et al., 1999).

How It Works

MRS, like functional MRI, follows the basic steps of structural MRI, but uses different scanner settings. In MRS, the magnetic pulses and radiofrequency energy are used to stimulate the nucleus of particular elements (e.g., hydrogen-1, carbon-13, phosphorous-31, or flu-

orine-19) that are present in metabolites of interest throughout the brain. The sum of all these signals is recorded and then analyzed using specialized computer programs to separate the signals corresponding to each metabolite. The results can be displayed as various metabolite peaks on a spectrum.

Insights From MRS

Researchers have used MRS to identify drug-related biochemical changes that indicate damage to the health and function of brain cells. Often, these studies focus on brain areas that preclinical models or other studies of the neuropathology of drug abusers have shown to be affected. In some cases, biochemical changes have been directly correlated with cognitive and behavioral deficits.

A central finding of MRS studies has been that drugs affect markers associated with inflammation, brain energy metabolism, and neuronal health. For example, Ernst and colleagues (2000) showed that methamphetamine abusers had reduced NAA concentrations in their basal ganglia and frontal white matter, compared with nonabusers of drugs. This finding could help explain the cognitive difficulties experienced by methamphetamine abusers; concentrations of NAA have correlated with measures of cognitive function even in healthy nondrug users (Rae et al., 1998).

Cocaine-dependent individuals also have been found to have decreased NAA levels, suggesting neuron damage, as well as elevated creatine and myoinositol levels reflecting increased glial cell activity or inflammation (Chang et al., 1999).

Other research has evaluated interactions between HIV and drugs of abuse on brain metabolites. For example, a study found that methamphetamine abuse and HIV decreased brain NAA additively, especially in the striatum, while choline and myoinositol were further elevated in the frontal lobes (Chang et al., 2005 *b*). Chronic marijuana use and HIV infection are each separately associated with lower levels of glutamate; together, they appear to moderate glutamate loss in the frontal white matter while exacerbating it in the basal ganglia (Chang et al., 2006).

Magnetic resonance techniques, including MRS, are especially useful for studying the effects of drugs in the pediatric population because they do not involve radiation. Smith and colleagues (2001 *a*, 2001 *b*) conducted MRS studies of children who had been exposed to cocaine or methamphetamine prenatally and found

that their total brain creatine levels were elevated, suggesting abnormalities in energy metabolism.

NUCLEAR MEDICINE IMAGING TECHNIQUES

PET and SPECT are called “nuclear medicine techniques” because they require injecting molecules labeled with radioactive isotopes into the bloodstream of the person being studied. Because the half-lives of the isotopes are short, the radiation dose is small, on the order of other medical diagnostic procedures, and studies can be carried out in healthy volunteers as well as in drug-addicted patients. However, PET and SPECT are not normally used in healthy children.

What They Tell

PET and SPECT, like MRS, map the presence of specific molecules in the brain. These techniques are particularly valuable in drug abuse research because they can measure concentrations of molecules that are extremely low—in the nanomolar and picomolar range, one millionth to one billionth the minimum amounts necessary for visibility in MRS (Fowler, Ding, and Volkow, 2003; Kung, Kung, and Choi, 2003). This level of sensitivity enables researchers to study drugs’ effects on key components of cell-to-cell communication, including cell receptors, transporters, and enzymes involved in the synthesis or metabolism of neurotransmitters (Volkow, Fowler, and Wang, 2003 *a*).

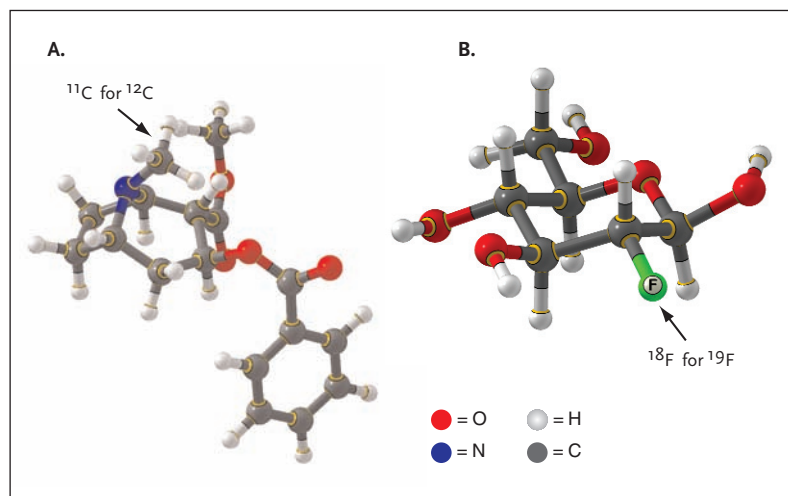
Researchers also use PET to study drug pharmacokinetics: A series of images taken at appropriate intervals provides a stop-action record of a drug’s movement into and out of the brain, showing how much enters the brain, where it binds in the brain, and how long it remains (Fowler et al., 1999). This information is crucial because the rate at which a drug enters the brain largely determines its euphoric effects and addictiveness. PET can also assess rates of glucose metabolism, complementing functional MRI measurement of changes in blood oxygen levels for determining cellular activity. A common use for SPECT is to measure brain blood flow.

What They Show

A PET or SPECT image displays the distribution of a labeled compound, called a radiotracer, that travels to the brain and other organs after being injected into the bloodstream. A radiotracer consists of two linked components:

- a carrier chemical, usually an organic compound or drug, whose properties determine where the radio-

FIGURE 5. Creating radiotracers for PET imaging



(A) Chemists replace a naturally occurring carbon 12 atom in the cocaine molecule with a carbon 11 atom to make [^{11}C] cocaine, a radiotracer that acts just like natural cocaine in the body and brain. [^{11}C] cocaine decays by positron emission, resulting in two energetic photons that are detected by a PET scanner to produce an image of glucose metabolism in the brain. (B) Chemists replace a hydroxyl (-OH) group on the glucose molecule with fluorine-18 to make ^{18}F FDG, a radiotracer which is used to measure brain glucose metabolism.

tracer goes once it reaches the brain; and

- a radioactive isotope, which is bound to, or “labels,” the carrier chemical and emits energy as products of its radioactive decay.

The emitted energy interacts with detectors in the PET or SPECT instrument. The instrument’s computers register the location of the radioisotope and use this information to calculate and map the radiotracer’s distribution in the brain or body.

How They Work

PET and SPECT are similar technologies. As their names suggest, their differences relate mainly to their use of different types of isotopes in their radiotracers.

PET radiotracers incorporate isotopes that emit beta positron (β^+) radiation. One especially important set of PET radiotracers incorporates positron-emitting isotopes of the chemical elements of life—carbon, oxygen, and nitrogen—into organic compounds in place of the naturally occurring nonradioactive elements. Substituting radioactive carbon-11 for nonradioactive carbon-12 in a drug molecule, for example, does not change the drug’s behavior in the brain, but does make it visible on PET imaging (Figure 5).

One uniquely valuable PET tool is 2-deoxy-2- [^{18}F] fluoro-D-glucose (^{18}F FDG), a radiotracer used to measure brain glucose metabolism. ^{18}F FDG consists of a glu-

cose molecule in which the radioactive isotope fluorine-18 has been substituted for the naturally occurring hydroxyl group (Fowler and Ido, 2002). PET’s ability to produce an image of glucose metabolism in the brain using ^{18}F FDG is a major advantage, as glucose, along with oxygen, is a major source of the organ’s energy.

Many PET studies have explored the role of the neurotransmitter dopamine in drug abuse and addiction. The radiotracers for these studies use as carrier components chemicals that bind to dopamine-related structures on brain cells, including dopamine receptors, dopamine transporters, and dopamine-degrading and synthetic enzymes (Halldin et al., 2001; Rinne et al., 1995; Volkow et al., 1995, 1996a; Wong et al., 1993).

SPECT radiotracers are labeled with single photon emitting radioisotopes. The most commonly used are iodine-123 and technetium-99m.

Insights From Nuclear Medicine Imaging Techniques

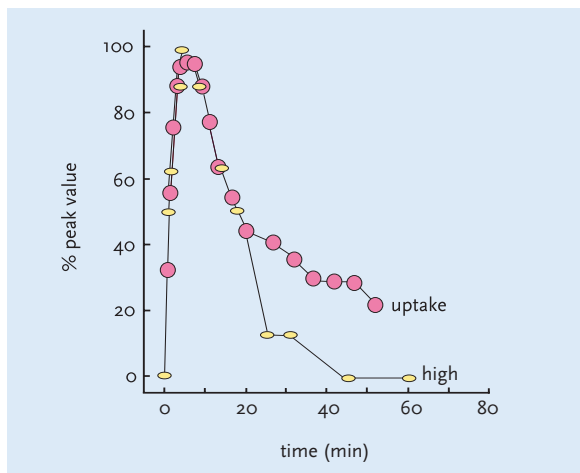
PET and SPECT brain imaging have perhaps shown their greatest value to date in helping researchers analyze how drugs affect the neurotransmitter systems that link and coordinate brain cells. Much of this work has focused on the dopamine system, but researchers also are exploring the roles of other neurotransmitters in drug abuse and drugs’ effects on cells’ energy consumption and health.

Dopamine Plays Key Roles in Drug Abuse Euphoria and Addiction

The neurotransmitter dopamine is highly concentrated in the striatum, which forms part of the brain’s reward system. Dopamine ebb and flow in these areas is a main determinant of how much pleasure we derive from our experiences; it also helps us focus our attention on what is important. PET studies have linked the presence and actions of drugs of abuse in the brain’s reward system with their euphoric properties and their ability to preoccupy addicted individuals to the exclusion of naturally rewarding activities (Di Chiara, 1999; Di Chiara and Imperato, 1988; Leshner, 1997; Volkow, Fowler, and Wang, 2003b).

In one study, researchers administered carbon-11-labeled cocaine to drug abusers who had refused treatment (a requirement for ethical review board approval) and used PET imaging to track the movement of the drug into and out of the brain while the abusers reported the intensity of their highs. The results showed that the

FIGURE 6. PET: Cocaine activity in the striatum underlies the cocaine high



After study subjects were given [^{11}C] cocaine, PET showed that their reports of how high they felt rose and fell in very close parallel with the passage of the drug in and out of the brain area called the striatum (Volkow et al., 1997).

high spiked and subsided in tandem with cocaine's movement in and out of the striatum (Volkow et al., 1997; Figure 6). Using the same experimental design with different radiotracers, PET and SPECT investigators established that cocaine, amphetamine, and methylphenidate, when given intravenously, produce their highs by massively increasing the amount of dopamine in the striatum (Drevets et al., 2001; Laruelle et al., 1995; Volkow et al., 1999). Previous studies with animals had suggested that this was probably the case, but nuclear medicine imaging enabled researchers to noninvasively document the correlation as it actually occurred in living people. Still other PET studies have shown that any drug's abuse liability depends both on the size of the dopamine spike it produces and the rapidity with which dopamine rises and falls back to normal levels.

PET experiments have identified how one drug, cocaine, causes dopamine to surge: The drug interferes with the normal activity of molecules called dopamine transporters on brain cell surfaces (Figure 7). By doing so, it disrupts the equilibrium of dopamine release and reuptake that maintains levels of the neurotransmitter within normal limits.

Chronic Methamphetamine Abuse Depletes Dopamine Function

A PET study revealed that while methamphetamine temporarily hyperactivates the dopamine system, chronic exposure to the drug reduces the availability of dopamine

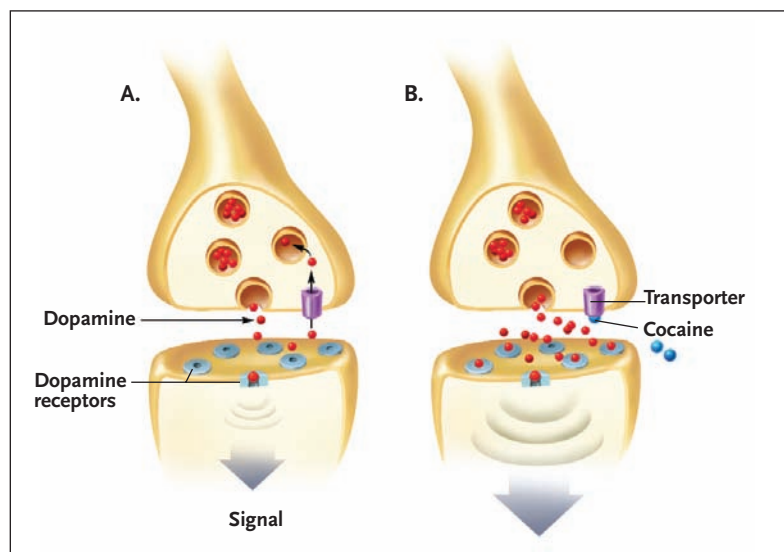
transporters, which may indicate a loss of dopamine cells (Volkow et al., 2001 *b*). Study participants with fewer dopamine transporters had poorer memory and slower motor function.

Stimulants Reduce Cellular Activity in Brain Areas Affecting Judgment

PET studies have explored cocaine's impact on brain structures and activity, and their relationship to addicted individuals' ability to function during and after treatment. Among important results in this line, studies have shown that cocaine (Volkow et al., 1993) and methamphetamine (Bolla et al., 2003; Volkow et al., 2001 *a*) reduce cellular activity in the orbitofrontal cortex (OFC), a brain area we rely on to make strategic, rather than impulsive, decisions (Figure 8). Patients with traumatic injuries to this area of the brain display problems—aggressiveness, poor judgment of future consequences, inability to inhibit inappropriate responses—that are similar to those observed in substance abusers (Bechara et al., 1994, 2001; Eslinger et al., 1992). The radiotracers used in these studies were ^{18}F FDG and oxygen-15 water, which measure the brain's consumption of its two main fuels, glucose and oxygen (Raichle et al., 1983).

Bolla and colleagues (2003) demonstrated the link between lower metabolism in the OFC and cocaine abusers' poor judgment. The researchers took serial PET images, using oxygen-15 water as the radiotracer, while

FIGURE 7. PET: Cocaine causes dopamine buildup in the synapse



In this illustration based on PET studies, cocaine blocks the dopamine transporter, preventing it from pulling dopamine back into the sending cell. As a result, dopamine molecules accumulate in the intercellular space, striking the receiving cell's receptors and causing an intensified response within the receiving cell.

cocaine abusers who had been abstinent for 25 days played a card game on a computer. Players who had used more cocaine before abstaining demonstrated less OFC activity, and they performed more poorly during the game.

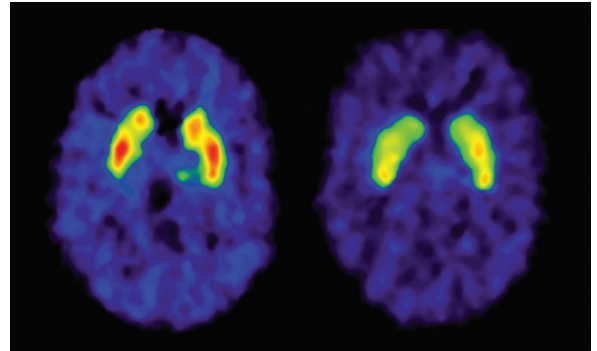
Dopamine Receptor Levels May Determine Vulnerability to Abuse and Addiction

PET studies have demonstrated that abusers of alcohol (Volkow et al., 1996*b*), cocaine (Volkow et al., 1990, 1993), heroin (Wang et al., 1997), and methamphetamine (Volkow et al., 2001*a*) all have reduced levels of brain dopamine receptors—the proteins on cell surfaces that dopamine activates to stimulate cellular activity (Figure 9). These findings, together with other evidence, have given rise to a hypothesis that people with low levels of these receptors, either genetically or as a result of their experiences, have a higher risk of drug abuse and addiction. Scientists speculate that such individuals obtain less than normal amounts of dopamine-mediated pleasure from ordinary activities and accomplishments and therefore are highly susceptible to wanting to repeat the euphoria that occurs when drugs massively increase dopamine in the brain.

The Mu-opioid System Plays a Role in Cocaine Craving

PET studies have suggested that the symptoms of cocaine dependence and craving may be caused at least in part by the drug's effects on another neurotransmitter system, the mu-opioid system. In one study (Zubieta et al., 1996), cocaine-addicted individuals who entered a clinic

FIGURE 9. PET: Cocaine markedly reduces dopamine D2 receptor availability



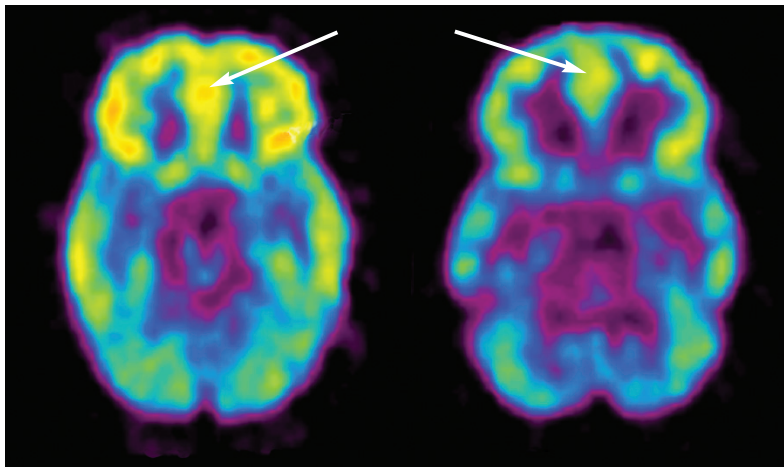
The striatum of the healthy control (left) is largely red, indicating the highest level of receptor availability, while that of the cocaine abuser has little red.

to quit the drug and remained there for a month of monitored abstinence filled out assessments of their mood and craving symptoms and underwent PET scans, once during their first 4 days in the clinic and again toward the end of the month. Using a radiotracer whose carrier component is an opioid medication (carbon-11 carfentanil), researchers found that the participants' symptom severity correlated with mu-opioid receptor levels in several brain areas. In interpreting their findings, the researchers suggested that cocaine may deplete the body's natural opioids, and the body may try to compensate by generating more receptors or increasing existing receptors' readiness to bind to opioid molecules.

Nicotine Is Not the Sole Culprit in Tobacco Addiction

PET imaging studies have affirmed the importance of dopamine in nicotine abuse and addiction (Brody et al., 2004) and also highlighted the need to investigate the other chemicals in tobacco smoke. Recent studies have found that one or more components of tobacco smoke reduces levels of monoamine oxidase (MAO) in the brain and throughout the body (Fowler et al., 1996*a*, 1996*b*, 2003*a*, 2003*b*, 2005; Figure 10). MAO is an enzyme that breaks down neurotransmitters; its two forms, MAO-A and MAO-B, perform different functions although both break down dopamine. One consequence of MAO inhibition by tobacco smoke may be exacerbation of the nicotine-induced dopamine dysregulation that reinforces the desire to smoke as well as to abuse other substances. Consistent with this idea, recent preclinical studies show that inhibiting MAO-A enhances nicotine self-administration in animals

FIGURE 8. PET: Cocaine abusers have reduced metabolism in the orbitofrontal cortex



In this comparison of a healthy subject (left) and a cocaine abuser, red represents the highest and blue and purple the lowest level of metabolic activity, as measured by ^{18}F FDG.

(Guillem et al., 2006). In contrast, in a recent trial using the selective MAO-B inhibitor selegiline, a dose of 10 mg/day safely enhanced smoking cessation rates compared with placebo in nicotine-dependent cigarette smokers (George et al., 2003).

The PET finding that smokers have low levels of MAO sheds light on why smokers have a reduced risk of Parkinson's disease (Morens et al., 1995). When MAO metabolizes dopamine, a byproduct is hydrogen peroxide, a potential source of free radicals that can damage nerve cells. MAO-inhibiting chemical compounds have been isolated from tobacco (Khalil, Steyn, and Castagnoli, 2000) and shown to have protective actions in a rodent model of Parkinson's disease (Castagnoli et al., 2002).

CLINICAL APPLICATIONS OF IMAGING

The information that magnetic resonance and nuclear imaging studies have yielded on the brain dynamics of addiction has become a primary source of medication development strategies. Direct clinical applications are still few, but recent studies suggest the techniques may in the future enhance patient assessment and monitoring.

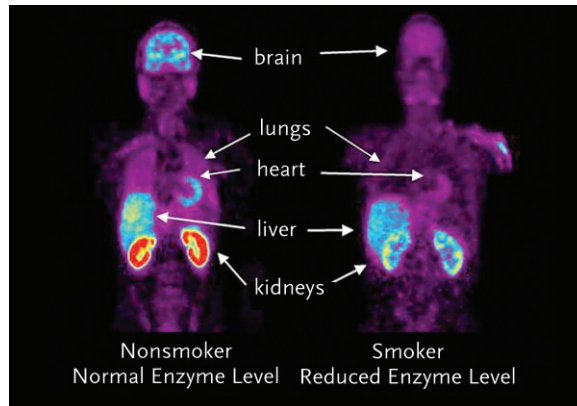
Medication Development

Imaging studies, together with other research, overwhelmingly indicate that drug addiction must be viewed as both a disease of changed brain biology and a behavioral disorder. To be effective over the long term, treatment should focus on enhancing and restoring disrupted dopamine function and brain circuitry, and include pharmacologic and behavioral approaches.

In the area of pharmacologic interventions in particular, imaging findings have suggested many avenues of possible approach. One strategy under active investigation takes its cue from the PET finding that stimulant drugs produce euphoria by causing a rapid dopamine spike and, in doing so, reduce abusers' ability to feel pleasure when their other, nondrug-related activities cause more modest, natural neurotransmitter elevations (see Volkow et al., 2004, for a review). Researchers are identifying and testing medications that slightly increase the amount of dopamine that cells release when a person engages in normally rewarding activities in hopes that the boost will enable addicted individuals to once again begin to feel pleasure from them. MAO-B inhibitors and other medications fitting this criterion have been used successfully to treat smoking addiction (George et al., 2003).

Another medication strategy, also following from

FIGURE 10. PET: Smoking reduces an important enzyme



In these composite PET images of smokers and nonsmokers, arrows demonstrate lower concentrations of the enzyme monoamine oxidase in many of the smokers' organs (Fowler et al., 2003b).

imaging evidence that dopamine spikes underlie drug euphoria, seeks to reduce the stimulant high and the desire to repeat it by inhibiting the dopamine response to these drugs. In one application of this strategy, researchers are testing compounds that enhance the neurotransmitter gamma-aminobutyric acid (GABA), which has been shown to inhibit dopamine-releasing cells' response to drug-related cues (Di Ciano and Everitt, 2003); preliminary clinical trials have yielded promising results (Brodie et al., 2005; Brodie, Figueroa, and Dewey, 2003; Gonzalez et al., 2003; Johnson et al., 2003). Other medications interfere with the responses of dopamine-receiving cells and thereby attenuate the reinforcing effects of abused drugs. For example, selective cannabinoid receptor (CB1) antagonists have been shown to modulate both dopamine-releasing and -receiving cell responses in pre-clinical studies (De Vries et al., 2001; Julian et al., 2003).

A third strategy to counter drug-induced euphoria and its hold over individuals utilizes a medication that activates the same neurotransmitter system as an abused drug, but produces no sharp dopamine spike. Treatment of heroin addiction with methadone and buprenorphine exemplifies this approach (Kreek, LaForge, and Butelman, 2002). Similar attempts to treat stimulant addiction have not yet proved successful. Replacement of cocaine with oral methylphenidate or oral amphetamine did not decrease cocaine consumption when compared with placebo in most drug-addicted individuals. However, treatment with oral methylphenidate did decrease drug consumption by patients suffering from comorbid addiction and attention deficit hyperactivity disorder (Grabowski

et al., 1997; Shearer et al., 2003; Volkow, Fowler, and Wang, 2004).

Patient Assessment and Monitoring

Recent studies suggest that imaging has the potential to help clinicians determine the most appropriate level of treatment for individual patients and monitor their progress toward recovery. Paulus, Tapert, and Schuckit (2005) performed functional MRI on a group of men

entering treatment for methamphetamine addiction while they made decisions during a psychological test.

The results revealed two contrasting patterns of brain activity that predicted with 90 percent accuracy which of the men would relapse within 1 to 3 years after completing treatment. Those who relapsed exhibited less activity in the

prefrontal lobe and also in regions not previously noted to play a role in addiction. Another study found that a more rapid response of the posterior cingulate to cocaine cues distinguished relapsers from nonrelapsers, even though both groups reported similarly intense cravings (Kosten et al., 2006).

Imaging researchers also have been documenting changes that appear to represent brain recovery in response to treatment. One group has applied MRS to evaluate the effects of methadone maintenance therapy on heroin-addicted individuals (Silveri et al., 2004). The subjects' levels of certain metabolites involved in cellular energy production were abnormal at the start of treatment and changed over the first month. The researchers interpreted the metabolite changes as evidence that the switch from heroin to methadone might improve the neurons' oxygen supply. This explanation may account for the finding in another study by the same research group that individuals' cognitive abilities improve during their first 2 months of methadone therapy (Gruber et al., 2006).

CONCLUSION

Brain imaging techniques enable researchers to observe drug effects while they are occurring in the brain and compare brain structure, function, and metabolism in drug-abusing and nonabusing individuals. The results to date have firmly established that drug addiction is a disease of the brain, causing important derangements in many areas, including pathways affecting reward and cognition. Ongoing studies continue to broaden our understanding of the dynamics underlying the development, symptoms, and consequences of addiction, as well as recovery. Having given rise to several potential approaches to medication development, imaging technologies are certain to become an increasingly important source of clinical benefits.

ACKNOWLEDGMENTS

Some of the work described in this article was performed at Brookhaven National Laboratory under contract DEAC02-98CH10886 with the U.S. Department of Energy and was supported by its Office of Biological and Environmental Research and by the National Institute on Drug Abuse (K24-DA16170 and K05-DA020001) and NIH GCRC (MO1RR10710).

CORRESPONDENCE


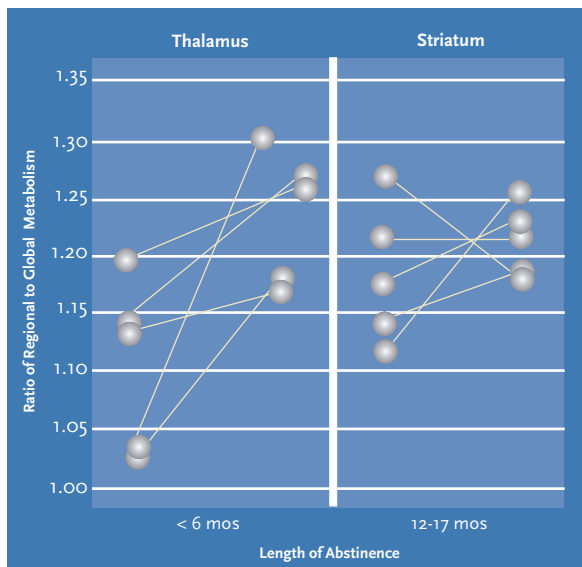
Joanna S. Fowler, Ph.D., Medical Department, Brookhaven National Laboratory, Upton, NY 11973; e-mail: fowler@bnl.gov. 

FIGURE 11. PET: Brain recovery occurs with methamphetamine abstinence



PET studies in methamphetamine abusers show that brain metabolism is depressed in the thalamus and striatum shortly after quitting methamphetamine but partly recovers in the thalamus after protracted abstinence (Wang et al., 2004).

prefrontal lobe and also in regions not previously noted to play a role in addiction. Another study found that a more rapid response of the posterior cingulate to cocaine cues distinguished relapsers from nonrelapsers, even though both groups reported similarly intense cravings (Kosten et al., 2006).

Imaging researchers also have been documenting changes that appear to represent brain recovery in response to treatment. One group has applied MRS to evaluate the effects of methadone maintenance therapy on heroin-addicted individuals (Silveri et al., 2004). The subjects' levels of certain metabolites involved in cellular energy production were abnormal at the start of treatment and changed over the first month. The researchers interpreted the metabolite changes as evidence that the switch from

REFERENCES

- Bechara, A., et al., 1994. Insensitivity to future consequences following damage to human prefrontal cortex. *Cognition* 50(1-3):7-15.
- Bechara, A., et al., 2001. Decision-making deficits, linked to a dysfunctional ventromedial prefrontal cortex, revealed in alcohol and stimulant abusers. *Neuropsychologia* 39(4):376-389.
- Bendszus, M., et al., 2001. Sequential MR imaging and proton MR spectroscopy in patients who underwent recent detoxification for chronic alcoholism: Correlation with clinical and neuropsychological data. *American Journal of Neuroradiology* 22(10):1926-1932.
- Birken, D.L., and Oldendorf, W.H., 1989. N-acetyl-L-aspartic acid: A literature review of a compound prominent in ¹H-NMR spectroscopic studies of brain. *Neuroscience and Biobehavioral Reviews* 13(1):23-31.
- Bolla, K.I., et al., 2003. Orbitofrontal cortex dysfunction in abstinent cocaine abusers performing a decision-making task. *Neuroimage* 19(3):1085-1094.
- Brand, A.; Richter-Landsberg, C.; and Leibfritz, D., 1993. Multinuclear NMR studies on the energy metabolism of glial and neuronal cells. *Developmental Neuroscience* 15(3-5):289-298.
- Breiter, H.C., et al., 1997. Acute effects of cocaine on human brain activity and emotion. *Neuron* 19(3):591-611.
- Breiter, H.C., and Rosen, B.R., 1999. Functional magnetic resonance imaging of brain reward circuitry in the human. *Annals of the New York Academy of Sciences* 877:523-547.
- Brodie, J.D., et al., 2005. Safety and efficacy of gamma-vinyl GABA (GVG) for the treatment of methamphetamine and/or cocaine addiction. *Synapse* 55(2):122-125.
- Brodie, J.D.; Figueroa, E.; and Dewey, S.L., 2003. Treating cocaine addiction: From preclinical to clinical trial experience with gamma-vinyl GABA. *Synapse* 50(3):261-265.
- Brody, A.L., et al., 2004. Smoking-induced ventral striatum dopamine release. *American Journal of Psychiatry* 161(7):1211-1218.
- Castagnoli, K., et al., 2002. Studies on the interactions of tobacco leaf and tobacco smoke constituents and monoamine oxidase. *Neurotoxicity Research* 4(2):151-160.
- Chang, L., et al., 1999. Gender effects on persistent cerebral metabolite changes in the frontal lobes of abstinent cocaine users. *American Journal of Psychiatry* 156(5):716-722.
- Chang, L., et al., 2005a. Enlarged striatum in abstinent methamphetamine abusers: Possible compensatory response. *Biological Psychiatry* 57(9):967-974.
- Chang, L., et al., 2005b. Additive effects of HIV and chronic methamphetamine use on brain metabolite abnormalities. *American Journal of Psychiatry* 162(2):361-369.
- Chang, L., et al., 2006. Combined and independent effects of chronic marijuana use and HIV on brain metabolites. *Journal of NeuroImmune Pharmacology* 1(1):65-76.
- Daurignac, E., et al., 2005. Applications of morphometric and diffusion tensor magnetic resonance imaging to the study of brain abnormalities in the alcoholism spectrum. *Alcoholism: Clinical and Experimental Research* 29(1):159-166.
- De Vries, T.J., et al., 2001. A cannabinoid mechanism in relapse to cocaine seeking. *Nature Medicine* 7(10):1151-1154.
- Di Chiara, G., 1999. Drug addiction as dopamine-dependent associative learning disorder. *European Journal of Pharmacology* 375(1-3):13-30.
- Di Chiara, G., and Imperato, A., 1988. Drugs abused by humans preferentially increase synaptic dopamine concentrations in the mesolimbic system of freely moving rats. *Proceedings of the National Academy of Sciences of the USA* 85(14):5274-5278.
- Di Ciano, P., and Everitt, B.J., 2003. The GABA(B) receptor agonist baclofen attenuates cocaine- and heroin-seeking behavior by rats. *Neuropsychopharmacology* 28(3):510-518.
- Drevets, W.C., et al., 2001. Amphetamine-induced dopamine release in human ventral striatum correlates with euphoria. *Biological Psychiatry* 49(2):81-96.
- Ernst, T., et al., 2000. Evidence for long-term neurotoxicity associated with methamphetamine abuse: A ¹H MRS study. *Neurology* 54(6):1344-1349.
- Eslinger, P.J., et al., 1992. Developmental consequences of childhood frontal lobe damage. *Archives of Neurology* 49(7):764-769.
- Fein, G., et al., 2002. Cortical gray matter loss in treatment-naïve alcohol dependent individuals. *Alcoholism: Clinical and Experimental Research* 26(4):558-564.
- Fowler, J.S.; Ding, Y.S.; and Volkow, N.D., 2003. Radiotracers for positron emission tomography imaging. *Seminars in Nuclear Medicine* 33(1):14-27.
- Fowler, J.S., et al., 1996a. Inhibition of monoamine oxidase B in the brains of smokers. *Nature* 379(6567):733-736.
- Fowler, J.S., et al., 1996b. Brain monoamine oxidase A inhibition in cigarette smokers. *Proceedings of the National Academy of Sciences of the USA* 93(24):14065-14069.
- Fowler, J.S., et al., 1999. PET and drug research and development. *Journal of Nuclear Medicine* 40(7):1154-1163.
- Fowler, J.S., and Ido, T., 2002. Initial and subsequent approach for the synthesis of ¹⁸F-DG. *Seminars in Nuclear Medicine* 32(1):6-12.
- Fowler, J.S., et al., 2003a. Monoamine oxidase and cigarette smoking. *Neurotoxicology* 24(1):75-82.
- Fowler, J.S., et al., 2003b. Low monoamine oxidase B in peripheral organs in smokers. *Proceedings of the National Academy of Sciences of the USA* 100(20):11600-11605.
- Fowler, J.S., et al., 2005. Comparison of monoamine oxidase A in peripheral organs in nonsmokers and smokers. *Journal of Nuclear Medicine* 46(9):1414-1420.
- George, T.P., et al., 2003. A preliminary placebo-controlled trial of selegiline hydrochloride for smoking cessation. *Biological Psychiatry* 53(2):136-143.
- Gilmore, J.H.; Lin, W.; and Gerig, G., 2006. Fetal and neonatal brain development. *American Journal of Psychiatry* 163(12):2046.
- Gonzalez, G., et al., 2003. Tiagabine increases cocaine-free urines in cocaine-dependent methadone-treated patients: Results of a randomized pilot study. *Addiction* 98(11):1625-1632.
- Grabowski, J., et al., 1997. Replacement medication for cocaine dependence: Methylphenidate. *Journal of Clinical Psychopharmacology* 17(6):485-488.
- Gruber, S.A., et al., 2006. Methadone maintenance improves cognitive performance after two months of treatment. *Experimental and Clinical Psychopharmacology* 14(2):157-164.
- Guillem, K., et al., 2006. Monoamine oxidase A rather than monoamine oxidase B inhibition increases nicotine reinforcement in rats. *European Journal of Neuroscience* 24(12):3532-3540.
- Gur, R.E., et al., 1998. Subcortical MRI volumes in neuroleptic-naïve and treated patients with schizophrenia. *American Journal of Psychiatry* 155(12):1711-1717.
- Halldin, C., et al., 2001. Brain radioligands—State of the art and new trends. *Quarterly Journal of Nuclear Medicine* 45(2):139-152.
- Hariri, A.R., et al., 2002. Serotonin transporter genetic variation and the response of the human amygdala. *Science* 297(5580):400-403.
- Hetherington, H.P., et al., 1999. Spectroscopic imaging of the uptake kinetics of human brain ethanol. *Magnetic Resonance in Medicine* 42(6):1019-1026.
- Hill, S.Y., et al., 2001. Right amygdala volume in adolescent and young adult offspring from families at high risk for developing alcoholism. *Biological Psychiatry* 49(11):894-905.
- Huang, H., et al., 2006. White and gray matter development in human fetal, newborn and pediatric brains. *Neuroimage* 33(1):27-38.
- Jacobsen, L.K., et al., 2001. Quantitative morphology of the caudate and putamen in patients with cocaine dependence. *American Journal of Psychiatry* 158(3):486-489.
- Jernigan, T.L., et al., 2005. Effects of methamphetamine dependence and HIV infection on cerebral morphology. *American Journal of Psychiatry* 162(8):1461-1472.
- Johnson, B.A., et al., 2003. Oral topiramate for treatment of alcohol dependence: A randomised controlled trial. *Lancet* 361(9370):1677-1685.
- Julian, M.D., et al., 2003. Neuroanatomical relationship between type 1 cannabinoid receptors and dopaminergic systems in the rat basal ganglia. *Neuroscience* 119(1):309-318.
- Kaufman, J.N., et al., 2003. Cingulate hypoactivity in cocaine users during a GO-NOGO task as revealed by event-related functional magnetic resonance imaging. *Journal of Neuroscience* 23(21):7839-7843.
- Khalil, A.A.; Steyn, S.; and Castagnoli, N., Jr., 2000. Isolation and characterization of a monoamine oxidase inhibitor from tobacco leaves. *Chemical Research in Toxicology* 13(1):31-35.
- Kim, S.J., et al., 2005. Prefrontal grey-matter changes in short-term and long-term abstinent methamphetamine abusers. *International Journal of Neuropsychopharmacology* 9(2):221-228.
- Kosten, T.R., et al., 2006. Cue-induced brain activity changes and relapse in cocaine-dependent patients. *Neuropsychopharmacology* 31(3):644-650.
- Kreek, M.J.; LaForge, K.S.; and Butelman, E., 2002. Pharmacotherapy of addictions. *Nature Reviews Drug Discovery* 1(9):710-726.

- Kufahl, P.R., et al., 2005. Neural responses to acute cocaine administration in the human brain detected by fMRI. *Neuroimage* 28(4):904-914.
- Kung, H.F.; Kung, M.P.; and Choi, S.R., 2003. Radiopharmaceuticals for single-photon emission computed tomography brain imaging. *Seminars in Nuclear Medicine* 33(1):2-13.
- Laruelle, M., et al., 1995. SPECT imaging of striatal dopamine release after amphetamine challenge. *Journal of Nuclear Medicine* 36(7):1182-1190.
- Leshner, A.I., 1997. Addiction is a brain disease, and it matters. *Science* 278(5335):45-47.
- Liu, X., et al., 1998. Smaller volume of prefrontal lobe in polysubstance abusers: A magnetic resonance imaging study. *Neuropsychopharmacology* 18(4):243-252.
- Mann, K., et al., 2001. Neuroimaging in alcoholism: Ethanol and brain damage. *Alcoholism: Clinical and Experimental Research* 25(5):1045-1095.
- Matochik, J.A., et al., 2003. Frontal cortical tissue composition in abstinent cocaine abusers: A magnetic resonance imaging study. *Neuroimage* 19(3):1095-1102.
- Mattay, V.S., et al., 2003. Catechol O-methyltransferase val158-met genotype and individual variation in the brain response to amphetamine. *Proceedings of the National Academy of Sciences of the USA* 100(10):6186-6191.
- Morens, D.M., et al., 1995. Cigarette smoking and protection from Parkinson's disease: False association or etiologic clue? *Neurology* 45(6):1041-1051.
- Neeb, H.; Zilles, K.; and Shah, N.J., 2005. Fully automated detection of cerebral water content changes: Study of age- and gender-related H₂O patterns with quantitative MRI. *Neuroimage* 29(3):910-922.
- O'Neill, J.; Cardenas, V.A.; and Meyerhoff, D., 2001. Effects of abstinence on the brain: Quantitative magnetic resonance imaging and magnetic resonance spectroscopic imaging in chronic alcohol abuse. *Alcoholism: Clinical and Experimental Research* 25(11):1673-1682.
- Paulus, M.P., et al., 2002. Behavioral and functional neuroimaging evidence for prefrontal dysfunction in methamphetamine-dependent subjects. *Neuropsychopharmacology* 26(1):53-63.
- Paulus, M.P.; Tapert, S.F.; and Schuckit, M.A., 2005. Neural activation patterns of methamphetamine-dependent subjects during decision making predict relapse. *Archives of General Psychiatry* 62(7):761-768.
- Pfefferbaum, A., et al., 1995. Longitudinal changes in magnetic resonance imaging brain volumes in abstinent and relapsed alcoholics. *Alcoholism: Clinical and Experimental Research* 19(5):1177-1191.
- Pfefferbaum, A., et al., 1998. A controlled study of cortical gray matter and ventricular changes in alcoholic men over a 5-year interval. *Archives of General Psychiatry* 55(10):905-912.
- Pfefferbaum, A., and Sullivan, E.V., 2005. Disruption of brain white matter microstructure by excessive intracellular and extracellular fluid in alcoholism: Evidence from diffusion tensor imaging. *Neuropsychopharmacology* 30(2):423-432.
- Rae, C., et al., 1998. Metabolic abnormalities in developmental dyslexia detected by ¹H magnetic resonance spectroscopy. *Lancet* 351(9119):1849-1852.
- Raichle, M.E., et al., 1983. Brain blood flow measured with intravenous H₂(¹⁵O). II. Implementation and validation. *Journal of Nuclear Medicine* 24(9):790-798.
- Rinne, J.O., et al., 1995. PET examination of the monoamine transporter with [¹¹C]beta-CIT and [¹¹C]beta-CFT in early Parkinson's disease. *Synapse* 21(2):97-103.
- Risinger, R.C., et al., 2005. Neural correlates of high and craving during cocaine self-administration using BOLD fMRI. *Neuroimage* 26(4):1097-1108.
- Ross, B.; Kreis, R.; and Ernst, T., 1992. Clinical tools for the 90s: Magnetic resonance spectroscopy and metabolite imaging. *European Journal of Radiology* 14(2):128-140.
- Schlaepfer, T.E., et al., 2006. Decreased frontal white-matter volume in chronic substance abuse. *International Journal of Neuropsychopharmacology* 9(2):147-153.
- Shearer, J., et al., 2003. Pilot randomized double blind placebo-controlled study of dexamphetamine for cocaine dependence. *Addiction* 98(8):1137-1141.
- Silveri, M.M., et al., 2004. Cerebral phosphorus metabolite and transverse relaxation time abnormalities in heroin-dependent subjects at onset of methadone maintenance treatment. *Psychiatry Research* 131(3):216-226.
- Smith, L.M., et al., 2001a. Brain proton magnetic resonance spectroscopy and imaging in children exposed to cocaine in utero. *Pediatrics* 107(2):227-231.
- Smith, L.M., et al., 2001b. Brain proton magnetic resonance spectroscopy in children exposed to methamphetamine in utero. *Neurology* 57(2):255-260.
- Stapleton, J.M., et al., 1995. Cerebral glucose utilization in polysubstance abuse. *Neuropsychopharmacology* 13(1):21-31.
- Thompson, P.M., et al., 2004. Structural abnormalities in the brains of human subjects who use methamphetamine. *Journal of Neuroscience* 24(26):6028-6036.
- Volkow, N.D., et al., 1990. Effects of chronic cocaine abuse on postsynaptic dopamine receptors. *American Journal of Psychiatry* 147(6):719-724.
- Volkow, N.D., et al., 1991. Changes in brain glucose metabolism in cocaine dependence and withdrawal. *American Journal of Psychiatry* 148(5):621-626.
- Volkow, N.D., et al., 1993. Decreased dopamine D₂ receptor availability is associated with reduced frontal metabolism in cocaine abusers. *Synapse* 14(2):169-177.
- Volkow, N.D., et al., 1995. A new PET ligand for the dopamine transporter: Studies in the human brain. *Journal of Nuclear Medicine* 36(12):2162-2168.
- Volkow, N.D., et al., 1996a. PET evaluation of the dopamine system of the human brain. *Journal of Nuclear Medicine* 37(7):1242-1256.
- Volkow, N.D., et al., 1996b. Decreases in dopamine receptors but not in dopamine transporters in alcoholics. *Alcoholism: Clinical and Experimental Research* 20(9):1594-1598.
- Volkow, N.D., et al., 1997. Relationship between subjective effects of cocaine and dopamine transporter occupancy. *Nature* 386(6627):827-830.
- Volkow, N.D., et al., 1999. Reinforcing effects of psychostimulants in humans are associated with increases in brain dopamine and occupancy of D(2) receptors. *Journal of Pharmacology and Experimental Therapeutics* 291(1):409-415.
- Volkow, N.D., et al., 2001a. Low level of brain dopamine D₂ receptors in methamphetamine abusers: Association with metabolism in the orbitofrontal cortex. *American Journal of Psychiatry* 158(12):2015-2021.
- Volkow, N.D., et al., 2001b. Association of dopamine transporter reduction with psychomotor impairment in methamphetamine abusers. *American Journal of Psychiatry* 158(3):377-382.
- Volkow, N.D., et al., 2004. Dopamine in drug abuse and addiction: Results from imaging studies and treatment implications. *Molecular Psychiatry* 9(6):557-569.
- Volkow, N.D.; Fowler, J.S.; and Wang, G.J., 2003a. Positron emission tomography and single-photon emission computed tomography in substance abuse research. *Seminars in Nuclear Medicine* 33(2):114-128.
- Volkow, N.D.; Fowler, J.S.; and Wang, G.J., 2003b. The addicted human brain: Insights from imaging studies. *Journal of Clinical Investigation* 111(10):1444-1451.
- Volkow, N.D.; Fowler, J.S.; and Wang, G.J., 2004. The addicted human brain viewed in the light of imaging studies: Brain circuits and treatment strategies. *Neuropharmacology* 47(Suppl 1):3-13.
- Wang, G.J., et al., 1997. Dopamine D₂ receptor availability in opiate-dependent subjects before and after naloxone-precipitated withdrawal. *Neuropsychopharmacology* 16(2):174-182.
- Wang, G.J., et al., 2004. Partial recovery of brain metabolism in methamphetamine abusers after protracted abstinence. *American Journal of Psychiatry* 161(2):242-248.
- Warner, T.D., et al., 2006. Diffusion tensor imaging of frontal white matter and executive functioning in cocaine-exposed children. *Pediatrics* 118(5):2014-2024.
- Wexler, B.E., et al., 2001. Functional magnetic resonance imaging of cocaine craving. *American Journal of Psychiatry* 158(1):86-95.
- Wong, D.F., et al., 1993. In vivo imaging of baboon and human dopamine transporters by positron emission tomography using [¹¹C]WIN 35,428. *Synapse* 15(2):130-142.
- Zubieta, J.K., et al., 1996. Increased mu opioid receptor binding detected by PET in cocaine-dependent men is associated with cocaine craving. *Nature Medicine* 2(11):1225-1229.