

PREOPERATIVE THERAPY IN INVASIVE BREAST CANCER

Reviewing the State of the Science and Exploring New Research Directions

Special Issues in Locally Advanced Breast Cancer – Surgical Perspective

David R. Byrd, MD

University of Washington

Seattle Cancer Care Alliance

Seattle, WA

Disclosures

- **None**

LABC – Definition by Stage Grouping – AJCC 6th Ed.

		Stage Grouping			
<input type="checkbox"/>	<input type="checkbox"/>	0	Tis	N0	M0
<input type="checkbox"/>	<input type="checkbox"/>	I	T1 ⁽⁷⁾	N0	M0
<input type="checkbox"/>	<input type="checkbox"/>	IIA	T0	N1	M0
			T1 ⁽⁷⁾	N1	M0
			T2	N0	M0
<input type="checkbox"/>	<input type="checkbox"/>	IIB	T2	N1	M0
		IIIA	T3	N0	M0
<input type="checkbox"/>	<input type="checkbox"/>		T0	N2	M0
			T1 ⁽⁷⁾	N2	M0
			T2	N2	M0
			T3	N1	M0
		IIIB	T3	N2	M0
<input type="checkbox"/>	<input type="checkbox"/>		T4	N0	M0
			T4	N1	M0
		IIIC	T4	N2	M0
<input type="checkbox"/>	<input type="checkbox"/>		Any T	N3	M0
<input type="checkbox"/>	<input type="checkbox"/>	IV	Any T	Any N	M1

LABC: Clinical T Stage – AJCC 6th Ed

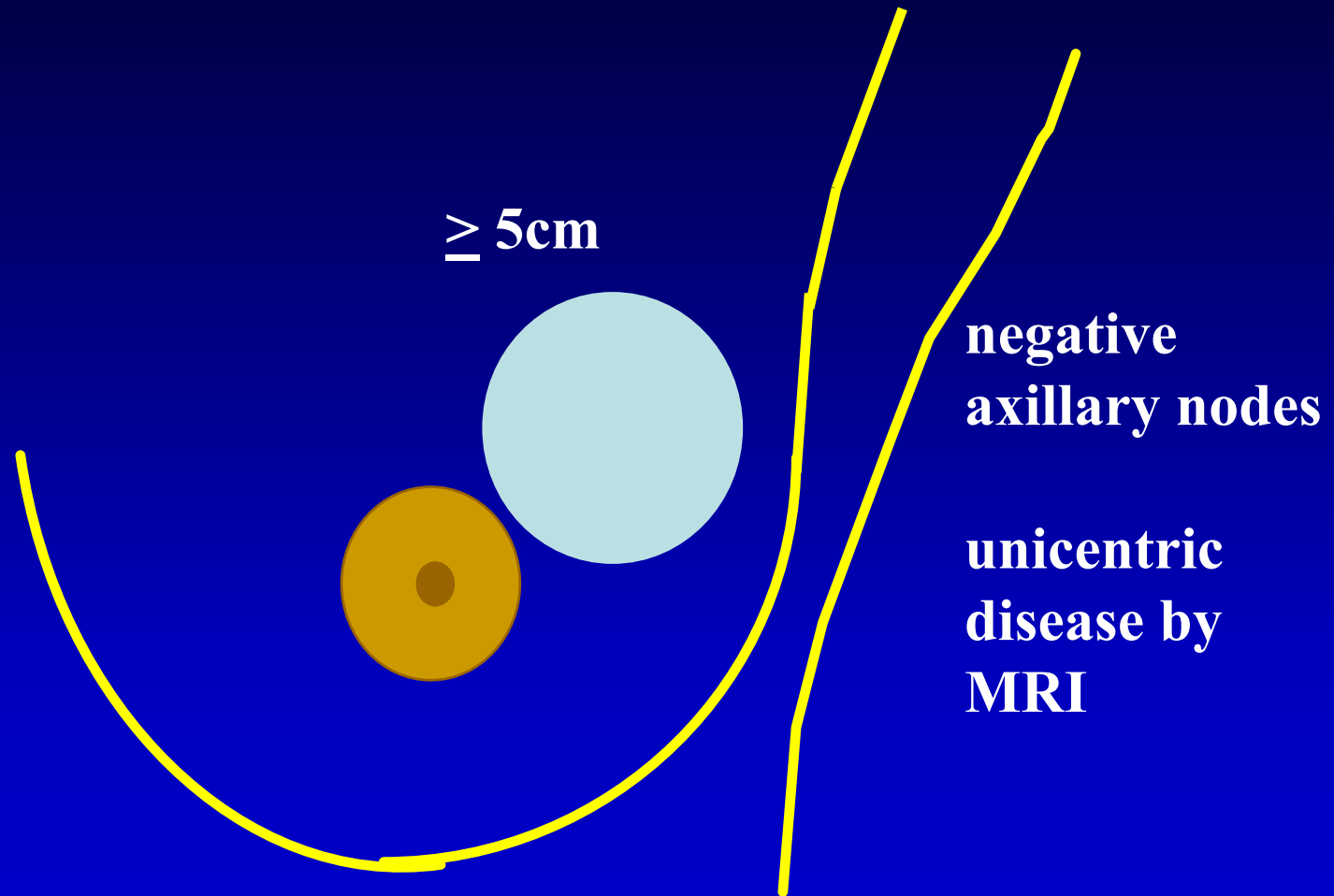
<input type="checkbox"/>	<input type="checkbox"/>	T3	Tumor more than 5 cm in greatest dimension
<input type="checkbox"/>	<input type="checkbox"/>	T4	Tumor of any size with direct extension to (a) chest wall or (b) skin, only as described below.
<input type="checkbox"/>	<input type="checkbox"/>	T4a	Extension to chest wall, not including pectoralis muscle
<input type="checkbox"/>	<input type="checkbox"/>	T4b	Edema (including peau d'orange) or ulceration of the skin of the breast, or satellite skin nodules confined to the same breast
<input type="checkbox"/>	<input type="checkbox"/>	T4c	Both T4a and T4b
<input type="checkbox"/>	<input type="checkbox"/>	T4d	Inflammatory carcinoma

yTNM – AJCC 6th Ed

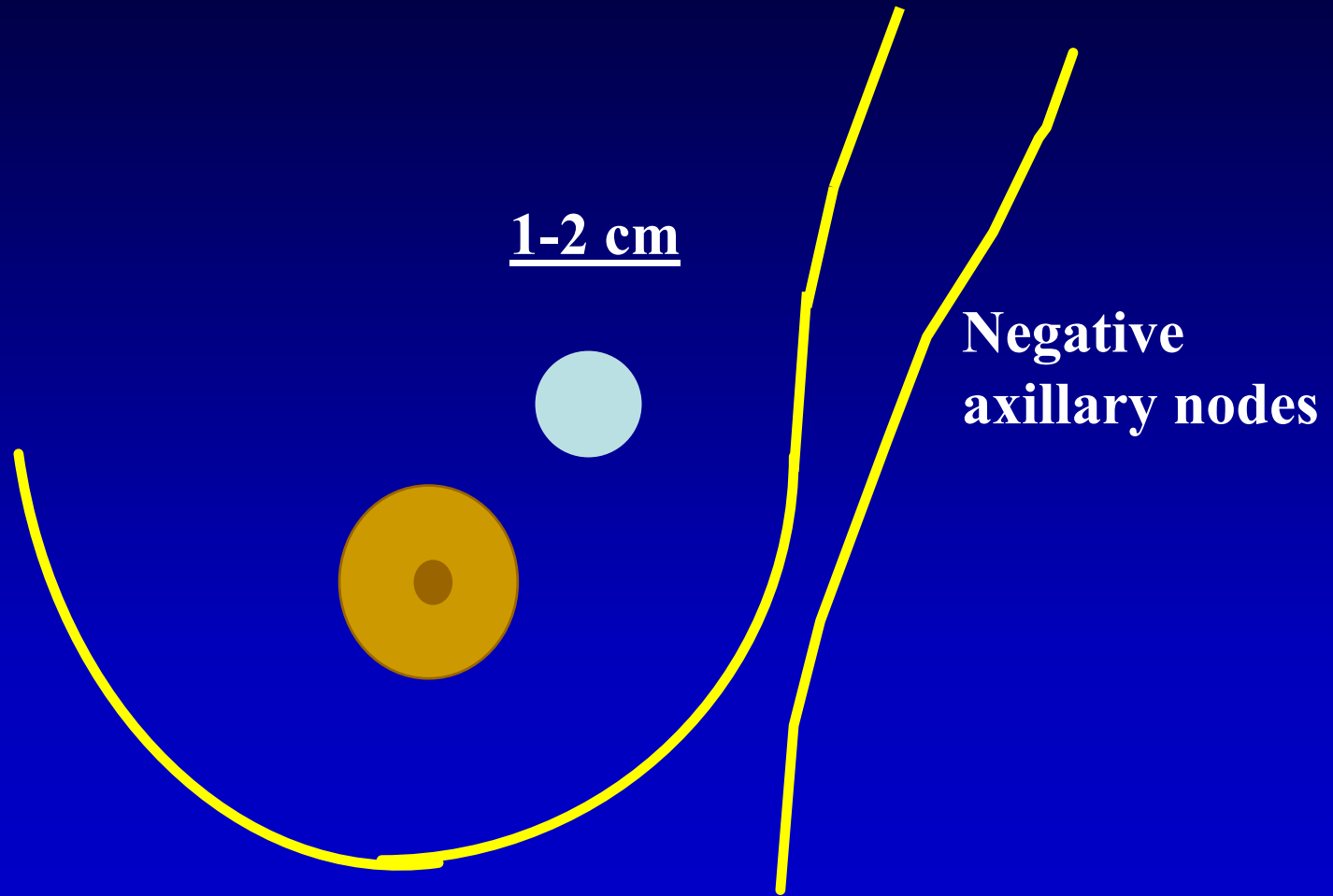
- **“y” designates the stage of the residual tumor after neoadjuvant therapy**
- **Includes both the primary tumor and regional lymph nodes**
- **AJCC 7th Ed breast task force (Dr. Daniel Hayes) has subcommittee focused on neoadjuvant therapy (Dr. Monica Morrow)**

Surgical Issues by T Stage

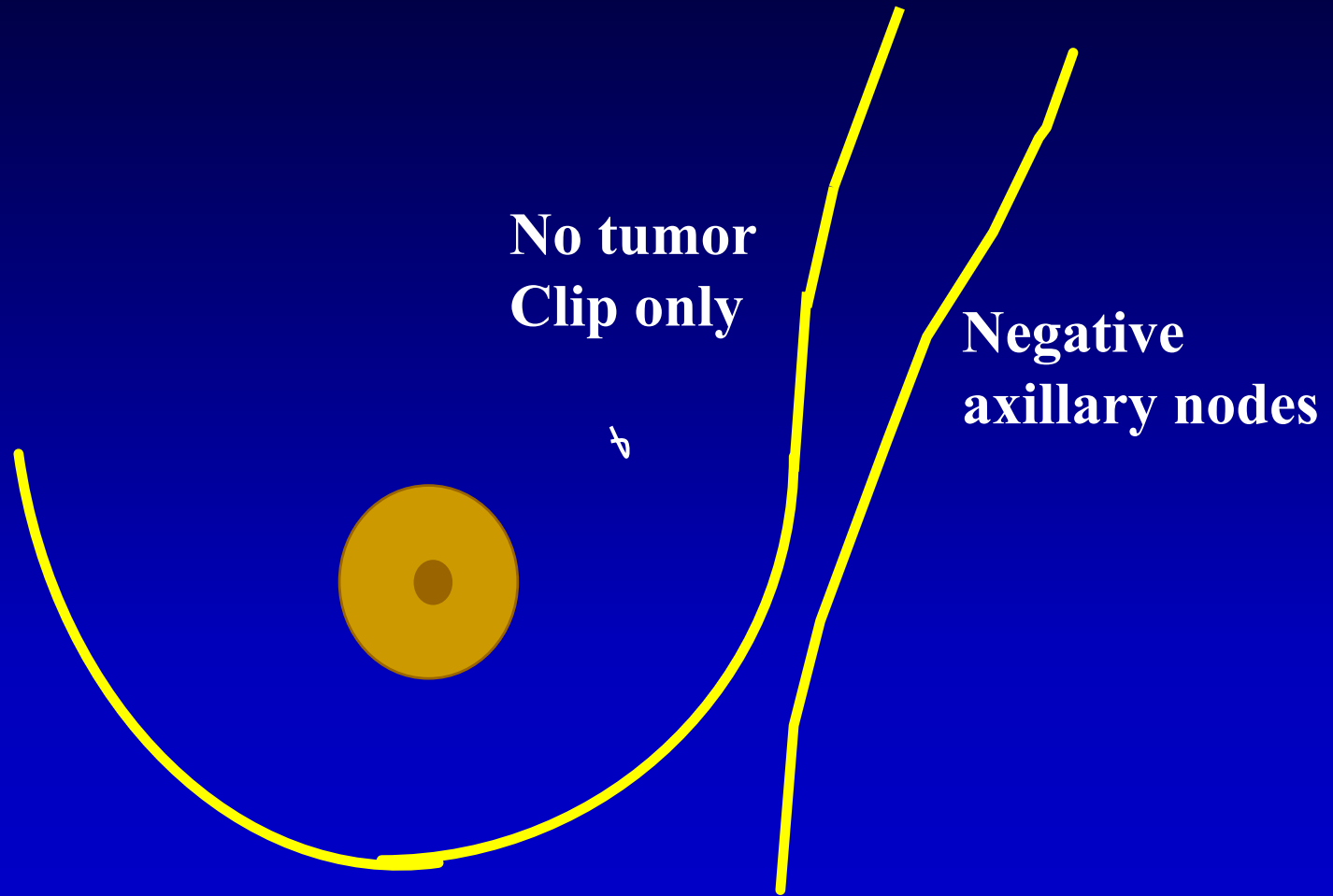
Clinical Stage T3N0 - Operable



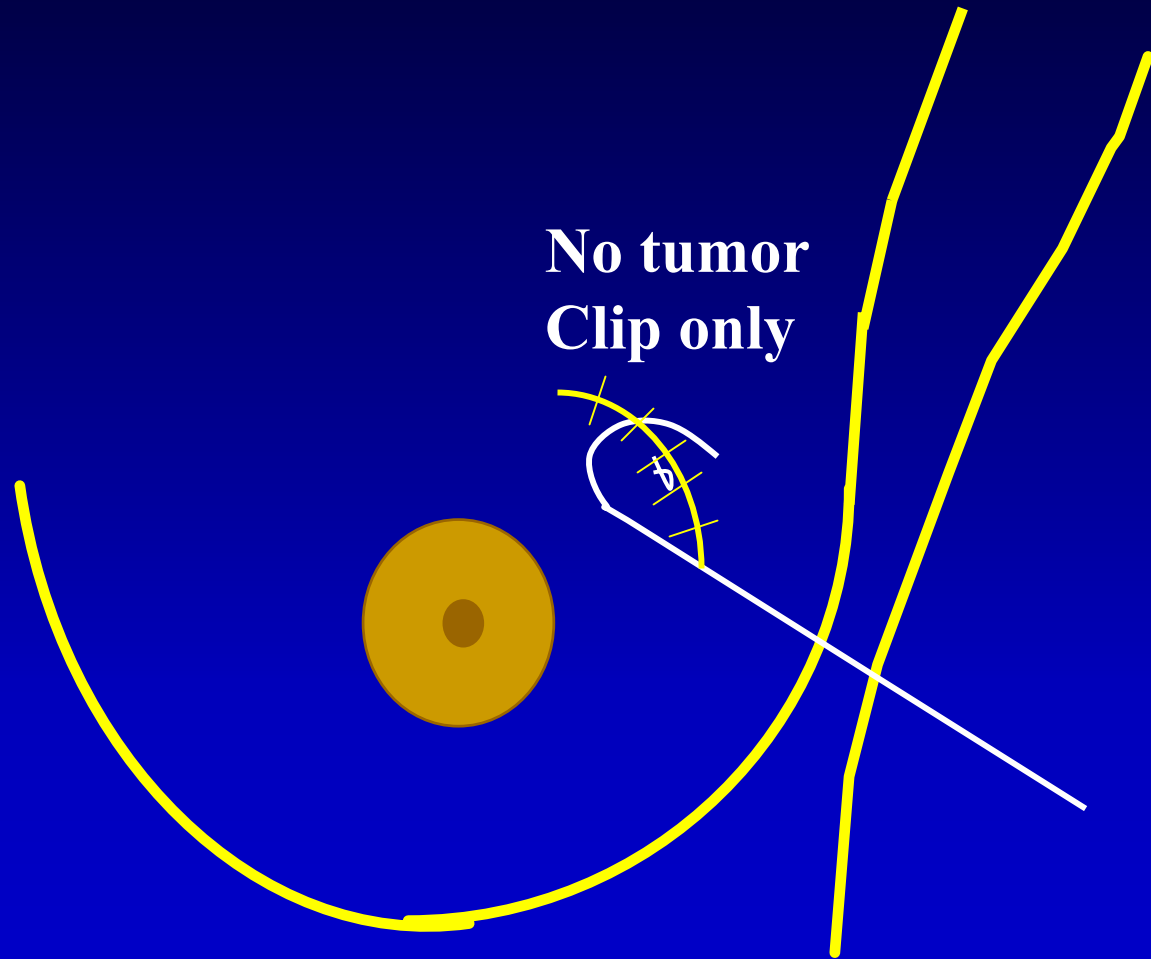
Clinical Stage T3N0 – Clinical Partial Response (cPR)



Clinical Stage T3N0 – Clinical Complete Response (cCR)

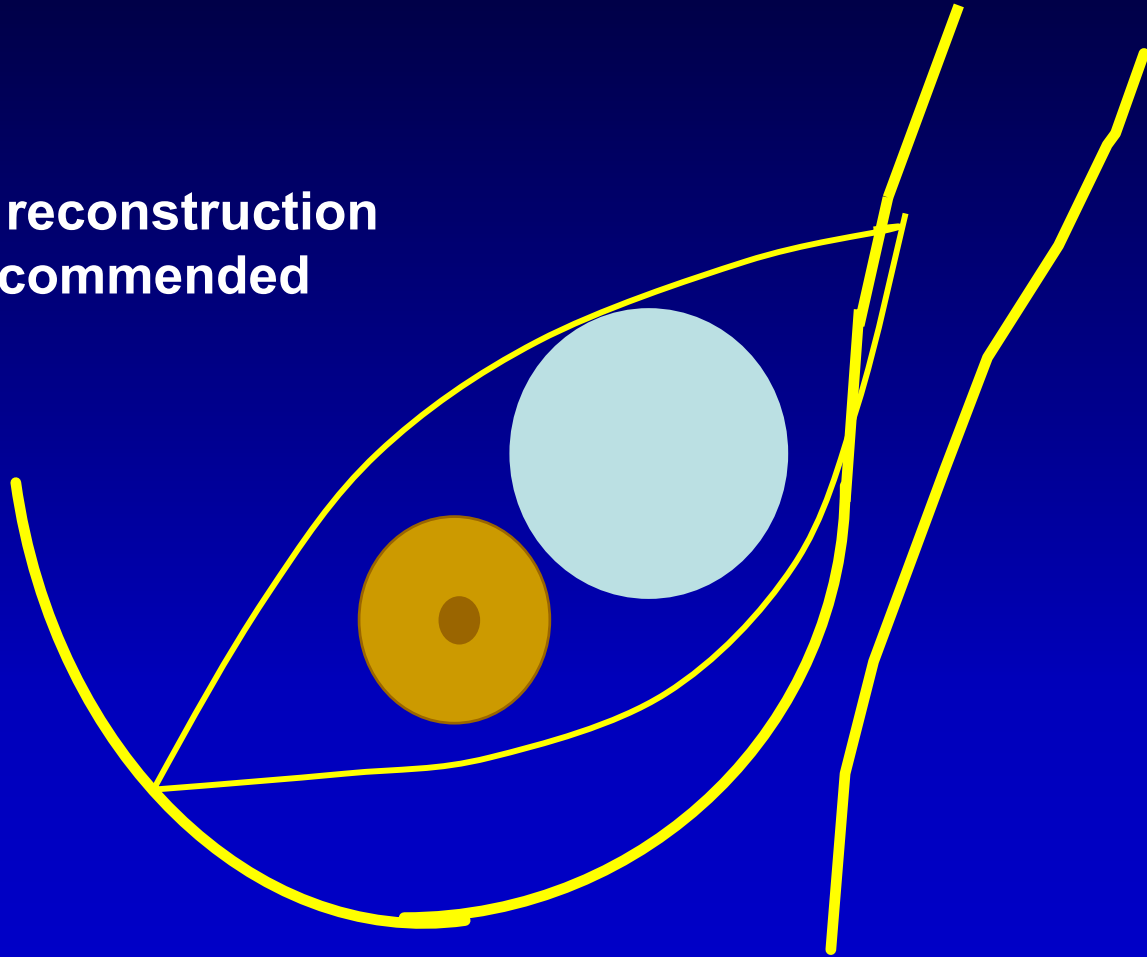


Breast Conservation: Wire-Localized Partial Mastectomy



Mastectomy for Residual Large Primary

No immediate reconstruction
since RT recommended



Clinical Stage T4 – non-inflammatory – skin or chest wall

- **Mastectomy with wide skin margins 1-2 cm**
- **BCT feasible and safe in selected patients with cPR or cCR to chemotherapy**

BCT for T4, non-inflammatory Tumors – M.D. Anderson

33 patients (IIIB = 23, IIIC = 10), mean age=52, all with skin involvement

	Pre-treatment	post-treatment
Median size	7 cm	2 cm
		Path tumor size:
		pCR 8(24%)
		resid >1cm 21(64%)
		resid ≤1cm 4(12%)
		Skin involvement:
		yes 4(12%)
		no 29(88%)
Clinical node status		Path node status
N0 5(15%)		ypN0 15(55%)

-Shen, et al. Ann Surg Onc 11(9):854-860, 2004

BCT for T4, non-inflammatory Tumors – M.D. Anderson-Results

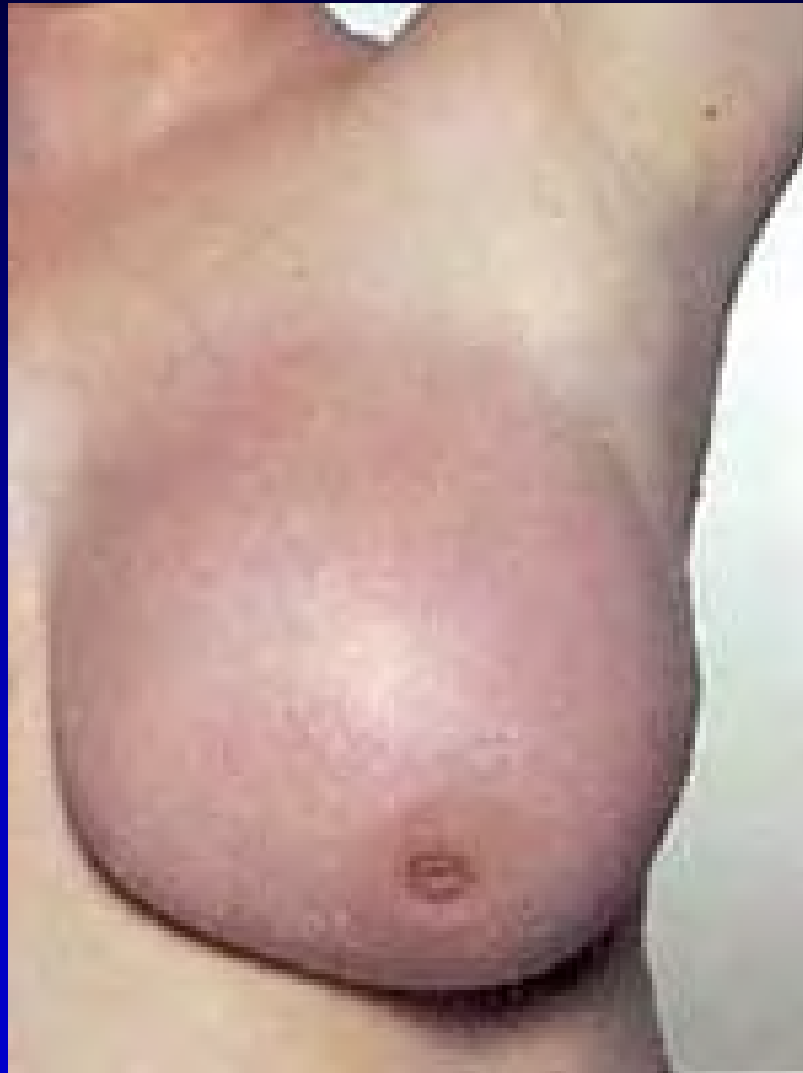- **29 pts (88%) skin changes resolved (pt selection)**
- **Median f/u = 91 mos.**
 - **O.S. = 78%**
 - **DFS = 70%**
- **Ipsilateral breast local recurrence = 6%**
- **Conclusion – mastectomy not mandatory in all patients with T4 skin involvement**

IBC – Working Clinical Definition

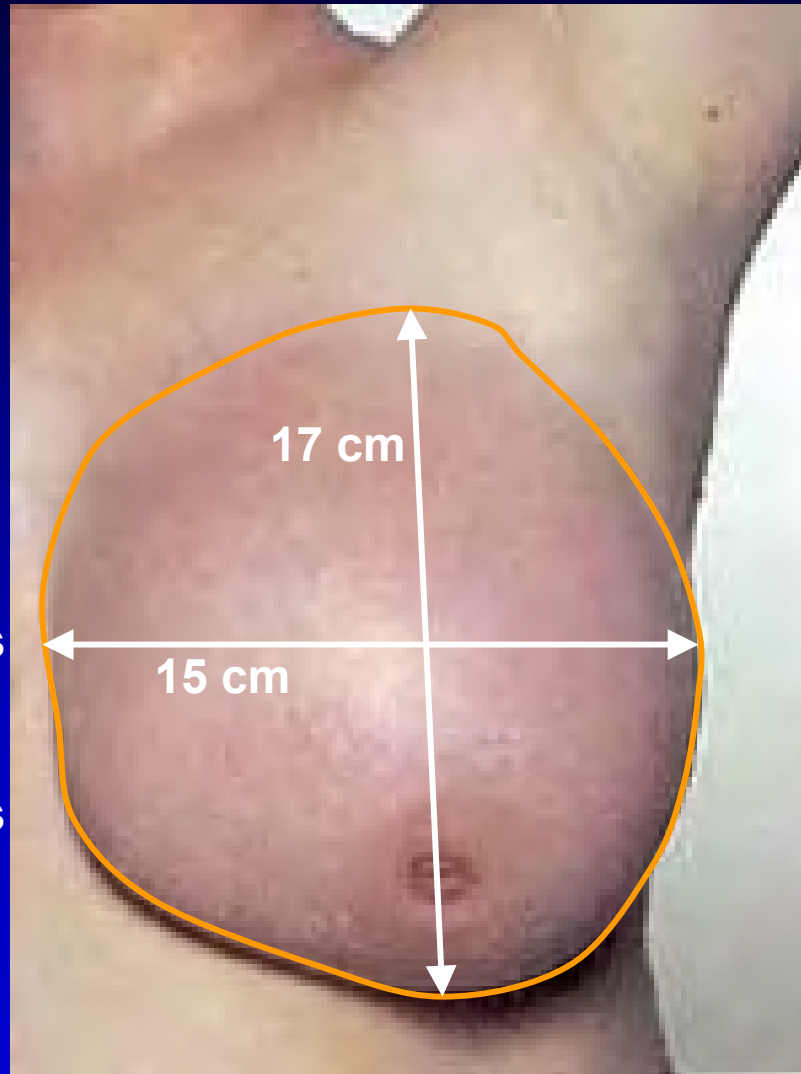Acute and rapid onset of breast symptoms including skin erythema, edema (peau d'orange), erysipeloid border, warmth and tenderness, and breast enlargement, involving at least 1/3 or more of the breast.

Breast mass often not palpable. Dermal lymphatic metastases may or may not be identified

Inflammatory Breast Carcinoma



Pre-Treatment Documentation of Skin Involvement



Special notes:

- ?dimensions
- ?cross midline
- ?beyond the confines of the breast
- ?satellite lesions – erythematous patches or nodules

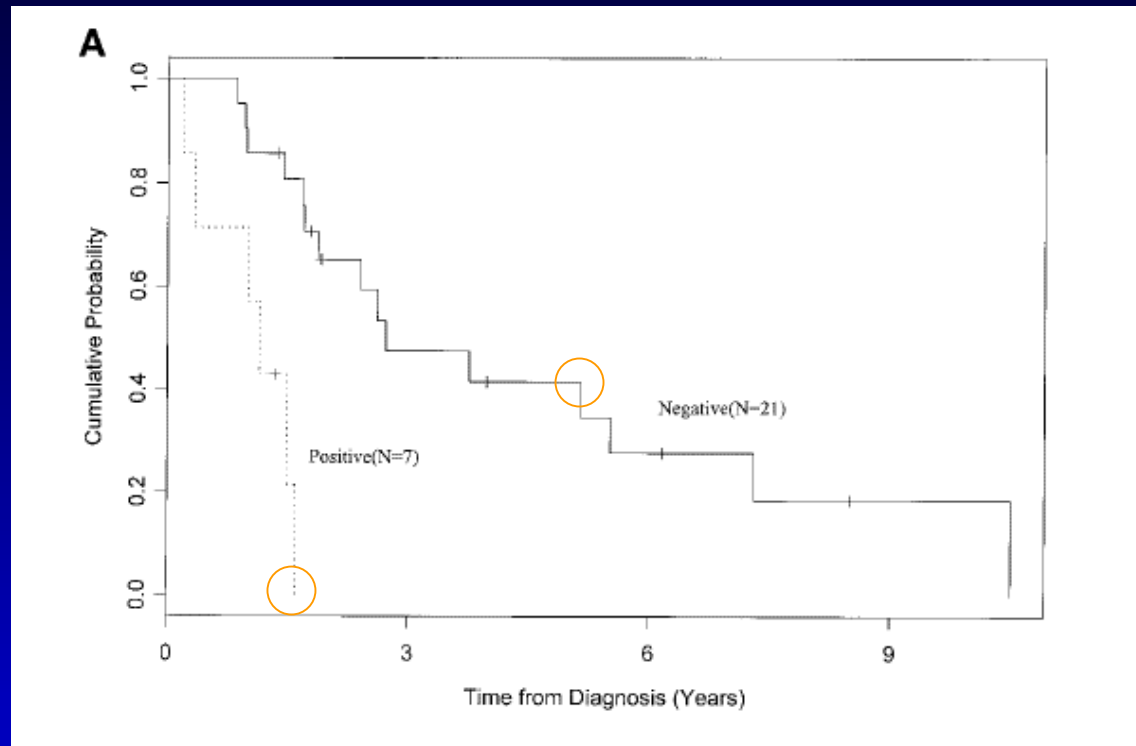
Consider digital photos and/or drawings, border tattoos

IBC – Breast Surgery after Preoperative Chemotherapy

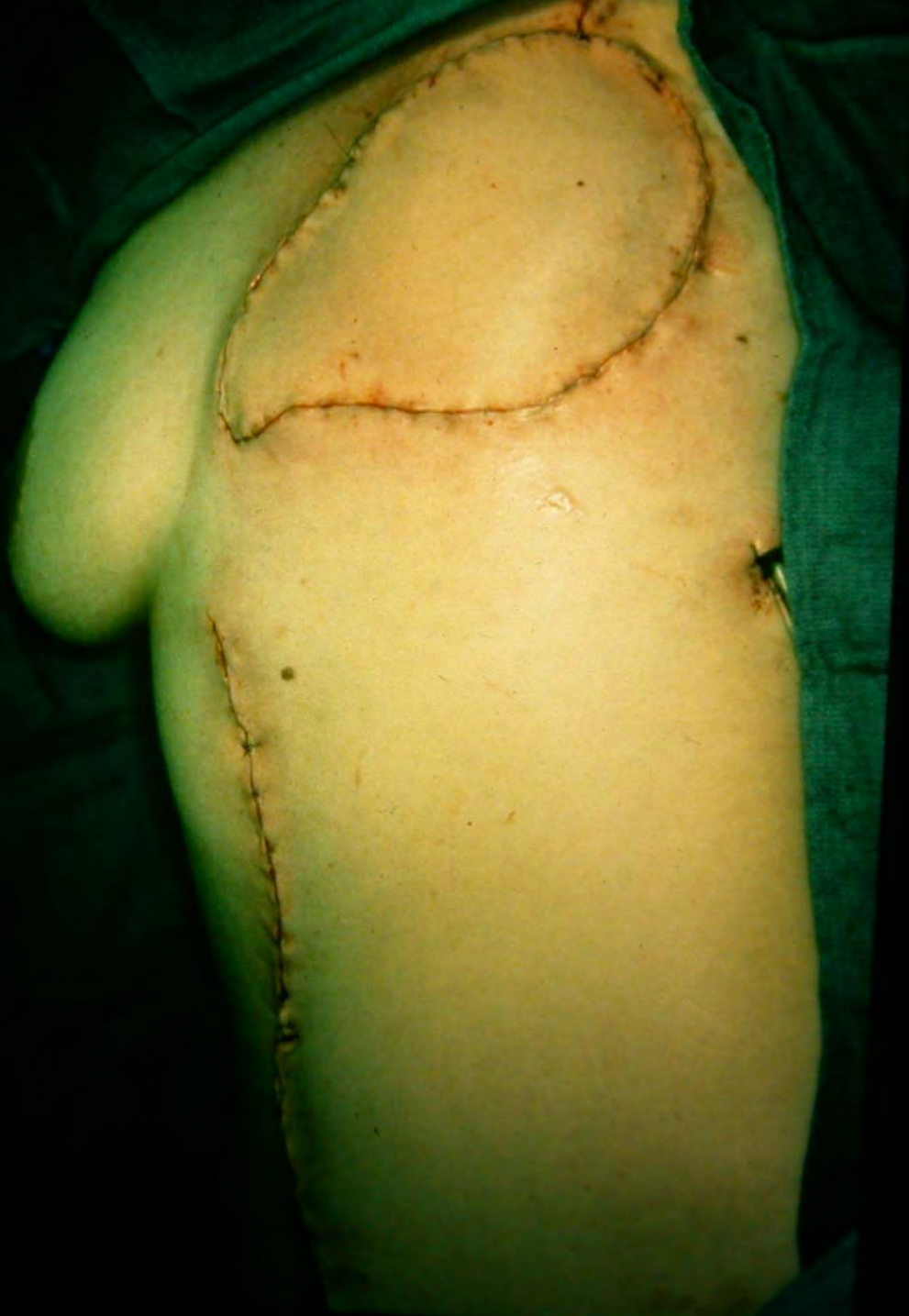- **Mastectomy:**
 - **primary closure based on initial extent and skin findings after chemotherapy**
 - **Skin punch biopsies of discordant findings may be helpful**
 - **Goal is negative skin and peripheral margins**
 - **Frozen section of skin margins not helpful**
 - **May require skin pedicle reconstruction**
 - **Counsel patient toward chest wall reconstruction and not breast reconstruction**
- **Breast Conservation is not indicated**

Post-Mastectomy Margin Significance in IBC

Stage IIIB, n=28
Overall Survival



-Curcio, et al. Ann Surg Oncol 1999; 6(3):249-254



Summary - Breast Surgery by T Stage

- **T3 – mastectomy if minimal or no response. BCT if clinical cPR or cCR. Long-term local recurrence is unknown**
- **T4 (non-inflammatory) – mastectomy. BCT possible for selected patients with cCR with skin response**
- **T4 (inflammatory) – mastectomy with wide skin margins**

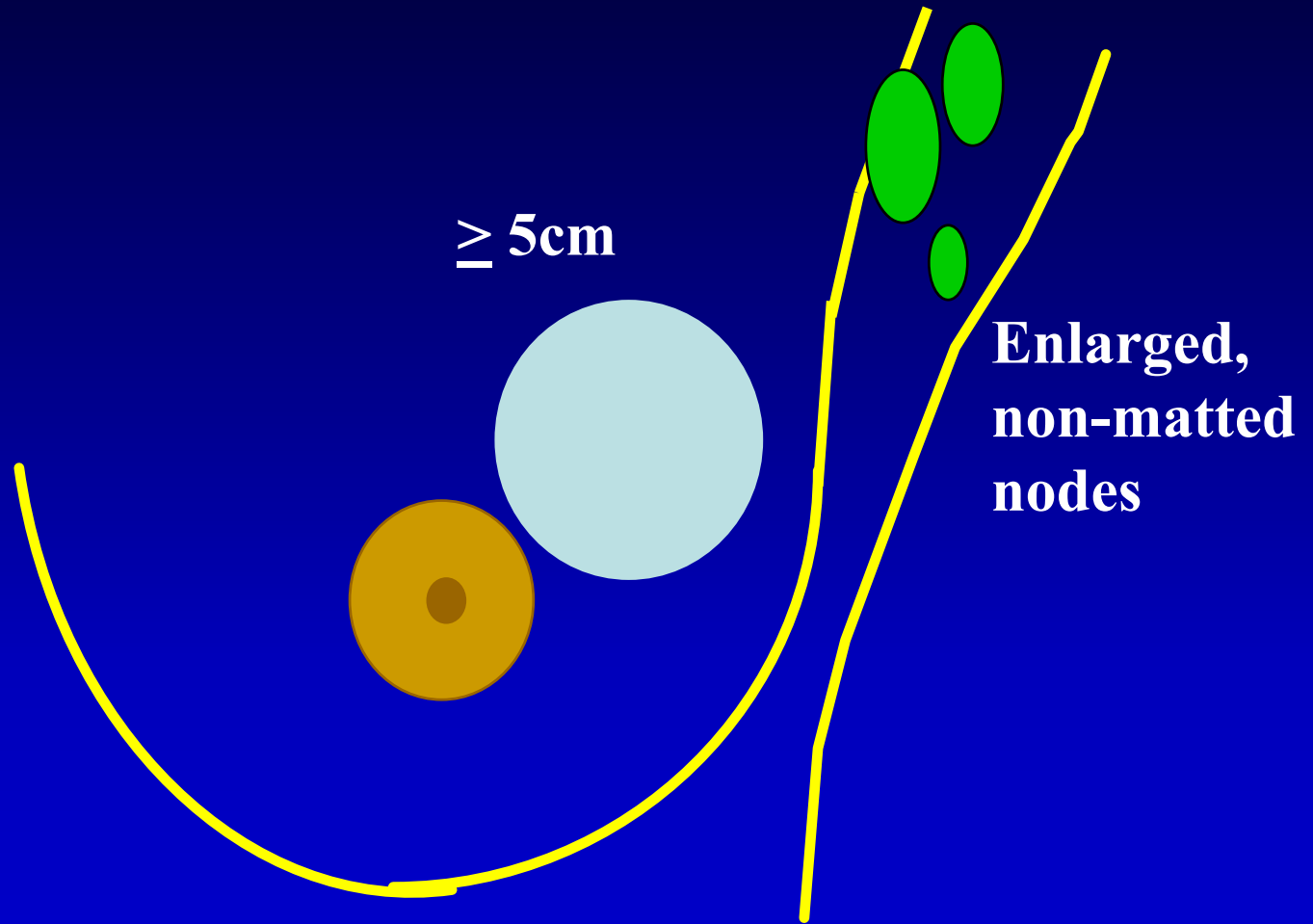
Surgical Issues by N Stage

LABC: Clinical N Stage – AJCC 6th Ed.

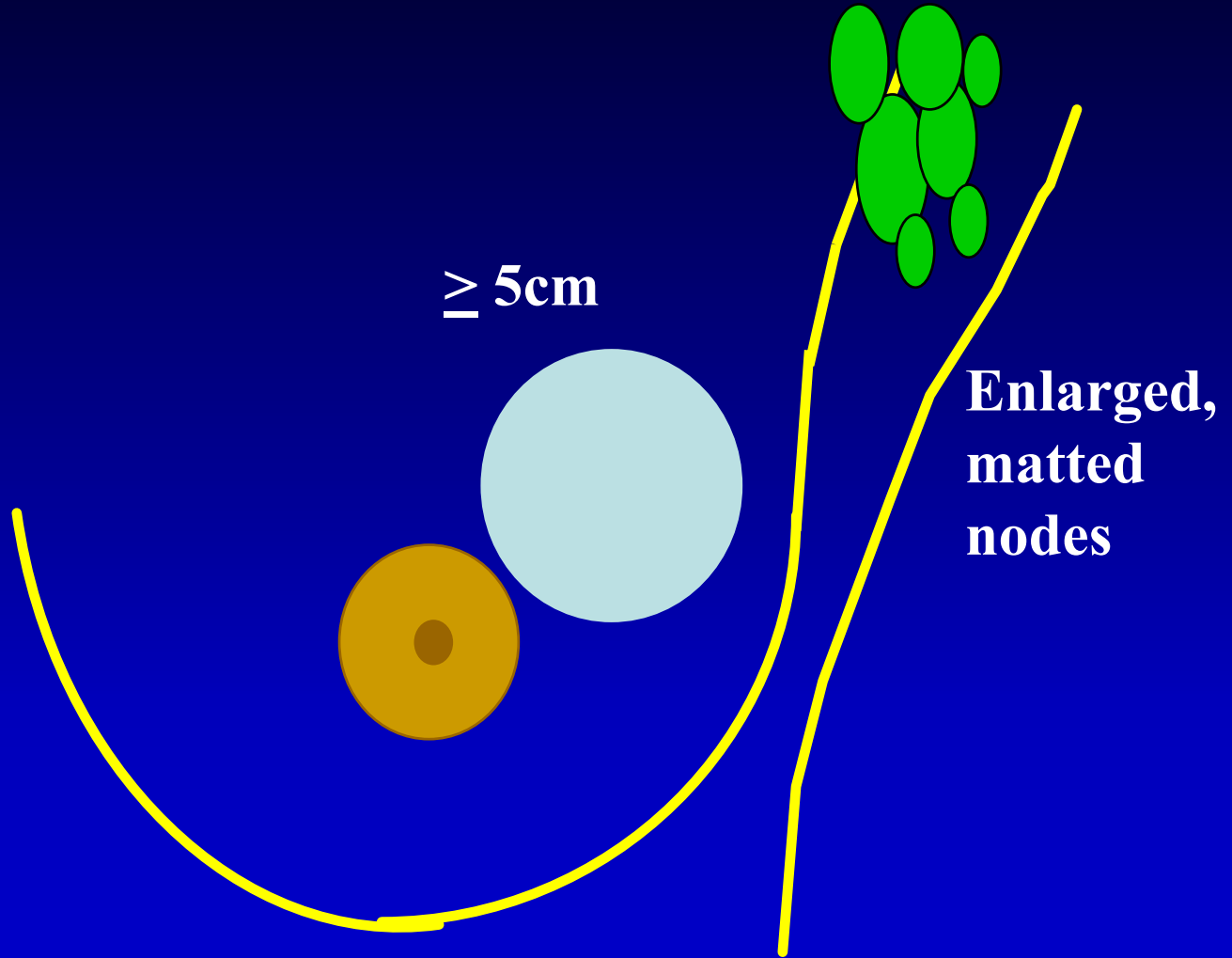
- N1 Metastasis in movable ipsilateral axillary lymph node(s)
- N2 Metastases in ipsilateral axillary lymph nodes **fixed or matted**, or in clinically apparent⁽¹⁾ ipsilateral internal mammary nodes in the *absence* of clinically evident axillary lymph node metastasis

- N3 Metastasis in ipsilateral infraclavicular lymph node(s) with or without axillary lymph node involvement, or in clinically apparent⁽¹⁾ ipsilateral **internal mammary** lymph node(s) and in the *presence* of clinically evident axillary lymph node metastasis; or metastasis in ipsilateral **supraclavicular lymph** node(s) with or without axillary or internal mammary lymph node involvement

Clinical Stage T3N1



Clinical Stage T3N2



Treatment of Clinical N1,2

- **Standard of care is axillary lymph node dissection, regardless of response**
- **Patients with a pCR in the breast have up to 85% chance of axillary node sterilization – not identified by current techniques**

LABC – Clinical N0 Disease

- **Pathologic nodal staging may influence both systemic therapy and regional nodal irradiation**
- **Most T3, T4 primary tumors are node positive – 60-85%**
- **Axillary U/S + biopsy should be considered prior to SLND**

LABC – Clinical N0 Disease

- **What is the role of SLND?**
- **What is the management of a positive SLN before or after preop chemo?**

SLND before Preoperative Chemotherapy for T3, T4 Tumors

- **T3 primary:**

	<u>n</u>	<u>false negative rate</u>
– Bedrosian (>3cm)	56 (T3=16)	1/34 (3%)
– Chung	41	1/31 (3%)
– Stearns	23	1/16 (6%)
- **T4/IBC:**
 - Stearns 8 2/5 (40%)

Bedrosian, et al. Cancer 2000;88:2540

Chung, et al. Ann Surg Oncol 2001;8(9):688-693

Stearns, et al. Ann Surg Oncol. 9(3):235-243,
2002

SLND after Preop Chemotherapy

TABLE 3. Studies reporting on SLN mapping after treatment with neoadjuvant chemotherapy

Author	Year	No. of patients	T status	Average tumor size (cm)	Failure to identify an SLN (%)	FNR (%)
Tafra ¹⁷	2001	29	1, 2	1.4	2/29 (7)	0
Miller ¹⁸	2002	35	1-3	3.5 median	5/35 (14)	0
Haid ¹⁹	2001	33	1-3	3.3	4/33 (12)	0
Julian ²⁰	2002	31	1-3	<4	3/34 (9)	0
Brady ²¹	2002	14	1-3	-	1/14 (7)	0
Balch ²²	2003	26	2-4	-	1/26 (4)	7
Schwartz ¹⁴	2003	21	2-4	>3	0/21 (100)	9
Lang ¹⁶	2004	53	-	4.5	3/53 (5.7)	9
Kang ¹⁵	2004	54	2-4	>3	15/54 (28)	11
Mamounas ²³	2002	428	1-3	-	65/428 (15)	11
Breslin ²⁴	2000	51	2, 3	5 median	9/51 (18)	12
Stearns ²⁵	2002	34	3, 4	>5	5/34 (15)	14
Piata ²⁶	2003	42	1, 2	<5	1/42 (2.4)	17
Fernandez ²⁷	2001	40	1-4	-	4/40 (10)	20
Nason ²⁸	2000	15	2, 3	5	2/15 (13.3)	33

SLN, sentinel lymph node; FNR, false-negative rate.

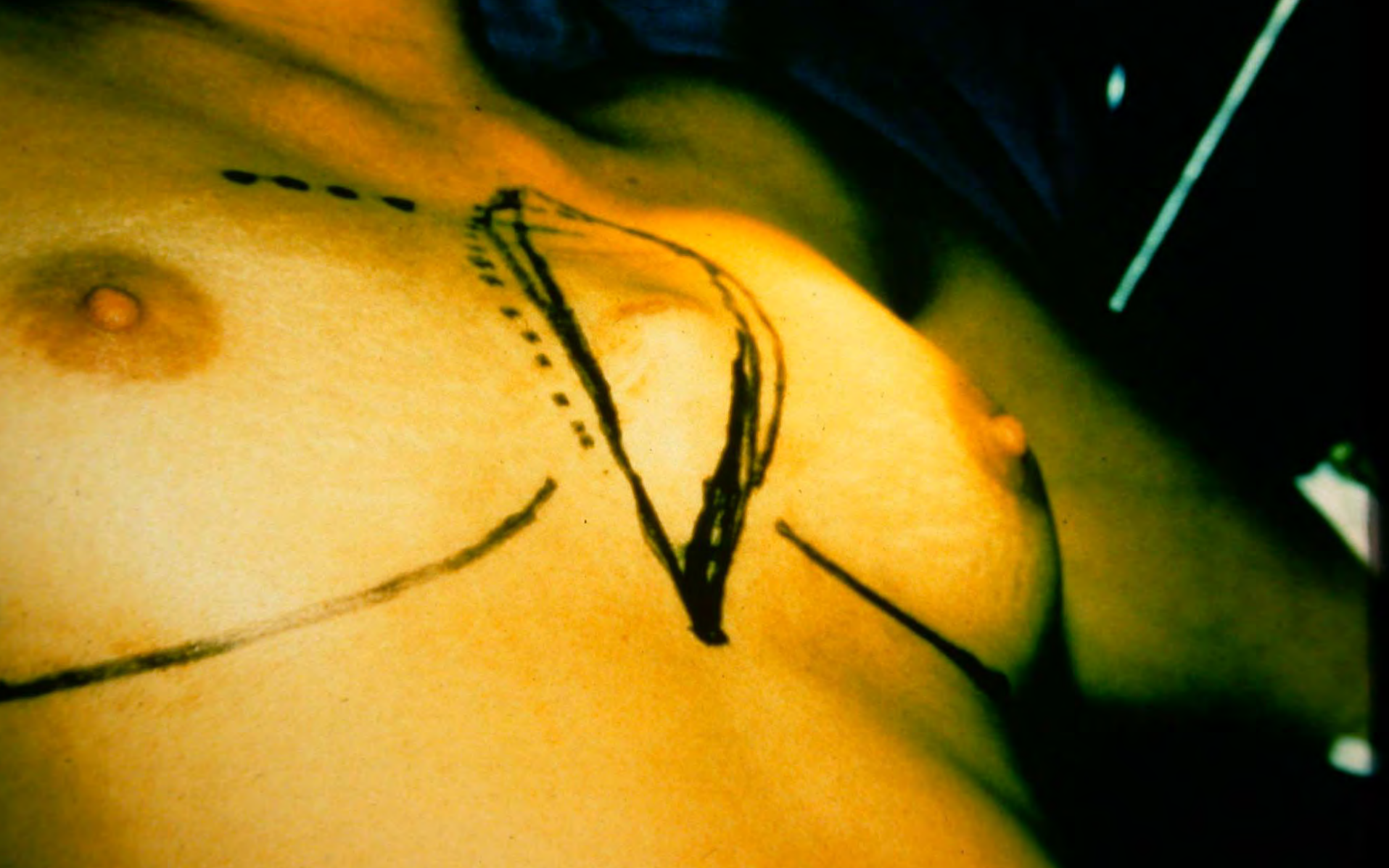Summary - SNB in LABC

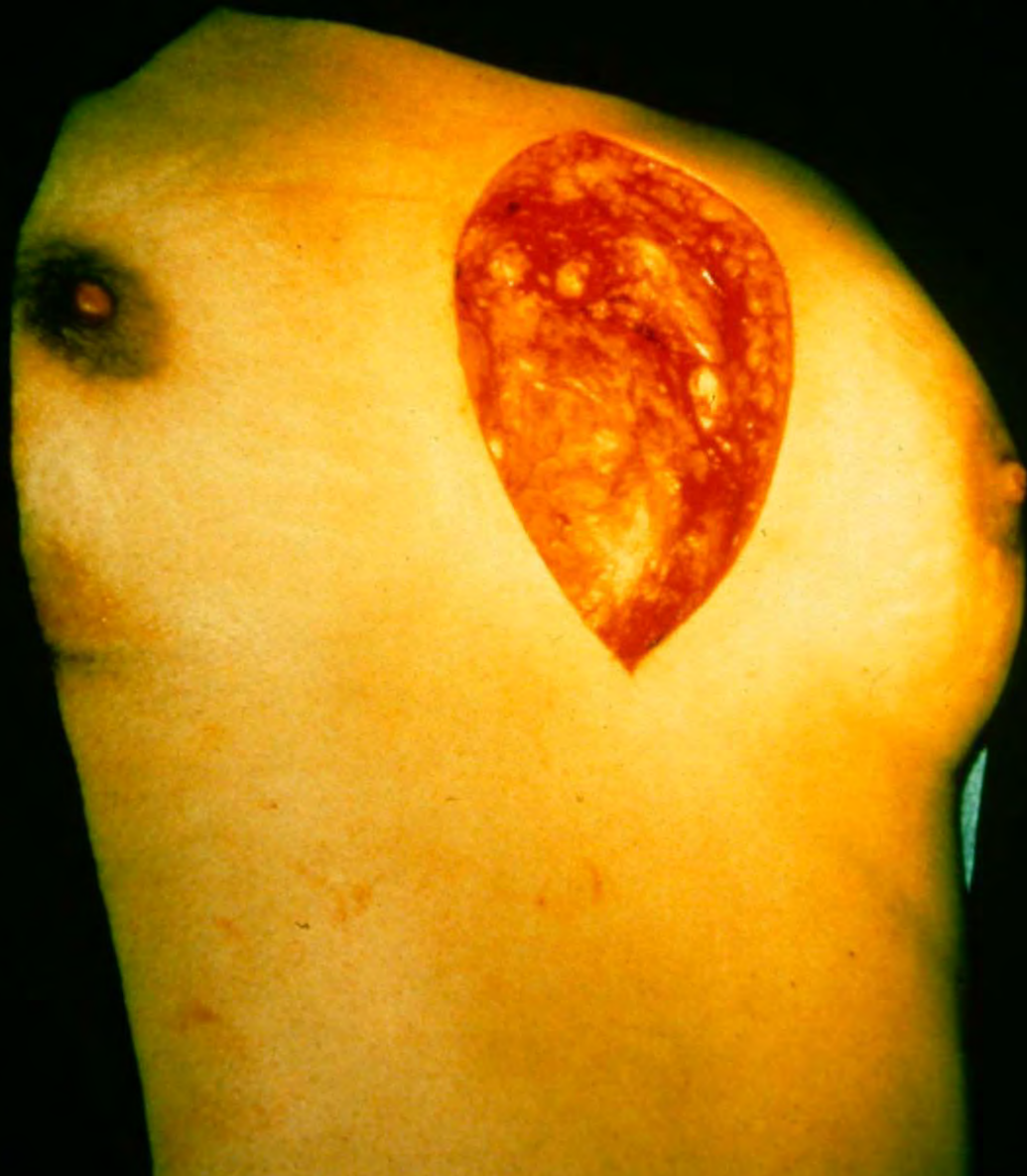- **Pre-treatment SNB may be accurate for T3, selected T4 tumors, NOT for IBC**
- **SNB post-treatment – insufficient data to recommend. Clinical significance of a false negative SLN more relevant as the denominator of node positive patients becomes larger**

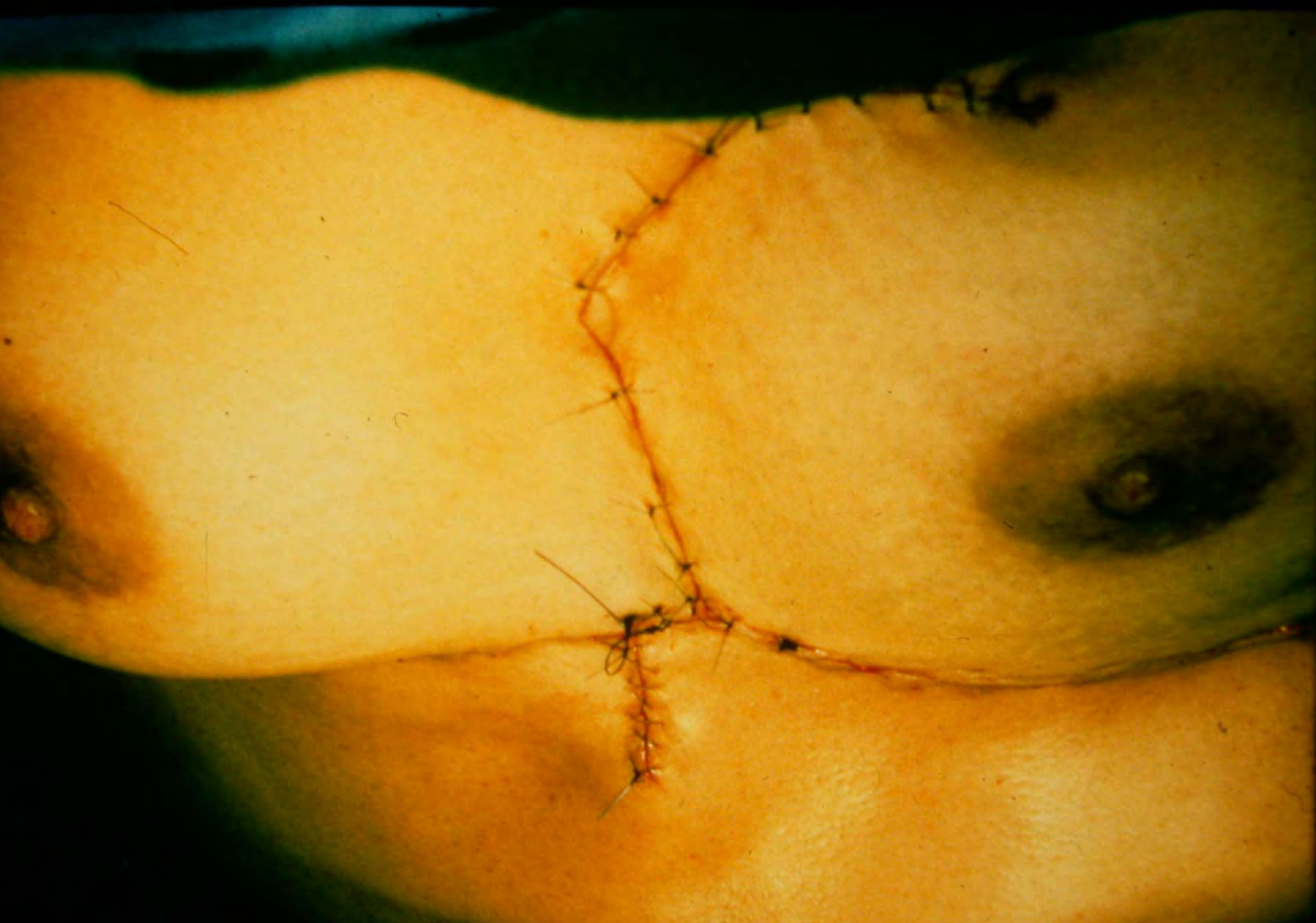
The “Take home” Nodal Message in LABC

- **Any patient found to have axillary nodal metastases by any technique, pre- or post-chemotherapy, should receive a completion axillary node dissection**
- **Current data are insufficient to identify patients who do not need axillary specific treatment**

Clinically Positive IMN Disease







Summary – Surgical Issues in LABC

- **surgeon involved in multidisciplinary decision up front**
- **surgeon involved in clinical evaluation during response**
- **BCT is option in selected patients**
 - **imaging may help evaluate response and residual disease - U/S, MRI, PET**
- **decide on axillary management pre-Rx**

Surgery in LABC – Unresolved Questions

- **How do we evaluate the extent of residual primary tumor to increase successful BCT?**
- **Can we identify patients with positive nodes (micro- or macro-) before neoadjuvant treatment who do not need axillary-specific treatment?**
- **What group will design and fund clinical trials that address locoregional treatment?**