

NATIONAL TOXICOLOGY PROGRAM
Technical Report Series
No. 280



TOXICOLOGY AND CARCINOGENESIS
STUDIES OF
CROCIDOLITE ASBESTOS
(CAS NO. 12001-28-4)
IN F344/N RATS
(FEED STUDIES)

U.S. DEPARTMENT OF HEALTH AND HUMAN SERVICES
Public Health Service
National Institutes of Health

NATIONAL TOXICOLOGY PROGRAM

The National Toxicology Program (NTP), established in 1978, develops and evaluates scientific information about potentially toxic and hazardous chemicals. This knowledge can be used for protecting the health of the American people and for the primary prevention of disease. By bringing together the relevant programs, staff, and resources from the U.S. Public Health Service, DHHS, the National Toxicology Program has centralized and strengthened activities relating to toxicology research, testing and test development/validation efforts, and the dissemination of toxicological information to the public and scientific communities and to the research and regulatory agencies.

The NTP is made up of four charter DHHS agencies: the National Cancer Institute (NCI), National Institutes of Health; the National Institute of Environmental Health Sciences (NIEHS), National Institutes of Health; the National Center for Toxicological Research (NCTR), Food and Drug Administration; and the National Institute for Occupational Safety and Health (NIOSH), Centers for Disease Control. In July 1981, the Carcinogenesis Bioassay Testing Program, NCI, was transferred to the NIEHS.

Special Note: This Technical Report was peer reviewed in public session and approved by the NTP Board of Scientific Counselors' Technical Reports Review Subcommittee on February 28, 1983 [see page 8]. Thereafter, the NTP adopted the policy that the experimental data and laboratory records from all NTP toxicology and carcinogenesis studies not yet printed and distributed would be audited. [A summary of the data audit is presented in Appendix I.] Consequently, printing and distribution of this Technical Report have been delayed, and the format differs from that of Technical Reports peer reviewed more recently. The categories of evidence of carcinogenicity adopted by the NTP in June 1983 were not used to evaluate these data. This final Technical Report supersedes all previous drafts of this report that have been distributed.

NTP TECHNICAL REPORT
ON THE
TOXICOLOGY AND CARCINOGENESIS
STUDIES OF CROCIDOLITE ASBESTOS
(CAS NO. 12001-28-4)
IN F344/N RATS
(FEED STUDIES)

Ernest E. McConnell, D.V.M., Chemical Manager

NATIONAL TOXICOLOGY PROGRAM
P.O. Box 12233
Research Triangle Park, NC 27709

December 1988

NTP TR 280

NIH Publication No. 89-2536

U.S. DEPARTMENT OF HEALTH AND HUMAN SERVICES
Public Health Service
National Institutes of Health

NOTE TO THE READER

This study was conducted under contract to the National Institute of Environmental Health Sciences, National Toxicology Program. The studies described in this Technical Report have been conducted in compliance with NTP chemical health and safety requirements and must meet or exceed all applicable Federal, state, and local health and safety regulations. Animal care and use were in accordance with the U.S. Public Health Service Policy on Humane Care and Use of Animals. All NTP toxicology and carcinogenesis studies are subjected to a data audit before being presented for peer review.

Although every effort is made to prepare the Technical Reports as accurately as possible, mistakes may occur. Readers are requested to identify any mistakes so that corrective action may be taken. Further, anyone who is aware of related ongoing or published studies not mentioned in this report is encouraged to make this information known to the NTP. Comments and questions about the National Toxicology Program Technical Reports on Toxicology and Carcinogenesis Studies should be directed to Dr. J.E. Huff, National Toxicology Program, P.O. Box 12233, Research Triangle Park, NC 27709 (919-541-3780).

These NTP Technical Reports are available for sale from the National Technical Information Service, U.S. Department of Commerce, 5285 Port Royal Road, Springfield, VA 22161 (703-487-4650). Single copies of this Technical Report are available without charge (and while supplies last) from the NTP Public Information Office, National Toxicology Program, P.O. Box 12233, Research Triangle Park, NC 27709.

CONTENTS

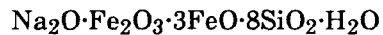
	PAGE
ABSTRACT	5
CONTRIBUTORS	6
PEER REVIEW PANEL	7
SUMMARY OF PEER REVIEW COMMENTS	8
I. INTRODUCTION	11
II. MATERIALS AND METHODS	15
STUDY MATERIAL	16
STUDY DIETS	17
SOURCE AND SPECIFICATIONS OF STUDY ANIMALS	17
ANIMAL MAINTENANCE	21
SAFETY PRECAUTIONS	21
CLINICAL EXAMINATIONS AND PATHOLOGY	22
STATISTICAL METHODS	23
III. RESULTS	25
ESTABLISHMENT OF STUDY GROUPS	26
PATHOGEN BURDEN	26
CLINICAL SIGNS	26
BODY WEIGHTS AND FEED CONSUMPTION	27
SURVIVAL	29
PATHOLOGY AND STATISTICAL ANALYSES OF RESULTS	29
IV. DISCUSSION AND CONCLUSIONS	39
V. REFERENCES	43

APPENDIXES

	PAGE
APPENDIX A	SUMMARY OF LESIONS IN MALE RATS IN THE LIFETIME FEED STUDY OF CROCIDOLITE ASBESTOS 47
APPENDIX B	SUMMARY OF LESIONS IN FEMALE RATS IN THE LIFETIME FEED STUDY OF CROCIDOLITE ASBESTOS 101
APPENDIX C	PATHOGEN BURDEN SURVEY 153
APPENDIX D	ANALYSIS OF BEDDING SAMPLES IN THE LIFETIME FEED STUDIES OF CROCIDOLITE ASBESTOS 163
APPENDIX E	WATER ANALYSIS IN THE LIFETIME FEED STUDIES OF CROCIDOLITE ASBESTOS 165
APPENDIX F	AIR ANALYSIS IN THE LIFETIME FEED STUDIES OF CROCIDOLITE ASBESTOS 167
APPENDIX G	SUMMARY OF CLINICAL SIGNS OBSERVED PRIOR TO MORIBUND KILL IN THE LIFETIME FEED STUDIES OF CROCIDOLITE ASBESTOS 171
APPENDIX H	FEED AND COMPOUND CONSUMPTION BY RATS IN THE LIFETIME FEED STUDIES OF CROCIDOLITE ASBESTOS 175
APPENDIX I	AUDIT SUMMARY 177

CROCIDOLITE ASBESTOS

CAS No. 12001-28-4



ABSTRACT

Carcinogenesis studies of crocidolite asbestos were conducted with male and female F344/N rats. This form of asbestos was administered at a concentration of 1% in pelleted diet for the lifetime of the rats, starting with the dams of the study animals. The studies were started in January 1978 and ended in December 1980. Group sizes were 118 for male and female controls and 250 for male and female crocidolite asbestos-exposed rats.

The offspring from mothers exposed to crocidolite asbestos and the controls were similar in size at birth but were slightly smaller at weaning and remained so throughout their life. Feed consumption and survival were comparable in the exposed and control groups. No overt toxicity was observed in the crocidolite asbestos-exposed animals. There was an elevated ($P < 0.05$) incidence of thyroid gland C-cell adenomas (control, 4/117, 3%, vs. exposed, 23/250, 9%) and of thyroid gland C-cell carcinomas (12/117, 10%, vs. 46/250, 18%) in crocidolite asbestos-exposed female rats relative to concurrent controls. Because these control incidences were low relative to control incidences observed in other contemporary studies at this laboratory (21% for thyroid gland C-cell tumors), this slight increase was not regarded as being biologically important.

The data, documents, and pathology materials from the lifetime studies of crocidolite asbestos have been audited. The audit findings show that the conduct of these studies is documented adequately and support the data and results presented in this Technical Report.

Conclusions: Under the conditions of these feed studies, crocidolite asbestos was not overtly toxic and did not cause a carcinogenic response when ingested at a concentration of 1% in the diet by male and female F344/N rats for their lifetime.

CONTRIBUTORS

The NTP Technical Report on the Toxicology and Carcinogenesis Studies of Crocidolite Asbestos is based on the lifetime studies that began in January 1978 and ended in December 1980 at Hazleton Laboratories America, Inc. (Vienna, Virginia).

National Toxicology Program (Evaluated Experiment, Interpreted Results, and Reported Findings)

E.E. McConnell, D.V.M., Chemical Manager

Gary A. Boorman, D.V.M., Ph.D.
Rajendra S. Chhabra, Ph.D.
Joseph K. Haseman, Ph.D.
James Huff, Ph.D.

John A. Moore, Ph.D.
B. A. Schwetz, D.V.M., Ph.D.
Raymond W. Tennant, Ph.D.

NTP Pathology Working Group (Evaluated Slides and Prepared Pathology Report on 10/7/82)

Miriam Anver (Clement Associates)
G. Boorman, D.V.M., Ph.D. (NTP)

S. Eustis, D.V.M., Ph.D. (NTP)
E. McConnell, D.V.M. (NTP)

Principal Contributors at Hazleton Laboratories America, Inc. (Conducted Studies and Evaluated Tissues)

Henry A. Rutter, Ph.D.
B. Ulland, D.V.M.

Frederick Snyder

Principal Contributors at Experimental Pathology Laboratories, Inc. (Provided Pathology Quality Assurance)

Jerry Hardisty, D.V.M.

Martin Robl, D.V.M.

Principal Contributors at Carltech Associates, Inc. (Contractor for Technical Report Preparation)

William D. Theriault, Ph.D.
Abigail C. Jacobs, Ph.D.

John Warner, M.S.

PEER REVIEW PANEL

The members of the Peer Review Panel who evaluated the draft Technical Report on crocidolite asbestos on February 28, 1983, are listed below. Panel members serve as independent scientists, not as representatives of any institution, company, or governmental agency. In this capacity, Panel members have five major responsibilities: (a) to ascertain that all relevant literature data have been adequately cited and interpreted, (b) to determine if the design and conditions of the NTP studies were appropriate, (c) to ensure that the Technical Report presents the experimental results and conclusions fully and clearly, (d) to judge the significance of the experimental results by scientific criteria, and (e) to assess the evaluation of the evidence of carcinogenicity and other observed toxic responses.

National Toxicology Program Board of Scientific Counselors Technical Reports Review Subcommittee

Margaret Hitchcock, Ph.D. (Chair)
John B. Pierce Foundation Laboratory
New Haven, Connecticut

Curtis Harper, Ph.D. (Principal Reviewer)
Department of Pharmacology
University of North Carolina
Chapel Hill, North Carolina

James A. Swenberg, D.V.M., Ph.D.
Pathology Department
Chemical Industry Institute of Toxicology
Research Triangle Park, North Carolina

Alice S. Whittemore, Ph.D.*
Department of Family, Community and
Preventive Medicine
Stanford University School of Medicine
Palo Alto, California

Ad Hoc Subcommittee Panel of Experts

Louis S. Beliczky, M.S., M.P.H.
Department of Industrial Hygiene
United Rubber Workers International Union
Akron, Ohio

Robert A. Scala, Ph.D.
Exxon Corporation
East Millstone, New Jersey

Devra L. Davis, Ph.D. (Principal Reviewer)
Environmental Law Institute
Washington, D.C.

Thomas J. Slaga, Ph.D.*
University of Texas System, Cancer Center
Smithville, Texas

Robert M. Elashoff, Ph.D. (Principal Reviewer)
University of California at Los Angeles
Jonsson Comprehensive Cancer Center
Los Angeles, California

John Van Ryzin, Ph.D.
Division of Biostatistics
School of Public Health, Columbia University
New York, New York

Seymour L. Friess, Ph.D.
Consultant in Toxicology
Arlington, Virginia

Stan D. Vesselinovitch, D.V.Sc.*
Departments of Radiology and Pathology
University of Chicago
Chicago, Illinois

J. Michael Holland, D.V.M., Ph.D.
Pathology Department
Chevron Environmental Health Center, Inc.
Richmond, California

Mary Vore, Ph.D.
Pharmacology Department
University of Kentucky College of Medicine
Lexington, Kentucky

*Unable to attend meeting

**SUMMARY OF PEER REVIEW COMMENTS
ON THE TOXICOLOGY AND CARCINOGENESIS STUDIES OF
CROCIDOLITE ASBESTOS**

On February 28, 1983, the draft Technical Report on the toxicology and carcinogenesis studies of crocidolite asbestos received peer review by the National Toxicology Program Board of Scientific Counselors' Technical Reports Review Subcommittee and associated Panel of Experts. The review meeting was held in the Conference Center, Building 101, South Campus, National Institute of Environmental Health Sciences, Research Triangle Park, North Carolina.

Dr. E.E. McConnell, NIEHS, introduced the studies by reviewing the experimental design, results, and proposed conclusions (crocidolite asbestos was not overtly toxic and did not cause a carcinogenic response when ingested at a concentration of 1% in the diet by male and female F344/N rats for their lifetime).

Dr. Harper, a principal reviewer, agreed with the conclusions as written. He said that offspring of asbestos-fed mothers were slightly smaller at weaning than were offspring of control mothers and that this fact should be emphasized.

A second principal reviewer, Dr. Elashoff, agreed with the conclusions. He noted that the justifiable use of historical control data on the incidences of thyroid gland C-cell adenomas and carcinomas in male rats likely averted a probable false positive finding in this study. He expressed interest and concern as to the design considerations and tradeoffs that led to use of a single dose group, the stated concentration, and the stated sample size. Dr. McConnell described the rationale for the design of these and other asbestos studies in the series. Because of the high dietary exposure (1%) and the lifetime duration of the studies, the design committee decided to recommend larger but fewer exposure groups.

As a third principal reviewer, Dr. Davis said that the thyroid gland tumors were a carcinogenic response but that because of the control incidences in the other lifetime asbestos studies, the results might not be important. She commented that additional data on tumor incidences in recent control groups, data on feed contaminants for both experimental and control groups, and data from 24-month rat studies would provide valuable information for further interpretation of the results from the current studies. Dr. Davis noted that by incorporating bulk rather than fractionated asbestos into the feed, a majority of the fibers were much longer than fibers to which humans are usually exposed in drinking water and that there is an inverse correlation between fiber length and toxicity and biologic translocation. She expressed concern that there were no specifications in the report of engineering and safety practices regarding production of the asbestos and preparation of the pellets used in the diet. She recommended that environmental and occupational monitoring be done of firms preparing test substances. She said that the increased longevity and decreased body weights in crocidolite asbestos-exposed animals merited more emphasis and speculated that the decreased weight might have been due in part to more rapid gastrointestinal transit time produced by the high fiber diet. Dr. Davis urged that due consideration be given to new studies using smaller fibers that are fractionated by size and, further, that exposure of animals should be through drinking water.

There was considerable discussion among panel members and NTP staff concerning the aspect ratio for the fibers used in the studies which was greater than the optimal aspect ratios for biologic translocation and carcinogenicity. With regard to diet formulation and route of exposure, Dr. McConnell said that had ground or fractionated fibers been used, there could have been a potential safety hazard as well as some undesired inhalation exposure. Administration in water would have been more hazardous to laboratory personnel, and because of settling of fibers, the dosage would have been uncertain. In terms of fiber size, he stated that fibers of the size range used were potent carcinogens for the

pleural cavity. He said that NTP could do an ashing study on tissues such as liver, kidney, and lymph nodes to see if fibers were present. Dr. Scala opined that useful information could be gained by grinding up or dissolving some of the asbestos pellets and examining the fiber composition. Dr. Moore said that data were available which characterize the proportion of fibers by length and width by electron microscopic examination. Dr. Swenberg asked for the incidences of thyroid gland C-cell tumors in recent lifetime studies. Dr. Haseman replied that in four recent lifetime studies carried out at this laboratory, these incidences were 20%, 21%, 21%, and 24%, which, taken together, were similar to the 27% incidence in the crocidolite asbestos-exposed animals. Dr. Davis requested that the wording of the last sentence of the second paragraph of the abstract be changed to say that "this slight increase [in tumor incidence] was not regarded as being biologically important," with "important" replacing "significant."

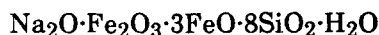
Dr. Davis then moved that the Technical Report on crocidolite asbestos be accepted with the additions and revisions discussed. Dr. Harper seconded the motion, which was approved unanimously.

I. INTRODUCTION

I. INTRODUCTION

CROCIDOLITE ASBESTOS

CAS No. 12001-28-4



The term "asbestos" has a commercial/industrial derivation limited to naturally occurring fibrous minerals of the serpentine or amphibole series. Chrysotile is the only type of asbestos in the serpentine series, whereas the amphibole series is represented by actinolite, amosite, anthophyllite, crocidolite, and tremolite. Chrysotile is the most abundant and widely used of the various types of asbestos. The essential characteristic of asbestos minerals is their fibrous nature.

Studies conducted during the past 25 years have established a clear association between occupational exposure to asbestos and increased risk of cancer. Excellent reviews of public health effects associated with past heavy asbestos exposure, primarily occupational exposure via the inhalation route, are those by Craighead and Mossman (1982), Peto and Schneiderman (1981), Selikoff (1980), the U.S. Environmental Protection Agency (EPA) (USEPA, 1980), Selikoff and Hammond (1979), and the International Agency for Research on Cancer (IARC, 1977). These studies clearly established causal association between occupational inhalation exposure to chrysotile, amosite, crocidolite, and anthophyllite asbestos and an increased risk of lung cancer as well as mesothelioma. The latter form of cancer is perhaps unique in its association with these fibrous minerals and is particularly associated with exposure to crocidolite asbestos (Wagner et al., 1960). A noteworthy review of the pathology associated with inhalation exposure to asbestos is that by Craighead et al. (1982).

Large portions of the population ingest asbestos through consumption of food and water (NAS, 1977). Analysis of water samples from 359 cities found that 65% of the samples had detectable levels of various types of asbestos (Millette et al., 1983). The water supplies of 41 cities have had asbestos concentrations in water which exceeded 10 million fibers per liter, but the length of the vast majority of fibers is under 5 μm . Asbestos or asbestos-like fibers may enter water supplies as a result of mining (e.g., operations at Lake Superior). Natural serpentine or amphibole

deposits have been detected in watersheds (Seattle, Washington, and San Francisco, California); under certain conditions, the presence of asbestos may have resulted from the use of chrysotile asbestos-cement pipe for municipal water supplies (USEPA, 1980). In the latter instance, erosion of the pipe (and release of fibers) is associated with the "aggressiveness" of the water, a term representing a mathematical expression of alkalinity and calcium content. Approximately 69% of the water systems in the United States have aggressive water that has the potential to erode asbestos-cement pipe.

Several studies have provided evidence that ingestion of asbestos in either food or water can result in the migration of asbestos through the gastrointestinal mucosa and to distant organ sites in humans (Carter and Taylor, 1980), in rats (Cunningham et al., 1977; Sebastien et al., 1980), and in baboons (Storeygard and Brown, 1977; Patel-Mandlik, 1980). Electron microscopic studies confirmed the presence of amphibole mineral fibers in the urine of individuals who ingested water containing these fibers (Cook and Olson, 1979).

Harrington et al. (1978) did not detect an association between the use of asbestos-cement pipe for municipal water supplies and the incidence of gastrointestinal cancer. Statistically significant trends for the incidence of several cancer types, including stomach, gallbladder, esophageal, and peritoneal cancer, were found when census tracts were analyzed on a gradient of low to high asbestos content in municipal water in the San Francisco Bay area (Cooper et al., 1979). The association between asbestos concentration in San Francisco Bay area drinking water and cancer was confirmed in subsequent studies (Kanarek, 1983; Conforti, 1983).

Inhalation of asbestos by laboratory animals produces lung carcinoma and mesothelioma in the pleural cavity (Wagner et al., 1974). Intrapleural, intratracheal, and intraperitoneal injection of asbestos will also produce neoplasia in

several species of laboratory animals (Wagner, 1962; Stanton and Wrench, 1972; Levine, 1978; Stanton et al., 1981).

Asbestos (chrysotile, amosite, and crocidolite) has been shown to be cytotoxic in vitro to human embryonic intestinal cells, mouse epithelial-like colon-derived cells, and rat liver epithelial cells (Reiss et al., 1979). Chrysotile asbestos was far more toxic than were the amphibole fibers, and the effects were more pronounced in the intestine-derived cells than in those from the liver. Chrysotile asbestos also was found to be cytotoxic to Syrian hamster (Bey and Harrington, 1971) and mouse (Wright et al., 1983) peritoneal macrophages and to rabbit alveolar macrophages (Desai and Richards, 1983). Chrysotile, amosite, and crocidolite asbestos were not mutagenic in *Salmonella typhimurium* or *Escherichia coli* (Chamberlain and Tarmy, 1977) or at the HGPRT locus in mammalian cells (Reiss et al., 1982; Oshimura et al., 1984).

In November 1973, the National Institute of Environmental Health Sciences and the EPA co-sponsored a symposium on the possible biologic effects of ingested asbestos (EHP, 1974). The participants at this conference concluded that the data concerning the effects of ingested asbestos were inadequate and that specific research was needed.

A subcommittee of the U.S. Department of Health, Education, and Welfare (now the U.S. Department of Health and Human Services) Committee to Coordinate Toxicology and Related Programs subsequently reviewed existing data and prepared a draft research protocol that the Committee felt was responsive to the major public health consensus. On the basis of comments received, a revised protocol was developed by the NTP for long-term animal toxicology and carcinogenesis studies. The forms of asbestos included chrysotile tested in Syrian golden hamsters (NTP, 1988a) and in F344/N rats (NTP, 1985a), amosite in Syrian golden hamsters (NTP, 1985b) and in F344/N rats (NTP, 1988b), crocidolite in F344/N rats (this report), and a nonfibrous tremolite, which contained low levels of asbestiform fibers, in F344/N rats (NTP, 1988c). All studies encompassed the lifetime of the animal, including exposure of the dams from which the study animals were derived. A single concentration of 1% in the diet was chosen because it represented the highest concentration thought to be reasonable from a biologic standpoint and that could be tolerated in a lifetime study.

This Technical Report presents the results of those studies undertaken to determine the effects of crocidolite asbestos fed to male and female F344/N rats in the diet.

II. MATERIALS AND METHODS

STUDY MATERIAL

STUDY DIETS

SOURCE AND SPECIFICATIONS OF STUDY ANIMALS

ANIMAL MAINTENANCE

SAFETY PRECAUTIONS

CLINICAL EXAMINATIONS AND PATHOLOGY

STATISTICAL METHODS

II. MATERIALS AND METHODS

STUDY MATERIAL

The crocidolite asbestos used in these studies was purchased by the U.S. Bureau of Mines from Certain-Teed Co. The 6,000-pound sample was identified as ML-6. Air jet milling was selected because this type of pulverizer would be the least damaging to the amphibole crystalline structure. The sample was passed through the mill twice to reduce the number of very long fibers in the final material. The crocidolite asbestos was bagged in 100-pound silicone-treated Dacron® filter bags.

To homogenize the sample, lots of six 100-pound bags were manually blended on a 5-foot × 8-foot blending table. After final blending, 1,200 pounds of crocidolite asbestos was packaged in 20-pound lots in virgin fiberboard containers. These drums were shipped to a special warehouse at Research Triangle Park, North Carolina. Each drum received a color marking unique to the mineral type. Homogeneity of the

samples was verified by fluorescent X-ray spectrography from samples collected from six randomly selected drums. No significant differences were detected for samples from the various containers.

The homogeneity of the samples and the physical and chemical properties of the material have been extensively characterized (Bureau of Mines, 1980; IITRI). [Copies of these reports are available on request from the National Toxicology Program (Public Information Office, National Toxicology Program, P.O. Box 12233, Research Triangle Park, NC 27709).] Selected chemical and physical properties of crocidolite are presented in Tables 1 and 2 (Bureau of Mines (1980). In an analysis of mineralogic composition, crocidolite ($\text{Na}_2\text{O}\cdot\text{Fe}_2\text{O}_3\cdot 3\text{FeO}\cdot 8\text{SiO}_2\cdot\text{H}_2\text{O}$) was detected at a volume percent abundance of 99%; trace amounts (less than 1% total) of biotite, quartz, opaques, feldspar, and glass were found.

TABLE 1. FIBER CHARACTERISTICS AND CHEMICAL INSTRUMENTAL ANALYSIS OF CROCIDOLITE ASBESTOS

Fiber characteristics			
Surface area (m^2/g)		9.8 ± 1.0	
Density (g/cm^3)		3.32 ± 0.08	
Mean length (μm) by electron microscopy		10	
Mean width (μm) by electron microscopy		0.27	
Chemical instrumental analysis (expressed as weight percent)			
Al_2O_3	0.07	TiO_2	0.07
CaO	1.04	MnO	0.08
FeO	18.32	Cr_2O_3	0.02
Fe_2O_3	18.62	CO_2	2.18
MgO	3.81	H_2O^-	0.45
K_2O	0.07	H_2O^+	2.10
SiO_2	48.73	Benzene-extracted organics	0.041
Na_2O	4.43		

TABLE 2. PARTICLE SIZE DISTRIBUTION OF CROCIDOLITE ASBESTOS BY PARTICLE NUMBER (a)

	Length Interval (µm)							
	8-8.99	9-9.99	10-19.99	20-39.99	40-59.99	60-79.99	80-99.99	>100
Crocidolite asbestos mean width (µm)	0.31	0.29	0.28	0.35	0.40	0.33	0.44	0.64
Crocidolite asbestos particles per interval	29	39	125	72	25	12	1	10
Percent of total crocidolite asbestos particles	2.8	3.8	12.0	6.8	2.4	1.1	0.1	1.0
Cumulative percent crocidolite asbestos	72.8	76.6	88.6	95.4	97.8	98.9	99.0	100
Volume percent crocidolite asbestos (b)	1.6	1.8	7.4	18.9	12.4	7.3	1.0	39.4
Cumulative volume percent crocidolite asbestos	11.8	13.6	21.0	39.9	52.3	59.6	60.6	100
Number of other particles	0	0	0	0	0	0	0	0
Crocidolite asbestos particles per length interval, percent, by aspect ratio								
1:1-2.9:1	0	0	0	0	0	0	0	0
3:1-4.9:1	0	0	0	0	0	0	0	0
5:1-9.9:1	7	0	0	0	0	0	0	0
10:1-19.9:1	0	3	1	1	0	0	0	0
20:1-49.9:1	83	89	48	5	0	0	0	0
50:1-99.9:1	10	8	45	53	16	16	0	0
100:1-199:1	0	0	6	39	64	42	0	50
200:1-499:1	0	0	0	2	20	42	100	50

(a) By electron microscopy; total particles = 1,050; total crocidolite asbestos = 1,040; total others = 10.

(b) Calculated from particle number data, assuming a rectangular cross-section with third dimension equal to one-third measured width

STUDY DIETS

The feed used was NIH 31 Rat and Mouse Ration. Crocidolite asbestos was incorporated to a concentration of 1% by weight into the study diet. Pilot studies determined that homogeneous mixing of crocidolite asbestos and feed would occur in a blender loaded by alternate layering of feed and crocidolite asbestos. Results of analyses for crocidolite asbestos in feed are given in Table 3. Each lot of blended feed was analyzed for crocidolite asbestos concentration, pesticide contamination, and nutrient content. Further details are given in Table 4.

SOURCE AND SPECIFICATIONS OF STUDY ANIMALS

Parental Generation (F₀): Weanling F344/N (cesarean-derived) rats, which were barrier sustained and specific pathogen free, were purchased from Charles River Breeding Laboratories. These animals constituted the F₀

generation and were received November 15, 1977 (Figure 1).

On arrival, animals were taken directly to the quarantine area and acclimated to laboratory conditions for approximately 2 weeks. Twenty-four hours after arrival, eight rats of each sex were selected at random, and pathogen burden was determined for each animal. Pathogens examined for included ectoparasites (mites, fleas, and lice), intestinal parasites (fecal flotation), and bacteria (*Mycoplasma sp.*, *Salmonella sp.*, *Diplococcus pneumoniae*, *Corynebacterium kutscheri*, and *Streptobacillus moniliformis*). Serologic tests were conducted for viruses (Appendix C, Tables C1-C3).

After approximately 2 months in quarantine (the regular 3- to 4-week quarantine period was extended because of a shortage of cages), male and female rats (15-16 weeks old) were separated randomly on January 27, 1978, into two groups (control and crocidolite asbestos) according to tables of random numbers.

TABLE 3. RESULTS OF ANALYSIS OF FORMULATED DIETS IN THE LIFETIME FEED STUDIES OF CROCIDOLITE ASBESTOS

Date Mixed	Determined Concentration in Feed for Target Concentration of 10,000 ppm (1%) (a)
11/21/77	11,100 ± 900
12/07/77	11,000 ± 500
02/01/78	9,100 ± 240
03/22/78	10,500 ± 30
05/22/78	11,800 ± 30
07/11/78	9,500 ± 20
09/14/78	11,600 ± 120
10/30/78	9,500 ± 60
12/15/78	9,300 ± 40
02/15/79	9,200 ± 40
04/02/79	10,900 ± 60
05/09/79	11,300 ± 60
06/26/79	10,700 ± 30
08/28/79	10,000 ± 100
10/16/79	10,000 ± 130
12/03/79	9,600 ± 430
01/10/80	9,500 ± 260
02/27/80	8,900 ± 170
04/18/80	8,900 ± 90
05/29/80	13,200 ± 290
07/18/80	10,500 ± 160
08/26/80	9,400 ± 40
10/13/80	9,600 ± 150
	Mean = 10,200 ± 210

(a) Average of five samples

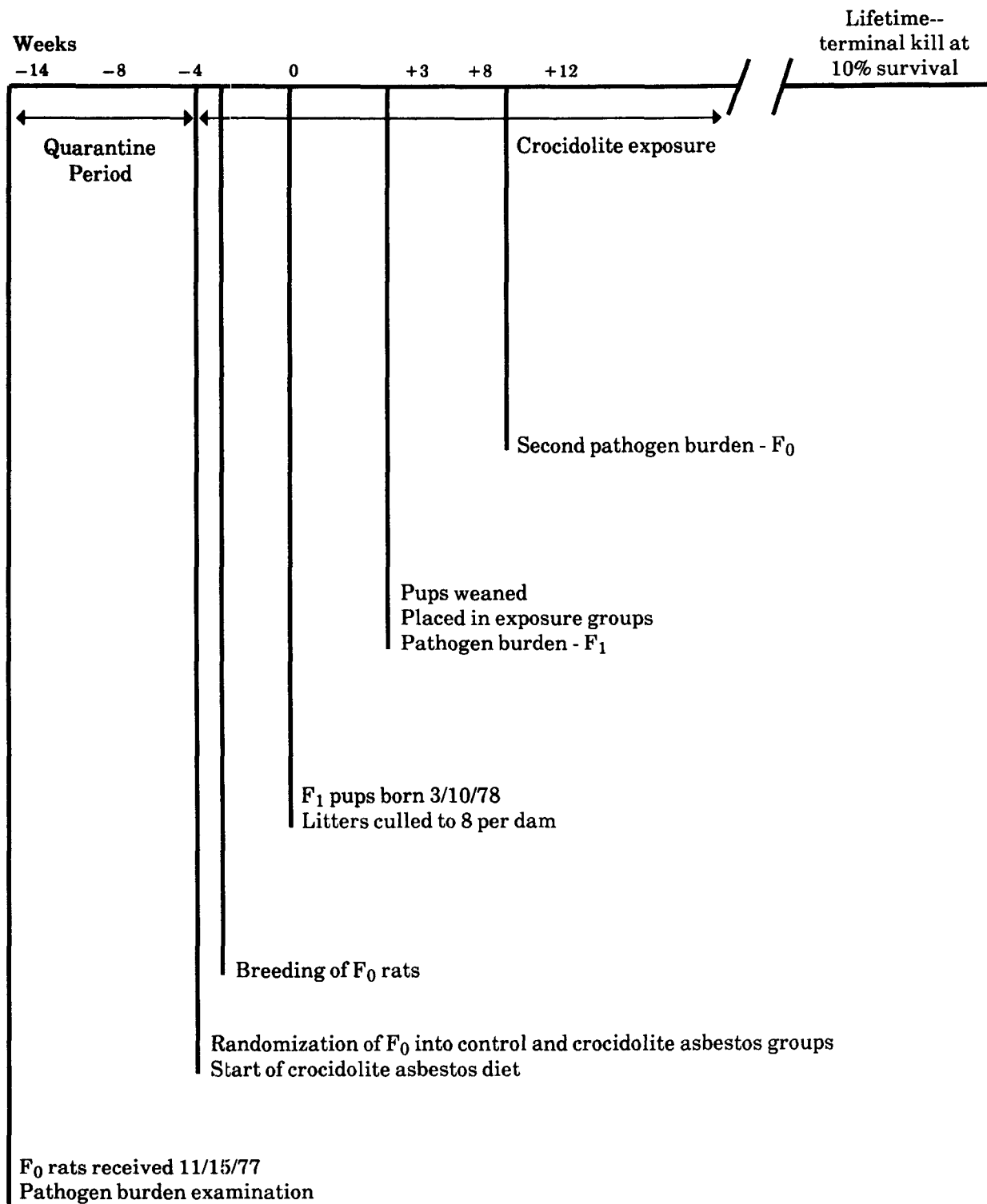


FIGURE 1. SCHEDULE OF MAJOR EVENTS IN RATS IN THE LIFETIME FEED STUDIES OF CROCIDOLITE ASBESTOS

TABLE 4. EXPERIMENTAL DESIGN AND MATERIALS AND METHODS IN THE LIFETIME FEED STUDIES OF CROCIDOLITE ASBESTOS

EXPERIMENTAL DESIGN

Size of Study Groups	F ₀ --control: male, 25; female, 50; dosed: male, 75; female, 150; F ₁ --control: 118; crocidolite asbestos: 250 rats of each sex
Doses	0% or 1% (10,000 ppm) crocidolite asbestos in feed
Date of First Dose	F ₀ --obtained 11/15/77, bred starting 2/17/78; F ₁ --date of weaning 4/1/78
Duration of Dosing	Lifetime until only 10% of the group remained
Type and Frequency of Observation	Observed 2 × d; examined clinically 1 × wk; weighed 1 × wk
Necropsy and Histologic Examination	Necropsy performed on all animals. Tissues examined histologically: adrenal glands; bone marrow (sternum); brain; bronchial, celiac, cervical, iliac, iliocolonic, mandibular, mesenteric, pancreatic, and renal lymph nodes; cecum; colon (carpet rolled); duodenum; esophagus; heart; ileum; jejunum; kidneys; larynx; liver; lungs and bronchi; mammary gland; pancreas; parathyroids; pituitary gland; prostate/testes or ovaries/uterus; salivary glands; small intestine; spleen; stomach; thigh muscle; thyroid gland; tissue masses; trachea; and urinary bladder. Epididymis, eyes, nasal cavity with turbinates, seminal vesicles, and spinal cord were examined microscopically if gross lesions were observed

ANIMALS AND ANIMAL MAINTENANCE

Strain and Species	F344/N rats
Animal Source	Charles River Breeding Laboratories (Wilmington, MA)
Study Laboratory	Hazleton Laboratories of America
Age When Placed on Study	F ₀ --15-16 wk prior to delivery of F ₁
Age When Killed	F ₁ --male: 142 wk; female: 145 wk
Necropsy Dates	Lifetime study
Method of Animal Distribution	According to tables of computer-generated random numbers
Feed	NIH 31 Rat and Mouse Ration (Zeigler Bros., Inc., Gardners, PA); available ad libitum
Bedding	Sani Chips® (J. P. Murphy, Rochelle Park, NJ, and Shurfire, Baltimore, MD)
Water	Tap water ad libitum
Cages	Polycarbonate (Hazleton Systems, Aberdeen, MD); stored on Enviro-racks®
Cage Filters	Remay nonwoven polyester sheets (Nationwide Papers, Washington, DC)
Animals per Cage	F ₀ --1 for males, 2 for females during breeding; 2 for males, 1 for females after breeding; F ₁ --3
Other Chemicals on Study in the Same Room	None
Animal Room Environment	Temp--23° ± 2° C; hum--50% ± 10%; fluorescent light 12 h/d; 10-15 room air changes/h

CHEMISTRY

Lot Numbers Used	N/A
Supplier	Certain-Teed (Ambler, PA); obtained from a mine in South Africa located near the Kalahari Desert in the Kuruman Hills

TABLE 4. EXPERIMENTAL DESIGN AND MATERIALS AND METHODS IN THE LIFETIME FEED STUDIES OF CROCIDOLITE ASBESTOS (Continued)

FORMULATED DIETS

Preparation	20 lb crocidolite asbestos/ton of feed mixed in a 55-ft ³ Patterson-Kelly® V-blender with intensifier bar; oval, 3/8-inch × 3/4-inch pellets prepared with Sprout-Waldron pellet mill. Pelleted feed packaged in 25-pound aliquots in standard paper feed bags that were color coded
Storage Conditions	Not available

After at least 7 days' exposure to the designated diets, the rats (16-17 weeks old) were placed in breeding cages (one male to two females) on February 3, 1978. During the breeding period, the rats continued to be fed the same diets. Twenty days later (on the average), females were separated and housed individually in polycarbonate cages. Males were removed from the breeding cages and rehoused two per cage.

After the pups were born and placed on the lifetime feeding phase of the study, 10 rats (5 rats of each sex) were selected from the F₀ generation for additional pathogen burden determinations (Tables C4-C6) to assure that the animals remained in acceptable health according to the infectious disease criteria.

Filial Generation (F₁): The F₀ females were allowed to deliver their F₁ litters naturally, and these were culled to groups of no more than eight pups (four per sex if possible) per litter. No particular system was used in reducing the number of pups to eight (other than four per sex).

At birth, the litters from the F₀ dams within the control and dosed groups were assigned randomly to the corresponding lifetime feeding phase groups (control and dosed) such that birth dates were equally distributed. Twenty-one days after birth, the pups were weaned, given a temporary number, and then assigned, according to a table of random numbers, to groups for the lifetime feed study. Litters in which only one sex was present were excluded from those animals to be selected. At this time, 16 rats (8 rats per sex) were selected for pathogen burden determinations (Tables C7-C9).

ANIMAL MAINTENANCE

The control and crocidolite asbestos-exposed rats were placed in separate rooms with monitored temperature and humidity and a controlled light cycle. Attempts were made to maintain the temperature at 74° ± 4° F and humidity at 50% ± 10%. Racks and filters were changed approximately once every 2 weeks. Cages and bedding were replaced twice per week. Bedding samples were collected periodically for analysis (Appendix D). Control and formulated diets and tap water via automatic waterers were available ad libitum. Two water samples were collected and submitted for analysis (Appendix E). Stainless steel feed containers were changed once every 2 weeks. Sources and description of the materials used for animal maintenance are presented in Table 4.

SAFETY PRECAUTIONS

The incoming air to the animal rooms was filtered to remove particulate matter. Ten to 15 changes of room air per hour were provided. Before initiation of the study, air samples were collected and analyzed for baseline asbestos concentrations. Additional samples were collected approximately every 6 months for analysis to assure personnel safety (Appendix F).

Other measures used for personnel protection included the wearing of fully protective disposable suits, gloves, boots, and bouffant caps and the use of a dust/mist respirator mask approved by the Occupational Safety and Health Administration. Personnel leaving the animal rooms were required to dispose of their protective clothing and to take showers. In addition, physical

II. MATERIALS AND METHODS

examinations, including pulmonary function tests and chest radiographs, were conducted at the initiation of the study, once per year thereafter, and at the end of the studies.

CLINICAL EXAMINATIONS AND PATHOLOGY

Rats were observed two times per day. Body weights by cage were recorded once per week for the duration of the studies. Mean body weights were calculated for each group. Moribund animals were killed, as were animals that survived to the end of the study. A necropsy was performed on all animals, including those found dead unless they were excessively autolyzed or cannibalized. Thus, the number of animals from which particular organs or tissues were examined microscopically varies and is not necessarily equal to the number of animals that were placed on study in each group. Animals were killed when exhibiting any one of these conditions:

1. Palpable masses within the abdominal cavity (excluding retained testes)
2. Masses protruding from the rectum.
3. Rectal discharge of bright red fluid (an indication of the presence of a bleeding colonic or rectal neoplasm)
4. Large ulcerated masses in the area of the ears or on the side of the face (Zymbal gland tumors)
5. Large subcutaneous masses that were ulcerated or infected.
6. Masses that interfered with breathing and eating or that severely hampered locomotion
7. Huge tissue masses
8. Central nervous system signs accompanied by weight loss (head tilt, circling, incoordination, ataxia, paralysis)
9. Severe weight loss or emaciation
10. Coma or extreme weakness.

When the remaining animals of the crocidolite asbestos-exposed group of either sex reached 10% of those starting the studies, that group and the corresponding control group for that sex were killed. Animals were killed by exsanguination under sodium pentobarbital anesthesia (Nembutal®, Abbott Laboratories, Inc., North

Chicago, Illinois, or Diabotal®, Diamond Laboratories, Inc., Des Moines, Iowa). Final body weights were recorded, and necropsies were performed which included blood smears taken from animals killed in extremis or those killed at the end of the study and touch preparations made from any enlarged spleen or lymphoid organ.

The gastrointestinal tract, chosen as one of the target organs before these studies began, was handled in a slightly different manner than in standard long-term rodent carcinogenesis studies. Before being placed in fixative, the entire esophagus was opened and pinned with the exterior surface adjacent to cardboard. The stomach and cecum were prepared similarly. Two-centimeter lengths of duodenum and ileum and two portions of jejunum were placed unopened in fixative. The remaining small intestine was opened, washed gently with saline, and carefully examined by transillumination on a radiograph viewing box. Suspected lesions were processed separately and identified individually as to location. Likewise, the entire colon with anus was opened, examined, and pinned to cardboard (serosal surface down) before fixation. The size and location of masses were recorded. Masses greater than 1 mm in diameter were removed as separate specimens for processing. After fixation and before embedding, the colon was "carpet-rolled" starting at the posterior end, with the mucosal surface inward.

Examinations for grossly visible lesions were performed on major tissues or organs. Tissues were preserved in 10% neutral buffered formalin, embedded in paraffin, sectioned, and stained with hematoxylin and eosin. Tissues examined microscopically are listed in Table 4.

When the pathology examination was completed, the slides, individual animal data records, and summary tables were sent to an independent quality assurance laboratory. Individual animal records and tables were compared for accuracy, slides and tissue counts were verified, and histotechnique was evaluated. All tumor diagnoses, all target tissues, and all tissues from a randomly selected 10% of the animals were evaluated by a quality assurance pathologist. Slides of all target tissues and those about which the original and quality assurance pathologists

II. MATERIALS AND METHODS

disagreed were submitted to the Chairperson of the Pathology Working Group (PWG) for evaluation. Representative coded slides selected by the Chairperson were reviewed by PWG pathologists, who reached a consensus and compared their findings with the original and quality assurance diagnoses. When diagnostic differences were found, the PWG sent the appropriate slides and comments to the original pathologist for review. This procedure has been described, in part, by Maronpot and Boorman (1982) and Boorman et al. (1985). The final diagnoses represent a consensus of contractor pathologists and the NTP Pathology Working Group.

STATISTICAL METHODS

Data Recording: Data on this experiment were recorded in the Carcinogenesis Bioassay Data System (Linhart et al., 1974). The data elements include descriptive information on the chemicals, animals, experimental design, survival, body weight, and individual pathology results, as recommended by the International Union Against Cancer (Berenblum, 1969).

Survival Analyses: The probability of survival was estimated by the product-limit procedure of Kaplan and Meier (1958) and is presented in the form of graphs. Animals were censored from the survival analyses at the time they were found to be missing or dead from other than natural causes; animals dying from natural causes were not censored. Statistical analyses for a possible dose-related effect on survival used the method of Cox (1972) for testing two groups for equality and Tarone's (1975) life table test for a dose-related trend. When significant survival differences were detected, additional analyses using these procedures were carried out to determine the time point at which significant differences in the survival curves were first detected. All reported P values for the survival analysis are two-sided.

Calculation of Incidence: The incidence of neoplastic or nonneoplastic lesions has been given as the ratio of the number of animals bearing such lesions at a specific anatomic site to the number of animals in which that site was examined. In most instances, the denominators include only those animals for which the site was

examined histologically. However, when macroscopic examination was required to detect lesions (e.g., skin or mammary tumors) prior to histologic sampling, or when lesions could have appeared at multiple sites (e.g., lymphomas), the denominators consist of the number of animals on which a necropsy was performed.

Analysis of Tumor Incidence: Three statistical methods are used to analyze tumor incidence data: life table tests, incidental tumor analysis, and Fisher exact/Cochran-Armitage trend analyses. Tests of significance include pairwise comparisons of high dose and low dose groups with controls and tests for overall dose-response trends. For studies in which administration of the test compound has little effect on survival, the results of the three alternative analyses will generally be similar. When differing results are obtained by the three methods, the final interpretation of the data will depend on the extent to which the tumor under consideration is regarded as being the cause of death. Continuity-corrected tests are used in the analysis of tumor incidence, and reported P values are one-sided. The procedures described below also were used to evaluate selected nonneoplastic lesions.

*Life Table Analyses--*The first method of analysis assumed that all tumors of a given type observed in animals dying before the end of the study were "fatal"; i.e., they either directly or indirectly caused the death of the animal. According to this approach, the proportions of tumor-bearing animals in the dosed and control groups were compared at each point in time at which an animal died with a tumor of interest. The denominators of these proportions were the total number of animals at risk in each group. These results, including the data from animals killed at the end of the study, were then combined by the Mantel-Haenszel method (1959) to obtain an overall P value. This method of adjusting for intercurrent mortality is the life table method of Cox (1972) and of Tarone (1975). The underlying variable considered by this analysis is time to death due to tumor. If the tumor is rapidly lethal, then time to death due to tumor closely approximates time to tumor onset. In this case, the life table test also provides a comparison of the time-specific tumor incidences.

II. MATERIALS AND METHODS

Incidental Tumor Analyses--The second method of analysis assumed that all tumors of a given type observed in animals that died before the end of the study were "incidental"; i.e., they were merely observed at necropsy in animals dying of an unrelated cause. According to this approach, the proportions of tumor-bearing animals in dosed and control groups were compared in each of five time intervals: weeks 0-60, weeks 61-86, weeks 87-112, weeks 113-126, and beyond week 126. The denominators of these proportions were the number of animals actually examined for tumors during the time interval. The individual time interval comparisons were then combined by the previously described method to obtain a single overall result. (See Haseman, 1984, for the computational details of both methods.)

Fisher Exact/Cochran-Armitage Trend Analyses--In addition to survival-adjusted methods, the results of the Fisher exact test for pairwise comparisons and the Cochran-Armitage linear trend test (Armitage, 1971; Gart et al., 1979) are given in the appendix containing the analyses of tumor incidence. These two tests are based on the overall proportion of tumor-bearing animals and do not adjust for survival differences.

Historical Control Data: Although the concurrent control group is always the first and most appropriate control group used for evaluation, there are certain instances in which historical control data can be helpful in the overall assessment of tumor incidence. Consequently, control tumor incidences from the NTP historical control data base (Haseman et al., 1984, 1985) are included for those tumors appearing to show compound-related effects.

III. RESULTS

ESTABLISHMENT OF STUDY GROUPS

PATHOGEN BURDEN

CLINICAL SIGNS

BODY WEIGHTS AND FEED CONSUMPTION

SURVIVAL

PATHOLOGY AND STATISTICAL ANALYSES OF

RESULTS

III. RESULTS

ESTABLISHMENT OF STUDY GROUPS

The studies were designed to evaluate the effects of ingested crocidolite asbestos during the entire life of the animal, starting from the time the rats were able to eat solid food. For this reason, the mated female rats had been on the study diets for approximately 14 weeks when the first litters were born. To minimize the chance that the mothers would reject or cannibalize their young, the litters were not handled during lactation except for weighing and culling at birth.

Litter size and survival of offspring were unaffected by the presence of crocidolite asbestos in the diet. The average number of live fetuses born to crocidolite asbestos-exposed dams was 7.7 vs. 7.4 for the control groups. The average weight at birth of the crocidolite asbestos-exposed pups, determined by dividing the weight of each litter by the number of live pups, was 4.8 g vs. 5.0 g for the controls. The crocidolite asbestos-exposed offspring were smaller at weaning than were controls (22.2 g vs. 27.5 g).

A summary of groups, number of animals, diets for the parental (F_0) animals, as well as the distribution of and diets for the filial (F_1) animals is presented in Figure 1 and Table 4.

PATHOGEN BURDEN

The tissues of the F_0 animals evaluated for pathogen burden revealed evidence of early spontaneous respiratory disease present in the lungs of all but one of the rats examined (Appendix C). The lesions consisted of minimal to slight peribronchial lymphoid hyperplasia and minimal perivascular lymphoid hyperplasia in three of these rats. In the repeated pathogen burden examination of the F_0 animals, evidence of respiratory disease was noted in all animals. This disease was characterized by moderate peribronchial lymphoid hyperplasia in all rats with an accompanying bronchial exudate in six males. The respiratory disease was slightly more pronounced than that observed at the earlier kill.

In the lungs of all F_1 rats examined, evidence of early spontaneous respiratory disease was present, characterized by minimal to slight peribronchial lymphoid hyperplasia.

No serologic evidence of Sendai virus was present in either F_0 or F_1 animals (Appendix C).

CLINICAL SIGNS

A summary of clinical signs from weeks 83 to 112 is presented in Appendix G. This time period was chosen for illustration because few signs were noted before week 83 and age-related signs complicated the observations after week 112.

The incidence of clinical signs occurred at essentially comparable frequencies in the crocidolite asbestos-exposed and control rats throughout the studies. The following representative findings were observed at generally comparable frequencies in all groups: soft feces; urine stains; pale, thin and/or hunched appearance; depression; localized alopecia or sores on head or body; rough haircoats; abnormal eyes (pale, cloudy, bloody crust, red, lacrimation, squinting, enlarged, sores, swollen, red discharge, protruding, small and/or necrotic); head tilt; salivation; localized swellings; stains on fur; bloated appearance; necrotic or abscessed tail; discharge from anus or vagina; protruding penis or vagina; small or enlarged testis; wheezing; wasting feed or decreased feed consumption; and labored respiration and/or abnormal central nervous system responses (circling, hyperactivity, loss of equilibrium, tremors, isolated occurrences of paralysis and/or ataxia).

As the study proceeded, the incidence of clinical signs increased in all groups. At intervals during which a large number of moribund animals were killed in any one particular group, the clinical signs most frequently observed were supportive of the conditions for moribund kills as outlined in the Materials and Methods section.

BODY WEIGHTS AND FEED CONSUMPTION

Mean body weights of rats in the lifetime feed studies, body weights relative to controls, and survival are presented in Table 5; mean body weights are also shown in Figure 2.

Mean body weights were statistically analyzed at selected intervals: birth and weeks 3, 8, 10, 14, 23, 34, 58, 86, and 112 for the males and birth and weeks 3, 8, 11, 16, 27, 48, 60, 86, and 112 for the females. The birth weights of pups from exposed and control dams were approximately the same but the crocidolite asbestos-exposed pups weighed 19% less than did the

controls at weaning. The depression in body weight gain in the crocidolite asbestos-exposed rats was greatest at 7 weeks of age (male, 32%; female, 23%), after which time weight gain was parallel to that in the controls for the remainder of the studies, with mean body weights remaining lower at all time points.

A summary of average weekly feed consumption per rat and ratios for dosed vs. control groups is given in Appendix H. The average weekly feed consumption by the crocidolite asbestos-exposed males and females was 95% that by the controls. These differences may have contributed to some degree to the depressed body weight gain in the crocidolite asbestos-exposed rats.

TABLE 5. MEAN BODY WEIGHTS AND SURVIVAL OF RATS IN THE LIFETIME FEED STUDIES OF CROCIDOLITE ASBESTOS

Weeks on Study (from birth)	Control		1% Crocidolite		
	Av. Wt. (grams)	No. of Survivors	Av. Wt. (grams)	Wt. (percent of controls)	No. of Survivors
MALE					
7	165	118	112	68	250
17	312	118	244	78	250
27	359	118	317	88	249
37	408	118	351	86	249
47	411	118	366	89	248
57	443	118	392	88	248
67	466	117	413	89	247
77	471	114	427	91	246
87	471	109	429	103	240
97	464	102	424	91	230
107	460	89	419	91	206
117	424	65	399	94	167
127	401	45	373	93	112
137	361	19	332	92	52
FEMALE					
7	126	118	97	77	250
17	188	118	163	87	250
27	203	118	186	92	250
37	224	118	200	89	250
47	228	118	220	96	249
57	251	118	235	94	248
67	282	117	259	92	244
77	303	115	280	92	239
87	317	109	292	92	232
97	328	94	294	90	228
107	334	81	302	90	202
117	324	70	295	91	160
127	314	51	275	88	111
137	295	28	253	86	66

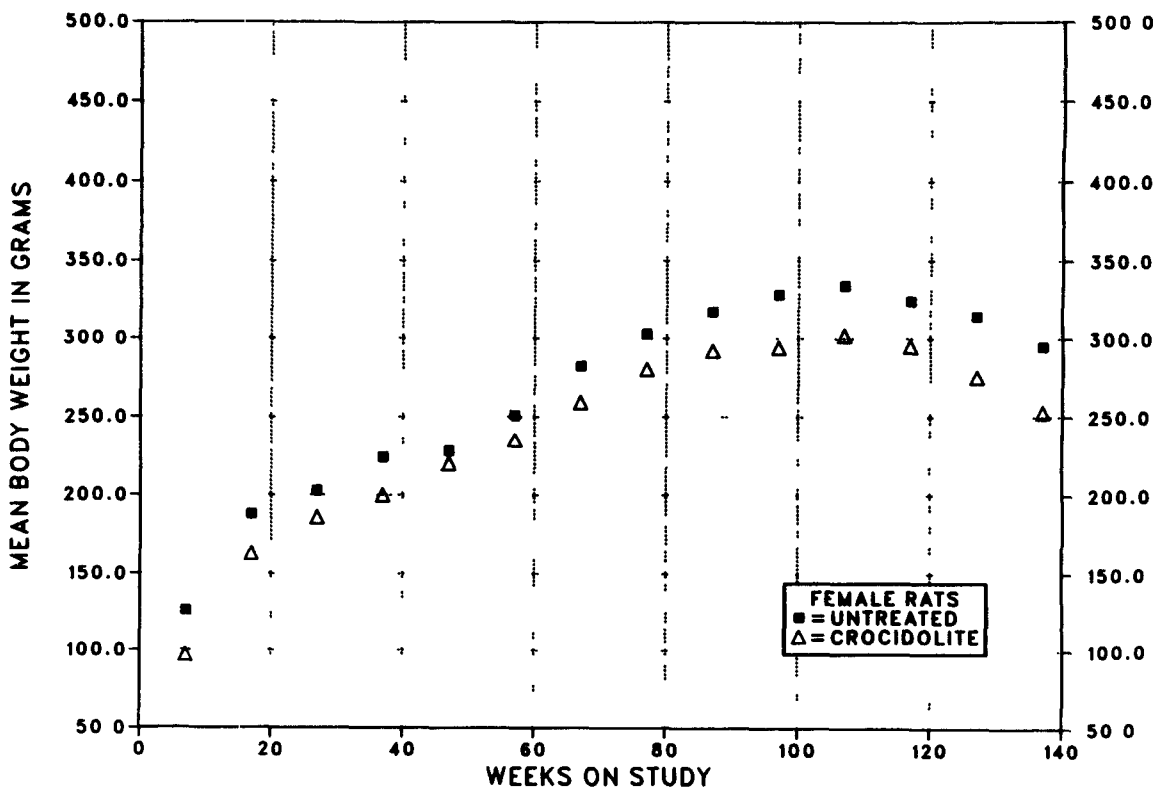
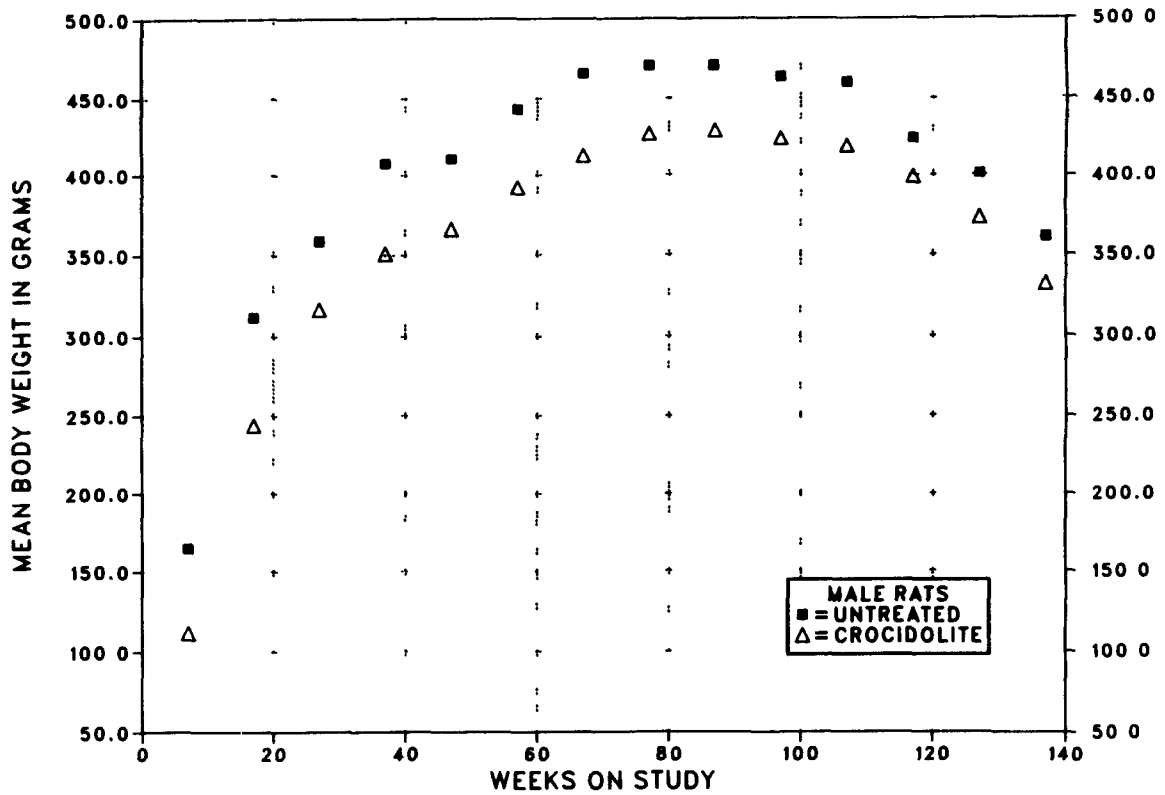


FIGURE 1. GROWTH CURVES FOR RATS IN THE LIFETIME FEED STUDIES OF CROCIDOLITE ASBESTOS

SURVIVAL

Estimates of the probabilities of survival for male and female rats fed diets containing crocidolite asbestos and for the controls are shown in Table 6 and in the Kaplan and Meier curves in Figure 3. No significant differences in survival between the dosed and control groups were observed, although a greater percentage of crocidolite asbestos-exposed rats were alive during most of the studies. Survival of males and females was approximately equal until week 112, after which a greater proportion of the females survived.

PATHOLOGY AND STATISTICAL ANALYSES OF RESULTS

This section describes the significant or noteworthy changes in the incidences of rats with neoplastic or nonneoplastic lesions. Only positive histopathologic findings based on hematoxylin- and eosin-stained sections are tabulated in the text. A few tissues were missing from occasional animals. Also, no diagnoses are given for several tissues in one male control rat because of autolysis.

Lesions in male rats are summarized in Appendix A. Histopathologic findings on neoplasms are summarized in Table A1. Table A2 gives the survival and tumor status for individual male rats. Table A3 contains the statistical analyses of those primary tumors that occurred with an incidence of at least 5% in one of the three groups. The statistical analyses used are discussed in Chapter II (Statistical Methods) and Table A3 (footnotes). Historical incidences of tumors in control male rats are listed in Table A4. Findings on nonneoplastic lesions are summarized in Table A5.

Lesions in female rats are summarized in Appendix B. Histopathologic findings on neoplasms are summarized in Table B1. Table B2 gives the survival and tumor status for individual female rats. Table B3 contains the statistical analyses of those primary tumors that occurred with an incidence of at least 5% in one of the three groups. The statistical analyses used are discussed in Chapter II (Statistical Methods) and Table B3 (footnotes). Historical incidences of tumors in control female rats are listed in Table B4. Findings on nonneoplastic lesions are summarized in Table B5.

TABLE 6. SURVIVAL OF RATS IN THE LIFETIME FEED STUDIES OF CROCIDOLITE ASBESTOS AT VARIOUS TIME POINTS AFTER WEEK 112

Group	Week	Male		Female	
		Number Alive/ Total Number	Percent Survival	Number Alive/ Total Number	Percent Survival
Control	112	78/118	66	75/118	64
	120	56/118	47	62/118	53
	134	20/118	17	32/118	27
	144	--	--	15/118	13
Crocidolite asbestos	112	179/250	72	172/250	69
	120	149/250	60	143/250	57
	134	64/250	26	73/250	29
	144	--	--	29/250	12

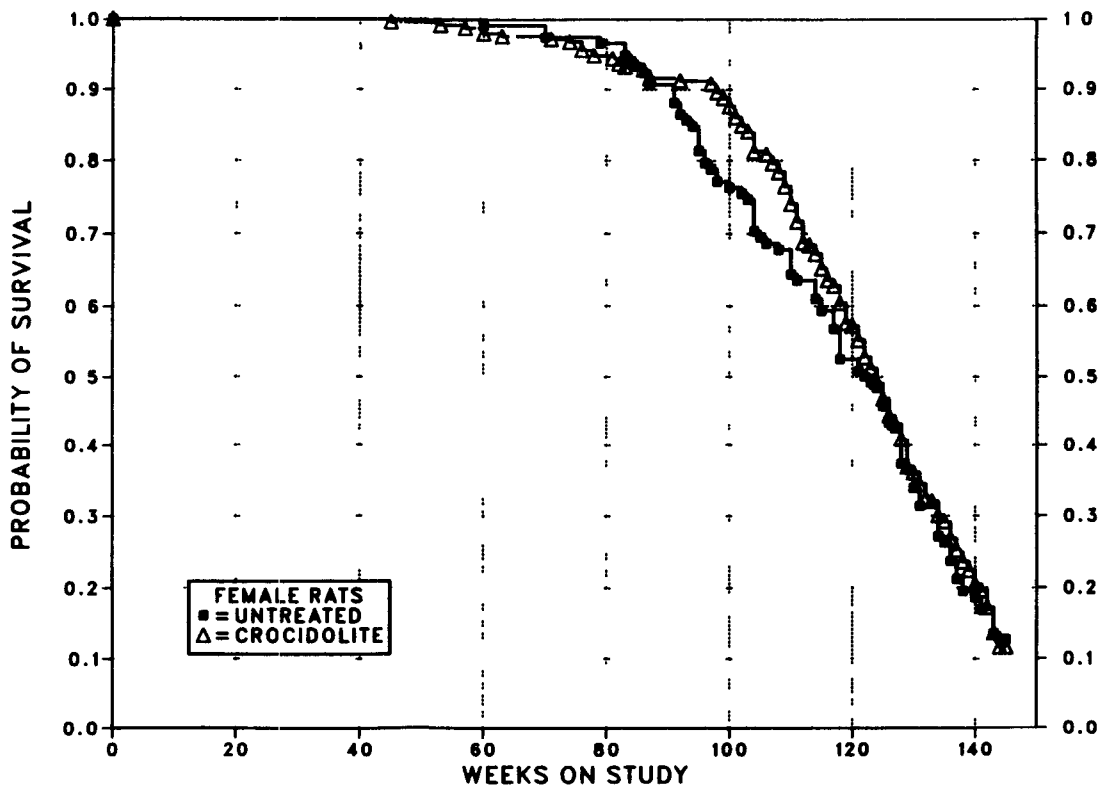
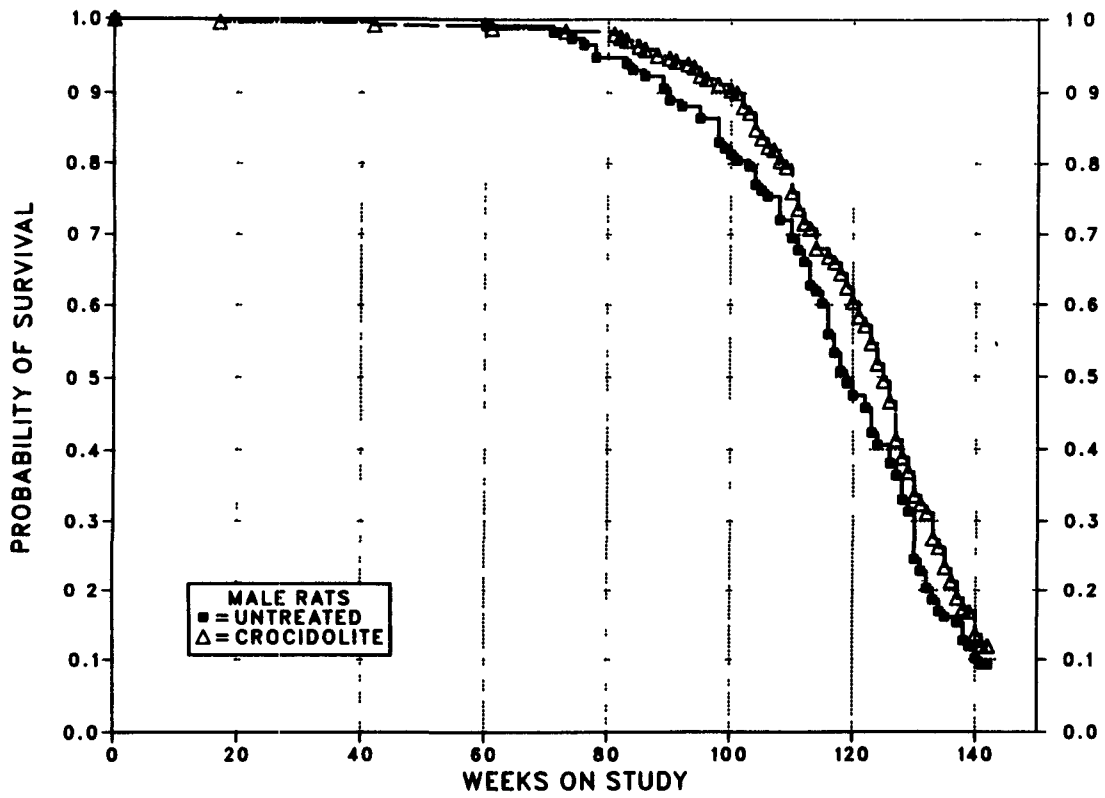


FIGURE 2. KAPLAN-MEIER SURVIVAL CURVES FOR RATS IN THE LIFETIME FEED STUDIES OF CROCIDOLITE ASBESTOS

A variety of neoplasms was found in the control and crocidolite asbestos-exposed groups, including monocytic (mononuclear cell) leukemia, endocrine tumors, testicular interstitial cell tumors, and mammary gland neoplasms (Table 7).

Stomach Neoplasms: Squamous cell papillomas occurred in the forestomach (nonglandular) and appeared as exophytic growths of thickened epithelium resting on a proliferative connective tissue stalk. Squamous cell carcinomas also occurred in the forestomach and were composed of proliferating small basophilic squamous cells that were growing down into the lamina propria and occasionally formed keratin pearls.

Intestinal Tract Neoplasms:

The primary epithelial neoplasms in the crocidolite asbestos studies were divided by the original pathologist into three major types, based on morphology and biologic behavior: adenomatous polyps, adenocarcinomas arising in an adenomatous polyp, and carcinomas.

*Adenomatous polyps--*The adenomatous polyps were exophytic lesions of the mucosa supported on a pedicle of fibrous tissue and/or elevated submucosa which appeared to extend up into the growth. The epithelial cells were usually deeply basophilic and hypertrophic and formed glands of varying sizes. Surface necrosis of these lesions was common and often accompanied by an inflammatory response. Invasion of the pedicle was not observed. These polyps often occurred as multiple neoplasms in the large intestine.

*Adenocarcinomas arising in adenomatous polyps--*These neoplasms were exophytic lesions of the mucosa composed of proliferating deeply basophilic hypertrophic epithelial cells similar to those described above. In addition, they often showed disorganization, loss of relationship to the basement membrane, and abnormal mitoses. Local invasion of the pedicle was a consistent finding; however, metastases were rarely observed.

*Carcinomas--*This classification includes signet ring cell carcinomas, adenocarcinomas, mucinous cystadenocarcinomas, and carcinomas. Biologically, all were similar and were usually characterized by transmural growth that penetrated the muscular tunics and serosa and spread throughout the coelomic cavity inducing a severe desmoplastic response. Metastasis to regional lymph nodes was common; metastasis to the lung and mediastinum occurred to a lesser extent. Grossly, in advanced cases, the loops of intestines were fused into an inseparable mass of tumor and desmoplastic tissue. Classification was based on the most prominent feature at the primary site. Signet ring cell carcinomas were composed of masses of clear oval cells with eccentric nuclei. Mucinous cystadenocarcinomas were characterized by the formation of multiple large ectatic glands or spaces that were filled with mucus and cellular debris. Adenocarcinomas consisted of clusters of cells and/or glands in pools of mucus or sequestered in desmoplastic tissue. The carcinomas were anaplastic neoplasms lacking acinar formations. In some cases, there was an overlap of cell types in the

TABLE 7. INCIDENCE OF PRIMARY NEOPLASMS IN RATS IN THE LIFETIME FEED STUDIES OF CROCIDOLITE ASBESTOS

	Male		Female	
	Control	1% Crocidolite	Control	1% Crocidolite
No. of animals examined	118	250	118	250
Total animals with primary tumors	118 (100%)	248 (99%)	115 (97%)	242 (97%)
Total primary tumors	(a) 395 (3.3)	(a) 831 (3.4)	(a) 291 (2.5)	(a) 661 (2.7)
Total animals with benign tumors	117 (99%)	242 (97%)	91 (77%)	190 (76%)
Total benign tumors	(a) 251 (2.1)	(a) 498 (2.1)	(a) 166 (1.8)	(a) 378 (2.0)
Total animals with malignant tumors	97 (82%)	209 (84%)	80 (68%)	187 (75%)
Total malignant tumors	(a) 134 (1.4)	(a) 315 (1.5)	(a) 120 (1.5)	(a) 273 (1.5)

(a) Average number of tumors per tumor-bearing animal is in parentheses.

III. RESULTS

same tumor, suggesting that the above morphologic types probably have the same histogenesis.

A few mesenchymal neoplasms of connective tissue or smooth muscle origin also were observed in the gastrointestinal tract. The incidences of these and of epithelial neoplasms are shown in Table 8. No statistically significant differences between the control and crocidolite asbestos-exposed groups were observed.

Evaluation of the incidence of the various categories of epithelial intestinal neoplasia by site and week of occurrence within the gastrointestinal tract does not indicate any significant ($P < 0.05$) compound-related effect (Table 9). In addition, the incidences of nonneoplastic lesions of the gastrointestinal tract, such as enteritis, ulceration, and inflammation, were generally comparable in the control and crocidolite asbestos-exposed rats (Table 10).

TABLE 8. INCIDENCE OF GASTROINTESTINAL TRACT NEOPLASMS IN RATS IN THE LIFETIME FEED STUDIES OF CROCIDOLITE ASBESTOS

	Male		Female	
	Control	1% Crocidolite	Control	1% Crocidolite
No. of animals examined	117	249	118	250
Total animals with neoplasms	5 (4.3%)	15 (6.0%)	3 (2.5%)	5 (2.0%)
Total animals with epithelial neoplasms	3 (2.6%)	9 (3.6%)	1 (0.8%)	5 (2.0%)
Total animals with mesenchymal neoplasms	2 (1.7%)	6 (2.4%)	2 (1.7%)	0 (0.0%)

TABLE 9. WEEK OF OCCURRENCE FOR EACH RAT WITH GASTROINTESTINAL TRACT EPITHELIAL NEOPLASMS IN THE LIFETIME FEED STUDIES OF CROCIDOLITE ASBESTOS

Site/Neoplasm	Male		Female	
	Control	1% Crocidolite	Control	1% Crocidolite
Stomach (forestomach)				
Squamous cell papilloma	--	108	--	71
Squamous cell carcinoma	--	142	--	86
Basal cell carcinoma	--	133	--	--
Stomach (fundus)				
Carcinoma, NOS	(a) 83	136	--	143
Adenomatous polyp	--	--	--	118
Jejunum				
Mucinous cystadenocarcinoma	--	121	126	--
Malignant carcinoid tumor	--	--	--	53
Ileum				
Adenocarcinoma	78	--	--	--
Cecum				
Adenomatous polyp	(b) 130	--	--	--
Colon (ascending)				
Adenomatous polyp	--	132	--	--
Colon (descending)				
Adenomatous polyp	--	104, 116, 142	--	--
Colon (transverse)				
Carcinoma	(b) 130	--	--	--

(a) Carcinoma in situ

(b) A carcinoma of the transverse colon and an adenomatous polyp of the cecum occurred in the same animal.

TABLE 10. INCIDENCE OF NONNEOPLASTIC LESIONS IN THE ALIMENTARY TRACT IN RATS IN THE LIFETIME FEED STUDIES OF CROCIDOLITE ASBESTOS

	Male		Female	
	Control	1% Crocidolite	Control	1% Crocidolite
Tongue	118	250	118	250
Inflammation	0 (0%)	2 (1%)	0 (0%)	0 (0%)
Hyperkeratosis	0 (0%)	2 (1%)	0 (0%)	0 (0%)
Acanthosis	0 (0%)	1 (<1%)	0 (0%)	1 (<1%)
Esophagus	115	247	116	239
Inflammation	0 (0%)	0 (0%)	1 (1%)	0 (0%)
Necrosis	0 (0%)	0 (0%)	1 (1%)	0 (0%)
Hyperkeratosis	8 (7%)	17 (7%)	5 (4%)	3 (1%)
Acanthosis	1 (1%)	0 (0%)	0 (0%)	0 (0%)
Stomach (nonglandular)	116	249	118	250
Mineralization	4 (3%)	3 (1%)	1 (1%)	0 (0%)
Inflammation, chronic	25 (22%)	38 (15%)	21 (18%)	46 (18%)
Ulcer, perforated	10 (9%)	21 (8%)	9 (8%)	17 (7%)
Necrosis, focal	19 (16%)	47 (19%)	23 (19%)	36 (14%)
Hyperplasia	4 (3%)	2 (1%)	1 (1%)	1 (<1%)
Hyperkeratosis	17 (15%)	47 (19%)	31 (26%)	28 (11%)
Acanthosis	28 (24%)	60 (24%)	28 (24%)	50 (20%)
Stomach (glandular)	116	249	118	250
Hyperplasia	0 (0%)	0 (0%)	0 (0%)	0 (0%)
Small intestine	117	249	118	250
Inflammation	1 (1%)	1 (<1%)	0 (0%)	3 (1%)
Necrosis	1 (1%)	1 (<1%)	0 (0%)	2 (1%)
Ulcer, perforated	0 (0%)	1 (<1%)	0 (0%)	1 (<1%)
Colon	117	249	118	250
Parasitism	5 (4%)	9 (4%)	9 (8%)	9 (4%)
Inflammation	1 (1%)	3 (1%)	0 (0%)	0 (0%)
Necrosis	2 (2%)	3 (1%)	1 (1%)	0 (0%)
Hyperplasia	0 (0%)	1 (<1%)	0 (0%)	0 (0%)
Cecum	117	249	118	250
Parasitism	0 (0%)	1 (<1%)	0 (0%)	0 (0%)
Inflammation	1 (1%)	2 (1%)	0 (0%)	6 (2%)
Necrosis	1 (1%)	3 (1%)	1 (1%)	2 (1%)
Hyperplasia	0 (0%)	0 (0%)	0 (0%)	2 (1%)

Miscellaneous Neoplasms: Occasionally, a somewhat higher or lower incidence of commonly occurring neoplasms was observed in dosed groups, but most of these were without statistical significance (Table 11). The only neoplasms showing a statistically significant increase were leukemia (Table 12) and tumors of the thyroid gland (Tables 13 and 14) and clitoral gland (referred to as preputial gland in Appendix B) (Table 15).

The incidence of leukemia (mononuclear cell leukemia or monocytic leukemia) was significantly increased ($P < 0.05$) in female crocidolite

asbestos-exposed rats compared with that in the control group (Table 12). However, statistical significance was absent ($P = 0.15$) when the incidence was examined by life table analysis.

The incidence of follicular cell carcinomas of the thyroid gland showed significant increases ($P < 0.05$) in male rats exposed to crocidolite asbestos (Table 13). The incidences of follicular cell adenomas and adenomas or carcinomas (combined) were not significantly increased in male rats, whereas the combination was significantly decreased ($P < 0.05$) in females.

TABLE 11. INCIDENCE OF PRIMARY NEOPLASMS IN RATS IN THE LIFETIME FEED STUDIES OF CROCIDOLITE ASBESTOS (a)

	Male		Female	
	Control	1% Crocidolite	Control	1% Crocidolite
Skin	118	250	118	250
Squamous cell papilloma	1 (1%)	6 (2%)	0 (0%)	1 (<1%)
Squamous cell carcinoma	2 (2%)	3 (1%)	1 (1%)	1 (<1%)
Basal cell carcinoma	2 (2%)	10 (4%)	1 (1%)	0 (0%)
Keratoacanthoma	4 (3%)	11 (4%)	0 (0%)	1 (<1%)
Subcutaneous tissue or skin	118	250	118	250
Fibroma	18 (15%)	27 (11%)	6 (5%)	9 (4%)
Fibrosarcoma	8 (7%)	7 (3%)	3 (3%)	5 (2%)
Neurofibroma	3 (3%)	9 (4%)	0 (0%)	1 (<1%)
Neurofibrosarcoma	0 (0%)	4 (2%)	0 (0%)	1 (<1%)
Lung	117	250	118	250
Alveolar/bronchiolar adenoma	1 (1%)	2 (1%)	0 (0%)	1 (<1%)
Alveolar/bronchiolar carcinoma	2 (2%)	2 (1%)	1 (1%)	2 (1%)
Hematopoietic system	118	250	118	250
Leukemia (monocytic or mononuclear cell)	43 (36%)	113 (45%)	43 (36%)	(b) 118 (47%)
Lymphoma	1 (1%)	5 (2%)	0 (0%)	1 (<1%)
Circulatory system	118	250	118	250
Hemangiosarcoma	3 (3%)	4 (2%)	0 (0%)	0 (0%)
Liver	117	250	118	250
Neoplastic nodule	8 (7%)	16 (6%)	3 (3%)	6 (2%)
Hepatocellular carcinoma	4 (3%)	3 (1%)	0 (0%)	1 (<1%)
Pancreas	118	249	118	249
Acinar cell adenoma	8 (7%)	15 (6%)	2 (2%)	5 (2%)
Acinar cell carcinoma	0 (0%)	2 (1%)	0 (0%)	1 (<1%)
Kidney	117	250	117	250
Tubular cell adenoma	0 (0%)	2 (1%)	2 (2%)	0 (0%)
Tubular cell adenocarcinoma	0 (0%)	5 (2%)	1 (1%)	0 (0%)
Pituitary gland	117	245	116	247
Adenoma	15 (13%)	41 (17%)	42 (36%)	101 (41%)
Carcinoma	3 (3%)	4 (2%)	9 (8%)	8 (3%)
Adrenal gland	117	250	118	250
Cortical adenoma	2 (2%)	8 (3%)	4 (3%)	18 (7%)
Cortical carcinoma	0 (0%)	0 (0%)	2 (2%)	1 (<1%)
Pheochromocytoma, benign	33 (28%)	54 (22%)	17 (14%)	39 (16%)
Pheochromocytoma, malignant	2 (2%)	8 (3%)	2 (2%)	3 (1%)
Thyroid gland	116	249	117	250
Follicular cell adenoma	7 (6%)	15 (6%)	8 (7%)	8 (3%)
Follicular cell carcinoma	3 (3%)	(b) 22 (9%)	3 (3%)	2 (1%)
C-cell adenoma	13 (11%)	34 (14%)	4 (3%)	(c) 23 (9%)
C-cell carcinoma	19 (16%)	48 (19%)	12 (10%)	(b) 46 (18%)
Pancreatic islets	117	249	118	249
Islet cell adenoma	2 (2%)	0 (0%)	2 (2%)	5 (2%)
Islet cell carcinoma	11 (9%)	(d) 11 (4%)	3 (3%)	6 (2%)
Mammary gland	118	250	118	250
Adenoma	0 (0%)	1 (<1%)	2 (2%)	1 (<1%)
Adenocarcinoma	1 (1%)	4 (2%)	16 (14%)	23 (9%)
Fibroadenoma	18 (15%)	(d) 18 (7%)	48 (41%)	112 (45%)

TABLE 11. INCIDENCE OF PRIMARY NEOPLASMS IN RATS IN THE LIFETIME FEED STUDIES OF CROCIDOLITE ASBESTOS (Continued)

	Male		Female	
	Control	1% Crocidolite	Control	1% Crocidolite
Preputial/clitoral gland	118	250	118	250
Adenoma	0 (0%)	0 (0%)	1 (1%)	2 (1%)
Carcinoma or squamous cell carcinoma	3 (3%)	16 (6%)	4 (3%)	(c) 23 (9%)
Testis	118	249		
Interstitial cell tumor	116 (98%)	237 (95%)		
Uterus			116	248
Endometrial stromal polyp			19 (16%)	38 (15%)
Endometrial stromal sarcoma			1 (1%)	3 (1%)
Ovary			116	248
Granulosa cell tumor			1 (1%)	4 (2%)
Granulosa cell carcinoma			1 (1%)	1 (<1%)
Zymbal gland	118	250	118	250
Squamous cell papilloma	0 (0%)	0 (0%)	0 (0%)	1 (<1%)
Squamous cell carcinoma	4 (3%)	5 (2%)	0 (0%)	4 (2%)
Tunica vaginalis	118	250		
Mesothelioma	4 (3%)	5 (2%)		

(a) Incidence of all neoplasms (other than those in the alimentary tract) that occurred at an incidence of 2% or more in at least one group

(b) $P < 0.05$ (increase) relative to controls (incidental tumor and the Fisher exact tests)

(c) $P < 0.05$ (increase) relative to controls

(d) $P < 0.01$ (decrease) relative to controls

TABLE 12. ANALYSIS OF MONOCYTIC OR MONUCLEAR CELL LEUKEMIA IN RATS IN THE LIFETIME FEED STUDIES OF CROCIDOLITE ASBESTOS (a)

	Male (b)		Female (c)	
	Control	1% Crocidolite	Control	1% Crocidolite
Overall Rates	43/118 (36%)	113/250 (45%)	43/118 (36%)	118/250 (47%)
Adjusted Rates	77.7%	81.2%	66.7%	74.9%
Terminal Rates	4/11 (36%)	15/29 (52%)	3/15 (20%)	8/29 (28%)
Week of First Observation	71	83	60	76
Life Table Test		$P = 0.452$		$P = 0.152$
Incidental Tumor Test		$P = 0.082$		$P = 0.032$
Fisher Exact Test		$P = 0.070$		$P = 0.033$

(a) The statistical analyses used are discussed in Chapter II (Statistical Methods) and Appendix A, Table A3 (footnotes).

(b) Historical incidence in untreated male controls in lifetime NTP studies (mean \pm SD): 192/529 (36% \pm 3%)

(c) Historical incidence in untreated female controls in lifetime NTP studies (mean \pm SD): 201/529 (38% \pm 6%)

TABLE 13. ANALYSIS OF FOLLICULAR CELL TUMORS OF THE THYROID GLAND IN RATS IN THE LIFETIME FEED STUDIES OF CROCIDOLITE ASBESTOS

	Male		Female	
	Control	1% Crocidolite	Control	1% Crocidolite
Adenoma				
Overall Rates	7/116 (6%)	15/249 (6%)	8/117 (7%)	8/250 (3%)
Adjusted Rates	15.5%	14.2%	18.8%	13.5%
Terminal Rates	0/11 (0%)	0/29 (0%)	1/15 (7%)	2/29 (7%)
Week of First Observation	108	88	92	118
Life Table Test		P=0.443N		P=0.092N
Incidental Tumor Test		P=0.562N		P=0.084N
Fisher Exact Test		P=0.582N		P=0.097N
Carcinoma				
Overall Rates	3/116 (3%)	22/249 (9%)	3/117 (3%)	2/250 (1%)
Adjusted Rates	9.0%	31.7%	11.0%	2.0%
Terminal Rates	0/11 (0%)	6/29 (21%)	1/15 (7%)	0/29 (0%)
Week of First Observation	100	110	121	118
Life Table Test		P=0.061		P=0.175N
Incidental Tumor Test		P=0.034		P=0.161N
Fisher Exact Test		P=0.019		P=0.188N
Adenoma or Carcinoma (a,b)				
Overall Rates	10/116 (9%)	37/249 (15%)	11/117 (9%)	10/250 (4%)
Adjusted Rates	23.1%	41.5%	28.2%	15.2%
Terminal Rates	0/11 (0%)	6/29 (21%)	2/15 (13%)	2/29 (7%)
Week of First Observation	100	88	92	118
Life Table Test		P=0.196		P=0.032N
Incidental Tumor Test		P=0.095		P=0.025N
Fisher Exact Test		P=0.065		P=0.037N

(a) Historical incidence in untreated male controls in lifetime NTP studies (mean ± SD): 44/520 (9% ± 1%)

(b) Historical incidence in untreated female controls in lifetime NTP studies (mean ± SD): 39/525 (7% ± 2%)

TABLE 14. ANALYSIS OF C-CELL TUMORS OF THE THYROID GLAND IN RATS IN THE LIFETIME FEED STUDIES OF CROCIDOLITE ASBESTOS

	Male		Female	
	Control	1% Crocidolite	Control	1% Crocidolite
Adenoma				
Overall Rates	13/116 (11%)	34/249 (14%)	4/117 (3%)	23/250 (9%)
Adjusted Rates	34.8%	31.2%	17.1%	34.3%
Terminal Rates	2/11 (18%)	3/29 (10%)	2/15 (13%)	5/29 (17%)
Week of First Observation	78	88	122	107
Life Table Test		P=0.518		P=0.046
Incidental Tumor Test		P=0.321		P=0.038
Fisher Exact Test		P=0.319		P=0.034
Carcinoma				
Overall Rates	19/116 (16%)	48/249 (19%)	12/117 (10%)	46/250 (18%)
Adjusted Rates	62.5%	57.8%	39.9%	53.4%
Terminal Rates	5/11 (45%)	10/29 (34%)	3/15 (20%)	6/29 (21%)
Week of First Observation	98	95	114	99
Life Table Test		P=0.497N		P=0.054
Incidental Tumor Test		P=0.436		P=0.041
Fisher Exact Test		P=0.304		P=0.030
Adenoma or Carcinoma (a)				
Overall Rates	32/116 (28%)	79/249 (32%)	16/117 (14%)	68/250 (27%)
Adjusted Rates	80.1%	71.6%	52.2%	71.2%
Terminal Rates	7/11 (64%)	13/29 (45%)	5/15 (33%)	11/29 (38%)
Week of First Observation	78	88	114	99
Life Table Test		P=0.458N		P=0.008
Incidental Tumor Test		P=0.353		P=0.003
Fisher Exact Test		P=0.250		P=0.002

(a) Historical incidence in untreated female controls in lifetime NTP studies (mean \pm SD): 103/525 (20% \pm 4%)

C-Cell adenomas and C-cell carcinomas showed statistically significant increases ($P < 0.05$) in exposed female but not male rats (Table 14). The increases were statistically significant by all three tests.

The incidence of clitoral gland tumors was significantly increased ($P < 0.05$) in female crocidolite asbestos-exposed rats compared with that in the controls (Table 15). However, there was no evidence of an increase in neoplasms in the male counterpart (preputial gland) of this tissue.

Nonneoplastic Findings

A plethora of incidental lesions of aging was found in all groups. Although the incidence of a few specific lesions in exposed rats was statistically different ($P < 0.05$) from that in controls, none of these lesions was thought to be compound related. Histopathologic findings are summarized in Appendixes A and B. Nonneoplastic lesions that were observed in more than 5% of the rats in any of the study groups are shown in Table 16.

TABLE 15. INCIDENCE OF FEMALE RATS WITH TUMORS OF THE CLITORAL GLAND IN THE LIFETIME FEED STUDIES OF CROCIDOLITE ASBESTOS

	Control	1% Crocidolite
Squamous Cell Carcinoma		
Overall Rates	4/118 (3%)	22/250 (9%)
Adjusted Rates	20.6%	31.6%
Terminal Rates	2/15 (13%)	5/29 (17%)
Week of First Observation	137	109
Life Table Test		P=0.058
Incidental Tumor Test		P=0.053
Fisher Exact Test		P=0.042
Carcinoma or Squamous Cell Carcinoma		
Overall Rates	4/118 (3%)	23/250 (9%)
Adjusted Rates	20.6%	32.2%
Terminal Rates	2/15 (13%)	5/29 (17%)
Week of First Observation	137	109
Life Table Test		P=0.047
Incidental Tumor Test		P=0.043
Fisher Exact Test		P=0.032
Adenoma, Carcinoma, or Squamous Cell Carcinoma (a)		
Overall Rates	5/118 (4%)	25/250 (10%)
Adjusted Rates	22.2%	33.1%
Terminal Rates	2/15 (13%)	5/29 (17%)
Week of First Observation	127	109
Life Table Test		P=0.060
Incidental Tumor Test		P=0.056
Fisher Exact Test		P=0.041

(a) Historical incidence in untreated female controls in lifetime NTP studies (mean \pm SD): 21/529 (4% \pm 2%)

TABLE 16. NONNEOPLASTIC LESIONS OBSERVED IN MORE THAN 5% OF RATS IN THE LIFETIME FEED STUDIES OF CROCIDOLITE ASBESTOS

Lung: chronic inflammation, congestion, hemorrhage, histiocytosis
Spleen: fibrosis, hemosiderosis, hematopoiesis, necrosis
Lymph nodes (various): lymphoid or reticulum cell hyperplasia, pigmentation, hemorrhage, erythrophagocytosis
Heart: chronic inflammation
Liver: degeneration, necrosis, fatty metamorphosis, toxic hepatitis, granulomas, pigmentation, focal cellular change
Bile duct (extrahepatic): chronic inflammation, hyperplasia
Pancreas (exocrine): atrophy, hyperplasia, ectopia
Kidney: chronic inflammation, cysts, pigmentation, mineralization
Pituitary gland: cysts, angiectasis, hyperplasia
Adrenal gland (cortex): fatty metamorphosis, hyperplasia, degeneration, angiectasis
Adrenal gland (medulla): hyperplasia
Thyroid gland: follicular cysts, C-cell hyperplasia
Parathyroid: hyperplasia
Testis: degeneration, interstitial cell hyperplasia
Prostate: abscess, chronic inflammation, hyperplasia
Ovary: cysts
Uterus: endometrial cysts
Mammary gland: cystic ducts, galactocele, hyperplasia
Abdominal cavity: fat necrosis
Eye: cataract, inflammation, retinal degeneration
Zymbal gland: cystic ducts
Bone: osteopetrosis
Esophagus: hyperkeratosis
Stomach: hyperkeratosis, chronic inflammation, necrosis, acanthosis, ulcers

IV. DISCUSSION AND CONCLUSIONS

IV. DISCUSSION AND CONCLUSIONS

Crocidolite asbestos was administered at a concentration of 1% in feed to male and female F344/N rats for their lifetime, beginning with exposure of the dams before and during gestation. The clinicopathologic results showed that the ingestion of crocidolite asbestos did not adversely affect the fertility of the mothers or the litter size of the F₁ animals. However, the average weight of the offspring at weaning from mothers exposed to crocidolite asbestos during gestation and lactation was 19% lower than that of the offspring of nonexposed mothers. This result was not due to gestational effects of crocidolite asbestos, since birth weights of the exposed pups were comparable to those of concurrent controls. Body weight gain differences became more apparent by 8 weeks of age (male, 32%; female, 23%), after which body weight gains of the crocidolite asbestos-exposed rats paralleled those of the control rats, even though the exposed rats remained smaller throughout their lives. Lower body weight of offspring of asbestos-exposed mothers has been a consistent finding in NTP oral asbestos studies, having been observed in both the amosite asbestos (NTP, 1988b) and the tremolite asbestos (NTP, 1988c) studies. The decreased body weight gain was not related to a decrease in feed consumption, and the reason for this effect is not known. Although feed consumption by both groups was similar, the total caloric intake was slightly lower in the crocidolite asbestos group because its diet contained 1% asbestos. The differential in weight gain was not considered a toxic effect because the lifespan was not altered and no compound-related lesions were observed.

No clinical signs were observed which could be attributed to the ingestion of crocidolite asbestos. The ingestion of 1% crocidolite asbestos in feed for the lifespan of the rats appeared to enhance the survival of both males and females. The most plausible explanation for the increased survival of the crocidolite asbestos-exposed rats is their lower weight throughout the studies. Yu et al. (1982) showed that F344 rats with lower body weights resulting from restricted caloric intake lived longer than rats that were given feed ad libitum.

Survival of the rats (control and exposed) in the current studies compares favorably with that in

other long-term NTP studies; at 112 weeks of age, the proportions of rats still alive in these studies were as follows: male control, 66%; exposed male, 72%; control female, 64%; exposed female, 69%. In reviewing 25 NTP feed studies, Haseman (1983) reported that an average of 66% of control males and 73% of control females were alive at 112 weeks of age.

In the crocidolite asbestos studies, the survival of males was similar to that of females at 112 weeks of age. However, after 134 weeks, better survival was observed for both control and exposed females. In most 2-year studies involving rats, females usually have better survival than males. It is possible that the rats in these studies could have tolerated a higher level of exposure, although a dietary concentration of 1% for the entire life of the animal is substantial.

Ingestion of crocidolite asbestos over the lifetime of these rats did not cause any biologically significant increase in neoplasms at any particular anatomic site compared with the concurrent controls. Since the gastrointestinal tract was considered a target organ, based on epidemiologic studies in humans (Cooper et al., 1979) and because the study material was administered in feed, the incidence of gastrointestinal neoplasms in the control and exposed groups was examined in particular detail. Overall, the incidence was low, and no significant ($P < 0.05$) differences in the total number of gastrointestinal neoplasms or neoplasms for any anatomic site within the gastrointestinal tract were observed between the exposed and control groups. Additionally, time to observation of the tumors was not affected by the ingestion of crocidolite asbestos. Most of these neoplasms were observed in rats over 112 weeks of age, the time when standard 2-year carcinogenesis studies are normally terminated.

Crocidolite asbestos did not cause an increase in any type of nonneoplastic disease in the gastrointestinal tract. In summary, the ingestion of this form of asbestos did not cause any adverse effects on the gastrointestinal tract of either male or female F344/N rats.

Statistically significant ($P < 0.05$) increased incidences of mononuclear cell leukemia (monocytic

IV. DISCUSSION AND CONCLUSIONS

leukemia, Fischer rat leukemia) were observed in exposed female rats. However, this is readily explained because the exposed group of rats lived longer than the concurrent control group and the increased tumor incidence is not significant ($P=0.15$) when survival differences are taken into account by a life table test. The historical incidence of mononuclear cell leukemia in 2-year feed studies is 33% for male rats and 19% for females; in lifetime studies, the incidence is 36% for males (Table A4a) and 38% for females (Table B4a), compared with 36% for both sexes in the current studies (see Table 12). Based on these data, it is apparent that the incidence of this type of neoplasm increases after 112 weeks of age.

There was a statistically significant ($P < 0.05$) increase in the number of follicular cell carcinomas in the thyroid gland of exposed male rats and a decrease in the incidence of follicular cell adenomas in exposed female rats. Since the progression of this neoplastic lesion is a continuum from benign to malignant and differentiation between the two is somewhat arbitrary, the combined incidence of tumors is more appropriate for comparative purposes when effects on the thyroid gland are evaluated. When the totals are compared, the differences for males disappear, whereas the incidences for females show a significant decrease ($P < 0.05$). The reason for this decrease is unknown, but Hase-man (1983) has observed that certain endocrine neoplasms and hormonally related neoplasms (e.g., mammary gland) commonly are decreased in exposed rats that weigh less than their respective control groups.

C-cell neoplasms (adenomas and carcinomas) in the thyroid gland were significantly ($P < 0.05$) increased in crocidolite asbestos-exposed female rats. Benign and malignant lesions of this tissue should be combined for the same reasons noted above. The analysis of combined C-cell neoplasms strengthens the significant ($P < 0.01$) difference between the exposed and control groups. The most plausible explanation for this observation is that the incidence in the control group may be abnormally low. In the corollary asbestos studies (Table B4c), the combined incidence of C-cell neoplasms in the female control groups were amosite, 21%, tremolite, 21%, long-range

chrysotile, 24%, and short-range chrysotile, 20%, compared with 14% in control and 27% in exposed rats in the current studies (see Table 14). When the incidence in the crocidolite asbestos-exposed group is compared with that in any of these other control groups, the statistical significance disappears. Another reason for discounting the relationship between C-cell neoplasms and crocidolite asbestos is that it is difficult to envision an increase in these neoplasms in the absence of lesions in the target tissues. For these reasons, the increase in C-cell neoplasms was not considered biologically important. The increased incidence of clitoral gland tumors (see Table 15) was discounted because there was no increase in neoplasms in the male counterpart to this organ, i.e., the preputial gland, and because this site was not a primary target for distribution of the asbestos fibers.

A large variety of nonneoplastic lesions, primarily age related, was observed in all groups. There was no obvious correlation between exposure and specific lesions. Therefore, crocidolite asbestos at a concentration of 1% in feed did not appear to be toxic in this sense. The decrease in body weight may or may not be considered an asbestos-related toxic effect.

Other studies on the effects of long-term ingestion of crocidolite asbestos are not available. However, Stanton et al. (1981) showed that the intrapleural inoculation of several different samples of South African crocidolite asbestos caused a high incidence of pleural sarcoma in Osborne Mendel rats. Also, crocidolite asbestos is considered to be the most "dangerous" form of asbestos in humans because of its strong association with mesothelioma (Craighead et al., 1982).

Few studies have dealt with the long-term ingestion of other types of asbestos. In a companion study to this investigation, F344/N rats were exposed to short-range or intermediate-range chrysotile asbestos at a concentration of 1% in the diet for their lifespan (NTP, 1985a). Neither type of fiber affected fertility, litter size, body weight, or survival. Adenomatous polyps of the large intestine in male rats exposed to intermediate-range chrysotile asbestos fibers were considered some evidence of carcinogenicity; no other asbestos-related neoplasms were observed

IV. DISCUSSION AND CONCLUSIONS

in female rats or in groups exposed to short-range fibers. Similarly, an ingestion study of amosite asbestos in F344 rats using a design similar to that used in these studies failed to demonstrate a carcinogenic response (NTP, 1988b). In companion studies to this investigation, Syrian golden hamsters were exposed to either amosite asbestos or to short-range (fiber length) or intermediate-range chrysotile asbestos at a concentration of 1% in the diet for their natural lifespan (NTP, 1985b; NTP, 1988a). In both studies, no adverse effects were observed for body weight gain or survival, and no asbestos-related neoplasms were diagnosed.

Donham et al. (1980) reported equivocal results in F344 rats that were fed a diet containing 10% chrysotile for their lifetime. Although no significant ($P < 0.05$) increase in the number of tumors in exposed animals was observed, the authors believed that there was a trend towards increased colon lesions in general, evidence of penetration of asbestos into the colonic mucosa, and possible cytotoxicity to colonic tissues; they also suggested a relationship to peritoneal mesothelioma. Another equivocal study was reported by Gibel et al. (1976) who described an increase in malignant tumors of the lung, kidney, liver, and reticuloendothelial system, but no increase in intestinal neoplasia, in Wistar rats fed asbestos filter material (20 mg per day) for 8-14 months. Cunningham et al. (1977) reported two studies (one 24-month and one 30-month) in male Wistar rats fed diets containing 1% chrysotile asbestos. These authors concluded that trace amounts of ingested asbestos can penetrate the walls of the gastrointestinal tract but that evidence of carcinogenicity was inconclusive. No evidence of carcinogenicity was found by Gross et al. (1974), who fed rats diets containing 5% chrysotile asbestos for 21 months.

An oral asbestos study in hamsters was reported by Smith et al. (1980). Groups of 30 male and 30 female hamsters were exposed via drinking water for their lifetime to amosite asbestos, mine tailings, beach rock, or Lake Superior drinking water. No adverse effects on body weight or survival were observed in any of the groups. One peritoneal mesothelioma, one pulmonary carcinoma, and two early squamous carcinomas of the nonglandular stomach were found in hamsters exposed to amosite asbestos, but the incidence was not statistically significant ($P < 0.05$). The authors concluded that the study was essentially negative. A subsequent study in rats using similar materials also failed to elicit a carcinogenic response (Hilding et al., 1981).

Except for the studies of Donham et al. (1980), Smith et al. (1980), and the NTP, the other studies were conducted with relatively small numbers of animals. Also, some were conducted for an insufficient period of time to adequately test the carcinogenic potential of ingested asbestos.

The experimental and tabulated data for the NTP Technical Report on crocidolite asbestos were examined for accuracy, consistency, completeness, and compliance with Good Laboratory Practice regulations. As summarized in Appendix I, the audit revealed no major problems with the conduct of the studies or with collection and documentation of the experimental data. No discrepancies were found that influenced the final interpretation of the results of these studies.

Under the conditions of these feed studies, crocidolite asbestos was not overtly toxic and did not cause a carcinogenic response when ingested at a concentration of 1% in the diet by male and female F344/N rats for their lifetime.

V. REFERENCES

V. REFERENCES

1. Armitage, P. (1971) *Statistical Methods in Medical Research*. New York: John Wiley & Sons, Inc., pp. 362-365.
2. Berenblum, I., Ed. (1969) *Carcinogenicity Testing: A Report of the Panel on Carcinogenicity of the Cancer Research Commission of UICC, Vol. 2*. Geneva: International Union Against Cancer.
3. Bey, E.; Harrington, J.S. (1971) Cytotoxic effects of some mineral dusts on Syrian hamster peritoneal macrophages. *J. Exp. Med.* 133:1149-1169.
4. Boorman, G.A.; Montgomery, C.A., Jr.; Eustis, S.L.; Wolfe, M.J.; McConnell, E.E.; Hardisty, J.F. (1985) Quality assurance in pathology for rodent carcinogenicity studies. Milman, H.; Weisburger, E., Eds.: *Handbook of Carcinogen Testing*. Park Ridge, NJ: Noyes Publications, pp. 345-357.
5. Bureau of Mines (1980) U.S. Department of the Interior, No. RI 28.23:8452.
6. Carter, R.E.; Taylor, W.G. (1980) Identification of a particular amphibole asbestos fiber in tissues of persons exposed to a high oral intake of the mineral. *Environ. Res.* 21:85-93.
7. Chamberlain, M.; Tarmy, E.M. (1977) Asbestos and glass fibers in bacterial mutation tests. *Mutat. Res.* 43:159-164.
8. Conforti, P. (1983) Effect of population density on the results of the study of water supplies in five California counties. *Environ. Health Perspect.* 53:69-78.
9. Cook, P.M.; Olson, G.F. (1979) Ingested mineral fibers: Elimination in human urine. *Science* 204:195-198.
10. Cooper, R.C.; Murchio, J.C.; Paffenbarger, R.S. (1979) Asbestos in Domestic Water Supplies for Five California Counties. Part II. *EHS Pub. No. 79-1*. Division of Environmental Health Sciences, School of Public Health, University of California, Berkeley.
11. Cox, D.R. (1972) Regression models and life tables. *J. R. Stat. Soc.* B34:187-220.
12. Craighead, J.E.; Mossman, B.T. (1982) The pathogenesis of asbestos-associated disease. *N. Engl. J. Med.* 306:1446-1455.
13. Craighead, J.E.; Abraham, J.L.; Churg, A.; Green, F.H.; Kleinerman, J.; Pratt, P.C.; Seemayer, T.A.; Vallyathan, V.; Weill, H. (1982) Asbestos-associated diseases. *Arch. Pathol. Lab. Med.* 106:544-596.
14. Cunningham, H.M.; Moodie, C.A.; Lawrence, G.A.; Pontefract, R.D. (1977) Chronic effects of ingested asbestos in rats. *Arch. Environ. Contam. Toxicol.* 6:507-513.
15. Desai, R.; Richards, R. (1983) Effects of chrysotile on a lysosomal enzyme preparation and on the hydrolytic enzyme activity of cultured alveolar macrophages. *Environ. Health Perspect.* 51:125-130.
16. Donham, K.J.; Berg, J.W.; Will, L.A.; Leininger, J.R. (1980) The effects of long-term ingestion of asbestos on the colon of F344 rats. *Cancer* 45:1073-1084.
17. Environmental Health Perspectives (EHP) (1974) Proceedings of the Joint NIEHS-EPA Conference on Biological Effects of Ingested Asbestos. 9:113-462.
18. Gart, J.J.; Chu, K.C.; Tarone, R.E. (1979) Statistical issues in interpretation of chronic bioassay tests for carcinogenicity. *J. Natl. Cancer Inst.* 62:957-974.
19. Gibel, W.; Lohs, K.H.; Horn, K.H.; Wildner, G.P.; Hoffman, F. (1976) Investigation into a carcinogenic effect of asbestos filter materials following oral intake in experimental animals. *Arch. Geschwulstforsch.* 46:437-442.
20. Gross, P.; Harley, R.A.; Swinberne, L.M.; Davis, J.M.G.; Green, W.B. (1974) Ingested mineral fibers, do they penetrate tissue or cause cancer? *Arch. Environ. Health* 29:341-347.
21. Harrington, J.M.; Craun, G.F.; Meigs, J.W.; Landrigen, P.J.; Flannery, J.T. (1978) An investigation of the use of asbestos-cement pipe for public water supply and the incidence of gastrointestinal cancer in Connecticut, 1935-1973. *Am. J. Epidemiol.* 107:96-103.

22. Haseman, J.K. (1983) Patterns of tumor incidence in two-year cancer bioassay feeding studies in Fischer 344 rats. *Fundam. Appl. Toxicol.* 3:1-9.
23. Haseman, J.K. (1984) Statistical issues in the design, analysis and interpretation of animal carcinogenicity studies. *Environ. Health Perspect.* 58:385-392.
24. Haseman, J.K.; Huff, J.; Boorman, G.A. (1984) Use of historical control data in carcinogenicity studies in rodents. *Toxicol. Pathol.* 12:126-135.
25. Haseman, J.K.; Huff, J.; Rao, G.N.; Arnold, J.; Boorman, G.A.; McConnell, E.E. (1985) Neoplasms observed in untreated and corn oil gavage control groups of F344/N rats and (C57BL/6N × C3H/HeN)F₁ (B6C3F₁) mice. *J. Natl. Cancer Inst.* 75:975-984.
26. Hilding, A.C.; Hilding, D.A.; Larsen, D.M.; Aufderheide, A.C. (1981) Biological effects of ingested amosite asbestos, taconite tailings, diatomaceous earth and Lake Superior water in rats. *Arch. Environ. Health* 36:298-303.
27. Illinois Institute of Technology Research Institute (IITRI) Special Report and Addendum on Project L6085. Chicago: Fine Particle Laboratories, IITRI.
28. International Agency for Research on Cancer (IARC) (1977) Asbestos. IARC Monographs on the Evaluation of the Carcinogenic Risk of Chemicals to Man, Vol. 14. Lyon, France: IARC, pp. 1-106.
29. Kanarek, M. (1983) The San Francisco Bay epidemiology studies on asbestos in drinking water and cancer incidence: Relationship to studies in other locations and pointers for further research. *Environ. Health Perspect.* 51:105-106.
30. Kaplan, E.L.; Meier, P. (1958) Nonparametric estimation from incomplete observations. *J. Am. Stat. Assoc.* 53:457-481.
31. Levine, R.J. (1978) Asbestos: An Information Resource. NIH 78-1681. U.S. Department of Health and Human Services, National Institutes of Health.
32. Linhart, M.S.; Cooper, J.; Martin, R.L.; Page, N.; Peters, J. (1974) Carcinogenesis Bioassay Data System. *Comput. Biomed. Res.* 7:230-248.
33. Mantel, N.; Haenszel, W. (1959) Statistical aspects of the analysis of data from retrospective studies of disease. *J. Natl. Cancer Inst.* 22:719-748.
34. Maronpot, R.R.; Boorman, G.A. (1982) Interpretation of rodent hepatocellular proliferative alterations and hepatocellular tumors in chemical safety assessment. *Toxicol. Pathol.* 10:71-80.
35. Millette, J.; Clark, P.; Stober, J.; Rosenthal, M. (1983) Asbestos in water supplies of the United States. *Environ. Health Perspect.* 53:45-48.
36. National Academy of Sciences (NAS) (1977) Drinking Water and Health. National Academy of Sciences/National Research Council.
37. National Toxicology Program (NTP) (1985a) Toxicology and Carcinogenesis Studies of Chrysotile Asbestos in F344/N Rats. NTP TR 295. U.S. Department of Health and Human Services, Public Health Service, National Institutes of Health. 390 p.
38. National Toxicology Program (NTP) (1985b) Lifetime Carcinogenesis Studies of Amosite Asbestos in Syrian Golden Hamsters (Feed Studies). NTP TR 249. U.S. Department of Health and Human Services, Public Health Service, National Institutes of Health. 81 p.
39. National Toxicology Program (NTP) (1988a) Lifetime Carcinogenesis Studies of Chrysotile Asbestos in Syrian Golden Hamsters (Feed Studies). NTP TR 246. U.S. Department of Health and Human Services, Public Health Service, National Institutes of Health (in preparation).
40. National Toxicology Program (NTP) (1988b) Lifetime Carcinogenesis Studies of Amosite Asbestos in F344/N Rats. NTP TR 279. U.S. Department of Health and Human Services, Public Health Service, National Institutes of Health (in preparation).

V. REFERENCES

41. National Toxicology Program (NTP) (1988c) Lifetime Carcinogenesis Studies of Tremolite Asbestos in F344/N Rats. NTP TR 277. U.S. Department of Health and Human Services, Public Health Service, National Institutes of Health (in preparation).
42. Oshimura, M.; Hesterberg, T.; Tsutsui, T.; Barrett, J. (1984) Correlation of asbestos-induced cytogenetic effects with cell transformation of Syrian hamster embryo cells in culture. *Cancer Res.* 44:5017-5022.
43. Patel-Mandlik, K.J. (1980) Distribution of Orally Administered Chrysotile Asbestos in Newborn Baboon Study. EPA 600/1-80-022. U.S. Environmental Protection Agency, Washington, DC.
44. Peto, R.; Schneiderman, M., Eds. (1981) Quantification of Occupational Cancer. Banbury Report No. 9. Cold Spring Harbor, New York.
45. Reiss, B.; Weisburger, J.H.; Williams, G.M. (1979) Asbestos and Gastrointestinal Cancer: Cell Culture Studies. EPA-600/1-79-023. U.S. Environmental Protection Agency, Washington, DC.
46. Reiss, B.; Solomon, S.; Tong, C.; Levenstein, M.; Rosenberg, S.; Williams, G. (1982) Absence of mutagenic activity of three forms of asbestos in liver epithelial cells. *Environ. Res.* 27:389-397.
47. Sebastien, P.; Masse, R.; Bignon, J. (1980) Recovery of ingested asbestos fibers from the gastrointestinal lymph in rats. *Environ. Res.* 22:201-216.
48. Selikoff, I.J. (1980) Asbestos-associated disease. Last, J., Ed.: *Maxcy-Rosehau's Public Health and Preventive Medicine*, 11th ed. Appleton-Century-Croft, pp. 568-589.
49. Selikoff, I.J.; Hammond, E.C., Eds. (1979) Health hazards of asbestos exposure. *Ann. N.Y. Acad. Sci.* B30:1-814.
50. Smith, W.E.; Hubert, D.D.; Sobel, H.J.; Peters, E.T.; Doerfler, T.E. (1980) Health in experimental animals drinking water with and without amosite and other mineral particles. *J. Environ. Pathol. Toxicol.* 3:277-300.
51. Stanton, M.F.; Wrench, C. (1972) Mechanisms of mesothelioma induction with asbestos and fibrous glass. *J. Natl. Cancer Inst.* 48:797-821.
52. Stanton, M.F.; Layard, M.; Tegarlis, A.; Miller, E.; May, M.; Morgan, E.; Smith, A. (1981) Relation of particle dimension to the carcinogenicity in amphibole asbestoses and other fibrous minerals. *J. Natl. Cancer Inst.* 67:965-975.
53. Storeygard, A.R.; Brown, A.L. (1977) Penetration of the small intestinal mucosa by asbestos fibers. *Mayo Clin. Proc.* 52:809-812.
54. Tarone, R.E. (1975) Tests for trend in life table analysis. *Biometrika* 62:679-682.
55. U.S. Environmental Protection Agency (USEPA) (1980) Ambient Water Quality Criteria for Asbestos. EPA 440/5-80-022. Washington, DC: USEPA, Office of Water Regulations and Standards.
56. Wagner, J.C. (1962) Experimental production of mesothelial tumors of the pleura by implantation of dusts in laboratory animals. *Nature* 196:180-181.
57. Wagner, J.C.; Sleggs, C.A.; Marchand, P. (1960) Diffuse pleural mesothelioma and asbestos exposure in the Northwestern Cape Province. *Br. J. Ind. Med.* 17:260-270.
58. Wagner, J.C.; Berry, G.; Skidmore, J.W.; Timbrell, V. (1974) Effects of the inhalation of asbestos in rats. *Br. J. Cancer* 29:252-269.
59. Wright, A.; Donaldson, K.; Davis, J. (1983) Cytotoxic effect of asbestos on macrophages in different activation states. *Environ. Health Perspect.* 51:147-152.
60. Yu, B.P.; Masoro, E.J.; Murata, I.; Bertrand, H.A.; Lund, F.T. (1982) Life span study of SPF Fischer 344 rats fed *ad libitum* or restricted diets: Longevity, growth, lean body mass and disease. *J. Gerontol.* 37:130-141.

APPENDIX A

SUMMARY OF LESIONS IN MALE RATS IN THE LIFETIME FEED STUDY OF CROCIDOLITE ASBESTOS

	PAGE
TABLE A1	
SUMMARY OF THE INCIDENCE OF NEOPLASMS IN MALE RATS IN THE LIFETIME FEED STUDY OF CROCIDOLITE ASBESTOS	49
TABLE A2	
INDIVIDUAL ANIMAL TUMOR PATHOLOGY OF MALE RATS IN THE LIFETIME FEED STUDY OF CROCIDOLITE ASBESTOS	54
TABLE A3	
ANALYSIS OF PRIMARY TUMORS IN MALE RATS IN THE LIFETIME FEED STUDY OF CROCIDOLITE ASBESTOS	84
TABLE A4a	
HISTORICAL INCIDENCE OF LEUKEMIA IN MALE F344/N RATS RECEIVING NO TREATMENT IN LIFETIME FEED STUDIES	89
TABLE A4b	
HISTORICAL INCIDENCE OF THYROID GLAND FOLLICULAR CELL TUMORS IN MALE F344/N RATS RECEIVING NO TREATMENT IN LIFETIME FEED STUDIES	89
TABLE A5	
SUMMARY OF THE INCIDENCE OF NONNEOPLASTIC LESIONS IN MALE RATS IN THE LIFETIME FEED STUDY OF CROCIDOLITE ASBESTOS	90

**TABLE A1. SUMMARY OF THE INCIDENCE OF NEOPLASMS IN MALE RATS IN THE LIFETIME
FEED STUDY OF CROCIDOLITE ASBESTOS**

	Untreated Control	1% Crocidolite Asbestos
ANIMALS INITIALLY IN STUDY	118	250
ANIMALS NECROPSIED	118	250
ANIMALS EXAMINED HISTOPATHOLOGICALLY	118	250
INTEGUMENTARY SYSTEM		
*Multiple organs	(118)	(250)
Fibrous histiocytoma, malignant	1 (1%)	
*Skin	(118)	(250)
Squamous cell papilloma	1 (1%)	6 (2%)
Squamous cell carcinoma	2 (2%)	3 (1%)
Basal cell tumor	1 (1%)	1 (0%)
Basal cell carcinoma	2 (2%)	10 (4%)
Trichoepithelioma		1 (0%)
Keratoacanthoma	4 (3%)	11 (4%)
Fibroma	1 (1%)	
Fibrosarcoma	2 (2%)	1 (0%)
Myxosarcoma	1 (1%)	
Neurofibroma		1 (0%)
Neurofibrosarcoma		3 (1%)
*Subcutaneous tissue	(118)	(250)
Keratoacanthoma		1 (0%)
Sarcoma, NOS	1 (1%)	
Sarcoma, NOS, invasive		1 (0%)
Fibroma	17 (14%)	‡ 27 (11%)
Fibrosarcoma	6 (5%)	6 (2%)
Lipoma	1 (1%)	3 (1%)
Osteosarcoma		2 (1%)
Neurofibroma	3 (3%)	8 (3%)
Neurofibrosarcoma		1 (0%)
RESPIRATORY SYSTEM		
#Trachea	(117)	(248)
C-cell carcinoma, invasive	1 (1%)	1 (0%)
#Lung	(117)	(250)
Neoplasm, NOS, metastatic		1 (0%)
Squamous cell carcinoma	1 (1%)	
Squamous cell carcinoma, metastatic	1 (1%)	2 (1%)
Alveolar/bronchiolar adenoma	1 (1%)	2 (1%)
Alveolar/bronchiolar carcinoma	2 (2%)	2 (1%)
C-cell carcinoma, metastatic	1 (1%)	1 (0%)
Pheochromocytoma, metastatic		5 (2%)
Liposarcoma, metastatic		3 (1%)
Mesothelioma, metastatic		2 (1%)
Osteosarcoma, metastatic		2 (1%)
HEMATOPOIETIC SYSTEM		
*Multiple organs	(118)	(250)
Malignant lymphoma, undifferentiated type		1 (0%)
Malignant lymphoma, histiocytic type	1 (1%)	3 (1%)
Monocytic leukemia	42 (36%)	110 (44%)
#Spleen	(117)	(250)
Pheochromocytoma, metastatic		1 (0%)
Fibrosarcoma		1 (0%)
Fibrosarcoma, metastatic		1 (0%)
Leukemia, mononuclear cell		1 (0%)
#Mandibular lymph node	(117)	(250)
Squamous cell carcinoma, metastatic	1 (1%)	1 (0%)
Sarcoma, NOS, invasive		1 (0%)

TABLE A1. SUMMARY OF THE INCIDENCE OF NEOPLASMS IN MALE RATS IN THE LIFETIME FEED STUDY OF CROCIDOLITE ASBESTOS (Continued)

	Untreated Control	1% Crocidolite Asbestos
HEMATOPOIETIC SYSTEM (Continued)		
#Mediastinal lymph node	(117)	(250)
C-cell carcinoma, metastatic		1 (0%)
Pheochromocytoma, metastatic		1 (0%)
Rhabdomyosarcoma, metastatic		1 (0%)
Mesothelioma, metastatic	1 (1%)	
#Liver	(117)	(250)
Malignant lymphoma, histiocytic type		1 (0%)
Kupffer cell sarcoma		1 (0%)
Monocytic leukemia		3 (1%)
#Thymus	(88)	(182)
Papillary adenocarcinoma		1 (1%)
Granulocytic leukemia	1 (1%)	
CIRCULATORY SYSTEM		
*Multiple organs	(118)	(250)
Hemangiosarcoma, metastatic		1 (0%)
*Skin	(118)	(250)
Hemangiopericytoma, malignant		1 (0%)
*Subcutaneous tissue	(118)	(250)
Hemangiosarcoma		2 (1%)
#Bone marrow	(117)	(248)
Hemangiosarcoma	1 (1%)	
#Spleen	(117)	(250)
Hemangiosarcoma, metastatic		1 (0%)
*Vertebral column	(118)	(250)
Hemangiosarcoma		1 (0%)
#Lung	(117)	(250)
Hemangiosarcoma, metastatic	1 (1%)	1 (0%)
*Costal pleura	(118)	(250)
Hemangiosarcoma	1 (1%)	
#Heart	(117)	(250)
Hemangiosarcoma	1 (1%)	
#Myocardium	(117)	(250)
Alveolar/bronchiolar carcinoma, invasive		1 (0%)
Neurilemoma	1 (1%)	
*Mesentery	(118)	(250)
Hemangiosarcoma		1 (0%)
DIGESTIVE SYSTEM		
*Oral mucous membrane	(118)	(250)
Squamous cell carcinoma	4 (3%)	2 (1%)
*Tongue	(118)	(250)
Squamous cell papilloma		1 (0%)
#Salivary gland	(115)	(249)
Adenoma, NOS		1 (0%)
Sarcoma, NOS	1 (1%)	5 (2%)
#Liver	(117)	(250)
Neoplastic nodule	8 (7%)	16 (6%)
Hepatocellular carcinoma	4 (3%)	3 (1%)
Sarcoma, NOS	1 (1%)	
#Pancreas	(117)	(249)
Acinar cell adenoma	8 (7%)	15 (6%)
Acinar cell carcinoma		2 (1%)
*Pharynx	(118)	(250)
Squamous cell carcinoma		1 (0%)

TABLE A1. SUMMARY OF THE INCIDENCE OF NEOPLASMS IN MALE RATS IN THE LIFETIME FEED STUDY OF CROCIDOLITE ASBESTOS (Continued)

	Untreated Control	1% Crocidolite Asbestos
DIGESTIVE SYSTEM (Continued)		
#Stomach	(116)	(249)
Carcinoma in-situ, NOS	1 (1%)	
Carcinoma, NOS		1 (0%)
Squamous cell papilloma		1 (0%)
Squamous cell carcinoma		1 (0%)
Basal cell carcinoma		1 (0%)
Fibrosarcoma		1 (0%)
Leiomyosarcoma		1 (0%)
#Duodenum	(117)	(249)
Fibrosarcoma	1 (1%)	1 (0%)
#Jejunum	(117)	(249)
Mucinous cystadenocarcinoma		1 (0%)
Fibrosarcoma	1 (1%)	
#Ileum	(117)	(249)
Adenocarcinoma, NOS	1 (1%)	
Leiomyosarcoma		1 (0%)
#Cecum	(117)	(249)
Adenomatous polyp, NOS	1 (1%)	
Lipoma		1 (0%)
#Ascending colon	(117)	(249)
Adenomatous polyp, NOS		1 (0%)
Leiomyosarcoma		1 (0%)
#Transverse colon	(117)	(249)
Carcinoma, NOS	1 (1%)	
#Descending colon	(117)	(249)
Adenomatous polyp, NOS		3 (1%)
URINARY SYSTEM		
#Kidney	(117)	(250)
Tubular cell adenoma		2 (1%)
Tubular cell adenocarcinoma		5 (2%)
Mixed tumor, malignant	1 (1%)	1 (0%)
#Urinary bladder	(116)	(250)
Transitional cell papilloma	2 (2%)	
ENDOCRINE SYSTEM		
#Pituitary	(117)	(245)
Carcinoma, NOS	3 (3%)	4 (2%)
Adenoma, NOS	15 (13%)	41 (17%)
#Adrenal	(117)	(250)
Cortical adenoma	2 (2%)	8 (3%)
Pheochromocytoma	29 (25%)	46 (18%)
Pheochromocytoma, malignant	2 (2%)	6 (2%)
#Adrenal medulla	(117)	(250)
Pheochromocytoma	4 (3%)	8 (3%)
Pheochromocytoma, malignant		2 (1%)
#Thyroid	(116)	(249)
Follicular cell adenoma	7 (6%)	15 (6%)
Follicular cell carcinoma	3 (3%)	22 (9%)
C-cell adenoma	13 (11%)	34 (14%)
C-cell carcinoma	19 (16%)	48 (19%)
#Pancreatic islets	(117)	(249)
Islet cell adenoma	2 (2%)	
Islet cell carcinoma	11 (9%)	11 (4%)

**TABLE A1. SUMMARY OF THE INCIDENCE OF NEOPLASMS IN MALE RATS IN THE LIFETIME
FEED STUDY OF CROCIDOLITE ASBESTOS (Continued)**

	Untreated Control	1% Crocidolite Asbestos
REPRODUCTIVE SYSTEM		
*Mammary gland	(118)	(250)
Adenoma, NOS		1 (0%)
Adenocarcinoma, NOS	1 (1%)	4 (2%)
Fibroadenoma	18 (15%)	18 (7%)
*Preputial gland	(118)	(250)
Squamous cell carcinoma	3 (3%)	16 (6%)
#Prostate	(116)	(250)
Carcinoma, NOS		1 (0%)
#Testis	(118)	(249)
Interstitial cell tumor	116 (98%)	237 (95%)
#Rete testis	(118)	(249)
Adenocarcinoma, NOS		1 (0%)
*Epididymis	(118)	(250)
Lipoma	1 (1%)	1 (0%)
Mesothelioma, NOS	1 (1%)	
NERVOUS SYSTEM		
#Cerebrum	(117)	(249)
Carcinoma, NOS, invasive	1 (1%)	1 (0%)
Granular cell tumor, NOS		1 (0%)
Astrocytoma		2 (1%)
#Cerebellum	(117)	(249)
Meningioma		1 (0%)
#Medulla oblongata	(117)	(249)
Meningioma, invasive		1 (0%)
*Cauda equina	(118)	(250)
Liposarcoma, invasive		1 (0%)
*Cranial nerve	(118)	(250)
Ganglioneuroma	1 (1%)	
SPECIAL SENSE ORGANS		
*Harderian gland	(118)	(250)
Squamous cell carcinoma, invasive		1 (0%)
Adenoma, NOS		1 (0%)
*Ear canal	(118)	(250)
Squamous cell carcinoma	1 (1%)	
*Zymbal gland	(118)	(250)
Squamous cell carcinoma	4 (3%)	5 (2%)
Keratoacanthoma	1 (1%)	1 (0%)
MUSCULOSKELETAL SYSTEM		
*Mandible	(118)	(250)
Squamous cell carcinoma, invasive		1 (0%)
Osteosarcoma	1 (1%)	
*Scapula	(118)	(250)
Osteosarcoma	1 (1%)	
*Rib	(118)	(250)
Osteosarcoma		1 (0%)
*Muscle of back	(118)	(250)
Rhabdomyosarcoma		1 (0%)
*Muscle of neck	(118)	(250)
C-cell carcinoma, invasive	2 (2%)	1 (0%)

TABLE A1. SUMMARY OF THE INCIDENCE OF NEOPLASMS IN MALE RATS IN THE LIFETIME FEED STUDY OF CROCIDOLITE ASBESTOS (Continued)

	Untreated Control	1% Crocidolite Asbestos
BODY CAVITIES		
*Mediastinum	(118)	(250)
Alveolar/bronchiolar carcinoma, invasive		1 (0%)
*Abdominal cavity	(118)	(250)
Lipoma	1 (1%)	
Leiomyosarcoma, invasive		1 (0%)
*Peritoneum	(118)	(250)
Liposarcoma		1 (0%)
*Pleura	(118)	(250)
Mesothelioma, malignant	1 (1%)	
*Mesentery	(118)	(250)
Fibrosarcoma		1 (0%)
Mesothelioma, malignant		1 (0%)
*Tunica vaginalis	(118)	(250)
Mesothelioma, NOS	1 (1%)	1 (0%)
Mesothelioma, malignant	3 (3%)	4 (2%)
ALL OTHER SYSTEMS		
*Multiple organs	(118)	(250)
Squamous cell carcinoma, invasive	4 (3%)	2 (1%)
Squamous cell carcinoma, metastatic	1 (1%)	
Alveolar/bronchiolar carcinoma, invasive	1 (1%)	
C-cell carcinoma, metastatic		1 (0%)
Sarcoma, NOS, invasive		1 (0%)
Fibrosarcoma, invasive		1 (0%)
Liposarcoma, metastatic		1 (0%)
Mesothelioma, invasive	4 (3%)	5 (2%)
Osteosarcoma, invasive	1 (1%)	
Osteosarcoma, metastatic	1 (1%)	
ANIMAL DISPOSITION SUMMARY		
Animals initially in study	118	250
Natural death	15	32
Moribund sacrifice	92	186
Terminal sacrifice	11	29
Accidentally killed, nda		3
TUMOR SUMMARY		
Total animals with primary tumors**	118	248
Total primary tumors	395	831
Total animals with benign tumors	117	242
Total benign tumors	251	498
Total animals with malignant tumors	97	209
Total malignant tumors	134	315
Total animals with secondary tumors##	17	37
Total secondary tumors	21	48
Total animals with tumors-- uncertain benign or malignant	9	18
Total uncertain tumors	10	18

* Number of animals receiving complete necropsy examination; all gross lesions including masses examined microscopically.

** Primary tumors: all tumors except secondary tumors

Number of animals examined microscopically at this site

Secondary tumors: metastatic tumors or tumors invasive into an adjacent organ

‡ Multiple occurrence of morphology; tissues are counted once only.

TABLE A2. INDIVIDUAL ANIMAL TUMOR PATHOLOGY OF MALE RATS IN THE LIFETIME FEED STUDY OF CROCIDOLITE ASBESTOS: UNTREATED CONTROL

ANIMAL NUMBER	512	515	517	419	416	517	413	513	510	417	419	418	414	416	418	513	418	511	511	514	417	511	415	416	419		
WEEKS ON STUDY	60	71	74	76	77	78	83	84	86	88	89	90	90	90	90	90	90	90	90	90	90	90	90	90	90	90	
INTEGUMENTARY SYSTEM																											
Skin	+	+	+	+	+	+	+	+	+	+	+	+	+	+	+	+	+	+	+	+	+	+	+	+	+	+	
Squamous cell papilloma																											
Squamous cell carcinoma																											
Basal cell tumor																											
Basal cell carcinoma																											
Keratoacanthoma																											
Fibroma																											
Fibrosarcoma																											
Myxosarcoma																											
Subcutaneous tissue	+	+	+	+	+	+	+	+	+	+	+	+	+	+	+	+	+	+	+	+	+	+	+	+	+	+	
Sarcoma, NOS																											
Fibroma										X									X								
Fibrosarcoma										X	X	X									X						
Lipoma																											
Neurofibroma																										X	
RESPIRATORY SYSTEM																											
Lungs and bronchi	+	+	+	+	+	+	+	+	+	+	+	+	+	+	+	+	+	+	+	+	+	+	+	+	+	+	
Squamous cell carcinoma																											
Squamous cell carcinoma, metastatic																											
Alveolar/bronchiolar adenoma																											
Alveolar/bronchiolar carcinoma																											
C cell carcinoma, metastatic																											
Hemangiosarcoma, metastatic																											
Trachea	+	+	+	+	+	+	+	+	+	+	+	+	+	+	+	+	+	+	+	+	+	+	+	+	+	+	
C-cell carcinoma, invasive																											
HEMATOPOIETIC SYSTEM																											
Bone marrow	+	+	+	+	+	+	+	+	+	+	+	+	+	+	+	+	+	+	+	+	+	+	+	+	+	+	
Hemangiosarcoma																											
Spleen	+	+	+	+	+	+	+	+	+	+	+	+	+	+	+	+	+	+	+	+	+	+	+	+	+	+	
Lymph nodes	+	+	+	+	+	+	+	+	+	+	+	+	+	+	+	+	+	+	+	+	+	+	+	+	+	+	
Squamous cell carcinoma, metastatic																											
Mesothelioma, metastatic																											
Thymus	+	+	+	+	+	+	+	+	-	+	-	-	+	-	+	+	+	+	+	+	+	+	+	+	+		
Granulocytic leukemia																						X					
CIRCULATORY SYSTEM																											
Heart	+	+	+	+	+	+	+	+	+	+	+	+	+	+	+	+	+	+	+	+	+	+	+	+	+	+	
Hemangiosarcoma																											
Neurilemoma																											
DIGESTIVE SYSTEM																											
Oral cavity	N	N	N	N	N	N	N	N	N	N	N	N	N	N	N	N	N	N	N	N	N	N	N	N	N	N	
Squamous cell carcinoma																											
Salivary gland	+	+	+	+	+	+	+	+	+	+	+	+	+	+	+	+	+	+	+	+	+	+	+	+	+	+	
Sarcoma, NOS																											
Liver	+	+	+	+	+	+	+	+	+	+	+	+	+	+	+	+	+	+	+	+	+	+	+	+	+	+	
Neoplastic nodule																											
Hepatocellular carcinoma																											
Sarcoma, NOS																											
Bile duct	+	+	+	+	+	+	+	+	+	+	+	+	+	+	+	+	+	+	+	+	+	+	+	+	+	+	
Pancreas	+	+	+	+	+	+	+	+	+	+	+	+	+	+	+	+	+	+	+	+	+	+	+	+	+	+	
Acinar cell adenoma																											
Esophagus	-	+	-	+	+	+	+	+	+	+	+	+	+	+	+	+	+	+	+	+	+	+	+	+	+	+	
Stomach	+	+	+	+	+	+	+	+	+	+	+	+	+	+	+	+	+	+	+	+	+	+	+	+	+	+	
Carcinoma in situ, NOS																											
Small intestine	+	+	+	+	+	+	+	+	+	+	+	+	+	+	+	+	+	+	+	+	+	+	+	+	+	+	
Adenocarcinoma, NOS																											
Fibrosarcoma																											
Large intestine	+	+	+	+	+	+	+	+	+	+	+	+	+	+	+	+	+	+	+	+	+	+	+	+	+	+	
Carcinoma, NOS																											
Adenomatous polyp, NOS																											
URINARY SYSTEM																											
Kidney	+	+	+	+	+	+	+	+	+	+	+	+	+	+	+	+	+	+	+	+	+	+	+	+	+	+	
Mixed tumor, malignant																											
Urinary bladder	+	+	+	+	+	+	+	+	+	+	+	+	+	+	+	+	+	+	+	+	+	+	+	+	+	+	
Transitional cell papilloma																											

+ Tissue examined microscopically
 - Required tissue not examined microscopically
 X Tumor incidence
 N Necropsy, no autolysis, no microscopic examination
 S Animal missexed
 No tissue information submitted
 C Necropsy, no histology due to protocol
 A Autolysis
 M Animal missing
 B No necropsy performed

TABLE A2. INDIVIDUAL ANIMAL TUMOR PATHOLOGY OF MALE RATS: UNTREATED CONTROL (Continued)

ANIMAL NUMBER	47	59	58	43	41	59	50	55	55	55	55	44	44	44	44	44	44	52	44	44	55	44	44	44	44	44	44	44
WEEKS ON STUDY	10	10	10	10	10	10	10	10	10	10	10	10	10	10	10	10	10	10	10	10	10	10	10	10	10	10	10	10
INTEGUMENTARY SYSTEM																												
Skin	+																											
Squamous cell papilloma																												
Squamous cell carcinoma	X																											
Basal cell tumor																												
Basal cell carcinoma																												
Keratoacanthoma																												
Fibroma																												
Fibrosarcoma																												
Myxosarcoma																												
Subcutaneous tissue	+																											
Sarcoma, NOS																												
Fibroma																												
Fibrosarcoma	X																											
Lipoma																												
Neurofibroma																												
RESPIRATORY SYSTEM																												
Lungs and bronchi	+																											
Squamous cell carcinoma																												
Squamous cell carcinoma, metastatic																												
Alveolar/bronchiolar adenoma																												
Alveolar/bronchiolar carcinoma																												
C-cell carcinoma, metastatic	X																											
Hemangiosarcoma, metastatic																												
Trachea	+																											
C-cell carcinoma, invasive																												
HEMATOPOIETIC SYSTEM																												
Bone marrow	+																											
Hemangiosarcoma																												
Spleen	+																											
Lymph nodes	+																											
Squamous cell carcinoma, metastatic																												
Mesothelioma, metastatic																												
Thymus	-																											
Granulocytic leukemia																												
CIRCULATORY SYSTEM																												
Heart	+																											
Hemangiosarcoma																												
Neurilemoma																												
DIGESTIVE SYSTEM																												
Oral cavity	N																											
Squamous cell carcinoma																												
Salivary gland	+																											
Sarcoma, NOS																												
Liver	+																											
Neoplastic nodule																												
Hepatocellular carcinoma																												
Sarcoma, NOS	X																											
Bile duct	+																											
Pancreas	+																											
Acinar cell adenoma																												
Esophagus	+																											
Stomach	+																											
Carcinoma in situ, NOS																												
Small intestine	+																											
Adenocarcinoma, NOS																												
Fibrosarcoma																												
Large intestine	+																											
Carcinoma, NOS																												
Adenomatous polyp, NOS																												
URINARY SYSTEM																												
Kidney	+																											
Mixed tumor, malignant																												
Urinary bladder	+																											
Transitional cell papilloma																												

TABLE A2. INDIVIDUAL ANIMAL TUMOR PATHOLOGY OF MALE RATS: UNTREATED CONTROL (Continued)

ANIMAL NUMBER	5 4 2	5 4 5	4 4 9	5 0 7	5 1 7	4 3 2	4 6 9	5 3 3	4 8 6	5 1 3	4 5 7	4 0 9	5 1 3	5 4 4	4 7 6	4 9 3	5 0 8	4 9 2	5 2 0	5 0 2	5 2 3	5 3 0	4 3 0	5 4 4	5 2 6		
WEEKS ON STUDY	1 1 6	1 1 6	1 1 7	1 1 7	1 1 7	1 1 8	1 1 8	1 1 8	1 1 9	1 1 9	1 2 0	1 2 0	1 2 2	1 2 2	1 2 3	1 2 3	1 2 3	1 2 4	1 2 4	1 2 6	1 2 6	1 2 6	1 2 7	1 2 7	1 2 7		
INTEGUMENTARY SYSTEM																											
Skin																											
Squamous cell papilloma			X																								
Squamous cell carcinoma																											
Basal cell tumor																											
Basal cell carcinoma																											
Keratoacanthoma								X		X																	
Fibroma																											
Fibrosarcoma																											
Myxosarcoma																											
Subcutaneous tissue																											
Sarcoma, NOS																											
Fibroma																											
Fibrosarcoma																											
Lipoma																											
Neurofibroma																											
RESPIRATORY SYSTEM																											
Lungs and bronchi																											
Squamous cell carcinoma																											
Squamous cell carcinoma, metastatic																											
Alveolar/bronchiolar adenoma																											
Alveolar/bronchiolar carcinoma																											
C-cell carcinoma, metastatic																											
Hemangiosarcoma, metastatic																											
Trachea																											
C cell carcinoma, invasive																											
HEMATOPOIETIC SYSTEM																											
Bone marrow																											
Hemangiosarcoma																											
Spleen																											
Lymph nodes																											
Squamous cell carcinoma, metastatic																											
Mesothelioma, metastatic																											
Thymus																											
Granulocytic leukemia																											
CIRCULATORY SYSTEM																											
Heart																											
Hemangiosarcoma																											
Neurilemoma																											
DIGESTIVE SYSTEM																											
Oral cavity																											
Squamous cell carcinoma																											
Salivary gland																											
Sarcoma, NOS																											
Liver																											
Neoplastic nodule																											
Hepatocellular carcinoma																											
Sarcoma, NOS																											
Bile duct																											
Pancreas																											
Acinar cell adenoma																											
Esophagus																											
Stomach																											
Carcinoma in situ, NOS																											
Small intestine																											
Adenocarcinoma, NOS																											
Fibrosarcoma																											
Large intestine																											
Carcinoma, NOS																											
Adenomatous polyp, NOS																											
URINARY SYSTEM																											
Kidney																											
Mixed tumor, malignant																											
Urinary bladder																											
Transitional cell papilloma																											

TABLE A2. INDIVIDUAL ANIMAL TUMOR PATHOLOGY OF MALE RATS: UNTREATED CONTROL (Continued)

ANIMAL NUMBER	4	5	5	5	4	5	4	4	4	4	4	5	5	5	4	4	4	5	5	4	5	4	4	5	5	4	4	5	5	
WEEKS ON STUDY	2	2	2	2	2	2	3	3	3	3	3	3	3	3	3	3	3	3	3	3	3	3	3	3	3	3	3	3	3	3
	8	8	8	8	9	9	0	0	0	0	0	0	0	0	0	1	1	2	2	2	2	2	2	2	2	2	2	2	2	2
INTEGUMENTARY SYSTEM																														
Skin																														
Squamous cell papilloma	+	+	+	+	+	+	+	+	+	+	+	+	+	+	+	+	+	+	+	+	+	+	+	+	+	+	+	+	+	+
Squamous cell carcinoma																														
Basal cell tumor																														
Basal cell carcinoma							X																							
Keratoacanthoma																														
Fibroma																														
Fibrosarcoma																														
Myxosarcoma																														
Subcutaneous tissue	+	+	+	+	+	+	+	+	+	+	+	+	+	+	+	+	+	+	+	+	+	+	+	+	+	+	+	+	+	+
Sarcoma, NOS																														
Fibroma																														
Fibrosarcoma																														
Lipoma																														
Neurofibroma																														
RESPIRATORY SYSTEM																														
Lungs and bronchi																														
Squamous cell carcinoma	+	+	+	+	+	+	+	+	+	+	+	+	+	+	+	+	+	+	+	+	+	+	+	+	+	+	+	+	+	+
Squamous cell carcinoma, metastatic																														
Alveolar/bronchiolar adenoma																														
Alveolar/bronchiolar carcinoma																														
C-cell carcinoma, metastatic																														
Hemangiosarcoma, metastatic																														
Trachea																														
C-cell carcinoma, invasive	+	+	+	+	+	+	+	+	+	+	+	+	+	+	+	+	+	+	+	+	+	+	+	+	+	+	+	+	+	+
HEMATOPOIETIC SYSTEM																														
Bone marrow																														
Hemangiosarcoma	+	+	+	+	+	+	+	+	+	+	+	+	+	+	+	+	+	+	+	+	+	+	+	+	+	+	+	+	+	+
Spleen																														
Lymph nodes	+	+	+	+	+	+	+	+	+	+	+	+	+	+	+	+	+	+	+	+	+	+	+	+	+	+	+	+	+	+
Squamous cell carcinoma, metastatic																														
Mesothelioma, metastatic																														
Thymus																														
Granulocytic leukemia	+	+	+	+	+	+	+	+	-	+	+	-	+	+	-	+	+	-	+	+	+	+	+	+	+	+	+	+	+	+
CIRCULATORY SYSTEM																														
Heart																														
Hemangiosarcoma	+	+	+	+	+	+	+	+	+	+	+	+	+	+	+	+	+	+	+	+	+	+	+	+	+	+	+	+	+	+
Neurilemoma																														
DIGESTIVE SYSTEM																														
Oral cavity																														
Squamous cell carcinoma	N	N	N	N	N	N	N	N	N	N	N	N	N	N	N	N	N	N	N	N	N	N	N	N	N	N	N	N	N	N
Squamous cell carcinoma, metastatic																														
Salivary gland																														
Sarcoma, NOS	+	+	+	+	+	+	+	+	+	+	+	+	+	+	+	+	+	+	+	+	+	+	+	+	+	+	+	+	+	+
Liver																														
Neoplastic nodule	+	+	+	+	+	+	+	+	+	+	+	+	+	+	+	+	+	+	+	+	+	+	+	+	+	+	+	+	+	+
Hepatocellular carcinoma	X																													
Sarcoma, NOS																														
Bile duct																														
Pancreas	+	+	+	+	+	+	+	+	+	+	+	+	+	+	+	+	+	+	+	+	+	+	+	+	+	+	+	+	+	+
Acinar cell adenoma	X	X																												
Esophagus																														
Stomach	+	+	+	+	+	+	+	+	+	+	+	+	+	+	+	+	+	+	+	+	+	+	+	+	+	+	+	+	+	+
Carcinoma in situ, NOS																														
Small intestine																														
Adenocarcinoma, NOS	+	+	+	+	+	+	+	+	+	+	+	+	+	+	+	+	+	+	+	+	+	+	+	+	+	+	+	+	+	+
Fibrosarcoma																														
Large intestine																														
Carcinoma, NOS	+	+	+	+	+	+	+	+	+	+	+	+	+	+	+	+	+	+	+	+	+	+	+	+	+	+	+	+	+	+
Adenomatous polyp, NOS																														
URINARY SYSTEM																														
Kidney																														
Mixed tumor, malignant	+	+	+	+	+	+	+	+	+	+	+	+	+	+	+	+	+	+	+	+	+	+	+	+	+	+	+	+	+	+
Urinary bladder	+	+	+	+	+	+	+	+	+	+	+	+	+	+	+	+	+	+	+	+	+	+	+	+	+	+	+	+	+	+
Transitional cell papilloma																														

TABLE A2. INDIVIDUAL ANIMAL TUMOR PATHOLOGY OF MALE RATS: UNTREATED CONTROL
(Continued)

ANIMAL NUMBER	4 6 1	4 7 8	5 2 7	4 6 0	4 4 6	4 8 9	5 0 1	4 3 9	4 4 2	4 5 2	4 6 2	4 6 2	4 7 2	4 8 2	4 8 2	4 9 2	5 9 2	TOTAL TISSUES TUMORS
WEEKS ON STUDY	1 3 8	1 3 8	1 3 8	1 3 9	1 4 0	1 4 0	1 4 1	1 4 2	1 4 2	1 4 2	1 4 2	1 4 2	1 4 2	1 4 2	1 4 2	1 4 2	1 4 2	
INTEGUMENTARY SYSTEM																		
Skin	+	+	+	+	+	+	+	+	+	+	+	+	+	+	+	+	+	*118
Squamous cell papilloma																		1
Squamous cell carcinoma																	X	2
Basal cell tumor																		1
Basal cell carcinoma																		2
Keratocanthoma				X														4
Fibroma																		1
Fibrosarcoma																		2
Myxosarcoma																		1
Subcutaneous tissue	+	+	+	+	+	+	+	+	+	+	+	+	+	+	+	+	+	*118
Sarcoma, NOS																		1
Fibroma	X							X	X			X						17
Fibrosarcoma																	X	6
Lipoma																		1
Neurofibroma																		3
RESPIRATORY SYSTEM																		
Lungs and bronchi	+	+	+	+	+	+	+	+	+	+	+	+	+	+	+	+	+	117
Squamous cell carcinoma											X							1
Squamous cell carcinoma, metastatic																	X	1
Alveolar/bronchiolar adenoma						X												1
Alveolar/bronchiolar carcinoma																		2
C-cell carcinoma, metastatic																		1
Hemangiosarcoma, metastatic																		1
Trachea	+	+	+	+	+	+	+	+	+	+	+	+	+	+	+	+	+	117
C cell carcinoma, invasive																		1
HEMATOPOIETIC SYSTEM																		
Bone marrow	+	+	+	+	+	+	+	+	+	+	+	+	+	+	+	+	+	117
Hemangiosarcoma	X																	1
Spleen	+	+	+	+	+	+	+	+	+	+	+	+	+	+	+	+	+	117
Lymph nodes	+	+	+	+	+	+	+	+	+	+	+	+	+	+	+	+	+	117
Squamous cell carcinoma, metastatic																	X	1
Mesothelioma, metastatic																		1
Thymus	+	+	+	+	+	+	+	+	+	+	+	+	+	+	+	+	+	88
Granulocytic leukemia																		1
CIRCULATORY SYSTEM																		
Heart	+	+	+	+	+	+	+	+	+	+	+	+	+	+	+	+	+	117
Hemangiosarcoma																		1
Neurilemoma										X								1
DIGESTIVE SYSTEM																		
Oral cavity	N	N	N	N	N	N	N	N	N	N	N	N	N	N	N	N	N	*118
Squamous cell carcinoma						X												4
Salivary gland	+	+	+	+	+	+	+	+	+	+	+	+	+	+	+	+	+	115
Sarcoma, NOS																	X	1
Liver	+	+	+	+	+	+	+	+	+	+	+	+	+	+	+	+	+	117
Neoplastic nodule	X									X								8
Hepatocellular carcinoma																	X	4
Sarcoma, NOS																		1
Bile duct	+	+	+	+	+	+	+	+	+	+	+	+	+	+	+	+	+	117
Pancreas	+	+	+	+	+	+	+	+	+	+	+	+	+	+	+	+	+	117
Acinar cell adenoma	X							X			X							8
Esophagus	+	+	+	+	+	+	+	+	+	+	+	+	+	+	+	+	+	115
Stomach	+	-	+	+	+	+	+	+	+	+	+	+	+	+	+	+	+	116
Carcinoma in situ, NOS																		1
Small intestine	+	+	+	+	+	+	+	+	+	+	+	+	+	+	+	+	+	117
Adenocarcinoma, NOS																		1
Fibrosarcoma	X																	2
Large intestine	+	+	+	+	+	+	+	+	+	+	+	+	+	+	+	+	+	117
Carcinoma, NOS																		1
Adenomatous polyp, NOS																		1
URINARY SYSTEM																		
Kidney	+	+	+	+	+	+	+	+	+	+	+	+	+	+	+	+	+	117
Mixed tumor, malignant																		1
Urinary bladder	+	+	+	+	+	+	+	+	+	+	+	+	+	+	+	+	+	116
Transitional cell papilloma										X								2

* Animals necropsied

TABLE A2. INDIVIDUAL ANIMAL TUMOR PATHOLOGY OF MALE RATS: UNTREATED CONTROL (Continued)

ANIMAL NUMBER	512	515	517	414	417	511	413	513	514	414	414	414	414	414	415	415	515	515	515	414	514	414	414	414
WEEKS ON STUDY	60	71	77	77	77	88	88	88	88	99	99	00	00	00	00	00	00	00	00	00	11	11	11	11
ENDOCRINE SYSTEM																								
Pituitary	+	+	+	+	+	+	+	+	+	+	+	+	+	+	+	+	+	+	+	+	+	+	+	+
Carcinoma, NOS																	X	X						
Adenoma NOS	-	-	-	+	+	+	+	+	+	+	+	+	+	+	+	+	+	+	+	+	+	+	+	+
Cortical adenoma																								
Pheochromocytoma													X											
Pheochromocytoma, malignant																								
Thyroid	+	+	+	+	+	+	+	+	+	+	+	+	+	+	+	+	+	+	+	+	+	+	+	+
Follicular cell adenoma																								
Follicular cell carcinoma																								
C-cell adenoma							X																	
C-cell carcinoma																		X		X				
Parathyroid	+	+	+	+	+	+	+	+	+	+	+	+	+	+	+	+	+	+	+	+	+	+	+	+
Pancreatic islets	+	+	+	+	+	+	+	+	+	+	+	+	+	+	+	+	+	+	+	+	+	+	+	+
Islet cell adenoma																		X						
Islet cell carcinoma																		X						
REPRODUCTIVE SYSTEM																								
Mammary gland	+	+	+	+	+	+	+	+	+	+	+	N	+	+	+	+	+	+	+	+	+	+	+	+
Adenocarcinoma, NOS																								
Fibroadenoma							X																	
Testis	+	+	+	+	+	+	+	+	+	+	+	+	+	+	+	+	+	+	+	+	+	+	+	+
Interstitial cell tumor	X	X	X	X	X	X	X	X	X	X	X	X	X	X	X	X	X	X	X	X	X	X	X	X
Prostate	+	+	+	+	+	+	+	+	+	+	+	+	+	+	+	+	+	+	+	+	+	+	+	+
Preputial/clitoral gland	N	N	N	N	N	N	N	N	N	N	N	N	N	N	N	N	N	N	N	N	N	N	N	N
Squamous cell carcinoma																								
Epididymis	N	N	N	N	N	N	N	N	N	N	N	N	N	N	N	N	N	N	N	N	N	N	N	N
Lipoma																								
Mesothelioma, NOS																		X						
NERVOUS SYSTEM																								
Nerves	N	N	N	N	N	N	N	N	N	N	N	N	N	N	N	N	N	N	N	N	N	N	N	N
Ganglioneuroma	X																							
Brain	+	+	+	+	+	+	+	+	+	+	+	+	+	+	+	+	+	+	+	+	+	+	+	+
Carcinoma, NOS, invasive																		X						
SPECIAL SENSE ORGANS																								
Ear	+	N	N	+	+	+	+	+	+	+	+	+	+	+	+	+	+	+	+	+	+	+	+	+
Squamous cell carcinoma																								
Zymbal gland	N	N	N	N	N	N	N	N	N	N	N	N	N	N	N	N	N	N	N	N	N	N	N	N
Squamous cell carcinoma																								
Keratoacanthoma																						X		
MUSCULOSKELETAL SYSTEM																								
Bones	N	N	N	N	N	N	N	N	N	N	N	N	N	N	N	N	N	N	N	N	N	N	N	N
Osteosarcoma																								
Muscle	N	N	N	N	N	N	N	N	N	N	N	N	N	N	N	N	N	N	N	N	N	N	N	N
C-cell carcinoma, invasive																								
BODY CAVITIES																								
Pleura	N	N	N	N	N	N	N	N	N	N	N	N	N	N	N	N	N	N	N	N	N	N	N	N
Mesothelioma, malignant																								
Hemangiosarcoma																								
Peritoneum	N	N	N	N	N	N	N	N	N	N	N	N	N	N	N	N	N	N	N	N	N	N	N	N
Lipoma																								
Tunica vaginalis	+	+	+	+	+	+	+	+	+	+	+	+	+	+	+	+	+	+	+	+	+	+	+	+
Mesothelioma, NOS																								
Mesothelioma, malignant																		X						
ALL OTHER SYSTEMS																								
Multiple organs NOS	N	N	N	N	N	N	N	N	N	N	N	N	N	N	N	N	N	N	N	N	N	N	N	N
Squamous cell carcinoma, invasive																								
Squamous cell carcinoma, metastatic																								
Alveolar/bronchiolar carcinoma, invasive																								
Fibrous histiocytoma, malignant																								
Mesothelioma, invasive														X										
Osteosarcoma, invasive																								
Osteosarcoma, metastatic																								
Malignant lymphoma, histiocytic type																								
Monocytic leukemia	X		X							X			X						X				X	X

**TABLE A2. INDIVIDUAL ANIMAL TUMOR PATHOLOGY OF MALE RATS: UNTREATED CONTROL
(Continued)**

ANIMAL NUMBER	4971	5298	5383	4411	4494	4499	5024	5025	5026	5027	4468	5366	4452	4458	4455	4456	5027	4472	4490	5332	4434	4435	4438	4439		
WEEKS ON STUDY	104	104	105	106	108	108	108	108	108	108	108	108	108	108	108	108	108	108	108	108	108	108	108	108	108	
ENDOCRINE SYSTEM																										
Pituitary	+	+	+	+	+	+	+	+	+	+	+	+	+	+	+	+	+	+	+	+	+	+	+	+	+	
Carcinoma, NOS																										
Adenoma, NOS								X			X													X		
Adrenal	+	+	+	+	+	+	+	+	+	+	+	+	+	+	+	+	+	+	+	+	+	+	+	+	+	
Cortical adenoma																										
Pheochromocytoma					X			X			X	X		X	X		X						X		X	
Pheochromocytoma, malignant																										
Thyroid	+	+	+	+	+	+	+	+	+	+	+	+	+	+	+	+	+	+	+	+	+	+	+	+	+	
Follicular cell adenoma					X																		X			
Follicular cell carcinoma																										
C-cell adenoma																										
C-cell carcinoma	X										X				X							X				
Parathyroid	-	+	+	+	+	+	+	+	+	+	+	+	+	+	+	+	+	+	+	+	+	+	+	+	+	
Pancreatic islets	+	+	+	+	+	+	+	+	+	+	+	+	+	+	+	+	+	+	+	+	+	+	+	+	+	
Islet cell adenoma																										
Islet cell carcinoma	X				X						X															
REPRODUCTIVE SYSTEM																										
Mammary gland	+	+	+	+	+	N	N	+	+	N	+	+	+	+	+	+	+	+	+	+	+	+	+	+	+	
Adenocarcinoma, NOS																										
Fibroadenoma								X		X					X							X				
Interstitial cell tumor	+	+	+	+	+	+	+	+	+	+	+	+	+	+	+	+	+	+	+	+	+	+	+	+	+	
Prostate	X	X	X	X	X	X	X	X	X	X	X	X	X	X	X	X	X	X	X	X	X	X	X	X	X	
Preputial/clitoral gland	+	+	+	+	+	+	+	+	+	+	+	+	+	+	+	+	+	+	+	+	+	+	+	+	+	
Squamous cell carcinoma	N	N	N	N	N	N	N	N	N	N	N	N	N	N	N	N	N	N	N	N	N	N	N	N	N	
Epididymis	N	N	N	N	N	N	N	N	N	N	N	N	N	N	N	N	N	N	N	N	N	N	N	N	N	
Lipoma																										
Mesothelioma, NOS								X																		
NERVOUS SYSTEM																										
Nerves	N	N	N	N	N	N	N	N	N	N	N	N	N	N	N	N	N	N	N	N	N	N	N	N	N	
Ganglioneuroma																										
Brain	+	+	+	+	+	+	+	+	+	+	+	+	+	+	+	+	+	+	+	+	+	+	+	+	+	
Carcinoma, NOS, invasive																										
SPECIAL SENSE ORGANS																										
Ear	+	N	+	+	+	+	+	+	+	+	+	+	+	+	+	+	+	+	+	+	N	+	+	+	+	
Squamous cell carcinoma																										
Zymbal gland	N	N	N	N	N	N	N	N	N	N	N	N	N	N	N	N	N	N	N	N	N	N	N	N	N	
Squamous cell carcinoma																										
Keratoacanthoma																										
MUSCULOSKELETAL SYSTEM																										
Bone	N	N	N	N	N	N	N	N	N	N	N	N	N	N	N	N	N	N	N	N	N	N	N	N	N	
Osteosarcoma																										
Muscle	N	+	N	N	N	N	N	N	N	N	N	N	N	N	N	N	N	N	N	N	N	N	N	N	N	
C-cell carcinoma, invasive																										
BODY CAVITIES																										
Pleura	N	N	N	N	N	N	N	N	N	N	N	N	N	N	N	N	N	N	N	N	N	N	N	N	N	
Mesothelioma, malignant																										
Hemangiosarcoma																										
Peritoneum	N	N	N	N	N	N	N	N	N	N	N	N	N	N	N	N	N	N	N	N	N	N	N	N	N	
Lipoma																										
Tunica vaginalis	+	+	+	+	+	+	+	+	+	+	+	+	+	+	+	+	+	+	+	+	+	+	+	+	+	
Mesothelioma, NOS																										
Mesothelioma, malignant	X									X																
ALL OTHER SYSTEMS																										
Multiple organs, NOS	N	N	N	N	N	N	N	N	N	N	N	N	N	N	N	N	N	N	N	N	N	N	N	N	N	
Squamous cell carcinoma, invasive																										
Squamous cell carcinoma, metastatic																										
Alveolar/bronchiolar carcinoma, invasive																										
Fibrous histiocytoma, malignant																									X	
Mesothelioma, invasive	X																									
Osteosarcoma, invasive											X															
Osteosarcoma, metastatic																										
Malignant lymphoma, histiocytic type																										
Monocytic leukemia		X					X				X				X	X	X	X	X						X	

TABLE A2. INDIVIDUAL ANIMAL TUMOR PATHOLOGY OF MALE RATS: UNTREATED CONTROL
(Continued)

ANIMAL NUMBER	5/4/2	5/4/5	4/4/9	5/0/7	5/1/7	4/3/2	4/6/9	5/3/3	4/8/6	5/1/3	4/5/3	4/7/9	5/0/3	5/1/4	4/4/6	4/9/3	5/0/8	4/9/2	5/0/0	5/0/2	5/2/3	5/3/0	4/4/4	5/2/6		
WEEKS ON STUDY	1/6	1/1	1/1	1/1	1/1	1/1	1/1	1/1	1/1	1/1	1/2	1/2	1/2	1/2	1/2	1/2	1/2	1/2	1/2	1/2	1/2	1/2	1/2	1/2	1/2	
ENDOCRINE SYSTEM																										
Pituitary	+	+	-	+	+	+	+	+	+	+	+	+	+	+	+	+	+	+	+	+	+	+	+	+	+	
Carcinoma, NOS																										
Adenoma, NOS													X												X	
Adrenal	+	+	-	+	+	+	+	+	+	+	+	+	+	+	+	+	+	+	+	+	+	+	+	+	+	
Cortical adenoma																										
Pheochromocytoma								X			X									X	X			X	X	
Pheochromocytoma, malignant																										
Thyroid	+	+	-	+	+	+	+	+	+	+	+	+	+	+	+	+	+	+	+	+	+	+	+	+	+	
Follicular cell adenoma																										
Follicular cell carcinoma																										
C-cell adenoma			X																							
C cell carcinoma							X	X					X	X	X		X	X			X				X	
Parathyroid	-	+	-	+	+	+	+	+	+	+	+	+	-	+	+	+	+	+	+	-	+	+	+	+	+	
Pancreatic islets	+	+	-	+	+	+	+	+	+	+	+	+	+	+	+	+	+	+	+	+	+	+	+	+	+	
Islet cell adenoma																										
Islet cell carcinoma					X																					
REPRODUCTIVE SYSTEM																										
Mammary gland	+	+	N	+	+	+	+	+	+	+	+	+	+	+	+	+	+	+	+	+	+	+	+	+	+	
Adenocarcinoma, NOS																										
Fibroadenoma																										
X																										
Testis	+	+	+	+	+	+	+	+	+	+	+	+	+	+	+	+	+	+	+	+	+	+	+	+	+	
Interstitial cell tumor	X	X	X	X	X	X	X	X	X	X	X	X	X	X	X	X	X	X	X	X	X	X	X	X	X	
Prostate	+	+	-	+	+	+	+	+	+	+	+	+	+	+	+	+	+	+	+	+	+	+	+	+	+	
Preputial/clitoral gland	N	N	N	N	N	N	N	N	N	N	N	N	N	N	N	N	N	N	N	N	N	N	N	N	N	
Squamous cell carcinoma																										
Epididymis	N	N	N	N	N	N	N	N	N	N	N	N	N	N	N	N	N	N	N	N	N	N	N	N	N	
Lipoma																										
Mesothelioma, NOS																										
NERVOUS SYSTEM																										
Nerves	N	N	N	N	N	N	N	N	N	N	N	N	N	N	N	N	N	N	N	N	N	N	N	N	N	
Ganglioneuroma																										
Brain	+	+	-	+	+	+	+	+	+	+	+	+	+	+	+	+	+	+	+	+	+	+	+	+	+	
Carcinoma, NOS, invasive																										
SPECIAL SENSE ORGANS																										
Ear	N	+	N	+	+	+	+	+	+	+	+	+	+	+	+	+	+	+	+	+	+	+	+	+	+	
Squamous cell carcinoma																										
Zymbal gland	N	N	N	N	N	N	N	N	N	N	N	N	N	N	N	N	N	N	N	N	N	N	N	N	N	
Squamous cell carcinoma																										
Keratoacanthoma																										
MUSCULOSKELETAL SYSTEM																										
Bone	N	N	N	N	N	N	N	N	N	N	N	N	N	N	N	N	N	N	N	N	N	N	N	N	N	
Osteosarcoma																										
Muscle	N	N	N	N	N	N	N	N	N	N	N	N	N	N	N	N	N	N	N	N	N	N	N	N	N	
C-cell carcinoma, invasive													X													
BODY CAVITIES																										
Pleura	N	N	N	N	N	N	N	N	N	N	N	N	N	N	N	N	N	N	N	N	N	N	N	N	N	
Mesothelioma, malignant																										
Hemangiosarcoma																										
Peritoneum	N	N	N	N	N	N	N	N	N	N	N	N	N	N	N	N	N	N	N	N	N	N	N	N	N	
Lipoma																										
X																										
Tunica vaginalis	+	+	+	+	+	+	+	+	+	+	+	+	+	+	+	+	+	+	+	+	+	+	+	+	+	
Mesothelioma, NOS																										
Mesothelioma, malignant																										
ALL OTHER SYSTEMS																										
Multiple organs, NOS	N	N	N	N	N	N	N	N	N	N	N	N	N	N	N	N	N	N	N	N	N	N	N	N	N	
Squamous cell carcinoma, invasive																										
Squamous cell carcinoma, metastatic																										
Alveolar/bronchiolar carcinoma, invasive																										
Fibrous histiocytoma, malignant																										
Mesothelioma, invasive																										
Osteosarcoma, invasive																										
Osteosarcoma, metastatic																										
Malignant lymphoma, histiocytic type																										
Monocytic leukemia	X	X			X							X	X											X		

TABLE A2. INDIVIDUAL ANIMAL TUMOR PATHOLOGY OF MALE RATS: UNTREATED CONTROL
(Continued)

ANIMAL NUMBER	40	55	58	59	43	51	47	48	45	46	48	50	53	54	44	45	48	50	54	43	51	47	48	45	46	
WEEKS ON STUDY	18	28	28	28	29	29	30	30	30	30	30	30	30	30	31	31	32	32	32	33	33	34	34	35	37	
ENDOCRINE SYSTEM																										
Pituitary																										
Carcinoma, NOS	+	+	+	+	+	+	+	+	+	+	+	+	+	+	+	+	+	+	+	+	+	+	+	+	+	+
Adenoma, NOS															X	X										X
Adrenal																										
Cortical adenoma																										
Pheochromocytoma	X					X					X									X						X
Pheochromocytoma, malignant					X																					
Thyroid																										
Follicular cell adenoma	+	+	+	+	+	+	+	+	+	+	+	+	+	+	+	+	+	+	+	+	+	+	+	+	+	+
Follicular cell carcinoma																										
C-cell adenoma																										
C-cell carcinoma								X	X						X											
Parathyroid																										
Pancreatic islets	+	+	+	+	+	+	+	+	+	+	+	+	+	+	+	+	+	+	+	+	+	+	+	+	+	+
Islet cell adenoma																										
Islet cell carcinoma	X					X					X					X										X
REPRODUCTIVE SYSTEM																										
Mammary gland																										
Adenocarcinoma, NOS						X																				
Fibroadenoma		X																								
Testis																										
Interstitial cell tumor	+	+	+	+	+	+	+	+	+	+	+	+	+	+	+	+	+	+	+	+	+	+	+	+	+	+
Prostate	X	X	X	X	X	X	X	X	X	X	X	X	X	X	X	X	X	X	X	X	X	X	X	X	X	X
Preputial/external gland	+	+	+	+	+	+	+	+	+	+	+	+	+	+	+	+	+	+	+	+	+	+	+	+	+	+
Squamous cell carcinoma	N	N	N	N	N	N	N	N	N	N	N	N	N	N	N	N	N	N	N	N	N	N	N	N	N	N
Epididymis																										
Lipoma	N	N	N	N	N	N	N	N	N	N	N	N	N	N	N	N	N	N	N	N	N	N	N	N	N	N
Mesothelioma, NOS																										
NERVOUS SYSTEM																										
Nerves																										
Ganglioneuroma	N	N	N	N	N	N	N	N	N	N	N	N	N	N	N	N	N	N	N	N	N	N	N	N	N	N
Brain																										
Carcinoma, NOS, invasive	+	+	+	+	+	+	+	+	+	+	+	+	+	+	+	+	+	+	+	+	+	+	+	+	+	+
SPECIAL SENSE ORGANS																										
Ear																										
Squamous cell carcinoma	+	+	+	+	+	+	+	+	+	+	+	+	+	+	+	+	+	+	+	+	+	+	+	+	+	+
Zymbal gland																										
Squamous cell carcinoma	N	N	N	N	N	N	N	N	N	N	N	N	N	N	N	N	N	N	N	N	N	N	N	N	N	N
Keratoacanthoma																										
MUSCULOSKELETAL SYSTEM																										
Bone																										
Osteosarcoma	N	N	N	N	N	N	N	N	N	N	N	N	N	N	N	N	N	N	N	N	N	N	N	N	N	N
Muscle	X																									
C-cell carcinoma, invasive	N	N	N	N	N	N	N	N	N	N	N	N	N	N	N	N	N	N	N	N	N	N	N	N	N	N
BODY CAVITIES																										
Pleura																										
Mesothelioma, malignant	N	N	N	N	N	N	N	N	N	N	N	N	N	N	N	N	N	N	N	N	N	N	N	N	N	N
Hemangiosarcoma																										
Peritoneum																										
Lipoma	N	N	N	N	N	N	N	N	N	N	N	N	N	N	N	N	N	N	N	N	N	N	N	N	N	N
Tunica vaginalis																										
Mesothelioma, NOS	+	+	+	+	+	+	+	+	+	+	+	+	+	+	+	+	+	+	+	+	+	+	+	+	+	+
Mesothelioma, malignant																										
ALL OTHER SYSTEMS																										
Multiple organs, NOS																										
Squamous cell carcinoma, invasive	N	N	N	N	N	N	N	N	N	N	N	N	N	N	N	N	N	N	N	N	N	N	N	N	N	N
Squamous cell carcinoma, metastatic				X	X																					
Alveolar/bronchiolar carcinoma, invasive																										
Fibrous histiocytoma, malignant		X																								
Mesothelioma, invasive																										
Osteosarcoma, invasive																										
Osteosarcoma, metastatic																										
Malignant lymphoma, histiocytic type	X																									
Monocytic leukemia			X			X					X	X	X			X			X		X		X			X

TABLE A2. INDIVIDUAL ANIMAL TUMOR PATHOLOGY OF MALE RATS: UNTREATED CONTROL
(Continued)

ANIMAL NUMBER	4	4	5	4	4	4	5	4	4	4	4	4	4	4	4	4	4	5	TOTAL TISSUES TUMORS
	61	78	27	60	46	49	01	39	43	59	62	64	73	80	87	91	94	99	
WEEKS ON STUDY	11	11	11	11	11	11	11	11	11	11	11	11	11	11	11	11	11	11	
ENDOCRINE SYSTEM																			
Pituitary	+	+	+	+	+	+	+	+	+	+	+	+	+	+	+	+	+	+	117
Carcinoma, NOS		X																	3
Adenoma, NOS							X	X			X	X		X	X				15
Adrenal	+	+	+	+	+	+	+	+	+	+	+	+	+	+	+	+	+	+	117
Cortical adenoma																			2
Pheochromocytoma		X		X	X	X	X	X		X				X	X				33
Pheochromocytoma, malignant														X					2
Thyroid	+	+	+	+	+	+	+	+	+	+	+	+	+	+	+	+	+	+	116
Follicular cell adenoma																			7
Follicular cell carcinoma																			3
C-cell adenoma	X							X				X							13
C-cell carcinoma			X			X		X		X		X	X	X					19
Parathyroid	+	+	+	+	+	+	+	+	+	+	+	+	+	+	+	+	+	+	111
Pancreatic islets	+	+	+	+	+	+	+	+	+	+	+	+	+	+	+	+	+	+	117
Islet cell adenoma																			2
Islet cell carcinoma			X																11
REPRODUCTIVE SYSTEM																			
Mammary gland	+	+	+	+	+	+	+	+	+	+	+	+	+	+	+	+	+	+	*118
Adenocarcinoma, NOS			X	X				X					X		X				1
Fibroadenoma																			18
Testis	+	+	+	+	+	+	+	+	+	+	+	+	+	+	+	+	+	+	118
Interstitial cell tumor	X	X	X	X	X	X	X	X	X	X	X	X	X	X	X	X	X	X	116
Prostate	+	+	+	+	+	+	+	+	+	+	+	+	+	+	+	+	+	+	116
Preputial/clitoral gland	N	N	N	N	N	N	N	N	N	N	N	N	N	N	N	N	N	N	*118
Squamous cell carcinoma				X															3
Epididymis	N	N	N	N	N	N	N	N	N	N	N	N	N	N	N	N	N	N	*118
Lipoma																			1
Mesothelioma, NOS																			1
NERVOUS SYSTEM																			
Nerves	N	N	N	N	N	N	N	N	N	N	N	N	N	N	N	N	N	N	*118
Ganglioneuroma																			1
Brain	+	+	+	+	+	+	+	+	+	+	+	+	+	+	+	+	+	+	117
Carcinoma, NOS, invasive																			1
SPECIAL SENSE ORGANS																			
Ear	+	+	+	+	+	+	+	+	+	+	+	+	+	+	+	+	+	+	*118
Squamous cell carcinoma																			1
Zymbal gland	N	N	N	N	N	N	N	N	N	N	N	N	N	N	N	N	N	N	*118
Squamous cell carcinoma											X								4
Keratoacanthoma																			1
MUSCULOSKELETAL SYSTEM																			
Bone	N	N	N	N	N	N	N	N	N	N	N	N	N	N	N	N	N	N	*118
Osteosarcoma																			2
Muscle	N	N	N	N	N	N	N	N	N	N	N	N	N	N	N	N	N	N	*118
C-cell carcinoma, invasive																			2
BODY CAVITIES																			
Pleura	N	N	N	N	N	N	N	N	N	N	N	N	N	N	N	N	N	N	*118
Mesothelioma, malignant												X							1
Hemangiosarcoma																			1
Peritoneum	N	N	N	N	N	N	N	N	N	N	N	N	N	N	N	N	N	N	*118
Lipoma																			1
Tunica vaginalis	+	+	+	+	+	+	+	+	+	+	+	+	+	+	+	+	+	+	*118
Mesothelioma, NOS																			1
Mesothelioma, malignant																			3
ALL OTHER SYSTEMS																			
Multiple organs, NOS	N	N	N	N	N	N	N	N	N	N	N	N	N	N	N	N	N	N	*118
Squamous cell carcinoma, invasive					X														4
Squamous cell carcinoma, metastatic																			1
Alveolar/bronchiolar carcinoma, invas																			1
Fibrous histiocytoma, malignant																			4
Mesothelioma, invasive											X								1
Osteosarcoma, invasive																			1
Osteosarcoma, metastatic																			1
Malignant lymphoma, histiocytic type							X	X				X					X		1
Monocytic leukemia	X		X	X															42

* Animals necropsied

TABLE A2. INDIVIDUAL ANIMAL TUMOR PATHOLOGY OF MALE RATS IN THE LIFETIME FEED STUDY OF CROCIDOLITE ASBESTOS: 1% CROCIDOLITE ASBESTOS

ANIMAL NUMBER	8	6	7	6	7	8	8	6	7	8	8	8	8	7	7	7	6	7	8	6	6	8	7	8	7		
WEEKS ON STUDY	6	9	4	6	7	8	8	3	1	7	1	7	0	8	6	7	0	8	8	8	8	7	0	9	2		
WEEKS ON STUDY	9	2	6	6	7	1	8	8	5	6	2	7	6	8	9	7	9	9	9	9	9	9	9	0	0		
WEEKS ON STUDY	0	0	0	0	0	0	0	0	0	0	0	0	0	0	0	0	0	0	0	0	0	0	1	1	1		
WEEKS ON STUDY	7	2	1	3	1	2	3	5	5	6	8	8	0	1	3	4	5	5	5	6	8	8	0	0	1		
INTEGUMENTARY SYSTEM																											
Skin																											
Squamous cell papilloma	+	+	+	+	N	+	+	+	+	+	+	+	+	+	+	+	+	+	+	+	+	+	+	+	+		
Squamous cell carcinoma																											
Basal cell tumor																											
Basal cell carcinoma																											
Trichoeplithoma																											
Keratoacanthoma																											
Fibrosarcoma																											
Hemangiopericytoma, malignant																											
Neurofibroma																											
Neurofibrosarcoma																											
Subcutaneous tissue																											
Keratoacanthoma	+	+	+	+	N	+	+	+	+	+	+	+	+	+	+	+	+	+	+	+	+	+	+	+	+		
Sarcoma, NOS, invasive																											
Fibroma												X				X											
Fibrosarcoma																			X								
Lipoma																											
Hemangiosarcoma																					X	X					
Osteosarcoma						X																					
Neurofibroma																											
Neurofibrosarcoma																											
RESPIRATORY SYSTEM																											
Lungs and bronchi																											
Neoplasm, NOS, metastatic	+	+	+	+	+	+	+	+	+	+	+	+	+	+	+	+	+	+	+	+	+	+	+	+	+		
Squamous cell carcinoma, metastatic																											
Alveolar/bronchiolar adenoma																											
Alveolar/bronchiolar carcinoma																							X				
C cell carcinoma, metastatic																											
Pheochromocytoma, metastatic																											
Liposarcoma, metastatic			X																								
Mesothelioma, metastatic																											
Hemangiosarcoma, metastatic			X																								
Osteosarcoma, metastatic					X		X																				
Trachea																											
C-cell carcinoma, invasive	+	+	+	+	+	+	+	-	+	+	+	+	+	+	+	+	+	+	+	+	+	+	+	+	-		
HEMATOPOIETIC SYSTEM																											
Bone marrow																											
Spleen	+	+	+	+	+	+	+	+	+	+	+	+	+	+	+	+	+	+	+	+	+	+	+	+	+		
Pheochromocytoma, metastatic																											
Fibrosarcoma																											
Fibrosarcoma, metastatic																											
Hemangiosarcoma, metastatic																						X					
Leukemia, mononuclear cell																											
Lymph nodes																											
Squamous cell carcinoma, metastatic	+	+	+	+	+	+	+	+	+	+	+	+	+	+	+	+	+	+	+	+	+	+	+	+	+		
C-cell carcinoma, metastatic																											
Pheochromocytoma, metastatic																											
Sarcoma, NOS, invasive																											
Rhabdomyosarcoma, metastatic																X											
Thymus	+	+	+	+	+	+	+	-	+	+	+	+	+	+	+	+	+	+	+	+	+	+	-	-	+		
Papillary adenocarcinoma																									+		
CIRCULATORY SYSTEM																											
Heart																											
Alveolar/bronchiolar carcinoma, invasive	+	+	+	+	+	+	+	+	+	+	+	+	+	+	+	+	+	+	+	+	+	+	+	+	+		
DIGESTIVE SYSTEM																											
Oral cavity																											
Squamous cell papilloma	N	N	N	N	N	N	N	N	N	N	N	N	N	N	N	N	N	N	N	N	N	N	N	N	N		
Squamous cell carcinoma																											
Salivary gland																											
Adenoma, NOS	+	+	+	+	+	+	+	+	+	+	+	+	+	+	+	+	+	+	+	+	+	+	+	+	+		
Sarcoma, NOS																											
Liver																											
Neoplastic nodule	+	+	+	+	+	+	+	+	+	+	+	+	+	+	+	+	+	+	+	+	+	+	+	+	+		
Hepatocellular carcinoma																											
Malignant lymphoma, histiocytic type																											
Kupffer cell sarcoma																											
Monocytic leukemia																											
Bile duct																											
Pancreas	+	+	+	+	+	+	+	+	-	+	+	+	+	+	+	+	+	+	+	+	+	+	+	+	+		
Acinar cell adenoma																											
Acinar cell carcinoma																											
Esophagus	-	-	+	+	+	+	+	+	+	-	+	+	+	+	+	+	+	+	+	+	+	+	+	+	+		
Stomach																											
Carcinoma, NOS																											
Squamous cell papilloma																											
Squamous cell carcinoma																											
Basal cell carcinoma																											
Fibrosarcoma																											
Fibrosarcoma																											
Leiomyosarcoma																											
Small intestine																											
Mucinous cystadenocarcinoma	+	+	+	+	+	+	+	+	+	+	+	+	+	+	+	+	+	+	+	+	+	+	+	+	+		
Fibrosarcoma																											
Leiomyosarcoma																											
Large intestine																											
Adenomatous polyp, NOS	+	+	+	+	+	+	+	+	+	+	+	+	+	+	+	+	+	+	+	+	+	+	+	+	+		
Lipoma																											
Leiomyosarcoma																											

TABLE A2. INDIVIDUAL ANIMAL TUMOR PATHOLOGY OF MALE RATS: 1% CROCIDOLITE ASBESTOS (Continued)

ANIMAL NUMBER	7	7	7	8	8	8	8	8	7	7	7	7	8	7	7	7	7	9	9	7	8	8	8	9	8		
	30	59	81	34	88	72	79	99	59	19	80	74	40	00	79	99	11	02	18	47	27	51	61	11	09		
WEEKS ON STUDY	10	10	10	10	10	10	10	10	10	10	10	10	10	10	10	10	10	10	10	10	10	10	10	10	10		
INTEGUMENTARY SYSTEM																											
Skin	+	+	+	+	+	+	+	+	+	+	+	+	+	+	+	+	+	+	+	+	+	+	+	+	+		
Squamous cell papilloma																											
Squamous cell carcinoma																											
Basal cell tumor																											
Basal cell carcinoma																											
Trichoepithelioma																											
Keratoacanthoma																											
Fibrosarcoma																											
Hemangiopericytoma, malignant																											
Neurofibroma																											
Neurofibrosarcoma																							X				
Subcutaneous tissue	+	+	+	+	+	+	+	+	+	+	+	+	+	+	+	+	+	+	+	+	+	+	+	+	+		
Keratoacanthoma																											
Sarcoma, NOS, invasive																											
Fibroma																											
Fibrosarcoma					X									X								X					
Lipoma																											
Hemangiosarcoma																											
Osteosarcoma																											
Neurofibroma					X																						
Neurofibrosarcoma																											
RESPIRATORY SYSTEM																											
Lungs and bronchi	+	+	+	+	+	+	+	+	+	+	+	+	+	+	+	+	+	+	+	+	+	+	+	+	+		
Neoplasm, NOS, metastatic																											
Squamous cell carcinoma, metastatic																											
Alveolar/bronchiolar adenoma																											
Alveolar/bronchiolar carcinoma																											
C cell carcinoma, metastatic																							X				
Pheochromocytoma, metastatic																											
Liposarcoma, metastatic																											
Mesothelioma, metastatic																											
Hemangiosarcoma, metastatic																											
Osteosarcoma, metastatic																											
Trachea	+	+	+	+	+	+	+	+	+	+	+	+	+	+	+	+	+	+	+	+	+	+	+	+	+		
C cell carcinoma, invasive																											
HEMATOPOIETIC SYSTEM																											
Bone marrow	+	+	+	+	+	+	+	+	+	+	+	+	+	+	+	+	+	+	+	+	+	+	+	+	+		
Spleen	+	+	+	+	+	+	+	+	+	+	+	+	+	+	+	+	+	+	+	+	+	+	+	+	+		
Pheochromocytoma, metastatic																											
Fibrosarcoma																											
Fibrosarcoma, metastatic																											
Hemangiosarcoma, metastatic																											
Leukemia, mononuclear cell																											
Lymph nodes	+	+	+	+	+	+	+	+	+	+	+	+	+	+	+	+	+	+	+	+	+	+	+	+	+		
Squamous cell carcinoma, metastatic																											
C cell carcinoma, metastatic																											
Pheochromocytoma, metastatic																											
Sarcoma, NOS, invasive																											
Rhabdomyosarcoma, metastatic																											
Thymus	+	+	-	+	+	+	-	-	+	-	+	+	-	-	+	+	-	-	+	-	+	+	+	+	+		
Papillary adenocarcinoma																											
CIRCULATORY SYSTEM																											
Heart	+	+	+	+	+	+	+	+	+	+	+	+	+	+	+	+	+	+	+	+	+	+	+	+	+		
Alveolar/bronchiolar carcinoma, invasive																						X					
DIGESTIVE SYSTEM																											
Oral cavity	N	N	N	N	N	N	N	N	N	N	N	N	N	N	N	N	N	N	N	N	N	N	N	N	N		
Squamous cell papilloma																											
Squamous cell carcinoma																								X			
Salivary gland	+	+	+	+	+	+	+	+	+	+	+	+	+	+	+	+	+	+	+	+	+	+	+	+	+		
Adenoma, NOS																											
Sarcoma, NOS										X																	
Liver	+	+	+	+	+	+	+	+	+	+	+	+	+	+	+	+	+	+	+	+	+	+	+	+	+		
Neoplastic nodule																											
Hepatocellular carcinoma																											
Malignant lymphoma, histiocytic type																											
Kupffer cell sarcoma																											
Monocytic leukemia																											
Bile duct	+	+	+	+	+	+	+	+	+	+	+	+	+	+	+	+	+	+	+	+	+	+	+	+	+		
Pancreas	+	+	+	+	+	+	+	+	+	+	+	+	+	+	+	+	+	+	+	+	+	+	+	+	+		
Acinar cell adenoma																											
Acinar cell carcinoma																											
Esophagus	+	+	+	+	+	+	+	+	+	+	+	+	+	+	+	+	+	+	+	+	+	+	+	+	+		
Stomach	+	+	+	+	+	+	+	+	+	+	+	+	+	+	+	+	+	+	+	+	+	+	+	+	+		
Carcinoma, NOS																											
Squamous cell papilloma																											
Squamous cell carcinoma																											
Basal cell carcinoma																											
Fibrosarcoma																											
Leiomyosarcoma																											
Small intestine	+	+	+	+	+	+	+	+	+	+	+	+	+	+	+	+	+	+	+	+	+	+	+	+	+		
Mucinous cystadenocarcinoma																											
Fibrosarcoma																											
Leiomyosarcoma																											
Large intestine	+	+	+	+	+	+	+	+	+	+	+	+	+	+	+	+	+	+	+	+	+	+	+	+	+		
Adenomatous polyp, NOS																											
Lipoma																											
Leiomyosarcoma																											

TABLE A2. INDIVIDUAL ANIMAL TUMOR PATHOLOGY OF MALE RATS: 1% CROCIDOLITE ASBESTOS (Continued)

ANIMAL NUMBER	8	6	6	7	7	7	7	7	7	8	7	7	7	8	8	8	6	7	7	8	8	7	8	6	7		
WEEKS ON STUDY	3	3	4	1	1	3	4	6	7	8	5	2	2	7	9	1	7	7	9	3	9	4	5	1	5		
	3	3	4	0	0	0	0	0	0	0	1	1	1	1	1	1	1	2	2	2	2	2	3	3	4		
INTEGUMENTARY SYSTEM																											
Skin																											
Squamous cell papilloma	+	+	+	+	+	+	+	+	+	+	+	+	+	+	+	+	+	+	+	+	+	+	+	+	+		
Squamous cell carcinoma																								X	+		
Basal cell tumor		X																									
Basal cell carcinoma																											
Trichoepithelioma																							X				
Keratoacanthoma																											
Fibrosarcoma																											
Hemangiopericytoma, malignant																											
Neurofibroma																											
Neurofibrosarcoma																											
Subcutaneous tissue																											
Keratoacanthoma	+	+	+	+	+	+	+	+	+	+	+	+	+	+	+	+	+	+	+	+	+	+	+	+	+		
Sarcoma, NOS, invasive																											
Fibroma																											
Fibrosarcoma																								@X			
Lipoma																											
Hemangiosarcoma																											
Osteosarcoma																											
Neurofibroma																											
Neurofibrosarcoma																											
RESPIRATORY SYSTEM																											
Lungs and bronchi																											
Neoplasm, NOS, metastatic	+	+	+	+	+	+	+	+	+	+	+	+	+	+	+	+	+	+	+	+	+	+	+	+	+		
Squamous cell carcinoma, metastatic																											
Alveolar/bronchiolar adenoma																											
Alveolar/bronchiolar carcinoma																											
C-cell carcinoma, metastatic																											
Pheochromocytoma, metastatic																											
Liposarcoma, metastatic																											
Mesothelioma, metastatic																											
Hemangiosarcoma, metastatic																											
Osteosarcoma, metastatic																											
Trachea																											
C cell carcinoma, invasive	+	+	+	+	+	+	+	+	+	+	+	+	+	+	+	+	+	+	+	+	+	+	+	+	+		
HEMATOPOIETIC SYSTEM																											
Bone marrow																											
Spleen																											
Pheochromocytoma, metastatic	+	+	+	+	+	+	+	+	+	+	+	+	+	+	+	+	+	+	+	+	+	+	+	+	+		
Fibrosarcoma																											
Fibrosarcoma, metastatic																											
Hemangiosarcoma, metastatic																											
Leukemia, mononuclear cell																											
Lymph nodes																											
Squamous cell carcinoma, metastatic	+	+	+	+	+	+	+	+	+	+	+	+	+	+	+	+	+	+	+	+	+	+	+	+	+		
C-cell carcinoma, metastatic		X																									
Pheochromocytoma, metastatic																											
Sarcoma, NOS, invasive																											
Rhabdomyosarcoma, metastatic																											
Thymus																											
Papillary adenocarcinoma	+	+	-	+	+	+	-	+	+	-	+	+	+	+	+	+	+	+	+	+	+	+	-	+	-		
CIRCULATORY SYSTEM																											
Heart																											
Alveolar/bronchiolar carcinoma, invasive	+	+	+	+	+	+	+	+	+	+	+	+	+	+	+	+	+	+	+	+	+	+	+	+	+		
DIGESTIVE SYSTEM																											
Oral cavity																											
Squamous cell papilloma	N	N	N	N	N	N	N	N	N	N	N	N	N	N	N	N	N	N	N	N	N	N	N	N	N		
Squamous cell carcinoma																											
Salivary gland																											
Adenoma, NOS	+	+	+	+	+	+	+	+	+	+	+	+	+	+	+	+	+	+	+	+	+	+	+	+	+		
Sarcoma, NOS																											
Liver																											
Neoplastic nodule	+	+	+	+	+	+	+	+	+	+	+	+	+	+	+	+	+	+	+	+	+	+	+	+	+		
Hepatocellular carcinoma																											
Malignant lymphoma, histiocytic type																											
Kupffer cell sarcoma																											
Monocytic leukemia																											
Bile duct																											
Pancreas																											
Acinar cell adenoma	+	+	+	+	+	+	+	+	+	+	+	+	+	+	+	+	+	+	+	+	+	+	+	+	+		
Acinar cell carcinoma																											
Esophagus																											
Stomach																											
Carcinoma, NOS	+	+	+	+	+	+	+	+	+	+	+	+	+	+	+	+	+	+	+	+	+	+	+	+	+		
Squamous cell papilloma																											
Squamous cell carcinoma																											
Basal cell carcinoma																											
Fibrosarcoma																											
Leiomyosarcoma																											
Small intestine																											
Mucinous cystadenocarcinoma	+	+	+	+	+	+	+	+	+	+	+	+	+	+	+	+	+	+	+	+	+	+	+	+	+		
Fibrosarcoma																											
Leiomyosarcoma																											
Large intestine																											
Adenomatous polyp, NOS	+	+	+	+	+	+	+	+	+	+	+	+	+	+	+	+	+	+	+	+	+	+	+	+	+		
Lipoma																											
Leiomyosarcoma																											
	X																										

@ Multiple occurrence of morphology

**TABLE A2. INDIVIDUAL ANIMAL TUMOR PATHOLOGY OF MALE RATS: 1% CROCIDOLITE ASBESTOS
(Continued)**

ANIMAL NUMBER	8 (6)	8 (9)	9 (0)	8 (1)	8 (2)	8 (3)	8 (4)	8 (5)	8 (6)	7 (7)	7 (8)	7 (9)	8 (1)	8 (2)	8 (3)	8 (4)	8 (5)	9 (0)	9 (1)	9 (2)	8 (3)	8 (4)	8 (5)
WEEKS ON STUDY	1 (5)	1 (5)	1 (5)	1 (6)	1 (6)	1 (6)	1 (6)	1 (6)	1 (6)	1 (7)	1 (7)	1 (7)	1 (7)	1 (7)	1 (7)	1 (7)	1 (7)	1 (7)	1 (7)	1 (7)	1 (8)	1 (8)	1 (8)
INTEGUMENTARY SYSTEM																							
Skin	+																						
Squamous cell papilloma	+																						
Squamous cell carcinoma	+																						
Basal cell tumor	+																						
Basal cell carcinoma	+																						
Trichoepithelioma	+																						
Keratoacanthoma	+																						
Fibrosarcoma	+																						
Hemangiopericytoma, malignant	+																						
Neurofibroma	+																						
Neurofibrosarcoma	+																						
Subcutaneous tissue	+																						
Keratoacanthoma	+																						
Sarcoma, NOS, invasive	+																						
Fibroma	+																						
Fibrosarcoma	+																						
Lipoma	+																						
Hemangiosarcoma	+																						
Osteosarcoma	+																						
Neurofibroma	+																						
Neurofibrosarcoma	+																						
RESPIRATORY SYSTEM																							
Lungs and bronchi	+																						
Neoplasm, NOS, metastatic	+																						
Squamous cell carcinoma, metastatic	+																						
Alveolar/bronchiolar adenoma	+																						
Alveolar/bronchiolar carcinoma	+																						
C-cell carcinoma, metastatic	+																						
Pheochromocytoma, metastatic	+																						
Liposarcoma, metastatic	+																						
Mesothelioma, metastatic	+																						
Hemangiosarcoma, metastatic	+																						
Osteosarcoma, metastatic	+																						
Trachea	+																						
C-cell carcinoma, invasive	+																						
HEMATOPOIETIC SYSTEM																							
Bone marrow	+																						
Spleen	+																						
Pheochromocytoma, metastatic	+																						
Fibrosarcoma	+																						
Fibrosarcoma, metastatic	+																						
Hemangiosarcoma, metastatic	+																						
Leukemia, mononuclear cell	+																						
Lymph nodes	+																						
Squamous cell carcinoma, metastatic	+																						
C-cell carcinoma, metastatic	+																						
Pheochromocytoma, metastatic	+																						
Sarcoma, NOS, invasive	+																						
Rhabdomyosarcoma, metastatic	+																						
Thymus	+																						
Papillary adenocarcinoma	+																						
CIRCULATORY SYSTEM																							
Heart	+																						
Alveolar/bronchiolar carcinoma, invasive	+																						
DIGESTIVE SYSTEM																							
Oral cavity	N																						
Squamous cell papilloma	N																						
Squamous cell carcinoma	N																						
Salivary gland	+																						
Adenoma, NOS	+																						
Sarcoma, NOS	+																						
Liver	+																						
Neoplastic nodule	+																						
Hepatocellular carcinoma	+																						
Malignant lymphoma, histiocytic type	+																						
Kupffer cell sarcoma	+																						
Monocytic leukemia	+																						
Bile duct	+																						
Pancreas	+																						
Acinar cell adenoma	+																						
Acinar cell carcinoma	+																						
Esophagus	+																						
Stomach	+																						
Carcinoma, NOS	+																						
Squamous cell papilloma	+																						
Squamous cell carcinoma	+																						
Basal cell carcinoma	+																						
Fibrosarcoma	+																						
Leiomyosarcoma	+																						
Small intestine	+																						
Mucinous cystadenocarcinoma	+																						
Fibrosarcoma	+																						
Leiomyosarcoma	+																						
Large intestine	+																						
Adenomatous polyp, NOS	+																						
Lipoma	+																						
Leiomyosarcoma	+																						

TABLE A2. INDIVIDUAL ANIMAL TUMOR PATHOLOGY OF MALE RATS: 1% CROCIDOLITE ASBESTOS
(Continued)

ANIMAL NUMBER	7 5 3	7 6 1	7 6 2	8 6 3	8 7 4	7 4 9	7 5 0	8 6 5	6 7 0	7 0 0	7 1 1	7 2 1	7 3 5	7 5 5	8 7 2	8 8 6	8 9 9	6 7 1	7 2 2	7 8 9	8 1 6	8 5 7	9 1 3	7 1 2	7 3 3		
WEEKS ON STUDY	1 8	1 8	1 8	1 8	1 9	1 9	1 9	1 9	1 9	1 0	1 0	1 0	1 0	1 0	1 0	1 0	1 0	1 0	1 1	1 1	1 1	1 2	1 2	1 2	1 3	1 3	
INTEGUMENTARY SYSTEM																											
Skin																											
Squamous cell papilloma														X													
Squamous cell carcinoma																											
Basal cell tumor																											
Basal cell carcinoma	X																										
Trichoepithelioma																											
Keratocanthoma							X	X		X					X												
Fibrosarcoma																											
Hemangioepithelioma, malignant																											
Neurofibroma																											
Neurofibrosarcoma																											
Subcutaneous tissue																											
Keratocanthoma																											
Sarcoma, NOS, invasive																											
Fibroma				X		X								X	X									X			X
Fibrosarcoma														X													
Lipoma						X	X																				
Hemangiosarcoma																											
Osteosarcoma																											
Neurofibroma														X													
Neurofibrosarcoma																											
RESPIRATORY SYSTEM																											
Lungs and bronchi																											
Neoplasm, NOS, metastatic																											
Squamous cell carcinoma, metastatic																											
Alveolar/bronchiolar adenoma																											
Alveolar/bronchiolar carcinoma																											
C-cell carcinoma, metastatic																											
Pheochromocytoma, metastatic																											
Liposarcoma, metastatic																											
Mesothelioma, metastatic																											
Hemangiosarcoma, metastatic																											
Osteosarcoma, metastatic																											
Trachea																											
C-cell carcinoma, invasive																											
HEMATOPOIETIC SYSTEM																											
Bone marrow																											
Pheochromocytoma, metastatic																											
Fibrosarcoma																											
Fibrosarcoma, metastatic																											
Hemangiosarcoma, metastatic																											
Leukemia, mononuclear cell																											
Lymph nodes																											
Squamous cell carcinoma, metastatic																											
C-cell carcinoma, metastatic																											
Pheochromocytoma, metastatic																											
Sarcoma, NOS, invasive																											
Rhabdomyosarcoma, metastatic																											
Thymus																											
Papillary adenocarcinoma																											
CIRCULATORY SYSTEM																											
Heart																											
Alveolar/bronchiolar carcinoma, invasive																											
DIGESTIVE SYSTEM																											
Oral cavity																											
Squamous cell papilloma	N	N	N	N	N	N	N	N	N	N	N	N	N	N	N	N	N	N	N	N	N	N	N	N	N	N	N
Squamous cell carcinoma																											
Salivary gland																											
Adenoma, NOS																											
Sarcoma, NOS																											
Liver																											
Neoplastic nodule																											
Hepatocellular carcinoma																											
Malignant lymphoma, histiocytic type																											
Kupffer cell sarcoma																											
Monocyte leukemia																											
Bile duct																											
Pancreas																											
Acinar cell adenoma																											
Acinar cell carcinoma																											
Esophagus																											
Stomach																											
Carcinoma, NOS																											
Squamous cell papilloma																											
Squamous cell carcinoma																											
Basal cell carcinoma																											
Fibrosarcoma																											
Leiomyosarcoma																											
Small intestine																											
Mucinous cystadenocarcinoma																											
Fibrosarcoma																											
Leiomyosarcoma																											
Large intestine																											
Adenomatous polyp, NOS																											
Lipoma																											
Leiomyosarcoma																											

TABLE A2. INDIVIDUAL ANIMAL TUMOR PATHOLOGY OF MALE RATS: 1% CROCIDOLITE ASBESTOS (Continued)

ANIMAL NUMBER	7 3	8 6	8 4	8 9	8 4	7 2	7 4	8 6	7 4	7 6	6 8	6 7	7 3	8 5	7 5	7 6	7 9	8 3	8 6	8 6	8 5	8 3	7 1	8 2	8 3	8 4	
WEEKS ON STUDY	1 4	1 4	1 4	1 4	1 4	1 6	1 6	1 6	1 7	1 7	1 8	1 8	1 8	1 8	1 9	1 9	1 9	1 9	1 9	1 9	1 9	1 9	1 0	1 0	1 0	1 0	
INTEGUMENTARY SYSTEM																											
Skin	+ +																										
Squamous cell papilloma																											
Squamous cell carcinoma																											
Basal cell tumor																											
Basal cell carcinoma																											
Trichoepithelioma																											
Keratocanthoma																											
Fibrosarcoma																											
Hemangopericytoma, malignant																											
Neurofibroma																											
Neurofibrosarcoma																											
Subcutaneous tissue	+ +																										
Keratocanthoma																											
Sarcoma, NOS, invasive																											
Fibroma																											
Fibrosarcoma																											
Lipoma																											
Hemangiosarcoma																											
Osteosarcoma																											
Neurofibroma																											
Neurofibrosarcoma	X																										
RESPIRATORY SYSTEM																											
Lungs and bronchi	+ +																										
Neoplasm, NOS, metastatic																											
Squamous cell carcinoma, metastatic																											
Alveolar/bronchiolar adenoma																											
Alveolar/bronchiolar carcinoma																											
C-cell carcinoma, metastatic																											
Pheochromocytoma, metastatic																											
Liposarcoma, metastatic																											
Mesothelioma, metastatic																											
Hemangiosarcoma, metastatic																											
Osteosarcoma, metastatic																											
Trachea	+ +																										
C cell carcinoma, invasive																											
HEMATOPOIETIC SYSTEM																											
Bone marrow	+ +																										
Spleen	+ +																										
Pheochromocytoma, metastatic																											
Fibrosarcoma																											
Fibrosarcoma, metastatic																											
Hemangiosarcoma, metastatic																											
Leukemia, mononuclear cell																											
Lymph nodes	+ +																										
Squamous cell carcinoma, metastatic																											
C-cell carcinoma, metastatic																											
Pheochromocytoma, metastatic																											
Sarcoma, NOS, invasive																											
Rhabdomyosarcoma, metastatic																											
Thymus	- - + + - + - +																										
Papillary adenocarcinoma																											
CIRCULATORY SYSTEM																											
Heart	+ +																										
Alveolar/bronchiolar carcinoma, invasive																											
DIGESTIVE SYSTEM																											
Oral cavity	N N																										
Squamous cell papilloma																											
Squamous cell carcinoma																											
Salivary gland	+ +																										
Adenoma, NOS																											
Sarcoma, NOS	X																										
Liver	+ +																										
Neoplastic nodule																											
Hepatocellular carcinoma																											
Malignant lymphoma, histiocytic type																											
Kupffer cell sarcoma																											
Monocytic leukemia																											
Bile duct	+ +																										
Pancreas	+ +																										
Acinar cell adenoma																											
Acinar cell carcinoma																											
Esophagus	+ +																										
Stomach	+ +																										
Carcinoma, NOS																											
Squamous cell papilloma																											
Squamous cell carcinoma																											
Basal cell carcinoma																											
Fibrosarcoma																											
Leiomyosarcoma																											
Small intestine	+ +																										
Mucinous cystadenocarcinoma																											
Fibrosarcoma																											
Leiomyosarcoma																											
Large intestine	+ +																										
Adenomatous polyp, NOS																											
Lipoma																											
Leiomyosarcoma	X																										

TABLE A2. INDIVIDUAL ANIMAL TUMOR PATHOLOGY OF MALE RATS: 1% CROCIDOLITE ASBESTOS
(Continued)

ANIMAL NUMBER	9	7	7	7	8	8	7	8	9	6	6	6	7	8	8	6	7	7	7	7	8	9	7	7	7		
WEEKS ON STUDY	1	1	1	1	1	1	1	1	1	1	1	1	1	1	1	1	1	1	1	1	1	1	1	1	1		
	7	8	2	7	1	2	8	2	9	9	7	8	9	0	8	2	4	4	3	4	6	0	3	4	6		
INTEGUMENTARY SYSTEM																											
Skin																											
Squamous cell papilloma	+	+	+	+	+	+	+	+	+	+	+	+	+	+	+	+	+	+	+	+	+	+	+	+	+	+	
Squamous cell carcinoma																											
Basal cell tumor						X																					
Basal cell carcinoma																											
Trichoeplithoma															X									X			
Keratoacanthoma	X					X																					
Fibrosarcoma																											
Hemangioepithelioma, malignant																											
Neurofibroma																											
Neurofibrosarcoma																											
Subcutaneous tissue																											
Keratoacanthoma	+	+	+	+	+	+	+	+	+	+	+	+	+	+	+	+	+	+	+	+	+	+	+	+	+	+	
Sarcoma, NOS, invasive																											
Fibroma											X																
Fibrosarcoma																											
Lipoma																											
Hemangiosarcoma																											
Osteosarcoma																											
Neurofibroma								X																			
Neurofibrosarcoma																											
RESPIRATORY SYSTEM																											
Lungs and bronchi																											
Neoplasm, NOS, metastatic	+	+	+	+	+	+	+	+	+	+	+	+	+	+	+	+	+	+	+	+	+	+	+	+	+	+	
Squamous cell carcinoma, metastatic																											
Alveolar bronchiolar adenoma																											
Alveolar bronchiolar carcinoma												X															
C-cell carcinoma, metastatic																											
Phaeochromocytoma, metastatic																											
Liposarcoma, metastatic																											
Mesothelioma, metastatic																											
Hemangiosarcoma, metastatic																											
Osteosarcoma, metastatic																											
Trachea																											
C-cell carcinoma, invasive	+	+	+	+	+	+	+	+	+	+	+	+	+	+	+	+	+	+	+	+	+	+	+	+	+	+	
HEMATOPOIETIC SYSTEM																											
Bone marrow																											
Phaeochromocytoma, metastatic	+	+	+	+	+	+	+	+	+	+	+	+	+	+	+	+	+	+	+	+	+	+	+	+	+	+	
Fibrosarcoma																											
Fibrosarcoma, metastatic						X																					
Hemangiosarcoma, metastatic																											
Leukemia, mononuclear cell																											
Lymph nodes																											
Squamous cell carcinoma, metastatic	+	+	+	+	+	+	+	+	+	+	+	+	+	+	+	+	+	+	+	+	+	+	+	+	+	+	
C-cell carcinoma, metastatic																											
Phaeochromocytoma, metastatic																											
Sarcoma, NOS, invasive																											
Rhabdomyosarcoma, metastatic											X																
Thymus																											
Papillary adenocarcinoma	+	-	-	+	+	-	-	-	+	+	-	+	+	+	+	-	-	-	+	-	+	-	-	+	+		
CIRCULATORY SYSTEM																											
Heart																											
Alveolar bronchiolar carcinoma, invasive	+	+	+	+	+	+	+	+	+	+	+	+	+	+	+	+	+	+	+	+	+	+	+	+	+	+	
DIGESTIVE SYSTEM																											
Oral cavity																											
Squamous cell papilloma	N	N	N	N	N	N	N	N	N	N	N	N	N	N	N	N	N	N	N	N	N	N	N	N	N	N	
Squamous cell carcinoma																											
Salivary gland	+	+	+	+	+	+	+	+	+	+	+	+	+	+	+	+	+	+	+	+	+	+	+	+	+	+	
Adenoma, NOS						X																					
Sarcoma, NOS																											
Liver																											
Neoplastic nodule	+	+	+	+	+	+	+	+	+	+	+	+	+	+	+	+	+	+	+	+	+	+	+	+	+	+	
Hepatocellular carcinoma																											
Malignant lymphoma, histiocytic type													X										X		X		
Kupffer cell sarcoma																											
Monocytic leukemia																											
Bile duct																											
Pancreas	+	+	+	+	+	+	+	+	+	+	+	+	+	+	+	+	+	+	+	+	+	+	+	+	+	+	
Acinar cell adenoma																											
Acinar cell carcinoma						X																					
Esophagus																											
Carcinoma, NOS	+	+	+	+	+	+	+	+	+	+	+	+	+	+	+	+	+	+	+	+	+	+	+	+	+	+	
Stomach																											
Squamous cell papilloma																											
Squamous cell carcinoma																											
Basal cell carcinoma																											
Fibrosarcoma																											
Leiomyosarcoma																											
Small intestine																											
Mucinous cystadenocarcinoma	+	+	+	+	+	+	+	+	+	+	+	+	+	+	+	+	+	+	+	+	+	+	+	+	+	+	
Fibrosarcoma																											
Leiomyosarcoma																											
Large intestine																											
Adenomatous polyp, NOS																											
Lipoma																											
Leiomyosarcoma																											

TABLE A2. INDIVIDUAL ANIMAL TUMOR PATHOLOGY OF MALE RATS: 1% CROCIDOLITE ASBESTOS (Continued)

ANIMAL NUMBER	7	8	8	8	8	8	8	9	6	8	9	7	7	7	8	8	8	9	7	7	8	8	9	6	6		
	6	0	0	3	4	5	8	0	8	4	1	4	8	9	7	9	9	1	1	6	5	6	0	8	8		
WEEKS ON STUDY	9	1	5	6	6	2	3	7	1	1	5	5	5	5	5	5	5	5	0	8	7	7	5	7	8		
INTEGUMENTARY SYSTEM																											
Skin																											
Squamous cell papilloma	+	+	+	+	+	+	+	+	+	+	+	+	+	+	+	+	+	+	+	+	+	+	+	+	+	+	
Squamous cell carcinoma			X			X									X										X		
Basal cell tumor																											
Basal cell carcinoma															X	X											
Trichoepithelioma																											
Keratoacanthoma				X																		X	X				
Fibrosarcoma																											
Hemangiopericytoma, malignant																											
Neurofibroma																											
Neurofibrosarcoma																											
Subcutaneous tissue																											
Keratoacanthoma	+	+	+	+	+	+	+	+	+	+	+	+	+	+	+	+	+	+	+	+	+	+	+	+	+	+	
Sarcoma, NOS, invasive																											
Fibroma															X												
Fibrosarcoma																											
Lipoma																											
Hemangiosarcoma																							X				
Osteosarcoma																											
Neurofibroma																											
Neurofibrosarcoma																											
RESPIRATORY SYSTEM																											
Lungs and bronchi																											
Neoplasm, NOS, metastatic	+	+	+	+	+	+	+	+	+	+	+	+	+	+	+	+	+	+	+	+	+	+	+	+	+	+	
Squamous cell carcinoma, metastatic																											
Alveolar/bronchiolar adenoma																											
Alveolar/bronchiolar carcinoma																											
C-cell carcinoma, metastatic																											
Pheochromocytoma, metastatic																											
Liposarcoma, metastatic																											
Mesothelioma, metastatic																											
Hemangiosarcoma, metastatic																											
Osteosarcoma, metastatic																											
Trachea																											
C-cell carcinoma, invasive	+	+	+	+	+	+	+	+	+	+	+	+	+	+	+	+	+	+	+	+	+	+	+	+	+	+	
HEMATOPOIETIC SYSTEM																											
Bone marrow																											
	+	+	+	+	+	+	+	+	+	+	+	+	+	+	+	+	+	+	+	+	+	+	+	+	+	+	
Spleen																											
Pheochromocytoma, metastatic	+	+	+	+	+	+	+	+	+	+	+	+	+	+	+	+	+	+	+	+	+	+	+	+	+	+	
Fibrosarcoma																											
Fibrosarcoma, metastatic																											
Hemangiosarcoma, metastatic																											
Leukemia, mononuclear cell																											
Lymph nodes																											
Squamous cell carcinoma, metastatic	+	+	+	+	+	+	+	+	+	+	+	+	+	+	+	+	+	+	+	+	+	+	+	+	+	+	
C-cell carcinoma, metastatic																											
Pheochromocytoma, metastatic																											
Sarcoma, NOS, invasive																											
Rhabdomyosarcoma, metastatic																											
Thymus																											
Papillary adenocarcinoma	+	-	+	+	+	+	+	+	-	+	+	+	+	+	+	+	+	+	+	+	+	+	+	+	+	+	
CIRCULATORY SYSTEM																											
Heart																											
Alveolar/bronchiolar carcinoma, invasive	+	+	+	+	+	+	+	+	+	+	+	+	+	+	+	+	+	+	+	+	+	+	+	+	+	+	
DIGESTIVE SYSTEM																											
Oral cavity																											
Squamous cell papilloma	N	N	N	N	N	N	N	N	N	N	N	N	N	N	N	N	N	N	N	N	N	N	N	N	N	N	
Squamous cell carcinoma																											
Salivary gland																											
Adenoma, NOS	+	+	+	+	+	+	+	+	+	+	+	+	+	+	+	+	+	+	+	+	+	+	+	+	+	+	
Sarcoma, NOS																											
Liver																											
Neoplastic nodule	+	+	+	+	+	+	+	+	+	+	+	+	+	+	+	+	+	+	+	+	+	+	+	+	+	+	
Hepatocellular carcinoma															X							X					
Malignant lymphoma, histiocytic type																											
Kupffer cell sarcoma																											
Monocytic leukemia																											
Bile duct																											
	+	+	+	+	+	+	+	+	+	+	+	+	+	+	+	+	+	+	+	+	+	+	+	+	+	+	
Pancreas																											
Acinar cell adenoma	+	+	+	+	+	+	+	+	+	+	+	+	+	+	+	+	+	+	+	+	+	+	+	+	+	+	
Acinar cell carcinoma																											
Esophagus																											
	+	+	+	+	+	+	+	+	+	+	+	+	+	+	+	+	+	+	+	+	+	+	+	+	+	+	
Stomach																											
Carcinoma, NOS	+	+	+	+	+	+	+	+	+	+	+	+	+	+	+	+	+	+	+	+	+	+	+	+	+	+	
Squamous cell papilloma																											
Squamous cell carcinoma																											
Basal cell carcinoma																											
Fibrosarcoma																											
Leiomyosarcoma																											
Small intestine																											
Mucinous cystadenocarcinoma	+	+	+	+	+	+	+	+	+	+	+	+	+	+	+	+	+	+	+	+	+	+	+	+	+	+	
Fibrosarcoma																											
Leiomyosarcoma																											
Large intestine																											
Adenomatous polyp, NOS	+	+	+	+	+	+	+	+	+	+	+	+	+	+	+	+	+	+	+	+	+	+	+	+	+	+	
Lipoma																											
Leiomyosarcoma																											

TABLE A2. INDIVIDUAL ANIMAL TUMOR PATHOLOGY OF MALE RATS: 1% CROCIDOLITE ASBESTOS (Continued)

ANIMAL NUMBER	7	7	8	8	7	7	8	8	8	7	7	8	8	8	8	9	9	6	7	8	8	6	6	6	6		
	4	5	2	4	4	1	4	9	6	3	0	0	4	1	7	7	1	8	7	6	4	8	7	7	9	9	
WEEKS ON STUDY	1	1	1	1	1	1	1	1	1	1	1	1	1	1	1	1	1	1	1	1	1	1	1	1	1	1	
	3	3	3	3	3	3	3	3	3	4	4	4	4	4	4	4	4	4	4	4	4	4	4	4	4	4	
	7	7	7	7	8	8	8	8	9	0	0	0	0	0	0	0	0	0	1	1	1	1	2	2	2	2	
INTEGUMENTARY SYSTEM																											
Skin																											
Squamous cell papilloma	+																										
Squamous cell carcinoma	+																										
Basal cell tumor	+																										
Basal cell carcinoma	+																										
Trichoepithelioma	+																										
Keratoacanthoma	+																										
Fibrosarcoma	+																										
Hemangiosarcoma, malignant	+																										
Neurofibroma	+																										
Neurofibrosarcoma	+																										
Subcutaneous tissue	+																										
Keratoacanthoma	+																										
Sarcoma, NOS, invasive	+																										
Fibroma	+																										
Fibrosarcoma	+																										
Lipoma	+																										
Hemangiosarcoma	+																										
Osteosarcoma	+																										
Neurofibroma	+																										
Neurofibrosarcoma	+																										
RESPIRATORY SYSTEM																											
Lungs and bronchi																											
Neoplasm, NOS, metastatic	+																										
Squamous cell carcinoma, metastatic	+																										
Alveolar/bronchiolar adenoma	+																										
Alveolar/bronchiolar carcinoma	+																										
C-cell carcinoma, metastatic	+																										
Pheochromocytoma, metastatic	+																										
Liposarcoma, metastatic	+																										
Mesothelioma, metastatic	+																										
Hemangiosarcoma, metastatic	+																										
Osteosarcoma, metastatic	+																										
Trachea																											
C-cell carcinoma, invasive	+																										
HEMATOPOIETIC SYSTEM																											
Bone marrow																											
Spleen	+																										
Pheochromocytoma, metastatic	+																										
Fibrosarcoma	+																										
Fibrosarcoma, metastatic	+																										
Hemangiosarcoma, metastatic	+																										
Leukemia, mononuclear cell	+																										
Lymph nodes																											
Squamous cell carcinoma, metastatic	+																										
C-cell carcinoma, metastatic	+																										
Pheochromocytoma, metastatic	+																										
Sarcoma, NOS, invasive	+																										
Rhabdomyosarcoma, metastatic	+																										
Thymus																											
Papillary adenocarcinoma	+																										
CIRCULATORY SYSTEM																											
Heart																											
Alveolar/bronchiolar carcinoma, invasive	+																										
DIGESTIVE SYSTEM																											
Oral cavity																											
Squamous cell papilloma	N																										
Squamous cell carcinoma	N																										
Salivary gland																											
Adenoma, NOS	+																										
Sarcoma, NOS	+																										
Liver																											
Neoplastic nodule	+																										
Hepatocellular carcinoma	+																										
Malignant lymphoma, histiocytic type	+																										
Kupffer cell sarcoma	+																										
Monocytic leukemia	+																										
Bile duct																											
Pancreas	+																										
Acinar cell adenoma	+																										
Acinar cell carcinoma	+																										
Esophagus																											
Stomach																											
Carcinoma, NOS	+																										
Squamous cell papilloma	+																										
Squamous cell carcinoma	+																										
Basal cell carcinoma	+																										
Fibrosarcoma	+																										
Leiomyosarcoma	+																										
Small intestine																											
Mucinous cystadenocarcinoma	+																										
Fibrosarcoma	+																										
Leiomyosarcoma	+																										
Large intestine																											
Adenomatous polyp, NOS	+																										
Lipoma	+																										
Leiomyosarcoma	+																										

TABLE A2. INDIVIDUAL ANIMAL TUMOR PATHOLOGY OF MALE RATS: 1% CROCIDOLITE ASBESTOS
(Continued)

ANIMAL NUMBER	86767886788887776786668788786
WEEKS ON STUDY	00000000000000000000000000001111
	7467888887776786668788786
URINARY SYSTEM	
Kidney	+
Tubular cell adenoma	+
Tubular cell adenocarcinoma	+
Mixed tumor, malignant	+
Urinary bladder	+
ENDOCRINE SYSTEM	
Pituitary	-
Carcinoma, NOS	+
Adenoma, NOS	X
Adrenal	+
Cortical adenoma	+
Pheochromocytoma	+
Pheochromocytoma, malignant	X
Thyroid	+
Follicular cell adenoma	+
Follicular cell carcinoma	X
C-cell adenoma	X
C-cell carcinoma	X
Parathyroid	-
Pancreatic islets	+
Islet cell carcinoma	+
REPRODUCTIVE SYSTEM	
Mammary gland	+
Adenoma, NOS	N
Adenocarcinoma, NOS	+
Fibroadenoma	+
Testis	+
Adenocarcinoma, NOS	+
Interstitial cell tumor	X X X X X X X X X X X X X X X X X X
Prostate	+
Carcinoma, NOS	+
Preputial/clitoral gland	N
Squamous cell carcinoma	X
Epididymis	N
Lipoma	N
NERVOUS SYSTEM	
Brain	+
Carcinoma, NOS, invasive	-
Granular cell tumor, NOS	+
Astrocytoma	+
Meningioma	+
Meningioma, invasive	X
Spinal cord	N
Liposarcoma, invasive	+
SPECIAL SENSE ORGANS	
Harderian gland	N
Squamous cell carcinoma, invasive	N
Adenoma, NOS	N
Zymbal gland	N
Squamous cell carcinoma	X
Keratosarcoma	X
MUSCULOSKELETAL SYSTEM	
Bone	N
Squamous cell carcinoma, invasive	N
Hemangiosarcoma	X
Osteosarcoma	X
Muscle	N
C-cell carcinoma, invasive	N
Rhabdomyosarcoma	X
BODY CAVITIES	
Mediastinum	N
Alveolar/bronchiolar carcinoma, invasive	N
Peritoneum	N
Liposarcoma	N
Leiomyosarcoma, invasive	N
Tunica vaginalis	+
Mesothelioma, NOS	+
Mesothelioma, malignant	+
Mesentery	N
Fibrosarcoma	N
Mesothelioma, malignant	N
Hemangiosarcoma	X
ALL OTHER SYSTEMS	
Multiple organs, NOS	N
Squamous cell carcinoma, invasive	N
C-cell carcinoma, metastatic	N
Sarcoma, NOS, invasive	N
Fibrosarcoma, invasive	N
Liposarcoma, metastatic	N
Mesothelioma, invasive	N
Hemangiosarcoma, metastatic	X
Malignant lymphoma, undifferentiated type	N
Malignant lymphoma, histiocytic type	N
Monocytic leukemia	X X X

TABLE A2. INDIVIDUAL ANIMAL TUMOR PATHOLOGY OF MALE RATS: 1% CROCIDOLITE ASBESTOS (Continued)

ANIMAL NUMBER	83	63	64	71	72	73	74	75	76	82	77	78	79	84	85	86	87	88	89	94	95	96	97	98	99		
WEEKS ON STUDY	109	110	111	112	113	114	115	116	117	118	119	120	121	122	123	124	125	126	127	128	129	130	131	132	133		
URINARY SYSTEM																											
Kidney	+																										
Tubular cell adenoma	+																										
Tubular cell adenocarcinoma	+																										
Mixed tumor, malignant	+																										
Urinary bladder	+																										
ENDOCRINE SYSTEM																											
Pituitary	+																										
Carcinoma, NOS	+																										
Adenoma, NOS	+																										
Adrenal	+																										
Cortical adenoma	+																										
Pheochromocytoma	X																										
Pheochromocytoma, malignant	X																										
Thyroid	+																										
Follicular cell adenoma	X																										
Follicular cell carcinoma	X																										
C-cell adenoma	X																										
C-cell carcinoma	X																										
Parathyroid	+																										
Pancreatic islets	+																										
Islet cell carcinoma	X																										
REPRODUCTIVE SYSTEM																											
Mammary gland	+																										
Adenoma, NOS	+																										
Adenocarcinoma, NOS	N																										
Fibroadenoma	+																										
Testis	+																										
Adenocarcinoma, NOS	X																										
Interstitial cell tumor	X																										
Prostate	+																										
Carcinoma, NOS	+																										
Preputial/clitoral gland	N																										
Squamous cell carcinoma	N																										
Epididymis	N																										
Lipoma	N																										
NERVOUS SYSTEM																											
Brain	+																										
Carcinoma, NOS, invasive	+																										
Granular cell tumor, NOS	+																										
Astrocytoma	+																										
Meningioma	+																										
Meningioma, invasive	+																										
Spinal cord	N																										
Liposarcoma, invasive	N																										
SPECIAL SENSE ORGANS																											
Harderian gland	N																										
Squamous cell carcinoma, invasive	N																										
Adenoma, NOS	N																										
Zymbal gland	N																										
Squamous cell carcinoma	N																										
Keratoacanthoma	N																										
MUSCULOSKELETAL SYSTEM																											
Bone	N																										
Squamous cell carcinoma, invasive	N																										
Hemangiosarcoma	+																										
Osteosarcoma	N																										
Muscle	N																										
C-cell carcinoma, invasive	N																										
Rhabdomyosarcoma	N																										
BODY CAVITIES																											
Mediastinum	N																										
Alveolar/broncholar carcinoma, invasive	N																										
Peritoneum	N																										
Liposarcoma	N																										
Leiomyosarcoma, invasive	X																										
Tunica vaginalis	+																										
Mesothelioma, NOS	+																										
Mesothelioma, malignant	X																										
Mesentery	N																										
Fibrosarcoma	N																										
Mesothelioma, malignant	X																										
Hemangiosarcoma	N																										
ALL OTHER SYSTEMS																											
Multiple organs, NOS	N																										
Squamous cell carcinoma, invasive	N																										
C-cell carcinoma, metastatic	N																										
Sarcoma, NOS, invasive	N																										
Fibrosarcoma, invasive	N																										
Liposarcoma, metastatic	X																										
Mesothelioma, invasive	X																										
Hemangiosarcoma, metastatic	X																										
Malignant lymphoma, undifferentiated type	X																										
Malignant lymphoma, histiocytic type	X																										
Monocytic leukemia	X																										

TABLE A2. INDIVIDUAL ANIMAL TUMOR PATHOLOGY OF MALE RATS: 1% CROCIDOLITE ASBESTOS (Continued)

ANIMAL NUMBER	7 7 3	8 1 6	8 2 4	8 8 9	8 9 4	7 7 2	7 7 4	8 0 6	7 6 4	7 8 8	6 6 8	6 7 3	8 5 0	7 5 8	7 6 0	7 9 9	8 4 3	8 6 4	8 6 5	8 9 3	7 1 2	8 2 3	8 3 5	8 4 4	
WEEKS ON STUDY	1 1 4	1 1 4	1 1 4	1 1 4	1 1 4	1 1 6	1 1 6	1 1 6	1 1 7	1 1 7	1 1 8	1 1 8	1 1 8	1 1 9	1 1 9	1 1 9	1 1 9	1 1 9	1 1 9	1 1 9	1 2 0	1 2 0	1 2 0	1 2 0	
URINARY SYSTEM																									
Kidney	+																								
Tubular cell adenoma	+																								
Tubular cell adenocarcinoma	+																								
Mixed tumor, malignant	+																								
Urinary bladder	+																								
ENDOCRINE SYSTEM																									
Pituitary	+																								
Carcinoma, NOS	+																								
Adenoma, NOS	X			X	X			X			X	X													X
Adrenal	+																								
Cortical adenoma	+																								
Pheochromocytoma	+																								
Pheochromocytoma, malignant	+																								
Thyroid	+																								
Follicular cell adenoma	X																								
Follicular cell carcinoma	+																								
C-cell adenoma	+																								
C-cell carcinoma			X		X							X	X												
Parathyroid	+																								
Pancreatic islets	+																								
Islet cell carcinoma	+																								
REPRODUCTIVE SYSTEM																									
Mammary gland	+																								
Adenoma, NOS	+																								
Adenocarcinoma, NOS	+																								
Fibroadenoma	+																								
Testis	+																								
Adenocarcinoma, NOS	+																								
Interstitial cell tumor	X	X	X	X	X	X	X	X	X	X	X	X	X	X	X	X	X	X	X	X	X	X	X	X	X
Prostate	+																								
Carcinoma, NOS	+																								
Preputial/choral gland	N																								
Squamous cell carcinoma	N																								
Epididymus	N																								
Lipoma	N																								
NERVOUS SYSTEM																									
Brain	+																								
Carcinoma, NOS, invasive	+																								
Granular cell tumor, NOS	+																								
Astrocytoma	+																								
Meningioma	+																								
Meningioma, invasive	+																								
Spinal cord	N																								
Liposarcoma, invasive	N																								
SPECIAL SENSE ORGANS																									
Hardian gland	N																								
Squamous cell carcinoma, invasive	N																								
Adenoma, NOS	N																								
Zymbal gland	N																								
Squamous cell carcinoma	N																								
Keratoacanthoma	N																								
MUSCULOSKELETAL SYSTEM																									
Bone	N																								
Squamous cell carcinoma, invasive	N																								
Hemangiosarcoma	N																								
Osteosarcoma	N																								
Muscle	N																								
C-cell carcinoma, invasive	N																								
Rhabdomyosarcoma	N																								
BODY CAVITIES																									
Mediastinum	N																								
Alveolar/bronchiolar carcinoma, invasive	N																								
Peritoneum	N																								
Liposarcoma	N																								
Leiomyosarcoma, invasive	N																								
Tunica vaginalis	+																								
Mesothelioma, NOS	+																								
Mesothelioma, malignant	+																								
Mesentery	N	N	X	N	N	N	N	N	N	N	N	N	N	N	N	N	N	N	N	N	N	N	N	N	N
Fibrosarcoma	N																								
Mesothelioma, malignant	N																								
Hemangiosarcoma	N																								
ALL OTHER SYSTEMS																									
Multiple organs, NOS	N																								
Squamous cell carcinoma, invasive	N																								
C-cell carcinoma, metastatic	N																								
Sarcoma, NOS, invasive	N																								
Fibrosarcoma, invasive	N																								
Liposarcoma, metastatic	N																								
Mesothelioma, invasive	N																								
Hemangiosarcoma, metastatic	N																								
Malignant lymphoma, undifferentiated type	N																								
Malignant lymphoma, histiocytic type	N																								
Monocytic leukemia	X					X	X					X	X								X	X	X	X	

TABLE A2. INDIVIDUAL ANIMAL TUMOR PATHOLOGY OF MALE RATS: 1% CROCIDOLITE ASBESTOS (Continued)

ANIMAL NUMBER	9 7 7 7 8 8 7 8 9 6 6 6 7 8 8 6 7 7 7 7 8 9 7 7 7																			
	1 6 8 8 9 9 3 3 0 8 9 9 1 1 4 8 2 8 8 9 6 0 1 3 7 7 8 2 7 1 2 8 2 9 9 7 8 9 0 8 2 4 3 4 6 0 3 4 4 6																			
WEEKS ON STUDY	1 1																			
	2 0 1 1 1 1 1 2 2 2 3 3 3 3 3 3 4 4 4 4 4 4 4 5 5 5																			
URINARY SYSTEM																				
Kidney	+ +																			
Tubular cell adenoma																				
Tubular cell adenocarcinoma																				
Mixed tumor, malignant																				
Urinary bladder	+ +																			
ENDOCRINE SYSTEM																				
Pituitary	+ +																			
Carcinoma, NOS																				
Adenoma, NOS	X																			
Adrenal	+ +																			
Cortical adenoma	X																			
Pheochromocytoma	X X X X																			
Pheochromocytoma, malignant	X X																			
Thyroid	+ +																			
Follicular cell adenoma	X																			
Follicular cell carcinoma	X																			
C-cell adenoma	X X X																			
C-cell carcinoma	X X X																			
Parathyroid	+ +																			
Pancreatic islets	+ +																			
Islet cell carcinoma	- +																			
REPRODUCTIVE SYSTEM																				
Mammary gland	+ + N + + + + + + + + + + + + N + + + N + + +																			
Adenoma, NOS																				
Adenocarcinoma, NOS																				
Fibroadenoma	X																			
Testis	+ +																			
Adenocarcinoma, NOS																				
Interstitial cell tumor	X X																			
Prostate	+ +																			
Carcinoma, NOS																				
Preputial/clitoral gland	N N																			
Squamous cell carcinoma	X																			
Epididymis	N N																			
Lipoma	N																			
NERVOUS SYSTEM																				
Brain	+ +																			
Carcinoma, NOS, invasive																				
Granular cell tumor, NOS																				
Astrocytoma																				
Meningioma																				
Meningioma, invasive																				
Spinal cord	N N																			
Liposarcoma, invasive																				
SPECIAL SENSE ORGANS																				
Harderian gland	N N																			
Squamous cell carcinoma, invasive																				
Adenoma, NOS																				
Zymbal gland	N N																			
Squamous cell carcinoma	X																			
Keratoacanthoma	X																			
MUSCULOSKELETAL SYSTEM																				
Bone	N N																			
Squamous cell carcinoma, invasive																				
Hemangiosarcoma																				
Osteosarcoma																				
Muscle	N N																			
C-cell carcinoma, invasive																				
Rhabdomyosarcoma																				
BODY CAVITIES																				
Medastinum	N N																			
Alveolar/bronchiolar carcinoma, invasive																				
Peritoneum	N N																			
Liposarcoma																				
Leiomyosarcoma, invasive																				
Tunica vaginalis	+ +																			
Mesothelioma, NOS																				
Mesothelioma, malignant	X																			
Mesentery	N N																			
Fibrosarcoma																				
Mesothelioma, malignant																				
Hemangiosarcoma																				
ALL OTHER SYSTEMS																				
Multiple organs, NOS	N N																			
Squamous cell carcinoma, invasive	X																			
C-cell carcinoma, metastatic																				
Sarcoma, NOS, invasive																				
Fibrosarcoma, invasive																				
Liposarcoma, metastatic																				
Mesothelioma, invasive	X																			
Hemangiosarcoma, metastatic																				
Malignant lymphoma, undifferentiated type																				
Malignant lymphoma, histiocytic type																				
Monocytic leukemia	X X X X X X X X X X																			

TABLE A2. INDIVIDUAL ANIMAL TUMOR PATHOLOGY OF MALE RATS: 1% CROCIDOLITE ASBESTOS (Continued)

ANIMAL NUMBER	8 6 2	8 8 0	9 1 5	8 1 7	8 2 0	8 3 6	8 5 6	8 6 8	8 7 1	8 8 5	7 2 6	7 4 1	7 9 1	8 1 5	8 2 5	8 2 6	8 2 8	8 2 9	8 3 7	8 4 2	9 0 0	9 0 6	9 0 8	6 7 3	6 8 5		
WEEKS ON STUDY	1 2 5	1 2 5	1 2 5	1 2 6	1 2 6	1 2 6	1 2 6	1 2 6	1 2 6	1 2 6	1 2 7	1 2 7	1 2 7	1 2 7	1 2 7	1 2 7	1 2 7	1 2 7	1 2 7	1 2 7	1 2 7	1 2 7	1 2 7	1 2 8	1 2 8		
URINARY SYSTEM																											
Kidney	+																										
Tubular cell adenoma	+																										
Tubular cell adenocarcinoma	+																										
Mixed tumor, malignant	+																										
Urinary bladder	+																										
ENDOCRINE SYSTEM																											
Pituitary	+																										
Carcinoma, NOS	+																										
Adenoma, NOS	+																										
Adrenal	+																										
Cortical adenoma	+																										
Pheochromocytoma	+																										
Pheochromocytoma, malignant	+																										
Thyroid	+																										
Follicular cell adenoma	+																										
Follicular cell carcinoma	+																										
C-cell adenoma	+																										
C-cell carcinoma	+																										
Parathyroid	+																										
Pancreatic islets	+																										
Islet cell carcinoma	+																										
REPRODUCTIVE SYSTEM																											
Mammary gland	+																										
Adenoma, NOS	+																										
Adenocarcinoma, NOS	+																										
Fibroadenoma	+																										
Testis	+																										
Adenocarcinoma, NOS	+																										
Interstitial cell tumor	+																										
Prostate	+																										
Carcinoma, NOS	+																										
Preputial/clitoral gland	+																										
Squamous cell carcinoma	+																										
Epididymis	+																										
Lipoma	+																										
NERVOUS SYSTEM																											
Brain	+																										
Carcinoma, NOS, invasive	+																										
Granular cell tumor, NOS	+																										
Astrocytoma	+																										
Meningioma	+																										
Meningioma, invasive	+																										
Spinal cord	+																										
Liposarcoma, invasive	+																										
SPECIAL SENSE ORGANS																											
Harderian gland	+																										
Squamous cell carcinoma, invasive	+																										
Adenoma, NOS	+																										
Zymbal gland	+																										
Squamous cell carcinoma	+																										
Keratoacanthoma	+																										
MUSCULOSKELETAL SYSTEM																											
Bone	+																										
Squamous cell carcinoma, invasive	+																										
Hemangiosarcoma	+																										
Osteosarcoma	+																										
Muscle	+																										
C-cell carcinoma, invasive	+																										
Rhabdomyosarcoma	+																										
BODY CAVITIES																											
Mediastinum	+																										
Alveolar/bronchiolar carcinoma, invasive	+																										
Peritoneum	+																										
Liposarcoma	+																										
Leiomyosarcoma, invasive	+																										
Tunica vaginalis	+																										
Mesothelioma, NOS	+																										
Mesothelioma, malignant	+																										
Mesentery	+																										
Fibrosarcoma	+																										
Mesothelioma, malignant	+																										
Hemangiosarcoma	+																										
ALL OTHER SYSTEMS																											
Multiple organs, NOS	+																										
Squamous cell carcinoma, invasive	+																										
C-cell carcinoma, metastatic	+																										
Sarcoma, NOS, invasive	+																										
Fibrosarcoma, invasive	+																										
Fibrosarcoma, metastatic	+																										
Liposarcoma, invasive	+																										
Liposarcoma, metastatic	+																										
Hemangiosarcoma, metastatic	+																										
Malignant lymphoma, undifferentiated type	+																										
Malignant lymphoma, histiocytic type	+																										
Monocytic leukemia	+																										

TABLE A2. INDIVIDUAL ANIMAL TUMOR PATHOLOGY OF MALE RATS: 1% CROCIDOLITE ASBESTOS
(Continued)

ANIMAL NUMBER	7 5 3	7 6 1	7 6 2	8 6 3	8 7 4	7 7 9	7 4 0	7 6 5	8 0 0	6 7 0	7 0 1	7 2 7	7 3 1	5 9 5	7 9 5	8 7 2	8 8 6	8 9 9	6 7 1	7 2 9	7 8 1	7 5 6	8 5 7	9 1 3	7 2 3		
WEEKS ON STUDY	1 8	1 8	1 8	1 8	1 9	1 9	1 9	1 9	1 9	1 0	1 0	1 0	1 0	1 0	1 0	1 0	1 0	1 0	1 0	1 1	1 1	1 1	1 1	1 1	1 2	1 2	
URINARY SYSTEM																											
Kidney	+																										
Tubular cell adenoma	+																										
Tubular cell adenocarcinoma	+																										
Mixed tumor, malignant	+																										
Urinary bladder	+																										
ENDOCRINE SYSTEM																											
Pituitary	+																										
Carcinoma, NOS	+																										
Adenoma, NOS	+																										
Adrenal	+																										
Cortical adenoma	+																										
Pheochromocytoma	+																										
Pheochromocytoma, malignant	+																										
Thyroid	+																										
Follicular cell adenoma	+																										
Follicular cell carcinoma	+																										
C-cell adenoma	+																										
C-cell carcinoma	+																										
Parathyroid	+																										
Pancreatic islets	+																										
Islet cell carcinoma	+																										
REPRODUCTIVE SYSTEM																											
Mammary gland	+																										
Adenoma, NOS	+																										
Adenocarcinoma, NOS	+																										
Fibroadenoma	+																										
Testis	+																										
Adenocarcinoma, NOS	+																										
Interstitial cell tumor	+																										
Prostate	+																										
Carcinoma, NOS	+																										
Preputial/clitoral gland	+																										
Squamous cell carcinoma	+																										
Epididymis	+																										
Lipoma	+																										
NERVOUS SYSTEM																											
Brain	+																										
Carcinoma, NOS, invasive	+																										
Granular cell tumor, NOS	+																										
Astrocytoma	+																										
Meningioma	+																										
Meningioma, invasive	+																										
Spinal cord	+																										
Liposarcoma, invasive	+																										
SPECIAL SENSE ORGANS																											
Harderian gland	+																										
Squamous cell carcinoma, invasive	+																										
Adenoma, NOS	+																										
Zymbal gland	+																										
Squamous cell carcinoma	+																										
Keratoacanthoma	+																										
MUSCULOSKELETAL SYSTEM																											
Bone	+																										
Squamous cell carcinoma, invasive	+																										
Hemangiosarcoma	+																										
Osteosarcoma	+																										
Muscle	+																										
C-cell carcinoma, invasive	+																										
Rhabdomyosarcoma	+																										
BODY CAVITIES																											
Mediastinum	+																										
Alveolar/bronchiolar carcinoma, invasive	+																										
Peritoneum	+																										
Liposarcoma	+																										
Leiomyosarcoma, invasive	+																										
Tunica vaginalis	+																										
Mesothelioma, NOS	+																										
Mesothelioma, malignant	+																										
Mesentery	+																										
Fibrosarcoma	+																										
Mesothelioma, malignant	+																										
Hemangiosarcoma	+																										
ALL OTHER SYSTEMS																											
Multiple organs, NOS	+																										
Squamous cell carcinoma, invasive	+																										
C-cell carcinoma, metastatic	+																										
Sarcoma, NOS, invasive	+																										
Fibrosarcoma, invasive	+																										
Liposarcoma, metastatic	+																										
Mesothelioma, invasive	+																										
Hemangiosarcoma, metastatic	+																										
Malignant lymphoma, undifferentiated type	+																										
Malignant lymphoma, histiocytic type	+																										
Monocytic leukemia	+																										

TABLE A2. INDIVIDUAL ANIMAL TUMOR PATHOLOGY OF MALE RATS: 1% CROCIDOLITE ASBESTOS (Continued)

ANIMAL NUMBER	7	8	8	8	8	8	9	6	8	9	7	7	7	8	8	8	9	7	7	8	8	9	6	6	
	6	0	0	3	4	5	8	0	8	4	1	4	8	9	9	9	1	1	6	5	6	0	0	8	8
WEEKS ON STUDY	1	1	1	1	1	1	1	1	1	1	1	1	1	1	1	1	1	1	1	1	1	1	1	1	
	3	3	3	3	3	3	3	3	4	4	4	5	5	5	5	5	5	5	6	6	6	6	7	7	
URINARY SYSTEM																									
Kidney	+																								
Tubular cell adenoma	+																								
Tubular cell adenocarcinoma	+																								
Mixed tumor, malignant	+																								
Urinary bladder	+																								
ENDOCRINE SYSTEM																									
Pituitary	+																								
Carcinoma, NOS	+																								
Adenoma, NOS	+																								
Adrenal	+																								
Cortical adenoma	+																								
Pheochromocytoma	+																								
Pheochromocytoma, malignant	+																								
Thyroid	+																								
Follicular cell adenoma	+																								
Follicular cell carcinoma	+																								
C-cell adenoma	+																								
C-cell carcinoma	+																								
Parathyroid	+																								
Pancreatic islets	+																								
Islet cell carcinoma	+																								
REPRODUCTIVE SYSTEM																									
Mammary gland	+																								
Adenoma, NOS	+																								
Adenocarcinoma, NOS	+																								
Fibroadenoma	+																								
Testis	+																								
Adenocarcinoma, NOS	+																								
Interstitial cell tumor	+																								
Prostate	+																								
Carcinoma, NOS	+																								
Preputial/clitoral gland	+																								
Squamous cell carcinoma	+																								
Epididymis	+																								
Lipoma	+																								
NERVOUS SYSTEM																									
Brain	+																								
Carcinoma, NOS, invasive	+																								
Granular cell tumor, NOS	+																								
Astrocytoma	+																								
Meningioma	+																								
Meningioma, invasive	+																								
Spinal cord	+																								
Liposarcoma, invasive	+																								
SPECIAL SENSE ORGANS																									
Harderian gland	+																								
Squamous cell carcinoma, invasive	+																								
Adenoma, NOS	+																								
Zymbal gland	+																								
Squamous cell carcinoma	+																								
Keratoacanthoma	+																								
MUSCULOSKELETAL SYSTEM																									
Bone	+																								
Squamous cell carcinoma, invasive	+																								
Hemangiosarcoma	+																								
Osteosarcoma	+																								
Muscle	+																								
C-cell carcinoma, invasive	+																								
Rhabdomyosarcoma	+																								
BODY CAVITIES																									
Mediastinum	+																								
Alveolar/bronchiolar carcinoma, invasive	+																								
Peritoneum	+																								
Liposarcoma	+																								
Leiomyosarcoma, invasive	+																								
Tunica vaginalis	+																								
Mesothelioma, NOS	+																								
Mesothelioma, malignant	+																								
Mesentery	+																								
Fibrosarcoma	+																								
Mesothelioma, malignant	+																								
Hemangiosarcoma	+																								
ALL OTHER SYSTEMS																									
Multiple organs, NOS	+																								
Squamous cell carcinoma, invasive	+																								
C-cell carcinoma, metastatic	+																								
Sarcoma, NOS, invasive	+																								
Fibrosarcoma, invasive	+																								
Liposarcoma, metastatic	+																								
Mesothelioma, invasive	+																								
Hemangiosarcoma, metastatic	+																								
Malignant lymphoma, undifferentiated type	+																								
Malignant lymphoma, histiocytic type	+																								
Monocytic leukemia	+																								

TABLE A2. INDIVIDUAL ANIMAL TUMOR PATHOLOGY OF MALE RATS: 1% CROCIDOLITE ASBESTOS (Continued)

ANIMAL NUMBER	7 4 8	7 5 6	8 2 1	8 4 3	7 0 1	7 4 0	8 9 8	8 1 9	8 4 3	7 0 0	7 4 0	8 0 4	8 1 4	8 7 0	8 7 0	9 0 1	9 1 2	6 8 7	7 6 5	8 4 1	8 8 7	6 4 5	6 7 2	6 7 2	6 9 1	6 9 2	
WEEKS ON STUDY	1 3 7	1 3 7	1 3 7	1 3 7	1 3 8	1 3 8	1 3 8	1 3 8	1 3 9	1 4 0	1 4 0	1 4 0	1 4 0	1 4 0	1 4 0	1 4 0	1 4 0	1 4 1	1 4 1	1 4 1	1 4 1	1 4 2	1 4 2	1 4 2	1 4 2	1 4 2	
URINARY SYSTEM																											
Kidney	+	+	+	+	+	+	+	+	+	+	+	+	+	+	+	+	+	+	+	+	+	+	+	+	+	+	+
Tubular cell adenoma																											
Tubular cell adenocarcinoma																											
Mixed tumor, malignant																											
Urinary bladder	+	+	+	+	+	+	+	+	+	+	+	+	+	+	+	+	+	+	+	+	+	+	+	+	+	+	+
ENDOCRINE SYSTEM																											
Pituitary	+	+	+	+	+	+	-	+	+	+	+	+	+	+	+	+	+	+	+	+	+	+	+	+	+	+	+
Carcinoma, NOS																											
Adenoma, NOS				X		X										X						X					
Adrenal	+	+	+	+	+	+	+	+	+	+	+	+	+	+	+	+	+	+	+	+	+	+	+	+	+	+	+
Cortical adenoma																											
Pheochromocytoma	X			X	X																			X	X	X	X
Pheochromocytoma, malignant		X				X																					
Thyroid	+	+	+	+	+	+	+	+	+	+	+	+	+	+	+	+	+	+	+	+	+	+	+	+	+	+	+
Follicular cell adenoma																											
Follicular cell carcinoma							X																				
C-cell adenoma																											
C-cell carcinoma															X	X								X			X
Parathyroid	+	+	+	+	+	+	+	+	+	+	+	+	+	+	+	+	+	+	+	+	+	+	+	+	+	+	+
Pancreatic islets	+	+	+	+	+	+	+	+	+	+	+	+	+	+	+	+	+	+	+	+	+	+	+	+	+	+	+
Islet cell carcinoma						X											X										
REPRODUCTIVE SYSTEM																											
Mammary gland	+	+	+	+	+	+	+	+	+	+	+	+	+	+	+	+	+	+	+	+	+	+	+	+	+	+	+
Adenoma, NOS																											
Adenocarcinoma, NOS																											
Fibroadenoma																											
Testis	+	+	+	+	+	+	+	+	+	+	+	+	+	+	+	+	+	+	+	+	+	+	+	+	+	+	+
Adenocarcinoma, NOS																											
Interstitial cell tumor	X	X	X	X	X	X	X	X	X	X	X	X	X	X	X	X	X	X	X	X	X	X	X	X	X	X	X
Prostate	+	+	+	+	+	+	+	+	+	+	+	+	+	+	+	+	+	+	+	+	+	+	+	+	+	+	+
Carcinoma, NOS																											
Preputial/leitoral gland	N	N	N	N	N	N	N	N	N	N	N	N	N	N	N	N	N	N	N	N	N	N	N	N	N	N	N
Squamous cell carcinoma																											
Epididymis	N	N	N	N	N	N	N	N	N	N	N	N	N	N	N	N	N	N	N	N	N	N	N	N	N	N	N
Lipoma									X																		
NERVOUS SYSTEM																											
Brain	+	+	+	+	+	+	+	+	+	+	+	+	+	+	+	+	+	+	+	+	+	+	+	+	+	+	+
Carcinoma, NOS, invasive																											
Granular cell tumor, NOS																											
Astrocytoma																											
Meningioma																											
Meningioma, invasive																											
Spinal cord	N	N	N	N	N	N	N	N	N	N	N	N	N	N	N	N	N	N	N	N	N	N	N	N	N	N	N
Liposarcoma, invasive																											
SPECIAL SENSE ORGANS																											
Harderian gland	N	N	N	N	N	N	N	N	N	N	N	N	N	N	N	N	N	N	N	N	N	N	N	N	N	N	N
Squamous cell carcinoma, invasive																											
Adenoma, NOS																											
Zymbal gland	N	N	N	N	N	N	N	N	N	N	N	N	N	N	N	N	N	N	N	N	N	N	N	N	N	N	N
Squamous cell carcinoma																											
Keratocanthoma				X																							
MUSCULOSKELETAL SYSTEM																											
Bone	N	N	N	N	N	N	N	N	N	N	N	N	N	N	N	N	N	N	N	N	N	N	N	N	N	N	N
Squamous cell carcinoma, invasive																											
Hemangiosarcoma																											
Osteosarcoma																											
Muscle	N	N	N	N	N	N	N	N	N	N	N	N	N	N	N	N	N	N	N	N	N	N	N	N	N	N	N
C-cell carcinoma, invasive																											
Rhabdomyosarcoma																											
BODY CAVITIES																											
Mediastinum	N	N	N	N	N	N	N	N	N	N	N	N	N	N	N	N	N	N	N	N	N	N	N	N	N	N	N
Alveolar/broncholar carcinoma, invasive																											
Peritoneum	N	N	N	N	N	N	N	N	N	N	N	N	N	N	N	N	N	N	N	N	N	N	N	N	N	N	N
Liposarcoma																											
Leiomyosarcoma, invasive																											
Tunica vaginalis	+	+	+	+	+	+	+	+	+	+	+	+	+	+	+	+	+	+	+	+	+	+	+	+	+	+	+
Mesothelioma, NOS																											
Mesothelioma, malignant																											
Mesentery	N	N	N	N	N	N	N	N	N	N	N	N	N	N	N	N	N	N	N	N	N	N	N	N	N	N	N
Fibrosarcoma																											
Mesothelioma, malignant																											
Hemangiosarcoma																											
ALL OTHER SYSTEMS																											
Multiple organs, NOS	N	N	N	N	N	N	N	N	N	N	N	N	N	N	N	N	N	N	N	N	N	N	N	N	N	N	N
Squamous cell carcinoma, invasive																											
C-cell carcinoma, metastatic																											
Sarcoma, NOS, invasive																											
Fibrosarcoma, invasive																											
Liposarcoma, metastatic																											
Mesothelioma, invasive																											
Hemangiosarcoma, metastatic																											
Malignant lymphoma, undifferentiated type																											
Malignant lymphoma, histiocytic type																											
Monocytic leukemia				X		X	X	X	X		X							X	X	X		X	X	X			

TABLE A3. ANALYSIS OF PRIMARY TUMORS IN MALE RATS IN THE LIFETIME FEED STUDY OF CROCIDOLITE ASBESTOS

	Control	1% Crocidolite Asbestos
Integumentary System: Fibroma		
Overall Rates (a)	18/118 (15%)	27/250 (11%)
Adjusted Rates (b)	48.8%	29.6%
Terminal Rates (c)	2/11 (18%)	3/29 (10%)
Week of First Observation	86	88
Life Table Test (d)		P=0.054N
Incidental Tumor Test (d)		P=0.103N
Fisher Exact Test (d)		P=0.148N
Integumentary System: Fibroma or Neurofibroma		
Overall Rates (a)	21/118 (18%)	36/250 (14%)
Adjusted Rates (b)	52.5%	36.9%
Terminal Rates (c)	2/11 (18%)	4/29 (14%)
Week of First Observation	86	88
Life Table Test (d)		P=0.093N
Incidental Tumor Test (d)		P=0.184N
Fisher Exact Test (d)		P=0.245N
Integumentary System: Fibroma or Fibrosarcoma		
Overall Rates (a)	26/118 (22%)	34/250 (14%)
Adjusted Rates (b)	61.5%	33.6%
Terminal Rates (c)	3/11 (27%)	3/29 (10%)
Week of First Observation	86	88
Life Table Test (d)		P=0.006N
Incidental Tumor Test (d)		P=0.016N
Fisher Exact Test (d)		P=0.032N
Integumentary System: Neurofibroma or Neurofibrosarcoma		
Overall Rates (a)	3/118 (3%)	13/250 (5%)
Adjusted Rates (b)	6.9%	16.2%
Terminal Rates (c)	0/11 (0%)	2/29 (7%)
Week of First Observation	104	102
Life Table Test (d)		P=0.287
Incidental Tumor Test (d)		P=0.210
Fisher Exact Test (d)		P=0.188
Integumentary System: Sarcoma, Fibrosarcoma, Neurofibrosarcoma, or Myxosarcoma		
Overall Rates (a)	10/118 (8%)	11/250 (4%)
Adjusted Rates (b)	25.2%	12.1%
Terminal Rates (c)	1/11 (9%)	1/29 (3%)
Week of First Observation	89	95
Life Table Test (d)		P=0.042N
Incidental Tumor Test (d)		P=0.075N
Fisher Exact Test (d)		P=0.094N
Integumentary System: Fibroma, Neurofibroma, Sarcoma, Fibrosarcoma, Neurofibrosarcoma, or Myxosarcoma		
Overall Rates (a)	30/118 (25%)	45/250 (18%)
Adjusted Rates (b)	64.8%	44.4%
Terminal Rates (c)	3/11 (27%)	5/29 (17%)
Week of First Observation	86	88
Life Table Test (d)		P=0.014N
Incidental Tumor Test (d)		P=0.037N
Fisher Exact Test (d)		P=0.068N
Hematopoietic System: Monocytic Leukemia		
Overall Rates (a)	42/118 (36%)	113/250 (45%)
Adjusted Rates (b)	73.5%	81.2%
Terminal Rates (c)	4/11 (36%)	15/29 (52%)
Week of First Observation	71	83
Life Table Test (d)		P=0.401
Incidental Tumor Test (d)		P=0.062
Fisher Exact Test (d)		P=0.051

TABLE A3. ANALYSIS OF PRIMARY TUMORS IN MALE RATS IN THE LIFETIME FEED STUDY OF CROCIDOLITE ASBESTOS (Continued)

	Control	1% Crocidolite Asbestos
Hematopoietic System: Leukemia		
Overall Rates (a)	43/118 (36%)	113/250 (45%)
Adjusted Rates (b)	73.7%	81.2%
Terminal Rates (c)	4/11 (36%)	15/29 (52%)
Week of First Observation	71	83
Life Table Test (d)		P=0.452
Incidental Tumor Test (d)		P=0.082
Fisher Exact Test (d)		P=0.070
Liver: Neoplastic Nodule		
Overall Rates (a)	8/117 (7%)	16/250 (6%)
Adjusted Rates (b)	30.8%	19.1%
Terminal Rates (c)	2/11 (18%)	2/29 (7%)
Week of First Observation	116	101
Life Table Test (d)		P=0.361N
Incidental Tumor Test (d)		P=0.449N
Fisher Exact Test (d)		P=0.518N
Liver: Neoplastic Nodule or Hepatocellular Carcinoma		
Overall Rates (a)	11/117 (9%)	18/250 (7%)
Adjusted Rates (b)	40.1%	22.7%
Terminal Rates (c)	2/11 (18%)	3/29 (10%)
Week of First Observation	116	101
Life Table Test (d)		P=0.152N
Incidental Tumor Test (d)		P=0.218N
Fisher Exact Test (d)		P=0.297N
Pancreas: Acinar Cell Adenoma		
Overall Rates (a)	8/117 (7%)	15/249 (6%)
Adjusted Rates (b)	30.0%	24.8%
Terminal Rates (c)	1/11 (9%)	4/29 (14%)
Week of First Observation	126	121
Life Table Test (d)		P=0.293N
Incidental Tumor Test (d)		P=0.365N
Fisher Exact Test (d)		P=0.464N
Pancreas: Acinar Cell Adenoma or Carcinoma		
Overall Rates (a)	8/117 (7%)	17/249 (7%)
Adjusted Rates (b)	30.0%	28.3%
Terminal Rates (c)	1/11 (9%)	5/29 (17%)
Week of First Observation	126	121
Life Table Test (d)		P=0.392N
Incidental Tumor Test (d)		P=0.481N
Fisher Exact Test (d)		P=0.578N
Pituitary Gland: Adenoma		
Overall Rates (a)	15/117 (13%)	41/245 (17%)
Adjusted Rates (b)	59.1%	45.4%
Terminal Rates (c)	5/11 (45%)	4/28 (14%)
Week of First Observation	89	98
Life Table Test (d)		P=0.499
Incidental Tumor Test (d)		P=0.337
Fisher Exact Test (d)		P=0.211
Pituitary Gland: Adenoma or Carcinoma		
Overall Rates (a)	18/117 (15%)	45/245 (18%)
Adjusted Rates (b)	62.3%	48.8%
Terminal Rates (c)	5/11 (45%)	5/28 (18%)
Week of First Observation	89	95
Life Table Test (d)		P=0.502N
Incidental Tumor Test (d)		P=0.439
Fisher Exact Test (d)		P=0.293

TABLE A3. ANALYSIS OF PRIMARY TUMORS IN MALE RATS IN THE LIFETIME FEED STUDY OF CROCIDOLITE ASBESTOS (Continued)

	Control	1% Crocidolite Asbestos
Adrenal Gland: Pheochromocytoma		
Overall Rates (a)	33/117 (28%)	54/250 (22%)
Adjusted Rates (b)	75.7%	58.9%
Terminal Rates (c)	5/11 (45%)	9/29 (31%)
Week of First Observation	90	103
Life Table Test (d)		P=0.017N
Incidental Tumor Test (d)		P=0.053N
Fisher Exact Test (d)		P=0.106N
Adrenal Gland: Pheochromocytoma or Malignant Pheochromocytoma		
Overall Rates (a)	35/117 (30%)	60/250 (24%)
Adjusted Rates (b)	80.3%	63.7%
Terminal Rates (c)	6/11 (55%)	10/29 (34%)
Week of First Observation	90	81
Life Table Test (d)		P=0.024N
Incidental Tumor Test (d)		P=0.076N
Fisher Exact Test (d)		P=0.142N
Thyroid Gland: Follicular Cell Adenoma		
Overall Rates (a)	7/116 (6%)	15/249 (6%)
Adjusted Rates (b)	15.5%	14.2%
Terminal Rates (c)	0/11 (0%)	0/29 (0%)
Week of First Observation	108	88
Life Table Test (d)		P=0.443N
Incidental Tumor Test (d)		P=0.562N
Fisher Exact Test (d)		P=0.582N
Thyroid Gland: Follicular Cell Carcinoma		
Overall Rates (a)	3/116 (3%)	22/249 (9%)
Adjusted Rates (b)	9.0%	31.7%
Terminal Rates (c)	0/11 (0%)	6/29 (21%)
Week of First Observation	100	110
Life Table Test (d)		P=0.061
Incidental Tumor Test (d)		P=0.034
Fisher Exact Test (d)		P=0.019
Thyroid Gland: Follicular Cell Adenoma or Carcinoma		
Overall Rates (a)	10/116 (9%)	37/249 (15%)
Adjusted Rates (b)	23.1%	41.5%
Terminal Rates (c)	0/11 (0%)	6/29 (21%)
Week of First Observation	100	88
Life Table Test (d)		P=0.196
Incidental Tumor Test (d)		P=0.095
Fisher Exact Test (d)		P=0.065
Thyroid Gland: C-Cell Adenoma		
Overall Rates (a)	13/116 (11%)	34/249 (14%)
Adjusted Rates (b)	34.8%	31.2%
Terminal Rates (c)	2/11 (18%)	3/29 (10%)
Week of First Observation	78	88
Life Table Test (d)		P=0.518
Incidental Tumor Test (d)		P=0.321
Fisher Exact Test (d)		P=0.319
Thyroid Gland: C-Cell Carcinoma		
Overall Rates (a)	19/116 (16%)	48/249 (19%)
Adjusted Rates (b)	62.5%	57.8%
Terminal Rates (c)	5/11 (45%)	10/29 (34%)
Week of First Observation	98	95
Life Table Test (d)		P=0.497N
Incidental Tumor Test (d)		P=0.436
Fisher Exact Test (d)		P=0.304

TABLE A3. ANALYSIS OF PRIMARY TUMORS IN MALE RATS IN THE LIFETIME FEED STUDY OF CROCIDOLITE ASBESTOS (Continued)

	Control	1% Crocidolite Asbestos
Thyroid Gland: C-Cell Adenoma or Carcinoma		
Overall Rates (a)	32/116 (28%)	79/249 (32%)
Adjusted Rates (b)	80.1%	71.6%
Terminal Rates (c)	7/11 (64%)	13/29 (45%)
Week of First Observation	78	88
Life Table Test (d)		P=0.458N
Incidental Tumor Test (d)		P=0.353
Fisher Exact Test (d)		P=0.250
Pancreatic Islets: Islet Cell Carcinoma		
Overall Rates (a)	11/117 (9%)	11/249 (4%)
Adjusted Rates (b)	25.7%	17.5%
Terminal Rates (c)	0/11 (0%)	1/29 (3%)
Week of First Observation	95	104
Life Table Test (d)		P=0.020N
Incidental Tumor Test (d)		P=0.028N
Fisher Exact Test (d)		P=0.055N
Pancreatic Islets: Islet Cell Adenoma or Carcinoma		
Overall Rates (a)	12/117 (10%)	11/249 (4%)
Adjusted Rates (b)	26.4%	17.5%
Terminal Rates (c)	0/11 (0%)	1/29 (3%)
Week of First Observation	95	104
Life Table Test (d)		P=0.010N
Incidental Tumor Test (d)		P=0.015N
Fisher Exact Test (d)		P=0.031N
Mammary Gland: Fibroadenoma		
Overall Rates (a)	18/118 (15%)	18/250 (7%)
Adjusted Rates (b)	52.4%	29.1%
Terminal Rates (c)	3/11 (27%)	4/29 (14%)
Week of First Observation	78	106
Life Table Test (d)		P=0.002N
Incidental Tumor Test (d)		P=0.005N
Fisher Exact Test (d)		P=0.015N
Mammary Gland: Adenoma or Fibroadenoma		
Overall Rates (a)	18/118 (15%)	19/250 (8%)
Adjusted Rates (b)	52.4%	29.8%
Terminal Rates (c)	3/11 (27%)	4/29 (14%)
Week of First Observation	78	106
Life Table Test (d)		P=0.003N
Incidental Tumor Test (d)		P=0.007N
Fisher Exact Test (d)		P=0.021N
Mammary Gland: Adenoma, Fibroadenoma, or Adenocarcinoma		
Overall Rates (a)	19/118 (16%)	22/250 (9%)
Adjusted Rates (b)	53.6%	33.6%
Terminal Rates (c)	3/11 (27%)	5/29 (17%)
Week of First Observation	78	106
Life Table Test (d)		P=0.005N
Incidental Tumor Test (d)		P=0.012N
Fisher Exact Test (d)		P=0.031N
Preputial Gland: Squamous Cell Carcinoma		
Overall Rates (a)	3/118 (3%)	16/250 (6%)
Adjusted Rates (b)	10.6%	21.3%
Terminal Rates (c)	0/11 (0%)	2/29 (7%)
Week of First Observation	118	86
Life Table Test (d)		P=0.183
Incidental Tumor Test (d)		P=0.109
Fisher Exact Test (d)		P=0.091

TABLE A3. ANALYSIS OF PRIMARY TUMORS IN MALE RATS IN THE LIFETIME FEED STUDY OF CROCIDOLITE ASBESTOS (Continued)

	Control	1% Crocidolite Asbestos
Testis: Interstitial Cell Tumor		
Overall Rates (a)	116/118 (98%)	237/249 (95%)
Adjusted Rates (b)	100.0%	100.0%
Terminal Rates (c)	11/11 (100%)	29/29 (100%)
Week of First Observation	60	81
Life Table Test (d)		P=0.023N
Incidental Tumor Test (d)		P=0.047N
Fisher Exact Test (d)		P=0.119N
All Sites: Benign Tumors		
Overall Rates (a)	117/118 (99%)	242/250 (97%)
Adjusted Rates (b)	100.0%	100.0%
Terminal Rates (c)	11/11 (100%)	29/29 (100%)
Week of First Observation	60	81
Life Table Test (d)		P=0.029N
Incidental Tumor Test (d)		P=0.050N
Fisher Exact Test (d)		P=0.159N
All Sites: Malignant Tumors		
Overall Rates (a)	97/118 (82%)	209/250 (84%)
Adjusted Rates (b)	98.8%	98.3%
Terminal Rates (c)	10/11 (91%)	26/29 (90%)
Week of First Observation	71	42
Life Table Test (d)		P=0.089N
Incidental Tumor Test (d)		P=0.498
Fisher Exact Test (d)		P=0.422
All Sites: All Tumors		
Overall Rates (a)	118/118 (100%)	248/250 (99%)
Adjusted Rates (b)	100.0%	100.0%
Terminal Rates (c)	11/11 (100%)	29/29 (100%)
Week of First Observation	60	42
Life Table Test (d)		P=0.042N
Incidental Tumor Test (d)		P=0.314N
Fisher Exact Test (d)		P=0.461N

(a) Number of tumor-bearing animals/number of animals examined at the site

(b) Kaplan-Meier estimated tumor incidences at the end of the study after adjusting for intercurrent mortality

(c) Observed tumor incidence at terminal kill

(d) Beneath the control incidence are the P values associated with the trend test. Beneath the dosed group incidence are the P values corresponding to pairwise comparisons between that dosed group and the controls. The life table analysis regards tumors in animals dying prior to terminal kill as being (directly or indirectly) the cause of death. The incidental tumor test regards these lesions as nonfatal. The Cochran-Armitage and Fisher exact tests compare directly the overall incidence rates. A negative trend or lower incidence in a dosed group is indicated by (N).

TABLE A4a. HISTORICAL INCIDENCE OF LEUKEMIA IN MALE F344/N RATS RECEIVING NO TREATMENT IN LIFETIME STUDIES (a)

Asbestos Studies	Incidence in Controls
Chrysotile (short range)	37/88
Chrysotile (intermediate range)	31/88
Tremolite	43/118
Crocidolite	43/118
Amosite	38/117
TOTAL	192/529 (36.3%)
SD (b)	3.48%
Range	
High	37/88 (42.0%)
Low	38/117 (32.5%)

(a) All studies conducted by Hazleton Laboratories; age at start of terminal kill, 138-146 weeks.

(b) Standard deviation

TABLE A4b. HISTORICAL INCIDENCE OF THYROID GLAND FOLLICULAR CELL TUMORS IN MALE F344/N RATS RECEIVING NO TREATMENT IN LIFETIME STUDIES (a)

Asbestos Studies	Incidence in Controls		
	Adenoma	Carcinoma	Adenoma or Carcinoma
Chrysotile (short range)	4/86	2/86	6/86
Chrysotile (intermediate range)	1/84	5/84	6/84
Tremolite	5/117	6/117	11/117
Crocidolite	7/116	3/116	10/116
Amosite	4/117	7/117	11/117
TOTAL	21/520 (4.0%)	23/520 (4.4%)	44/520 (8.5%)
SD (b)	1.79%	1.81%	1.19%
Range			
High	7/116 (6.0%)	7/117 (6.0%)	11/117 (9.4%)
Low	1/84 (1.2%)	2/86 (2.3%)	6/86 (7.0%)

(a) All studies conducted by Hazleton Laboratories; age at start of terminal kill, 138-146 weeks.

(b) Standard deviation

TABLE A5. SUMMARY OF THE INCIDENCE OF NONNEOPLASTIC LESIONS IN MALE RATS IN THE LIFETIME FEED STUDY OF CROCIDOLITE ASBESTOS

	Untreated Control	1% Crocidolite Asbestos
ANIMALS INITIALLY IN STUDY	118	250
ANIMALS NECROPSIED	118	250
ANIMALS EXAMINED HISTOPATHOLOGICALLY	118	250
INTEGUMENTARY SYSTEM		
*Skin	(118)	(250)
Epidermal inclusion cyst	2 (2%)	3 (1%)
Edema, NOS		1 (0%)
Hemorrhage		1 (0%)
Inflammation, acute		1 (0%)
Inflammation, acute focal		1 (0%)
Abscess, NOS		2 (1%)
Inflammation, acute/chronic	1 (1%)	
Necrosis, focal		2 (1%)
Hyperplasia, focal		1 (0%)
Hyperkeratosis	1 (1%)	2 (1%)
Acanthosis	1 (1%)	2 (1%)
Metaplasia, osseous	1 (1%)	
*Subcutaneous tissue	(118)	(250)
Abscess, NOS		2 (1%)
Inflammation, chronic		1 (0%)
Fibrosis		1 (0%)
RESPIRATORY SYSTEM		
*Nasal cavity	(118)	(250)
Hyperkeratosis		1 (0%)
Metaplasia, squamous		1 (0%)
*Nasal turbinate	(118)	(250)
Inflammation, chronic		1 (0%)
#Trachea	(117)	(248)
Inflammation, chronic		1 (0%)
#Lung	(117)	(250)
Bronchiectasis		1 (0%)
Congestion, NOS	7 (6%)	8 (3%)
Hemorrhage	5 (4%)	14 (6%)
Inflammation, interstitial	2 (2%)	1 (0%)
Pneumonia, aspiration		1 (0%)
Inflammation, acute		1 (0%)
Inflammation, acute focal		1 (0%)
Inflammation, acute diffuse	1 (1%)	
Pneumonia, chronic murine		1 (0%)
Inflammation, chronic	98 (84%)	214 (86%)
Granuloma, NOS	1 (1%)	5 (2%)
Necrosis, focal		1 (0%)
Pigmentation, NOS	2 (2%)	7 (3%)
Hyperplasia, alveolar epithelium	3 (3%)	10 (4%)
Metaplasia, squamous		1 (0%)
#Lung/alveoli	(117)	(250)
Histiocytosis	4 (3%)	4 (2%)
HEMATOPOIETIC SYSTEM		
*Mediastinum	(118)	(250)
Hematopoiesis		1 (0%)
#Bone marrow	(117)	(248)
Congestion, NOS	1 (1%)	
Hemorrhage	1 (1%)	
Necrosis, focal		1 (0%)
Hypoplasia, NOS	3 (3%)	8 (3%)
Hyperplasia, NOS	3 (3%)	7 (3%)

TABLE A5. SUMMARY OF THE INCIDENCE OF NONNEOPLASTIC LESIONS IN MALE RATS IN THE LIFETIME FEED STUDY OF CROCIDOLITE ASBESTOS (Continued)

	Untreated Control	1% Crocidolite Asbestos
HEMATOPOIETIC SYSTEM (Continued)		
#Spleen	(117)	(250)
Hemorrhage		6 (2%)
Fibrosis		1 (0%)
Fibrosis, focal	3 (3%)	21 (8%)
Fibrosis, multifocal		6 (2%)
Fibrosis, diffuse	2 (2%)	2 (1%)
Necrosis, NOS		1 (0%)
Necrosis, focal	1 (1%)	13 (5%)
Amyloidosis	1 (1%)	
Pigmentation, NOS		2 (1%)
Hemosiderosis	14 (12%)	48 (19%)
Hyperplasia, reticulum cell		1 (0%)
Hyperplasia, lymphoid	1 (1%)	
Hematopoiesis	21 (18%)	49 (20%)
#Splenic capsule	(117)	(250)
Fibrosis, multifocal		1 (0%)
#Splenic follicles	(117)	(250)
Atrophy, NOS	1 (1%)	6 (2%)
#Submandibular lymph node	(117)	(250)
Hyperplasia, lymphoid		1 (0%)
#Mandibular lymph node	(117)	(250)
Hemorrhage	1 (1%)	1 (0%)
Inflammation, acute diffuse		1 (0%)
Inflammation, chronic diffuse		1 (0%)
Fibrosis, focal	1 (1%)	
Hyperplasia, lymphoid	14 (12%)	37 (15%)
#Cervical lymph node	(117)	(250)
Pigmentation, NOS		1 (0%)
Erythrophagocytosis		1 (0%)
#Mediastinal lymph node	(117)	(250)
Congestion, NOS		1 (0%)
Hemorrhage	5 (4%)	16 (6%)
Pigmentation, NOS	12 (10%)	36 (14%)
Atrophy, NOS		1 (0%)
Erythrophagocytosis	4 (3%)	16 (6%)
Hyperplasia, reticulum cell	1 (1%)	
Hyperplasia, lymphoid	1 (1%)	7 (3%)
#Pancreatic lymph node	(117)	(250)
Hemorrhage		3 (1%)
Pigmentation, NOS	1 (1%)	15 (6%)
Atrophy, NOS		1 (0%)
Hyperplasia, reticulum cell	2 (2%)	6 (2%)
#Mesenteric lymph node	(117)	(250)
Congestion, NOS	1 (1%)	
Hemorrhage	1 (1%)	2 (1%)
Pigmentation, NOS	1 (1%)	3 (1%)
Atrophy, NOS	1 (1%)	1 (0%)
Erythrophagocytosis	1 (1%)	6 (2%)
Hyperplasia, reticulum cell	37 (32%)	58 (23%)
Hyperplasia, lymphoid	3 (3%)	9 (4%)
Mastocytosis	1 (1%)	
#Ileocolic lymph node	(117)	(250)
Edema, NOS	1 (1%)	
Inflammation, acute diffuse	1 (1%)	
Inflammation, chronic diffuse		1 (0%)
Necrosis, NOS	1 (1%)	
Pigmentation, NOS		2 (1%)
#Renal lymph node	(117)	(250)
Pigmentation, NOS	1 (1%)	2 (1%)
Hyperplasia, reticulum cell		1 (0%)

TABLE A5. SUMMARY OF THE INCIDENCE OF NONNEOPLASTIC LESIONS IN MALE RATS IN THE LIFETIME FEED STUDY OF CROCIDOLITE ASBESTOS (Continued)

	Untreated Control	1% Crocidolite Asbestos
HEMATOPOIETIC SYSTEM (Continued)		
#Iliac lymph node	(117)	(250)
Hemorrhage		1 (0%)
Hyperplasia, lymphoid		1 (0%)
#Lung	(117)	(250)
Leukocytosis, NOS	1 (1%)	
#Liver	(117)	(250)
Leukocytosis, NOS	5 (4%)	7 (3%)
Hematopoiesis	1 (1%)	2 (1%)
#Hepatic sinusoid	(117)	(250)
Leukocytosis, NOS		1 (0%)
#Kidney	(117)	(250)
Hematopoiesis		1 (0%)
#Adrenal	(117)	(250)
Hematopoiesis		1 (0%)
#Thymus	(88)	(182)
Cyst, NOS		1 (1%)
Congestion, NOS		1 (1%)
Hemorrhage		1 (1%)
Hyperplasia, epithelial		1 (1%)
CIRCULATORY SYSTEM		
*Eye	(118)	(250)
Thrombosis, NOS		1 (0%)
Embolus, septic		1 (0%)
#Spleen	(117)	(250)
Thrombosis, NOS		1 (0%)
#Mandibular lymph node	(117)	(250)
Lymphangiectasis	2 (2%)	5 (2%)
#Mediastinal lymph node	(117)	(250)
Lymphangiectasis	2 (2%)	
Thrombosis, NOS		1 (0%)
#Pancreatic lymph node	(117)	(250)
Lymphangiectasis		2 (1%)
#Mesenteric lymph node	(117)	(250)
Lymphangiectasis	12 (10%)	21 (8%)
#Ileocolic lymph node	(117)	(250)
Lymphangiectasis	3 (3%)	3 (1%)
#Iliac lymph node	(117)	(250)
Lymphangiectasis		2 (1%)
#Lung	(117)	(250)
Thrombosis, NOS		1 (0%)
#Heart	(117)	(250)
Embolus, septic		2 (1%)
#Heart/atrium	(117)	(250)
Thrombosis, NOS		5 (2%)
#Myocardium	(117)	(250)
Mineralization	1 (1%)	
Thrombosis, NOS		1 (0%)
Inflammation, acute focal		1 (0%)
Inflammation, chronic focal	40 (34%)	96 (38%)
Inflammation, chronic diffuse	33 (28%)	78 (31%)
Fibrosis, focal	3 (3%)	2 (1%)
Fibrosis, multifocal	1 (1%)	
Degeneration, NOS		2 (1%)
Necrosis, focal		1 (0%)
#Endocardium	(117)	(250)
Fibrosis		1 (0%)
#Cardiac valve	(117)	(250)
Inflammation, acute focal		1 (0%)
Inflammation, chronic		1 (0%)

TABLE A5. SUMMARY OF THE INCIDENCE OF NONNEOPLASTIC LESIONS IN MALE RATS IN THE LIFETIME FEED STUDY OF CROCIDOLITE ASBESTOS (Continued)

	Untreated Control	1% Crocidolite Asbestos
CIRCULATORY SYSTEM (Continued)		
*Aorta	(118)	(250)
Mineralization	1 (1%)	2 (1%)
Atherosclerosis		1 (0%)
*Coronary artery	(118)	(250)
Mineralization		1 (0%)
*Pulmonary artery	(118)	(250)
Inflammation, chronic	1 (1%)	
*Mesenteric artery	(118)	(250)
Inflammation, chronic	1 (1%)	
*Vena cava	(118)	(250)
Mineralization		1 (0%)
#Liver	(117)	(250)
Thrombosis, NOS	3 (3%)	1 (0%)
#Pancreas	(117)	(249)
Periarteritis	1 (1%)	6 (2%)
#Stomach	(116)	(249)
Periarteritis		1 (0%)
*Mesentery	(118)	(250)
Periarteritis		3 (1%)
#Kidney	(117)	(250)
Thrombosis, NOS		1 (0%)
Embolism, NOS		1 (0%)
Embolus, septic		1 (0%)
#Testis	(118)	(249)
Periarteritis	2 (2%)	4 (2%)
#Adrenal	(117)	(250)
Thrombosis, NOS	2 (2%)	
#Adrenal cortex	(117)	(250)
Thrombosis, NOS		1 (0%)
DIGESTIVE SYSTEM		
*Tongue	(118)	(250)
Epidermal inclusion cyst		1 (0%)
Edema, NOS		1 (0%)
Inflammation, acute diffuse		1 (0%)
Inflammation, chronic focal		1 (0%)
Hyperkeratosis		2 (1%)
Acanthosis		1 (0%)
#Salivary gland	(115)	(249)
Inflammation, acute focal	1 (1%)	
Inflammation, chronic focal	1 (1%)	1 (0%)
Inflammation, chronic diffuse	1 (1%)	5 (2%)
Degeneration, NOS		2 (1%)
Atrophy, diffuse		7 (3%)
#Submaxillary gland	(115)	(249)
Inflammation, chronic	1 (1%)	
Atrophy, NOS	1 (1%)	
#Liver	(117)	(250)
Congestion, NOS		2 (1%)
Hemorrhage	2 (2%)	5 (2%)
Inflammation, fibrinous		1 (0%)
Granuloma, NOS	9 (8%)	17 (7%)
Hepatitis, toxic	8 (7%)	37 (15%)
Degeneration, NOS	11 (9%)	30 (12%)
Necrosis, NOS	1 (1%)	1 (0%)
Necrosis, focal	18 (15%)	29 (12%)
Metamorphosis, fatty	28 (24%)	56 (22%)
Pigmentation, NOS	18 (15%)	50 (20%)
Hemosiderosis		1 (0%)
Focal cellular change	44 (38%)	89 (36%)
Angiectasis	1 (1%)	7 (3%)

TABLE A5. SUMMARY OF THE INCIDENCE OF NONNEOPLASTIC LESIONS IN MALE RATS IN THE LIFETIME FEED STUDY OF CROCIDOLITE ASBESTOS (Continued)

	Untreated Control	1% Crocidolite Asbestos
DIGESTIVE SYSTEM (Continued)		
#Liver/hepatocytes	(117)	(250)
Cytomegaly		1 (0%)
Hepatocytomegaly		1 (0%)
#Bile duct	(117)	(250)
Calculus, unknown gross or micro		1 (0%)
Dilatation, NOS		1 (0%)
Cyst, NOS	1 (1%)	1 (0%)
Multilocular cyst		1 (0%)
Inflammation, chronic	15 (13%)	18 (7%)
Fibrosis	10 (9%)	9 (4%)
Hyperplasia, NOS	45 (38%)	79 (32%)
Hyperplasia, focal		2 (1%)
#Pancreas	(117)	(249)
Ectopia	4 (3%)	20 (8%)
Inflammation, acute diffuse	1 (1%)	
Inflammation, chronic focal	1 (1%)	2 (1%)
Inflammation, chronic diffuse	2 (2%)	
Atrophy, NOS		1 (0%)
Atrophy, focal	14 (12%)	50 (20%)
Atrophy, diffuse	3 (3%)	10 (4%)
Hyperplasia, focal		2 (1%)
#Pancreatic acinus	(117)	(249)
Hyperplasia, focal	4 (3%)	16 (6%)
#Esophagus	(115)	(247)
Hyperkeratosis	8 (7%)	17 (7%)
Acanthosis	1 (1%)	
#Stomach	(116)	(249)
Mineralization	4 (3%)	3 (1%)
Cyst, NOS		2 (1%)
Edema, NOS		2 (1%)
Hemorrhage		2 (1%)
Ulcer, NOS		1 (0%)
Inflammation, acute focal	2 (2%)	5 (2%)
Inflammation, acute diffuse		1 (0%)
Inflammation, chronic	5 (4%)	3 (1%)
Inflammation, chronic focal	7 (6%)	7 (3%)
Inflammation, chronic diffuse	13 (11%)	28 (11%)
Ulcer, perforated	10 (9%)	21 (8%)
Fibrosis, diffuse	2 (2%)	
Adhesion, NOS		1 (0%)
Necrosis, focal	19 (16%)	47 (19%)
Hyperplasia, epithelial	4 (3%)	1 (0%)
Hyperplasia, focal		1 (0%)
Hyperkeratosis	17 (15%)	47 (19%)
Acanthosis	28 (24%)	60 (24%)
#Gastric submucosa	(116)	(249)
Edema, NOS		1 (0%)
#Gastric muscularis	(116)	(249)
Degeneration, NOS		3 (1%)
#Small intestine	(117)	(249)
Inflammation, acute focal	1 (1%)	
Necrosis, focal	1 (1%)	
#Duodenum	(117)	(249)
Inflammation, acute focal		1 (0%)
Necrosis, focal	1 (1%)	1 (0%)
#Jejunum	(117)	(249)
Diverticulum	1 (1%)	
Ulcer, perforated		1 (0%)
#Large intestine	(117)	(249)
Parasitism		3 (1%)

TABLE A5. SUMMARY OF THE INCIDENCE OF NONNEOPLASTIC LESIONS IN MALE RATS IN THE LIFETIME FEED STUDY OF CROCIDOLITE ASBESTOS (Continued)

	Untreated Control	1% Crocidolite Asbestos
DIGESTIVE SYSTEM (Continued)		
#Colon	(117)	(249)
Inflammation, chronic focal		2 (1%)
Inflammation, chronic diffuse	1 (1%)	
Fibrosis, focal	1 (1%)	
Parasitism	5 (4%)	9 (4%)
Necrosis, focal	2 (2%)	2 (1%)
Hyperplasia, focal		1 (0%)
#Colonic muscularis propria	(117)	(249)
Degeneration, NOS		1 (0%)
#Cecum	(117)	(249)
Hemorrhage	2 (2%)	
Inflammation, acute diffuse		1 (0%)
Inflammation, chronic diffuse	1 (1%)	1 (0%)
Parasitism		1 (0%)
Necrosis, focal	1 (1%)	2 (1%)
Necrosis, diffuse		1 (0%)
#Transverse colon	(117)	(249)
Inflammation, chronic focal		1 (0%)
Necrosis, focal		1 (0%)
URINARY SYSTEM		
#Kidney	(117)	(250)
Mineralization	12 (10%)	6 (2%)
Hydronephrosis		1 (0%)
Congestion, NOS		1 (0%)
Inflammation, acute focal	1 (1%)	
Abscess, NOS		1 (0%)
Inflammation, acute/chronic		1 (0%)
Inflammation, chronic	105 (90%)	220 (88%)
Inflammation, chronic diffuse		2 (1%)
Fibrosis, diffuse	1 (1%)	
Necrosis, focal		1 (0%)
Calcification, NOS		1 (0%)
Pigmentation, NOS	1 (1%)	1 (0%)
Hyperplasia, tubular cell	1 (1%)	1 (0%)
#Kidney/cortex	(117)	(250)
Cyst, NOS	5 (4%)	12 (5%)
Multiple cysts	1 (1%)	1 (0%)
#Renal papilla	(117)	(250)
Necrosis, NOS		1 (0%)
#Kidney/tubule	(117)	(250)
Pigmentation, NOS	43 (37%)	85 (34%)
Hyperplasia, focal		2 (1%)
*Ureter	(118)	(250)
Dilatation, NOS	1 (1%)	
Inflammation, chronic		1 (0%)
Hyperplasia, epithelial		1 (0%)
#Urinary bladder	(116)	(250)
Hemorrhage		5 (2%)
Inflammation, hemorrhagic	2 (2%)	1 (0%)
Inflammation, acute		1 (0%)
Inflammation, acute diffuse		1 (0%)
Inflammation, chronic		1 (0%)
Inflammation, chronic focal		2 (1%)
Inflammation, chronic diffuse	1 (1%)	3 (1%)
Granuloma, NOS		1 (0%)
Necrosis, NOS		1 (0%)
Necrosis, focal		1 (0%)
Pigmentation, NOS		1 (0%)

TABLE A5. SUMMARY OF THE INCIDENCE OF NONNEOPLASTIC LESIONS IN MALE RATS IN THE LIFETIME FEED STUDY OF CROCIDOLITE ASBESTOS (Continued)

	Untreated Control	1% Crocidolite Asbestos
URINARY SYSTEM		
#Urinary bladder (Continued)		
Hyperplasia, epithelial	2 (2%)	7 (3%)
Hyperplasia, diffuse		1 (0%)
Hyperplasia, papillary		3 (1%)
Polyp, inflammatory		2 (1%)
Metaplasia, squamous		1 (0%)
ENDOCRINE SYSTEM		
#Pituitary	(117)	(245)
Cyst, NOS		3 (1%)
Hemorrhage		1 (0%)
Abscess, NOS		1 (0%)
Necrosis, NOS		1 (0%)
Necrosis, focal		1 (0%)
Pigmentation, NOS		2 (1%)
Hyperplasia, focal	7 (6%)	12 (5%)
Angiectasis	7 (6%)	6 (2%)
#Adrenal	(117)	(250)
Congestion, NOS		1 (0%)
Hemorrhage		1 (0%)
Necrosis, NOS	1 (1%)	
Necrosis, focal	1 (1%)	1 (0%)
Metamorphosis, fatty		2 (1%)
Hyperplasia, focal	1 (1%)	
Angiectasis		5 (2%)
#Adrenal cortex	(117)	(250)
Congestion, NOS	2 (2%)	1 (0%)
Degeneration, NOS	1 (1%)	2 (1%)
Necrosis, focal		2 (1%)
Metamorphosis, fatty	31 (26%)	55 (22%)
Hyperplasia, focal	8 (7%)	19 (8%)
Angiectasis	4 (3%)	1 (0%)
#Adrenal medulla	(117)	(250)
Hyperplasia, NOS		1 (0%)
Hyperplasia, focal	30 (26%)	68 (27%)
Hyperplasia, diffuse		1 (0%)
#Thyroid	(116)	(249)
Follicular cyst, NOS	6 (5%)	22 (9%)
Hemorrhage		1 (0%)
Inflammation, chronic		1 (0%)
Pigmentation, NOS		1 (0%)
Hyperplasia, C-cell	13 (11%)	48 (19%)
Hyperplasia, follicular cell	1 (1%)	
#Parathyroid	(111)	(238)
Hyperplasia, NOS	16 (14%)	28 (12%)
#Pancreatic islets	(117)	(249)
Hyperplasia, focal	3 (3%)	7 (3%)
REPRODUCTIVE SYSTEM		
*Mammary gland	(118)	(250)
Galactocele	1 (1%)	2 (1%)
Cystic ducts	6 (5%)	7 (3%)
Fibrosis, focal	1 (1%)	
Pigmentation, NOS		1 (0%)
Hyperplasia, NOS	11 (9%)	11 (4%)
Hyperplasia, focal		2 (1%)
Hyperplasia, diffuse	1 (1%)	

TABLE A5. SUMMARY OF THE INCIDENCE OF NONNEOPLASTIC LESIONS IN MALE RATS IN THE LIFETIME FEED STUDY OF CROCIDOLITE ASBESTOS (Continued)

	Untreated Control	1% Crocidolite Asbestos
REPRODUCTIVE SYSTEM (Continued)		
*Preputial gland	(118)	(250)
Cystic ducts	5 (4%)	11 (4%)
Abscess, NOS	2 (2%)	3 (1%)
Inflammation, chronic		1 (0%)
Inflammation, chronic diffuse		1 (0%)
Hyperplasia, NOS	1 (1%)	
Hyperplasia, diffuse	1 (1%)	2 (1%)
Hyperkeratosis	1 (1%)	2 (1%)
#Prostate	(116)	(250)
Cyst, NOS		3 (1%)
Cystic ducts		1 (0%)
Hemorrhage	1 (1%)	3 (1%)
Inflammation, acute	1 (1%)	
Inflammation, acute focal	2 (2%)	1 (0%)
Inflammation, acute diffuse	1 (1%)	3 (1%)
Abscess, NOS	8 (7%)	12 (5%)
Inflammation active chronic		1 (0%)
Inflammation, acute/chronic	1 (1%)	4 (2%)
Inflammation, chronic		1 (0%)
Inflammation, chronic focal	25 (22%)	71 (28%)
Inflammation, chronic diffuse	7 (6%)	23 (9%)
Hyperplasia, NOS		1 (0%)
Hyperplasia, epithelial	3 (3%)	9 (4%)
Hyperplasia, focal	4 (3%)	7 (3%)
Hyperplasia, diffuse		2 (1%)
Angiectasis		1 (0%)
*Seminal vesicle	(118)	(250)
Cyst, NOS		9 (4%)
Cystic ducts	2 (2%)	2 (1%)
Hemorrhage		1 (0%)
Inflammation, acute focal		2 (1%)
Abscess, NOS		1 (0%)
Inflammation, chronic	1 (1%)	
Inflammation, chronic diffuse	1 (1%)	1 (0%)
Hyperplasia, focal		1 (0%)
Hyperplasia, diffuse	1 (1%)	5 (2%)
Hyperplasia, papillary		1 (0%)
#Testis	(118)	(249)
Granuloma, spermatic		1 (0%)
Degeneration, NOS	12 (10%)	17 (7%)
Infarct, NOS		2 (1%)
Hyperplasia, interstitial cell	51 (43%)	98 (39%)
*Epididymis	(118)	(250)
Inflammation, chronic focal		1 (0%)
Necrosis, fat	1 (1%)	8 (3%)
*Scrotum	(118)	(250)
Hemorrhage		1 (0%)
NERVOUS SYSTEM		
#Brain/meninges	(117)	(249)
Abscess, NOS		1 (0%)
#Cerebrum	(117)	(249)
Hemorrhage	1 (1%)	
Gliosis		1 (0%)
Necrosis, focal		2 (1%)
Malacia	1 (1%)	
#Brain	(117)	(249)
Hydrocephalus, NOS		1 (0%)
Hemorrhage	3 (3%)	1 (0%)
Necrosis, focal	1 (1%)	

TABLE A5. SUMMARY OF THE INCIDENCE OF NONNEOPLASTIC LESIONS IN MALE RATS IN THE LIFETIME FEED STUDY OF CROCIDOLITE ASBESTOS (Continued)

	Untreated Control	1% Crocidolite Asbestos
NERVOUS SYSTEM (Continued)		
*Spinal cord	(118)	(250)
Degeneration, NOS		1 (0%)
*Optic nerve	(118)	(250)
Necrosis, NOS		1 (0%)
SPECIAL SENSE ORGANS		
*Eye	(118)	(250)
Hemorrhage	5 (4%)	6 (2%)
Empyema	2 (2%)	3 (1%)
Synechia, anterior		1 (0%)
Synechia, posterior	2 (2%)	2 (1%)
Cataract	18 (15%)	24 (10%)
Phthisis bulbi	2 (2%)	4 (2%)
*Vitreous body	(118)	(250)
Inflammation, chronic		1 (0%)
Vascularization	1 (1%)	1 (0%)
*Eye/cornea	(118)	(250)
Inflammation, acute		1 (0%)
Inflammation, acute diffuse	1 (1%)	1 (0%)
Inflammation, chronic focal	2 (2%)	3 (1%)
Inflammation, chronic diffuse	7 (6%)	7 (3%)
Acanthosis		1 (0%)
*Eye/retina	(118)	(250)
Degeneration, NOS	41 (35%)	58 (23%)
*Eye/crystalline lens	(118)	(250)
Rupture		4 (2%)
*Eyelid	(118)	(250)
Hemorrhage		1 (0%)
Inflammation, acute		1 (0%)
Necrosis, NOS		1 (0%)
*Harderian gland	(118)	(250)
Inflammation, acute diffuse		1 (0%)
Inflammation, chronic diffuse	1 (1%)	1 (0%)
Atrophy, NOS		1 (0%)
*Ear canal	(118)	(250)
Necrosis, NOS	1 (1%)	
*Zymbal gland	(118)	(250)
Cystic ducts	17 (14%)	51 (20%)
Abscess, NOS	1 (1%)	2 (1%)
Inflammation, chronic	1 (1%)	
Inflammation, chronic focal		1 (0%)
Hyperkeratosis	1 (1%)	5 (2%)
Acanthosis		1 (0%)
MUSCULOSKELETAL SYSTEM		
*Skull	(118)	(250)
Osteopetrosis	1 (1%)	2 (1%)
*Mandible	(118)	(250)
Fibrous osteodystrophy		1 (0%)
*Sternum	(118)	(250)
Osteopetrosis		1 (0%)
Fibrous osteodystrophy	1 (1%)	
Hypoplasia, NOS		1 (0%)
*Rib	(118)	(250)
Degeneration, NOS		5 (2%)

TABLE A5. SUMMARY OF THE INCIDENCE OF NONNEOPLASTIC LESIONS IN MALE RATS IN THE LIFETIME FEED STUDY OF CROCIDOLITE ASBESTOS (Continued)

	Untreated Control	1% Crocidolite Asbestos
BODY CAVITIES		
*Abdominal cavity	(118)	(250)
Steatitis	1 (1%)	2 (1%)
Necrosis, fat	5 (4%)	12 (5%)
*Pleura	(118)	(250)
Hemorrhage	1 (1%)	
Inflammation, chronic diffuse	1 (1%)	
*Mesentery	(118)	(250)
Hemorrhage	1 (1%)	
Inflammation, acute diffuse	1 (1%)	
Inflammation, chronic focal	3 (3%)	1 (0%)
Granuloma, NOS	2 (2%)	
Necrosis, fat		1 (0%)
Pigmentation, NOS	1 (1%)	
ALL OTHER SYSTEMS		
*Multiple organs	(118)	(250)
Mineralization	4 (3%)	2 (1%)
Cyst, NOS	1 (1%)	
Inflammation, acute		1 (0%)
Inflammation, chronic	8 (7%)	21 (8%)
Inflammation, chronic diffuse		2 (1%)
Degeneration, NOS		1 (0%)
Necrosis, focal		2 (1%)
Pigmentation, NOS	1 (1%)	2 (1%)
Hyperplasia, NOS	3 (3%)	3 (1%)
Diaphragm		
Hernia, NOS	2	1
SPECIAL MORPHOLOGY SUMMARY		
None		

* Number of animals receiving complete necropsy examination; all gross lesions including masses examined microscopically.
 # Number of animals examined microscopically at this site

APPENDIX B

SUMMARY OF LESIONS IN FEMALE RATS IN THE LIFETIME FEED STUDY OF CROCIDOLITE ASBESTOS

		PAGE
TABLE B1	SUMMARY OF THE INCIDENCE OF NEOPLASMS IN FEMALE RATS IN THE LIFETIME FEED STUDY OF CROCIDOLITE ASBESTOS	103
TABLE B2	INDIVIDUAL ANIMAL TUMOR PATHOLOGY OF FEMALE RATS IN THE LIFETIME FEED STUDY OF CROCIDOLITE ASBESTOS	108
TABLE B3	ANALYSIS OF PRIMARY TUMORS IN FEMALE RATS IN THE LIFETIME FEED STUDY OF CROCIDOLITE ASBESTOS	138
TABLE B4a	HISTORICAL INCIDENCE OF LEUKEMIA IN FEMALE F344/N RATS RECEIVING NO TREATMENT IN LIFETIME FEED STUDIES	143
TABLE B4b	HISTORICAL INCIDENCE OF THYROID GLAND FOLLICULAR CELL TUMORS IN FEMALE F344/N RATS RECEIVING NO TREATMENT IN LIFETIME FEED STUDIES	143
TABLE B4c	HISTORICAL INCIDENCE OF THYROID GLAND C-CELL TUMORS IN FEMALE F344/N RATS RECEIVING NO TREATMENT IN LIFETIME FEED STUDIES	144
TABLE B4d	HISTORICAL INCIDENCE OF CLITORAL GLAND TUMORS IN FEMALE F344/N RATS RECEIVING NO TREATMENT IN LIFETIME FEED STUDIES	144
TABLE B5	SUMMARY OF THE INCIDENCE OF NONNEOPLASTIC LESIONS IN FEMALE RATS IN THE LIFETIME FEED STUDY OF CROCIDOLITE ASBESTOS	145

TABLE B1. SUMMARY OF THE INCIDENCE OF NEOPLASMS IN FEMALE RATS IN THE LIFETIME FEED STUDY OF CROCIDOLITE ASBESTOS

	Untreated Control	1% Crocidolite Asbestos
ANIMALS INITIALLY IN STUDY	118	250
ANIMALS NECROPSIED	118	250
ANIMALS EXAMINED HISTOPATHOLOGICALLY	118	250
INTEGUMENTARY SYSTEM		
*Skin	(118)	(250)
Squamous cell papilloma		1 (0%)
Squamous cell carcinoma	1 (1%)	1 (0%)
Squamous cell carcinoma, invasive		1 (0%)
Basal cell tumor		1 (0%)
Basal cell carcinoma	1 (1%)	
Trichoepithelioma	1 (1%)	
Keratoacanthoma		1 (0%)
Fibroma	1 (1%)	
Fibrosarcoma	2 (2%)	2 (1%)
Neurofibrosarcoma		1 (0%)
*Subcutaneous tissue	(118)	(250)
Squamous cell papilloma		1 (0%)
Squamous cell carcinoma, invasive	1 (1%)	1 (0%)
Follicular cell carcinoma, invasive		1 (0%)
Sarcoma, NOS	1 (1%)	1 (0%)
Fibroma	5 (4%)	9 (4%)
Fibrosarcoma	1 (1%)	3 (1%)
Lipoma	2 (2%)	
Neurofibroma		1 (0%)
RESPIRATORY SYSTEM		
*Nasal turbinate	(118)	(250)
Squamous cell carcinoma		1 (0%)
Adenocarcinoma, NOS		1 (0%)
#Trachea	(117)	(250)
Follicular cell carcinoma, invasive		1 (0%)
#Lung	(118)	(250)
Squamous cell carcinoma, metastatic		1 (0%)
Adenocarcinoma, NOS, metastatic	1 (1%)	2 (1%)
Alveolar/bronchiolar adenoma		1 (0%)
Alveolar/bronchiolar carcinoma	1 (1%)	2 (1%)
Cortical carcinoma, metastatic	1 (1%)	
C-cell carcinoma, metastatic		1 (0%)
Granulosa cell carcinoma, metastatic	1 (1%)	
Pheochromocytoma, metastatic		1 (0%)
Liposarcoma, metastatic		1 (0%)
HEMATOPOIETIC SYSTEM		
*Multiple organs	(118)	(250)
Malignant lymphoma, lymphocytic type		1 (0%)
Myelomonocytic leukemia		4 (2%)
Monocytic leukemia	41 (35%)	118 (47%)
Leukemia, mononuclear cell	1 (1%)	
#Spleen	(118)	(250)
Fibrosarcoma	1 (1%)	
#Mandibular lymph node	(118)	(250)
Squamous cell carcinoma, metastatic		2 (1%)
#Axillary lymph node	(118)	(250)
Sarcoma, NOS, metastatic	1 (1%)	
#Liver	(118)	(250)
Monocytic leukemia	2 (2%)	
#Thymus	(91)	(187)
Thymoma		1 (1%)

**TABLE B1. SUMMARY OF THE INCIDENCE OF NEOPLASMS IN FEMALE RATS IN THE LIFETIME
FEED STUDY OF CROCIDOLITE ASBESTOS (Continued)**

	Untreated Control	1% Crocidolite Asbestos
CIRCULATORY SYSTEM		
#Heart	(117)	(250)
Alveolar/bronchiolar carcinoma, metastatic		1 (0%)
#Myocardium	(117)	(250)
Neurilemoma	1 (1%)	
DIGESTIVE SYSTEM		
*Oral mucous membrane	(118)	(250)
Squamous cell papilloma	1 (1%)	
Squamous cell carcinoma		3 (1%)
*Tongue	(118)	(250)
Squamous cell carcinoma	1 (1%)	
*Tooth	(118)	(250)
Squamous cell carcinoma, invasive		1 (0%)
#Salivary gland	(117)	(248)
Fibrosarcoma		1 (0%)
#Liver	(118)	(250)
Neoplastic nodule	3 (3%)	6 (2%)
Hepatocellular carcinoma		1 (0%)
#Pancreas	(118)	(249)
Acinar cell adenoma	2 (2%)	5 (2%)
Acinar cell carcinoma		1 (0%)
*Pharynx	(118)	(250)
Squamous cell carcinoma		1 (0%)
#Stomach	(118)	(250)
Carcinoma, NOS		1 (0%)
Squamous cell papilloma		1 (0%)
Squamous cell carcinoma		1 (0%)
Adenomatous polyp, NOS		1 (0%)
#Duodenum	(118)	(250)
Leiomyoma	1 (1%)	
#Jejunum	(118)	(250)
Carcinoid tumor, malignant		1 (0%)
Mucinous cystadenocarcinoma	1 (1%)	
Leiomyosarcoma	1 (1%)	
URINARY SYSTEM		
#Kidney	(117)	(250)
Tubular cell adenoma	2 (2%)	
Tubular cell adenocarcinoma	1 (1%)	
Lipoma	1 (1%)	
Mixed tumor, malignant	1 (1%)	
ENDOCRINE SYSTEM		
#Pituitary	(116)	(247)
Carcinoma, NOS	9 (8%)	8 (3%)
Adenoma, NOS	42 (36%)	101 (41%)
#Adrenal	(118)	(250)
Cortical adenoma	4 (3%)	18 (7%)
Cortical carcinoma	2 (2%)	1 (0%)
Pheochromocytoma	14 (12%)	36 (14%)
Pheochromocytoma, malignant		3 (1%)
Ganglioneuroma		2 (1%)
#Adrenal medulla	(118)	(250)
Pheochromocytoma	3 (3%)	3 (1%)
Pheochromocytoma, malignant	2 (2%)	

TABLE B1. SUMMARY OF THE INCIDENCE OF NEOPLASMS IN FEMALE RATS IN THE LIFETIME FEED STUDY OF CROCIDOLITE ASBESTOS (Continued)

	Untreated Control	1% Crocidolite Asbestos
ENDOCRINE SYSTEM (Continued)		
#Thyroid	(117)	(250)
Follicular cell adenoma	8 (7%)	8 (3%)
Follicular cell carcinoma	3 (3%)	2 (1%)
C-cell adenoma	4 (3%)	23 (9%)
C-cell carcinoma	12 (10%)	46 (18%)
#Parathyroid	(108)	(224)
Adenoma, NOS	1 (1%)	1 (0%)
#Pancreatic islets	(118)	(249)
Islet cell adenoma	2 (2%)	5 (2%)
Islet cell carcinoma	3 (3%)	6 (2%)
REPRODUCTIVE SYSTEM		
*Mammary gland	(118)	(250)
Adenoma, NOS	2 (2%)	1 (0%)
Adenocarcinoma, NOS	16 (14%)	23 (9%)
Fibroadenoma	48 (41%)	112 (45%)
*Preputial gland	(118)	(250)
Carcinoma, NOS		1 (0%)
Squamous cell carcinoma	4 (3%)	22 (9%)
Basal cell carcinoma	1 (1%)	
Adenoma, NOS	1 (1%)	2 (1%)
Keratoacanthoma		1 (0%)
#Uterus	(116)	(248)
Adenocarcinoma, NOS	1 (1%)	2 (1%)
Papillary adenoma	1 (1%)	1 (0%)
Leiomyoma		1 (0%)
Leiomyosarcoma	1 (1%)	
Endometrial stromal polyp	19 (16%)	38 (15%)
Endometrial stromal sarcoma	1 (1%)	3 (1%)
#Cervix uteri	(116)	(248)
Squamous cell carcinoma		1 (0%)
Sarcoma, NOS		1 (0%)
Endometrial stromal sarcoma, invasive		1 (0%)
#Uterus/endometrium	(116)	(248)
Papillary adenoma		1 (0%)
#Fallopian tube	(116)	(248)
Granulosa cell carcinoma, invasive	1 (1%)	
#Ovary	(116)	(248)
Granulosa cell tumor	1 (1%)	4 (2%)
Granulosa cell carcinoma	1 (1%)	1 (0%)
NERVOUS SYSTEM		
#Brain/meninges	(118)	(248)
Meningioma	1 (1%)	
#Cerebrum	(118)	(248)
Carcinoma, NOS, invasive	4 (3%)	5 (2%)
Glioma, invasive	1 (1%)	
Astrocytoma		1 (0%)
Meningioma	1 (1%)	
#Brain	(118)	(248)
Carcinosarcoma, metastatic	1 (1%)	
#Cerebellum	(118)	(248)
Carcinoma, NOS, invasive	3 (3%)	3 (1%)
Granular cell tumor, NOS	1 (1%)	
Glioma, NOS	1 (1%)	
Astrocytoma	1 (1%)	

TABLE B1. SUMMARY OF THE INCIDENCE OF NEOPLASMS IN FEMALE RATS IN THE LIFETIME FEED STUDY OF CROCIDOLITE ASBESTOS (Continued)

	Untreated Control	1% Crocidolite Asbestos
NERVOUS SYSTEM (Continued)		
*Medulla oblongata	(118)	(248)
Astrocytoma, invasive		1 (0%)
*Spinal cord	(118)	(250)
Astrocytoma	1 (1%)	
SPECIAL SENSE ORGANS		
*Eyelid	(118)	(250)
Squamous cell carcinoma		1 (0%)
*Eye/conjunctiva	(118)	(250)
Squamous cell carcinoma, invasive	1 (1%)	
*Harderian gland	(118)	(250)
Squamous cell carcinoma	1 (1%)	
Squamous cell carcinoma, metastatic	1 (1%)	
*Zymbal gland	(118)	(250)
Carcinoma in-situ, NOS		1 (0%)
Squamous cell papilloma		1 (0%)
Squamous cell carcinoma		4 (2%)
Carcinosarcoma	1 (1%)	
MUSCULOSKELETAL SYSTEM		
*Skull	(118)	(250)
Squamous cell carcinoma, invasive	1 (1%)	
*Maxilla	(118)	(250)
Squamous cell carcinoma, invasive		1 (0%)
*Mandible	(118)	(250)
Squamous cell carcinoma, invasive		3 (1%)
BODY CAVITIES		
*Mediastinum	(118)	(250)
Mesothelioma, malignant		1 (0%)
ALL OTHER SYSTEMS		
*Multiple organs	(118)	(250)
Squamous cell carcinoma, invasive		2 (1%)
Squamous cell carcinoma, metastatic		1 (0%)
Adenocarcinoma, NOS, invasive	1 (1%)	
Alveolar/bronchiolar carcinoma, metastatic	1 (1%)	
C-cell carcinoma, metastatic	1 (1%)	1 (0%)
Endometrial stromal sarcoma, invasive	1 (1%)	2 (1%)
Carcinosarcoma, invasive	1 (1%)	
Mesothelioma, invasive		1 (0%)
Orbital region		
Squamous cell carcinoma, metastatic	1	
Adipose tissue		
Cortical carcinoma, invasive		1

TABLE B1. SUMMARY OF THE INCIDENCE OF NEOPLASMS IN FEMALE RATS IN THE LIFETIME FEED STUDY OF CROCIDOLITE ASBESTOS (Continued)

	Untreated Control	1% Crocidolite Asbestos
ANIMAL DISPOSITION SUMMARY		
Animals initially in study	118	250
Natural death	21	30
Moribund sacrifice	85	195
Terminal sacrifice	12	25
TUMOR SUMMARY		
Total animals with primary tumors**	115	242
Total primary tumors	291	661
Total animals with benign tumors	91	190
Total benign tumors	166	378
Total animals with malignant tumors	80	187
Total malignant tumors	120	273
Total animals with secondary tumors##	17	28
Total secondary tumors	24	36
Total animals with tumors-- uncertain benign or malignant	5	10
Total uncertain tumors	5	10

* Number of animals receiving complete necropsy examination; all gross lesions including masses examined microscopically.

** Primary tumors: all tumors except secondary tumors

Number of animals examined microscopically at this site

Secondary tumors: metastatic tumors or tumors invasive into an adjacent organ

TABLE B2. INDIVIDUAL ANIMAL TUMOR PATHOLOGY OF FEMALE RATS IN THE LIFETIME FEED STUDY OF CROCIDOLITE ASBESTOS: UNTREATED CONTROL

ANIMAL NUMBER	578	594	604	607	578	621	623	626	556	559	637	556	645	556	556	663	663	567	666	666	666	666	666	666	666	666	
WEEKS ON STUDY	660	677	677	677	688	688	688	688	688	688	688	688	688	688	688	688	688	688	688	688	688	688	688	688	688	688	
INTEGUMENTARY SYSTEM																											
Skin	+	+	+	+	+	+	+	+	+	+	+	+	+	+	+	+	+	+	+	+	+	+	+	+	+	+	
Squamous cell carcinoma																											
Basal cell carcinoma																											
Trichoepithelioma																											
Fibroma																											
Fibrosarcoma																											
Subcutaneous tissue	+	+	+	+	+	+	+	+	+	+	+	+	+	+	+	+	+	+	+	+	+	+	+	+	+	+	
Squamous cell carcinoma, invasive																											
Sarcoma, NOS																											
Fibroma																											
Fibrosarcoma																											
Lipoma																											
RESPIRATORY SYSTEM																											
Lungs and bronchi	+	+	+	+	+	+	+	+	+	+	+	+	+	+	+	+	+	+	+	+	+	+	+	+	+	+	
Adenocarcinoma, NOS, metastatic																											
Alveolar/bronchiolar carcinoma																											
Cortical carcinoma, metastatic																											
Granulosa cell carcinoma, metastatic																											
Trachea	+	+	+	+	+	+	+	+	+	+	+	+	+	+	+	+	+	+	+	+	+	+	+	+	+	+	
HEMATOPOIETIC SYSTEM																											
Bone marrow	+	+	+	+	+	+	+	+	+	+	+	+	+	+	+	+	+	+	+	+	+	+	+	+	+	+	
Spleen	+	+	+	+	+	+	+	+	+	+	+	+	+	+	+	+	+	+	+	+	+	+	+	+	+	+	
Fibrosarcoma																											
Lymph nodes	+	+	+	+	+	+	+	+	+	+	+	+	+	+	+	+	+	+	+	+	+	+	+	+	+	+	
Sarcoma, NOS, metastatic																											
Thymus	+	-	+	+	+	+	+	+	-	+	+	+	+	+	+	+	+	+	+	+	+	+	+	+	+	+	
CIRCULATORY SYSTEM																											
Heart	+	+	+	+	+	+	+	+	+	+	+	+	+	+	+	+	+	+	+	+	+	+	+	+	+	+	
Neurilemoma																											
DIGESTIVE SYSTEM																											
Oral cavity	N	N	N	N	N	N	N	N	N	N	N	N	N	N	N	N	N	N	N	N	N	N	N	N	N	N	
Squamous cell papilloma																											
Squamous cell carcinoma																											
Salivary gland																											
Liver	+	+	+	+	+	+	+	+	+	+	+	+	+	+	+	+	+	+	+	+	+	+	+	+	+	+	
Neoplastic nodule																											
Monocytic leukemia	X																										
Bile duct	+	+	+	+	+	+	+	+	+	+	+	+	+	+	+	+	+	+	+	+	+	+	+	+	+	+	
Pancreas	+	+	+	+	+	+	+	+	+	+	+	+	+	+	+	+	+	+	+	+	+	+	+	+	+	+	
Acinar cell adenoma																											
Esophagus	-	-	+	+	+	+	+	+	+	+	+	+	+	+	+	+	+	+	+	+	+	+	+	+	+	+	
Stomach	+	+	+	+	+	+	+	+	+	+	+	+	+	+	+	+	+	+	+	+	+	+	+	+	+	+	
Small intestine	+	+	+	+	+	+	+	+	+	+	+	+	+	+	+	+	+	+	+	+	+	+	+	+	+	+	
Mucinous cystadenocarcinoma																											
Leiomyoma																											
Leiomyosarcoma																											
Large intestine	+	+	+	+	+	+	+	+	+	+	+	+	+	+	+	+	+	+	+	+	+	+	+	+	+	+	
URINARY SYSTEM																											
Kidney	+	+	+	+	+	+	+	+	+	+	+	+	+	+	+	+	+	+	+	+	+	+	+	+	+	+	
Tubular cell adenoma																											
Tubular cell adenocarcinoma																											
Lipoma																											
Mixed tumor, malignant																											
Urinary bladder	+	+	+	+	+	+	+	+	+	+	+	+	+	+	+	+	+	+	+	+	+	+	+	+	+	+	

+ : Tissue examined microscopically
 - : Required tissue not examined microscopically
 X : Tumor incidence
 N : Necropsy, no autolysis, no microscopic examination
 S : Animal missexed
 : No tissue information submitted
 C : Necropsy, no histology due to protocol
 A : Autolysis
 M : Animal missing
 B : No necropsy performed

**TABLE B2. INDIVIDUAL ANIMAL TUMOR PATHOLOGY OF FEMALE RATS: UNTREATED CONTROL
(Continued)**

ANIMAL NUMBER	660	666	665	665	661	666	667	660	661	664	661	662	665	663	663	665	666	667	668	662	666	665	665	667	666	
WEEKS ON STUDY	08	08	10	11	11	11	11	11	11	11	11	11	11	11	11	11	11	11	11	11	11	11	11	11	11	
INTEGUMENTARY SYSTEM																										
Skin	+																									
Squamous cell carcinoma																										
Basal cell carcinoma																										
Trichoepithelioma																										
Fibroma																										
Fibrosarcoma																										
Subcutaneous tissue	+																									
Squamous cell carcinoma, invasive																										
Sarcoma, NOS																										
Fibroma	X X																									
Fibrosarcoma																										
Lipoma																										
RESPIRATORY SYSTEM																										
Lungs and bronchi	+																									
Adenocarcinoma, NOS, metastatic																										
Alveolar/bronchiolar carcinoma																										
Cortical carcinoma, metastatic																										
Granulosa cell carcinoma, metastatic																										
Trachea	+																									
HEMATOPOIETIC SYSTEM																										
Bone marrow	+																									
Spleen	+																									
Fibrosarcoma																										
Lymph nodes	+																									
Sarcoma, NOS, metastatic																										
Thymus	+ + + - + - + + - + - + + + - - + + - + + - + +																									
CIRCULATORY SYSTEM																										
Heart	+																									
Neurilemoma																										
DIGESTIVE SYSTEM																										
Oral cavity	N N																									
Squamous cell papilloma																										
Squamous cell carcinoma																										
Salivary gland	+																									
Liver	+																									
Neoplastic nodule																										
Monocytic leukemia																										
Bile duct	+																									
Pancreas	+																									
Acinar cell adenoma																										
Esophagus	+																									
Stomach	+																									
Small intestine	+																									
Mucinous cystadenocarcinoma																										
Leiomyoma																										
Leiomyosarcoma																										
Large intestine	+																									
URINARY SYSTEM																										
Kidney	+																									
Tubular cell adenoma																										
Tubular cell adenocarcinoma																										
Lipoma																										
Mixed tumor, malignant																										
Urinary bladder	+																									

TABLE B2. INDIVIDUAL ANIMAL TUMOR PATHOLOGY OF FEMALE RATS: UNTREATED CONTROL
(Continued)

ANIMAL NUMBER	636	559	564	574	583	589	597	598	604	609	606	605	602	604	603	604	603	604	605	608	608	609	611	612	616		
WEEKS ON STUDY	17	18	18	18	18	18	11	11	22	22	22	22	22	22	22	22	22	22	22	22	22	22	22	22	22		
INTEGUMENTARY SYSTEM																											
Skin	+	+	+	+	+	+	+	+	+	+	+	+	+	+	+	+	+	+	+	+	+	+	+	+	+	+	
Squamous cell carcinoma																											
Basal cell carcinoma																											
Trichoepithelioma																											
Fibroma																											
Fibrosarcoma																											
Subcutaneous tissue	+	+	+	+	+	+	+	+	+	+	+	+	+	+	+	+	+	+	+	+	+	+	+	+	+	+	
Squamous cell carcinoma, invasive																											
Sarcoma, NOS						X																					
Fibroma																											
Fibrosarcoma																											
Lipoma										X								X									
RESPIRATORY SYSTEM																											
Lungs and bronchi	+	+	+	+	+	+	+	+	+	+	+	+	+	+	+	+	+	+	+	+	+	+	+	+	+	+	
Adenocarcinoma, NOS, metastatic																											
Alveolar/bronchiolar carcinoma																											
Cortical carcinoma, metastatic																											
Granulosa cell carcinoma, metastatic																											
Trachea	+	+	-	+	+	+	+	+	+	+	+	+	+	+	+	+	+	+	+	+	+	+	+	+	+	+	
HEMATOPOIETIC SYSTEM																											
Bone marrow	+	+	+	+	+	+	+	+	+	+	+	+	+	+	+	+	+	+	+	+	+	+	+	+	+	+	
Spleen	+	+	+	+	+	+	+	+	+	+	+	+	+	+	+	+	+	+	+	+	+	+	+	+	+	+	
Fibrosarcoma																											
Lymph nodes	+	+	+	+	+	+	+	+	+	+	+	+	+	+	+	+	+	+	+	+	+	+	+	+	+	+	
Sarcoma, NOS, metastatic																											
Thymus	-	+	-	-	+	+	+	+	+	-	-	-	+	-	+	+	-	-	+	-	+	-	+	+	-	-	
CIRCULATORY SYSTEM																											
Heart	+	+	-	+	+	+	+	+	+	+	+	+	+	+	+	+	+	+	+	+	+	+	+	+	+	+	
Neurilemoma																											
DIGESTIVE SYSTEM																											
Oral cavity	N	N	N	N	N	N	N	N	N	N	N	N	N	N	N	N	N	N	N	N	N	N	N	N	N	N	
Squamous cell papilloma																											
Squamous cell carcinoma																											
Salivary gland	+	+	-	+	+	+	+	+	+	+	+	+	+	+	+	+	+	+	+	+	+	+	+	+	+	+	
Liver	+	+	+	+	+	+	+	+	+	+	+	+	+	+	+	+	+	+	+	+	+	+	+	+	+	+	
Neoplastic nodule																											
Monocytic leukemia			X																								
Bile duct	+	+	+	+	+	+	+	+	+	+	+	+	+	+	+	+	+	+	+	+	+	+	+	+	+	+	
Pancreas	+	+	+	+	+	+	+	+	+	+	+	+	+	+	+	+	+	+	+	+	+	+	+	+	+	+	
Acinar cell adenoma																											
Esophagus	+	+	+	+	+	+	+	+	+	+	+	+	+	+	+	+	+	+	+	+	+	+	+	+	+	+	
Stomach	+	+	+	+	+	+	+	+	+	+	+	+	+	+	+	+	+	+	+	+	+	+	+	+	+	+	
Small intestine	+	+	+	+	+	+	+	+	+	+	+	+	+	+	+	+	+	+	+	+	+	+	+	+	+	+	
Mucinous cystadenocarcinoma																											
Leiomyoma																											
Leiomyosarcoma																											
Large intestine	+	+	+	+	+	+	+	+	+	+	+	+	+	+	+	+	+	+	+	+	+	+	+	+	+	+	
URINARY SYSTEM																											
Kidney	+	+	+	+	+	+	+	+	+	+	+	+	+	-	+	+	+	+	+	+	+	+	+	+	+	+	
Tubular cell adenoma																											
Tubular cell adenocarcinoma																											
Lipoma																											
Mixed tumor, malignant																											
Urinary bladder	+	+	+	+	+	+	+	+	+	+	+	+	+	+	+	+	+	+	+	+	+	+	+	+	+	+	

**TABLE B2. INDIVIDUAL ANIMAL TUMOR PATHOLOGY OF FEMALE RATS: UNTREATED CONTROL
(Continued)**

ANIMAL NUMBER	5 5	5 6	6 0	5 7	6 9	6 3	5 2	5 8	5 7	6 5	6 5	5 7	6 7	6 7	5 8	6 9	6 9	5 7	5 0	5 3	5 6	6 5	5 0	5 6	
WEEKS ON STUDY	1 0	1 3	1 3	1 1	1 1	1 1	1 4	1 4	1 4	1 4	1 4	1 5	1 6	1 6	1 6	1 7	1 7	1 7	1 8	1 8	1 3	1 6	1 5	1 3	1 6
INTEGUMENTARY SYSTEM																									
Skin	+	+	+	+	+	+	+	+	+	+	+	+	+	+	+	+	+	+	+	+	+	+	+	+	+
Squamous cell carcinoma																									
Basal cell carcinoma																									
Trichoepithelioma																									
Fibroma																									
Fibrosarcoma																									
Subcutaneous tissue	+	+	+	+	+	+	+	+	+	+	+	+	+	+	+	+	+	+	+	+	+	+	+	+	+
Squamous cell carcinoma, invasive																									
Sarcoma, NOS																									
Fibroma																									
Fibrosarcoma																									
Lipoma																									
RESPIRATORY SYSTEM																									
Lungs and bronchi	+	+	+	+	+	+	+	+	+	+	+	+	+	+	+	+	+	+	+	+	+	+	+	+	+
Adenocarcinoma, NOS, metastatic																									
Alveolar/bronchiolar carcinoma																									
Cortical carcinoma, metastatic																									
Granulosa cell carcinoma, metastatic																									
Trachea	+	+	+	+	+	+	+	+	+	+	+	+	+	+	+	+	+	+	+	+	+	+	+	+	+
HEMATOPOIETIC SYSTEM																									
Bone marrow	+	+	+	+	+	+	+	+	+	+	+	+	+	+	+	+	+	+	+	+	+	+	+	+	+
Spleen	+	+	+	+	+	+	+	+	+	+	+	+	+	+	+	+	+	+	+	+	+	+	+	+	+
Fibrosarcoma																									
Lymph nodes	+	+	+	+	+	+	+	+	+	+	+	+	+	+	+	+	+	+	+	+	+	+	+	+	+
Sarcoma, NOS, metastatic																									
Thymus	+	+	+	+	-	-	+	+	+	+	+	+	+	+	+	+	+	+	+	+	+	+	+	+	+
CIRCULATORY SYSTEM																									
Heart	+	+	+	+	+	+	+	+	+	+	+	+	+	+	+	+	+	+	+	+	+	+	+	+	+
Neurilemoma																									
DIGESTIVE SYSTEM																									
Oral cavity	N	N	N	N	N	N	N	N	N	N	N	N	N	N	N	N	N	N	N	N	N	N	N	N	N
Squamous cell papilloma																									
Squamous cell carcinoma																									
Salivary gland	+	+	+	+	+	+	+	+	+	+	+	+	+	+	+	+	+	+	+	+	+	+	+	+	+
Liver	+	+	+	+	+	+	+	+	+	+	+	+	+	+	+	+	+	+	+	+	+	+	+	+	+
Neoplastic nodule																									
Monocytic leukemia																									
Bile duct	+	+	+	+	+	+	+	+	+	+	+	+	+	+	+	+	+	+	+	+	+	+	+	+	+
Pancreas	+	+	+	+	+	+	+	+	+	+	+	+	+	+	+	+	+	+	+	+	+	+	+	+	+
Acinar cell adenoma																									
Esophagus	+	+	+	+	+	+	+	+	+	+	+	+	+	+	+	+	+	+	+	+	+	+	+	+	+
Stomach	+	+	+	+	+	+	+	+	+	+	+	+	+	+	+	+	+	+	+	+	+	+	+	+	+
Small intestine	+	+	+	+	+	+	+	+	+	+	+	+	+	+	+	+	+	+	+	+	+	+	+	+	+
Mucinous cystadenocarcinoma																									
Leiomyoma																									
Leiomyosarcoma																									
Large intestine	+	+	+	+	+	+	+	+	+	+	+	+	+	+	+	+	+	+	+	+	+	+	+	+	+
URINARY SYSTEM																									
Kidney	+	+	+	+	+	+	+	+	+	+	+	+	+	+	+	+	+	+	+	+	+	+	+	+	+
Tubular cell adenoma																									
Tubular cell adenocarcinoma																									
Lipoma																									
Mixed tumor, malignant																									
Urinary bladder	+	+	+	+	+	+	+	+	+	+	+	+	+	+	+	+	+	+	+	+	+	+	+	+	+

TABLE B2. INDIVIDUAL ANIMAL TUMOR PATHOLOGY OF FEMALE RATS: UNTREATED CONTROL (Continued)

ANIMAL NUMBER	620	666	653	566	571	591	593	600	617	622	622	622	633	633	642	644	647	650	TOTAL TISSUES TUMORS
WEEKS ON STUDY	14	14	14	14	14	14	14	14	14	14	14	14	14	14	14	14	14	14	
INTEGUMENTARY SYSTEM																			
Skin	+	+	+	+	+	+	+	+	+	+	+	+	+	+	+	+	+	+	*118
Squamous cell carcinoma																			1
Basal cell carcinoma																			1
Trichoepithelioma																			1
Fibroma																			1
Fibrosarcoma																X			2
Subcutaneous tissue	+	+	+	+	+	+	+	+	+	+	+	+	+	+	+	+	+	+	*118
Squamous cell carcinoma, invasive																			1
Sarcoma, NOS																			1
Fibroma																			5
Fibrosarcoma																			1
Lipoma																			2
RESPIRATORY SYSTEM																			
Lungs and bronchi	+	+	+	+	+	+	+	+	+	+	+	+	+	+	+	+	+	+	118
Adenocarcinoma, NOS, metastatic																			1
Alveolar/bronchiolar carcinoma																			1
Cortical carcinoma, metastatic																	X		1
Granulosa cell carcinoma, metastatic																			1
Trachea	+	+	+	+	+	+	+	+	+	+	+	+	+	+	+	+	+	+	117
HEMATOPOIETIC SYSTEM																			
Bone marrow	+	+	+	+	+	+	+	+	+	+	+	+	+	+	+	+	+	+	118
Spleen	+	+	+	+	+	+	+	+	+	+	+	+	+	+	+	+	+	+	118
Fibrosarcoma						X													1
Lymph nodes	+	+	+	+	+	+	+	+	+	+	+	+	+	+	+	+	+	+	118
Sarcoma, NOS, metastatic																			1
Thymus	-	+	+	+	-	+	+	+	+	+	+	+	+	+	+	+	+	+	91
CIRCULATORY SYSTEM																			
Heart	+	+	+	+	+	+	+	+	+	+	+	+	+	+	+	+	+	+	117
Neurilemoma																			1
DIGESTIVE SYSTEM																			
Oral cavity	N	N	N	N	N	N	N	N	N	N	N	N	N	N	N	N	N	N	*118
Squamous cell papilloma	X																		1
Squamous cell carcinoma																			1
Salivary gland	+	+	+	+	+	+	+	+	+	+	+	+	+	+	+	+	+	+	117
Liver	+	+	+	+	+	+	+	+	+	+	+	+	+	+	+	+	+	+	118
Neoplastic nodule																			3
Monocytic leukemia																			2
Bile duct	+	+	+	+	+	+	+	+	+	+	+	+	+	+	+	+	+	+	118
Pancreas	+	+	+	+	+	+	+	+	+	+	+	+	+	+	+	+	+	+	118
Acinar cell adenoma					X		X												2
Esophagus	+	+	+	+	+	+	+	+	+	+	+	+	+	+	+	+	+	+	118
Stomach	+	+	+	+	+	+	+	+	+	+	+	+	+	+	+	+	+	+	118
Small intestine	+	+	+	+	+	+	+	+	+	+	+	+	+	+	+	+	+	+	118
Mucinous cystadenocarcinoma																			1
Leiomyoma																X			1
Leiomyosarcoma																			1
Large intestine	+	+	+	+	+	+	+	+	+	+	+	+	+	+	+	+	+	+	118
URINARY SYSTEM																			
Kidney	+	+	+	+	+	+	+	+	+	+	+	+	+	+	+	+	+	+	117
Tubular cell adenoma							X						X						2
Tubular cell adenocarcinoma																			1
Lipoma																			1
Mixed tumor, malignant																			1
Urinary bladder	+	+	+	+	+	+	+	+	+	+	+	-	+	+	+	+	+	+	116

* Animals necropsied

TABLE B2. INDIVIDUAL ANIMAL TUMOR PATHOLOGY OF FEMALE RATS: UNTREATED CONTROL (Continued)

ANIMAL NUMBER	578	594	604	609	579	582	623	616	568	598	637	598	561	646	551	590	562	630	618	622	656	629	629	653	653		
WEEKS ON STUDY	000	070	070	079	083	083	044	055	086	087	087	091	091	091	092	092	093	094	095	095	099	099	099	099	097		
ENDOCRINE SYSTEM																											
Pituitary	+	+	+	+	+	+	+	+	+	+	+	+	+	+	+	+	+	+	+	+	+	+	+	+	+	+	
Carcinoma, NOS														X													
Adenoma, NOS		X		X	X	X	X				X	X											X				
Adrenal	+	+	+	+	+	+	+	+	+	+	+	+	+	+	+	+	+	+	+	+	+	+	+	+	+	+	
Cortical adenoma																											
Cortical carcinoma																											
Pheochromocytoma																											
Pheochromocytoma, malignant																							X				
Thyroid	+	+	+	+	+	+	+	+	+	+	+	+	+	+	+	+	+	+	+	+	+	+	+	+	+	+	
Follicular cell adenoma																											
Follicular cell carcinoma																											
C-cell adenoma																											
C-cell carcinoma																											
Parathyroid	+	+	+	+	+	+	+	+	+	-	-	-	+	+	+	+	+	+	+	+	+	+	+	+	+	+	
Adenoma, NOS																											
Pancreatic islets	+	+	+	+	+	+	+	+	+	+	+	+	+	+	+	+	+	+	+	+	+	+	+	+	+	+	
Islet cell adenoma																											
Islet cell carcinoma																											
REPRODUCTIVE SYSTEM																											
Mammary gland	+	+	+	+	+	+	+	+	+	+	+	+	+	+	+	+	+	+	+	+	+	+	+	+	+	+	
Adenoma, NOS																											
Adenocarcinoma, NOS																											
Fibroadenoma																											
Preputial/clitoral gland	N	N	N	N	N	N	N	N	N	N	N	N	N	N	N	N	N	N	N	N	N	N	N	N	N	N	
Squamous cell carcinoma																											
Basal cell carcinoma																											
Adenoma, NOS																											
Uterus	+	+	+	+	+	+	+	+	+	+	+	+	+	+	+	+	+	+	+	+	+	+	+	+	+	+	
Adenocarcinoma, NOS																											
Papillary adenoma																											
Granulosa cell carcinoma, invasive																											
Leiomyosarcoma																											
Endometrial stromal polyp																											
Endometrial stromal sarcoma																											
Ovary	+	+	+	+	+	+	+	+	+	+	+	+	+	+	+	+	+	+	+	+	+	+	+	+	+	+	
Granulosa cell tumor																											
Granulosa cell carcinoma																											
NERVOUS SYSTEM																											
Brain	+	+	+	+	+	+	+	+	+	+	+	+	+	+	+	+	+	+	+	+	+	+	+	+	+	+	
Carcinoma, NOS, invasive																											
Carcinosarcoma, metastatic																											
Granular cell tumor, NOS																											
Glioma, NOS																											
Glioma, invasive																											
Astrocytoma																											
Meningioma																											
Spinal cord	N	N	N	N	N	N	N	N	N	N	N	N	N	N	N	N	N	N	N	N	N	N	N	N	N	N	
Astrocytoma																											
SPECIAL SENSE ORGANS																											
Eye appendages	N	N	N	N	N	N	N	N	N	N	N	N	N	N	N	N	N	N	N	N	N	N	N	N	N	N	
Squamous cell carcinoma, invasive																											
Harderian gland	N	N	N	N	N	N	N	N	N	N	N	N	N	N	N	N	N	N	N	N	N	N	N	N	N	N	
Squamous cell carcinoma																											
Squamous cell carcinoma, metastatic																											
Zymbal gland	N	N	N	N	N	N	N	N	N	N	N	N	N	N	N	N	N	N	N	N	N	N	N	N	N	N	
Carcinosarcoma																											
MUSCULOSKELETAL SYSTEM																											
Bone	N	N	N	N	N	N	N	N	N	N	N	N	N	N	N	N	N	N	N	N	N	N	N	N	N	N	
Squamous cell carcinoma, invasive																											
ALL OTHER SYSTEMS																											
Multiple organs, NOS	N	N	N	N	N	N	N	N	N	N	N	N	N	N	N	N	N	N	N	N	N	N	N	N	N	N	
Adenocarcinoma, NOS, invasive																											
Alveolar/bronchiolar carcinoma, metastatic																											
C-cell carcinoma, metastatic																											
Endometrial stromal sarcoma, invasive																											
Carcinosarcoma, invasive																											
Monocytic leukemia																											
Leukemia, mononuclear cell	X				X	X						X	X	X													
Orbital region																											
Squamous cell carcinoma, metastatic																											

TABLE B2. INDIVIDUAL ANIMAL TUMOR PATHOLOGY OF FEMALE RATS: UNTREATED CONTROL
(Continued)

ANIMAL NUMBER	6606	6604	6605	6609	6612	6615	6616	6617	6618	6619	6620	6621	6622	6623	6624	6625	6626	6627	6628	6629	6630	6631	6632	6633	6634	6635	6636	6637	6638	6639	6640			
WEEKS ON STUDY	08	08	10	10	11	11	11	11	11	11	11	11	11	11	11	11	11	11	11	11	11	11	11	11	11	11	11	11	11	11	11			
ENDOCRINE SYSTEM																																		
Pituitary	+	+	+	+	+	+	+	+	+	+	+	+	+	+	+	+	+	+	+	+	+	+	+	+	+	+	+	+	+	+	+	+		
Carcinoma, NOS																																		
Adenoma, NOS	X	X			X		X		X	X	X																						X	
Adrenal	+	+	+	+	+	+	+	+	+	+	+	+	+	+	+	+	+	+	+	+	+	+	+	+	+	+	+	+	+	+	+	+		
Cortical adenoma																																		
Cortical carcinoma																																		
Pheochromocytoma											X	X																					X	
Pheochromocytoma, malignant																																		
Thyroid	+	+	+	+	+	+	+	+	+	+	+	+	+	+	+	+	+	+	+	+	+	+	+	+	+	+	+	+	+	+	+	+	+	
Follicular cell adenoma																																		
Follicular cell carcinoma																																		
C-cell adenoma																																		
C-cell carcinoma																																		
Parathyroid	+	+	+	+	+	+	+	+	+	+	+	+	+	+	+	+	+	+	+	+	+	+	+	+	+	+	+	+	+	+	+	+	+	
Adenoma, NOS																																		
Pancreatic islets	+	+	+	+	+	+	+	+	+	+	+	+	+	+	+	+	+	+	+	+	+	+	+	+	+	+	+	+	+	+	+	+	+	
Islet cell adenoma																																		
Islet cell carcinoma																																		
REPRODUCTIVE SYSTEM																																		
Mammary gland	+	+	+	+	+	+	+	+	+	+	+	+	+	+	+	+	+	+	+	+	+	+	+	+	+	+	+	+	+	+	+	+	+	
Adenoma, NOS																																		
Adenocarcinoma, NOS																																		
Fibroadenoma	X							X																										
Preputial/clitoral gland	N	N	N	N	N	N	N	N	N	N	N	N	N	N	N	N	N	N	N	N	N	N	N	N	N	N	N	N	N	N	N	N	N	
Squamous cell carcinoma																																		
Basal cell carcinoma																																		
Adenoma, NOS																																		
Uterus	+	+	+	+	+	+	+	+	+	+	+	+	+	+	+	+	+	+	+	+	+	+	+	+	+	+	+	+	+	+	+	+	+	
Adenocarcinoma, NOS																																		
Papillary adenoma																																		
Granulosa cell carcinoma, invasive																																		
Leiomyosarcoma																																		
Endometrial stromal polyp			X	X		X							X					X		X													X	
Endometrial stromal sarcoma																																		
Ovary	+	+	+	+	+	+	+	+	+	+	+	+	+	+	+	+	+	+	+	+	+	+	+	+	+	+	+	+	+	+	+	+	+	
Granulosa cell tumor																																		
Granulosa cell carcinoma																																		
NERVOUS SYSTEM																																		
Brain	+	+	+	+	+	+	+	+	+	+	+	+	+	+	+	+	+	+	+	+	+	+	+	+	+	+	+	+	+	+	+	+	+	
Carcinoma, NOS, invasive																																		
Carcinosarcoma, metastatic																																		
Granular cell tumor, NOS																																		
Glioma, NOS																																		
Glioma, invasive																																		
Astrocytoma																																		
Meningioma																																		
Spinal cord	N	N	N	N	N	N	N	N	N	N	N	N	N	N	N	N	N	N	N	N	N	N	N	N	N	N	N	N	N	N	N	N	N	
Astrocytoma																																		
SPECIAL SENSE ORGANS																																		
Eye appendages	N	N	N	N	N	N	N	N	N	N	N	N	N	N	N	N	N	N	N	N	N	N	N	N	N	N	N	N	N	N	N	N	N	
Squamous cell carcinoma, invasive																																		
Harderian gland	N	N	N	N	N	N	N	N	N	N	N	N	N	N	N	N	N	N	N	N	N	N	N	N	N	N	N	N	N	N	N	N	N	
Squamous cell carcinoma																																		
Squamous cell carcinoma, metastatic																																		
Zymbal gland	N	N	N	N	N	N	N	N	N	N	N	N	N	N	N	N	N	N	N	N	N	N	N	N	N	N	N	N	N	N	N	N	N	
Carcinosarcoma																																		
MUSCULOSKELETAL SYSTEM																																		
Bone	N	N	N	N	N	N	N	N	N	N	N	N	N	N	N	N	N	N	N	N	N	N	N	N	N	N	N	N	N	N	N	N	N	
Squamous cell carcinoma, invasive																																		
ALL OTHER SYSTEMS																																		
Multiple organs, NOS	N	N	N	N	N	N	N	N	N	N	N	N	N	N	N	N	N	N	N	N	N	N	N	N	N	N	N	N	N	N	N	N	N	
Adenocarcinoma, NOS, invasive																																		
Alveolar/bronchiolar carcinoma, metastatic																																		
C-cell carcinoma, metastatic																																		
Endometrial stromal sarcoma, invasive																																		
Carcinosarcoma, invasive																																		
Monocytic leukemia			X	X																														
Leukemia, mononuclear cell																																		
Orbital region																																		
Squamous cell carcinoma, metastatic																																		

TABLE B2. INDIVIDUAL ANIMAL TUMOR PATHOLOGY OF FEMALE RATS: UNTREATED CONTROL
(Continued)

ANIMAL NUMBER	636	594	564	574	583	589	579	584	608	602	606	605	600	601	604	603	606	605	608	608	609	611	612	615	615	618	618	622	622
WEEKS ON STUDY	17	8	8	8	8	8	1	1	2	2	2	2	2	2	2	2	2	2	2	2	2	2	2	2	2	2	2	2	2
ENDOCRINE SYSTEM																													
Pituitary	+	+	+	+	+	+	+	+	+	+	+	+	+	+	+	+	+	+	+	+	+	+	+	+	+	+	+	+	
Carcinoma, NOS				X																									
Adenoma, NOS	X					X		X		X	X		X	X												X			
Adrenal	+	+	+	+	+	+	+	+	+	+	+	+	+	+	+	+	+	+	+	+	+	+	+	+	+	+	+	+	
Cortical adenoma																													
Cortical carcinoma																													
Pheochromocytoma																													
Pheochromocytoma, malignant																													
Thyroid	+	+	-	+	+	+	+	+	+	+	+	+	+	+	+	+	+	+	+	+	+	+	+	+	+	+	+	+	
Follicular cell adenoma																													
Follicular cell carcinoma									X																		X		
C-cell adenoma										X																			
C-cell carcinoma														X												X		X	
Parathyroid	+	+	-	+	+	+	+	+	+	+	+	+	+	+	+	+	+	+	+	+	+	+	+	+	+	+	+	+	
Adenoma, NOS																													
Pancreatic islets	+	+	+	+	+	+	+	+	+	+	+	+	+	+	+	+	+	+	+	+	+	+	+	+	+	+	+	+	
Islet cell adenoma																													
Islet cell carcinoma													X																
REPRODUCTIVE SYSTEM																													
Mammary gland	+	+	+	+	+	+	+	+	+	+	+	+	+	+	+	+	+	+	+	+	+	+	+	+	+	+	+	+	
Adenoma, NOS								X																					
Adenocarcinoma, NOS																													
Fibroadenoma																													
Preputial/external gland	N	N	N	N	N	N	N	N	N	N	N	N	N	N	N	N	N	N	N	N	N	N	N	N	N	N	N	N	
Squamous cell carcinoma																													
Basal cell carcinoma																													
Adenoma, NOS																													
Uterus	+	+	+	+	+	+	+	+	+	+	+	+	+	+	+	+	+	+	+	+	+	+	+	+	+	+	+	+	
Adenocarcinoma, NOS																													
Papillary adenoma																													
Granulosa cell carcinoma, invasive																													
Leiomyosarcoma																													
Endometrial stromal polyp																													
Endometrial stromal sarcoma					X						X		X														X		
Ovary	+	+	+	+	+	+	+	+	+	+	+	+	+	+	+	+	+	+	+	+	+	+	+	+	+	+	+	+	
Granulosa cell tumor																													
Granulosa cell carcinoma																													
NERVOUS SYSTEM																													
Brain	+	+	+	+	+	+	+	+	+	+	+	+	+	+	+	+	+	+	+	+	+	+	+	+	+	+	+	+	
Carcinoma, NOS, invasive																													
Carcinosarcoma, metastatic				@X				X																					
Granular cell tumor, NOS																													
Glioma, NOS																													
Glioma, invasive																													
Astrocytoma																													
Meningioma																													
Spinal cord	N	+	N	N	N	N	N	N	N	N	N	N	N	N	N	N	N	N	N	N	N	N	N	N	N	N	N	N	
Astrocytoma		X																											
SPECIAL SENSE ORGANS																													
Eye appendages	N	N	N	N	N	N	N	N	N	N	N	N	N	N	N	N	N	N	N	N	N	N	N	N	N	N	N	N	
Squamous cell carcinoma, invasive																													
Harderian gland	N	N	N	N	N	N	N	N	N	N	N	N	N	N	N	N	N	N	N	N	N	N	N	N	N	N	N	N	
Squamous cell carcinoma																													
Squamous cell carcinoma, metastatic																													
Zymbal gland	N	N	N	N	N	N	N	N	N	N	N	N	N	N	N	N	N	N	N	N	N	N	N	N	N	N	N	N	
Carcinosarcoma																													
MUSCULOSKELETAL SYSTEM																													
Bone	N	N	N	N	N	N	N	N	N	N	N	N	N	N	N	N	N	N	N	N	N	N	N	N	N	N	N	N	
Squamous cell carcinoma, invasive																													
ALL OTHER SYSTEMS																													
Multiple organs, NOS	N	N	N	N	N	N	N	N	N	N	N	N	N	N	N	N	N	N	N	N	N	N	N	N	N	N	N	N	
Adenocarcinoma, NOS, invasive																													
Alveolar/bronchiolar carcinoma, metastatic																													
C-cell carcinoma, metastatic																													
Endometrial stromal sarcoma, invasive																													
Carcinosarcoma, invasive																													
Monocytic leukemia																													
Leukemia, mononuclear cell				X					X																		X	X	
Orbital region																													
Squamous cell carcinoma, metastatic																													

@ Multiple occurrence of morphology

TABLE B2. INDIVIDUAL ANIMAL TUMOR PATHOLOGY OF FEMALE RATS: UNTREATED CONTROL
(Continued)

ANIMAL NUMBER	5 5	5 6	6 0	5 7	6 9	6 3	5 2	5 8	5 9	6 0	6 5	5 7	6 0	6 2	5 4	6 9	6 9	5 7	5 0	5 3	5 8	6 3	5 5	5 8	5 0	5 9	
WEEKS ON STUDY	1 0	1 3	1 3	1 3	1 3	1 3	1 4	1 4	1 4	1 4	1 4	1 5	1 6	1 6	1 7	1 7	1 7	1 8	1 8	1 8	1 8	1 8	1 8	1 8	1 8	1 8	1 8
ENDOCRINE SYSTEM																											
Pituitary	+	+	+	+	+	+	+	+	+	+	+	+	+	-	+	+	+	+	+	+	+	+	+	+	+	+	+
Carcinoma, NOS	X	X													X												
Adenoma, NOS	X	X	X	X	X	X	X	X	X	X	X	X	X	X	X	X	X	X	X	X	X	X	X	X	X	X	X
Adrenal	+	+	+	+	+	+	+	+	+	+	+	+	+	+	+	+	+	+	+	+	+	+	+	+	+	+	+
Cortical adenoma																											
Cortical carcinoma																											
Pheochromocytoma			X	X	X		X	X																			
Pheochromocytoma, malignant																											
Thyroid	+	+	+	+	+	+	+	+	+	+	+	+	+	+	+	+	+	+	+	+	+	+	+	+	+	+	+
Follicular cell adenoma																											
Follicular cell carcinoma			X																								
C-cell adenoma																											
C-cell carcinoma																											
Parathyroid	+	+	+	+	-	+	+	+	+	+	+	+	+	+	+	+	+	+	+	+	+	+	+	+	+	+	+
Adenoma, NOS																											
Pancreatic islets	+	+	+	+	+	+	+	+	+	+	+	+	+	+	+	+	+	+	+	+	+	+	+	+	+	+	+
Islet cell adenoma																											
Islet cell carcinoma																									X	X	
REPRODUCTIVE SYSTEM																											
Mammary gland	+	+	+	+	+	+	+	+	+	+	+	+	+	+	+	+	+	+	+	+	+	+	+	+	+	+	+
Adenoma, NOS																											
Adenocarcinoma, NOS																											
Fibroadenoma	X			X	X	X	X	X	X	X	X	X	X	X	X	X	X	X	X	X	X	X	X	X	X	X	X
Preputial/choral gland	N	N	N	N	N	N	N	N	N	N	N	N	N	N	N	N	N	N	N	N	N	N	N	N	N	N	N
Squamous cell carcinoma																											
Basal cell carcinoma																											
Adenoma, NOS																											
Uterus	+	+	+	+	+	+	+	+	+	+	+	+	+	+	+	+	+	+	+	+	+	+	+	+	+	+	+
Adenocarcinoma, NOS																											
Papillary adenoma																											
Granulosa cell carcinoma, invasive																											
Leiomyosarcoma				X																							
Endometrial stromal polyp					X																						
Endometrial stromal sarcoma																											
Ovary	+	+	+	+	+	+	+	+	+	+	+	+	+	+	+	+	+	+	+	+	+	+	+	+	+	+	+
Granulosa cell tumor																											
Granulosa cell carcinoma																											
NERVOUS SYSTEM																											
Brain	+	+	+	+	+	+	+	+	+	+	+	+	+	+	+	+	+	+	+	+	+	+	+	+	+	+	+
Carcinoma, NOS, invasive																											
Carcinosarcoma, metastatic																											
Granular cell tumor, NOS																											
Glioma, NOS																											
Glioma, invasive																											
Astrocytoma																											
Meningioma																											
Spinal cord	N	N	N	N	N	N	N	N	N	N	N	N	N	N	N	N	N	N	N	N	N	N	N	N	N	N	N
Astrocytoma																											
SPECIAL SENSE ORGANS																											
Eye appendages	N	N	N	N	N	N	N	N	N	N	N	N	N	N	N	N	N	N	N	N	N	N	N	N	N	N	N
Squamous cell carcinoma, invasive																											
Harderian gland	N	N	N	N	N	N	N	N	N	N	N	N	N	N	N	N	N	N	N	N	N	N	N	N	N	N	N
Squamous cell carcinoma																											
Squamous cell carcinoma, metastatic																											
Zymbal gland	N	N	N	N	N	N	N	N	N	N	N	N	N	N	N	N	N	N	N	N	N	N	N	N	N	N	N
Carcinosarcoma																											
MUSCULOSKELETAL SYSTEM																											
Bone	N	N	N	N	N	N	N	N	N	N	N	N	N	N	N	N	N	N	N	N	N	N	N	N	N	N	N
Squamous cell carcinoma, invasive																											
ALL OTHER SYSTEMS																											
Multiple organs, NOS	N	N	N	N	N	N	N	N	N	N	N	N	N	N	N	N	N	N	N	N	N	N	N	N	N	N	N
Adenocarcinoma, NOS, invasive																											
Alveolar/bronchiolar carcinoma, metastatic																											
C cell carcinoma, metastatic																											
Endometrial stromal sarcoma, invasive																											
Carcinosarcoma, invasive																											
Monocytic leukemia	X	X	X																								
Leukemia, mononuclear cell																											
Orbital region																											
Squamous cell carcinoma, metastatic																											

**TABLE B2. INDIVIDUAL ANIMAL TUMOR PATHOLOGY OF FEMALE RATS: UNTREATED CONTROL
(Continued)**

ANIMAL NUMBER	60	66	65	66	57	59	59	60	61	62	62	63	63	64	64	64	64	65	65	
WEEKS ON STUDY	43	43	44	45	45	45	45	45	45	45	45	45	45	45	45	45	45	45	45	
ENDOCRINE SYSTEM																				TOTAL: TISSUES TUMORS
Pituitary	+	+	+	+	+	+	+	+	+	+	+	+	+	-	+	+	+	+		
Carcinoma, NOS			X		X															
Adenoma, NOS				X	X		X	X	X							X			X	
Adrenal	+	+	+	+	+	+	+	+	+	+	+	+	+	+	+	+	+	+	+	
Cortical adenoma							X													
Cortical carcinoma											X	X							X	
Pheochromocytoma	X	X			X	X				X	X			X	X					
Pheochromocytoma, malignant																				
Thyroid	+	+	+	+	+	+	+	+	+	+	+	+	+	+	+	+	+	+	+	
Follicular cell adenoma													X							
Follicular cell carcinoma					X															
C-cell adenoma											X								X	
C-cell carcinoma			X										X		X	X				
Parathyroid	+	+	+	+	+	+	+	+	+	+	+	+	+	+	+	+	+	+	+	
Adenoma, NOS																				
Pancreatic islets	+	+	+	+	+	+	+	+	+	+	+	+	+	+	+	+	+	+	+	
Islet cell adenoma																				
Islet cell carcinoma			X																	
REPRODUCTIVE SYSTEM																				
Mammary gland	+	+	+	+	+	+	+	+	+	+	+	+	+	+	+	+	+	+	+	
Adenoma, NOS																				
Adenocarcinoma, NOS		X	X				X										X		X	
Fibroadenoma	X	X		X			X	X	X			X	X	X	X	X				
Preputial/clitoral gland	N	N	N	N	N	N	N	N	N	N	N	N	N	N	N	N	N	N	N	
Squamous cell carcinoma	X								X	X										
Basal cell carcinoma						X														
Adenoma, NOS																				
Uterus	+	+	+	+	+	+	+	+	+	+	-	+	+	+	+	+	+	+	+	
Adenocarcinoma, NOS																				
Papillary adenoma																X				
Granulosa cell carcinoma, invasive																				
Leiomyosarcoma																				
Endometrial stromal polyp					X										X		X			
Endometrial stromal sarcoma																				
Ovary	+	+	+	+	+	+	+	+	+	+	-	+	+	+	+	+	+	+	+	
Granulosa cell tumor																				
Granulosa cell carcinoma																				
NERVOUS SYSTEM																				
Brain	+	+	+	+	+	+	+	+	+	+	+	+	+	+	+	+	+	+	+	
Carcinoma, NOS, invasive			X																	
Carcinosarcoma, metastatic																				
Granular cell tumor, NOS																				
Glioma, NOS			X																	
Glioma, invasive			X																	
Astrocytoma																				
Meningioma																			@X	
Spinal cord	N	N	N	N	N	N	N	N	N	N	N	N	N	N	N	N	N	N	N	
Astrocytoma																				
SPECIAL SENSE ORGANS																				
Eye appendages	N	N	N	N	N	N	N	N	N	N	N	N	N	N	N	N	N	N	N	
Squamous cell carcinoma, invasive																				
Harderian gland	N	N	N	N	N	N	N	N	N	N	N	N	N	N	N	N	N	N	N	
Squamous cell carcinoma																				
Squamous cell carcinoma, metastatic																				
Zymbal gland	N	N	N	N	N	N	N	N	N	N	N	N	N	N	N	N	N	N	N	
Carcinosarcoma																				
MUSCULOSKELETAL SYSTEM																				
Bone	N	N	N	N	N	N	N	N	N	N	N	N	N	N	N	N	N	N	N	
Squamous cell carcinoma, invasive																				
ALL OTHER SYSTEMS																				
Multiple organs, NOS	N	N	N	N	N	N	N	N	N	N	N	N	N	N	N	N	N	N	N	
Adenocarcinoma, NOS, invasive																				
Alveolar/bronchiolar carcinoma, meta																				
C-cell carcinoma, metastatic																				
Endometrial stromal sarcoma, invasive																				
Carcinosarcoma, invasive																				
Monocytic leukemia																				
Leukemia, mononuclear cell	X					X		X							X					
Orbital region																				
Squamous cell carcinoma, metastatic																				

* Animals necropsied
@ Multiple occurrence of morphology

TABLE B2. INDIVIDUAL ANIMAL TUMOR PATHOLOGY OF FEMALE RATS IN THE LIFETIME FEED STUDY OF CROCIDOLITE ASBESTOS: 1% CROCIDOLITE ASBESTOS

ANIMAL NUMBER	0	0	1	0	1	1	0	0	0	1	9	0	9	9	9	9	0	0	0	0	1	0	1	0	0
WEEKS ON STUDY	4	5	5	6	6	7	7	7	7	7	7	7	7	8	8	8	8	8	8	8	8	8	9	9	9
INTEGUMENTARY SYSTEM																									
Skin	+	+	+	+	+	+	+	+	+	+	+	+	+	+	+	+	+	+	+	+	+	+	+	+	
Squamous cell papilloma																									
Squamous cell carcinoma																									
Squamous cell carcinoma, invasive																									
Basal cell tumor																									
Keratoacanthoma																									
Fibrosarcoma																									
Neurofibrosarcoma																									
Subcutaneous tissue	+	+	+	+	+	+	+	+	+	+	+	+	+	+	+	+	+	+	+	+	+	+	+	+	
Squamous cell papilloma																									
Squamous cell carcinoma, invasive																									
Follicular cell carcinoma, invasive																									
Sarcoma, NOS																									
Fibroma																									
Fibrosarcoma																									
Neurofibroma																									
RESPIRATORY SYSTEM																									
Lungs and bronchi	+	+	+	+	+	+	+	+	+	+	+	+	+	+	+	+	+	+	+	+	+	+	+	+	
Squamous cell carcinoma, metastatic																									
Adenocarcinoma, NOS, metastatic																									
Alveolar/bronchiolar adenoma																									
Alveolar/bronchiolar carcinoma																									
C-cell carcinoma, metastatic																									
Pheochromocytoma, metastatic																									
Liposarcoma, metastatic																									
Trachea	+	+	+	+	+	+	+	+	+	+	+	+	+	+	+	+	+	+	+	+	+	+	+	+	
Follicular cell carcinoma, invasive																									
Nasal cavity	+	N	N	N	N	N	N	N	N	N	N	N	N	N	N	N	N	N	N	N	N	N	N	N	
Squamous cell carcinoma																									
Adenocarcinoma, NOS																									
HEMATOPOIETIC SYSTEM																									
Bone marrow	+	+	+	+	+	+	+	+	+	+	+	+	+	+	+	+	-	+	+	+	+	+	+	+	
Spleen	+	+	+	+	+	+	+	+	+	+	+	+	+	+	+	+	+	+	+	+	+	+	+	+	
Lymph nodes	+	+	+	+	+	+	+	+	+	+	+	+	+	+	+	+	+	+	+	+	+	+	+	+	
Squamous cell carcinoma, metastatic																									
Thymus	+	+	+	+	+	+	+	+	+	+	+	+	+	+	+	+	+	+	+	+	+	+	+	+	
Thymoma, benign																									
CIRCULATORY SYSTEM																									
Heart	+	+	+	+	+	+	+	+	+	+	+	+	+	+	+	+	+	+	+	+	+	+	+	+	
Alveolar/bronchiolar carcinoma, metastatic																									
DIGESTIVE SYSTEM																									
Oral cavity	N	N	N	N	N	N	N	N	N	N	N	N	N	N	N	N	N	N	N	N	N	N	N	N	
Squamous cell carcinoma																									
Squamous cell carcinoma, invasive																									
Salivary gland	+	+	+	+	+	+	+	+	+	+	+	+	+	+	+	+	+	+	+	+	+	+	+	+	
Fibrosarcoma																									
Liver	+	+	+	+	+	+	+	+	+	+	+	+	+	+	+	+	+	+	+	+	+	+	+	+	
Neoplastic nodule																									
Hepatocellular carcinoma																									
Bile duct	+	+	+	+	+	+	+	+	+	+	+	+	+	+	+	+	+	+	+	+	+	+	+	+	
Pancreas	+	+	+	+	+	+	+	+	+	+	+	+	+	+	+	+	+	+	+	+	+	+	+	+	
Acinar cell adenoma																									
Acinar cell carcinoma																									
Esophagus	-	-	-	-	-	-	+	+	+	-	+	+	+	+	+	+	+	+	+	+	+	+	+		
Stomach	+	+	+	+	+	+	+	+	+	+	+	+	+	+	+	+	+	+	+	+	+	+	+	+	
Carcinoma, NOS																									
Squamous cell papilloma																									
Squamous cell carcinoma																									
Adenomatous polyp, NOS																									
Small intestine	+	+	+	+	+	+	+	+	+	+	+	+	+	+	+	+	+	+	+	+	+	+	+	+	
Carcinoid tumor, malignant		X																							
Large intestine	+	+	+	+	+	+	+	+	+	+	+	+	+	+	+	+	+	+	+	+	+	+	+	+	
URINARY SYSTEM																									
Kidney	+	+	+	+	+	+	+	+	+	+	+	+	+	+	+	+	+	+	+	+	+	+	+	+	
Urinary bladder	+	+	+	+	+	+	+	+	+	+	+	+	+	+	+	+	+	+	+	+	+	+	+	+	

TABLE B2. INDIVIDUAL ANIMAL TUMOR PATHOLOGY OF FEMALE RATS: 1% CROCIDOLITE ASBESTOS (Continued)

ANIMAL NUMBER	98	98	98	00	99	99	00	11	11	99	99	99	99	11	11	00	00	00	00	11	99	99	00	11	
WEEKS ON STUDY	8	0	8	0	9	5	8	3	1	8	7	3	3	9	2	4	8	0	9	0	1	5	9	8	7
INTEGUMENTARY SYSTEM																									
Skin	+	+	+	+	+	+	+	+	+	+	+	+	+	+	+	+	+	+	+	+	+	+	+	+	+
Squamous cell papilloma																									
Squamous cell carcinoma																									
Squamous cell carcinoma, invasive																									
Basal cell tumor																									
Keratoacanthoma																									
Fibrosarcoma																									
Neurofibrosarcoma																									
Subcutaneous tissue	+	+	+	+	+	+	+	+	+	+	+	+	+	+	+	+	+	+	+	+	+	+	+	+	+
Squamous cell papilloma																									
Squamous cell carcinoma, invasive																									
Follicular cell carcinoma, invasive																									
Sarcoma, NOS																									
Fibroma																									
Fibrosarcoma																									
Neurofibroma																									
RESPIRATORY SYSTEM																									
Lungs and bronchi	+	+	+	+	+	+	+	+	+	+	+	+	+	+	+	+	+	+	+	+	+	+	+	+	+
Squamous cell carcinoma, metastatic																									
Adenocarcinoma, NOS, metastatic																									
Alveolar/bronchiolar adenoma																									
Alveolar/bronchiolar carcinoma																									
C-cell carcinoma, metastatic																									
Phaeochromocytoma, metastatic																									
Liposarcoma, metastatic																									
Trachea	+	+	+	+	+	+	+	+	+	+	+	+	+	+	+	+	+	+	+	+	+	+	+	+	+
Follicular cell carcinoma, invasive																									
Nasal cavity	N	N	N	N	N	N	N	N	N	N	N	N	N	N	N	N	N	N	N	N	N	N	N	N	N
Squamous cell carcinoma																									
Adenocarcinoma, NOS																									
HEMATOPOIETIC SYSTEM																									
Bone marrow	+	+	+	+	+	+	+	+	+	+	+	+	+	+	+	+	+	+	+	+	+	+	+	+	+
Spleen	+	+	+	+	+	+	+	+	+	+	+	+	+	+	+	+	+	+	+	+	+	+	+	+	+
Lymph nodes	+	+	+	+	+	+	+	+	+	+	+	+	+	+	+	+	+	+	+	+	+	+	+	+	+
Squamous cell carcinoma, metastatic																									
Thymus	-	+	-	+	+	+	+	-	+	-	-	+	+	-	+	-	-	+	-	+	+	+	-	-	-
Thymoma, benign																									
CIRCULATORY SYSTEM																									
Heart	+	+	+	+	+	+	+	+	+	+	+	+	+	+	+	+	+	+	+	+	+	+	+	+	+
Alveolar/bronchiolar carcinoma, metastatic																									
DIGESTIVE SYSTEM																									
Oral cavity	N	N	N	N	N	N	N	N	N	N	N	N	N	N	N	N	N	N	N	N	N	N	N	N	N
Squamous cell carcinoma																									
Squamous cell carcinoma, invasive																									
Salivary gland	+	+	+	+	+	+	+	+	-	+	+	+	+	+	+	+	+	+	+	+	+	+	+	+	+
Fibrosarcoma																									
Liver	+	+	+	+	+	+	+	+	+	+	+	+	+	+	+	+	+	+	+	+	+	+	+	+	+
Neoplastic nodule																									
Hepatocellular carcinoma																									
Bile duct	+	+	+	+	+	+	+	+	+	+	+	+	+	+	+	+	+	+	+	+	+	+	+	+	+
Pancreas	+	+	+	+	+	+	+	+	+	+	+	+	+	+	+	+	+	+	+	+	+	+	+	+	+
Acinar cell adenoma																									
Acinar cell carcinoma																									
Esophagus	+	+	+	+	+	+	+	+	+	+	+	+	+	+	+	+	+	+	+	+	+	+	+	+	+
Stomach	+	+	+	+	+	+	+	+	+	+	+	+	+	+	+	+	+	+	+	+	+	+	+	+	+
Carcinoma, NOS																									
Squamous cell papilloma																									
Squamous cell carcinoma																									
Adenomatous polyp, NOS																									
Small intestine	+	+	+	+	+	+	+	+	+	+	+	+	+	+	+	+	+	+	+	+	+	+	+	+	+
Carcinoid tumor, malignant																									
Large intestine	+	+	+	+	+	+	+	+	+	+	+	+	+	+	+	+	+	+	+	+	+	+	+	+	+
URINARY SYSTEM																									
Kidney	+	+	+	+	+	+	+	+	+	+	+	+	+	+	+	+	+	+	+	+	+	+	+	+	+
Urinary bladder	+	+	+	+	+	+	+	+	+	+	+	+	+	+	+	+	+	+	+	+	+	+	+	+	+

TABLE B2. INDIVIDUAL ANIMAL TUMOR PATHOLOGY OF FEMALE RATS: 1% CROCIDOLITE ASBESTOS (Continued)

ANIMAL NUMBER	979	188	188	988	083	077	155	933	933	022	044	077	122	990	990	088	122	166	922	922	922	044	066	115	159		
WEEKS ON STUDY	107	188	188	188	199	199	199	199	199	100	111	111	111	111	111	111	111	111	111	111	111	111	111	111	111	111	
INTEGUMENTARY SYSTEM																											
Skin																											
Squamous cell papilloma	+	+	+	+	+	+	+	+	+	+	+	+	+	+	+	+	+	+	+	+	+	+	+	+	+	+	
Squamous cell carcinoma																											
Squamous cell carcinoma, invasive																											
Basal cell tumor																											
Keratoacanthoma																											
Fibrosarcoma																											
Neurofibrosarcoma																											
Subcutaneous tissue																											
Squamous cell papilloma	+	+	+	+	+	+	+	+	+	+	+	+	+	+	+	+	+	+	+	+	+	+	+	+	+	+	
Squamous cell carcinoma, invasive																											
Follicular cell carcinoma, invasive																											
Sarcoma, NOS																											
Fibroma																											
Fibrosarcoma																											
Neurofibroma																											
RESPIRATORY SYSTEM																											
Lungs and bronchi																											
Squamous cell carcinoma, metastatic	+	+	+	+	+	+	+	+	+	+	+	+	+	+	+	+	+	+	+	+	+	+	+	+	+	+	
Adenocarcinoma, NOS, metastatic																											
Alveolar/bronchiolar adenoma																											
Alveolar/bronchiolar carcinoma																											
C-cell carcinoma, metastatic																											
Pheochromocytoma, metastatic																											
Liposarcoma, metastatic																											
Trachea																											
Follicular cell carcinoma, invasive	+	+	+	+	+	+	+	+	+	+	+	+	+	+	+	+	+	+	+	+	+	+	+	+	+	+	
Nasal cavity																											
Squamous cell carcinoma	N	N	N	N	N	N	N	N	N	N	N	N	N	N	N	N	N	N	N	N	N	N	N	N	N	N	
Adenocarcinoma, NOS																											
HEMATOPOIETIC SYSTEM																											
Bone marrow																											
	+	+	+	+	+	+	+	+	+	+	+	+	+	+	+	+	+	+	+	+	+	+	+	+	+	+	
Spleen																											
	+	+	+	+	+	+	+	+	+	+	+	+	+	+	+	+	+	+	+	+	+	+	+	+	+	+	
Lymph nodes																											
	+	+	+	+	+	+	+	+	+	+	+	+	+	+	+	+	+	+	+	+	+	+	+	+	+	+	
Squamous cell carcinoma, metastatic																											
Thymus	+	+	+	+	-	-	+	+	+	+	-	-	-	-	+	-	+	-	+	-	+	-	+	-	+		
Thymoma, benign																											
CIRCULATORY SYSTEM																											
Heart																											
Alveolar/bronchiolar carcinoma, metastatic	+	+	+	+	+	+	+	+	+	+	+	+	+	+	+	+	+	+	+	+	+	+	+	+	+	+	
DIGESTIVE SYSTEM																											
Oral cavity																											
Squamous cell carcinoma	N	N	N	N	N	N	N	N	N	N	N	N	N	N	N	N	N	N	N	N	N	N	N	N	N	N	
Squamous cell carcinoma, invasive																											
Salivary gland																											
Fibrosarcoma	+	+	+	+	+	+	+	+	+	+	+	+	+	+	+	+	+	+	+	+	+	+	+	+	+	+	
Liver																											
Neoplastic nodule	+	+	+	+	+	+	+	+	+	+	+	+	+	+	+	+	+	+	+	+	+	+	+	+	+	+	
Hepatocellular carcinoma																											
Bile duct																											
Pancreas	+	+	+	+	+	+	+	+	+	+	+	+	+	+	+	+	+	+	+	+	+	+	+	+	+	+	
Acinar cell adenoma	+	+	+	+	+	+	+	+	+	+	+	+	+	+	+	+	+	+	+	+	+	+	+	+	+	+	
Acinar cell carcinoma																											
Esophagus																											
Stomach	+	+	+	+	+	+	+	+	+	+	+	+	+	+	+	+	+	+	+	+	+	+	+	+	+	+	
Carcinoma, NOS																											
Squamous cell papilloma																											
Squamous cell carcinoma																											
Adenomatous polyp, NOS																											
Small intestine																											
Carcinoid tumor, malignant	+	+	+	+	+	+	+	+	+	+	+	+	+	+	+	+	+	+	+	+	+	+	+	+	+	+	
Large intestine																											
	+	+	+	+	+	+	+	+	+	+	+	+	+	+	+	+	+	+	+	+	+	+	+	+	+	+	
URINARY SYSTEM																											
Kidney																											
	+	+	+	+	+	+	+	+	+	+	+	+	+	+	+	+	+	+	+	+	+	+	+	+	+	+	
Urinary bladder																											
	+	+	+	+	+	+	+	+	+	+	+	+	+	+	+	+	+	+	+	+	+	+	+	+	+	+	

TABLE B2. INDIVIDUAL ANIMAL TUMOR PATHOLOGY OF FEMALE RATS: 1% CROCIDOLITE ASBESTOS (Continued)

ANIMAL NUMBER	920	923	930	148	192	160	139	054	152	942	960	053	137	139	966	064	163	027	031	147	133	938	958	983	007		
WEEKS ON STUDY	12	12	12	13	14	14	14	15	15	15	15	16	16	16	16	17	17	18	18	18	18	18	18	18	19		
INTEGUMENTARY SYSTEM																											
Skin																											
Squamous cell papilloma	+	+	+	+	+	+	+	+	+	+	+	+	+	+	+	+	+	+	+	+	+	+	+	+	+	+	
Squamous cell carcinoma																											
Squamous cell carcinoma, invasive																											
Basal cell tumor																											
Keratoacanthoma																											
Fibrosarcoma																											
Neurofibrosarcoma																											
Subcutaneous tissue																											
Squamous cell papilloma	+	+	+	+	+	+	+	+	+	+	+	+	+	+	+	+	+	+	+	+	+	+	+	+	+	+	
Squamous cell carcinoma, invasive																											
Follicular cell carcinoma, invasive																											
Sarcoma, NOS																											
Fibroma																											
Fibrosarcoma																											
Neurofibroma																											
RESPIRATORY SYSTEM																											
Lungs and bronchi																											
Squamous cell carcinoma, metastatic	+	+	+	+	+	+	+	+	+	+	+	+	+	+	+	+	+	+	+	+	+	+	+	+	+	+	
Adenocarcinoma, NOS, metastatic																											
Alveolar/bronchiolar adenoma																											
Alveolar/bronchiolar carcinoma																											
C-cell carcinoma, metastatic																											
Pheochromocytoma, metastatic																											
Liposarcoma, metastatic																											
Trachea																											
Follicular cell carcinoma, invasive	+	+	+	+	+	+	+	+	+	+	+	+	+	+	+	+	+	+	+	+	+	+	+	+	+	+	
Nasal cavity																											
Squamous cell carcinoma	N	N	N	N	N	N	N	N	N	N	N	N	N	N	N	N	N	N	N	N	N	N	N	N	N	N	
Adenocarcinoma, NOS																											
HEMATOPOIETIC SYSTEM																											
Bone marrow																											
Spleen	+	+	+	+	+	+	+	+	+	+	+	+	+	+	+	+	+	+	+	+	+	+	+	+	+	+	
Lymph nodes	+	+	+	+	+	+	+	+	+	+	+	+	+	+	+	+	+	+	+	+	+	+	+	+	+	+	
Squamous cell carcinoma, metastatic																											
Thymus	-	+	+	-	+	+	+	+	+	+	+	+	+	+	+	+	+	+	+	+	+	+	+	+	+	+	
Thymoma, benign																											
CIRCULATORY SYSTEM																											
Heart																											
Alveolar/bronchiolar carcinoma, metastatic	+	+	+	+	+	+	+	+	+	+	+	+	+	+	+	+	+	+	+	+	+	+	+	+	+	+	
DIGESTIVE SYSTEM																											
Oral cavity																											
Squamous cell carcinoma	N	N	N	N	N	N	N	N	N	N	N	N	N	N	N	N	N	N	N	N	N	N	N	N	N	N	
Squamous cell carcinoma, invasive																											
Salivary gland	+	+	+	+	+	+	+	+	+	+	+	+	+	+	+	+	+	+	+	+	+	+	+	+	+	+	
Fibrosarcoma																											
Liver																											
Neoplastic nodule																											
Hepatocellular carcinoma																											
Bile duct																											
Pancreas	+	+	+	+	+	+	+	+	+	+	+	+	+	+	+	+	+	+	+	+	+	+	+	+	+	+	
Acinar cell adenoma																											
Acinar cell carcinoma																											
Esophagus																											
Stomach	+	+	+	+	+	+	+	+	+	+	+	+	+	+	+	+	+	+	+	+	+	+	+	+	+	+	
Carcinoma, NOS																											
Squamous cell papilloma																											
Squamous cell carcinoma																											
Adenomatous polyp, NOS																											
Small intestine																											
Carcinoid tumor, malignant																											
Large intestine																											
Squamous cell carcinoma	+	+	+	+	+	+	+	+	+	+	+	+	+	+	+	+	+	+	+	+	+	+	+	+	+	+	
URINARY SYSTEM																											
Kidney																											
Urinary bladder	+	+	+	+	+	+	+	+	+	+	+	+	+	+	+	+	+	+	+	+	+	+	+	+	+	+	

TABLE B2. INDIVIDUAL ANIMAL TUMOR PATHOLOGY OF FEMALE RATS: 1% CROCIDOLITE ASBESTOS (Continued)

ANIMAL NUMBER	0	1	1	1	1	9	9	0	0	0	1	9	0	0	1	1	9	9	0	0	0	9	0	0	1
WEEKS ON STUDY	1	1	1	1	1	1	1	1	1	1	1	1	1	1	1	1	1	1	1	1	1	1	1	1	1
	6	9	9	9	9	0	0	1	1	1	1	1	1	1	1	1	1	1	1	1	1	1	1	1	
INTEGUMENTARY SYSTEM																									
Skin	+	+	+	+	+	+	+	+	+	+	+	+	+	+	+	+	+	+	+	+	+	+	+	+	
Squamous cell papilloma																									
Squamous cell carcinoma																									
Squamous cell carcinoma, invasive																						X			
Basal cell tumor																									
Keratoacanthoma																									
Fibrosarcoma																									
Neurofibrosarcoma																									
Subcutaneous tissue	+	+	+	+	+	+	+	+	+	+	+	+	+	+	+	+	+	+	+	+	+	+	+	+	
Squamous cell papilloma																									
Squamous cell carcinoma, invasive																									
Follicular cell carcinoma, invasive																									
Sarcoma, NOS																									
Fibroma																									
Fibrosarcoma																								X	
Neurofibroma																									
RESPIRATORY SYSTEM																									
Lungs and bronchi	+	+	+	+	+	+	+	+	+	+	+	+	+	+	+	+	+	+	+	+	+	+	+	+	
Squamous cell carcinoma, metastatic																									
Adenocarcinoma, NOS, metastatic																									
Alveolar/bronchiolar adenoma																									
Alveolar/bronchiolar carcinoma																									
C-cell carcinoma, metastatic																									
Pheochromocytoma, metastatic																									
Liposarcoma, metastatic																									
Trachea	+	+	+	+	+	+	+	+	+	+	+	+	+	+	+	+	+	+	+	+	+	+	+	+	
Follicular cell carcinoma, invasive																									
Nasal cavity	+	N	N	N	N	N	N	N	N	N	N	N	N	N	+	N	N	N	+	N	N	N	N	N	
Squamous cell carcinoma																									
Adenocarcinoma, NOS																								X	
HEMATOPOIETIC SYSTEM																									
Bone marrow	+	+	+	+	+	+	+	+	+	+	+	+	+	+	+	+	+	+	+	+	+	+	+	+	
Spleen	+	+	+	+	+	+	+	+	+	+	+	+	+	+	+	+	+	+	+	+	+	+	+	+	
Lymph nodes	+	+	+	+	+	+	+	+	+	+	+	+	+	+	+	+	+	+	+	+	+	+	+	+	
Squamous cell carcinoma, metastatic																									
Thymus	+	+	+	+	+	-	+	+	+	+	+	+	+	+	+	+	+	+	+	+	+	+	+	+	
Thymoma, benign																									
CIRCULATORY SYSTEM																									
Heart	+	+	+	+	+	+	+	+	+	+	+	+	+	+	+	+	+	+	+	+	+	+	+	+	
Alveolar/bronchiolar carcinoma, metastatic																									
DIGESTIVE SYSTEM																									
Oral cavity	N	N	N	N	N	N	N	N	N	N	N	N	N	N	N	N	N	N	N	N	N	N	N	N	
Squamous cell carcinoma	X																								
Squamous cell carcinoma, invasive																									
Salivary gland	+	+	+	+	+	+	+	+	+	+	+	+	+	+	+	+	+	+	+	+	+	+	+	+	
Fibrosarcoma																									
Liver	+	+	+	+	+	+	+	+	+	+	+	+	+	+	+	+	+	+	+	+	+	+	+	+	
Neoplastic nodule																									
Hepatocellular carcinoma																									
Bile duct	+	+	+	+	+	+	+	+	+	+	+	+	+	+	+	+	+	+	+	+	+	+	+	+	
Pancreas	+	+	+	+	+	+	+	+	+	+	+	+	+	+	+	+	+	+	+	+	+	+	+	+	
Acinar cell adenoma																									
Acinar cell carcinoma	X																								
Esophagus	+	+	+	+	+	+	+	+	+	+	+	+	+	+	+	+	+	+	+	+	+	+	+	+	
Stomach	+	+	+	+	+	+	+	+	+	+	+	+	+	+	+	+	+	+	+	+	+	+	+	+	
Carcinoma, NOS																									
Squamous cell papilloma																									
Squamous cell carcinoma																									
Adenomatous polyp, NOS																									
Small intestine	+	+	+	+	+	+	+	+	+	+	+	+	+	+	+	+	+	+	+	+	+	+	+	+	
Carcinoid tumor, malignant																									
Large intestine	+	+	+	+	+	+	+	+	+	+	+	+	+	+	+	+	+	+	+	+	+	+	+	+	
URINARY SYSTEM																									
Kidney	+	+	+	+	+	+	+	+	+	+	+	+	+	+	+	+	+	+	+	+	+	+	+	+	
Urinary bladder	+	+	+	+	+	+	+	+	+	+	+	+	+	+	+	+	+	+	+	+	+	+	+	+	

TABLE B2. INDIVIDUAL ANIMAL TUMOR PATHOLOGY OF FEMALE RATS: 1% CROCIDOLITE ASBESTOS (Continued)

ANIMAL NUMBER	1	9	0	0	0	1	9	9	0	0	0	9	9	9	9	0	1	1	0	0	1	1	9	9	0	0
WEEKS ON STUDY	4	9	8	7	1	4	2	2	6	9	2	6	7	7	0	7	0	0	0	6	3	3	7	4	5	2
INTEGUMENTARY SYSTEM																										
Skin	+	+	+	+	+	+	+	+	+	+	+	+	+	+	+	+	+	+	+	+	+	+	+	+	+	+
Squamous cell papilloma																										
Squamous cell carcinoma						X																				
Squamous cell carcinoma, invasive																										
Basal cell tumor																										
Keratoacanthoma																										
Fibrosarcoma																										
Neurofibrosarcoma																										
Subcutaneous tissue	+	+	+	+	+	+	+	+	+	+	+	+	+	+	+	+	+	+	+	+	+	+	+	+	+	+
Squamous cell papilloma																										
Squamous cell carcinoma, invasive																						X				
Follicular cell carcinoma, invasive																										
Sarcoma, NOS																										
Fibroma																										
Fibrosarcoma										X																
Neurofibroma																										
RESPIRATORY SYSTEM																										
Lungs and bronchi	+	+	+	+	+	+	+	+	+	+	+	+	+	+	+	+	+	+	+	+	+	+	+	+	+	+
Squamous cell carcinoma, metastatic																										
Adenocarcinoma, NOS, metastatic																										
Alveolar/bronchiolar adenoma																										
Alveolar/bronchiolar carcinoma																							X			
C-cell carcinoma, metastatic																										
Pheochromocytoma, metastatic																										
Liposarcoma, metastatic																										
Trachea	+	+	+	+	+	+	+	+	+	+	+	+	+	+	+	+	+	+	+	+	+	+	+	+	+	+
Follicular cell carcinoma, invasive																										
Nasal cavity	N	N	N	N	N	N	N	N	N	N	N	N	N	N	N	N	N	N	N	N	N	N	N	N	N	N
Squamous cell carcinoma																										
Adenocarcinoma, NOS																										
HEMATOPOIETIC SYSTEM																										
Bone marrow	+	+	+	+	+	+	+	+	+	+	+	+	+	+	+	+	+	+	+	+	+	+	+	+	+	+
Spleen	+	+	+	+	+	+	+	+	+	+	+	+	+	+	+	+	+	+	+	+	+	+	+	+	+	+
Lymph nodes	+	+	+	+	+	+	+	+	+	+	+	+	+	+	+	+	+	+	+	+	+	+	+	+	+	+
Squamous cell carcinoma, metastatic																										
Thymus	+	-	+	+	+	-	+	+	+	+	+	+	+	+	+	+	+	+	+	+	+	+	+	+	+	+
Thymoma, benign																										
CIRCULATORY SYSTEM																										
Heart	+	+	+	+	+	+	+	+	+	+	+	+	+	+	+	+	+	+	+	+	+	+	+	+	+	+
Alveolar/bronchiolar carcinoma, metastatic																							X			
DIGESTIVE SYSTEM																										
Oral cavity	N	N	N	N	N	N	N	N	N	N	N	N	N	N	N	N	N	N	N	N	N	N	N	N	N	N
Squamous cell carcinoma																										
Squamous cell carcinoma, invasive																										
Salivary gland	+	+	+	+	+	+	+	+	+	+	+	+	+	+	+	+	+	+	+	+	+	+	+	+	+	+
Fibrosarcoma																										
Liver	+	+	+	+	+	+	+	+	+	+	+	+	+	+	+	+	+	+	+	+	+	+	+	+	+	+
Neoplastic nodule																										
Hepatocellular carcinoma																										
Bile duct	+	+	+	+	+	+	+	+	+	+	+	+	+	+	+	+	+	+	+	+	+	+	+	+	+	+
Pancreas	+	+	+	+	+	+	+	+	+	+	+	+	+	+	+	+	+	+	+	+	+	+	+	+	+	+
Acinar cell adenoma																										
Acinar cell carcinoma																										
Esophagus	+	+	+	+	+	+	+	+	+	+	+	+	+	+	+	+	+	+	+	+	+	+	+	+	+	+
Stomach	+	+	+	+	+	+	+	+	+	+	+	+	+	+	+	+	+	+	+	+	+	+	+	+	+	+
Carcinoma, NOS																										
Squamous cell papilloma																										
Squamous cell carcinoma																										
Adenomatous polyp, NOS																										
Small intestine	+	+	+	+	+	+	+	+	+	+	+	+	+	+	+	+	+	+	+	+	+	+	+	+	+	+
Carcinoid tumor, malignant																										
Large intestine	+	+	+	+	+	+	+	+	+	+	+	+	+	+	+	+	+	+	+	+	+	+	+	+	+	+
URINARY SYSTEM																										
Kidney	+	+	+	+	+	+	+	+	+	+	+	+	+	+	+	+	+	+	+	+	+	+	+	+	+	+
Urinary bladder	+	+	+	+	+	+	+	+	+	+	+	+	+	+	+	+	+	+	+	+	+	+	+	+	+	+

TABLE B2. INDIVIDUAL ANIMAL TUMOR PATHOLOGY OF FEMALE RATS: 1% CROCIDOLITE ASBESTOS (Continued)

ANIMAL NUMBER	0	0	1	1	1	1	9	9	0	0	0	0	9	9	0	0	1	1	1	0	0	0	0	1	9		
	2	7	2	3	4	4	8	1	8	7	9	5	6	8	9	1	5	5	4	4	6	9	2	6	1		
WEEKS ON STUDY	1	1	1	1	1	1	1	1	1	1	1	1	1	1	1	1	1	1	1	1	1	1	1	1	1		
	9	9	9	9	9	9	9	9	0	0	1	1	1	1	1	1	1	1	1	1	1	1	1	1	1		
INTEGUMENTARY SYSTEM																											
Skin																											
Squamous cell papilloma	+	+	+	+	+	+	+	+	+	+	+	+	+	+	+	+	+	+	+	+	+	+	+	+	+		
Squamous cell carcinoma																											
Squamous cell carcinoma, invasive																											
Basal cell tumor																											
Keratoacanthoma																											
Fibrosarcoma																											
Neurofibrosarcoma																											
Subcutaneous tissue																											
Squamous cell papilloma	+	+	+	+	+	+	+	+	+	+	+	+	+	+	+	+	+	+	+	+	+	+	+	+	+		
Squamous cell carcinoma, invasive																											
Follicular cell carcinoma, invasive																											
Sarcoma, NOS																											
Fibroma																											
Fibrosarcoma																											
Neurofibroma																											
RESPIRATORY SYSTEM																											
Lungs and bronchi																											
Squamous cell carcinoma, metastatic	+	+	+	+	+	+	+	+	+	+	+	+	+	+	+	+	+	+	+	+	+	+	+	+	+		
Adenocarcinoma, NOS, metastatic																											
Alveolar/bronchiolar adenoma																											
Alveolar/bronchiolar carcinoma																											
C-cell carcinoma, metastatic																											
Pheochromocytoma, metastatic																											
Liposarcoma, metastatic																											
Trachea																											
Follicular cell carcinoma, invasive	+	+	+	+	+	+	+	+	+	+	+	+	+	+	+	+	+	+	+	+	+	+	+	+	+		
Nasal cavity																											
Squamous cell carcinoma	N	N	N	N	N	N	N	N	N	N	N	N	N	N	N	N	N	N	N	N	N	N	N	N	N		
Adenocarcinoma, NOS																											
HEMATOPOIETIC SYSTEM																											
Bone marrow																											
Spleen	+	+	+	+	+	+	+	+	+	+	+	+	+	+	+	+	+	+	+	+	+	+	+	+	+		
Lymph nodes	+	+	+	+	+	+	+	+	+	+	+	+	+	+	+	+	+	+	+	+	+	+	+	+	+		
Squamous cell carcinoma, metastatic																											
Thymus	-	+	+	+	+	-	+	+	+	+	+	+	+	+	+	+	+	+	+	+	+	+	-	+	-		
Thymoma, benign																											
CIRCULATORY SYSTEM																											
Heart																											
Alveolar/bronchiolar carcinoma, metastatic	+	+	+	+	+	+	+	+	+	+	+	+	+	+	+	+	+	+	+	+	+	+	+	+	+		
DIGESTIVE SYSTEM																											
Oral cavity																											
Squamous cell carcinoma	N	N	N	N	N	N	N	N	N	N	N	N	N	N	N	N	N	N	N	N	N	N	N	N	N		
Squamous cell carcinoma, invasive																											
Salivary gland																											
Fibrosarcoma	+	+	+	+	+	+	+	+	+	+	+	+	+	+	+	+	+	+	+	+	+	+	+	+	+		
Liver																											
Neoplastic nodule	+	+	+	+	+	+	+	+	+	+	+	+	+	+	+	+	+	+	+	+	+	+	+	+	+		
Hepatocellular carcinoma																											
Bile duct	+	+	+	+	+	+	+	+	+	+	+	+	+	+	+	+	+	+	+	+	+	+	+	+	+		
Pancreas																											
Acinar cell adenoma	+	+	+	+	+	+	+	+	+	+	+	+	+	+	+	+	+	+	+	+	+	+	+	+	+		
Acinar cell carcinoma																											
Esophagus																											
Stomach	+	+	+	+	+	+	+	+	+	+	+	+	+	+	+	+	+	+	+	+	+	+	+	+	+		
Carcinoma, NOS																											
Squamous cell papilloma																											
Squamous cell carcinoma																											
Adenomatous polyp, NOS																											
Small intestine																											
Carcinoid tumor, malignant	+	+	+	+	+	+	+	+	+	+	+	+	+	+	+	+	+	+	+	+	+	+	+	+	+		
Large intestine																											
	+	+	+	+	+	+	+	+	+	+	+	+	+	+	+	+	+	+	+	+	+	+	+	+	+		
URINARY SYSTEM																											
Kidney																											
Urinary bladder	+	+	+	+	+	+	+	+	+	+	+	+	+	+	+	+	+	+	+	+	+	+	+	+	+		

TABLE B2. INDIVIDUAL ANIMAL TUMOR PATHOLOGY OF FEMALE RATS: 1% CROCIDOLITE ASBESTOS (Continued)

ANIMAL NUMBER	1	9	0	0	1	9	9	9	0	1	1	9	0	0	0	1	1	1	9	0	1	1	9	9	0		
WEEKS ON STUDY	2	7	3	9	1	4	5	6	5	1	4	5	1	7	9	4	1	3	9	6	0	6	2	4	4		
	9	4	6	4	8	6	6	8	5	6	6	9	5	0	8	4	2	3	1	8	2	6	2	5	2		
INTEGUMENTARY SYSTEM																											
Skin																											
Squamous cell papilloma	+	+	+	+	+	+	+	+	+	+	+	+	+	+	+	+	+	+	+	+	+	+	+	+	+		
Squamous cell carcinoma																											
Squamous cell carcinoma, invasive																											
Basal cell tumor																											
Keratoacanthoma																											
Fibrosarcoma																											
Neurofibrosarcoma																											
Subcutaneous tissue																											
Squamous cell papilloma	+	+	+	+	+	+	+	+	+	+	+	+	+	+	+	+	+	+	+	+	+	+	+	+	+		
Squamous cell carcinoma, invasive																											
Follicular cell carcinoma, invasive	X																										
Sarcoma, NOS																											
Fibroma																											
Fibrosarcoma																											
Neurofibroma																											
RESPIRATORY SYSTEM																											
Lungs and bronchi																											
Squamous cell carcinoma, metastatic	+	+	+	+	+	+	+	+	+	+	+	+	+	+	+	+	+	+	+	+	+	+	+	+	+		
Adenocarcinoma, NOS, metastatic																											
Alveolar/bronchiolar adenoma																											
Alveolar/bronchiolar carcinoma																											
C-cell carcinoma, metastatic																											
Pheochromocytoma, metastatic																											
Liposarcoma, metastatic																											
Trachea																											
Follicular cell carcinoma, invasive	X																										
Nasal cavity																											
Squamous cell carcinoma	N	N	N	N	N	N	N	N	N	N	N	N	N	N	N	N	N	N	N	N	N	N	N	N	N		
Adenocarcinoma, NOS																											
HEMATOPOIETIC SYSTEM																											
Bone marrow																											
Spleen	+	+	+	+	+	+	+	+	+	+	+	+	+	+	+	+	+	+	+	+	+	+	+	+	+		
Lymph nodes	+	+	+	+	+	+	+	+	+	+	+	+	+	+	+	+	+	+	+	+	+	+	+	+	+		
Squamous cell carcinoma, metastatic																											
Thymus	+	-	+	+	+	+	+	-	+	+	-	+	-	+	-	+	+	+	+	+	+	-	-	+	+		
Thymoma, benign																											
CIRCULATORY SYSTEM																											
Heart																											
Alveolar/bronchiolar carcinoma, metastatic	+	+	+	+	+	+	+	+	+	+	+	+	+	+	+	+	+	+	+	+	+	+	+	+	+		
DIGESTIVE SYSTEM																											
Oral cavity																											
Squamous cell carcinoma	N	N	N	N	N	N	N	N	N	N	N	N	N	N	N	N	N	N	N	N	N	N	N	N	N		
Squamous cell carcinoma, invasive																											
Salivary gland																											
Fibrosarcoma																											
Liver																											
Neoplastic nodule	+	+	+	+	+	+	+	+	+	+	+	+	+	+	+	+	+	+	+	+	+	+	+	+	+		
Hepatocellular carcinoma																											
Bile duct																											
Pancreas	+	+	+	+	+	+	+	+	+	+	+	+	+	+	+	+	+	+	+	+	+	+	+	+	+		
Acinar cell adenoma																											
Acinar cell carcinoma	X																										
Esophagus																											
Squamous cell carcinoma	+	+	+	+	+	+	+	+	+	+	+	+	+	+	+	+	+	+	+	+	+	+	+	+	+		
Stomach																											
Squamous cell carcinoma	+	+	+	+	+	+	+	+	+	+	+	+	+	+	+	+	+	+	+	+	+	+	+	+	+		
Adenomatous polyp, NOS																											
Small intestine																											
Carcinoid tumor, malignant	+	+	+	+	+	+	+	+	+	+	+	+	+	+	+	+	+	+	+	+	+	+	+	+	+		
Large intestine																											
Carcinoid tumor, malignant	+	+	+	+	+	+	+	+	+	+	+	+	+	+	+	+	+	+	+	+	+	+	+	+	+		
URINARY SYSTEM																											
Kidney																											
Urinary bladder	+	+	+	+	+	+	+	+	+	+	+	+	+	+	+	+	+	+	+	+	+	+	+	+	+		

TABLE B2. INDIVIDUAL ANIMAL TUMOR PATHOLOGY OF FEMALE RATS: 1% CROCIDOLITE ASBESTOS (Continued)

ANIMAL NUMBER	1	0	0	9	9	9	9	0	0	0	1	1	1	9	9	9	0	0	0	9	9	0	0	0	0	0	0
WEEKS ON STUDY	4	4	4	4	4	4	4	4	4	4	4	4	4	4	4	4	4	4	4	4	4	4	4	4	4	4	4
	1	2	2	2	2	2	2	3	3	3	3	3	3	3	3	3	4	4	4	4	4	5	5	5	5	5	
INTEGUMENTARY SYSTEM																											
Skin																											
Squamous cell papilloma	+	+	+	+	+	+	+	+	+	+	+	+	+	+	+	+	+	+	+	+	+	+	+	+	+	+	+
Squamous cell carcinoma																X											
Squamous cell carcinoma, invasive																											
Basal cell tumor																											
Keratoacanthoma										X																	
Fibrosarcoma																											
Neurofibrosarcoma																											
Subcutaneous tissue																											
Squamous cell papilloma	+	+	+	+	+	+	+	+	+	+	+	+	+	+	+	+	+	+	+	+	+	+	+	+	+	+	+
Squamous cell carcinoma			X																								
Squamous cell carcinoma, invasive																											
Follicular cell carcinoma, invasive																											
Sarcoma, NOS																											
Fibroma	X										X																
Fibrosarcoma																											
Neurofibroma																											
RESPIRATORY SYSTEM																											
Lungs and bronchi																											
Squamous cell carcinoma, metastatic	+	+	+	+	+	+	+	+	+	+	+	+	+	+	+	+	+	+	+	+	+	+	+	+	+	+	+
Adenocarcinoma, NOS, metastatic																											
Alveolar/bronchiolar adenoma																X											
Alveolar/bronchiolar carcinoma																											
C-cell carcinoma, metastatic																											
Pheochromocytoma, metastatic																											
Liposarcoma, metastatic																											
Trachea																											
Follicular cell carcinoma, invasive																											
Nasal cavity																											
Squamous cell carcinoma	N	N	N	N	N	N	N	N	N	N	N	N	N	N	N	N	N	N	N	N	N	N	N	N	N	N	N
Adenocarcinoma, NOS																											
HEMATOPOIETIC SYSTEM																											
Bone marrow																											
Spleen	+	+	+	+	+	+	+	+	+	+	+	+	+	+	+	+	+	+	+	+	+	+	+	+	+	+	+
Lymph nodes	+	+	+	+	+	+	+	+	+	+	+	+	+	+	+	+	+	+	+	+	+	+	+	+	+	+	+
Squamous cell carcinoma, metastatic																											
Thymus	-	+	+	+	+	+	-	+	+	-	+	+	+	+	+	+	+	+	+	+	+	+	+	+	+	+	+
Thymoma, benign																											
CIRCULATORY SYSTEM																											
Heart																											
Alveolar/bronchiolar carcinoma, metastatic	+	+	+	+	+	+	+	+	+	+	+	+	+	+	+	+	+	+	+	+	+	+	+	+	+	+	+
DIGESTIVE SYSTEM																											
Oral cavity																											
Squamous cell carcinoma	N	N	N	N	N	N	N	N	N	N	N	N	N	N	N	N	N	N	N	N	N	N	N	N	N	N	N
Squamous cell carcinoma, invasive																											
Salivary gland																											
Fibrosarcoma																											
Liver																											
Neoplastic nodule	+	+	+	+	+	+	+	+	+	+	+	+	+	+	+	+	+	+	+	+	+	+	+	+	+	+	+
Hepatocellular carcinoma																											
Bile duct																											
Pancreas																											
Acinar cell adenoma																											
Acinar cell carcinoma																											
Esophagus																											
Stomach																											
Carcinoma, NOS																											
Squamous cell papilloma																X											
Squamous cell carcinoma																											
Adenomatous polyp, NOS																											
Small intestine																											
Carcinoid tumor, malignant	+	+	+	+	+	+	+	+	+	+	+	+	+	+	+	+	+	+	+	+	+	+	+	+	+	+	+
Large intestine																											
URINARY SYSTEM																											
Kidney																											
Urinary bladder	+	+	+	+	+	+	+	+	+	+	+	+	+	+	+	+	+	+	+	+	+	+	+	+	+	+	+
	+	+	+	+	+	+	+	+	+	+	+	+	+	+	+	+	+	+	+	+	+	+	+	+	+	+	+

TABLE B2. INDIVIDUAL ANIMAL TUMOR PATHOLOGY OF FEMALE RATS: 1% CROCIDOLITE ASBESTOS (Continued)

ANIMAL NUMBER	00111000019099990000101000	0208250993819745532742019	108250993819745532742019	018250993819745532742019	118250993819745532742019	008250993819745532742019	008250993819745532742019	008250993819745532742019	018250993819745532742019	098250993819745532742019	098250993819745532742019	098250993819745532742019	098250993819745532742019	098250993819745532742019	008250993819745532742019	008250993819745532742019	008250993819745532742019	008250993819745532742019	018250993819745532742019	018250993819745532742019	008250993819745532742019	008250993819745532742019	
WEEKS ON STUDY	45	53	57	60	66	66	73	77	77	77	77	77	77	77	77	77	77	77	77	77	77	77	77
ENDOCRINE SYSTEM																							
Pituitary																							
Carcinoma, NOS	+	+	+	+	+	+	+	+	+	+	+	+	+	+	+	+	+	+	+	+	+	+	+
Adenoma, NOS					X		X						X					X			X		
Adrenal																							
Cortical adenoma	+	+	+	+	+	+	+	+	+	+	+	+	+	+	+	+	+	+	+	+	+	+	+
Cortical carcinoma																							
Pheochromocytoma																					X		
Pheochromocytoma, malignant																							
Ganglioneuroma	X			X																			
Thyroid																							
Follicular cell adenoma	+	+	+	+	+	+	+	+	+	+	+	+	+	+	+	+	+	+	+	+	+	+	+
Follicular cell carcinoma																							
C cell adenoma																							
C cell carcinoma																							
Parathyroid																							
Adenoma, NOS	+	+	+	+	-	+	+	-	+	+	+	+	+	+	+	+	-	+	-	+	+	+	-
Pancreatic islets																							
Islet cell adenoma	+	+	+	+	+	+	+	+	+	+	+	+	+	+	+	+	+	+	+	+	+	+	+
Islet cell carcinoma																							
REPRODUCTIVE SYSTEM																							
Mammary gland																							
Adenoma, NOS	+	+	+	+	+	+	+	+	+	+	+	+	+	+	+	+	+	+	+	+	+	+	+
Adenocarcinoma, NOS																							
Fibroadenoma										X			X					X			X		X
Preputial/clitoral gland																							
Carcinoma, NOS	N	N	N	N	N	N	N	N	N	N	N	N	N	N	N	N	N	N	N	N	N	N	N
Squamous cell carcinoma																							
Adenoma, NOS																							
Keratoacanthoma																							
Uterus																							
Squamous cell carcinoma	+	+	+	+	+	+	+	+	+	+	+	+	+	+	+	+	+	+	+	+	+	+	+
Adenocarcinoma, NOS																							
Papillary adenoma																							
Sarcoma, NOS																							
Leiomyoma																							
Endometrial stromal polyp					X																	X	
Endometrial stromal sarcoma								X															
Endometrial stromal sarcoma, invasive																							
Ovary																							
Granulosa cell tumor	+	+	+	+	+	+	+	+	+	+	+	+	+	+	+	+	+	+	+	+	+	+	+
Granulosa cell carcinoma																							
NERVOUS SYSTEM																							
Brain																							
Carcinoma, NOS, invasive	+	+	+	+	+	+	+	+	+	+	+	+	+	+	+	+	+	+	+	+	+	+	+
Astrocytoma																							
Astrocytoma, invasive																							
SPECIAL SENSE ORGANS																							
Eye appendages																							
Squamous cell carcinoma	N	N	N	N	N	N	N	N	N	N	N	N	N	N	N	N	N	N	N	N	N	N	N
Zymbal gland																							
Carcinoma in situ, NOS																							
Squamous cell papilloma																							
Squamous cell carcinoma																							
MUSCULOSKELETAL SYSTEM																							
Bone																							
Squamous cell carcinoma, invasive	N	N	N	N	N	N	N	N	N	N	N	N	N	N	N	N	N	N	N	N	N	N	N
BODY CAVITIES																							
Mediastinum																							
Mesothelioma, malignant	N	N	N	N	N	N	N	N	N	N	N	N	N	N	N	N	N	N	N	N	N	N	N
ALL OTHER SYSTEMS																							
Multiple organs NOS																							
Squamous cell carcinoma, invasive																							
Squamous cell carcinoma, metastatic																							
C cell carcinoma, metastatic																							
Endometrial stromal sarcoma, invasive																							
Mesothelioma, invasive																							
Malignant lymphoma, lymphocytic type																							
Myelomonocytic leukemia																							
Monocytic leukemia										X	X	X		X		X	X			X		X	
Adipose tissue																							
Cortical carcinoma, invasive																							

TABLE B2. INDIVIDUAL ANIMAL TUMOR PATHOLOGY OF FEMALE RATS: 1% CROCIDOLITE ASBESTOS (Continued)

ANIMAL NUMBER	988	940	948	060	929	935	088	113	114	978	974	953	956	119	112	004	005	006	008	001	961	973	959	058	127		
WEEKS ON STUDY	98	99	99	00	00	00	01	01	01	01	01	01	01	01	01	01	01	01	01	01	01	01	01	01	01	01	
ENDOCRINE SYSTEM																											
Pituitary	+	+	+	+	+	+	+	+	+	+	+	+	+	+	+	+	+	+	+	+	+	+	+	+	+	+	
Carcinoma, NOS							X																				
Adenoma, NOS																											
Adrenal	+	+	+	+	+	+	+	+	+	+	+	+	+	+	+	+	+	+	+	+	+	+	+	+	+	+	
Cortical adenoma																											
Cortical carcinoma																											
Pheochromocytoma																											
Pheochromocytoma, malignant																											
Ganglioneuroma																											
Thyroid	+	+	+	+	+	+	+	+	+	+	+	+	+	+	+	+	+	+	+	+	+	+	+	+	+	+	
Follicular cell adenoma																											
Follicular cell carcinoma																											
C cell adenoma																											
C cell carcinoma																											
Parathyroid		X																									
Adenoma, NOS	+	+	+	+	+	+	+	+	+	+	+	+	+	+	+	+	+	+	+	+	+	+	+	+	+	+	
Pancreatic islets	+	+	+	+	+	+	+	+	+	+	+	+	+	+	+	+	+	+	+	+	+	+	+	+	+	+	
Islet cell adenoma																											
Islet cell carcinoma																											
REPRODUCTIVE SYSTEM																											
Mammary gland	+	+	+	+	+	+	+	+	+	+	+	+	+	+	+	+	+	+	+	+	+	+	+	+	+	+	
Adenoma, NOS																											
Adenocarcinoma, NOS																											
Fibroadenoma																											
Preputial/clitoral gland	N	N	N	N	N	N	N	N	N	N	N	N	N	N	N	N	N	N	N	N	N	N	N	N	N	N	
Carcinoma, NOS																											
Squamous cell carcinoma																											
Adenoma, NOS																											
Keratoacanthoma																											
Uterus	+	+	+	+	+	+	+	+	+	+	+	+	+	+	+	+	+	+	+	+	+	+	+	+	+	+	
Squamous cell carcinoma																											
Adenocarcinoma, NOS																											
Papillary adenoma																											
Sarcoma, NOS																											
Leiomyoma																											
Endometrial stromal polyp							X																				
Endometrial stromal sarcoma																											
Endometrial stromal sarcoma, invas ve																											
Ovary	+	+	+	+	+	+	+	+	+	+	+	+	+	+	+	+	+	+	+	+	+	+	+	+	+	+	
Granulosa cell tumor																											
Granulosa cell carcinoma																											
NERVOUS SYSTEM																											
Brain	+	+	+	+	+	+	+	+	+	+	+	+	+	+	+	+	+	+	+	+	+	+	+	+	+	+	
Carcinoma, NOS, invasive																											
Astrocytoma																											
Astrocytoma, invasive							X																				
SPECIAL SENSE ORGANS																											
Eye appendages	N	N	N	N	N	N	N	N	N	N	N	N	N	N	N	N	N	N	N	N	N	N	N	N	N	N	
Squamous cell carcinoma																											
Zymbal gland	N	N	N	N	N	N	N	N	N	N	N	N	N	N	N	N	N	N	N	N	N	N	N	N	N	N	
Carcinoma in situ, NOS																											
Squamous cell papilloma																											
Squamous cell carcinoma																											
MUSCULOSKELETAL SYSTEM																											
Bone	N	N	N	N	N	N	N	N	N	N	N	N	N	N	N	N	N	N	N	N	N	N	N	N	N	N	
Squamous cell carcinoma, invasive																											
BODY CAVITIES																											
Mediastinum	N	N	N	N	N	N	N	N	N	N	N	N	N	N	N	N	N	N	N	N	N	N	N	N	N	N	
Mesothelioma, malignant																											
ALL OTHER SYSTEMS																											
Multiple organs, NOS	N	N	N	N	N	N	N	N	N	N	N	N	N	N	N	N	N	N	N	N	N	N	N	N	N	N	
Squamous cell carcinoma, invasive																											
Squamous cell carcinoma, metastatic																											
C cell carcinoma, metastatic																											
Endometrial stromal sarcoma, invasive																											
Mesothelioma, invasive																											
Malignant lymphoma, lymphocytic type																											
Myelomonocytic leukemia																											
Monocytic leukemia																											
Adipose tissue																											
Cortical carcinoma, invasive																											

TABLE B2. INDIVIDUAL ANIMAL TUMOR PATHOLOGY OF FEMALE RATS: 1% CROCIDOLITE ASBESTOS (Continued)

ANIMAL NUMBER	979	138	156	988	013	007	155	931	932	025	004	007	124	990	995	088	120	167	921	922	926	044	006	114	115		
WEEKS ON STUDY	107	108	108	108	109	109	109	109	109	110	110	110	110	110	110	111	111	111	111	111	111	111	112	112	112	112	
ENDOCRINE SYSTEM																											
Pituitary																											
Carcinoma, NOS	+	+	+	+	+	+	+	+	+	+	+	+	+	+	+	+	+	+	+	+	+	+	+	+	+	+	
Adenoma, NOS		X				X	X						X	X	X	X						X				X	
Adrenal																											
Cortical adenoma	+	+	+	+	+	+	+	+	+	+	+	+	+	+	+	+	+	+	+	+	+	+	+	+	+	+	
Cortical carcinoma										X																	
Pheochromocytoma																											
Pheochromocytoma, malignant																											
Ganglioneuroma																											
Thyroid																											
Follicular cell adenoma	+	+	+	+	+	+	+	+	+	+	+	+	+	+	+	+	+	+	+	+	+	+	+	+	+	+	
Follicular cell carcinoma																											
C-cell adenoma							X																				
C-cell carcinoma															X	X										X	
Parathyroid																											
Adenoma, NOS	+	-	-	+	+	+	+	+	+	+	+	+	+	-	+	+	+	+	+	+	-	+	+	+	-	+	
Pancreatic islets																											
Islet cell adenoma	+	+	+	+	+	+	+	+	+	+	+	+	+	+	+	+	+	+	+	+	+	+	+	+	+	+	
Islet cell carcinoma							X																				
REPRODUCTIVE SYSTEM																											
Mammary gland																											
Adenoma, NOS	+	+	+	+	+	+	+	+	+	+	+	+	+	+	+	+	+	+	+	+	+	+	+	+	+	+	
Adenocarcinoma, NOS																											
Fibroadenoma		X		X			X		X	X				X		X	X	X									
Preputial/clitoral gland																											
Carcinoma, NOS	N	N	N	N	N	N	N	N	N	N	N	N	N	N	N	N	N	N	N	N	N	N	N	N	N	N	
Squamous cell carcinoma							X															X			X		
Adenoma, NOS																											
Keratoacanthoma																											
Uterus																											
Squamous cell carcinoma	+	+	+	+	+	+	+	+	+	+	+	+	+	-	+	+	+	+	+	+	+	+	+	+	+	+	
Adenocarcinoma, NOS																											
Papillary adenoma																											
Sarcoma, NOS																											
Leiomyoma																											
Endometrial stromal polyp										X	X					X											
Endometrial stromal sarcoma																											
Endometrial stromal sarcoma, invasive																											
Ovary																											
Granulosa cell tumor	+	+	+	+	+	+	+	+	+	+	+	+	+	-	+	+	+	+	+	+	+	+	+	+	+	+	
Granulosa cell carcinoma																											
NERVOUS SYSTEM																											
Brain																											
Carcinoma, NOS, invasive	+	+	+	+	+	-	+	+	+	+	+	+	+	+	+	+	+	+	+	+	+	+	+	+	+	+	
Astrocytoma																											
Astrocytoma, invasive																											
SPECIAL SENSE ORGANS																											
Eye appendages																											
Squamous cell carcinoma	N	N	N	N	N	N	N	N	N	N	N	N	N	N	N	N	N	N	N	N	N	N	N	N	N	N	
Zymbal gland																											
Carcinoma in situ, NOS																											
Squamous cell papilloma																											
Squamous cell carcinoma			X																								
MUSCULOSKELETAL SYSTEM																											
Bone																											
Squamous cell carcinoma, invasive	N	N	N	N	N	N	N	N	N	N	N	N	N	N	N	N	N	N	N	N	N	N	N	N	N	N	
							@X																				
BODY CAVITIES																											
Medastinum																											
Mesothelioma, malignant	N	N	N	N	N	N	N	N	N	N	N	N	N	N	N	N	N	N	N	N	N	N	N	N	N	N	
ALL OTHER SYSTEMS																											
Multiple organs, NOS																											
Squamous cell carcinoma, invasive	N	N	N	N	N	N	N	N	N	N	N	N	N	N	N	N	N	N	N	N	N	N	N	N	N	N	
Squamous cell carcinoma, metastatic																											
C cell carcinoma, metastatic																											
Endometrial stromal sarcoma, invasive																											
Mesothelioma, invasive																											
Malignant lymphoma, lymphocytic type																											
Myelomonocytic leukemia																											
Monocytic leukemia	X		X			X		X	X	X	X	X	X	X		X							X		X	X	
Adipose tissue																											
Cortical carcinoma, invasive																											

@ Multiple occurrence of morphology

TABLE B2. INDIVIDUAL ANIMAL TUMOR PATHOLOGY OF FEMALE RATS: 1% CROCIDOLITE ASBESTOS (Continued)

ANIMAL NUMBER	0 1	1 0	1 1	1 2	1 5	9 8	9 7	0 6	0 7	0 8	1 2	9 5	0 6	0 7	1 5	1 6	9 4	9 4	0 7	0 9	0 3	9 3	0 3	0 4	1 4	1 0	
WEEKS ON STUDY	1 9	1 9	1 9	1 9	1 9	1 9	1 0	1 1	1 1	1 1	1 1	1 1	1 2	1 2	1 2	1 2	1 2	1 2	1 2	1 3	1 3	1 3	1 3	1 4	1 4	1 2	1 4
ENDOCRINE SYSTEM																											
Pituitary	+	+	+	+	+	+	+	+	+	+	+	+	+	+	+	+	+	+	+	+	+	+	+	+	+	+	+
Carcinoma, NOS						X													X								
Adenoma, NOS	X	X						X	X	X	X	X					X	X			X		X	X			
Adrenal	+	+	+	+	+	+	+	+	+	+	+	+	+	+	X		+	+	+	+	+	+	+	+	+	+	+
Cortical adenoma																					X						X
Cortical carcinoma						X																					
Pheochromocytoma																											
Pheochromocytoma, malignant																											
Ganglioneuroma																											X
Thyroid	+	+	+	+	+	+	+	+	+	+	+	+	+	+	+	+	+	+	+	+	+	+	+	+	+	+	+
Follicular cell adenoma															X												
Follicular cell carcinoma																											
C cell adenoma																											
C cell carcinoma																											
Parathyroid		X			X													X						X			
Adenoma, NOS	+	+	+	+	+	+	+	+	+	+	+	+	+	+	+	+	+	+	+	+	+	+	+	+	+	+	+
Pancreatic islets	+	+	+	+	+	+	+	+	+	+	+	+	+	+	+	+	+	+	+	+	+	+	+	+	+	+	+
Islet cell adenoma															X												
Islet cell carcinoma						X																					
REPRODUCTIVE SYSTEM																											
Mammary gland	+	+	+	+	+	+	+	+	+	+	+	+	+	+	+	+	+	+	+	+	+	+	+	+	+	+	+
Adenoma, NOS																											
Adenocarcinoma, NOS																											
Fibroadenoma																											
Preputial/clitoral gland	X	X	X	X	X	X	X																				
Carcinoma, NOS	N	N	N	N	N	N	N	N	N	N	N	N	N	N	N	N	N	N	N	N	N	N	N	N	N	N	N
Squamous cell carcinoma																											
Adenoma, NOS															X												
Keratoacanthoma																											
Uterus	+	+	+	+	+	+	+	+	+	+	+	+	+	+	+	+	+	+	+	+	+	+	+	+	+	+	+
Squamous cell carcinoma																											
Adenocarcinoma, NOS																											
Papillary adenoma																											
Sarcoma, NOS																											
Leiomyoma																											
Endometrial stromal polyp															X												
Endometrial stromal sarcoma																											
Endometrial stromal sarcoma, invasive																											
Ovary	+	+	+	+	+	+	+	+	+	+	+	+	+	+	+	+	+	+	+	+	+	+	+	+	+	+	+
Granulosa cell tumor																											
Granulosa cell carcinoma																											
NERVOUS SYSTEM																											
Brain	+	+	+	+	+	+	+	+	+	+	+	+	+	+	+	+	+	+	+	+	+	+	+	+	+	+	+
Carcinoma, NOS, invasive							X														X						
Astrocytoma																											
Astrocytoma, invasive																											
SPECIAL SENSE ORGANS																											
Eye appendages	N	N	N	N	N	N	N	N	N	N	N	N	N	N	N	N	N	N	N	N	N	N	N	N	N	N	N
Squamous cell carcinoma																											
Zymbal gland	N	N	N	N	N	N	N	N	N	N	N	N	N	N	N	N	N	N	N	N	N	N	N	N	N	N	N
Carcinoma in situ, NOS																											
Squamous cell papilloma																						X					
Squamous cell carcinoma																											
MUSCULOSKELETAL SYSTEM																											
Bone	N	N	N	N	N	N	N	N	N	N	N	N	N	N	N	N	N	N	N	N	N	N	N	N	N	N	N
Squamous cell carcinoma, invasive	X																										
BODY CAVITIES																											
Mediastinum	N	N	N	N	N	N	N	N	N	N	N	N	N	N	N	N	N	N	N	N	N	N	N	N	N	N	N
Mesothelioma, malignant																											
ALL OTHER SYSTEMS																											
Multiple organs, NOS	N	N	N	N	N	N	N	N	N	N	N	N	N	N	N	N	N	N	N	N	N	N	N	N	N	N	N
Squamous cell carcinoma, invasive																X											
Squamous cell carcinoma, metastatic																						X					
C cell carcinoma, metastatic																											
Endometrial stromal sarcoma, invasive																											
Mesothelioma, invasive																											
Malignant lymphoma, lymphocytic type																											
Myelomonocytic leukemia	X					X							X														
Monocytic leukemia		X		X	X	X	X	X	X	X	X	X	X	X	X	X	X	X	X	X	X	X	X	X	X	X	X
Adipose tissue																											
Cortical carcinoma, invasive																											

TABLE B2. INDIVIDUAL ANIMAL TUMOR PATHOLOGY OF FEMALE RATS: 1% CROCIDOLITE ASBESTOS (Continued)

ANIMAL NUMBER	104	99	08	07	06	11	94	92	02	00	00	97	97	97	08	03	07	05	04	05	00	14	13	97	96	00	01	
WEEKS ON STUDY	4	4	5	5	5	5	5	5	6	6	6	6	6	6	7	7	7	8	8	8	8	8	8	8	8	8	9	9
ENDOCRINE SYSTEM																												
Pituitary																												
Carcinoma, NOS	+	+	+	+	+	+	+	+	+	+	+	+	+	+	+	+	+	+	+	+	+	+	+	+	+	+	+	+
Adenoma, NOS		X	X		X	X					X	X	X														X	X
Adrenal																												
Cortical adenoma	+	+	+	+	+	+	+	+	+	+	+	+	+	+	+	+	+	+	+	+	+	+	+	+	+	+	+	+
Cortical carcinoma					X																							
Pheochromocytoma																												
Pheochromocytoma, malignant																												X
Ganglioneuroma																												
Thyroid																												
Follicular cell adenoma	+	+	+	+	+	+	+	+	+	+	+	+	+	+	+	+	+	+	+	+	+	+	+	+	+	+	+	+
Follicular cell carcinoma																												
C cell adenoma																												
C-cell carcinoma		X							X			X															X	X
Parathyroid																												
Adenoma, NOS	+	+	+	+	+	+	+	+	+	+	+	+	+	+	+	+	+	+	+	+	+	+	+	+	+	+	+	+
Pancreatic islets																												
Islet cell adenoma	+	+	+	+	+	+	+	+	+	+	+	+	+	+	+	+	+	+	+	+	+	+	+	+	+	+	+	+
Islet cell carcinoma																											X	
REPRODUCTIVE SYSTEM																												
Mammary gland																												
Adenoma, NOS	+	+	+	+	+	+	+	+	+	+	+	+	+	+	+	+	+	+	+	+	+	+	+	+	+	+	+	+
Adenocarcinoma, NOS													X															
Fibroadenoma		X	X		X	X		X		X	X		X	X		X	X		X		X		X		X		X	
Preputial/external gland																												
Carcinoma, NOS	N	N	N	N	N	N	N	N	N	N	N	N	N	N	N	N	N	N	N	N	N	N	N	N	N	N	N	N
Squamous cell carcinoma															X													
Adenoma, NOS		X																										
Keratoacanthoma																												
Uterus																												
Squamous cell carcinoma	+	+	+	+	+	+	+	+	+	+	+	+	+	+	+	+	+	+	+	+	+	+	+	+	+	+	+	+
Adenocarcinoma, NOS																												
Papillary adenoma																												
Sarcoma, NOS																												
Leiomyoma																												
Endometrial stromal polyp									X	X	X																	
Endometrial stromal sarcoma																												
Endometrial stromal sarcoma, invasive																												
Ovary																												
Granulosa cell tumor	+	+	+	+	+	+	+	+	+	+	+	+	+	+	+	+	+	+	+	+	+	+	+	+	+	+	+	+
Granulosa cell carcinoma																												
NERVOUS SYSTEM																												
Brain																												
Carcinoma, NOS, invasive	+	+	+	+	+	+	+	+	+	+	+	+	+	+	+	+	+	+	+	+	+	+	+	+	+	+	+	+
Astrocytoma															X													
Astrocytoma, invasive																												
SPECIAL SENSE ORGANS																												
Eye appendages																												
Squamous cell carcinoma	N	N	N	N	N	N	N	N	N	N	N	N	N	N	N	N	N	N	N	N	N	N	N	N	N	N	N	N
Zymbal gland																												
Carcinoma in situ, NOS	N	N	N	N	N	N	N	N	N	N	N	N	N	N	N	N	N	N	N	N	N	N	N	N	N	N	N	N
Squamous cell papilloma																												
Squamous cell carcinoma																												
MUSCULOSKELETAL SYSTEM																												
Bone																												
Squamous cell carcinoma, invasive	N	N	N	N	N	N	N	N	N	N	N	N	N	N	N	N	N	N	N	N	N	N	N	N	N	N	N	N
BODY CAVITIES																												
Mediastinum																												
Mesothelioma, malignant	N	N	N	N	N	N	N	N	N	N	N	N	N	N	N	N	N	N	N	N	N	N	N	N	N	N	N	N
ALL OTHER SYSTEMS																												
Multiple organs, NOS																												
Squamous cell carcinoma, invasive	N	N	N	N	N	N	N	N	N	N	N	N	N	N	N	N	N	N	N	N	N	N	N	N	N	N	N	N
Squamous cell carcinoma, metastatic																												
C cell carcinoma, metastatic																												
Endometrial stromal sarcoma, invasive																												
Mesothelioma, invasive																												
Malignant lymphoma, lymphocytic type																												
Myelomonocytic leukemia																												
Monocytic leukemia	X			X		X		X		X					X	X	X	X		X	X		X	X	X	X	X	X
Adipose tissue																												
Cortical carcinoma, invasive																												

TABLE B2. INDIVIDUAL ANIMAL TUMOR PATHOLOGY OF FEMALE RATS: 1% CROCIDOLITE ASBESTOS (Continued)

ANIMAL NUMBER	1 2 3 4	9 7 3 4	0 3 3 6	0 9 3 4	1 1 4 8	9 4 5 6	9 6 8 9	0 5 5 6	1 1 4 6	1 1 4 6	9 5 9 0	0 7 9 0	0 4 8 4	1 1 3 1	1 3 9 6	9 6 0 2	1 0 6 2	1 6 2 2	9 4 4 2	9 4 4 5	0 4 4 2	
WEEKS ON STUDY	5	5	6	6	6	6	6	7	7	7	7	8	8	8	8	9	9	9	0	0	0	1
ENDOCRINE SYSTEM																						
Pituitary																						
Carcinoma, NOS																						
Adenoma, NOS	X	X		X			X				X	X	X	X	X	X	X	X	X	X	X	X
Adrenal																						
Cortical adenoma	+	+	+	+	+	+	+	+	+	+	+	+	+	+	+	+	+	+	+	+	+	+
Cortical carcinoma								X														
Pheochromocytoma											X	X										
Pheochromocytoma, malignant				X		X	X		X	X	X						X					
Ganglioneuroma																						
Thyroid																						
Follicular cell adenoma	+	+	+	+	+	+	+	+	+	+	+	+	+	+	+	+	+	+	+	+	+	+
Follicular cell carcinoma	X																					
C-cell adenoma																						
C-cell carcinoma													X		X							
Parathyroid																						
Adenoma, NOS	-	+	+	+	+	+	+	+	+	+	+	+	+	+	+	+	+	+	+	+	+	+
Pancreatic islets																						
Islet cell adenoma	+	+	+	+	+	+	+	+	+	+	+	+	+	+	+	+	+	+	+	+	+	+
Islet cell carcinoma								X														
REPRODUCTIVE SYSTEM																						
Mammary gland																						
Adenoma, NOS	+	+	+	+	+	+	+	+	+	+	+	+	+	+	+	+	+	+	+	+	+	+
Adenocarcinoma, NOS																						
Fibroadenoma	X	X		X				X							X							
Preputial/clitoral gland																						
Carcinoma, NOS	N	N	N	N	N	N	N	N	N	N	N	N	N	N	N	N	N	N	N	N	N	N
Squamous cell carcinoma																						
Adenoma, NOS								X	X			X	X									
Keratoacanthoma																						
Uterus																						
Squamous cell carcinoma	+	+	+	+	+	+	+	+	+	+	+	+	+	+	+	+	+	+	+	+	+	+
Adenocarcinoma, NOS																						
Papillary adenoma																						
Sarcoma, NOS																						
Leiomyoma																						
Endometrial stromal polyp	X	X					X								X	X						
Endometrial stromal sarcoma																						
Endometrial stromal sarcoma, invasive																						
Ovary																						
Granulosa cell tumor	+	+	+	+	+	+	+	+	+	+	+	+	+	+	+	+	+	+	+	+	+	+
Granulosa cell carcinoma											X											
NERVOUS SYSTEM																						
Brain																						
Carcinoma, NOS, invasive	+	+	+	+	+	+	+	+	+	+	+	+	+	+	+	+	+	+	+	+	+	+
Astrocytoma																						
Astrocytoma, invasive																						
SPECIAL SENSE ORGANS																						
Eye appendages																						
Squamous cell carcinoma	N	N	N	N	N	N	N	N	N	N	N	N	N	N	N	N	N	N	N	N	N	N
Zymbal gland																						
Carcinoma in situ, NOS	N	N	N	N	N	N	N	N	N	N	N	N	N	N	N	N	N	N	N	N	N	N
Squamous cell papilloma																						
Squamous cell carcinoma																						
MUSCULOSKELETAL SYSTEM																						
Bone																						
Squamous cell carcinoma, invasive	N	N	N	N	N	N	N	N	N	N	N	N	N	N	N	N	N	N	N	N	N	N
BODY CAVITIES																						
Mediastinum																						
Mesothelioma, malignant	N	N	N	N	N	N	N	N	N	N	N	N	N	N	N	N	N	N	N	N	N	N
ALL OTHER SYSTEMS																						
Multiple organs, NOS																						
Squamous cell carcinoma, invasive	N	N	N	N	N	N	N	N	N	N	N	N	N	N	N	N	N	N	N	N	N	N
Squamous cell carcinoma, metastatic																						
C-cell carcinoma, metastatic																						
Endometrial stromal sarcoma, invasive																						
Mesothelioma, invasive																						
Malignant lymphoma, lymphocytic t.rpe																						
Myelomonocytic leukemia																						
Monocytic leukemia	X				X						X				X	X	X				X	X
Adipose tissue																						
Cortical carcinoma, invasive																						

TABLE B2. INDIVIDUAL ANIMAL TUMOR PATHOLOGY OF FEMALE RATS: 1% CROCIDOLITE ASBESTOS (Continued)

ANIMAL NUMBER	1	0	0	9	9	9	9	0	0	0	1	1	1	9	9	9	0	0	0	9	9	0	0	0	0	0	0	0	0
	3	0	8	4	5	6	6	2	2	2	0	5	5	2	4	8	4	8	8	3	9	0	1	1	1	2	2	2	2
WEEKS ON STUDY	1	1	1	1	1	1	1	1	1	1	1	1	1	1	1	1	1	1	1	1	1	1	1	1	1	1	1	1	1
	4	4	4	4	4	4	4	4	4	4	4	4	4	4	4	4	4	4	4	4	4	4	4	4	4	4	4	4	4
ENDOCRINE SYSTEM																													
Pituitary																													
Carcinoma, NOS	+	+	+	+	+	+	+	+	+	+	+	+	+	+	+	+	+	+	+	+	+	+	+	+	+	+	+	+	+
Adenoma, NOS	X	X	X	X	X	X	X	X	X	X	X	X	X	X	X	X	X	X	X	X	X	X	X	X	X	X	X	X	X
Adrenal																													
Cortical adenoma	+	+	+	+	+	+	+	+	+	+	+	+	+	+	+	+	+	+	+	+	+	+	+	+	+	+	+	+	+
Cortical carcinoma	+	+	+	+	+	+	+	+	+	+	+	+	+	+	+	+	+	+	+	+	+	+	+	+	+	+	+	+	+
Pheochromocytoma	X	X	X	X	X	X	X	X	X	X	X	X	X	X	X	X	X	X	X	X	X	X	X	X	X	X	X	X	X
Pheochromocytoma, malignant	X	X	X	X	X	X	X	X	X	X	X	X	X	X	X	X	X	X	X	X	X	X	X	X	X	X	X	X	X
Ganglioneuroma	X	X	X	X	X	X	X	X	X	X	X	X	X	X	X	X	X	X	X	X	X	X	X	X	X	X	X	X	X
Thyroid																													
Follicular cell adenoma	+	+	+	+	+	+	+	+	+	+	+	+	+	+	+	+	+	+	+	+	+	+	+	+	+	+	+	+	+
Follicular cell carcinoma	+	+	+	+	+	+	+	+	+	+	+	+	+	+	+	+	+	+	+	+	+	+	+	+	+	+	+	+	+
C cell adenoma	+	+	+	+	+	+	+	+	+	+	+	+	+	+	+	+	+	+	+	+	+	+	+	+	+	+	+	+	+
C cell carcinoma	+	+	+	+	+	+	+	+	+	+	+	+	+	+	+	+	+	+	+	+	+	+	+	+	+	+	+	+	+
Parathyroid																													
Adenoma, NOS	+	+	+	+	+	+	+	+	+	+	+	+	+	+	+	+	+	+	+	+	+	+	+	+	+	+	+	+	+
Pancreatic islets																													
Islet cell adenoma	+	+	+	+	+	+	+	+	+	+	+	+	+	+	+	+	+	+	+	+	+	+	+	+	+	+	+	+	+
Islet cell carcinoma	+	+	+	+	+	+	+	+	+	+	+	+	+	+	+	+	+	+	+	+	+	+	+	+	+	+	+	+	+
REPRODUCTIVE SYSTEM																													
Mammary gland																													
Adenoma, NOS	+	+	+	+	+	+	+	+	+	+	+	+	+	+	+	+	+	+	+	+	+	+	+	+	+	+	+	+	+
Adenocarcinoma, NOS	+	+	+	+	+	+	+	+	+	+	+	+	+	+	+	+	+	+	+	+	+	+	+	+	+	+	+	+	+
Fibroadenoma	+	+	+	+	+	+	+	+	+	+	+	+	+	+	+	+	+	+	+	+	+	+	+	+	+	+	+	+	+
Preputial/clitoral gland																													
Carcinoma, NOS	X	X	X	X	X	X	X	X	X	X	X	X	X	X	X	X	X	X	X	X	X	X	X	X	X	X	X	X	X
Squamous cell carcinoma	X	X	X	X	X	X	X	X	X	X	X	X	X	X	X	X	X	X	X	X	X	X	X	X	X	X	X	X	X
Adenoma, NOS	X	X	X	X	X	X	X	X	X	X	X	X	X	X	X	X	X	X	X	X	X	X	X	X	X	X	X	X	X
Keratoacanthoma	X	X	X	X	X	X	X	X	X	X	X	X	X	X	X	X	X	X	X	X	X	X	X	X	X	X	X	X	X
Uterus																													
Squamous cell carcinoma	+	+	+	+	+	+	+	+	+	+	+	+	+	+	+	+	+	+	+	+	+	+	+	+	+	+	+	+	+
Adenocarcinoma, NOS	+	+	+	+	+	+	+	+	+	+	+	+	+	+	+	+	+	+	+	+	+	+	+	+	+	+	+	+	+
Papillary adenoma	+	+	+	+	+	+	+	+	+	+	+	+	+	+	+	+	+	+	+	+	+	+	+	+	+	+	+	+	+
Sarcoma, NOS	+	+	+	+	+	+	+	+	+	+	+	+	+	+	+	+	+	+	+	+	+	+	+	+	+	+	+	+	+
Leiomyoma	+	+	+	+	+	+	+	+	+	+	+	+	+	+	+	+	+	+	+	+	+	+	+	+	+	+	+	+	+
Endometrial stromal polyp	+	+	+	+	+	+	+	+	+	+	+	+	+	+	+	+	+	+	+	+	+	+	+	+	+	+	+	+	+
Endometrial stromal sarcoma	+	+	+	+	+	+	+	+	+	+	+	+	+	+	+	+	+	+	+	+	+	+	+	+	+	+	+	+	+
Endometrial stromal sarcoma, invasive	+	+	+	+	+	+	+	+	+	+	+	+	+	+	+	+	+	+	+	+	+	+	+	+	+	+	+	+	+
Ovary																													
Granulosa cell tumor	+	+	+	+	+	+	+	+	+	+	+	+	+	+	+	+	+	+	+	+	+	+	+	+	+	+	+	+	+
Granulosa cell carcinoma	+	+	+	+	+	+	+	+	+	+	+	+	+	+	+	+	+	+	+	+	+	+	+	+	+	+	+	+	+
NERVOUS SYSTEM																													
Brain																													
Carcinoma, NOS, invasive	+	+	+	+	+	+	+	+	+	+	+	+	+	+	+	+	+	+	+	+	+	+	+	+	+	+	+	+	+
Astrocytoma	+	+	+	+	+	+	+	+	+	+	+	+	+	+	+	+	+	+	+	+	+	+	+	+	+	+	+	+	+
Astrocytoma, invasive	+	+	+	+	+	+	+	+	+	+	+	+	+	+	+	+	+	+	+	+	+	+	+	+	+	+	+	+	+
SPECIAL SENSE ORGANS																													
Eye appendages																													
Squamous cell carcinoma	N	N	N	N	N	N	N	N	N	N	N	N	N	N	N	N	N	N	N	N	N	N	N	N	N	N	N	N	N
Zymbal gland																													
Carcinoma in situ, NOS	N	N	N	N	N	N	N	N	N	N	N	N	N	N	N	N	N	N	N	N	N	N	N	N	N	N	N	N	N
Squamous cell papilloma	N	N	N	N	N	N	N	N	N	N	N	N	N	N	N	N	N	N	N	N	N	N	N	N	N	N	N	N	N
Squamous cell carcinoma	N	N	N	N	N	N	N	N	N	N	N	N	N	N	N	N	N	N	N	N	N	N	N	N	N	N	N	N	N
MUSCULOSKELETAL SYSTEM																													
Bone																													
Squamous cell carcinoma, invasive	+	N	N	N	N	N	N	N	N	N	N	N	N	N	N	N	N	N	N	N	N	N	N	N	N	N	N	N	N
BODY CAVITIES																													
Mediastinum																													
Mesothelioma, malignant	N	N	N	N	N	N	N	N	N	N	N	N	N	N	N	N	N	N	N	N	N	N	N	N	N	N	N	N	N
ALL OTHER SYSTEMS																													
Multiple organs, NOS																													
Squamous cell carcinoma, invasive	N	N	N	N	N	N	N	N	N	N	N	N	N	N	N	N	N	N	N	N	N	N	N	N	N	N	N	N	N
Squamous cell carcinoma, metastatic	N	N	N	N	N	N	N	N	N	N	N	N	N	N	N	N	N	N	N	N	N	N	N	N	N	N	N	N	N
C cell carcinoma, metastatic	N	N	N	N	N	N	N	N	N	N	N	N	N	N	N	N	N	N	N	N	N	N	N	N	N	N	N	N	N
Endometrial stromal sarcoma, invasive	N	N	N	N	N	N	N	N	N	N	N	N	N	N	N	N	N	N	N	N	N	N	N	N	N	N	N	N	N
Mesothelioma, invasive	N	N	N	N	N	N	N	N	N	N	N	N	N	N	N	N	N	N	N	N	N	N	N	N	N	N	N	N	N
Malignant lymphoma, lymphocytic type	N	N	N	N	N	N	N	N	N	N	N	N	N	N	N	N	N	N	N	N	N	N	N	N	N	N	N	N	N
Myelomonocytic leukemia	N	N	N	N	N	N	N	N	N	N	N	N	N	N	N	N	N	N	N	N	N	N	N	N	N	N	N	N	N
Monocytic leukemia	X	X	X	X	X	X	X	X	X	X	X	X	X	X	X	X	X	X	X	X	X	X	X	X	X	X	X	X	X
Adipose tissue																													
Cortical carcinoma, invasive	X	X	X	X	X	X	X	X	X	X	X	X	X	X	X	X	X	X	X	X	X	X	X	X	X	X	X	X	X

TABLE B2. INDIVIDUAL ANIMAL TUMOR PATHOLOGY OF FEMALE RATS: 1% CROCIDOLITE ASBESTOS (Continued)

ANIMAL NUMBER	WEEKS ON STUDY																				TOTAL TISSUES TUMORS	
	0 4	0 8	0 2	0 6	0 10	0 14	0 18	0 22	0 26	1 0	1 4	1 8	1 12	1 16	1 20	1 24	1 28	1 32	1 36	1 40		
ENDOCRINE SYSTEM																						
Pituitary	+	+	+	+	+	+	+	+	+	+	+	+	+	+	+	+	+	+	+	+	247	
Carcinoma, NOS																					8	
Adenoma, NOS		X		X	X		X	X	X	X	X							X	X	X	X	101
Adrenal	+	+	+	+	+	+	+	+	+	+	+	+	+	+	+	+	+	+	+	+	250	
Cortical adenoma																					18	
Cortical carcinoma		X		X														X			1	
Pheochromocytoma																				X	39	
Pheochromocytoma, malignant																				X	3	
Ganglioneuroma																				X	2	
Thyroid	+	+	+	+	+	+	+	+	+	+	+	+	+	+	+	+	+	+	+	+	250	
Follicular cell adenoma																					8	
Follicular cell carcinoma		X												X							2	
C-cell adenoma																				X	23	
C cell carcinoma		X	X																	X	46	
Parathyroid	+	+	+	+	+	+	+	+	+	+	+	+	+	+	+	+	+	+	+	+	224	
Adenoma, NOS																				X	1	
Pancreatic islets	+	+	+	+	+	+	+	+	+	+	+	+	+	+	+	+	+	+	+	+	249	
Islet cell adenoma																				X	5	
Islet cell carcinoma																				X	6	
REPRODUCTIVE SYSTEM																						
Mammary gland	+	+	+	+	+	+	+	+	+	+	+	+	+	+	+	+	+	+	+	+	*250	
Adenoma, NOS																					1	
Adenocarcinoma, NOS																				X	23	
Fibroadenoma	X	X			X	X	X	X											X	X	112	
Preputial/clitoral gland	N	N	N	N	N	N	N	N	N	N	N	N	N	N	N	N	N	N	N	N	*250	
Carcinoma, NOS																					1	
Squamous cell carcinoma																				X	22	
Adenoma, NOS																					2	
Keratoacanthoma																					1	
Uterus	+	+	+	+	+	+	+	+	+	+	+	+	+	+	+	+	+	+	+	+	248	
Squamous cell carcinoma																					1	
Adenocarcinoma, NOS																					2	
Papillary adenoma																					2	
Sarcoma, NOS																					1	
Leiomyoma																					1	
Endometrial stromal polyp																				X	38	
Endometrial stromal sarcoma																					3	
Endometrial stromal sarcoma, invasive																					1	
Ovary	+	+	+	+	+	+	+	+	+	+	+	+	+	+	+	+	+	+	+	+	248	
Granulosa cell tumor																					4	
Granulosa cell carcinoma																				X	1	
NERVOUS SYSTEM																						
Brain	+	+	+	+	+	+	+	+	+	+	+	+	+	+	+	+	+	+	+	+	248	
Carcinoma, NOS, invasive																				X	7	
Astrocytoma																					1	
Astrocytoma, invasive																					1	
SPECIAL SENSE ORGANS																						
Eye appendages	N	N	N	N	N	N	N	N	N	N	N	N	N	N	N	N	N	N	N	N	*250	
Squamous cell carcinoma																					1	
Zymbal gland	N	N	N	N	N	N	N	N	N	N	N	N	N	N	N	N	N	N	N	N	*250	
Carcinoma in situ, NOS																					1	
Squamous cell papilloma																					1	
Squamous cell carcinoma																					4	
MUSCULOSKELETAL SYSTEM																						
Bone	N	N	N	N	N	N	N	N	N	N	N	N	N	N	N	N	N	N	N	N	*250	
Squamous cell carcinoma, invasive																				X	3	
BODY CAVITIES																						
Mediastinum	N	N	N	N	N	N	N	N	N	N	N	N	N	N	N	N	N	N	N	N	*250	
Mesothelioma, malignant																					1	
ALL OTHER SYSTEMS																						
Multiple organs, NOS	N	N	N	N	N	N	N	N	N	N	N	N	N	N	N	N	N	N	N	N	*250	
Squamous cell carcinoma, invasive																					2	
Squamous cell carcinoma, metastatic																					1	
C cell carcinoma, metastatic																					1	
Endometrial stromal sarcoma, invasive																					2	
Mesothelioma, invasive																					1	
Malignant lymphoma, lymphocytic type																					1	
Myelomonocytic leukemia																					4	
Monocytic leukemia																					4	
Adipose tissue																					118	
Cortical carcinoma, invasive																					1	

* Animals necropsied

TABLE B3. ANALYSIS OF PRIMARY TUMORS IN FEMALE RATS IN THE LIFETIME FEED STUDY OF CROCIDOLITE ASBESTOS

	Control	1% Crocidolite Asbestos
Integumentary System: Fibroma		
Overall Rates (a)	6/118 (5%)	9/250 (4%)
Adjusted Rates (b)	14.5%	15.8%
Terminal Rates (c)	0/15 (0%)	2/29 (7%)
Week of First Observation	98	102
Life Table Test (d)		P=0.307N
Incidental Tumor Test (d)		P=0.345N
Fisher Exact Test (d)		P=0.339N
Integumentary System: Fibroma or Neurofibroma		
Overall Rates (a)	6/118 (5%)	10/250 (4%)
Adjusted Rates (b)	14.5%	16.8%
Terminal Rates (c)	0/15 (0%)	2/29 (7%)
Week of First Observation	98	102
Life Table Test (d)		P=0.373N
Incidental Tumor Test (d)		P=0.416N
Fisher Exact Test (d)		P=0.409N
Integumentary System: Fibroma or Fibrosarcoma		
Overall Rates (a)	9/118 (8%)	14/250 (6%)
Adjusted Rates (b)	26.3%	20.1%
Terminal Rates (c)	1/15 (7%)	2/29 (7%)
Week of First Observation	98	102
Life Table Test (d)		P=0.252N
Incidental Tumor Test (d)		P=0.293N
Fisher Exact Test (d)		P=0.297N
Integumentary System: Fibroma, Neurofibroma, Sarcoma, Fibrosarcoma, or Neurofibrosarcoma		
Overall Rates (a)	10/118 (8%)	16/250 (6%)
Adjusted Rates (b)	29.3%	21.1%
Terminal Rates (c)	1/15 (7%)	2/29 (7%)
Week of First Observation	98	102
Life Table Test (d)		P=0.248N
Incidental Tumor Test (d)		P=0.298N
Fisher Exact Test (d)		P=0.301N
Hematopoietic System: Monocytic Leukemia		
Overall Rates (a)	43/118 (36%)	118/250 (47%)
Adjusted Rates (b)	66.7%	74.9%
Terminal Rates (c)	3/15 (20%)	8/29 (28%)
Week of First Observation	60	76
Life Table Test (d)		P=0.152
Incidental Tumor Test (d)		P=0.032
Fisher Exact Test (d)		P=0.033
Hematopoietic System: Myelomonocytic Leukemia		
Overall Rates (a)	0/118 (0%)	4/250 (2%)
Adjusted Rates (b)	0.0%	2.7%
Terminal Rates (c)	0/15 (0%)	0/29 (0%)
Week of First Observation		118
Life Table Test (d)		P=0.227
Incidental Tumor Test (d)		P=0.238
Fisher Exact Test (d)		P=0.211
Hematopoietic System: All Leukemia		
Overall Rates (a)	43/118 (36%)	122/250 (49%)
Adjusted Rates (b)	66.7%	75.6%
Terminal Rates (c)	3/15 (20%)	8/29 (28%)
Week of First Observation	60	76
Life Table Test (d)		P=0.111
Incidental Tumor Test (d)		P=0.018
Fisher Exact Test (d)		P=0.017

TABLE B3. ANALYSIS OF PRIMARY TUMORS IN FEMALE RATS IN THE LIFETIME FEED STUDY OF CROCIDOLITE ASBESTOS (Continued)

	Control	1% Crocidolite Asbestos
Pituitary Gland: Adenoma		
Overall Rates (a)	42/116 (36%)	101/247 (41%)
Adjusted Rates (b)	76.0%	82.9%
Terminal Rates (c)	8/14 (57%)	16/29 (55%)
Week of First Observation	70	63
Life Table Test (d)		P=0.383
Incidental Tumor Test (d)		P=0.239
Fisher Exact Test (d)		P=0.231
Pituitary Gland: Carcinoma		
Overall Rates (a)	9/116 (8%)	8/247 (3%)
Adjusted Rates (b)	26.1%	9.6%
Terminal Rates (c)	1/14 (7%)	1/29 (3%)
Week of First Observation	91	100
Life Table Test (d)		P=0.045N
Incidental Tumor Test (d)		P=0.034N
Fisher Exact Test (d)		P=0.055N
Pituitary Gland: Adenoma or Carcinoma		
Overall Rates (a)	51/116 (44%)	109/247 (44%)
Adjusted Rates (b)	84.1%	85.3%
Terminal Rates (c)	9/14 (64%)	17/29 (59%)
Week of First Observation	70	63
Life Table Test (d)		P=0.415N
Incidental Tumor Test (d)		P=0.517N
Fisher Exact Test (d)		P=0.534
Adrenal Gland: Cortical Adenoma		
Overall Rates (a)	4/118 (3%)	18/250 (7%)
Adjusted Rates (b)	21.6%	25.3%
Terminal Rates (c)	3/15 (20%)	4/29 (14%)
Week of First Observation	128	104
Life Table Test (d)		P=0.131
Incidental Tumor Test (d)		P=0.126
Fisher Exact Test (d)		P=0.111
Adrenal Gland: Cortical Adenoma or Carcinoma		
Overall Rates (a)	6/118 (5%)	19/250 (8%)
Adjusted Rates (b)	29.0%	27.5%
Terminal Rates (c)	4/15 (27%)	4/29 (14%)
Week of First Observation	106	104
Life Table Test (d)		P=0.278
Incidental Tumor Test (d)		P=0.266
Fisher Exact Test (d)		P=0.255
Adrenal Gland: Pheochromocytoma		
Overall Rates (a)	17/118 (14%)	39/250 (16%)
Adjusted Rates (b)	54.7%	55.4%
Terminal Rates (c)	6/15 (40%)	10/29 (34%)
Week of First Observation	84	92
Life Table Test (d)		P=0.484
Incidental Tumor Test (d)		P=0.490
Fisher Exact Test (d)		P=0.448
Adrenal Gland: Pheochromocytoma or Malignant Pheochromocytoma		
Overall Rates (a)	19/118 (16%)	42/250 (17%)
Adjusted Rates (b)	55.8%	57.2%
Terminal Rates (c)	6/15 (40%)	10/29 (34%)
Week of First Observation	84	60
Life Table Test (d)		P=0.537
Incidental Tumor Test (d)		P=0.561N
Fisher Exact Test (d)		P=0.497

TABLE B3. ANALYSIS OF PRIMARY TUMORS IN FEMALE RATS IN THE LIFETIME FEED STUDY OF CROCIDOLITE ASBESTOS (Continued)

	Control	1% Crocidolite Asbestos
Thyroid Gland: Follicular Cell Adenoma		
Overall Rates (a)	8/117 (7%)	8/250 (3%)
Adjusted Rates (b)	18.8%	13.5%
Terminal Rates (c)	1/15 (7%)	2/29 (7%)
Week of First Observation	92	118
Life Table Test (d)		P=0.092N
Incidental Tumor Test (d)		P=0.084N
Fisher Exact Test (d)		P=0.097N
Thyroid Gland: Follicular Cell Adenoma or Carcinoma		
Overall Rates (a)	11/117 (9%)	10/250 (4%)
Adjusted Rates (b)	28.2%	15.2%
Terminal Rates (c)	2/15 (13%)	2/29 (7%)
Week of First Observation	92	118
Life Table Test (d)		P=0.032N
Incidental Tumor Test (d)		P=0.025N
Fisher Exact Test (d)		P=0.037N
Thyroid Gland: C-Cell Adenoma		
Overall Rates (a)	4/117 (3%)	23/250 (9%)
Adjusted Rates (b)	17.1%	34.3%
Terminal Rates (c)	2/15 (13%)	5/29 (17%)
Week of First Observation	122	107
Life Table Test (d)		P=0.046
Incidental Tumor Test (d)		P=0.038
Fisher Exact Test (d)		P=0.034
Thyroid Gland: C-Cell Carcinoma		
Overall Rates (a)	12/117 (10%)	46/250 (18%)
Adjusted Rates (b)	39.9%	53.4%
Terminal Rates (c)	3/15 (20%)	6/29 (21%)
Week of First Observation	114	99
Life Table Test (d)		P=0.054
Incidental Tumor Test (d)		P=0.041
Fisher Exact Test (d)		P=0.030
Thyroid Gland: C-Cell Adenoma or Carcinoma		
Overall Rates (a)	16/117 (14%)	68/250 (27%)
Adjusted Rates (b)	52.2%	71.2%
Terminal Rates (c)	5/15 (33%)	11/29 (38%)
Week of First Observation	114	99
Life Table Test (d)		P=0.008
Incidental Tumor Test (d)		P=0.003
Fisher Exact Test (d)		P=0.002
Mammary Gland: Fibroadenoma		
Overall Rates (a)	48/118 (41%)	112/250 (45%)
Adjusted Rates (b)	85.7%	85.7%
Terminal Rates (c)	9/15 (60%)	17/29 (59%)
Week of First Observation	83	76
Life Table Test (d)		P=0.417
Incidental Tumor Test (d)		P=0.322
Fisher Exact Test (d)		P=0.264
Mammary Gland: Adenoma or Fibroadenoma		
Overall Rates (a)	49/118 (42%)	112/250 (45%)
Adjusted Rates (b)	86.0%	85.7%
Terminal Rates (c)	9/15 (60%)	17/29 (59%)
Week of First Observation	83	76
Life Table Test (d)		P=0.467
Incidental Tumor Test (d)		P=0.385
Fisher Exact Test (d)		P=0.316

TABLE B3. ANALYSIS OF PRIMARY TUMORS IN FEMALE RATS IN THE LIFETIME FEED STUDY OF CROCIDOLITE ASBESTOS (Continued)

	Control	1% Crocidolite Asbestos
Mammary Gland: Adenocarcinoma		
Overall Rates (a)	16/118 (14%)	23/250 (9%)
Adjusted Rates (b)	46.6%	39.2%
Terminal Rates (c)	3/15 (20%)	7/29 (24%)
Week of First Observation	70	87
Life Table Test (d)		P=0.131N
Incidental Tumor Test (d)		P=0.102N
Fisher Exact Test (d)		P=0.140N
Mammary Gland: Adenoma or Adenocarcinoma		
Overall Rates (a)	18/118 (15%)	24/250 (10%)
Adjusted Rates (b)	48.2%	39.8%
Terminal Rates (c)	3/15 (20%)	7/29 (24%)
Week of First Observation	70	87
Life Table Test (d)		P=0.074N
Incidental Tumor Test (d)		P=0.049N
Fisher Exact Test (d)		P=0.081N
Mammary Gland: Adenoma, Fibroadenoma, or Adenocarcinoma		
Overall Rates (a)	58/118 (49%)	125/250 (50%)
Adjusted Rates (b)	90.5%	90.6%
Terminal Rates (c)	10/15 (67%)	20/29 (69%)
Week of First Observation	70	76
Life Table Test (d)		P=0.459N
Incidental Tumor Test (d)		P=0.508N
Fisher Exact Test (d)		P=0.484
Preputial (Clitoral) Gland Squamous Cell Carcinoma		
Overall Rates (a)	4/118 (3%)	22/250 (9%)
Adjusted Rates (b)	20.6%	31.6%
Terminal Rates (c)	2/15 (13%)	5/29 (17%)
Week of First Observation	137	109
Life Table Test (d)		P=0.058
Incidental Tumor Test (d)		P=0.053
Fisher Exact Test (d)		P=0.042
Preputial (Clitoral) Gland Carcinoma or Squamous Cell Carcinoma		
Overall Rates (a)	4/118 (3%)	23/250 (9%)
Adjusted Rates (b)	20.6%	32.2%
Terminal Rates (c)	2/15 (13%)	5/29 (17%)
Week of First Observation	137	109
Life Table Test (d)		P=0.047
Incidental Tumor Test (d)		P=0.043
Fisher Exact Test (d)		P=0.032
Preputial (Clitoral) Gland Adenoma, Carcinoma, or Squamous Cell Carcinoma		
Overall Rates (a)	5/118 (4%)	25/250 (10%)
Adjusted Rates (b)	22.2%	33.1%
Terminal Rates (c)	2/15 (13%)	5/29 (17%)
Week of First Observation	127	109
Life Table Test (d)		P=0.060
Incidental Tumor Test (d)		P=0.056
Fisher Exact Test (d)		P=0.041
Uterus: Endometrial Stromal Polyp		
Overall Rates (a)	19/116 (16%)	38/248 (15%)
Adjusted Rates (b)	41.8%	40.7%
Terminal Rates (c)	3/14 (21%)	5/29 (17%)
Week of First Observation	91	60
Life Table Test (d)		P=0.375N
Incidental Tumor Test (d)		P=0.440N
Fisher Exact Test (d)		P=0.454N

TABLE B3. ANALYSIS OF PRIMARY TUMORS IN FEMALE RATS IN THE LIFETIME FEED STUDY OF CROCIDOLITE ASBESTOS (Continued)

	Control	1% Crocidolite Asbestos
All Sites: Benign Tumors		
Overall Rates (a)	91/118 (77%)	190/250 (76%)
Adjusted Rates (b)	100.0%	98.2%
Terminal Rates (c)	15/15 (100%)	26/29 (90%)
Week of First Observation	70	45
Life Table Test (d)		P=0.312N
Incidental Tumor Test (d)		P=0.377N
Fisher Exact Test (d)		P=0.462N
All Sites: Malignant Tumors		
Overall Rates (a)	80/118 (68%)	187/250 (75%)
Adjusted Rates (b)	93.4%	95.8%
Terminal Rates (c)	10/15 (67%)	23/29 (79%)
Week of First Observation	60	53
Life Table Test (d)		P=0.389
Incidental Tumor Test (d)		P=0.128
Fisher Exact Test (d)		P=0.101
All Sites: All Tumors		
Overall Rates (a)	115/118 (97%)	242/250 (97%)
Adjusted Rates (b)	100.0%	100.0%
Terminal Rates (c)	15/15 (100%)	29/29 (100%)
Week of First Observation	60	45
Life Table Test (d)		P=0.297N
Incidental Tumor Test (d)		P=0.513N
Fisher Exact Test (d)		P=0.509N

(a) Number of tumor-bearing animals/number of animals examined at the site

(b) Kaplan-Meier estimated tumor incidences at the end of the study after adjusting for intercurrent mortality

(c) Observed tumor incidence at terminal kill

(d) Beneath the control incidence are the P values associated with the trend test. Beneath the dosed group incidence are the P values corresponding to pairwise comparisons between that dosed group and the controls. The life table analysis regards tumors in animals dying prior to terminal kill as being (directly or indirectly) the cause of death. The incidental tumor test regards these lesions as nonfatal. The Cochran-Armitage and Fisher exact tests compare directly the overall incidence rates. A negative trend or lower incidence in a dosed group is indicated by (N).

TABLE B4a. HISTORICAL INCIDENCE OF LEUKEMIA IN FEMALE F344/N RATS RECEIVING NO TREATMENT IN LIFETIME FEED STUDIES (a)

Asbestos Studies	Incidence in Controls
Chrysotile (short range)	28/88
Chrysotile (intermediate range)	34/88
Tremolite	56/118
Crocidolite	43/118
Amosite	40/117
TOTAL	201/529 (38.0%)
SD (b)	6.01%
Range	
High	56/118 (47.5%)
Low	28/88 (31.8%)

(a) All studies conducted by Hazleton Laboratories; age at start of terminal kill, 138-146 weeks.

(b) Standard deviation

TABLE B4b. HISTORICAL INCIDENCE OF THYROID GLAND FOLLICULAR CELL TUMORS IN FEMALE F344/N RATS RECEIVING NO TREATMENT IN LIFETIME FEED STUDIES (a)

Asbestos Studies	Incidence in Controls		
	Adenoma	Carcinoma	Adenoma or Carcinoma
Chrysotile (short range)	1/87	4/87	5/87
Chrysotile (intermediate range)	6/87	1/87	7/87
Tremolite	3/118	5/118	7/118
Crocidolite	8/117	3/117	11/117
Amosite	2/116	7/116	9/116
TOTAL	20/525 (3.8%)	20/525 (3.8%)	39/525 (7.4%)
SD (b)	2.82%	1.89%	1.54%
Range			
High	6/87 (6.9%)	7/116 (6.0%)	11/117 (9.4%)
Low	1/87 (1.1%)	1/87 (1.1%)	5/87 (5.7%)

(a) All studies conducted by Hazleton Laboratories; age at start of terminal kill, 138-146 weeks.

(b) Standard deviation

TABLE B4c. HISTORICAL INCIDENCE OF THYROID GLAND C-CELL TUMORS IN FEMALE F344/N RATS RECEIVING NO TREATMENT IN LIFETIME FEED STUDIES (a)

Asbestos Studies	Incidence in Controls		
	Adenoma	Carcinoma	Adenoma or Carcinoma
Chrysotile (short range)	11/87	7/87	17/87
Chrysotile (intermediate range)	11/87	11/87	21/87
Tremolite	7/118	18/118	25/118
Crocidolite	4/117	12/117	16/117
Amosite	14/116	10/116	24/116
TOTAL	47/525 (9.0%)	58/525 (11.0%)	103/525 (19.6%)
SD (b)	4.36%	2.99%	3.84%
Range			
High	1/87 (12.6%)	18/116 (15.5%)	21/87 (24.1%)
Low	4/117 (3.4%)	7/87 (8.0%)	16/117 (13.7%)

(a) All studies conducted by Hazleton Laboratories; age at start of terminal kill, 138-146 weeks.
 (b) Standard deviation

TABLE B4d. HISTORICAL INCIDENCE OF CLITORAL GLAND TUMORS IN FEMALE F344/N RATS RECEIVING NO TREATMENT IN LIFETIME FEED STUDIES (a)

Asbestos Studies	Incidence in Controls		
	Adenoma	Carcinoma	Adenoma or Carcinoma
Chrysotile (short range)	1/88	2/88	3/88
Chrysotile (intermediate range)	0/88	1/88	1/88
Tremolite	0/118	6/118	6/118
Crocidolite	1/118	4/118	5/118
Amosite	0/117	6/117	6/117
TOTAL	2/529 (0.2%)	19/529 (3.6%)	21/529 (4.0%)
SD (b)	0.55%	1.75%	1.65%
Range			
High	0/118 (0%)	6/117 (5.1%)	6/117 (5.1%)
Low	1/88 (1.1%)	1/88 (1.1%)	1/88 (1.1%)

(a) All studies conducted by Hazleton Laboratories; age at start of terminal kill, 138-146 weeks.
 (b) Standard deviation

TABLE B5. SUMMARY OF THE INCIDENCE OF NONNEOPLASTIC LESIONS IN FEMALE RATS IN THE LIFETIME FEED STUDY OF CROCIDOLITE ASBESTOS

	Untreated Control	1% Crocidolite Asbestos
ANIMALS INITIALLY IN STUDY	118	250
ANIMALS NECROPSIED	118	250
ANIMALS EXAMINED HISTOPATHOLOGICALLY	118	250
INTEGUMENTARY SYSTEM		
*Skin	(118)	(250)
Abscess, NOS		2 (1%)
Fibrosis, focal		1 (0%)
Hyperplasia, NOS	‡ 1 (1%)	
Hyperkeratosis	1 (1%)	1 (0%)
Acanthosis	1 (1%)	2 (1%)
*Subcutaneous tissue	(118)	(250)
Inflammation, pyogranulomatous		1 (0%)
RESPIRATORY SYSTEM		
*Nasal cavity	(118)	(250)
Congestion, NOS	1 (1%)	
*Nasal turbinate	(118)	(250)
Abscess, NOS		1 (0%)
Inflammation, chronic		1 (0%)
#Trachea	(117)	(250)
Abscess, NOS	1 (1%)	
#Lung	(118)	(250)
Mineralization		1 (0%)
Atelectasis		1 (0%)
Congestion, NOS	2 (2%)	2 (1%)
Hemorrhage	4 (3%)	9 (4%)
Inflammation, interstitial	2 (2%)	6 (2%)
Inflammation, acute diffuse		1 (0%)
Inflammation, chronic	96 (81%)	218 (87%)
Granuloma, NOS	2 (2%)	3 (1%)
Necrosis, focal		1 (0%)
Pigmentation, NOS	5 (4%)	3 (1%)
Hyperplasia, alveolar epithelium	3 (3%)	5 (2%)
#Lung/alveoli	(118)	(250)
Histiocytosis	6 (5%)	11 (4%)
HEMATOPOIETIC SYSTEM		
#Bone marrow	(116)	(249)
Osteopetrosis		2 (1%)
Hypoplasia, NOS	5 (4%)	7 (3%)
Histiocytosis	1 (1%)	
#Spleen	(118)	(250)
Hemorrhage	1 (1%)	6 (2%)
Hemorrhagic cyst	1 (1%)	
Inflammation, fibrinous		2 (1%)
Inflammation, chronic diffuse		1 (0%)
Granuloma, NOS		1 (0%)
Fibrosis, focal		4 (2%)
Fibrosis, multifocal	1 (1%)	2 (1%)
Fibrosis, diffuse		8 (3%)
Necrosis, NOS		2 (1%)
Necrosis, focal		6 (2%)
Infarct, NOS		1 (0%)
Metamorphosis, fatty		1 (0%)
Pigmentation, NOS		1 (0%)
Hemosiderosis	29 (25%)	46 (18%)
Metaplasia, osseous		1 (0%)
Hyperplasia, reticulum cell	1 (1%)	
Hyperplasia, lymphoid	3 (3%)	1 (0%)
Hematopoiesis	22 (19%)	61 (24%)

TABLE B5. SUMMARY OF THE INCIDENCE OF NONNEOPLASTIC LESIONS IN FEMALE RATS IN THE LIFETIME FEED STUDY OF CROCIDOLITE ASBESTOS (Continued)

	Untreated Control	1% Crocidolite Asbestos
HEMATOPOIETIC SYSTEM (Continued)		
#Splenic follicles	(118)	(250)
Atrophy, NOS	2 (2%)	3 (1%)
#Mandibular lymph node	(118)	(250)
Congestion, NOS		1 (0%)
Edema, NOS		1 (0%)
Hemorrhage	1 (1%)	
Pigmentation, NOS		1 (0%)
Atrophy, NOS		1 (0%)
Hyperplasia, reticulum cell		1 (0%)
Hyperplasia, lymphoid	21 (18%)	28 (11%)
#Cervical lymph node	(118)	(250)
Pigmentation, NOS		1 (0%)
Erythrophagocytosis		3 (1%)
#Mediastinal lymph node	(118)	(250)
Congestion, NOS	2 (2%)	1 (0%)
Hemorrhage	5 (4%)	6 (2%)
Pigmentation, NOS	18 (15%)	32 (13%)
Erythrophagocytosis	6 (5%)	9 (4%)
Hyperplasia, reticulum cell	1 (1%)	1 (0%)
Hyperplasia, lymphoid	4 (3%)	4 (2%)
#Pancreatic lymph node	(118)	(250)
Hemorrhage		1 (0%)
Pigmentation, NOS	2 (2%)	4 (2%)
Erythrophagocytosis		1 (0%)
Hyperplasia, reticulum cell	3 (3%)	8 (3%)
Hyperplasia, lymphoid		2 (1%)
Hematopoiesis		1 (0%)
#Mesenteric lymph node	(118)	(250)
Hemorrhage	3 (3%)	2 (1%)
Pigmentation, NOS	3 (3%)	7 (3%)
Atrophy, NOS		2 (1%)
Erythrophagocytosis	4 (3%)	11 (4%)
Hyperplasia, reticulum cell	44 (37%)	68 (27%)
Hyperplasia, lymphoid	6 (5%)	10 (4%)
#Ileocolic lymph node	(118)	(250)
Hemorrhage	1 (1%)	
Hyperplasia, lymphoid	2 (2%)	1 (0%)
#Renal lymph node	(118)	(250)
Hemorrhage		1 (0%)
Pigmentation, NOS		2 (1%)
Atrophy, NOS	2 (2%)	
Erythrophagocytosis	2 (2%)	4 (2%)
Hyperplasia, reticulum cell	1 (1%)	2 (1%)
Hyperplasia, lymphoid	1 (1%)	1 (0%)
#Iliac lymph node	(118)	(250)
Inflammation, acute diffuse		1 (0%)
Hyperplasia, lymphoid		1 (0%)
*Sternum	(118)	(250)
Myelofibrosis		1 (0%)
#Liver	(118)	(250)
Leukocytosis, NOS	5 (4%)	7 (3%)
Hematopoiesis	1 (1%)	2 (1%)
#Adrenal	(118)	(250)
Hematopoiesis	1 (1%)	1 (0%)
#Thymus	(91)	(187)
Multilocular cyst		1 (1%)
Hemorrhage	1 (1%)	

TABLE B5. SUMMARY OF THE INCIDENCE OF NONNEOPLASTIC LESIONS IN FEMALE RATS IN THE LIFETIME FEED STUDY OF CROCIDOLITE ASBESTOS (Continued)

	Untreated Control	1% Crocidolite Asbestos
CIRCULATORY SYSTEM		
#Spleen	(118)	(250)
Thrombosis, NOS		4 (2%)
#Mesenteric lymph node	(118)	(250)
Lymphangiectasis	2 (2%)	3 (1%)
#Ileocolic lymph node	(118)	(250)
Lymphangiectasis	2 (2%)	1 (0%)
#Renal lymph node	(118)	(250)
Lymphangiectasis	1 (1%)	
#Iliac lymph node	(118)	(250)
Lymphangiectasis		1 (0%)
#Heart	(117)	(250)
Inflammation, chronic focal		1 (0%)
Inflammation, chronic diffuse		1 (0%)
#Heart/atrium	(117)	(250)
Thrombosis, NOS	1 (1%)	3 (1%)
#Myocardium	(117)	(250)
Inflammation, chronic		1 (0%)
Inflammation, chronic focal	22 (19%)	67 (27%)
Inflammation, chronic diffuse	34 (29%)	80 (32%)
Fibrosis, focal		1 (0%)
Fibrosis, multifocal		1 (0%)
#Cardiac valve	(117)	(250)
Inflammation, chronic focal	1 (1%)	
#Liver	(118)	(250)
Thrombosis, NOS		2 (1%)
Thrombus, organized	1 (1%)	
#Stomach	(118)	(250)
Periarteritis		1 (0%)
*Mesentery	(118)	(250)
Periarteritis		1 (0%)
#Uterus	(116)	(248)
Thrombosis, NOS		3 (1%)
#Pituitary	(116)	(247)
Thrombosis, NOS		1 (0%)
#Adrenal	(118)	(250)
Thrombosis, NOS		1 (0%)
DIGESTIVE SYSTEM		
*Tongue	(118)	(250)
Acanthosis		1 (0%)
#Salivary gland	(117)	(248)
Mineralization		1 (0%)
Inflammation, acute focal	1 (1%)	
Inflammation, acute diffuse	2 (2%)	
Inflammation, chronic	1 (1%)	3 (1%)
Inflammation, chronic focal	1 (1%)	
Inflammation, chronic diffuse		1 (0%)
Fibrosis		1 (0%)
Fibrosis, diffuse		2 (1%)
Atrophy, NOS	1 (1%)	
Atrophy, focal	1 (1%)	2 (1%)
#Parotid gland	(117)	(248)
Inflammation, chronic diffuse		1 (0%)

TABLE B5. SUMMARY OF THE INCIDENCE OF NONNEOPLASTIC LESIONS IN FEMALE RATS IN THE LIFETIME FEED STUDY OF CROCIDOLITE ASBESTOS (Continued)

	Untreated Control	1% Crocidolite Asbestos
DIGESTIVE SYSTEM (Continued)		
#Liver	(118)	(250)
Congestion, NOS		2 (1%)
Hemorrhage		1 (0%)
Inflammation, chronic		1 (0%)
Inflammation, chronic focal		1 (0%)
Granuloma, NOS	25 (21%)	39 (16%)
Fibrosis, focal	1 (1%)	1 (0%)
Hepatitis, toxic	20 (17%)	56 (22%)
Degeneration, NOS		2 (1%)
Necrosis, NOS		1 (0%)
Necrosis, focal	15 (13%)	38 (15%)
Metamorphosis, fatty	43 (36%)	58 (23%)
Pigmentation, NOS	21 (18%)	55 (22%)
Hemosiderosis		1 (0%)
Focal cellular change	54 (46%)	109 (44%)
Angiectasis	4 (3%)	6 (2%)
#Hepatic capsule	(118)	(250)
Inflammation, acute focal	1 (1%)	
#Bile duct	(118)	(250)
Inflammation, chronic	3 (3%)	7 (3%)
Fibrosis		1 (0%)
Hyperplasia, NOS	6 (5%)	9 (4%)
#Pancreas	(118)	(249)
Ectopia	6 (5%)	6 (2%)
Hemorrhage		1 (0%)
Inflammation, chronic focal		2 (1%)
Necrosis, fat		1 (0%)
Pigmentation, NOS		1 (0%)
Atrophy, NOS	2 (2%)	
Atrophy, focal	3 (3%)	17 (7%)
Atrophy, diffuse	2 (2%)	4 (2%)
#Pancreatic acinus	(118)	(249)
Hyperplasia, focal	2 (2%)	9 (4%)
#Esophagus	(116)	(239)
Inflammation, chronic diffuse	1 (1%)	
Necrosis, diffuse	1 (1%)	
Hyperkeratosis	5 (4%)	3 (1%)
#Stomach	(118)	(250)
Mineralization	1 (1%)	
Cyst, NOS		1 (0%)
Edema, NOS	1 (1%)	
Inflammation, chronic	1 (1%)	2 (1%)
Inflammation, chronic focal	5 (4%)	10 (4%)
Inflammation, chronic diffuse	15 (13%)	34 (14%)
Ulcer, perforated	9 (8%)	17 (7%)
Necrosis, focal	23 (19%)	36 (14%)
Hyperplasia, epithelial	1 (1%)	1 (0%)
Hyperkeratosis	31 (26%)	28 (11%)
Acanthosis	28 (24%)	50 (20%)
#Duodenum	(118)	(250)
Inflammation, acute focal		1 (0%)
Inflammation, chronic focal		2 (1%)
Ulcer, perforated		1 (0%)
Necrosis, focal		1 (0%)
#Jejunum	(118)	(250)
Fibrosis, focal		1 (0%)
Necrosis, focal		1 (0%)
#Ileal mucosa	(118)	(250)
Hyperplasia, NOS		1 (0%)

TABLE B5. SUMMARY OF THE INCIDENCE OF NONNEOPLASTIC LESIONS IN FEMALE RATS IN THE LIFETIME FEED STUDY OF CROCIDOLITE ASBESTOS (Continued)

	Untreated Control	1% Crocidolite Asbestos
DIGESTIVE SYSTEM (Continued)		
#Large intestine	(118)	(250)
Cyst, NOS		1 (0%)
Inflammation, chronic focal		1 (0%)
Parasitism	1 (1%)	8 (3%)
#Colon	(118)	(250)
Fibrosis, multifocal	1 (1%)	
Parasitism	8 (7%)	1 (0%)
Necrosis, focal	1 (1%)	
#Cecum	(118)	(250)
Congestion, NOS	1 (1%)	
Hemorrhage		3 (1%)
Inflammation, acute focal		1 (0%)
Inflammation, acute diffuse		1 (0%)
Inflammation, acute/chronic		1 (0%)
Inflammation, chronic focal		2 (1%)
Inflammation, chronic diffuse		1 (0%)
Fibrosis, focal		1 (0%)
Necrosis, focal	1 (1%)	2 (1%)
Hyperplasia, epithelial		2 (1%)
URINARY SYSTEM		
#Kidney	(117)	(250)
Mineralization	84 (72%)	208 (83%)
Hydronephrosis	1 (1%)	
Inflammation, acute focal	1 (1%)	
Inflammation, chronic	98 (84%)	28 (91%)
Inflammation, chronic diffuse		1 (0%)
Granuloma, NOS		1 (0%)
Fibrosis, focal	1 (1%)	
Necrosis, focal	1 (1%)	
Infarct, NOS	1 (1%)	
Infarct, healed	1 (1%)	
Calcification, NOS	7 (6%)	12 (5%)
Hyperplasia, tubular cell	2 (2%)	
#Kidney/capsule	(117)	(250)
Inflammation, chronic focal	1 (1%)	
#Kidney/cortex	(117)	(250)
Cyst, NOS	1 (1%)	2 (1%)
#Renal papilla	(117)	(250)
Abscess, NOS	1 (1%)	
#Kidney/tubule	(117)	(250)
Pigmentation, NOS	68 (58%)	179 (72%)
#Urinary bladder	(116)	(248)
Edema, NOS	1 (1%)	
Inflammation, chronic	1 (1%)	
Inflammation, chronic focal	1 (1%)	
Inflammation, chronic diffuse		1 (0%)
Hyperplasia, epithelial	3 (3%)	2 (1%)
Hyperplasia, papillary	1 (1%)	
Hyperkeratosis	1 (1%)	
Metaplasia, squamous	1 (1%)	
ENDOCRINE SYSTEM		
#Pituitary	(116)	(247)
Cyst, NOS	6 (5%)	15 (6%)
Hemorrhage	4 (3%)	1 (0%)
Hemorrhagic cyst	3 (3%)	5 (2%)
Necrosis, focal		1 (0%)
Pigmentation, NOS	1 (1%)	2 (1%)
Hyperplasia, focal	13 (11%)	17 (7%)
Angiectasis	13 (11%)	28 (11%)

TABLE B5. SUMMARY OF THE INCIDENCE OF NONNEOPLASTIC LESIONS IN FEMALE RATS IN THE LIFETIME FEED STUDY OF CROCIDOLITE ASBESTOS (Continued)

	Untreated Control	1% Crocidolite Asbestos
ENDOCRINE SYSTEM (Continued)		
#Adrenal	(118)	(250)
Congestion, NOS	1 (1%)	
Hemorrhage	1 (1%)	
Metamorphosis, fatty	1 (1%)	3 (1%)
Pigmentation, NOS	1 (1%)	
Atrophy, NOS	1 (1%)	
Angiectasis	1 (1%)	2 (1%)
Metaplasia, osseous		1 (0%)
#Adrenal cortex	(118)	(250)
Congestion, NOS		3 (1%)
Degeneration, NOS	5 (4%)	12 (5%)
Necrosis, focal	2 (2%)	2 (1%)
Metamorphosis, fatty	35 (30%)	99 (40%)
Hypertrophy, focal	1 (1%)	
Hyperplasia, focal	12 (10%)	30 (12%)
Angiectasis	2 (2%)	12 (5%)
#Adrenal medulla	(118)	(250)
Hyperplasia, focal	19 (16%)	31 (12%)
#Thyroid	(117)	(250)
Cystic follicles		1 (0%)
Follicular cyst, NOS	7 (6%)	11 (4%)
Hemorrhagic cyst		1 (0%)
Hyperplasia, C-cell	15 (13%)	63 (25%)
Hyperplasia, follicular cell	1 (1%)	1 (0%)
#Parathyroid	(108)	(224)
Hyperplasia, NOS	8 (7%)	9 (4%)
#Pancreatic islets	(118)	(249)
Hyperplasia, focal		2 (1%)
REPRODUCTIVE SYSTEM		
*Mammary gland	(118)	(250)
Galactocele	8 (7%)	44 (18%)
Cyst, NOS	1 (1%)	1 (0%)
Cystic ducts	32 (27%)	88 (35%)
Inflammation, acute diffuse		1 (0%)
Abscess, NOS		4 (2%)
Hyperplasia, NOS	11 (9%)	28 (11%)
Hyperplasia, diffuse	2 (2%)	1 (0%)
*Preputial gland	(118)	(250)
Cystic ducts	3 (3%)	8 (3%)
Hemorrhage		1 (0%)
Inflammation, acute		1 (0%)
Inflammation, acute diffuse		2 (1%)
Abscess, NOS	1 (1%)	2 (1%)
Inflammation, acute/chronic	1 (1%)	
Inflammation, chronic diffuse	1 (1%)	2 (1%)
Necrosis, NOS		1 (0%)
Necrosis, focal	1 (1%)	
Necrosis, diffuse		1 (0%)
Hyperplasia, NOS		3 (1%)
Hyperplasia, diffuse	2 (2%)	
Hyperkeratosis	2 (2%)	2 (1%)
*Vagina	(118)	(250)
Acanthosis	1 (1%)	

TABLE B5. SUMMARY OF THE INCIDENCE OF NONNEOPLASTIC LESIONS IN FEMALE RATS IN THE LIFETIME FEED STUDY OF CROCIDOLITE ASBESTOS (Continued)

	Untreated Control	1% Crocidolite Asbestos
REPRODUCTIVE SYSTEM (Continued)		
#Uterus	(116)	(248)
Hydrometra	4 (3%)	8 (3%)
Cyst, NOS		1 (0%)
Hemorrhage		1 (0%)
Inflammation, acute focal		1 (0%)
Inflammation, acute/chronic	1 (1%)	
Inflammation, chronic diffuse	1 (1%)	1 (0%)
Hyperplasia, papillary		1 (0%)
#Cervix uteri	(116)	(248)
Cyst, NOS		1 (0%)
Abscess, NOS	1 (1%)	2 (1%)
Inflammation, chronic focal		1 (0%)
Fibrosis	1 (1%)	3 (1%)
Hyperkeratosis	1 (1%)	2 (1%)
Acanthosis		5 (2%)
#Uterus/endometrium	(116)	(248)
Cyst, NOS	4 (3%)	13 (5%)
#Ovary	(116)	(248)
Cyst, NOS	9 (8%)	10 (4%)
Follicular cyst, NOS		1 (0%)
Parovarian cyst	2 (2%)	3 (1%)
NERVOUS SYSTEM		
#Cerebrum	(118)	(248)
Hemorrhage	2 (2%)	3 (1%)
Inflammation, acute focal		1 (0%)
Necrosis, focal	1 (1%)	2 (1%)
Malacia	1 (1%)	
#Brain	(118)	(248)
Hemorrhage	2 (2%)	
#Cerebellum	(118)	(248)
Hemorrhage	1 (1%)	
Necrosis, focal		1 (0%)
Pigmentation, NOS		1 (0%)
SPECIAL SENSE ORGANS		
*Eye	(118)	(250)
Hemorrhage	5 (4%)	4 (2%)
Empyema	4 (3%)	
Inflammation, acute		1 (0%)
Synechia, anterior	1 (1%)	1 (0%)
Synechia, posterior	2 (2%)	2 (1%)
Cataract	21 (18%)	26 (10%)
Phthisis bulbi	2 (2%)	5 (2%)
*Eye/cornea	(118)	(250)
Inflammation, necrotizing		2 (1%)
Inflammation, acute diffuse	1 (1%)	
Inflammation, chronic focal	7 (6%)	2 (1%)
Inflammation, chronic diffuse	5 (4%)	12 (5%)
*Eye/retina	(118)	(250)
Degeneration, NOS	38 (32%)	78 (31%)
*Eyelid	(118)	(250)
Abscess, NOS		1 (0%)
*Harderian gland	(118)	(250)
Abscess, NOS		1 (0%)
Inflammation, chronic focal		1 (0%)
Inflammation, chronic diffuse		1 (0%)
Inflammation, pyogranulomatous		1 (0%)
Atrophy, NOS		2 (1%)
Hyperplasia, diffuse	1 (1%)	

TABLE B5. SUMMARY OF THE INCIDENCE OF NONNEOPLASTIC LESIONS IN FEMALE RATS IN THE LIFETIME FEED STUDY OF CROCIDOLITE ASBESTOS (Continued)

	Untreated Control	1% Crocidolite Asbestos
SPECIAL SENSE ORGANS (Continued)		
*Zymbal gland	(118)	(250)
Cystic ducts	13 (11%)	24 (10%)
Inflammation, chronic		1 (0%)
Inflammation, chronic focal		1 (0%)
Hyperplasia, focal		1 (0%)
Hyperkeratosis	2 (2%)	4 (2%)
Acanthosis	1 (1%)	
MUSCULOSKELETAL SYSTEM		
*Skull	(118)	(250)
Osteopetrosis	2 (2%)	4 (2%)
*Sternum	(118)	(250)
Osteopetrosis	4 (3%)	18 (7%)
Hypoplasia, NOS	2 (2%)	
*Rib	(118)	(250)
Degeneration, NOS		1 (0%)
BODY CAVITIES		
*Abdominal cavity	(118)	(250)
Embryonal rest		1 (0%)
Inflammation, chronic focal	1 (1%)	
Inflammation, chronic diffuse	1 (1%)	
Necrosis, fat	4 (3%)	11 (4%)
*Mesentery	(118)	(250)
Inflammation, acute focal		1 (0%)
Inflammation, chronic		1 (0%)
Inflammation, chronic focal	1 (1%)	
ALL OTHER SYSTEMS		
*Multiple organs	(118)	(250)
Osteopetrosis	1 (1%)	
Mineralization		1 (0%)
Cyst, NOS	3 (3%)	
Inflammation, chronic	9 (8%)	5 (2%)
Pigmentation, NOS	2 (2%)	1 (0%)
Hyperplasia, NOS	1 (1%)	1 (0%)
Diaphragm		
Hernia, NOS	1	1
Inflammation, acute focal		1
Adipose tissue		
Hamartoma	1	
Inflammation, acute focal	1	1
SPECIAL MORPHOLOGY SUMMARY		
None		

* Number of animals receiving complete necropsy examination, all gross lesions including masses examined microscopically

Number of animals examined microscopically at this site

‡ Multiple occurrence of morphology in the same organ, tissue is counted once only

APPENDIX C

PATHOGEN BURDEN SURVEY

	PAGE	
TABLE C1	INITIAL MICROSCOPIC EXAMINATION FOR ENDOPARASITES AND BACTERIA IN F ₀ RATS IN THE LIFETIME FEED STUDIES OF CROCIDOLITE ASBESTOS	154
TABLE C2	MURINE VIRUS ANTIBODY DETERMINATION IN F ₀ RATS IN THE LIFETIME FEED STUDIES OF CROCIDOLITE ASBESTOS	154
TABLE C3	INITIAL INDIVIDUAL HISTOPATHOLOGIC FINDINGS IN F ₀ RATS IN THE LIFETIME FEED STUDIES OF CROCIDOLITE ASBESTOS	155
	PATHOGEN BURDEN SUMMARY (F ₀ Repeated)	156
TABLE C4	REPEATED MICROSCOPIC EXAMINATION FOR ENDOPARASITES AND BACTERIA IN F ₀ RATS IN THE LIFETIME FEED STUDIES OF CROCIDOLITE ASBESTOS	157
TABLE C5	REPEATED MURINE VIRUS ANTIBODY DETERMINATION IN F ₀ RATS IN THE LIFETIME FEED STUDIES OF CROCIDOLITE ASBESTOS	157
TABLE C6	REPEATED INDIVIDUAL HISTOPATHOLOGIC FINDINGS IN F ₀ RATS IN THE LIFETIME FEED STUDIES OF CROCIDOLITE ASBESTOS	158
	PATHOGEN BURDEN SUMMARY (F ₁)	159
TABLE C7	MICROSCOPIC EXAMINATION FOR ENDOPARASITES AND BACTERIA IN F ₁ RATS IN THE LIFETIME FEED STUDIES OF CROCIDOLITE ASBESTOS	160
TABLE C8	MURINE VIRUS ANTIBODY DETERMINATION IN F ₁ RATS IN THE LIFETIME FEED STUDIES OF CROCIDOLITE ASBESTOS	161
TABLE C9	INDIVIDUAL HISTOPATHOLOGIC FINDINGS IN F ₁ RATS IN THE LIFETIME FEED STUDIES STUDIES OF CROCIDOLITE ASBESTOS	162

TABLE C1. INITIAL MICROSCOPIC EXAMINATION FOR ENDOPARASITES AND BACTERIA IN F₀ RATS IN THE LIFETIME FEED STUDIES OF CROCIDOLITE ASBESTOS

Animal/Specimen Number (a)	Micro-organisms Identified (b)
165/3782	1 + Coliform; 1 + <i>Proteus vulgaris</i>
166/3783	3 + Coliform; 3 + <i>Proteus vulgaris</i>
167/3784	1 + Coliform; 1 + <i>Proteus vulgaris</i>
168/3785	1 + Coliform; 1 + <i>Proteus vulgaris</i>
169/3786	1 + Coliform; 1 + <i>Proteus vulgaris</i>
170/3787	1 + Coliform; 1 + <i>Proteus vulgaris</i>
171/3788	1 + Coliform; 1 + <i>Proteus vulgaris</i>
172/3789	1 + Coliform; 1 + <i>Proteus vulgaris</i>
173/3790	1 + Coliform
174/3791	No growth
175/3792	2 + Coliform
176/3793	2 + Coliform; 1 + <i>Proteus vulgaris</i>
177/3794	1 + Coliform
178/3795	No growth
179/3796	No growth
180/3797	3 + Coliform; 1 + <i>Proteus vulgaris</i>

(a) Date of specimen: 11/16/77

(b) Lung, spleen, feces, and tracheal wash were examined for each specimen; no growth observed in the spleen or lungs; no mycoplasma isolated from tracheal washings.

TABLE C2. MURINE VIRUS ANTIBODY DETERMINATION IN F₀ RATS IN THE LIFETIME FEED STUDIES OF CROCIDOLITE ASBESTOS

Sample Number	Complement Fixation	
	Sendai	LCM
3782	—	—
3784	—	—
3785	—	—
3786	—	—
3788	—	—
3789	—	—
3790	—	—
3792	—	—
3793	—	—
3795	—	—
3796	—	—
3797	—	—
Significant titer	10	10

TABLE C3. INITIAL INDIVIDUAL HISTOPATHOLOGIC FINDINGS IN F₀ RATS IN THE LIFETIME FEED STUDIES OF CROCIDOLITE ASBESTOS

Organ and Lesion	Animal Number:	Male								Female							
		1 6 5	1 6 6	1 6 7	1 6 8	1 6 9	1 7 0	1 7 1	1 7 2	1 7 3	1 7 4	1 7 5	1 7 6	1 7 7	1 7 8	1 8 9	1 8 0
Brain		X	X	X	X	X	X	X	X	X	X	X	X	X	X	X	X
Heart		X	X	X	X	X	X	X	X	X	X	X	X	X	X	X	O
Lung																	X
Peribronchial lymphoid hyperplasia	2	1	1	1	2	1	1	2	2	2	2	2	2	2		1	
Perivascular lymphoid hyperplasia		1	1									1					
Aspirated blood											P						
Spleen		X	X	X	X	X	X	X	X	X	X	X	X	X	X	X	
Liver		X	X		X	X	X	X	X	X	X	X	X	X	X	X	
Nonsuppurative pericholangitis				1													
Kidney		X	X	X	X	X	X	X	X	X	X	X	X	X	X	X	
Small intestine		X	X	X	X	X	X	X	X	X	X	X	X	X	X	X	
Large intestine		X	X	X	X	X	X	X	X	X	X	X	X	X	X	X	
Salivary gland		X	X	X	X	X	X	X	X	X	X	X	X	X	X	X	
Urinary bladder		X	X	X	X	X	X	X	X	X	X	X	X	X	X	O	
Harderian gland		X	X	X	X	X	X	X	X	X	O	X	X	X	X	O	
Skin		X	X	X	X	O	X	X	X	X	O	X	X	O	X	O	
Anus		O	X	O	X	X	X	O	X	X	X	X	X	X	X	X	
Trachea		X	X	X	X	X	O	X	X	X	X	X	X	X	X	X	

Type of Finding

- O = Tissue absent
- X = Tissue examined and not remarkable
- P = Finding present

Degree of Finding

- 1 = Minimal
- 2 = Slight
- 3 = Moderate
- 4 = Moderately severe
- 5 = Severe

Pathogen Burden Summary (F₀ Repeated)

Sections of brain, heart, lung, spleen, liver, kidney, small intestine, large intestine, salivary gland, urinary bladder, harderian gland, skin, anus, and cecum were examined from five rats of each sex in the parental generation killed for pathology burden.

Evidence of respiratory disease was noted in all rats. This was characterized by minimal to moderate peribronchial lymphoid hyperplasia in all 10 rats and a bronchial exudate in 6 rats. The respiratory disease was slightly more pronounced than that observed at a prior kill. Microbiologic examination did not reveal the presence of *Mycoplasma* sp., and serum titers were negative for Sendai virus.

Minimal to focal nonsuppurative myocarditis was noted in two males. Minimal to slight pigment deposition (presumably hemosiderin) was noted in sections of spleen from three rats.

In sections of liver, minimal nonsuppurative pericholangitis occurred in four males and two females, and scattered microgranulomas and vacuolated hepatocytes were each noted in single male rats.

In sections of kidney, minimal chronic interstitial nephritis occurred in all five males and in one female. Intratubular mineralization was noted at the corticomedullary junction in four females.

Porphyrin pigment was noted in the harderian gland of four rats.

The remaining tissues examined were not remarkable; no external or internal parasites were observed.

TABLE C4. REPEATED MICROSCOPIC EXAMINATION FOR ENDOPARASITES AND BACTERIA IN F₀ RATS IN THE LIFETIME FEED STUDIES OF CROCIDOLITE ASBESTOS

Animal/Specimen Number (a)	Micro-organisms Identified (b)
287/4021	4+ Group D <i>Streptococcus</i> ; 3+ Coliform, 3+ <i>Proteus vulgaris</i> 2+ <i>Pseudomonas aeruginosa</i>
288/4022	4+ Group D <i>Streptococcus</i> , 3+ <i>Micrococcus</i> sp.; 3+ Coliform; 2+ <i>Proteus vulgaris</i> ; 2+ <i>Pseudomonas aeruginosa</i>
289/4023	4+ Group D <i>Streptococcus</i> ; 4+ <i>Staphylococcus epidermis</i> ; 4+ <i>Micrococcus</i> sp.; 1+ Coliform
290/4024	4+ Group D <i>Streptococcus</i> ; 4+ <i>Micrococcus</i> sp.; 4+ Coliform; 1+ <i>Pseudomonas aeruginosa</i>
291/4025	4+ Group D <i>Streptococcus</i> ; 4+ <i>Micrococcus</i> sp.; 4+ Coliform; 2+ <i>Pseudomonas aeruginosa</i>
292/4026	4+ Group D <i>Streptococcus</i> ; 4+ <i>Micrococcus</i> sp., 4+ Coliform, 2+ <i>Pseudomonas aeruginosa</i>
293/4027	4+ Group D <i>Streptococcus</i> ; 2+ <i>Micrococcus</i> sp., 2+ Coliform; 3+ <i>Proteus vulgaris</i> ; 1+ <i>Pseudomonas aeruginosa</i>
294/4028	4+ Group D <i>Streptococcus</i> ; 4+ <i>Micrococcus</i> sp.; 4+ Diphtheroids; 4+ Coliform, 4+ <i>Pseudomonas aeruginosa</i>
295/4029	4+ Group D <i>Streptococcus</i> ; 4+ <i>Micrococcus</i> sp.; 4+ Coliform
296/4030	4+ Group D <i>Streptococcus</i> ; 4+ <i>Micrococcus</i> sp.; 4+ Diphtheroids; 4+ Coliform, 4+ <i>Proteus vulgaris</i>

(a) Date of specimen 6/5/78

(b) Lung, spleen, feces, and tracheal wash were examined for each specimen, no growth observed in the spleen or lung; no mycoplasma isolated from tracheal washings

TABLE C5. REPEATED MURINE VIRUS ANTIBODY DETERMINATION IN F₀ RATS IN THE LIFETIME FEED STUDIES OF CROCIDOLITE ASBESTOS

Sample Number	<u>Complement Fixation</u>	
	Sendai	LCM
4021	—	—
4022	—	—
4023	—	—
4024	—	—
4025	—	—
4026	—	—
4027	—	—
4028	—	—
4029	—	—
4030	—	—
Significant titer	10	10

TABLE C6. REPEATED INDIVIDUAL HISTOPATHOLOGIC FINDINGS IN F₀ RATS IN THE LIFETIME FEED STUDIES OF CROCIDOLITE ASBESTOS

Organ and Lesion	Animal Number:	Control					1% Crocidolite				
		Male		Female			Male		Female		
		2	2	2	2	2	2	2	2	2	2
		8	8	8	9	9	9	9	9	9	9
		7	8	9	0	1	2	3	4	5	6
Brain		X	X	X	X	X	X	X	X	X	X
Heart			X	X	X		X	X	X	X	X
Focal nonsuppurative myocarditis		1				1					
Lung											
Peribronchial lymphoid hyperplasia		1	2	2	3	3	2	1	1	2	2
Bronchial exudate			P	P	P	P				P	P
Spleen			X	X	X		X	X	X		X
Pigment deposition		1			2					2	
Liver							X		X		X
Microgranulomas		P									
Vacuolated hepatocytes				P							
Nonsuppurative pericholangitis		1	1		1	1	1			1	
Kidney											
Chronic interstitial nephritis		1	1	1	1	1	1				
Foci of mineralization								P	P	P	P
Small intestine		X	X	X	X	X	X	X	X	X	X
Large intestine		X	X	X	X	X	X	X	X	X	X
Salivary gland		X	X	X	X	X	X	X	X	X	O
Urinary bladder		X	X	X	X	X	X	X	X	X	X
Harderian gland			X	O	X		O		O	O	
Porphyrin pigment		P				P	P				P
Skin		X	X	X	X	X	X	X	X	X	O
Anus		X	O	O	O	O	O	O	O	X	O
Cecum		X	X	X	X	X	X	X	O	X	X

Type of Finding:

- O = Tissue absent
- X = Tissue examined and not remarkable
- P = Finding present

Degree of Finding:

- 1 = Minimal
- 2 = Slight
- 3 = Moderate
- 4 = Moderately severe
- 5 = Severe

Pathogen Burden Summary (F₁)

Sections of brain, heart, lung, spleen, liver, kidney, small intestine, large intestine, salivary gland, urinary gland, harderian gland, skin, anus, and cecum were examined from eight male and eight female rats killed for pathology burden.

Evidence of early spontaneous respiratory disease was present in the lungs of all rats examined. This lesion consisted of minimal to slight peribronchial lymphoid hyperplasia. Microbiologic examination did not reveal the presence of *Mycoplasma* sp., and serum titers were negative for Sendai virus.

In sections of kidney, foci of intratubular mineralization were noted at the corticomedullary junction in two males and six females.

The remaining tissues examined were not remarkable; no external or internal parasites were observed.

TABLE C7. MICROSCOPIC EXAMINATION FOR ENDOPARASITES AND BACTERIA IN F₁ RATS IN THE LIFETIME FEED STUDIES OF CROCIDOLITE ASBESTOS

Animal/Specimen Number (a)	Micro-organisms Identified (b)
245/3951	4+ Group D <i>Streptococcus</i> ; 1+ <i>Staphylococcus aureus</i> ; 3+ Coliform; 3+ <i>Pseudomonas aeruginosa</i>
246/3952	4+ Group D <i>Streptococcus</i> ; 1+ <i>Proteus morganii</i> ; 1+ <i>Pseudomonas aeruginosa</i>
247/3953	4+ Group D <i>Streptococcus</i> ; 3+ Coliform; 1+ <i>Proteus vulgaris</i>
248/3954	4+ Group D <i>Streptococcus</i> ; 1+ <i>Staphylococcus aureus</i> ; 2+ Coliform; 2+ <i>Pseudomonas aeruginosa</i>
249/3955	4+ Group D <i>Streptococcus</i> ; 3+ <i>Staphylococcus epidermidis</i> ; 4+ <i>Pseudomonas aeruginosa</i>
250/3956	4+ Group D <i>Streptococcus</i> ; 1+ <i>Bacillus</i> sp.; 1+ Coliform
251/3957	4+ Group D <i>Streptococcus</i> ; 1+ <i>Staphylococcus aureus</i> ; 3+ Coliform
252/3958	4+ Group D <i>Streptococcus</i> ; 3+ Coliform; 2+ <i>Proteus vulgaris</i> ; 1+ <i>Pseudomonas aeruginosa</i>
253/3959	4+ Group D <i>Streptococcus</i> ; 1+ <i>Micrococcus</i> sp.; 3+ Coliform
254/3960	1+ <i>Bacillus</i> sp.; 4+ Group D <i>Streptococcus</i> ; 1+ Coliform
255/3961	4+ Group D <i>Streptococcus</i> ; 1+ <i>Bacillus</i> sp.
256/3962	4+ Group D <i>Streptococcus</i> ; 4+ Coliform
257/3963	4+ Group D <i>Streptococcus</i> ; 1+ Coliform
258/3964	4+ Group D <i>Streptococcus</i> ; 3+ Coliform; 1+ <i>Pseudomonas aeruginosa</i>
259/3965	4+ Group D <i>Streptococcus</i> ; 3+ Coliform; 1+ <i>Pseudomonas aeruginosa</i> ; 2+ <i>Proteus vulgaris</i>
260/3966	4+ Group D <i>Streptococcus</i> ; 2+ <i>Staphylococcus aureus</i> ; 1+ <i>Pseudomonas aeruginosa</i>

(a) Date of specimen: 4/24/78

(b) Lung, spleen, feces, and tracheal wash were examined for each specimen; no growth observed in the spleen or lung; no mycoplasma isolated from tracheal washings.

TABLE C8. MURINE VIRUS ANTIBODY DETERMINATION IN F₁ RATS IN THE LIFETIME FEED STUDIES OF CROCIDOLITE ASBESTOS

Sample Number	Complement Fixation	
	Sendai	LCM
3951	—	—
3952	—	—
3953	—	—
3954	—	—
3955	—	—
3957	—	—
3958	—	—
3959	—	—
3960	—	—
3961	—	—
3962	—	—
3963	—	—
3964	—	—
3966	—	—
Significant titer	10	10

TABLE C9. INDIVIDUAL HISTOPATHOLOGIC FINDINGS IN F₁ RATS IN THE LIFETIME FEED STUDIES OF CROCIDOLITE ASBESTOS

Organ and Lesion	Animal Number:	Control						1% Crocidolite									
		Male			Female			Male					Female				
		2	2	2	2	2	2	2	2	2	2	2	2	2	2	2	2
4	4	4	4	4	5	5	5	5	5	5	5	5	5	5	6		
		5	6	7	8	9	0	1	2	3	4	5	6	7	8	9	0
Brain		X	X	X	X	X	X	X	X	X	X	X	X	X	X	X	X
Heart		X	X	X	X	X	X	X	X	X	X	X	X	X	X	X	X
Lung																	
Peribronchial lymphoid hyperplasia		1	2	2	2	2	2	1	2	1	1	2	1	1	2	2	1
Spleen		X	X	X	O	X	X	X	X	X	X	X	X	X	X	X	X
Liver		X	X	X	X	X	X	X	X	X	X	X	X	X	X	X	X
Kidney			X	X				X	X	X	X		X	X			
Focal mineralization		P			P	P	P					P			P	P	P
Small intestine		X	X	X	X	X	X	X	X	X	X	X	X	X	X	X	X
Large intestine		X	X	X	X	X	X	X	X	X	X	X	X	X	X	X	X
Salivary gland		X	X	X	X	X	X	X	X	X	X	X	X	X	X	X	O
Urinary bladder		X	X	X	X	X	X	X	X	X	X	X	O	X	X	X	X
Harderian gland		X	X	X	O	O	O	X	X	X	X	X	X	X	X	X	O
Skin		X	O	X	X	X	X	X	O	X	X	X	X	X	X	X	X
Anus		X	X	X	X	X	X	X	X	X	X	X	X	X	X	X	X
Cecum		O	X	X	X	X	X	X	X	X	X	X	X	X	O	X	X

Type of Finding:

- O = Tissue absent
- X = Tissue examined and not remarkable
- P = Finding present

Degree of Finding:

- 1 = Minimal
- 2 = Slight
- 3 = Moderate
- 4 = Moderately severe
- 5 = Severe

APPENDIX D

ANALYSIS OF BEDDING SAMPLES IN THE LIFETIME FEED STUDIES OF CROCIDOLITE ASBESTOS

	PAGE
TABLE D1 ANALYSIS OF BEDDING SAMPLES AT HAZLETON LABORATORIES	164
TABLE D2 ANALYSIS OF BEDDING SAMPLES AT ILLINOIS INSTITUTE OF TECHNOLOGY RESEARCH INSTITUTE	164

TABLE D1. ANALYSIS OF BEDDING SAMPLES AT HAZLETON LABORATORIES

Collection Date	Desired Level (ppm)	Determined Level of Pentachlorophenol (ppm)	Determined Level of Polychlorinated Biphenyls (ppm)
07/78	<1.0	6.0	<0.5
08/78	<1.0	<0.5	<0.5
08/79	<1.0	<0.2	<0.5
01/80	<1.0	<0.2	<0.5
08/80	<1.0	<0.2	<0.5

TABLE D2. ANALYSIS OF BEDDING SAMPLES AT ILLINOIS INSTITUTE OF TECHNOLOGY RESEARCH INSTITUTE

Collection Date	Fiber Concentration	
	Total (a)	Asbestos (a)
03/77	110/g	ND
03/79	90/g	ND
02/80	130/g	ND
08/80	40/g	ND

(a) ND = less than detection limit (~ 25,000 fibers per liter or 25 fibers per gram)

APPENDIX E

WATER ANALYSIS IN THE LIFETIME FEED STUDIES OF CROCIDOLITE ASBESTOS

APPENDIX E. WATER ANALYSIS

Samples of drinking water were submitted to the Water Supply Research Laboratory, U.S. Environmental Protection Agency, Cincinnati, Ohio, for baseline asbestos determinations. The samples were collected on November 8, 1976, and November 11, 1980.

The results of the first analysis determined the concentration of chrysotile asbestos and amphibole asbestos to be below detectable limits of 10,000 fibers per liter.

The second analysis detected one chrysotile asbestos fiber, equivalent to 50,000 fibers per liter, but a count based on a single fiber is not statistically significant. The chrysotile asbestos fiber was probably a contaminant from the study diet.

APPENDIX F

AIR ANALYSIS IN THE LIFETIME FEED STUDIES OF CROCIDOLITE ASBESTOS

	PAGE
TABLE F1 RESULTS OF ANALYSES OF AIR SAMPLES IN LIFETIME FEED STUDIES OF CROCIDOLITE ASBESTOS IN RATS	169

APPENDIX F. ANALYSIS OF AIR SAMPLES

Results of air sample analyses are presented in Table F1.

Initially, 6-hour samplings of air were taken for baseline asbestos determinations from clean and dirty corridors and one room. Samples were sent for analysis to the Illinois Institute of Technology Research Institute (IITRI). Additional 6-hour air samplings of rooms and corridors were taken when each asbestos diet was introduced into a room and thereafter approximately every 6 months.

Air samples were obtained with a portable pump Model G (part no. 456058) from Mining Safety Appliances Co. (Pittsburgh, Pennsylvania), which was connected by Tygon tubing to a Millipore Filter Field Monitor (pore size, 5 μ).

TABLE F1. RESULTS OF ANALYSES OF AIR SAMPLES IN LIFETIME FEED STUDIES OF CROCIDOLITE ASBESTOS IN RATS (a)

Date	Room No. 32 (next to return hall door)	Service Hall (outside room no. 30)	Room No. 35 (next to service hall door)	Return Hall Intersection of Nos. 45 and 44	Room No. 36 (next to return hall door)
Total Fiber Concentration (no./cc of air)					
6/78	0.0	0	0	0	0
1/79	0.17	0.04	0.04		0.30
2/80	0.095		0.048		
7/80	0.11	0.09	0.03		0
Asbestos Fiber Concentration (no./cc of air)					
6/78	0.06	0	0	0	0
1/79	0.13	0.04	0.00		0.17
2/80	0.095		0.00		
7/80	0.03	0.03	0.03		
>5 μm (no./cc of air)					
6/78	0	0		0	0
1/79	0	0	0		0
2/80	0		0		
7/80	0	0	0		0
>1 μm (no./cc of air)					
6/78	0	0		0	0
1/79	0.13	0	0		0.14
2/80	0		0		
7/80	0	0	0.03		0

Date	Service Hall Intersection of Nos. 29 and 55	Room No. 33 (next to return hall door)	Return Hall (No. 20) Outside of Women's Locker Room	Room No. 30 (next to return hall door)	Service Hall
Total Fiber Concentration (no./cc of air)					
6/78	0.12	(b)0	0	0	
1/79		0.11		0.04	0.04
2/80		0.00			
7/80		0.11		0.34	
Asbestos Fiber Concentration (no./cc of air)					
6/78	0.06	(b)0	0	0	
1/79		0.04		0.04	0.00
2/80		0.00			
7/80		0.03		0.23	
>5 μm (no./cc of air)					
6/78	0	(b)0	0	0	
1/79		0		0	0
2/80		0			
7/80		0		0	
>1 μm (no./cc of air)					
6/78	0	(b)0	0	0	
1/79		0		0	0
2/80		0			
7/80		0.03		0.11	

TABLE F1. RESULTS OF ANALYSES OF AIR SAMPLES IN LIFETIME FEED STUDIES OF CROCIDOLITE ASBESTOS IN RATS (Continued)

Date	Return Hall	Service Hall (halls 55 and 56)	Room 31	Room 34	Blank
Total Fiber Concentration (no./cc of air)					
6/78					
1/79	0.07		0.13	0.17	0.04
2/80	0.048	0.048	0.048	0.24	
7/80		0.26	0.03	0.20	0.03
Asbestos Fiber Concentration (no./cc of air)					
6/78					
1/79	0.04		0.04	0.04	0.00
2/80	0.048	0.048	0.00	0.14	
7/80		0.20	0.03	0.09	0
>5 μm (no./cc of air)					
6/78					
1/79	0		0	0	0
2/80	0	0	0	0	
7/80		0.06	0	0	0
>1 μm (no./cc of air)					
6/78					
1/79	0		0	0.04	0
2/80	0	0	0	0.05	
7/80		0.14	0	0.06	0

Date	Service Hall	Wash Area Room 48	Change Area	Room 56
Total Fiber Concentration (no./cc of air)				
6/78				
1/79				
2/80				
7/80	0	0.06	0.11	0.09
Asbestos Fiber Concentration (no./cc of air)				
6/78				
1/79	0			
2/80				
7/80		0	0.03	0.09
>5 μm (no./cc of air)				
6/78				
1/79	0			
2/80				
7/80		0	0	0
>1 μm (no./cc of air)				
6/78				
1/79	0			
2/80				
7/80		0	0.03	0.09

(a) Samples analyzed by IITRI; the computations are based on a 1 liter/min sample rate and a 6-h sample period = 360 min.
 (b) Sample holder was damaged.

APPENDIX G

SUMMARY OF CLINICAL SIGNS OBSERVED PRIOR TO MORIBUND KILL IN THE LIFETIME FEED STUDIES OF CROCIDOLITE ASBESTOS

		PAGE
TABLE G1	SUMMARY OF CLINICAL SIGNS OBSERVED IN RATS BEFORE MORIBUND KILL IN THE LIFETIME FEED STUDIES OF CROCIDOLITE ASBESTOS: CONTROL	172
TABLE G2	SUMMARY OF CLINICAL SIGNS OBSERVED IN RATS BEFORE MORIBUND KILL IN THE LIFETIME FEED STUDIES OF CROCIDOLITE ASBESTOS: 1%	173

TABLE G2. SUMMARY OF CLINICAL SIGNS OBSERVED IN RATS BEFORE MORIBUND KILL IN THE LIFETIME FEED STUDIES OF CROCIDOLITE ASBESTOS: 1% (a)

	<u>Weeks 83-87</u>		<u>Weeks 88-92</u>		<u>Weeks 93-97</u>		<u>Weeks 98-102</u>	
	Male	Female	Male	Female	Male	Female	Male	Female
Number of animals killed in moribund condition	2	2	4	3	5	1	6	8
Pale	1	2			2		3	6
Thin	1	2	1		2		2	1
Bloody crust around nose and/or eyes	1							
Pale eyes	1		1	1	1			1
Malocclusion								1
Hunched		1						
Depressed	1	2	1	1	1		3	3
Labored respiration				1				
Wheezing			1					
Abdomen firm and/or distended				1				
Palpable mass in abdomen		2		1				3
Tissue mass--hindleg, neck, chest, back, eye, head, axilla, hip, inguinal, midline, or perineal	1	1	4	1	1	1	2	2
Loss of pain perception		1						
Unable to stand							1	
Lack of coordination					1			
Loss of equilibrium or righting reflex							2	1
Rough haircoat			2					
Flaccid muscle tone	1							
Yellow extremities		1		1				
Cold to touch		2			1			
Prostrate in cage					1			
Paralysis in hindlegs					1			1
Red discharge from penis					1			
Urine stains								1

	<u>Weeks 103-107</u>		<u>Weeks 108-112</u>	
	Male	Female	Male	Female
Number of animals killed in moribund condition	13	12	12	15
Pale	4	10	6	6
Thin	7	5	3	8
Cloudy eyes				2
Pale eyes	2	1	2	4
Salivating	1			
Hunched				1
Depressed	7	4	4	2
Labored respiration	1			1
Rapid respiration	1			
Wheezing	1			
Cyanotic	1			
Abdomen firm and/or distended			1	
Palpable mass in abdomen	8	8	8	5
Tissue mass--hindleg, neck, chest, back, eye, head, axilla, hip, inguinal, midline, or perineal	5	5	3	6
Nodule	1		1	
Side of head swollen				1
Unkempt	2		2	
Loss of equilibrium or righting reflex				1
Prostrate in cage	1		1	1
Paralysis in hindlegs		1		1
Urine discoloration (red, bright yellow)	2			

(a) The intervals were arbitrarily selected based on weeks when a large percentage of moribund kills occurred. Clinical signs observed after the last interval selected were believed not to be readily discernible from signs of aging.

APPENDIX H

FEED AND COMPOUND CONSUMPTION BY RATS IN THE LIFETIME FEED STUDIES OF CROCIDOLITE ASBESTOS

		PAGE
TABLE H1	FEED AND COMPOUND CONSUMPTION BY MALE RATS FOR REPRESENTATIVE WEEKS IN THE LIFETIME FEED STUDY OF CROCIDOLITE ASBESTOS	176
TABLE H2	FEED AND COMPOUND CONSUMPTION BY FEMALE RATS FOR REPRESENTATIVE WEEKS IN THE LIFETIME FEED STUDY OF CROCIDOLITE ASBESTOS	176

TABLE H1. FEED AND COMPOUND CONSUMPTION BY MALE RATS FOR REPRESENTATIVE WEEKS IN THE LIFETIME FEED STUDY OF CROCIDOLITE ASBESTOS

Week	Control		1% Crocidolite Asbestos			
	Grams Feed/ Day (a)	Body Weight (grams)	Grams Feed/ Day (a)	Body Weight (grams)	1%/Control (b)	Dose/Day (c)
17	17	312	17	244	1.0	697
27	17	359	16	317	0.9	505
37	18	408	17	351	0.9	484
47	18	411	17	366	0.9	464
57	17	443	17	392	1.0	434
67	18	466	17	413	0.9	412
77	16	471	16	427	1.0	375
87	17	417	16	429	0.9	373
97	16	464	15	424	0.9	354
107	17	460	15	419	0.9	358
117	15	424	15	399	1.0	376
127	18	401	16	373	0.9	429
137	15	361	18	332	1.2	542
Mean	16.8	415	16.3	376	1.0	446
SD(d)	1.1		0.9		0.1	96
CV(e)	6.5		5.5		10.0	21.5

- (a) Grams of feed removed from the feeder per animal per day; not corrected for scatter.
 (b) Grams of feed per day for the dosed group divided by that for the controls
 (c) Estimated milligrams of crocidolite asbestos consumed per day per kilogram of body weight
 (d) Standard deviation
 (e) Coefficient of variation = (standard deviation/mean) × 100

TABLE H2. FEED AND COMPOUND CONSUMPTION BY FEMALE RATS FOR REPRESENTATIVE WEEKS IN THE LIFETIME FEED STUDY OF CROCIDOLITE ASBESTOS

Week	Control		1% Crocidolite Asbestos			
	Grams Feed/ Day (a)	Body Weight (grams)	Grams Feed/ Day (a)	Body Weight (grams)	1%/Control (b)	Dose/Day (c)
17	12	188	12	163	1.0	736
27	12	203	11	186	0.9	591
37	13	224	12	200	0.9	600
47	13	228	13	220	1.0	591
57	13	251	12	235	0.9	511
67	14	282	13	259	0.9	502
77	13	303	12	280	0.9	429
87	15	317	13	292	0.9	445
97	14	328	12	294	0.9	408
107	15	334	13	302	0.9	430
117	14	324	13	295	0.9	441
127	15	314	14	275	0.9	509
137	13	295	13	253	1.0	514
Mean	13.5	276	12.5	250	0.9	516
SD(d)	1.1		0.8		0.0	93
CV(e)	8.1		6.4		0.0	18.0

- (a) Grams of feed removed from the feeder per animal per day; not corrected for scatter.
 (b) Grams of feed per day for the dosed group divided by that for the controls
 (c) Estimated milligrams of crocidolite asbestos consumed per day per kilogram of body weight
 (d) Standard deviation
 (e) Coefficient of variation = (standard deviation/mean) × 100

APPENDIX I

AUDIT SUMMARY

APPENDIX I. AUDIT SUMMARY

The experimental data, documents, pathology materials, and draft Technical Report for the lifetime toxicology and carcinogenesis studies of crocidolite asbestos in F344/N rats were audited for accuracy, consistency, and completeness. The laboratory experiments were conducted for the NTP at Hazleton Laboratories (Vienna, Virginia) under a subcontract with Tracor Jitco, Inc., from the National Cancer Institute. The exposure portion of the studies was begun in January 1978 and ended in December 1980, before the time (October 1981) the NTP implemented the requirement that studies be conducted in compliance with the Good Laboratory Practice (GLP) regulations of the Food and Drug Administration. The retrospective audit was conducted for the NIEHS at the NTP Archives from June to July 1985 by Dynamac Corporation (F. Cavender, Ph.D., Principal Investigator). A separate audit for the chemistry data for all NTP asbestos studies was conducted by Argus Research Laboratories (P. Wennerberg, D.V.M., Principal Investigator) in October 1986. The other individuals who conducted the audit are listed in the full audit report, which is on file at the NIEHS. The audit included a review of:

- (1) All records concerning animal receipt, quarantine, randomization, and disposition prior to study start.
- (2) Chemistry records for fiber characterization and chemical/vehicle analyses.
- (3) Body weight and clinical observation data for a random 10% sample of the study animals.
- (4) Feed consumption for approximately 10% of the animals.
- (5) Inlife records concerning environmental conditions, palpable masses, and mortality.
- (6) All postmortem records for individual animals concerning identification, disposition and condition codes, and correlation between gross observations and microscopic diagnoses.
- (7) Wet tissues from a random 10% sample of the study animals to verify animal identification and to examine for untrimmed potential lesions.
- (8) Blocks and slides of tissues from 50% of the control and exposed groups to examine for inventory and correspondence.
- (9) Tabulated pathology diagnoses for a random 10% of study animals to verify computer data entry.

The audit indicated that records were not available for environmental conditions for the control animals or gestation and litter data following breeding of the F₀ to produce the F₁ generation. A Daily Animal Observation Record was not available for control animals, and therefore the primary mortality records for these animals were the Individual Animal Data Records. Other inlife records were generally complete and consistent.

The records documenting the identification and characterization of the various mineral fibers were complete and adequate. Recalculated values for formulated diets containing crocidolite asbestos were in agreement with the values recorded.

Wet tissues were present for all animals except three exposed male rats. Of the 74 rats examined at random for ear tag identification, 2 control males, 2 exposed males, and 1 exposed female had no ear tags in the tissue bags; all others were properly identified. Audit examination for gross to microscopic noncorrelation indicated four nonneoplastic lesions for the gastrointestinal tract (one exposed male, three exposed females) and eight potentially neoplastic lesions in "nontarget" organs (two control males, two exposed males, two control females, two exposed females). The NTP pathology review of these findings indicated that they would in no way change or affect the conclusions drawn in the study.

The retrospective audit indicated that the records and specimens for the lifetime studies of crocidolite asbestos support the data and results presented in the NTP Technical Report.