

IMACS Core Set Measures – Case examples

Myositis Disease Activity Assessment Tool (MDAAT) Physician Global Disease Activity

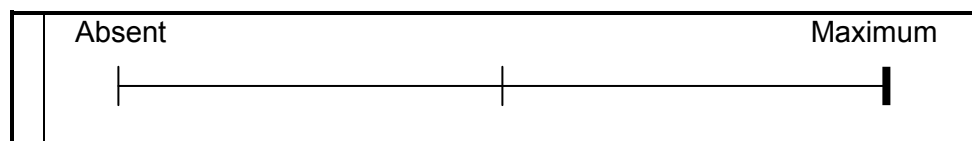
The purpose of this exercise is to provide some guidelines in scoring the MDAAT. These cases were prepared by Lisa Rider, Fred Miller and David Isenberg. The scores provided in the 3 cases are suggestions for your consideration and there may be some differences of opinion. These cases particularly focus on scoring of the muscle systems and global activity VAS scores, although the discussion presents the scoring of other involved organ systems as well.

Case 1: JDM at Presentation

A 12-year old African-American girl presented with a two-month history of progressive severe, diffuse muscle pains, increasing weakness, worsening rashes over her knuckles, elbows and knees and severe fatigue. She had been previously well with no past relevant medical history. She also has not been eating well due to difficulty swallowing with occasional nasal regurgitation, has lost 10 pounds (going from 85 to 75 lbs), and in the last 2 days cannot get out of bed or into or out of cars without assistance from 2 persons. Over the past four weeks she developed full thickness skin ulcerations on her Gottron's lesions over her buttocks and elbows; the lesions have progressed through the dermis, subcutaneous fat and muscle to the underlying bone. In the last one to two days she has also noticed shortness of breath and dyspnea on exertion, which is worsening. Review of systems was otherwise negative.

Physical exam was remarkable for an ill-appearing girl in mild respiratory distress, BP 95/70, pulse 140 and regular, respiratory rate 28, Temp 38.5 deg C. She had Gottron's papules overlying the knuckles, severe deep skin ulcerations to bone over the buttocks and elbows, and periungual capillary loop changes. She is clearly not able to ambulate or arise from the bed and proximal muscle strength was decreased symmetrically with manual muscle testing (MMT) grades 2-5/10 weakness with neck and hip flexors and abductors being 3/10 (Unilateral Manual Muscle Testing [MMT] score = 30 out of 80, with 80 representing normal strength. CHAQ score was 3.0, with 3.0 representing maximum disability. CMAS could not be performed. CK levels were 4760 (normal 20 to 215 U/l) and PFTs demonstrated moderately restrictive lung disease with a DLCO 60% of predicted. EKG showed sinus tachycardia. Chest radiograph showed right lower lobe infiltrates as well as diffuse interstitial markings. Barium swallow showed abnormal peristalsis and aspiration. Skin biopsies of the ulcerations showed no evidence of infection and extensive multiple urine, blood and sputum cultures were negative. Muscle biopsy showed significant perivascular lymphocytic infiltration, degeneration and regeneration, perifascicular atrophy and vascular changes but no fatty replacement. The remainder of physical exam and laboratory testing were unremarkable. She was pulsed with high dose IV corticosteroids and IVIG but rapidly deteriorated, requiring intubation, mechanical ventilation, and hyperalimentation in the intensive care unit.

Proposed Muscle Disease Activity Assessments: VAS = 10 cm (maximum score)



Example of Max score: severe muscle weakness resulting in being bed bound and an inability to perform self care

25. Myositis:

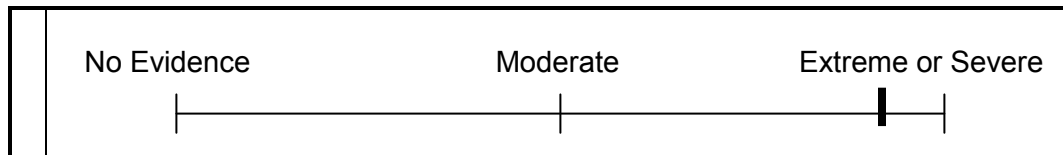
a) Severe muscle inflammation	0	1	2	3	4	NA
b) Moderate muscle inflammation	0	1	2	3	4	NA
c) Mild muscle inflammation	0	1	2	3	4	NA

26. Myalgia

0	1	2	3	4	NA
---	---	---	---	---	----

Proposed Global Disease Activity Assessment: VAS = 9 cm

Overall evaluation for the totality of disease activity in **ALL** systems (**including** muscle)



Discussion of Case 1:

This child has new onset dermatomyositis (0-4 numerical scores = 4 [new onset] for all involved systems) and is non-ambulatory, without anti-gravity strength in a number of muscles, with maximum functional impairment, very high CK levels and an active biopsy. These findings are indicative of maximum muscle disease activity of new onset (**Muscle VAS score = 10 cm; MDAAT numeric score = 4**). She has new onset fevers, weight loss and severe fatigue (**Constitutional VAS score = 8 cm; MITAX numeric score = 4**). Her most severe cutaneous manifestations are full-thickness ulcerations, which represent maximal cutaneous disease activity (**Cutaneous VAS= 10 cm**). She also has new onset Gottron’s papules and periungual changes (MDAAT numeric score = 4), but since these are less severe than the ulcerations they are not included in determining the MDAAT score for the Cutaneous system. Her new onset severe dysphagia requiring parenteral hyperalimentation in an ICU setting indicates near maximal GI disease activity (**GI VAS = 8 cm; MDAAT numeric score = 4**). She has pulmonary involvement with both aspiration pneumonitis and interstitial lung disease, which rapidly progresses requiring mechanical ventilation (**Pulmonary VAS = 10 cm; MDAAT numeric score = 4**). Her cardiac score for sinus tachycardia is **Cardiac VAS = 1 cm; MDAAT numeric score = 4**. Overall, her **Global VAS score** is placed at 9cm.

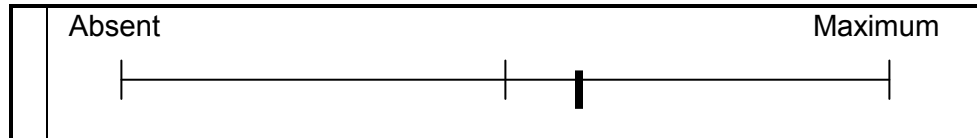
NOTE: There is no evidence of irreversible damage but because the disease has not been present for at least 6 months, damage cannot be formally assessed.

Case 2 - DM at presentation

A 36 year-old white man presented with a one-week history of an acute onset of progressively worse fevers, joint pains, moderate weakness and myalgias, shortness of breath, fatigue, dysphagia, anorexia and mild intermittent abdominal pain. He had been well prior to this event and had never been hospitalized or diagnosed with any chronic problems. He was an insurance salesman who had just returned from a stressful overseas business trip during which he only had minor sun exposure and no illnesses.

On exam the patient appeared acutely ill with BP 135/88, Pulse 132 and regular, Respiratory rate 26, Temp. 38 deg C. His exam was remarkable for moderately active heliotrope, Gottron’s papules, mechanic’s hands, diffuse maculopapular rashes over his face and chest, edematous ankles and wrists with symmetric MCP and PIP swelling and tenderness with moderate loss of function. MMT revealed grade 6-8/10 weakness of upper and lower extremities bilaterally, proximal > distal (MMT8 score = 58 out of 80) and harsh inspiratory crackles at both lung bases. HAQ score was 2.0 out of 3.0, partially due to limitations induced by his arthritis. His white count was 14,600 with lymphocytosis, platelets were elevated at 240,000, CK was 3100 (normal 20 to 215), and aldolase was 20 (normal 1 to 9), but all cultures were negative and all other labs were within normal limits. Chest x-ray showed fine diffuse interstitial infiltrates, most intense at the bases, and pulmonary function testing demonstrated moderately restrictive lung disease with a DLCO 65% of predicted. An EKG showed sinus tachycardia and a normal rhythm strip and abdominal X-rays and stool evaluations were normal. EMG and muscle biopsy were consistent with active myositis.

Proposed Muscle Disease Activity Assessments: VAS = 6 cm



Example of Max score: severe muscle weakness resulting in being bed bound and an inability to perform self care

25. Myositis:

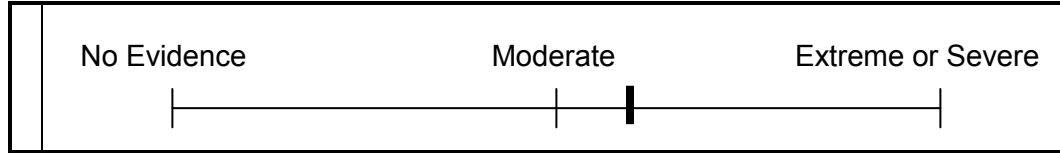
- a) Severe muscle inflammation 0 1 2 3 4 NA
- b) Moderate muscle inflammation 0 1 2 3 4 NA
- c) Mild muscle inflammation 0 1 2 3 4 NA

26. Myalgia

- 0 1 2 3 4 NA

Proposed Global Disease Activity Assessment: VAS = 6 cm

Overall evaluation for the totality of disease activity in **ALL** systems (**including** muscle)



Discussion of Case 2:

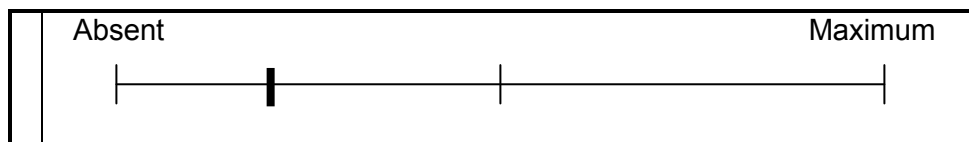
The patient has new onset (numerical score = 4 for all involved systems), moderate myositis with moderate constitutional, skin, joint and pulmonary involvement, all consistent with the anti-synthetase syndrome. His global score is moderate, in part because of these systemic manifestations. His **Muscle** system yields a 6 cm VAS score. For his constitutional system he has new onset (numerical score = 4), moderate fatigue and fever, which translates to a **Constitutional** VAS = 5 cm. For his cutaneous system, he has new onset moderate erythematous rashes, mechanic's hands, Gottron's and heliotrope, all of which translate to a **Cutaneous** VAS = 5 cm. For his skeletal system he has new onset arthritis with moderate evidence of inflammation and some loss of function which translates to a **Skeletal** VAS = 5 cm. His pulmonary manifestations are ILD with a DLCO of 65% which translates to a **Pulmonary** VAS = 6 cm. For his cardiac system he has sinus tachycardia only which is **Cardiac** VAS = 1 cm. Overall, he requires high-dose corticosteroids and other immunomodulatory therapy. His overall **Global Activity** VAS is placed at 6 cm. There is no evidence of irreversible damage, but because the disease has not been present for 6 months, damage cannot be formally assessed.

Case 3 – JDM at presentation

A 10-year-old white girl developed a rash over her knuckles two months ago. In the past month, after a beach vacation, the rash progressed to involve areas over her face, chest, back, arms and knees symmetrically. She was not able to run as fast as the other children in her class or do cartwheels as she did 3 months earlier and was fatigued and mildly hoarse. Her parents and she assessed that her energy level was decreased to about 75% of normal. She denied muscle pain. Review of systems was otherwise negative.

Today she appears well and vital signs are normal. Physical exam was remarkable for moderate malar rash and erythematous rashes over the chest and arms, heliotrope, Gottron’s papules overlying the knuckles and knees, and periungual capillary loop changes. She has moderate swelling of wrists and knees with some limitation of motion. Proximal muscle strength was decreased and symmetric with grades 9/10 deltoid, 8/10 neck and hip flexors and grade 8/10 abdominals (Unilateral MMT8 score = 74 out of 80). Mild contractures of leg adductors were present. CK levels are 250 [normal 20 to 215 U/l] and aldolase is 10 (normal 1 to 9 U/l). CHAQ = 1.0 out of 3.0. Muscle biopsy showed scant, scattered perivascular lymphocytic infiltration with perifascicular atrophy and 1 to 2 fibers with necrosis but no fatty replacement, consistent with dermatomyositis. The remainder of physical exam and laboratory testing were unremarkable.

Proposed Muscle Disease Activity Assessments: VAS = 2 cm



Example of Max score: severe muscle weakness resulting in being bed bound and an inability to perform self care

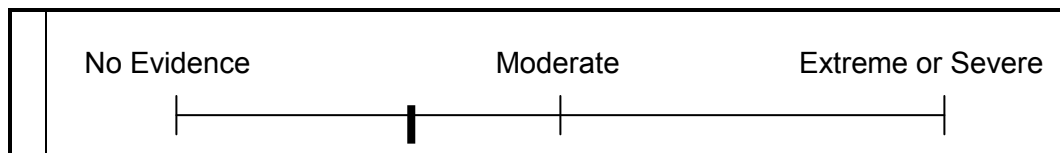
25. Myositis:

- a) Severe muscle inflammation 0 1 2 3 4 NA
- b) Moderate muscle inflammation 0 1 2 3 4 NA
- c) Mild muscle inflammation 0 1 2 3 4 NA

26. Myalgia 0 1 2 3 4 NA

Proposed Global Disease Activity Assessment: VAS = 3 cm

Overall evaluation for the totality of disease activity in **ALL** systems (**including** muscle)



Discussion of Case 3:

The patient has new onset (numerical score = 4 for all involved systems) mild to moderate myositis with mild-moderately active systemic features. She has: mild muscle weakness and inflammation on biopsy with slight elevation in CK but some loss of function, which translates to a **Muscle VAS** = 2.5 cm. She has fatigue (**Constitutional VAS** = 2 cm); erythematous rashes without secondary changes, heliotrope, Gottron's and periungual capillary changes (**Cutaneous VAS** = 4 cm); arthritis with moderately active inflammation and some loss of function (**Skeletal VAS** = 3 cm); mild dysphonia (**Pulmonary VAS** = 2 cm); but no other organs were involved. Her **Global VAS activity** score = 3.0 cm.

NOTE: There is no evidence of irreversible damage, but because the disease has not been present for 6 months, damage cannot be formally assessed.