



UNIVERSITY OF NEW MEXICO HEALTH SCIENCES CENTER

## Silica Exposure and Systemic Vasculitis

Karen B. Mulloy

Program in Occupational and Environmental Health, Department of Internal Medicine, University of New Mexico Health Sciences Center, University of New Mexico, Albuquerque, New Mexico, USA

Work in Department of Energy (DOE) facilities has exposed workers to multiple toxic agents leading to acute and chronic diseases. Many exposures were common to numerous work sites. Exposure to crystalline silica was primarily restricted to a few facilities. I present the case of a 63-year-old male who worked in DOE facilities for 30 years as a weapons testing technician. In addition to silica, other workplace exposures included beryllium, various solvents and heavy metals, depleted uranium, and ionizing radiation. In 1989 a painful macular skin lesion was biopsied and diagnosed as leukocytoclastic vasculitis. By 1992 he developed gross hematuria and dyspnea. Blood laboratory results revealed a serum creatinine concentration of 2.1 mg/dL, erythrocyte sedimentation rate of 61 mm/hr, negative cANCA (antineutrophil cytoplasmic antibody cytoplasmic pattern), positive pANCA (ANCA perinuclear pattern), and antiglomerular basement membrane negative. Renal biopsy showed proliferative (crescentic) and necrotizing glomerulonephritis. The patient's diagnoses included microscopic polyangiitis, systemic necrotizing vasculitis, leukocytoclastic vasculitis, and glomerulonephritis. Environmental triggers are thought to play a role in the development of an idiopathic expression of systemic autoimmune disease. Crystalline silica exposure has been linked to rheumatoid arthritis, scleroderma, systemic lupus erythematosus, rapidly progressive glomerulonephritis and some of the small vessel vasculitides. DOE workers are currently able to apply for compensation under the federal Energy Employees Occupational Illness Compensation Program (EEOICP). However, the only diseases covered by EEOICP are cancers related to radiation exposure, chronic beryllium disease, and chronic silicosis. **Key words:** crystalline silica, Department of Energy workers, Energy Employees Occupational Illness Compensation Program, Nevada test site, systemic vasculitis. *Environ Health Perspect* 111:1933–1938 (2003). doi:10.1289/ehp.6400 available via <http://dx.doi.org/> [Online 6 October 2003]

### Case Presentation

During a medical screening program for former Department of Energy (DOE) workers by the Johns Hopkins University Former Los Alamos National Laboratory (LANL) Workers Program (Española, NM) a 63-year-old white male expressed concern that his diagnoses of microscopic polyangiitis, systemic necrotizing vasculitis, leukocytoclastic vasculitis, pulmonary interstitial fibrosis, and glomerulonephritis were related to silica exposure. He had applied for compensation under the federal Energy Employees Occupational Illness Compensation Program (EEOICP). He was referred to the University of New Mexico's Program in Occupational and Environmental Health.

Before 1988 the patient's medical history included *a*) irritable bowel syndrome and hypoglycemia; *b*) seasonal allergies with chronic polyposis and deviated nasal septum with moderate to severe obstruction; *c*) eustachian tube rupture with corrective septoplasty and bilateral

turbinoplasties; *d*) pneumonia and pleural effusions; and *e*) hypertension.

In 1988 the patient developed migratory joint pain that progressed in severity, and by 1989 he had difficulty walking. Short course prednisone treatment provided relief. In 1989, a painful macular erythematous lesion developed on the patient's chest; a skin biopsy diagnosed leukocytoclastic vasculitis. In spring 1992, he was referred to the Mayo Clinic (Scottsdale, AZ) for pulmonary and renal workup for gross hematuria and dyspnea. Results of laboratory tests are presented in Table 1. Renal biopsy showed proliferative (crescentic) and necrotizing glomerulonephritis; treatment with prednisone and cyclophosphamide placed patient in prompt remission (Table 1). In late 1992 the patient developed acute shortness of breath, and spirometry, lung scan, and bronchoscopy with biopsy diagnosed pulmonary embolism in the right infrahilar region; this was treated with anticoagulants. In 1999 he had a subdural

hematoma, which was treated by craniotomy and evacuation. Laboratory tests, renal biopsies, and clinical evaluations by rheumatologists at the Mayo Clinic, the University of New Mexico, and in San Francisco, California, confirmed the diagnoses of microscopic polyangiitis, systemic necrotizing vasculitis, leukocytoclastic vasculitis, and glomerulonephritis with positive antineutrophil cytoplasmic antibodies (ANCA) perinuclear pattern (pANCA) and negative cytoplasmic pattern (cANCA).

In 1999, the patient's joint pain became severe again, and he was placed on prednisone and methotrexate until remission. His kidney function remained stable until 2002 (Table 1) when he was again placed on prednisone and cyclophosphamide.

Spirometry of the patient in 1992 showed a reduction in lung function (mixed obstructive/restrictive pattern with moderate obstruction; Table 1). A high resolution computerized tomography (CT) scan of the chest in 2001 showed fine linear markings at the bases extending to the pleural surface, with thickened interlobular septa.

In 2000, the Former LANL Worker Program screened the patient for health effects related to beryllium, lead, radiation, and noise exposure. Test results indicated no lung disease related to beryllium exposure and negative beryllium sensitivity, renal insufficiency (chronic renal failure) not related to lead exposure but as a result of vasculitis, and sensorineural hearing loss related to noise exposure.

The patient had no family history of vasculitides or rheumatologic disorders. He had smoked cigarettes (36 pack-year history) but quit smoking in 1979.

Address correspondence to K.B. Mulloy, Program in Occupational and Environmental Health, Department of Internal Medicine, MSC10 5550, 1 University of New Mexico, Albuquerque, NM 87131-0001 USA. Telephone: (505) 272-4027. Fax: (505) 272-5958. E-mail: [kmulloy@salud.unm.edu](mailto:kmulloy@salud.unm.edu)

The author declares she has no competing financial interests.

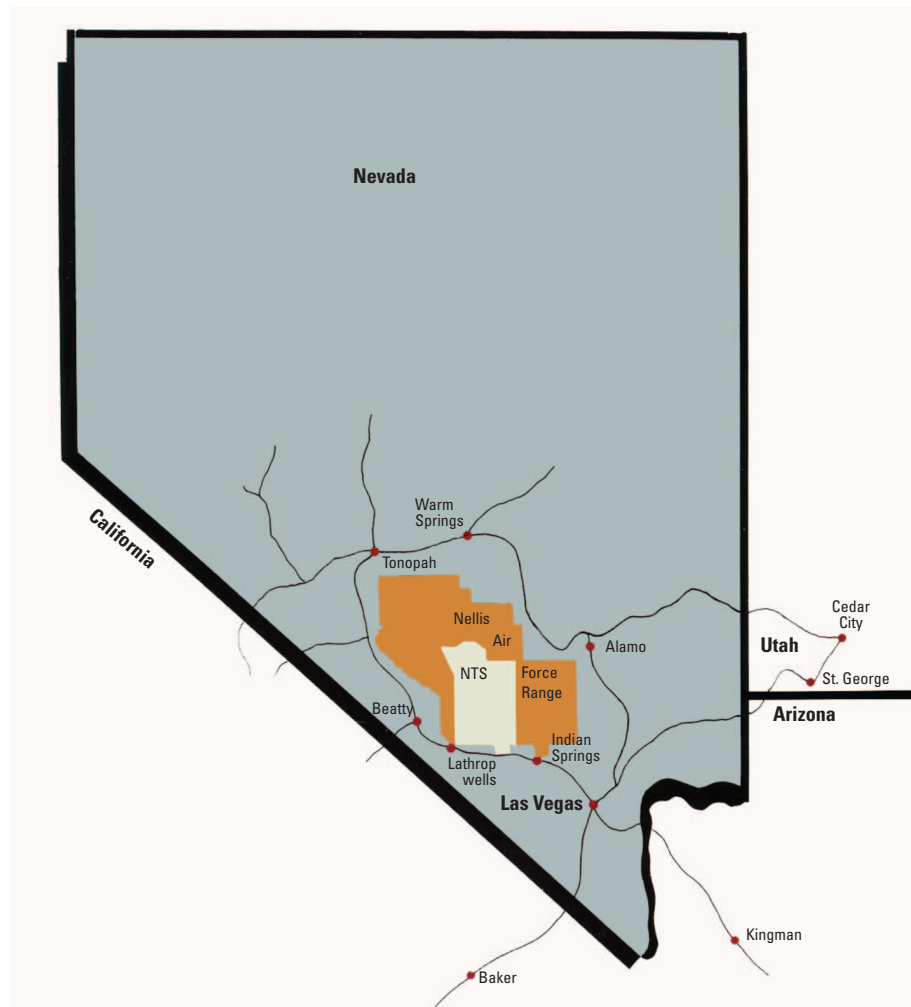
Received 21 April 2003; accepted 6 October 2003.

**Table 1.** Laboratory and spirometry test results.

	June 1992	August 1992 <sup>a</sup>	2000 <sup>b</sup>	2002 <sup>c</sup>
Hemoglobin (g/dL)	11.0	13.1	15.8	14.8
Ethrythrocyte sedimentation rate (mm/hr)	61	10		
Blood urea nitrogen (mg/dL)			25	46
Creatinine (mg/dL)	2.1	1.7	1.8	4.2
cANCA	Negative		Negative	
pANCA	Positive	Negative	Positive	
Anti-myeloperoxidase			Positive	
Anti-proteinase 3			Negative	
Rheumatoid factor; ANA; cryoglobulins; cryofibrinogen; hepatitis A, B, and C; angioconverting enzyme; immunoelectrophoresis; antiglomerular basement membrane antibodies	Negative			
Urine protein (mg/24hr)	1,226			6,443
Urinalysis	Protein 100 mg/dL 11–20 RBCs/hpf	Protein 100 mg/dL No RBCs		
<b>Spirometry</b>				
FVC (L) (% predicted)		3.71		3.11
FEV <sub>1</sub> (L) (%predicted)		2.40		1.95
FEV <sub>1</sub> /FVC (%)		64.7		63

Abbreviations: ANA, antinuclear antibodies; FEV<sub>1</sub>, forced expiratory volume in 1 sec; FVC, forced vital capacity; hpf, high-power field (microscopy); RBCs, red blood cells; RF, rheumatoid factor.

<sup>a</sup>Treated with prednisone 60 mg and cyclophosphamide 100 mg, both every day; weaned off slowly after remission. <sup>b</sup>Treated with prednisone 10 mg every day and methotrexate 7.5 mg weekly; weaned off slowly after remission. <sup>c</sup>Treated with prednisone 10 mg and cyclophosphamide 150 mg, both every day.

**Figure 1.** Nevada Test Site tunnel. Map reproduced from DOE Nevada (2003).

From 1953 to 1959, the patient worked as a sonar operator and electronics technician in the Navy on a destroyer and a submarine. He worked in areas with asbestos-covered pipes but no friable asbestos. From 1959 to 1961, he worked as a junior engineer at NASA, where his work involved testing reentry vehicles in a wind tunnel. The tunnel walls were finished, so he had no dust exposure.

In his job as a weapons testing technician and apparatus operator at the University of California, Lawrence Livermore National Laboratory (LLNL; Livermore, CA) from 1961 to 1966, the patient gathered data and cleaned areas after weapons explosions. He was in an underground bunker about 100 ft from testing sites during explosions. Testing was done every other day for 5 years. The patient was provided protective clothing, gloves, and a respirator. He was unable to wear the respirator consistently because he took the respirator off to talk; therefore, the patient received a significant amount of respirable dust exposure contaminated with beryllium and depleted uranium.

From 1966 to 1971, the patient worked as an assistant analyst for a Los Alamos National Laboratory (LANL) contractor; he worked in an office doing mostly computer work and received no significant exposures. He worked as a technician for LANL from 1971 until he retired in 1991. His work involved field data collections after explosions. Exposures at the test sites included dust, noise, depleted uranium, and ionizing radiation. The patient did not work directly with lead or beryllium, but he may have been exposed to small amounts of these elements during detonation of test shots. He worked in buildings with asbestos-covered pipes but reported no direct work with asbestos or exposure to asbestos dust. He was not enrolled in a lead or asbestos monitoring program. Exposure to solvents (i.e., acetone, carbon tetrachloride, methylethyl ketone), epoxies, and nitric acid fumes were intermittent and brief during those years, and he reported no acute symptoms while working with chemicals.

From 1983 to 1984 the patient was assigned by LANL to work in oil shale mines in Colorado. The mining operation was an *in situ* perfusion operation to extract oil. His underground job was to test and measure explosions, instrumentation, and the structure of the mines. During this period he drilled holes, installed gauges, set charges, and gathered information about the tests. He worked in dusty conditions; he was given a dust mask but wore it only periodically.

From 1987 to 1991 the patient was assigned by LANL to work at the Nevada Test Site (NTS) underground (Figure 1). He worked in Area 25, an abandoned silver mine (drift tunnel) under construction, where there

was constant drilling and high levels of dust for  $\geq 8$  hr/day for 4 months. Respiratory protection consisted of a dust mask, which he often had to take off to talk. Until retirement, the patient worked underground in Area 3, a shaft tunnel, 0.25 mile below the surface; in this job—setting up instruments to measure data during explosions—he received moderate dust exposure.

## Discussion

The vasculitides are a group of diseases characterized by inflammatory cell infiltration and necrosis of blood vessel walls (Watts and Scott 1997). The classification (Langford 2003; Mansi et al. 2002) and description of the vasculitides are presented in Table 2. The epidemiologic study of systemic vasculitides has been difficult because they are all rare conditions. The annual incidence of systemic vasculitides in the United Kingdom has been estimated to be 36.6/million (with the exclusion of giant cell arteritis and cutaneous vasculitis) (Watts and Scott 1997). Specific vasculitides are more rare than the systemic vasculitides. In a study conducted in the United Kingdom from 1988 to 1994, the incidence of microscopic polyangiitis was 3.6/million (Watts and Scott 1997). There is some indication that there are geographical and ethnic differences in the occurrence of vasculitides. Wegener's granulomatosis and giant cell arteritis are extremely rare in India and Japan, but Takayasu arteritis is common. The opposite seems to be true in northern Europe. Wegener's granulomatosis is common and polyarteritis nodosa is rare in northern Europe, but in southern Europe Wegener's granulomatosis is rare and polyarteritis nodosa is common.

Vasculitides can be caused by an infection of the blood vessel wall (bacterial or viral) or an immune response. Of interest are the vasculitides associated with autoimmune diseases such as lupus, rheumatoid arthritis, scleroderma, and Wegener's granulomatosis. There are studies that explain the influence of multiple complex genetic factors on the development of autoimmunity and specific autoimmune diseases (Theofilopoulos and Kono 1998). Environmental triggers are thought to play a role in the development of an idiopathic expression of systemic autoimmune diseases (Mayes 1999; Powell et al. 1999). Exogenous sex hormones (specifically estrogen), pharmaceutical agents (i.e. penicillamine, procainamide, bleomycin) silica, organic solvents (i.e., vinyl chloride, trichloroethylene, epoxy resins), herbicides, pesticides, mercury, mercuric chloride, iodine, aromatic amines, and hydrazine have been linked to the development of systemic autoimmune diseases (D'Cruz 2000; Gonzalez-Gay and Garcia-Porrúa 2001; Mayes 1999; Powell

et al. 1999; Smith and Germolec 1999). Specifically, estrogen has been linked with the risk of developing systemic lupus, scleroderma, and Raynaud disease (Mayes 1999); solvents linked with systemic sclerosis and scleroderma (Mayes 1999); mercuric chloride linked with immune complex glomerulonephritis (Mayes 1999; Powell et al. 1999); and crystalline silica linked with rheumatoid arthritis, systemic sclerosis, systemic lupus, glomerulonephritis, and small-vessel vasculitides (Koeger et al. 1995; Mayes 1999; Parks et al. 1999; Powell et al. 1999; Steenland and Goldsmith 1995).

Small vessel vasculitides have a common pathology of focal necrotizing lesions in the lungs causing alveolar hemorrhage, in the glomeruli of the kidney causing renal failure, and in the dermis causing a purpuric rash or ulcerations on the skin (Kamesh et al. 2002). The most common primary small-vessel vasculitis that occurs in adults is associated with ANCA (Mansi et al. 2002). ANCA are specific antibodies for antigens in cytoplasmic granules of neutrophils and monocyte lysosomes, have their direct effects against proteinase 3 or myeloperoxidase, and can be detected with

direct immunofluorescence microscopically (Booth et al. 2003; Mansi et al. 2002). ANCA directed against proteinase 3 has a cytoplasmic immunofluorescence pattern and is noted as cANCA. ANCA directed against myeloperoxidase has a perinuclear immunofluorescence pattern and is termed pANCA (Langford 2003). cANCA is positive in 75–90% of Wegener granulomatosis cases, and pANCA positivity is most commonly seen in microscopic polyangiitis (Mansi et al. 2002). Fever, myalgia, anorexia, weight loss, malaise, and night sweats are common early symptoms of vasculitis. Microscopic polyangiitis usually has renal involvement, and patients present with hematuria, proteinuria, and red cell casts and can have rapid renal failure. Pulmonary hemorrhage can occur in microscopic polyangiitis, but unlike Wegener granulomatosis, upper airway involvement is rare. Untreated ANCA-positive vasculitis has a very poor prognosis with up to 90% mortality in 2 years (Kamesh et al. 2002). Current standard treatment is based on cyclophosphamide and high-dose corticosteroids (Mansi et al. 2002). The goal of therapy is to induce remission, maintain remission, and treat relapses. Treatment-related

**Table 2.** Classification of systemic vasculitis.

Class	Name	Pathophysiology	Characteristics
Large-vessel vasculitis	Giant cell arteritis	Granulomatous inflammation affects aorta and major branches, carotid, cranial, and temporal arteries	Most common over 50 years of age; frequency increases with aging; associated with polymyalgia rheumatica
	Takayasu arteritis	Granulomatous inflammation of aorta and major branches, pulmonary and coronary arteries	Occurs in patients under 50 years of age; associated with connective tissue, autoimmune, endocrine, inflammatory bowel, and sarcoidosis
Medium-vessel vasculitis	Polyarteritis nodosa	Necrotizing inflammation of medium size or small vessels	Two times more common in men, typically during the 40s and 50s; without glomerulonephritis or vasculitis in small vessels; ANCA positive is rare
	Kawasaki disease	Vasculitis of coronary arteries; aorta and veins may be involved	Occurs usually in children; associated with mucocutaneous lymph node syndrome; potential aneurism formation
Small-vessel vasculitis	Henoch-Schönlein purpura	Necrotizing vasculitis; IgA-dominant immune deposits in walls of small vessels and renal glomeruli	Most common vasculitis in children and infrequent in adults; involves skin, gut, and glomeruli; associated with arthralgias or arthritis
	Wegener granulomatosis	Granulomatous inflammation involving upper and lower respiratory tract and necrotizing vasculitis affecting small to medium vessels	Equal in men and women; occurs in any age; necrotizing glomerulonephritis common; cANCA positive
	Microscopic polyangiitis	Necrotizing arteritis, few or no immune deposits; affects small vessels	Cardinal features include glomerulonephritis, pulmonary hemorrhage, mononeuritis multiplex, and fever; pANCA positive

Adapted from Langford (2003) and Mansi et al. (2002).



complications including steroid-induced diabetes, bladder and lymphoproliferative malignancy, and infertility can occur in more than 50% of treated patients (Kamesh et al. 2002). Alternate treatment includes methotrexate, azathioprine, trimethoprim-sulfamethoxazole, plasma exchange, cyclosporine, intravenous immunoglobulin, and monoclonal antibodies (Kamesh et al. 2002; Mansi et al. 2002).

Silica (silicon dioxide), one of the occupational and environmental exposures linked to autoimmune diseases, is formed from the two most abundant elements in the earth's crust, oxygen and silicon (U.S. Department of the Interior 2003). SiO<sub>2</sub> occurs in a non-crystalline (amorphous) or a crystalline form. Crystalline silica is found in seven forms (polymorphisms) [National Institute for Occupational Safety and Health (NIOSH) 2002; U.S. Department of the Interior 2003], of which quartz, cristobalite, and tridymite are the most common. The quartz form is an abundant component of soil and rock; the term is often used to refer to crystalline silica. It is when the crystalline silica-containing rock and sand is used or processed (i.e., mining, quarrying, drilling, sand blasting, tunneling operations) that workers can be exposed to airborne dust levels of respirable crystalline silica that can cause respiratory diseases. Occupational exposure to respirable crystalline silica is associated with a number of respiratory diseases, including silicosis (acute, accelerated, and chronic), progressive pulmonary fibrosis, chronic obstructive pulmonary disease (e.g., chronic bronchitis, emphysema), and lung cancer, and places workers with silicosis at higher risk for tuberculosis (American Thoracic Society Committee of the Scientific Assembly on Environmental and Occupational Health 1997; NIOSH 2002).

The patient worked from 1983 to 1984 in the two oil shale mines (Exxon and Union) in existence in the 1980s in Garfield County, Colorado. The geologic underground rock formation in the area is oil shale and marlstone. The dominant matrix minerals in oil shale and marlstone include silicates. The above-ground rock formation is sandstone and also contains high silica content (Chenoweth W. Personal communication).

Pepper et al. (1998) studied former workers of the NTS and tried to quantify silica exposure rates. In the Phase 1 report of exposures from the NTS, Pepper et al. (1998) noted that the underground environment and the work of drilling, blasting, and mucking provided an essentially uniform dust exposure to all workers (Figure 2). The tunnels are geologically made of soft volcanic tuff. As reported by Pepper et al. (1998), a 1959–1971 U.S. Geologic Survey measured core samples and found a 70% silica concentration weighted average in 1959, and 10–40% cristobalite/crystalline

silica concentration weighted average in 1971. The use of silica-containing grout compound also added to the respirable silica contamination of the ambient air (Pepper et al. 1998) at the NTS. The silica-containing grout was used in the areas around the line-of-sight and the bypass drift and along the tunnels to permit the containment of explosions, moderate potential geological stress, and plug any fractures that may have been formed after an explosion. Pepper et al. (1998) reported that area sampling of respirable dust conducted in 1974 as part of the industrial hygiene program at the NTS showed total dust concentrations of 2–543 mg/m<sup>3</sup> and the percentage of free silica of 0–62%. The permissible exposure levels to respirable quartz as established by the Occupational Safety and Health Administration (OSHA 2003) for an 8-hr time-weighted average are determined as follows:

$$10 \text{ mg/m}^3 \div (\text{percentage of silica} + 2).$$

Industrial hygiene records available from the NTS show that exposures were probably above levels mandated by OSHA (Pepper L. Personal communication).

Respiratory complications from crystalline silica exposures have been known for centuries, but the link of silica exposure and autoimmune disease has been more recent. In the 1950s, Caplan (1953) first described unusual radiologic changes in the lungs of Welsh coal miners who had pneumoconiosis. In a subsequent study of these miners, Miall et al. (1953) found that the rheumatoid lesions in the lung were

predictive for rheumatoid arthritis (subsequently called Caplan's syndrome). Since that time many studies have examined the link between crystalline silica exposure and development of autoimmune diseases (Parks et al. 1999). Among the systemic autoimmune diseases, occupational exposure to crystalline silica exposure has been linked to rheumatoid arthritis, scleroderma, systemic lupus erythematosus, and some of the small vessel vasculitides (Koeper et al. 1995; Parks et al. 1999).

Crystalline silica particles are ingested by alveolar macrophages and result in inflammation and activation of fibroblasts (Parks et al. 1999). The digested crystalline silica destroys the macrophages, and the crystalline silica is again digested by new macrophages. This repeated process leads to chronic immune activity and fibrosis. Studies have shown that crystalline silica can be mobilized from the lungs to other organs, including lymph nodes, spleen, and kidney (Parks et al. 1999). Silicosis and mineral dust pneumoconiosis have been linked to an increase in autoantibodies, immune complexes, and excess production of immunoglobulins, even in the absence of a specific autoimmune disease (Jones et al. 1976; Lippmann et al. 1973). Many of the cases of autoimmune disease were first discovered during screening of silica-exposed workers or workers who were being treated for silicosis. It was not clear in these cases whether the silicosis was a pathologic process that may predispose some individuals to develop autoimmune disease or whether the opposite was true, that the autoimmune disease may



Figure 2. Nevada Test Site. Photograph reproduced from DOE Nevada (2003).

predispose some individuals to develop silicosis in the lung (Parks et al. 1999).

The mechanism of crystalline silica in the development of autoimmune diseases may be a result of the adjuvant effect on antibody production (Parks et al. 1999). (An adjuvant is a substance that enhances an immune response to an antigen.) The development of silicosis is dose dependent, but no studies have determined a dose–response or threshold effect of crystalline silica as an adjuvant. Genetic differences and susceptibility to autoimmune diseases may vary the characteristics and extent of the inflammation caused by silica exposure. Crystalline silica can also cause cell death by necrosis and apoptosis (an active process involving gene regulation) (Nowack et al. 1998; Otsuki et al. 1998). Apoptosis is enhanced by silica and at levels where an acute toxicity is not detected. The sFas ligand, a type II membrane protein that induces apoptosis, is elevated in silicosis patients (Tomokuni et al. 1999). The elevation of sFas levels have been reported in silicosis patients who have slight shortness of breath, normal partial pressure of carbon dioxide (Tomokuni et al. 1999), or normal partial pressure of oxygen (Tomokuni et al. 1997) and have been classified with slight respiratory disorders. Tomokuni et al. (1997) speculated that the severity of respiratory involvement may not occur to the same degree as the abnormalities and elevation of apoptosis-related molecules in silicosis patients. Tomokuni et al. (1999) found no significant correlation of duration of exposure to crystalline silica dust and the serum levels of sFas. Host susceptibility may explain why all workers exposed to silica do not develop autoimmune disorders (Gregorini et al. 1997).

There is experimental and clinical evidence that crystalline silica affects the immune response. Gregorini et al. (1997) reported the presence of increased rheumatoid factors and antinuclear antibodies in 26–44% of patients with silicosis. The most frequently reported autoimmune diseases among crystalline-silica exposed workers are scleroderma, rheumatoid arthritis, systemic lupus erythematosus, autoimmune hemolytic anemia, and dermatomyositis or dermatopolymyositis (NIOSH 2002; Steenland and Goldsmith 1995; Tervaert et al. 1998). A statistically significant association between crystalline silica exposure and several renal diseases has been reported in epidemiologic studies (NIOSH 2002). Steenland et al. (2001) reported an increasing standardized rate ratio for acute and chronic renal disease with increasing cumulative crystalline silica exposure and an excess of end-stage renal disease incidence (highest for glomerulonephritis). The reported cases of glomerulonephritis in patients with crystalline silica exposure show rapid progression and are associated with positive anti-neutrophil cytoplasmic antibodies (ANCA)

with or without systemic vasculitis, such as Wegener granulomatosis or microscopic polyangiitis (Gregorini et al. 1993, 1997). pANCA is strongly associated with microscopic polyangiitis and rapidly progressive glomerulonephritis (RPGN) (Danning et al. 1998). In a recent study (Gregorini et al. 1997), crystalline silica-exposed patients with positive ANCA showed mainly a pANCA pattern. Not all silica-exposed patients with pANCA-positive RPGN reported by Gregorini et al. (1993) had pulmonary silicosis. Gregorini et al. (1997) reported immune abnormalities in patients with silicosis and in silica-exposed patients with no evidence of lung disease.

The intensity of exposure to silica dust may be more important than cumulative exposure or duration in the development of autoimmune diseases (Martin et al. 1999; Sluis-Cremer et al. 1986, 1985). In a study of silica-exposed gold miners, Calvert et al. (1997) investigated end-stage renal disease (ESRD) and exposures. They suggested that crystalline silica exposure was most strongly associated with ESRD (especially ESRD caused by glomerulonephritis) and that the median exposure of the cohort was below the OSHA permissible exposures levels (indicating a lower level of exposure needed to start the disease process).

Effects of silica are thought to be either immune-complex mediated or a result of direct toxic effects of the silica on the glomeruli. Long latency periods (15–25 years) have been reported between first silica exposure and the development of autoimmune diseases. However, in a 1987 study of granite workers, Klockars et al. (1987) documented individuals who developed autoimmune disease in a shorter period of time. The authors published results of a followup of 35 workers exposed to silica who had developed rheumatoid arthritis. Of the workers, 13 had  $\leq 5$  years of exposure before the onset of rheumatoid arthritis. For 7 of the workers, latency ranged from 1 to 12 years. This study was also interesting in that 20 of the 35 miners had normal chest X rays at the time of the onset of rheumatoid arthritis.

The issue of latency was also addressed by Parks et al. (2002), who evaluated occupational exposure to silica and the risk of systemic lupus erythematosus (SLE). In this population-based, case–control study, the authors observed an association between silica and SLE, with medium or high-level silica exposures found in individuals working in farming or trades. The analysis revealed no predominant time window of exposure that accounted for the association observed between silica and SLE.

Irregular opacities in the bases of the lungs, with pleural thickening, that were detected by the case patient's chest CT scan

are consistent with asbestos-related lung disease (Churg 1998; Rom 1998), silicosis and mixed-dust pneumoconiosis (Honma and Chiyotani 1993; Shida et al. 1996), idiopathic pulmonary fibrosis, and smoking tobacco (Dick et al. 1992). Although silicosis is classically described as rounded opacities in the upper lobes, some studies and reviews of the literature describe a less classical finding of irregular opacities in the lower lobes (Dick et al. 1992; Gibbs and Wagner 1998). Honma and Chiyotani (1993) described diffuse interstitial fibrosis (DIF) among workers with a variety of occupations (rock driller, stone mason, metal miner, tunneler, construction worker). The cases were diagnosed pathologically as silicosis (142 cases) or mixed dust pneumoconiosis (91 cases); the diffuse interstitial fibrosis was predominantly in the lower lobes and thickening and adhesion of the pleura covering the DIF was seen in 40.6% of the cases. Two cases were associated with collagen disease, one case was associated with systemic sclerosis, and one was associated with rheumatoid arthritis. In addition, no significant correlation was found between the occurrence of DIF and smoking history (Honma and Chiyotani 1993).

The Energy Employees Occupational Illness Compensation Program Act (EEOICPA; DOE 2003) was passed by the U.S. Congress in October 2000 and went into effect 31 July 2001. The compensation program provides for workers or survivors who have become ill or who have died as a result of exposure to beryllium, silica, or ionizing radiation while working for the DOE and its contractors or subcontractors in the nuclear weapons industry. The diseases covered by EEOICPA include cancer caused by radiation, chronic beryllium lung disease, and chronic silicosis. Workers with beryllium sensitivity are eligible for medical monitoring. For those diseases related to workplace exposures not covered under EEOICPA, Congress has directed the DOE to help workers file state workers' compensation claims. A system including a three-physician panel has been established to review all medical claims. If the panel finds that a medical condition not covered under EEOICPA is related to workplace exposures at a DOE facility, the applicant can include the panel report with the claim for state workers' compensation.

## Conclusion

I have presented the case of a DOE worker with several years of high-intensity exposure to respirable crystalline silica in his workplace. The patient developed pANCA-positive systemic vasculitides (microscopic polyangiitis) with progressive necrotizing glomerulonephritis. Most of the studies on the relationship of silica exposure and the development of systemic vasculitides have been conducted among patients with silicosis, but there is sufficient mention in



the literature that systemic vasculitides may develop independently of silicosis in patients with crystalline silica exposure. Epidemiologic studies link solvent exposure to an increased risk of systemic sclerosis but not systemic pANCA-positive vasculitis. The patient's exposure to solvents has not contributed to the development of his systemic vasculitis. In addition, the patient's other workplace exposures—beryllium, asbestos, lead, and ionizing radiation—are not known causes of systemic vasculitis. On the chest CT scan, the patient did not have the more common abnormality of rounded opacities in the upper lobes, but instead had a linear pattern of interstitial lung fibrosis with pleural thickening. This pattern of pulmonary fibrosis has a larger number of potential causes and risk factors. The literature supports the possibility that his chest CT scan findings of lower lobe interstitial fibrosis may be attributed to the silica exposure.

DOE workers are currently able to apply for compensation under the federal EEOICP. As of 29 August 2003, 18,823 workers nationwide had applied for compensation under EEOICP (DOE Office of Worker Advocacy 2003). Of these applications, 1,077 case claims have been completed; 928 claims have been declared ineligible; 75 claims have been withdrawn by the applicant; 2,806 claims are being developed; 374 cases have been developed and are awaiting final review by the applicant; 14,434 cases are awaiting development; and 132 claims are currently in the physician panel process. Of the claims reviewed by the physician's panel the panel returned 45 positive findings and 29 negative findings. The only diseases covered by EEOICP are cancers related to radiation exposure, chronic beryllium disease, and chronic silicosis. All other diseases are to be covered under state Workers' Compensation systems. The differences in each state's workers' compensation law and the resistance of employers have made compensation difficult to obtain for many workers with serious diseases. Currently, many workers must rely on private insurance, Medicare, or public or charity health plans to cover their medical expenses. Federal legislation should be developed to cover all diseases related to workplace exposures in DOE workers.

## REFERENCES

American Thoracic Society Committee of the Scientific Assembly on Environmental and Occupational Health. 1997. Adverse effects of crystalline silica exposure. *Am J Respir Crit Care Med* 155:761–768.

- Booth AD, Almond MK, Burns A, Ellis P, Gaskin G, Neild GH, et al. 2003. Outcome of ANCA-associated renal vasculitis: a 5-year retrospective study. *Am J Kidney Dis* 41:776–784.
- Calvert GM, Steenland K, Palu S. 1997. End-stage renal disease among silica-exposed gold miners. *JAMA* 277:1219–1223.
- Caplan A. 1953. Certain unusual radiological appearances in the chest of coal-miners suffering from rheumatoid arthritis. *Thorax* 8:29–35.
- Churg A. 1998. Nonneoplastic disease caused by asbestos. In: *Pathology of Occupational Lung Disease* (Churg A, Green FHY, eds). 2nd ed. Baltimore, MD:Williams & Wilkins, 277–338.
- Danning CL, Illei GG, Boumpas DT. 1998. Vasculitis associated with primary rheumatologic diseases. *Curr Opin Rheumatol* 10:58–65.
- D'Cruz D. 2000. Autoimmune diseases associated with drugs, chemicals and environmental factors. *Toxicol Lett* 112-113:421–432.
- Dick JA, Morgan WKC, Muir DFC, Reger RB, Sargent N. 1992. The significance of irregular opacities on the chest roentgenogram. *Chest* 102:251–260.
- DOE. 2000. Energy Employees Occupational Illness Compensation Program Act of 2000 (EEOICPA). Fact Sheet. Washington, DC:U.S. Department of Energy. Available: <http://tis.eh.doe.gov/portal/feature/Factsheet2000.pdf> [accessed 12 March 2003].
- DOE Nevada. 2003. Photo Library. Las Vegas, NV:Department of Energy, Nevada Operations Office. Available: <http://www.nv.doe.gov/news&pubs/photos&films/photolib.htm> [accessed 20 October 2003].
- DOE Office of Worker Advocacy. 2003. EEOICP Claims Status. Washington, DC:U.S. Department of Energy. Available: <http://tis.eh.doe.gov/advocacy/whatshot/20030311programstats.pdf> [accessed 5 September 2003].
- Gibbs AR, Wagner JC. 1998. Diseases due to silica. In: *Pathology of Occupational Lung Disease* (Churg A, Green FHY, eds). 2nd ed. Baltimore, MD:Williams & Wilkins, 209–233.
- Gregorini G, Ferioli A, Donato F, Tira P, Morassi L, Tardanico R, et al. 1993. Association between silica exposure and necrotizing crescentic glomerulonephritis with pANCA and anti-MPO antibodies: a hospital-based case-control study. *Adv Exp Med Biol* 336:435–440.
- Gregorini G, Tira P, Frizza J, D'Haese PC, Elsevieri MM, Nuyts G, et al. 1997. ANCA-associated diseases and silica exposure. *Clin Rev Allergy Immunol* 15:21–40.
- Gonzales-Gay MA, Garcia-Porrúa C. 2001. Epidemiology of the vasculitides. *Rheum Dis Clin North Am* 27:729–749.
- Honma K, Chiyotani K. 1993. Diffuse interstitial fibrosis in non-asbestos pneumoconiosis—a pathological study. *Respiration* 60:120–126.
- Jones RN, Turner-Warwick M, Ziskind M, Weill H. 1976. High prevalence of antinuclear antibodies in sandblasters' silicosis. *Am Rev Respir Dis* 113:393–395.
- Kamesh L, Harper L, Savage CO. 2002. ANCA-positive vasculitis. *J Am Soc Nephrol* 13:1953–1960.
- Klockars M, Koskela RS, Jarvinen E, Kolari PJ, Rossi A. 1987. Silica exposure and rheumatoid arthritis: a follow up study of granite workers 1940–81. *Br Med J* 294:997–1000.
- Koeger A-C, Lang T, Alcaix D, Milleron B, Rozenberg S, Chaibi P, et al. 1995. Silica-associated connective tissue disease. *Medicine* 74:221–237.
- Langford CA. 2003. Vasculitis. *J Allergy Clin Immunol* 111(2 suppl):S602–612.
- Lippmann M, Eckert HL, Hahon N, Morgan WK. 1973. Circulating antinuclear and rheumatoid factors in coal miners: a prevalence study in Pennsylvania and West Virginia. *Ann Int Med* 79:807–811.
- Mansi IA, Opran A, Rosner F. 2002. ANCA-associated small-vessel vasculitis. *Am Fam Physician* 65:1615–1620.
- Martin JR, Griffin M, Moore E, Lochead JA, Edwards AC, Williams J, et al. 1999. Systemic sclerosis (scleroderma) in two iron ore miners. *Occup Med* 49:161–169.
- Mayes MD. 1999. Epidemiologic studies of environmental agents and systemic autoimmune diseases. *Environ Health Perspect* 107(suppl 5):743–748.
- Miall WE, Caplan A, Cochrane AL, Kilpatrick GS, Oldham PD. 1953. An epidemiological study of rheumatoid arthritis associated with characteristic chest x-ray appearances in coal-workers. *Br Med J* 11:1231–1236.
- NIOSH. 2002. NIOSH Hazard Review – Health Effects of Occupational Exposure to Respirable Crystalline Silica. DHHS (NIOSH) Publication No. 2002–2129. Cincinnati, OH:National Institute for Occupational Safety and Health. Available: <http://www.cdc.gov/niosh/02-129pd.html> [accessed 20 October 2003].
- Nowack R, Flores-Suarez LF, van der Woude FJ. 1998. New developments in pathogenesis of systemic vasculitis. *Curr Opin Rheumatol* 10:3–11.
- OSHA. 2003. Regulations (Standards—29 CFR) Table Z-3 Mineral Dusts—1910.1000. Available: [http://www.osha-slc.gov/pls/oshaweb/owadisp.show\\_document?p\\_table=STANDARDS&p\\_id=9994](http://www.osha-slc.gov/pls/oshaweb/owadisp.show_document?p_table=STANDARDS&p_id=9994) [accessed 25 August 2003].
- Otsuki T, Sakaguchi H, Tomokuni A, Aikoh T, Matsuki T, Kawakami Y, et al. 1998. Soluble Fas mRNA is dominantly expressed in cases with silicosis. *Immunology* 94:258–262.
- Parks CG, Conrad K, Cooper GS. 1999. Occupational exposure to crystalline silica and autoimmune disease. *Environ Health Perspect* 107(suppl 5):793–802.
- Parks CG, Cooper GS, Nylander-French LA, Sanderson WT, Dement JM, Cohen PL, et al. 2002. Occupational exposure to crystalline silica and risk of systemic lupus erythematosus: a population-based, case-control study in the southeastern United States. *Arthritis Rheum* 46:1840–1850.
- Pepper L, Boden L, Kozar N, Lally J, Suza K, Medina S. 1998. Medical Surveillance for Former Department of Energy Workers at the Nevada Test Site. Phase 1 Report: Needs Assessment. Boston, MA:Boston University School of Public Health.
- Powell JJ, Van de Water J, Gershwin ME. 1999. Evidence for the role of environmental agents in the initiation or progression of autoimmune conditions. *Environ Health Perspect* 107(suppl 5):667–672.
- Rom WN. 1998. Asbestos-related diseases. In: *Environmental and Occupational Medicine* (Rom WN, ed). 3rd ed. Philadelphia:Lippincott-Raven, 349–375.
- Shida H, Chiyotani K, Honma K, Hosoda Y, Nobeche T, Morikubo H, et al. 1996. Radiologic and pathologic characteristics of mixed dust pneumoconiosis. *Radiographics* 16:483–498.
- Sluis-Cremer GK, Hessel PA, Nizdo EH, Churchill AR. 1986. Relationship between silicosis and rheumatoid arthritis. *Thorax* 41:596–601.
- Sluis-Cremer GK, Hessel PA, Nizdo EH, Churchill AR, Zeiss EA. 1985. Silica, silicosis, and progressive systemic sclerosis. *Br J Ind Med* 42:838–843.
- Smith DA, Germolec DR. 1999. Introduction to immunology and autoimmunity. *Environ Health Perspect* 107(suppl 5):661–665.
- Steenland K, Goldsmith DF. 1995. Silica exposure and autoimmune diseases. *Am J Ind Med* 28:603–608.
- Steenland K, Sanderson W, Calvert GM. 2001. Kidney disease and arthritis in a cohort study of workers exposed to silica. *Epidemiology* 12:405–412.
- Tervaert JWC, Stegeman CA, Kallenberg CGM. 1998. Silica exposure and vasculitis. *Curr Opin Rheumatol* 10:12–17.
- Theofilopoulos AN, Kono DH. 1998. Mechanisms and genetics of autoimmunity. *Ann NY Acad Sci* 841:225–235.
- Tomokuni A, Aikoh T, Matsuki T, Isozaki Y, Otsuki T, Kita S, et al. 1997. Elevated soluble Fas/APO-1 (CD95) levels in silicosis patients without clinical symptoms of autoimmune diseases or malignant tumours. *Clin Exp Immunol* 110:303–309.
- Tomokuni A, Otsuki T, Isozaki Y, Kita S, Ueki H, Kusaka M, et al. 1999. Serum levels of soluble Fas ligand in patients with silicosis. *Clin Exp Immunol* 118:441–444.
- U.S. Bureau of Mines. 1992. Crystalline Silica Primer. Available: <http://minerals.usgs.gov/minerals/pubs/commodity/silica/780292.pdf> [accessed 25 August 2003].
- Watts RA, Scott DG. 1997. Classification and epidemiology of the vasculitides. *Baillieres Clin Rheumatol* 11:191–217.