

# Regional Specificity in the Neuropathologic Substrates of Schizophrenia

## A Morphometric Analysis of Broca's Area 44 and Area 9

Lynn D. Selemon, PhD; Jasna Mrzljak, MD; Joel E. Kleinman, MD, PhD; Mary M. Herman, MD; Patricia S. Goldman-Rakic, PhD

**Background:** Numerous recent studies of postmortem schizophrenic brains have reported the presence of structural abnormalities in the dorsolateral prefrontal cortex (dlPFC) that are consistent with a reduction of neuropil. Ventrolateral prefrontal areas have been studied less extensively, and therefore it is not clear whether these cortices exhibit pathologic abnormalities of the same type and magnitude. Because thought disturbances in schizophrenic patients involve language processing, we have performed a morphometric analysis of Broca's area in the ventral frontal lobe.

**Methods:** Neuronal and glial density and somal size were assessed via stereologic cell counting in postmortem samples of Broca's area 44 in 9 schizophrenic patients and 14 normal controls. Cell density was reexamined in dorsolateral prefrontal area 9 as an internal control.

**Results:** We did not detect abnormalities in overall or laminar neuronal density, glial density, cortical thickness, or somal size in area 44 of schizophrenic patients. In contrast, neuronal density in area 9 exhibited a 12% increase in the schizophrenic cohort, replicating previous findings. In addition, there was a significant effect of disease on laminar neuronal density in area 9, with neuronal density tending to be higher (7%-29%) in all layers.

**Conclusions:** The absence of significant cytoarchitectonic abnormalities in Broca's area in the same brains in which the dlPFC exhibited an increase in neuronal density suggests that the neuropil deficit is a regionally specific pathologic finding in schizophrenia and indicates that the dlPFC is a particularly vulnerable target of the disease process.

*Arch Gen Psychiatry.* 2003;60:69-77

**I**N RECENT YEARS, the dorsolateral prefrontal cortex (dlPFC) has been the target of intensive study in schizophrenia with noninvasive neuroimaging analyses and morphologic and biochemical analyses of postmortem brains.<sup>1,2</sup> Using stereologic methods, we have shown that neuronal density is elevated in the dlPFC (areas 9 and 46) in schizophrenic patients,<sup>3,4</sup> and these findings have been interpreted as evidence that a reduction in cortical neuropil may be a neuropathologic substrate for cognitive dysfunction of the prefrontal cortex in schizophrenia.<sup>5</sup> Numerous postmortem studies<sup>6-11</sup> of presynaptic and postsynaptic elements support the hypothesis that neuronal connectivity is impoverished in the dlPFC in schizophrenic brains.

Neuropathologic findings in the dlPFC provide a biologic basis for working memory impairments, including associated eye tracking deficits, that are reliably observed in schizophrenic patients.<sup>12-16</sup> Pathologic abnormalities in the dlPFC may also account for abnormal brain activation of this region as observed in neuroimaging studies.<sup>17-22</sup> One question that arises is whether

the prominence of neuropathologic findings in the dlPFC in schizophrenia simply reflects a research bias because many contemporary studies have focused on this area or if in fact pathologic findings of the dlPFC are more pronounced than those of other cortical areas. In addition, as divergent findings in the cortex have emerged from independent laboratories using different methods and studying distinct cohorts of patients, it has not been possible to determine which of the factors—cortical region, methods, or patient cohort—accounts for the disparate neuropathologic findings. Thus, despite the diversity of reported changes in neuronal density, the existence of regional specificity in the neuropathologic substrate of schizophrenia has been viewed with considerable skepticism.

Language dysfunction is prominent in schizophrenia and encompasses a broad spectrum of disturbances, ranging from syntactic and semantic abnormalities to incoherency of speech and loose associations.<sup>23-26</sup> Despite the prominence of aberrant speech patterns in schizophrenic patients, Broca's area has not been studied in postmortem schizophrenic brains.

*From the Department of Neurobiology, Yale University School of Medicine, New Haven, Conn (Drs Selemon, Mrzljak, and Goldman-Rakic); and Clinical Brain Disorders Branch, National Institute of Mental Health, Intramural Research Program, National Institutes of Health, Bethesda, Md (Drs Kleinman and Herman).*

**Table 1. Case List\***

Brain No.	Diagnosis	Age, y/Sex/Race	Postmortem Interval, h	Time in Formalin, mo	Cause of Death
B3500	Control	76/M/W	24.0	10.2	Prostate cancer
B3547	Control	49/F/W	23.4	NA	Breast cancer
B3688	Control	66/M/NA	18.7	4.0	Myocardial infarct
B3700†	Control	62/F/W	16	4.5	Myocardial infarct
B3732†	Control	69/M/W	15.3	3.9	Respiratory failure
B3740†	Control	48/M/W	15.4	3.9	Heart attack
B3748†	Control	44/M/W	23	3.9	Heart attack
B3806†	Control	70/F/NA	15	2.2	Cardiac arrest
B3826	Control	53/M/NA	16.25	1.6	Asthma
B3838	Control	65/M/W	10.4	NA	Myocardial infarct
N10†	Control	52/F/B	10	49.0	Ruptured pericardial aorta
N11†	Control	28/M/B	14	48.3	Gunshot wound
N12†	Control	41/M/B	15	48.0	Stab wound to chest
N14†	Control	38/M/B	32	44.6	Pulmonary embolism
B3249†	Schizophrenia	66/F/W	7.2	11.1	Chronic obstructive pulmonary disease
B3441	Schizophrenia, probable‡	36/M/W	24.7	5.0	Sudden death unknown
B3456†	Schizophrenia, probable‡	74/F/W	27.2	NA	Breast cancer
B3498	Schizophrenia	66/M/NA	22.1	5.0	Emphysema
B3546†	Schizophrenia	69/M/W	17.8	8.6	Cancer, colon and liver
B3574	Schizophrenia, probable‡	66/M/W	24.4	5.7	Arrhythmia
N7†	Schizophrenia	36/M/W	35	46.1	Suicide with body burns
N15†	Schizophrenia	61/F/B	21.5	44.0	Aspiration of food bolus
N16†	Schizophrenia	32/M/H	24	53.0	Suicide, neck wounds

Abbreviations: B, black; H, Hispanic; NA, not available; and W, white.

\*B-numbered brains are from the Harvard Brain Tissue Resource Center; N-numbered brains, from the National Institute of Mental Health. The mean ± SD age (in years) was 54.4 ± 14.0 for controls and 56.2 ± 16.6 for schizophrenic patients ( $F_1 = 0.084, P = .78$ ). The mean ± SD postmortem interval (in hours) was 17.7 ± 6.0 for controls and 22.6 ± 9.1 for schizophrenic patients ( $F_1 = 3.04, P = .10$ ). The mean ± SD time in formalin (in months) was 17.9 ± 19.8 for controls and 22.3 ± 21.3 for schizophrenic patients ( $F_1 = 234, P = .63$ ).

†Cases analyzed for area 9.

‡Cases designated as "probable schizophrenia" have met the Feigner criteria for schizophrenia with regard to duration and symptoms, ie, these cases have a chronic illness of at least 6 months' duration without subsequent return to premorbid levels of psychosomatic adjustment and do not show signs of depression or mania consistent with affective disorder. The diagnosis of "probable schizophrenia" also indicates the presence of either delusions and/or hallucinations, significant communication deficits due to lack of logical thinking, or both. "Probable schizophrenia" is distinguished from "schizophrenia" by meeting 2 of 5 of the following demographic criteria. To qualify for a diagnosis of schizophrenia, 3 or more of these criteria must be met: (1) single, (2) poor premorbid social adjustment or work history, (3) family history of schizophrenia, (4) absence of alcoholism or drug abuse within 1 year of onset of psychosis, and (5) onset of illness before age 40 years.

The objectives of the present study were (1) to examine the neuropathologic correlate of language dysfunction in Broca's area and (2) to determine whether Broca's area exhibits pathologic abnormalities similar to those of the dlPFC. Accordingly, a 3-dimensional cell counting method was used to assess alterations in neuronal and glial density and somal size in Broca's area 44, and, in a subset of the same schizophrenic and control brains, cell density in area 9 was reexamined. Increased neuronal density was again found in area 9. Cytoarchitectonic abnormalities were not detected in area 44. These data provide further evidence that the pronounced reduction of neuropil that characterizes the dlPFC in schizophrenia is a regionally specific pathologic finding.

## METHODS

### SOURCES AND DIAGNOSIS OF BRAIN MATERIALS

A total of 33 brains (15 from schizophrenic patients and 18 from normal controls) were examined in this study. Twenty-five brains were obtained from the Harvard Brain Tissue Resource Center (HBTRC) in Belmont, Mass; an additional 8 brains were procured from the Section of Neuropathology, Clinical Brain Disorder Branch, Intramural Research Program, National Institute of Mental Health (NIMH), Bethesda, Md. All brains were obtained in accordance with the procedures established by the institutional review boards of the participating institutes. Ten brains had

to be eliminated because a final diagnosis of schizophrenia (6) or control (1) could not be confirmed because of confounding secondary diagnoses or neuropathologic conditions (2) or because the tissue was unsuitable for counting (1). An additional HBTRC control case was eliminated because of long storage time in formalin (TF) that did not match any of the remaining HBTRC schizophrenic brains. Thus, analysis was performed on the remaining 9 schizophrenic and 14 normal control brains (**Table 1**).

Brains included in the study were from subjects 76 years or younger who did not have a history of prior neurologic illness or injury (**Table 2**). The brains were placed in phosphate-buffered neutral 10% formalin within 35 hours of death and in most cases within 25 hours. All brains obtained from the HBTRC were stored in formalin for less than 1 year; exact storage times for 3 of these brains were not available, but TF was in the same range as that of the other brains from this source. Brains obtained from the NIMH had all been stored in formalin for 3.5 to 4.5 years. Thus, schizophrenic and control brains were matched for age, postmortem interval (PMI), and TF by source (Table 1). At autopsy, none of the brains showed evidence of atrophy or other pathologic changes in the frontal lobes or contained lesions near the sites of analysis. One schizophrenic brain (B3498) had a few scattered plaques in the anterior frontal cortex consistent with the effects of normal aging. Another schizophrenic brain (B3546) was found to have an old, small infarct in the putamen, and a third (B3574) exhibited 2 small infarcts, one in the calcarine cortex and another in the white matter subjacent to the precentral gyrus. Control subjects did not have a history of schizophrenia or psychiatric illness in their families. The diagnosis of

**Table 2. Diagnostic Information\***

Brain No.	Age of Onset, y	Duration of Illness, y	Symptoms†	Family History	Alcohol or Other Drug Intake	Medication
B3249	30	36	1, 2, 4	Schizophrenia	None	Chlorpromazine, 1200 mg
B3441	20	14	1, 2, 3, 4	Alcohol abuse	A(s)	Chlorpromazine, 10 mg
B3456	25	49	1, 2, 4	Paranoid behavior	None	Clozapine, 150 mg/d
B3498	NA	NA	1, 2, 3	None	None	Haloperidol, 1 mg
B3546	31	38	1, 2	Psychosis	None	Chlorpromazine, 0‡
B3574	20	46	1, 4	Suicide	A	Theophylline
N7	12	24	1, 2, 3, 4	None	None	Perphenazine, 32 mg/d
N15	34	27	1, 2, 3	None	None	Chlorpromazine, 200 mg
N16	23	9	1, 3, 4	None	A, M, PCP	Haloperidol, up to 30 mg/d

Abbreviations: A, alcohol use; A(s), secondary diagnosis of alcohol abuse; M, occasional marijuana; NA, not available; PCP, occasional phencyclidine.

\*Control cases with a history of alcohol or other drug intake: B3732-A; B3826-A; N11-PCP; N12-A; and N14—drug abuse. B-numbered brains are from the Harvard Brain Tissue Resource Center; N-numbered, from the National Institute of Mental Health.

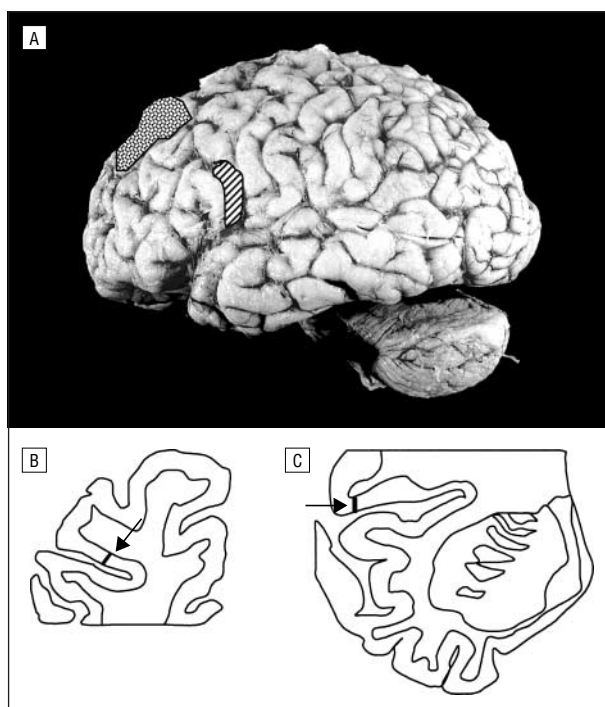
†1 indicates hallucinations and/or delusions; 2, flatness of affect; 3, thought disorder; and 4, depression (eg, sleep or appetite loss, hopelessness, social withdrawal, or multiple suicide attempts).

‡Patient was free of neuroleptic agents at the time of death.

schizophrenia was ascertained via retrospective review of the subjects' medical records and application of either the Feigner criteria (Francine M. Benes, MD, PhD, HBTRC) or *DSM-IV* (J.E.K.). Information regarding age of onset, duration of illness, symptoms, medications, substance abuse, and family history of mental illness are provided in Table 2.

#### HISTOLOGIC PROCESSING AND CELL COUNTING

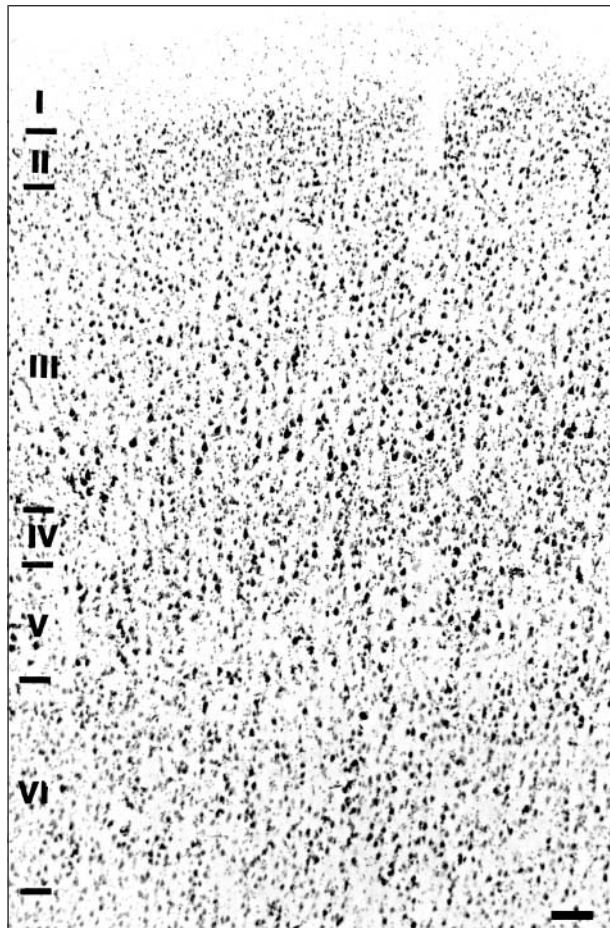
Small blocks (approximately 1 cm<sup>3</sup>) of Broca's area 44 were dissected from the posterior portion of the third frontal convolution (pars opercularis) of the left hemisphere, embedded in celloidin, and sectioned at 40 μm (**Figure 1**). Nissl-stained sections were examined to identify sections containing area 44 based on cytoarchitectonic characteristics of this area as described in the "Results" section. Five sections evenly spaced throughout the sections containing area 44 were chosen for measurement of cell density. For example, if after identifying the extent of area 44 in slides from the block, area 44 was located in 15 slides (cut at 40 μm spaced 400 μm apart), we sampled every third slide or every 1.2 mm. All slides were coded so that the investigators (L.D.S. and J.M.) were blind to diagnosis during the analysis. Slides of area 44 were analyzed under an ×100 oil objective on either a Zeiss Standard (L.D.S.) or Zeiss Axiophot (J.M.) (Carl Zeiss, Oberkochen, Germany) microscope with video output to a personal computer. The custom designed software Quantify (Oguz Algan, MD, PhD, Department of Neurobiology, Yale University School of Medicine) was used to define a 3-dimensional box (dimensions: 80 μm [x] × 60 μm [y] × 25 μm [z]) within the thickness of the section, allowing at least 5-μm guard zones at the top and bottom of the section, and to apply a direct, 3-dimensional counting method.<sup>27,28</sup> Neurons and glia were counted separately in a linear probe of stacked counting boxes extending from the pial surface to the underlying white matter. Small neurons were distinguished from glia on the basis of cytologic characteristics, including presence of visible cytoplasm, a less distinct nuclear membrane, and a less heterogeneous distribution of chromatin material in the nucleus as illustrated previously.<sup>29</sup> Laminar boundaries, which were most clearly visible at low power (6.3×), were marked on the linear probes by switching back and forth between 6.3× and 100× objectives during the analysis so that cell density for each of the 6 layers could be calculated. Total length of the linear probe provided a measurement of cortical thickness. Values from the 5 linear probes were averaged to obtain a mean value of neuronal density, glial density, and cortical thickness for each case. Because layers II and IV are very thin in area 44, an additional 6 to 12 linear probes were analyzed in which only neurons in



**Figure 1.** A, Lateral view of schizophrenic brain B3546 (brain from Harvard Brain Tissue Resource Center) showing Broca's area 44 (striped area) and the magnocellular portion of area 9 (stippling). B and C, Coronal sections through area 9 and Broca's area 44, illustrating the location of probes for this case (see arrows pointing to black bars).

layers II and IV were counted. This ensured that a minimum volume of  $3 \times 10^{-3}$  mm<sup>3</sup> (range,  $3.00$ - $4.59 \times 10^{-3}$  mm<sup>3</sup>) was sampled for these small granular layers, a volume comparable to the sampling volume in layers V and VI ( $4.05 \times 10^{-3}$  mm<sup>3</sup> and  $4.93 \times 10^{-3}$  mm<sup>3</sup>, respectively). Linear probes of layers II and IV were located on the same 5 sections but spaced a minimum of 500 μm from the original probes. Pyramidal and nonpyramidal density was assessed in a minimum of 2 linear probes in all cases and in the additional 6 to 12 linear probes per case for layers II and IV. Pyramidal neurons were identified by the triangular shape of the nucleus; all other neurons were classified as nonpyramidal.

In 15 cases (6 schizophrenic and 9 control), representing all cases in which area 9 was available for study, additional small blocks of the magnocellular portion of area 9 were dissected



**Figure 2.** Photomicrograph illustrating the cytoarchitectonic composition of Broca's area 44 in a Nissl-stained section. Characteristic features of this cortex include thin granular layers II and IV and the presence of large pyramidal cells in lower layer III. Scale bar=100  $\mu$ m.

from the left hemisphere (Figure 1) and processed for cell counting as described herein. A minimum of 3 probes per case were analyzed (L.D.S.).

#### SOMAL SIZE MEASUREMENTS

In 2 probes from all cases, somal sizes were measured throughout all 6 cortical layers of area 44 as described in detail previously<sup>30</sup> and in an additional 6 to 10 probes in layers II and IV. The outlines of neuronal and glial soma were traced with the aid of a digitizing tablet. Note that glial soma were approximated by the glial nucleus since glial cytoplasm was not visible. The diameter of a circle with equivalent area was then calculated for each of these measurements. Average diameters for neuronal soma and glial nuclei were calculated for each layer of individual cases. Group means for control and schizophrenic cases were then computed by averaging the means from individual cases.

#### STATISTICAL ANALYSIS

An analysis of variance (ANOVA) with post hoc comparison of normal and schizophrenic groups was performed to determine the presence of abnormalities in overall neuronal density, glial density, and cortical thickness in the schizophrenic brains. Similar statistical analyses of group means for age, PMI, and TF were performed. Cell densities and proportionate thickness of the 6 cortical layers were analyzed with a repeated-measures ANOVA. A Bonferroni correction was applied to take into account the large number of comparisons ( $P$  value/number of cortical layers = .05/6).

Therefore, laminar differences were considered significant at  $P < .008$ . Interrater reliability of the overall neuronal density in area 44 was assessed with a Spearman  $\rho$  correlation. In addition, regression analysis was performed to assess any possible influence of age, PMI, or storage TF on the measured parameters of cell density and cortical thickness. A regression analysis was also performed on the 15 cases in which both areas 9 and 44 were counted to determine if there were a correlation between neuronal density in the 2 areas.

## RESULTS

### QUALITATIVE OBSERVATIONS

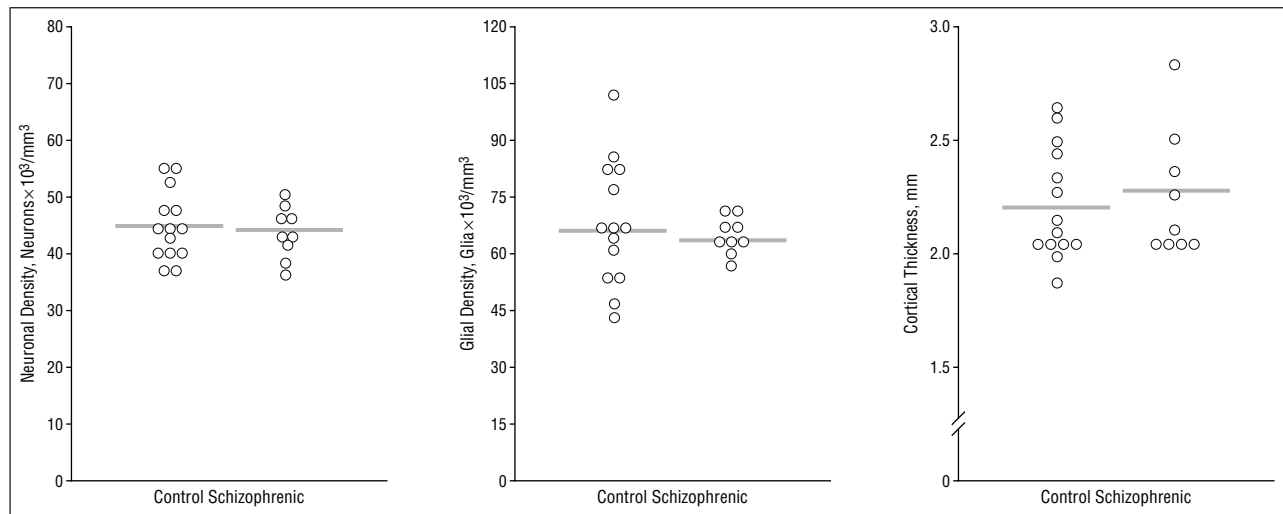
Area 44 was identified on the basis of classic cytoarchitectonic descriptions of this cortical area by Brodmann,<sup>31</sup> and delineation of area 44 in these brains was consistent with a recent quantitative analysis of area 44.<sup>32</sup> Area 44, a dysgranular cortex, is characterized by thin layers II and IV (Figure 2). In addition, large magnopyramidal cells occupy lower layer III in area 44. Area 44 is distinguished from adjoining area 9 by having an even thinner layer IV than area 9 yet more extensive infragranular layers V and VI, thus resulting in a thicker cortical ribbon overall. Area 44 is easily distinguished from neighboring area 45, which has wider, more prominent granular layers. No overt abnormalities in cytoarchitectonic arrangement were observed in the schizophrenic brains in area 44. The magnocellular division of area 9, as described previously,<sup>33</sup> has a wide layer III with increasingly larger pyramidal cells in the deeper sublayers, a thin layer IV that often is interrupted by the protrusion of large pyramidal cells from adjacent layers, and thin infragranular layers. Area 9 in the schizophrenic brains exhibited a normal arrangement of cell layers and cell types.

### QUANTITATIVE DATA

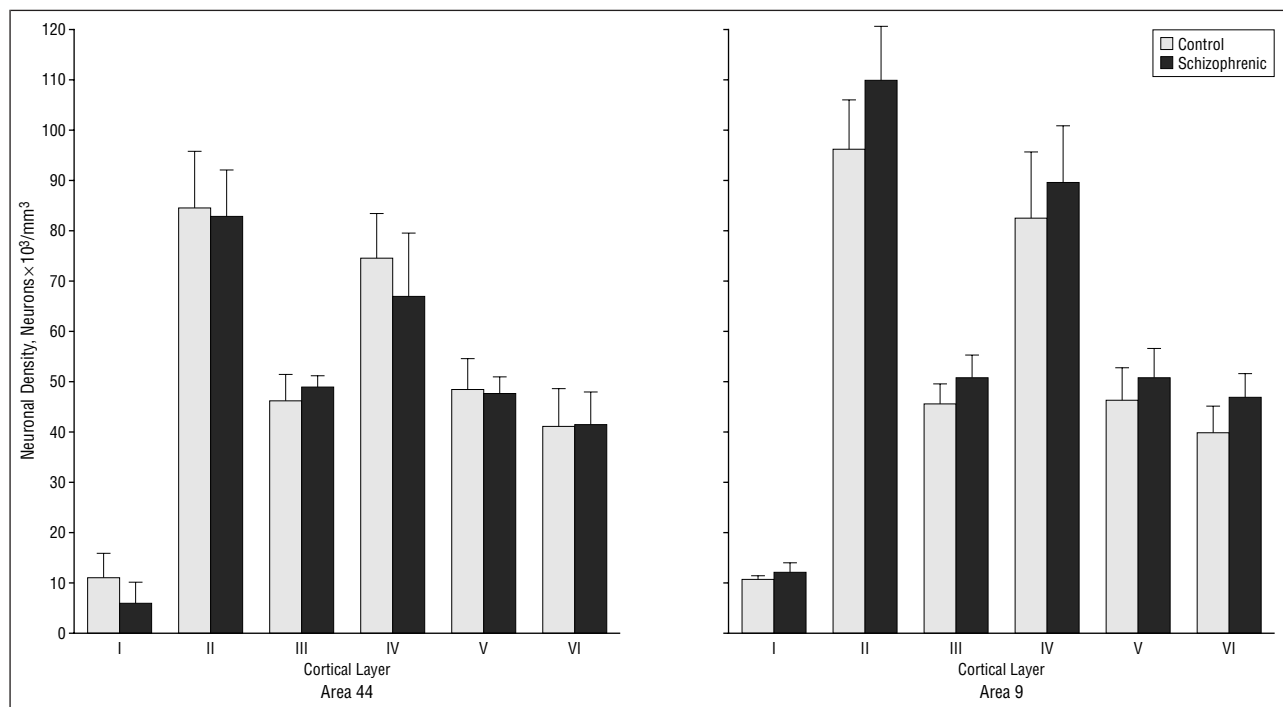
A total of 39 527 neurons and 50 991 glia were counted in this study. Of the 29 301 area 44 neurons counted, 5955 were measured to assess neuronal somal size; glial nuclear size was measured in 8690 of 37 476 glia. The number of neurons counted per layer in area 44 ranged from 4415 (layer V) to 8554 (layer III), with the exception of the neuron-sparse layer I (508). Glial counts ranged from 3104 (layer I) to 11 235 (layer III). Average neuronal and glial counts per probe in area 44 were 164 and 237, respectively. In area 9, average neuronal and glial counts per probe were 168 and 221. In area 9, total neuronal counts per layer, excluding layer I, ranged from 1304 (layer V) to 4021 (layer III); glial counts ranged from 865 (layer II) to 5021 (layer III). Therefore, for each case, a minimum of 90 neurons per layer (II-VI) were counted in area 9, and no less than 191 neurons per layer were counted in every case in area 44.

#### Area 44

The overall morphometric profile of area 44 in the schizophrenic brains did not differ from that of the control group (Figure 3). Mean  $\pm$  SD neuronal density spanning layers I through VI in controls measured  $45.80 \pm 6.03 \times 10^3$  neurons/mm<sup>3</sup> and was nearly identical in the schizophrenic cohort ( $44.64 \pm 4.20 \times 10^3$  neurons/mm<sup>3</sup>;  $F_{1,21} = 0.255$ ;  $P = .62$ ). When the 3 cases with a diagnosis of "probable schizophrenia" were excluded from the analy-



**Figure 3.** Plots of individual case values for neuronal density, glial density, and cortical thickness are shown for Broca's area 44. No differences were observed between control and schizophrenic brains.



**Figure 4.** Neuronal density for each of the 6 cortical layers for Broca's area 44 is shown in the graph to the left. On the right, neuronal density in layers I through VI of area 9 is illustrated. Note that neuronal density tended to be higher in all 6 layers in the schizophrenic brains compared with the controls. The elevation in neuronal density in layer III was marginally significant.

sis, neuronal density in the schizophrenic group was again similar to controls ( $44.58 \pm 5.13 \times 10^3/\text{mm}^3$ ;  $F_{1,18}=0.185$ ;  $P=.67$ ). Mean glial density across all layers was comparable in control ( $68.23 \pm 16.85 \times 10^3/\text{mm}^3$ ) and schizophrenic groups ( $65.56 \pm 4.68 \times 10^3/\text{mm}^3$ ;  $F_{1,21}=0.213$ ;  $P=.65$ ), and cortical thickness did not differ between control ( $2.24 \pm 0.23$  mm) and schizophrenic brains ( $2.26 \pm 0.25$  mm;  $F_{1,21}=0.046$ ;  $P=.83$ ) (Figure 3).

Repeated-measures ANOVA for neuronal density in each of the 6 cortical layers showed neither a significant effect of disease ( $F_{1,21}=0.555$ ,  $P=.46$ ) nor a layers-by-disease effect ( $F_{5,105}=1.726$ ,  $P=.14$ ) in area 44 (Figure 4). Likewise, laminar analyses of nonpyramidal cell density did not indicate a significant effect of disease ( $F_{1,21}=2.46$ ,

$P=.13$ ) or layers-by-disease ( $F_{5,105}=1.059$ ,  $P=.39$ ), and laminar pyramidal cell density did not differ between schizophrenic and control groups (disease effect:  $F_{1,21}=0.414$ ,  $P=.53$ ; layers-by-disease effect:  $F_{5,105}=1.252$ ,  $P=.29$ ).

There was no significant effect of disease ( $F_{1,21}=0.309$ ,  $P=.58$ ) or layers-by-disease ( $F_{5,105}=0.279$ ,  $P=.92$ ) for glial density in the 6 cortical laminae. Although no significant difference in proportionate width of the 6 layers was indicated by the initial ANOVA (disease effect:  $F_{1,21}=.008$ ,  $P=.09$ ), a significant layers-by-disease effect was found ( $F_{5,105}=5.44$ ,  $P<.001$ ). Post hoc pairwise analysis of individual layers revealed a trend 7% decrease in layer III (control,  $37.14\% \pm 2.58\%$ ; schizophrenic,  $34.55\% \pm 1.81\%$ ;  $F_{1,21}=6.855$ ,  $P=.02$ ) and a significant 16% increase in layer

V (control,  $16.98\% \pm 1.59\%$ ; schizophrenic,  $19.76\% \pm 1.94\%$ ;  $F_{1,21} = 14.05$ ,  $P = .001$ ). All other layers of area 44 were comparable in relative thickness between schizophrenic and control brains.

Mean neuronal somal size ranged from 7.7 to 13.3  $\mu\text{m}$  in layers I through VI; no differences between schizophrenic and control cases were found (**Table 3**). Mean glial nuclear size was much more homogeneous across all cortical layers, ranging from 4.6 to 4.9  $\mu\text{m}$ , and did not differ between schizophrenic and control groups (disease effect:  $F_{1,21} = 0.027$ ,  $P = .87$ ; layers-by-disease effect:  $F_{5,105} = 0.724$ ,  $P = .61$ ).

### Area 9

In the 15 cases in which area 9 was analyzed, neuronal density in the 9 control brains measured  $46.40 \pm 5.55 \times 10^3$  neurons/ $\text{mm}^3$ , which was comparable to the density found in our previous study<sup>3</sup> of area 9 ( $47.79 \times 10^3$  neurons/ $\text{mm}^3$ ). In the schizophrenic brains, neuronal density was 12% higher ( $52.09 \pm 1.97 \times 10^3$  neurons/ $\text{mm}^3$ ,  $F_{1,13} = 5.694$ ,  $P = .03$ ) than controls (**Figure 5**). Exclusion of the case with a diagnosis of probable schizophrenia had virtually no effect on neuronal density for the schizophrenic cohort ( $52.61 \pm 1.69 \times 10^3$  neurons/ $\text{mm}^3$ ;  $F_{1,12} = 5.762$ ;  $P = .03$ ).

**Table 3. Area 44 Neuronal Somal Diameter**

Cortical Layer	Somal Diameter, $\mu\text{m}$		Statistic*
	Controls	Schizophrenic Patients	
I	$7.78 \pm 0.80$	$7.70 \pm 0.95$	$F_{1,21} = 0.018$ , $P = .89$
II	$9.05 \pm 0.69$	$9.10 \pm 0.75$	$F_{1,21} = 0.164$ , $P = .69$
III	$12.32 \pm 1.13$	$12.38 \pm 1.00$	$F_{1,21} = 0.139$ , $P = .71$
IV	$9.68 \pm 0.87$	$9.69 \pm 0.61$	$F_{1,21} = 0.139$ , $P = .71$
V	$11.91 \pm 1.26$	$12.77 \pm 0.96$	$F_{1,21} = 3.387$ , $P = .08$
VI	$13.29 \pm 1.97$	$13.15 \pm 0.79$	$F_{1,21} = 0.001$ , $P = .98$

\*Disease effect:  $F_{1,21} = 0.124$ ,  $P = .73$ ; layers-by-disease effect:  $F_{5,105} = 1.277$ ,  $P = .28$ .

Mean glial density did not differ between control ( $61.95 \pm 14.69 \times 10^3$  glia/ $\text{mm}^3$ ) and schizophrenic brains ( $66.46 \pm 6.31 \times 10^3$  glia/ $\text{mm}^3$ ;  $F_{1,13} = 0.494$ ,  $P = .50$ ). Likewise cortical thickness was not significantly different between control ( $2.05 \pm 0.31$  mm) and schizophrenic groups ( $2.06 \pm 0.05$  mm;  $F_{1,13} = .003$ ,  $P = .96$ ). When neuronal density was analyzed for area 44 in the same 15 cases, no significant difference was found (Figure 5). Neuronal density in area 9 was higher in every schizophrenic case than neuronal density in area 44 (Figure 5), and regression analysis indicated that neuronal densities in areas 9 and 44 were not correlated for these 15 cases (Figure 5).

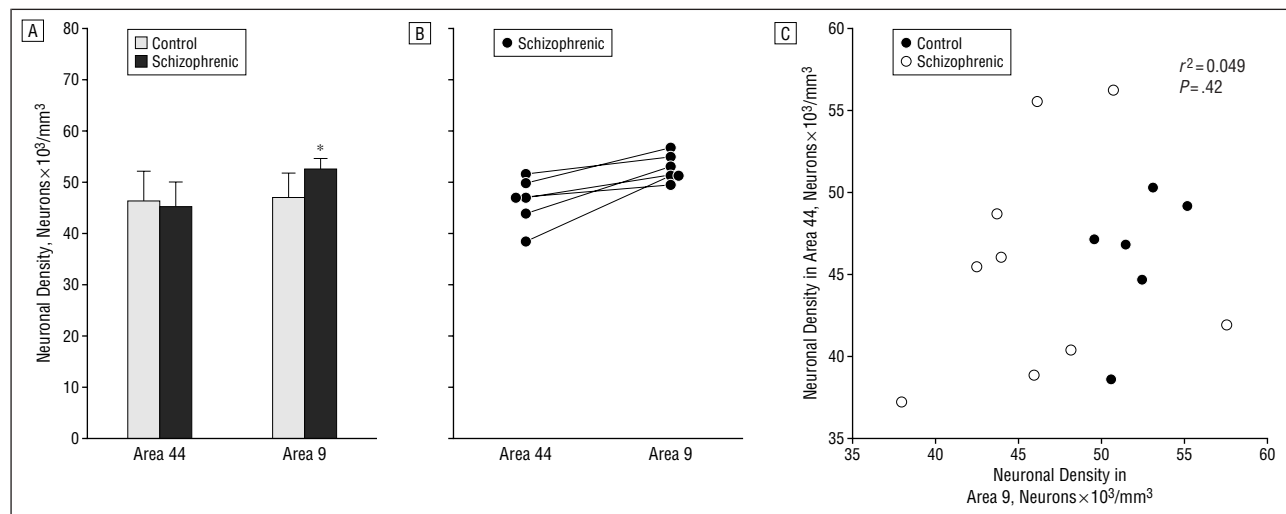
In agreement with data from our previous study<sup>3</sup> of area 9, there was a significant effect of disease on laminar neuronal density ( $F_{1,13} = 6.65$ ,  $P = .02$ ), with no significant effect of layers by disease ( $F_{5,65} = 0.826$ ,  $P = .54$ ), because neuronal density tended to be elevated in all 6 layers with a marginally significant increase in layer III ( $F_{1,13} = 9.254$ ,  $P = .009$ ) (Figure 4). Analysis of laminar glial density in area 9 did not uncover significant effects of disease ( $F_{1,13} = 0.681$ ,  $P = .42$ ) or layers by disease ( $F_{5,65} = 0.66$ ,  $P = .66$ ). Likewise, the proportionate width of the 6 cortical layers was not different in schizophrenic and control groups in area 9 (disease:  $F_{1,13} = 1.08$ ,  $P = .32$ ; layers by disease:  $F_{5,65} = 0.541$ ,  $P = .74$ ).

### Interrater Reliability

A Spearman  $\rho$  correlation of 0.668 ( $n = 18$ ,  $P = .002$ ) was found for neuronal density in area 44. Because different probes were counted by the 2 raters, this correlation reflects an acceptable degree of congruence between the counts.

### Effects of Age, PMI, and TF

In the 9 schizophrenic and 14 control cases in which area 44 was analyzed, there were no significant differences in age, PMI, or TF between the schizophrenic and control groups (Table 1); furthermore, regression analysis did



**Figure 5.** A, Neuronal density was 12% higher in area 9 in schizophrenic brains compared with controls. No difference was observed between these same 6 schizophrenic and 9 control brains in Broca's area 44. B, Neuronal density was as high or higher in area 9 in all 6 schizophrenic brains analyzed for both areas. C, There was no correlation between neuronal density in area 9 and neuronal density in area 44 in the 15 brains analyzed for both areas.

not reveal any correlation between these factors and neuronal density, glial density, or cortical thickness. In the 15 cases analyzed for both areas, no significant differences between groups were found for age ( $F_1=0.226$ ,  $P=.64$ ), PMI ( $F_1=0.282$ ,  $P=.60$ ), or TF ( $F_1=0.177$ ,  $P=.68$ ). Note that these statistics represent TF values for area 9 blocks, which differed slightly from the TF for area 44 blocks from the same cases. Regression analysis did not reveal any influence of age or PMI on neuronal density in area 9. Although a significant effect of TF on neuronal density was observed ( $r^2=0.282$ ,  $P=.02$ ), when analysis of covariance was performed for neuronal density in area 9 with TF as the covariate, the difference in the adjusted means remained significant ( $F_1=8.513$ ,  $P=.01$ ).

#### COMMENT

In the present study, neuronal density in Brodmann area 44 in schizophrenic brains was not different from that of controls, whereas in the same brains a generalized increase in neuronal density was measured in dlPFC area 9, replicating our previous morphometric findings in an entirely new cohort of brains.<sup>3</sup> In addition, the previously reported<sup>29</sup> reduction in neuronal somal size in layer III of area 9 was not present in area 44 in the schizophrenic brains studied herein. These results add to a growing body of evidence suggesting that the dlPFC exhibits more pronounced pathologic abnormalities than ventral regions of the prefrontal cortex and that the neuropathologic substrate of schizophrenia are characterized by regional specificity.

#### LIMITATIONS OF THE METHODS

The boundaries of individual cortical areas in the prefrontal cortex are not sharply defined because the cytoarchitectonic features of neighboring areas blend gradually into each other. Thus, it was not possible to systematically, randomly sample area 44 or 9 in this study; instead we sampled as widely as possible throughout each cortical area of interest. As a result, we could not assess total volume or total cell number in either area. As discussed at length previously,<sup>3,4</sup> drawing any conclusions about changes in neuron number from our findings must be done with caution because changes in the reference volume of the cortical area could have occurred. In addition, because we sampled the middle of each cortical area where the cytoarchitectonic features could be clearly identified, our findings may not apply to transitional regions of cortex at the boundaries of the area. Finally, the possibility that differential shrinkage occurred between schizophrenic and control groups in area 9 and in area 9 selectively, resulting in the increase in neuronal density only in area 9 in the schizophrenic brains, cannot be entirely dismissed. However, this possibility seems highly unlikely because 3 separate cohorts of brains have now shown similar elevations in neuronal density in the dlPFC. Furthermore, it is well established that reduction of cortical gray matter of the dlPFC is present in living schizophrenic subjects,<sup>34,35</sup> and therefore it seems more reasonable to attribute changes in cell density in this area to the endogenous condition than to postmortem processing.

#### POSSIBLE CONFOUNDING FACTORS

The subjects in this study were matched for age, PMI, and TF; therefore, the morphometric abnormalities observed in the schizophrenic brains are not likely due to age, post-mortem factors related to preservation of brain tissue, or shrinkage. Although regression analysis of the 15 brains analyzed for both areas revealed a significant correlation between neuronal density and TF, analysis of covariance indicated that the elevation in neuronal density was not affected by removal of TF. The association of TF with neuronal density in area 9 seems to be due to the longer storage times and higher densities for both control and schizophrenic brains from the NIMH. Separate analysis of the HBTRC and NIMH brains revealed higher neuronal densities for schizophrenic brains from both sources relative to their source-matched controls, although the elevation was not significant for the NIMH brains. Furthermore, if shrinkage due to long storage times in fixative were responsible for the increase in neuronal packing density, elevated neuronal density would have been found in both areas since blocks of area 44 from the same brains were stored for as long or longer than those from area 9 in the 6 schizophrenic cases analyzed for both areas.

A shift in the proportionate width of layers III and V was noted in the schizophrenic brains in area 44. Because area 44 is located on the frontal operculum, probes of this area of necessity sampled curved brain surfaces. In the schizophrenic brains, sampling sites may have involved the convexity of the gyrus, where the infragranular layers tend to be expanded and the supragranular layers compressed, more often than in controls. This laminar distortion would not have any effect on measured densities in individual laminae but could have influenced overall cell density estimates for area 44. However, since layers III and V have similar densities, which were not altered by the diseased state, it is unlikely that the shift in laminar proportion masked a significant change in neuronal density across all layers.

The number of cases in which we were able to examine area 9 was limited by the necessity of eliminating several brains from the study. Both putative schizophrenic brains excluded due to insufficient medical records had relatively high neuronal densities in area 9 (ie,  $>50 \times 10^3$  neurons/mm<sup>3</sup>), and one schizophrenic brain with a secondary diagnosis of multiple sclerosis had a comparably high density in area 9 as well. In contrast, neuronal density for area 9 in the excluded schizoaffective brain was close to the control mean. This observation is consistent with the results of our original analysis of area 9 in which schizoaffective brains exhibited wide-ranging neuronal densities with some having normal or even below normal densities.<sup>3</sup> The brain originally diagnosed as schizophrenic but ultimately assigned a diagnosis of bipolar disorder had relatively high neuronal density.

Most of the schizophrenic patients in this study had been medicated with antipsychotic drugs. One case had a chlorpromazine equivalent of zero, indicating that this subject was free of neuroleptic agents at the time of death. Densities in this neuroleptic-free schizophrenic brain were similar to the other neuroleptic-treated brains. Moreover, our recent morphometric analysis of the cortex in

rhesus monkeys following long-term administration of antipsychotic drugs indicated that neuronal density is not altered by antipsychotic treatment for a period of 6 months.<sup>29</sup> Therefore, the changes in neuronal density observed in the prefrontal cortex of this cohort of patients are unlikely to be caused by medication.

One schizophrenic patient was assigned a secondary diagnosis of alcohol abuse; 2 others had a history of alcohol use, and 1 of these occasionally used illicit drugs (Table 2). However, the neuronal densities in these subjects were not different from other schizophrenic patients in the study. Moreover, 3 control cases also had a history of significant daily consumption of alcohol, although they were not diagnosed as having alcoholism (Table 2), again indicating that the alterations in cellular packing density were not alcohol related. Comparative analysis of alcoholic and schizophrenic patients with magnetic resonance imaging has indicated that alcoholism is associated with reductions in both gray and white matter volumes, whereas schizophrenic patients show selective gray matter deficits.<sup>35</sup> Likewise, 2 control cases with normal neuronal density had a history of drug abuse (Table 2), indicating that elevated cell density is not associated with drug intake.

#### REGIONAL SPECIFICITY IN THE NEUROPATHOLOGIC SUBSTRATE OF SCHIZOPHRENIA: PROMINENCE OF THE dlPFC

Previous morphometric analyses<sup>3,4</sup> from our laboratory have consistently revealed increases in neuronal density in prefrontal areas 9 and 46 in schizophrenic brains. A similar trend of increased neuronal density and decreased cortical volume has been observed in the cortex as a whole and in frontal, parietal, and temporal lobes.<sup>36</sup> However, the reduced neuropil deficit may not extend to ventrolateral regions of the prefrontal cortex. Previous studies of the orbitofrontal cortex in schizophrenic patients have uncovered subtle, laminar-specific reductions in neuronal density. Decreased density of small neurons in layer II, in conjunction with an increase in pyramidal cell density in layer V, has been observed in area 10,<sup>37</sup> whereas reduced neuronal density in layer I has been reported in area 47.<sup>38</sup> The present study, which shows that neuronal density is unaltered in area 44, adds to the literature suggesting that neuronal density is not markedly abnormal in ventral regions of frontal cortex of schizophrenic patients. Indeed, these regionally diverse changes in neuronal density in dorsal and ventral frontal areas may account for the lack of significant changes in neuronal density when the prefrontal cortex or frontal lobes are analyzed as a whole.<sup>36,39</sup>

The finding of heterogeneous pathologic findings in the cortex fits well with magnetic imaging data on human schizophrenic patients, indicating that gray matter volume reduction is not uniform across the cerebral mantle. Although global loss of cortical gray matter is well documented, a more pronounced deficit in the frontal lobe has been described in first-episode patients.<sup>40-42</sup> Heterogeneity even within the frontal lobe has been described. For example, volume is reduced in schizophrenic patients in conjunction with a smaller decrease in the "frontal" region, corresponding to motor and premotor regions.<sup>34</sup> Similarly, a selective reduction of cortical volume has been re-

ported in heteromodal association cortices, including prefrontal, parietal, and temporal higher-order association cortices.<sup>43</sup> Moreover, analysis of *N*-acetyl-aspartate concentrations as measured with magnetic resonance spectroscopy is selectively decreased in the dlPFC in schizophrenia patients, lending further support for decreased structural integrity of this cortical region.<sup>44</sup>

#### MULTIPLE COMPONENTS OF THE VERBAL DEFICIT IN SCHIZOPHRENIA

New evidence from functional magnetic resonance imaging analysis in normal human subjects has implicated a much wider expanse of frontal cortex in verbal processing than the language area originally described by Broca.<sup>45-48</sup> For example, patients with frontal lobe lesions limited to area 44 exhibit a classic Broca's area syndrome with disturbances of syntax, whereas more anterior and dorsal cortical lesions in areas 45, 46, and 9 are associated with story incoherence.<sup>49</sup> A recent functional magnetic resonance imaging study<sup>50</sup> has shown a further dissociation of activity in areas 44 and 45 during a verbal working memory task, thus indicating that the inferior frontal gyrus is comprised of multiple functionally distinct subregions. Because schizophrenic patients exhibit many forms of verbal abnormalities, ranging from deficits in phonemic fluency and semantic organization to looseness of associations, verbal working memory deficits, and thought disorder,<sup>23-26,51,52</sup> the abnormalities in schizophrenic language function are likely to involve areas of the prefrontal cortex beyond Broca's area. Although involvement of Broca's area in the pathophysiologic characteristics of schizophrenia is supported by functional magnetic resonance imaging studies in schizophrenic patients that show a deficit in activation of the left inferior frontal gyrus during a word serial position task,<sup>53</sup> schizophrenic patients show deficits in the dorsolateral cortex with intact activation of the inferior frontal cortex on tasks that involve higher-order language function such as memory for contextual information.<sup>54</sup> Findings in the present study suggest that deficits in syntax and sentence structure are not associated with cytoarchitectonic abnormalities comparable to those observed in the dlPFC and reaffirm the prominence of dysfunction of the dlPFC in mediating complex cognitive function in schizophrenia.<sup>12-15</sup>

*Submitted for publication June 8, 2001; final revision received December 5, 2001; accepted January 22, 2002.*

*This work was supported by grant 44866 from the Center for Neuroscience of Mental Disorders, NIMH, Rockville, Md (Dr Goldman-Rakic), grant RO1 MH59329 from the NIMH (Dr Selemon), and a grant from the Stanley Foundation, Bethesda, Md (Dr Selemon).*

*This study was presented at the 29th Annual Meeting of the Society for Neuroscience, Miami Beach, Fla, October 25, 1999.*

*We thank HBTRC (Public Health Service grant MH/NS 31862) for provision and diagnosis of the HBTRC brains. We also thank Ladislav Mrzljak, MD, PhD, Department of Neuroscience, AstraZeneca, Wilmington, Del, for dissection and cytoarchitectonic identification of area 44, and Ian Paul, PhD, University of Mississippi, for statistical consultation. We also recognize the excellent technical assistance of Anita Begovic,*



MD, and JoAnn Coburn, BS, and thank Douglas Gelowitz, PhD, for help in preparation of the figures.

Corresponding author and reprints: Lynn D. Selemon, PhD, Department of Neurobiology, Yale University School of Medicine, 333 Cedar St, Room C-303 SHM, New Haven, CT 06510 (ldselemon@aol.com).

## REFERENCES

- McCarley RW, Wible CG, Frumin M, Hirayasu Y, Levitt JJ, Fischer IA, Shenton ME. MRI anatomy of schizophrenia. *Biol Psychiatry*. 1999;45:1099-1119.
- Selemon LD. Regionally diverse pathology in schizophrenia: clues to the etiology of the disease. *Schizophr Bull*. 2001;27:349-377.
- Selemon LD, Rajkowska G, Goldman-Rakic PS. Abnormally high neuronal density in the schizophrenic cortex: a morphometric analysis of prefrontal area 9 and occipital area 17. *Arch Gen Psychiatry*. 1995;52:805-818.
- Selemon LD, Rajkowska G, Goldman-Rakic PS. Elevated neuronal density in prefrontal area 46 in brains from schizophrenic patients: application of a 3-dimensional, stereologic counting method. *J Comp Neurol*. 1998;392:402-412.
- Selemon LD, Goldman-Rakic PS. The reduced neuropil hypothesis: a circuit based model of schizophrenia. *Biol Psychiatry*. 1999;45:17-25.
- Perrone-Bizzozero NI, Sower AC, Bird ED, Benowitz LI, Ivins KJ, Neve RL. Levels of growth-associated protein GAP-43 are selectively increased in association cortices in schizophrenia. *Proc Natl Acad Sci U S A*. 1996;93:14182-14187.
- Garey LJ, Ong WY, Patel TS, Kannai M, Davis A, Mortimer AM, Barnes TRE, Hirsh SR. Reduced dendritic spine density on cerebral cortical pyramidal neurons in schizophrenia. *J Neurol Neurosurg Psychiatry*. 1998;65:446-453.
- Glantz LA, Lewis DA. Reduction of synaptophysin immunoreactivity in the prefrontal cortex of subjects with schizophrenia. *Arch Gen Psychiatry*. 1997;54:943-952.
- Glantz LA, Lewis DA. Decreased dendritic spine density on prefrontal cortical pyramidal neurons in schizophrenia. *Arch Gen Psychiatry*. 2000;57:65-73.
- Woo T-U, Whitehead RE, Melchitzky DS, Lewis DA. A subclass of prefrontal-aminobutyric acid axon terminals are selectively altered in schizophrenia. *Proc Natl Acad Sci U S A*. 1998;95:5341-5346.
- Akil M, Pierri JN, Whitehead RE, Edgar CL, Mohila C, Sampson AR, Lewis DA. Lamina-specific alterations in the dopamine innervation of the prefrontal cortex in schizophrenic subjects. *Am J Psychiatry*. 1999;156:1580-1589.
- Goldman-Rakic PS. The physiological approach: functional architecture of working memory and disordered cognition in schizophrenia. *Biol Psychiatry*. 1999;46:650-651.
- Goldman-Rakic PS. Psychopathology and neuropathology of prefrontal cortex in schizophrenia. In: Fog R, Gerlach J, Hemmingsen R, eds. *Schizophrenia*. Copenhagen, Denmark: Munksgaard; 1995:126-136.
- Goldman-Rakic PS. Prefrontal cortical dysfunction in schizophrenia: the relevance of working memory. In: Carroll BJ, Barrett JE, eds. *Psychopathology and the Brain*. New York, NY: Raven Press; 1991:1-23.
- Goldman-Rakic PS, Selemon LD. Functional and anatomical aspects of prefrontal pathology in schizophrenia. *Schizophr Bull*. 1997;23:437-458.
- Holzman PS. Eye movements and the search for the essence of schizophrenia. *Brain Res Rev*. 2000;31:350-356.
- Weinberger DR, Berman KF, Illowsky BP. Physiologic dysfunction of dorsolateral prefrontal cortex in schizophrenia. I: regional cerebral blood flow (rCBF) evidence. *Arch Gen Psychiatry*. 1986;43:114-124.
- Buchsbaum MS, Nuechterlein KH, Haier RJ, Wu J, Sicotte N, Hazlett E, Asarnow R, Potkin S, Guich S. Glucose metabolic rate in normals and schizophrenics during the Continuous Performance Test assessed by positron emission tomography. *Br J Psychiatry*. 1990;156:216-227.
- Andreasen NC, Rezaei K, Alliger R, Swayze VW II, Flaum M, Kirchner P, Cohen G, O'Leary DS. Hypofrontality in neuroleptic-naive patients and in patients with chronic schizophrenia: assessment with xenon 133 single-photon emission computed topography and the Tower of London. *Arch Gen Psychiatry*. 1992;49:943-958.
- Andreasen NC, Paradiso S, O'Leary DS. "Cognitive dysmetria" as an integrative theory of schizophrenia: a dysfunction in cortical-subcortical-cerebellar circuitry? *Schizophr Bull*. 1998;24:203-218.
- Callicott JH, Bertolino A, Mattay VS, Langheim FJP, Duyn J, Coppola R, Goldberg TE, Weinberger DR. Physiologic dysfunction of the dorsolateral prefrontal cortex in schizophrenia revisited. *Cereb Cortex*. 2000;10:1078-1092.
- Manoach DS, Gollub RL, Benson ES, Searl MM, Goff DC, Halpern E, Saper CB, Rauch SL. Schizophrenic subjects show aberrant fMRI activation of dorsolateral prefrontal cortex and basal ganglia during working memory performance. *Biol Psychiatry*. 2000;48:99-109.
- Morice R, McNicol D. Language changes in schizophrenia: a limited replication. *Schizophr Bull*. 1986;12:239-251.
- Fraser WI, King KM, Thomas P, Kendell RE. The diagnosis of schizophrenia by language analysis. *Br J Psychiatry*. 1986;148:275-278.
- Doherty NM, Miller TN, Lewis MA. Communication disturbances in the natural speech of schizophrenic patients and non-schizophrenic parents of patients. *Acta Psychiatr Scand*. 1997;95:500-507.
- Doherty NM, Hall MJ, Gordinier SW, Cutting LP. Conceptual sequencing and disordered speech in schizophrenia. *Schizophr Bull*. 2000;26:723-735.
- Williams RW, Rakic P. Three-dimensional counting: an accurate and direct method to estimate numbers of cells in sectioned material. *J Comp Neurol*. 1988;278:344-352.
- Gundersen HJG. Stereology of arbitrary particles: a review of unbiased number and size estimators and the presentation of some new ones: in memory of William R. Thompson. *J Microsc*. 1986;143:3-45.
- Selemon LD, Lidow MS, Goldman-Rakic PS. Increased volume and glial density in primate prefrontal cortex associated with chronic antipsychotic drug exposure. *Biol Psychiatry*. 1999;46:161-172.
- Rajkowska G, Selemon LD, Goldman-Rakic PS. Neuronal and glial somal size in the prefrontal cortex: a postmortem morphometric study of schizophrenia and Huntington's disease. *Arch Gen Psychiatry*. 1998;55:215-224.
- Brodman K. *Vergleichende Lokalisationslehre der Großhirnrinde in ihren Prinzipien dargestellt auf Grund des Zellenbaues*. Leipzig, Germany: Barth JA; 1909.
- Amunts K, Schleicher A, Burgel U, Mohlberg H, Uylings HBM, Zilles K. Broca's area revisited: cytoarchitecture and intersubject variability. *J Comp Neurol*. 1999;412:310-341.
- Rajkowska G, Goldman-Rakic PS. Cytoarchitectonic definition of prefrontal areas in the normal human cortex. I: remapping of areas 9 and 46 using quantitative criteria. *Cereb Cortex*. 1995;5:307-322.
- Sullivan EV, Lim KO, Mathalon D, Marsh L, Beal M, Harris D, Hoff AL, Faustman WO, Pfefferbaum A. A profile of cortical gray matter volume deficits characteristic of schizophrenia. *Cereb Cortex*. 1998;8:117-124.
- Sullivan EV, Mathalon DH, Lim KO, Marsh L, Pfefferbaum A. Patterns of regional cortical dysmorphology distinguishing schizophrenia and chronic alcoholism. *Biol Psychiatry*. 1998;43:118-131.
- Pakkenberg B. Total nerve cell number in neocortex in chronic schizophrenic and controls estimated using optical disectors. *Biol Psychiatry*. 1993;34:768-772.
- Benes FM, McSparren J, Bird ED, SanGiovanni JP, Vincent SL. Deficits in small interneurons in prefrontal and cingulate cortices of schizophrenic and schizoaffective patients. *Arch Gen Psychiatry*. 1991;48:996-1001.
- Rajkowska G, Wei J, Miguel-Hidalgo JJ, Stockmeier CA. Glial and neuronal pathology in rostral orbitofrontal cortex in schizophrenic postmortem brain. *Schizophr Res*. 1999;36:84.
- Thune JJ, Uhlings HB, Pakkenberg B. No deficit in total number of neurons in the prefrontal cortex in schizophrenics. *J Psychiatr Res*. 2001;35:15-21.
- Nopoulos P, Torres I, Flaum M, Andreasen NC, Ehrhardt JC, Yuh WTC. Brain morphology in first-episode schizophrenia. *Am J Psychiatry*. 1995;152:1721-1723.
- Gur RE, Cowell PE, Latschaw A, Turetsky BI, Grossman RI, Arnold SE, Bilker WB, Gur RC. Reduced dorsal and orbital prefrontal gray matter volumes in schizophrenia. *Arch Gen Psychiatry*. 2000;57:761-768.
- Hirayasu Y, Tanaka S, Shenton ME, Salisbury DF, DeSantis MA, Levitt JJ, Wible C, Yurgelin-Todd D, Kikinis R, Jolesz F, McCarley RW. Prefrontal gray matter volume reduction in first episode schizophrenia. *Cereb Cortex*. 2001;11:374-381.
- Schlaepfer TE, Harris GJ, Tien AY, Peng LW, Lee S, Federman EB, Chase GA, Barta PE, Pearlson GD. Decreased regional cortical gray matter volume in schizophrenia. *Am J Psychiatry*. 1994;151:842-848.
- Bertolino A, Nawroz S, Mattay VS, Barnett AS, Duyn JH, Moonen CT, Frank JA, Tedeschi G, Weinberger DR. Regionally specific pattern of neurochemical pathology in schizophrenia as assessed by multislice proton magnetic resonance spectroscopic imaging. *Am J Psychiatry*. 1996;153:1554-1563.
- Paulesu E, Frith CD, Frackowiak RS. The neural correlates of the verbal component of working memory. *Nature*. 1993;362:342-345.
- Rueckert L, Appollonio I, Grafman J, Jezard P, Johnson R Jr, Le Bihan D, Turner R. Magnetic resonance imaging functional activation of left frontal cortex during covert word production. *J Neuroimaging*. 1994;4:67-70.
- Salmon E, Van der Linden M, Collette F, Delfiore G, Maquet P, Degueldre C, Luxen A, Franck G. Regional brain activity during working memory tasks. *Brain*. 1996;119:1617-1625.
- Hugdahl K, Lundervold A, Erslund L, Smievoll AI, Sundberg H, Barndon R, Roscher BE. Left frontal activation during a semantic categorization task: an fMRI-study. *Int J Neurosci*. 1999;99:49-58.
- Sirigu A, Cohen L, Zalla T, Pradat-Diehl P, Van Eeckhout P, Grafman J. Distinct frontal regions for processing sentence syntax and story grammar. *Cortex*. 1998;34:771-778.
- Chen JM, Fiez JA. Dissociation of verbal working memory system components using a delayed serial recall task. *Cereb Cortex*. 2001;11:1003-1014.
- Wexler BE, Stevens AA, Bowers AA, Semyak MJ, Goldman-Rakic PS. Word and tone working memory deficits in schizophrenia. *Arch Gen Psychiatry*. 1998;55:1097-1103.
- Stevens AA, Donegan NH, Anderson M, Goldman-Rakic PS, Wexler BE. Verbal processing deficits in schizophrenia. *J Abnorm Psychol*. 2000;109:461-471.
- Stevens AA, Goldman-Rakic PS, Gore JC, Fulbright RK, Wexler BE. Cortical dysfunction in schizophrenia during auditory and tone working memory demonstrated by functional magnetic resonance imaging. *Arch Gen Psychiatry*. 1998;55:1097-1103.
- Barch DM, Carter CS, Sabb FW, MacDonald A III, Noll DC, Cohen JD. Prefrontal cortex and context processing in medication naive first episode patients with schizophrenia. *Soc Neurosci Abst*. 1999;25:1289.