

Polybrominated Biphenyl Toxicosis in Rats Fed an Iodine-Deficient, Iodine-Adequate, or Iodine-Excess Diet

by S. D. Sleight,* Soesanto Mangkoewidjojo,*
B. T. Akoso,* and V. L. Sanger*

Young male Sprague-Dawley rats were fed 0, 1, 10, or 100 ppm of polybrominated biphenyls (PBB) in iodine-deficient, iodine-adequate (0.2 ppm), or iodine-excess (1000 ppm) diets. Six rats in each of the 12 groups were killed at 30 days and the remaining six in each group at 60 days. Growth rates were similar in all rats fed diets containing 0, 1, or 10 ppm PBB but were slower from 30 to 60 days in rats given 100 ppm PBB. Results of routine hematologic examinations and urinalyses were essentially normal. Although liver weights were substantially increased by PBB, the smallest increases were in rats fed an iodine-deficient diet. Thyroid weights were increased by iodine deficiency and by 10 and 100 ppm PBB. Electropherograms of serum proteins, serum lipoproteins, and LDH isozymes at 60 days from rats given PBB indicated hepatic alterations, but changes were least dramatic in rats fed an iodine-deficient diet plus PBB and most severe in rats fed iodine-excess diets plus PBB. Hepatic lesions were basically similar to those previously described except that bile duct proliferation was seen at 60 days only in rats fed an iodine-deficient diet and 100 ppm PBB. Histologic changes in thyroid glands were associated with iodine deficiency and with PBB. The iodine-excess diet plus 100 ppm PBB induced squamous metaplasia of respiratory bronchiolar epithelium. These results indicate interrelationships between PBB and iodine which may affect the toxicosis caused by PBB.

A wide variety of nonspecific clinical signs in Michigan livestock were associated with the ingestion of polybrominated biphenyls (PBB) (1). Since the signs reported were variable and nonspecific, questions have been raised regarding the role of infectious diseases, nutritional factors and other toxic chemicals. Some workers have suggested the possibility of a physiologic and pathologic response to competition between bromine and iodine (2). Michigan is well recognized as an iodine-deficient state, and it is necessary to supplement iodine in livestock rations. Organic iodides such as ethylenediamine dihydriodide (EDDI) are commonly used as preventatives and treatments for certain livestock diseases. Generally, EDDI does not cause adverse effects (3), but iodine toxicosis is a distinct possibility if high doses of EDDI are used for animals already being oversupplemented with

inorganic iodine. Adverse effects of EDDI were induced in an experiment with lambs (4) and were described in cattle (5). The effects were especially severe when respiratory infections were present.

The possibility of multiple toxicoses in Michigan livestock stimulated interest in this research on the combined effects of PBB and iodine. It was also of interest as to what effects iodine deficiency would have on PBB toxicosis. Rats were selected for these experiments.

This report will emphasize data relating to growth rate; routine hematologic studies and urinalyses; liver, kidney, and thyroid weights; electropherograms of serum proteins, serum lipoproteins, and LDH isozymes; and the major pathologic changes.

Materials and Methods

Young male Sprague-Dawley rats were randomly assigned into 12 groups of 12 each. They were fed 0, 1, 10, or 100 ppm PBB in iodine-deficient, iodine-adequate, or iodine-excess diets. Six rats in each

* Department of Pathology, Michigan State University, East Lansing, Michigan 48824.

group were killed at 30 days and the remaining 6 at 60 days. The basic ration was the Remington iodine-deficient diet (United States Biochemical Corp., Cleveland, Ohio). Sufficient EDDI was added to formulate the iodine-adequate (0.2 ppm) or iodine-excess (1000 ppm) diets. The source of PBB was FireMaster BP-6 (Michigan Chemical Corp., St. Louis, Michigan), which is a mixture of PBB with an average of six bromine atoms per molecule.

Feed was removed 12 hr before rats were killed and the body weights used to calculate organ to body weight ratios were obtained the morning of the day of necropsy. Rats were killed with ether and during anesthesia blood samples were obtained by cardiac puncture for hematologic examinations and for determination of values for blood urea nitrogen (BUN), serum alkaline phosphatase (SAP), and serum glutamic oxalacetic transaminase (SGOT). Urine samples were obtained at necropsy for routine urinalysis. The liver and kidneys of each rat were weighed with a top-loading balance and the thyroid glands were weighed with an analytical balance.

Samples of liver, kidney, thyroid gland, pituitary gland, brain, lung, heart, thymus, spleen, adrenal gland, stomach, small intestine, colon, pancreas, testes, urinary bladder, and skeletal muscle were fixed in 10% buffered formalin. After fixation, tissues for histologic examination were embedded in paraffin, sectioned at 6 μ m and routinely stained with hematoxylin and eosin. Special stains for fat and glycogen were used as indicated. Pieces of liver, thyroid gland, kidney, and pituitary gland were fixed in 3% glutaraldehyde for electron microscopy. After fixation, the tissues were washed in phosphate buffer, post-fixed in osmic acid, dehydrated and embedded in epoxy. Staining was with uranyl acetate and lead citrate.

At 60 days, samples of serum from 3 rats in each group were submitted to a private laboratory for electrophoresis (Special-Chem Laboratories, East Lansing, Michigan). Electropherograms for serum proteins, serum lipoproteins, and LDH isozymes were evaluated. Values for total serum protein, for the various serum protein fractions, total serum triglycerides, serum cholesterol, and serum LDH were also obtained.

Results

The only noticeable clinical sign of toxicosis was a slower rate of weight gain in rats fed diets containing 100 ppm PBB (Table 1). Weight gains were especially slow between 30 and 60 days in rats fed the iodine-deficient diet with 100 ppm PBB.

There were no significant differences in hemoglobin concentrations, packed cell volumes, erythro-

cyte counts, and total or differential leukocyte counts at 30 or 60 days. Values for BUN, SAP, and SGOT were not elevated. Results of tests of urine for specific gravity, pH, protein, glucose, ketones, bilirubin, and blood were similar in all groups.

The increases in liver weight caused by PBB were dose related and were similar in rats fed iodine-adequate or iodine-excess diets (Table 2). The pattern was somewhat different in rats fed the iodine-deficient diet. Liver size was slightly but significantly smaller ($p < 0.05$) at 30 days in rats fed an iodine-deficient diet and 1 or 100 ppm PBB than in rats fed the iodine-adequate diet and the same levels of PBB. At 60 days the liver size was significantly smaller at all levels of PBB for rats fed the iodine-deficient diet.

Thyroid size was markedly increased by 30 days in rats fed the iodine-deficient diet (Table 3). At 10 and 100 ppm PBB there were significant increases ($p < 0.05$) in thyroid size when compared to rats fed 0 ppm of PBB and the iodine-deficient diet. By 60 days the addition of 10 or 100 ppm PBB to an iodine-adequate diet and 100 ppm of PBB to the iodine-excess diet caused significant increases ($p < 0.05$) in thyroid size.

An estimation of hepatic alterations based on interpretation of electropherograms is shown in (Table 4). In the most severe change in the serum protein patterns, there was a prominent β globulin fraction with depression of α_2 haptoglobin. Severe alterations in serum lipoprotein electropherograms were typified by an especially prominent α_1 -lipoprotein fraction. In some instances the β and pre- β peaks were markedly depressed. Although the values for total serum LDH were not elevated, there was a prominent liver fraction in the severely altered electrophoretic patterns. The albumin/globulin ratios were increased in rats fed diets containing 100 ppm PBB. Serum cholesterol was also elevated in these rats.

For the most part, hepatic lesions related to PBB toxicosis were as previously described by this laboratory (6). The hepatic cells of rats fed diets containing 100 ppm PBB were swollen and vacuolated. Vacuolation appeared to be most severe in the iodine-deficient rats. Electron micrographs of hepatic cells of rats given high levels of PBB revealed a marked increase in smooth endoplasmic reticulum and large, laminated myelin bodies. At 60 days in rats fed the iodine-deficient diet and 100 ppm PBB, there was proliferation of bile ducts and fibrosis in the portal triads (Fig. 1).

Changes seen in the thyroid glands of rats fed the iodine-adequate diet and 100 ppm PBB consisted of a mild hyperplasia of the follicular epithelium and a change from the normal low cuboidal epithelium (Fig. 2) to one which had a more columnar appear-

Table 1. Weight gains in rats fed polybrominated biphenyls in iodine-deficient, iodine-adequate, or iodine-excess diets for 30 or 60 days.

| Concentration of PBB in feed, ppm | Weight gain, g ^a | | | | | |
|-----------------------------------|-----------------------------|---------|---------------------------|---------|--------------------------|---------|
| | Iodine-deficient | | Iodine-adequate (0.2 ppm) | | Iodine-excess (1000 ppm) | |
| | 30 days | 60 days | 30 days | 60 days | 30 days | 60 days |
| 0 | 107 | 170 | 103 | 170 | 89 | 163 |
| 1 | 108 | 173 | 102 | 161 | 77 | 164 |
| 10 | 108 | 178 | 94 | 154 | 81 | 141 |
| 100 | 77 | 88 | 75 | 109 | 69 | 103 |

^a Data are expressed as the mean values for total weight gained from day 0 for 6 rats in each group.

Table 2. Percentage liver weight of body weight for rats fed polybrominated biphenyls in iodine-deficient, iodine-adequate, or iodine-excess diets for 30 or 60 days.

| Concentration of PBB in feed, ppm | Liver weight/body weight, % ^a | | | | | |
|-----------------------------------|--|--------------------------|---------------------------|--------------------------|--------------------------|--------------------------|
| | Iodine-deficient | | Iodine-adequate (0.2 ppm) | | Iodine-excess (1000 ppm) | |
| | 30 days | 60 days | 30 days | 60 days | 30 days | 60 days |
| 0 | 3.29 ± 0.30 | 3.37 ± 0.30 | 3.17 ± 0.28 | 3.76 ± 0.14 | 3.26 ± 0.23 | 4.17 ± 0.31 |
| 1 | 3.07 ± 0.24 | 3.28 ± 0.36 | 3.50 ± 0.26 | 4.26 ± 0.54 | 3.31 ± 0.16 | 3.91 ± 0.58 |
| 10 ^b | 3.01 ± 0.28 ^b | 4.18 ± 0.42 ^b | 4.04 ± 0.27 ^b | 4.83 ± 0.30 ^b | 4.53 ± 0.25 ^b | 4.96 ± 0.46 ^b |
| 100 ^b | 6.79 ± 0.19 ^b | 6.37 ± 0.40 ^b | 7.81 ± 0.29 ^b | 8.14 ± 0.32 ^b | 7.63 ± 0.69 ^b | 7.71 ± 0.82 ^b |

^a Data were obtained from 6 rats in each group and are expressed as mean ± SD of the liver weight to body weight ratios × 100 (%).

^b All values for rats fed 10 or 100 ppm of PBB were significantly higher ($p < 0.05$ or greater) when compared to those fed 0 ppm of PBB.

Table 3. Thyroid gland per 100 grams of body weight for rats fed polybrominated biphenyls in iodine-deficient, iodine-adequate, or iodine-excess diets for 30 or 60 days.

| Concentration of PBB in feed, ppm | Thyroid gland, mg/100 g body weight ^a | | | | | |
|-----------------------------------|--|--------------|---------------------------|--------------------------|--------------------------|--------------------------|
| | Iodine-deficient | | Iodine-adequate (0.2 ppm) | | Iodine-excess (1000 ppm) | |
| | 30 days | 60 days | 30 days | 60 days | 30 days | 60 days |
| 0 | 24.72 ± 4.08 | 37.79 ± 6.52 | 12.49 ± 3.99 | 4.11 ± 0.47 | 5.16 ± 0.93 | 3.58 ± 0.54 |
| 1 | 26.20 ± 1.55 | 40.63 ± 7.22 | 18.38 ± 5.58 | 4.01 ± 0.71 | 6.84 ± 1.10 | 3.96 ± 0.87 |
| 10 | 34.89 ± 6.48 ^b | 40.93 ± 7.47 | 10.44 ± 2.22 | 6.11 ± 0.97 ^b | 7.60 ± 2.60 | 4.94 ± 1.42 |
| 100 | 37.42 ± 3.33 ^b | 27.21 ± 5.93 | 10.13 ± 0.49 | 8.40 ± 2.14 ^b | 7.71 ± 1.25 ^b | 8.39 ± 2.36 ^b |

^a Data were obtained from four rats in each group and are expressed as mean ± SD of the thyroid weight to body weight ratios × 100,000 (mg-%).

^b Values significantly greater ($p < 0.05$) than rats fed the same concentration of iodine in the diet and 0 ppm PBB.

Table 4. Estimation of liver alterations based on interpretation of electropherograms of serum from rats fed polybrominated biphenyls in iodine-deficient, iodine-adequate, or iodine-excess diets for 60 days.^a

| PBB, ppm | Serum protein | | | Serum lipoproteins | | | LDH isozymes | | |
|----------|------------------|-----------------|---------------|--------------------|-----------------|---------------|------------------|-----------------|---------------|
| | Iodine deficient | Iodine adequate | Iodine excess | Iodine deficient | Iodine adequate | Iodine excess | Iodine deficient | Iodine adequate | Iodine excess |
| 0 | N | N | * | N | N | * | * | N | * |
| 1 | N | N | N | N | N | * | * | * | * |
| 10 | N | * | * | N | * | ** | * | * | * |
| 100 | ** | ** | *** | ** | ** | *** | * | ** | *** |

^a N = Normal pattern; * = slight alteration indicating only minor hepatic changes; ** = moderate changes in electropherogram indicating appreciable damage; *** = severe disruption of patterns indicating loss of hepatic function.

ance (Fig. 3). The colloid stained poorly and appeared to be absent in some follicles. The thyroid glands from the iodine-deficient rats and from the rats fed the iodine-excess diet and 100 ppm PBB had a similar appearance to that shown in Figure 2.

The bronchiolar epithelium of rats fed the iodine-excess diet and 100 ppm PBB had undergone

squamous metaplasia. This change was not seen in rats fed the iodine-excess diet without PBB.

We have found no significant lesions in the kidney, brain, lung, heart, adrenal gland, stomach, small intestine, colon, pancreas, testes, urinary bladder, or skeletal muscle. Examination of thymus, spleen, and pituitary gland has not been completed.

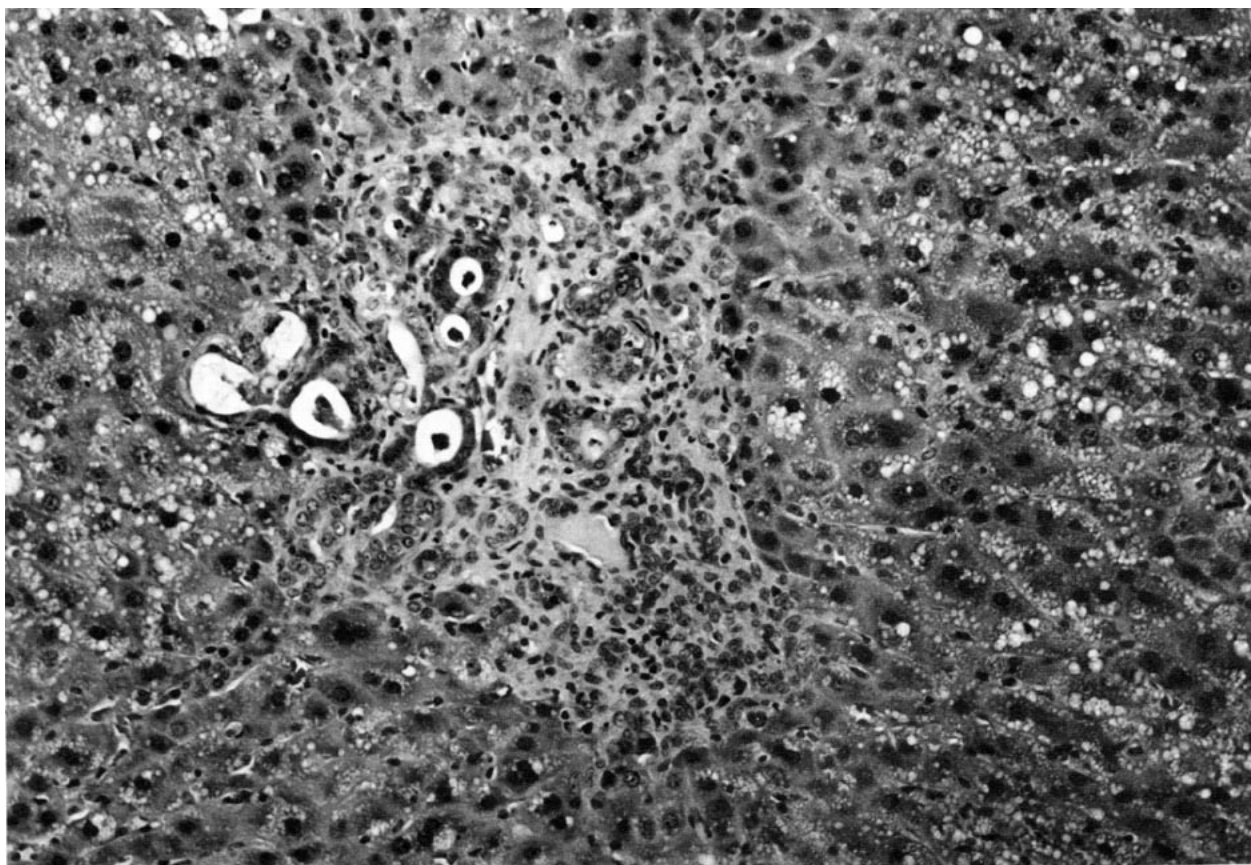


FIGURE 1. Hyperplasia of bile ducts and fibrosis of the portal triads of the liver of a rat fed an iodine-deficient diet and 100 ppm PBB for 60 days. Notice vacuolation of hepatic cells and accumulation of debris in a few dilated bile ducts. Hematoxylin-eosin, $\times 111.5$.

Discussion

The results indicate that there are interrelationships between the iodine levels in the diet and PBB. Iodine excess and PBB may affect vitamin A metabolism since the changes seen in the bronchiolar epithelium are similar to what would be expected in vitamin A deficiency.

The increases in liver weight, the growth curves and the results of hematologic examination and urinalyses were similar to those earlier reported with PBB toxicosis in rats (6). Iodine deficiency did accentuate the diminution in growth rate at 100 ppm PBB. The combination of iodine deficiency and 100 ppm PBB also resulted in the occurrence of bile duct hyperplasia and portal fibrosis. These changes have been associated previously with PBB toxicosis in a cow (7) and polychlorinated biphenyl (PCB) toxicosis in rats (8).

Iodine deficiency combined with PBB may have resulted in less stimulation of the smooth endoplasmic reticulum and thereby less induction of he-

patic drug metabolizing enzymes since liver size was significantly smaller in rats fed these diets than in those in the other groups. Results of microsomal enzyme assays and of electron microscopy should allow a better explanation of these effects. It is apparent that PBB causes histologic changes in the thyroid gland. Changes similar to what we have described were found in the thyroid gland of rats given PCB (9).

Electrophoresis of serum proteins, lipoproteins and LDH isozymes apparently provides a more sensitive indication of alterations in liver function than SGOT and SAP determinations. Iodine excess apparently had an additive effect since the most severe changes were seen in electropherograms of serum from rats fed the iodine-excess diet and 100 ppm PBB. Conversely, the least severe alterations were seen in the rats fed the iodine-deficient diets. Further investigation is needed to explain these differences.

These studies further emphasize that nutritional factors such as iodine should be considered in toxicologic evaluations.

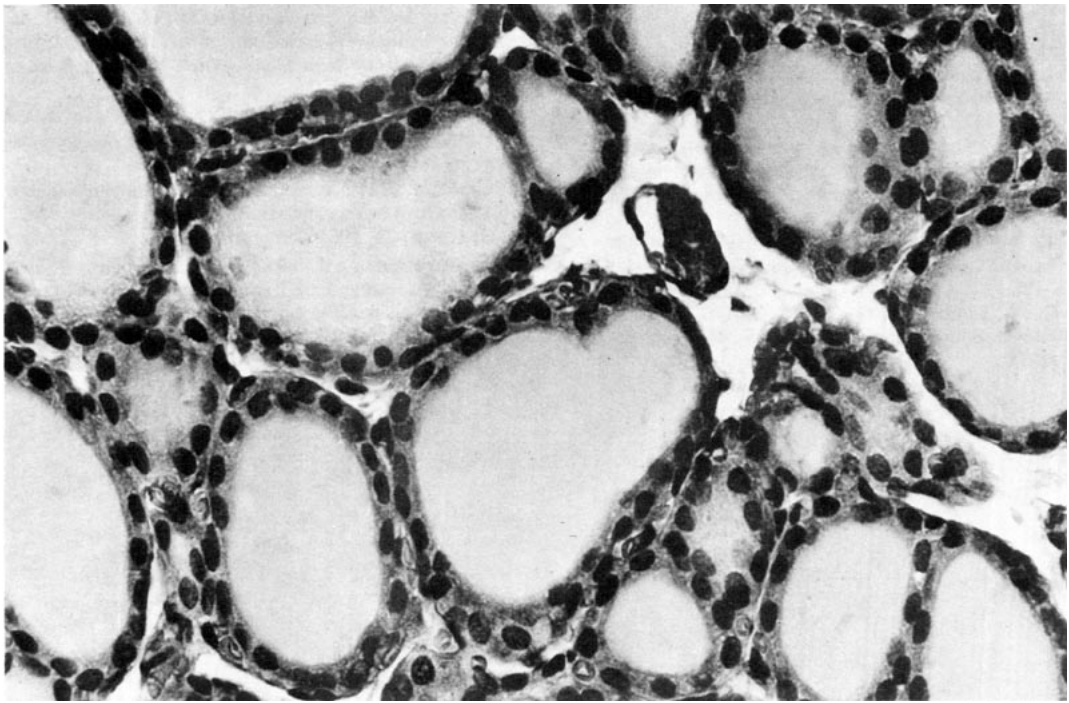


FIGURE 2. Normal thyroid gland of rat fed an iodine-adequate diet and 0 ppm PBB. Hematoxylin-eosin, $\times 281$.

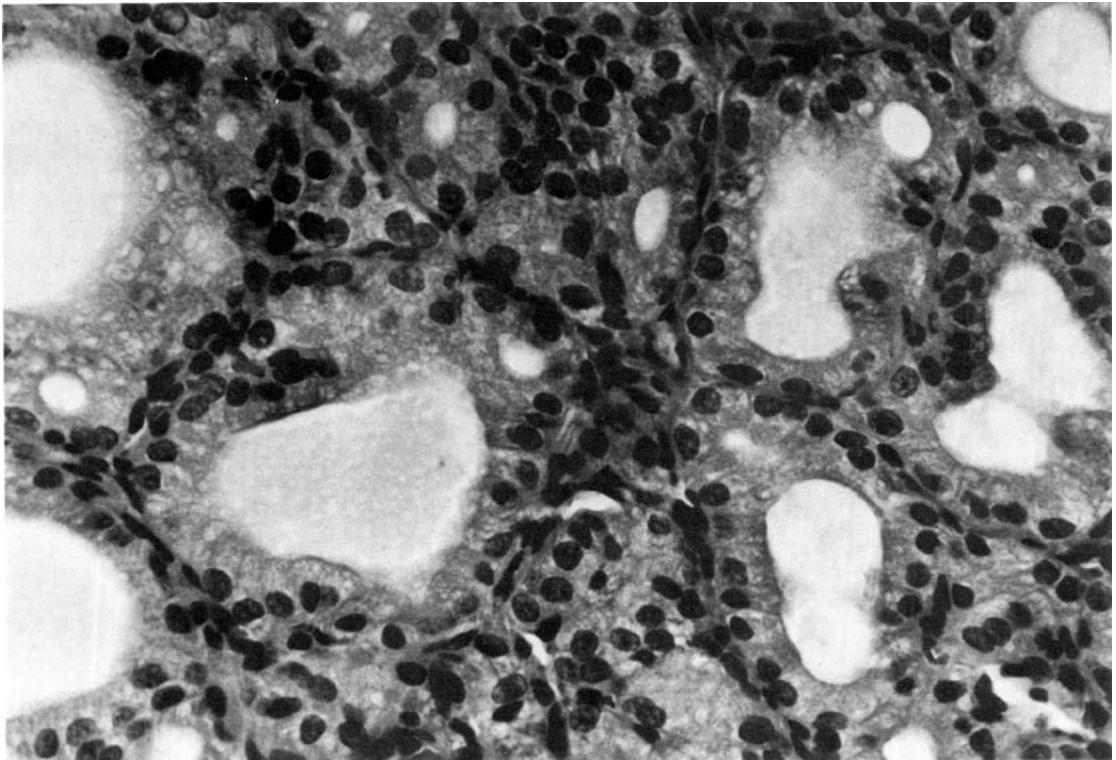


FIGURE 3. Thyroid gland of rat fed an iodine-adequate diet and 100 ppm PBB for 30 days. Notice irregular size of follicles and increased cellularity. The epithelium in columnar and colloid is sparse. Hematoxylin-eosin, $\times 281$.

REFERENCES

1. Jackson, T. F., and Halbert, F. L. A toxic syndrome associated with the feeding of polybrominated biphenyl-contaminated protein concentrate to dairy cattle. *J. Amer. Vet. Med. Assoc.* 165: 437 (1974).
2. Norris, J. M., et al. Toxicological and environmental factors involved in the selection of decabromodiphenyl oxide as a fire retardant chemical. *J. Fire Flammability/Combustion Toxicol.* 1: 52 (1974).
3. Herrick, J. B. What role for EDDI (ethylenediamine dihydriodide) in bovine respiratory disease complex? *Vet. Med./Small Anim. Clin.* 67: 480 (1972).
4. McCauley, E. H., Linn, L. J. G., and Goodrich, R. D. Experimentally induced iodine toxicosis in lambs. *Amer. J. Vet. Res.* 34: 65 (1973).
5. McCauley, E. H., and Johnson, D. W. The role of EDDI (ethylenediamine dihydriodide) in bovine respiratory disease complex. Another point of view. *Vet. Med./Small Anim. Clin.* 67: 836 (1972).
6. Sleight, S. D., and Sanger, V. L. Pathologic features of polybrominated biphenyl toxicosis in the rat and guinea pig. *J. Amer. Vet. Med. Assoc.* 169: 1231 (1976).
7. Gutenmann, W. H., and Lisk, D. J. Tissue storage and excretion in milk of polybrominated biphenyls in ruminants. *J. Agr. Food Chem.* 23: 1005 (1975).
8. Kimbrough, R. D., Linder, R. E., and Gaines, T. B. Morphological changes in livers of rats fed polychlorinated biphenyls. *Arch. Environ. Health.* 25: 354 (1972).
9. Collins, W. T., et al. Effect of polychlorinated biphenyl (PCB) on the thyroid gland of rats. *Amer. J. Pathol.* 89: 119 (1977).