

**McKenna & Cuneo, L.L.P.**

Attorneys at Law

1001147/A  
DUPLICATE

Los Angeles  
San Francisco  
San Diego

1900 K Street, N.W. ■ Washington, D.C. 20006-1108  
202-496-7500 ■ Fax: 202-496-7756  
www.mckennacuneo.com

Denver  
Dallas  
Brussels

8394 '01 AUG -8 10:12

August 1, 2001

**VIA HAND DELIVERY AND U.S. MAIL**

Larry R. Pilot  
202-496-7561  
larry\_pilot@mckennacuneo.com

Document Mail Center, ODE (HFZ-401)  
Center for Devices and Radiological Health  
Food and Drug Administration  
9200 Corporate Boulevard  
Rockville, Maryland 20850

**Re: Request for Evaluation of Automatic Class III Designation for  
CAVITAT™ Ultrasound Bone Densitometer (K011147) under  
Section 513(f)(2) of the Federal Food, Drug, and Cosmetic Act**

Dear Sir or Madam:

Pursuant to Section 513(f)(2)(A) of the Federal Food, Drug, and Cosmetic Act ("the Act"), McKenna & Cuneo, L.L.P., on behalf of CAVITAT Medical Technologies, Inc. of Aurora, Colorado, requests that the Food and Drug Administration ("FDA" or "Agency") classify the CAVITAT™ Ultrasound Bone Densitometer into class II (Special Controls); because, compliance with special controls for the indicated use is adequate to provide reasonable assurance of device safety and effectiveness. This product is indicated for the detection of areas of *ischemic bone change* (i.e., moderate to low bone density) in the maxilla (upper jaw) and mandible (lower jaw).

After reviewing the 510(k) submission (K011147) for the CAVITAT™ device, the FDA concluded in a July 3, 2001 letter that this product "is not substantially equivalent to devices marketed in interstate commerce prior to May 28, 1976, the enactment date of the Medical Device Amendments, or to any device which has been reclassified into class I (General Controls) or class II (Special Controls)." Although the CAVITAT™ device is

OIP-0344

RECEIVED  
AUG 1 3 59 PM '01  
FDA/CDRH/ODE/DWC

Document Mail Center, ODE (HFZ-401)

August 1, 2001

Page 2

intended for the same general use as another legally marketed bone densitometer,<sup>1</sup> it uses a 2.5 MHz pulsed ultrasound signal instead of X-ray energy. The CAVITAT™ device does not raise any new safety questions because the acoustical output of this device is well within the Agency's allowable limits for diagnostic ultrasound. In addition, information from a clinical study<sup>2</sup> demonstrates that the CAVITAT™ device is as least as safe and effective as other bone densitometers.

In support of this request for classification, we have incorporated by reference the entire submission (K011147) and have enclosed a complete discussion of the proposed general and/or special controls that are adequate to provide reasonable assurance of the safety and effectiveness of the CAVITAT™ device.

We have enclosed an original and two copies of this request. If you require additional information about the device or copies of the literature references, please contact either me at (202) 496-7561 or Stuart Kim at (202) 496-7534. We look forward to your reply.

Cordially,

  
Larry R. Pilot

LRP/sk

Enclosure(s)

cc: CAVITAT Medical Technologies, Inc.

---

<sup>1</sup> The predicate device cited in the 510(k) submission (K011147) is the DPX-RX Bone Densitometer (K982267).

<sup>2</sup> See Section XI and Exhibit 6 of Submission K011147.

CAVITAT Medical Technologies, Inc.

Request for Evaluation of Automatic Class III Designation for  
the CAVITAT™ Ultrasound Bone Densitometer (K011147)

The following information is being submitted in accordance with Section 513(f)(2)(A) of the Federal Food, Drug, and Cosmetic Act ("the Act"), 21 U.S.C. § 360c(b)(2)(A):

**I. Submitter's Information**

A. Address:

CAVITAT Medical Technologies, Inc.  
10691 East Bethany Drive, Suite 900  
Aurora, Colorado 80014  
Telephone: (303) 755-2688  
Facsimile: (303) 755-2699

B. Contact Persons:

Larry R. Pilot, Esq.  
Stuart Kim, Esq.  
McKenna & Cuneo, L.L.P.  
1900 K Street N.W.  
Washington, D.C. 20006-1108  
Telephone: (202) 496-7500  
Facsimile: (202) 496-7756

**II. Statement of cross-reference to the information contained in the 510(k) submission.**

This request for Evaluation of Automatic Class III Designation cross-references information contained in the 510(k) submission for the CAVITAT™ Ultrasound Bone Densitometer (K011147).

### III. Discussion of potential benefits when compared to the potential of anticipated risks when the device is used as intended.

Recognition of *ischemic bone change* (i.e., moderate to low bone density) in the lower and upper portions of the jaw is a clinical concern for licensed health care practitioners and the patients they serve. See Exhibit 1 and BRAD W. DOUGLAS D. DAMM, CARL M. ALLEN & JERRY E. BOUQUOT, ORAL AND MAXILLOFACIAL PATHOLOGY 631-632 (W.B. Saunders, 1995). Dentists, including orthodontic specialists, have used periapical and panoramic dental radiographs, the <sup>99</sup>technetium-MDP scintigraphy and Single Photon Emission Computed Tomography ("SPECT") scans, and magnetic resonance imaging ("MRI") to identify areas of *ischemic bone change* in the lower and upper portions of the jaw. However, each technology has its drawbacks because *ischemic bone change* can occur over long periods of time without overt signs. The use of periapical and panoramic dental radiographs expose patients to ionizing radiation and cannot accurately detect early *ischemic bone change* in the jaw. See STEPHEN COHEN & RICHARD C. BURNS, PATHWAYS OF THE PULP 56 (Mosby-Year Book 1976). Scintigraphy and SPECT scans are expensive and fail to recognize *ischemic bone change* in at least 30% of cases. See Jerry E. Bouquot, A new technology: Through-transmission sonography (TS) scans of the jaws; Investigation of ischemic osteonecrosis in 15 facial pain patients and 6 cadavers (unpublished manuscript). MRI scans are not suited to identify changes in the thin and irregular marrow spaces of the jaw and therefore are not particularly useful for localizing *ischemic bone change*. See *id.*

The CAVITAT™ Ultrasound Bone Densitometer – a stand-alone computerized imaging system that uses sound waves instead of ionizing radiation to generate color images of bone tissue – has the capability of detecting *ischemic bone change*. See Exhibit 2. The CAVITAT™ device does not use the standard ultrasound technique of interpreting scatter or reflected sound waves, but rather picks up residual sound waves after the sound has traveled completely through the bone. This technology is ideal for detecting *ischemic bone change* in the jaw because sound travels faster through water (or the liquefied fat in fat cells) or through moist tissue rather than dry tissue or air. The two-dimensional (2-D) and three-dimensional (3-D) images generated by the CAVITAT™ device are color-coded to distinguish the various levels of bone density: Normal bone is represented by dark green and increasingly damaged bone is represented by light

green, green/yellow, yellow (moderate loss); brown, brown/red, and red (most severe loss). See Exhibit 3.

Licensed health care practitioners would be able to use the CAVITAT™ device to help detect areas of *ischemic bone change* in the jaw, which is a present limitation of routine periapical and panoramic dental radiographs. See Exhibit 4 and Section XI of Submission K011147. The 2-D and 3-D images generated by the CAVITAT™ device represent each 1.1 cm<sup>2</sup> area exposed to the ultrasonic signals and therefore have the detail required to detect *ischemic bone change*. Early detection of areas of *ischemic bone change* is helpful for licensed health care practitioners and the patients they serve to take preventative measures, and the CAVITAT device provides a safe and effective method to detect *ischemic bone change*.

#### **IV. Discussion of the proposed general and/or special controls to ensure reasonable assurance of the safety and effectiveness of the device.**

The proposed controls to ensure reasonable assurance of the safety and effectiveness of the CAVITAT™ device include:

- ALL controls presently applied to class I devices under the Act, including the submission of a pre-market notification to the FDA
- Compliance with the limits for diagnostic ultrasound allowed by the FDA (*see* Section XI and Exhibit 5 of Submission K011147; *see also* FDA/CDRH Guidance Document, "Information for Manufacturers Seeking Marketing Clearance of Diagnostic Ultrasound Systems and Transducers"(1997) and ACOUSTIC OUTPUT MEASUREMENT STANDARD FOR DIAGNOSTIC ULTRASOUND EQUIPMENT (American Institute of Ultrasound Medicine 1997) and R C Preston, D R Bacon & R A Smith, *Calibration of medical ultrasonic equipment*, 35 IEEE TRANS. UFFC 110-121 (1988)
- Validation and verification of the CAVITAT™ device software (*see* Section XIV of Submission K011147)
- A requirement for a timed cut-off in the event the power level exceeds the acceptable calibrated level for more than five (5) seconds

V. **Clinical or pre-clinical data not included in the 510(k) submission.**

The following exhibits are case studies of ischemic bone change using the CAVITAT™ device.

- Exhibit 5 is a CAVITAT scan of a tuberosity in a 54-year-old male. The tuberosity, the bone behind the upper wisdom teeth, is “hollow” and shows *ischemic bone change*.
- Exhibit 6 is a CAVITAT scan of the left posterior mandible in a 50-year-old female. The left mandibular molar region shows *ischemic bone change*.
- Exhibit 7 is a CAVITAT scan of the maxillary right tuberosity and the third molar region in a 49-year-old female. The patient suffered from right mid-face pain. The maxillary right tuberosity and the third molar region show *ischemic bone change*.
- Exhibit 8 is a CAVITAT scan of the mandibular left third molar area of a 50-year-old female. The patient suffered from chronic jaw pain and “toothache” for two years. Only the mandibular left third molar area shows some *ischemic bone change*. The rest of the bone appears normal.

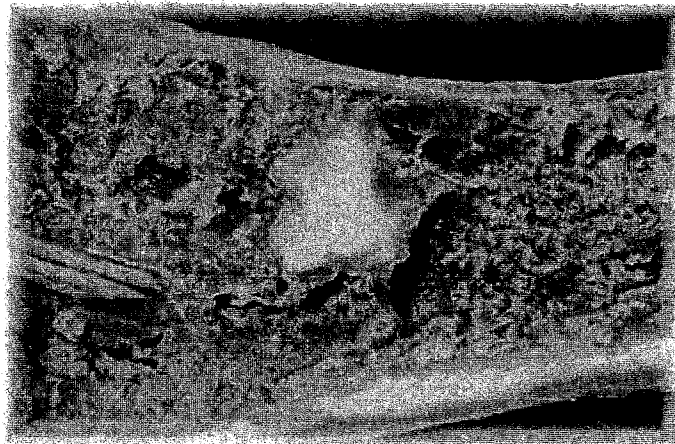
*Robert J. Jones SK*

---

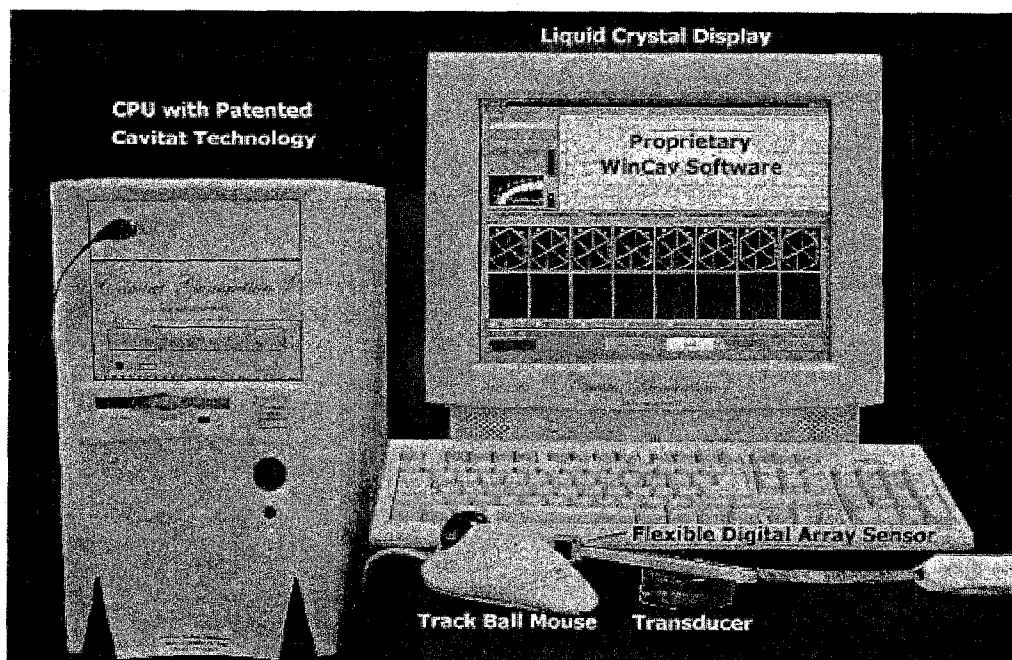
Robert J. Jones, President  
CAVITAT Medical Technologies, Inc.

August 1, 2001


**Exhibit 1.** Photograph of a mandible with severe ischemic bone change. Note the presence of the white irregular *bone island*. (Photograph courtesy of Dr. Jerry Bouquot, D.D.S., M.S.D.)




**Exhibit 2.** The CAVITAT Ultrasound Bone Densitometer.



**Exhibit 3.** CAVITAT scan of the jaw in a 50-year-old female. Scans of the left posterior maxilla and the right anterior mandible show normal bone, but scans of the right posterior mandible show severe ischemic bone change. (Scan courtesy of Dr. Jerry Bouquot, D.D.S., M.S.D.)

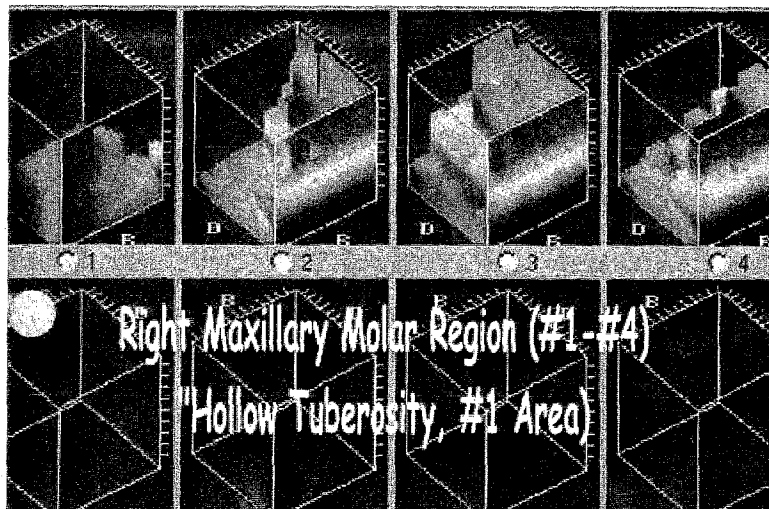

**Exhibit 4.** Comparison of a panoramic radiograph and a CAVITAT scan of a jaw in an unidentified patient. The radiograph shows the jaw has a normal appearance, but the scan shows significant *ischemic bone change*. (Photograph and scan courtesy of Dr. Wesley Shankland, D.D.S., Ph.D.)

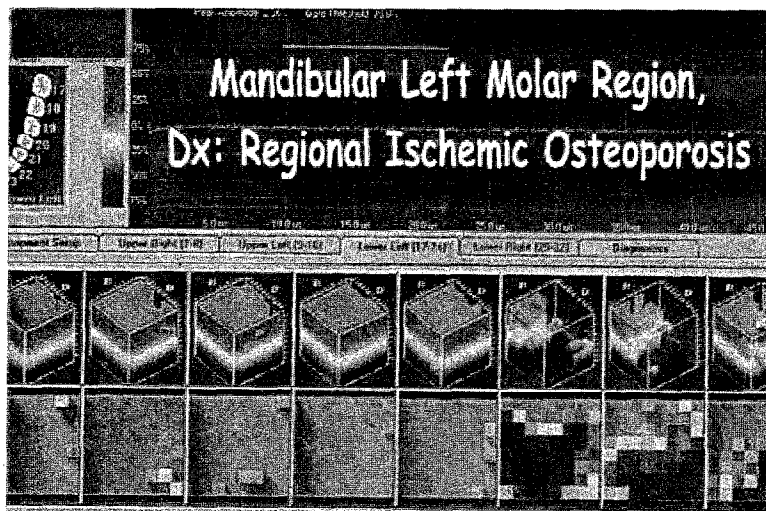




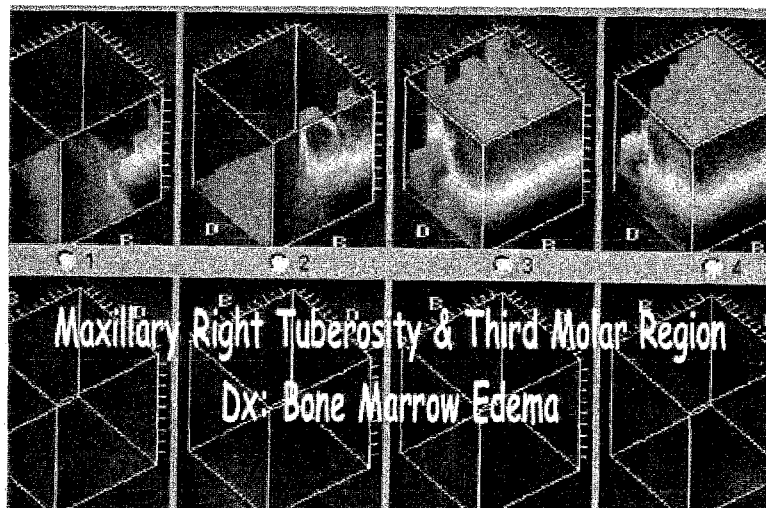
**Exhibit 5.** CAVITAT scan of the tuberosity in a 54-year-old male. The tuberosity, the bone behind the upper wisdom teeth, is “hollow” and shows *ischemic bone change*. (Scan courtesy of Dr. Jerry Bouquot, D.D.S., M.S.D.)




**Exhibit 6.** CAVITAT scan of the left posterior mandible in a 50-year-old female. The left posterior mandible shows extensive ischemic bone change. (Scan courtesy of Dr. Jerry Bouquot, D.D.S., M.S.D.)



**Exhibit 7.** CAVITAT scan of the maxillary right tuberosity and third molar region in a 49-year-old female. The maxillary right tuberosity and the third molar region show extensive *ischemic bone change*. (Scan courtesy of Dr. Jerry Bouquot, D.D.S., M.S.D.)



**Exhibit 8.** CAVITAT scan of the mandibular left third molar area of a 50-year-old female. The mandibular left third molar area shows some ischemic bone change, while the rest of the bone appears normal. (Scan courtesy of Dr. Jerry Bouquot, D.D.S., M.S.D.)



ROUTING AND TRANSMITTAL SLIP

Date

8/6

TO: (Name, office symbol, room number, building, Agency/ Post)	Initials	Date
1. Dockets Management Branch		
2. HFA-305		
3.		
4.		
5.		

Action	<input checked="" type="checkbox"/> File	Note and Return
Approval	For Clearance	Per Conversation
As Requested	For Correction	Prepare Reply
Circulate	For Your Information	See Me
Comment	Investigate	Signature
Coordination	Justify	

REMARKS

Please file as a new "de novo" classification Petition.

DO NOT use this form as a RECORD of approvals, concurrences, disposals, clearances, and similar actions

FROM: (Name, org. symbol, Agency/ Post)	Room No. - Bldg.
HF2-215	240W/1350
Joseph Sheehan	Phone No.
	827-2974

5041-103

OPTIONAL FORM 41 (Rev. 1-94)  
 Prescribed by GSA  
 UNICOR FPI - SST