

5. Galgiani JN, Ampel NM, Catanzaro A, Johnson RH, Stevens DA, Williams PL. Practice guideline for the treatment of coccidioidomycosis. *Clin Infect Dis*. 2000;30:658–61.

Address for correspondence: Po-Ren Hsueh, Departments of Laboratory Medicine and Internal Medicine, National Taiwan University Hospital, National Taiwan University College of Medicine, 7 Chung-Shan South Rd, Taipei, Taiwan; fax: 886-2-23224263; email: hsporen@ha.mc.ntu.edu.tw

Kytococcus schroeteri Endocarditis

To the Editor: Becker et al. recently reported the probable implication of *Kytococcus schroeteri* in a case of acute prosthetic valve endocarditis, on the basis of its recovery from blood cultures drawn at the time of infection (1). *K. schroeteri* was only characterized on that occasion and is a new micrococcal species resistant to penicillins (2). Here, we report the isolation of this organism from prosthetic valve vegetations in a patient who had undergone aortic valve replacement 3 years earlier. The 73-year-old man was admitted with fever (38.8°C) and shortness of breath, which had both increased gradually over the previous 2 months. He had no recent history of intravenous drug administration or catheterization. Laboratory findings showed a leukocyte count of $12 \times 10^9/L$ (90% neutrophils) and a raised C-reactive protein level. Transesophageal echocardiogram revealed several small vegetations on the Carpentier-Edwards aortic bioprosthesis and a voluminous perivalvular abscess. Four sets of blood cultures were drawn before antimicrobial therapy was initiated.

Intravenous vancomycin (2 g twice a day) and gentamicin (240 mg/d) were started empirically. The prosthetic material was replaced promptly and the abscess was debrided extensively. Vegetations from the resected material showed numerous polymorphonuclear neutrophils and gram-positive cocci on microscopic examination. Oral rifampicin (600 mg twice a day) was added to the initial regimen.

The postoperative course was uneventful except for cutaneous intolerance to vancomycin, which was replaced with teicoplanin. The physical condition of the patient improved steadily. Gentamicin and rifampicin were discontinued after 3 weeks. Eight months after completion of the 6-week treatment, the patient had no clinical or biologic evidence of infection, although moderate aortic incompetence persisted.

All blood cultures drawn on admission grew gram-positive cocci

after 72 hours and subcultures on Trypticase soy agar yielded convex, muddy-yellow colonies of heterogeneous sizes. The vegetations, pus samples of the abscess, and prosthetic valve cultures grew the same type of colonies. All isolates displayed identical biotype and antimicrobial susceptibility and were considered as a single strain. The causative organism (designated ROG140) was initially identified as *Micrococcus* sp. based on the morphologic features, resistance to nitrofurantoin, and inability to grow anaerobically. Assignment to the genus *Kytococcus* was suggested by the arginine dihydrolase activity and resistance to oxacillin, 2 characteristics that are not shared by other micrococci (3).

The definitive *K. schroeteri* identification was provided by analysis of the fatty acid content, which was similar to that of the type strain (2), and sequencing of the 16S rRNA genes.

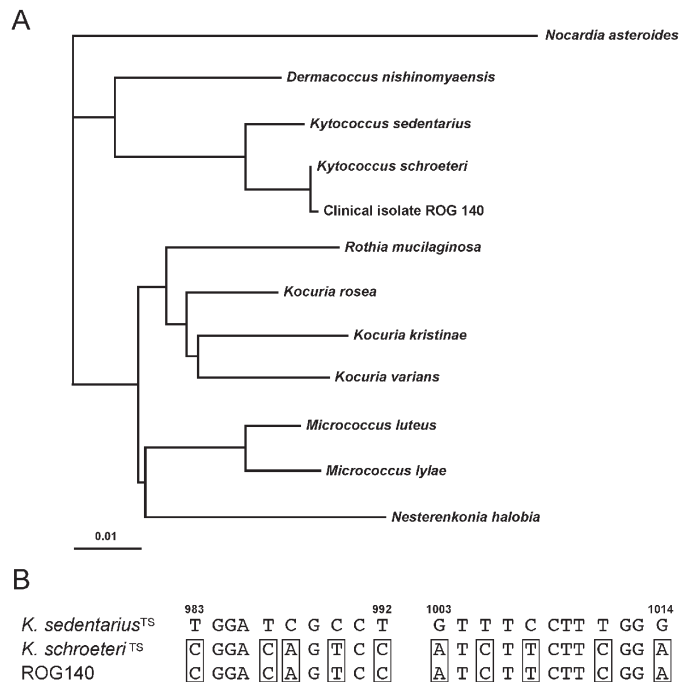


Figure. (A) Phylogenetic tree showing relationships among 16S rDNA sequences of clinical isolate ROG140 and type strains of members of the former *Micrococcus* genus. *Nocardia asteroides* was included as an out-group organism. The scale bar represents 1% differences in nucleotide sequences. (B) Sequence alignment of 16S rDNA nucleotides 983–992 and 1003–1014 of *Kytococcus* sp. type strains (TS) and clinical isolate ROG140. *K. schroeteri* molecular signatures are boxed. Nucleotide numbering refers to the sequence of the 16S rDNA of *E. coli*.

We sequenced a 1,012-bp fragment encompassing the first two thirds of the 16S rDNA of ROG140 (accession no. AY692224). The sequence was compared with those of type strains of all members of the former genus *Micrococcus*, and a phylogenetic tree was deduced by the neighbor-joining method (Figure). The sequences of ROG140 and the *K. schroeteri* type strain only differ by an A-to-G substitution at position 747 (*E. coli* numbering). Among the 21 nucleotide differences between the sequences of *K. schroeteri* and the closely related species *K. sedentarius*, 10 are located on a 30-base stretch and constitute a convenient *K. schroeteri* signature (Figure).

Antimicrobial susceptibility testing performed with the disk diffusion method and Etests (AB Biodisk, Solna, Sweden) indicated that the isolate was resistant to penicillins, cephalosporins, kanamycin, tobramycin, erythromycin, clindamycin, sulfonamides, and fusidic acid, but susceptible to imipenem (MIC, 0.25 µg/mL), gentamicin (MIC, 1 µg/mL), trimethoprim (MIC, 0.25 µg/mL), tetracycline (MIC, 0.12 µg/mL), linezolid (MIC, 0.25 µg/mL), vancomycin (MIC, 0.125 µg/mL), teicoplanin (MIC, 0.06 µg/mL), and rifampicin (MIC, <0.002 µg/mL). Unlike the original isolate reported by Becker et al. (1), isolate ROG140 was resistant to ofloxacin and ciprofloxacin (MICs, 8 µg/mL). Conversely, moxifloxacin displayed excellent in vitro activity (MIC, 0.05 µg/mL). As moxifloxacin was more rapidly microbicidal than vancomycin in an animal model of *Staphylococcus aureus* prosthetic valve endocarditis (4), it might present a potential advantage against infections caused by *K. schroeteri*, especially when the oral route is favored.

The natural habitat of *K. schroeteri* remains unknown. The only isolates of *K. schroeteri* identified so far originated from blood or cardiac material, although *Kytococcus* literally means

“a coccus from the skin.” Our attempts to recover *K. schroeteri* from the mouth, nose, or skin of our patient were unsuccessful. In a recent study, Szczerba et al. were able to isolate most micrococcal species, including *K. sedentarius* but not *K. schroeteri*, from human skin and mucosa (5). However, at that time the authors may not have been aware of this newly described species. The mode of contamination also remains unclear. In the original description (1), *K. schroeteri* endocarditis had developed in the patient <3 months after she underwent cardiac surgery, which suggested perioperative contamination. Here, we describe a late onset, subacute infection 3 years after surgery, which is more likely to have been caused by hematogenous spread.

Although *Micrococcus*-like organisms cause endocarditis infrequently (6), the description of 2 independent infections due to a new species in a short period is intriguing and suggests a specific pathogenicity, at least on prosthetic heart devices. By demonstrating the presence of the bacteria in the infected site, this report establishes *K. schroeteri* as a genuine pathogen in this clinical setting and should prompt further investigations to identify its natural habitat and virulence determinants. At present, commercial systems are not able to identify *K. schroeteri*. However, gram-positive cocci that are strictly aerobic, oxacillin-resistant, and arginine dihydrolase-positive should be recognized as potential *Kytococcus* species and taken into account when endocarditis is suspected.

**Cécile Le Brun,* Julien Bouet,*
Philippe Gautier,* Jean-Loup Avril,*
and Olivier Gaillot***

*Centre Hospitalier Universitaire de
Rennes, Rennes, France

References

1. Becker K, Wüllenweber J, Odenthal HJ, Moeller M, Schumann P, Peters G, et al. Prosthetic valve endocarditis due to

Kytococcus schroeteri. Emerg Infect Dis 2003;9:1493-4.

2. Becker K, Schumann P, Wüllenweber J, Schulte M, Weil HP, Stackebrandt E, et al. *Kytococcus schroeteri* sp. nov., a novel gram-positive actinobacterium isolated from a human clinical source. Int J Syst Evol Microbiol 2002;52:1609-14.
3. Stackebrandt E, Koch C, Gvozdiak O, Schumann P. Taxonomic dissection of the genus *Micrococcus*: *Kocuria* gen. nov., *Nesterenkonina* gen. nov., *Kytococcus* gen. nov., *Dermacoccus* gen. nov., and *Micrococcus* Cohn 1872 gen. emend. Int J Syst Bacteriol 1995;45:682-92.
4. Entenza JM, Que YA, Vouillamoz J, Glauser MP, Moreillon P. Efficacies of moxifloxacin, ciprofloxacin, and vancomycin against experimental endocarditis due to methicillin-resistant *Staphylococcus aureus* expressing various degrees of ciprofloxacin resistance. Antimicrob Agents Chemother 2001;45:3076-83.
5. Szczerba I, Krzeminski Z. Occurrence and number of bacteria from the *Micrococcus*, *Kocuria*, *Nesterenkonina*, *Kytococcus* and *Dermacoccus* genera on skin and mucous membranes in humans. Med Dosw Mikrobiol 2002;55:67-74.
6. Seifert H, Kaltheuner M, Perdreaux-Remington F. *Micrococcus luteus* endocarditis: case report and review of the literature. Zentralbl Bakteriol 1995;282:431-5.

Address for correspondence: Olivier Gaillot, Laboratoire de Bactériologie-Virologie, Faculté de Médecine-Université de Rennes 1, 35033 Rennes, France; fax: + 33 2 99 28 41 59; email: Olivier.Gaillot@univ-rennes1.fr

Viral Gastroenteritis in Mongolian Infants

To the Editor: Viral agents of gastroenteritis affect millions of persons of all ages worldwide (1). The major agents include rotavirus, norovirus, sapovirus, astrovirus, and enteric adenovirus. Rotavirus is the most frequent cause of acute sporadic childhood gastroenteritis (1), whereas norovirus infects both adults and children and is mainly associated with