

(73%) during December 2003 to November 2004, to 23 of 65 (35%) during December 2004 to July 2005 ($p < 0.0001$).

Although reports of H5N1 family clusters slightly increased, the increase was not statistically significant. Nevertheless, we believe any cluster of cases is of great concern and should be promptly and thoroughly investigated because it might be the first indication of viral mutations resulting in more efficient person-to-person spread. Family clustering does not necessarily indicate person-to-person transmission, as it may also result from common household exposures to the same H5N1-infected poultry or from other exposures, such as to uncooked poultry products.

The decrease in proportion of deaths during 2005 is another epidemiologic change that should be monitored closely because it may reflect viral adaptation to the human host. Surveillance for human cases of avian influenza has been intensified in recent months, perhaps resulting in the identification of less severe cases. Alternatively, more widespread laboratory testing may be associated with false-positive results. No evidence to date shows genetic reassortment between H5N1 and human influenza A viruses (7). Viruses isolated from case-patients need to be immediately sequenced and characterized in relation to previously circulating viruses to see whether they are evolving.

Recent modeling studies suggest that containing a pandemic at its source may be possible because emergent pandemic viruses may be less transmissible than commonly assumed (8), and antiviral treatment and chemoprophylaxis may slow the spread (9). Although the logistics of an attempt to contain the beginning of a potential influenza pandemic are formidable, we believe it is not beyond the capability of the modern global public health system. As WHO (10) has called for,

countries should intensify their pandemic preparedness plans and strengthen international collaborations.

Sonja J. Olsen,*

Kumnuan Ungchusak,†

Ly Sovann,‡ Timothy M. Uyeki,§

Scott F. Dowell,* Nancy J. Cox,§

William Aldis,¶ and Supamit

Chunsuttiwat†

*International Emerging Infections Program, Nonthaburi, Thailand; †Ministry of Public Health, Nonthaburi, Thailand; ‡Ministry of Health, Phnom Penh, Cambodia; §Centers for Disease Control and Prevention, Atlanta, Georgia, USA; and ¶World Health Organization, Nonthaburi, Thailand

References

- Hien TT, de Jong M, Farrar J. Avian influenza—a challenge to global health care structures. *N Engl J Med*. 2004;351: 2363–5.
- Centers for Disease Control and Prevention. Cases of influenza A (H5N1)—Thailand, 2004. *MMWR Morb Mortal Wkly Rep*. 2004;53:100–3.
- Chokephaibulkit K, Uiprasertkul M, Puthavathana P, Chearskul P, Auewarakul P, Dowell SF, et al. A child with avian influenza A (H5N1) infection. *Pediatr Infect Dis J*. 2005;24:162–6.
- Chotpitayasonondh T, Ungchusak K, Hansaoworakul W, Chunsuttiwat S, Sawanpanyalert P, Kijphati R, et al. Human disease from influenza A (H5N1), Thailand, 2004. *Emerg Infect Dis*. 2005;11:201–9.
- Ungchusak K, Auewarakul P, Dowell SF, Kitphati R, Auwanit W, Puthavathana P, et al. Probable person-to-person transmission of avian influenza A (H5N1). *N Engl J Med*. 2005;352:333–40.
- World Health Organization. Cumulative number of confirmed human cases of avian influenza A/(H5N1) reported to WHO. Vol. 2005. Geneva: The Organization; 2005. [cited 2005 Sep 22]. Available from http://www.who.int/csr/disease/avian_influenza/country/cases_table_2005_07_27/en/index.html
- World Health Organization. Evolution of H5N1 avian influenza viruses in Asia. *Emerg Infect Dis*. 2005;11:1515–21.
- Mills CE, Robins JM, Lipsitch M. Transmissibility of 1918 pandemic influenza. *Nature*. 2004;432:904–6.
- Longini IM Jr, Nizam A, Xu S, Ungchusak K, Hansaoworakul W, Cummings DA, et al. Containing pandemic influenza at the source. *Science*. 2005 Aug 12;309:1083–7. Epub 2005 Aug 3.
- World Health Organization. Influenza pandemic preparedness and response. Geneva: The Organization; 2005. [cited 2005 Sep 22]. Available from http://www.who.int/gb/ebwha/pdf_files/EB115/B115_44-en.pdf

Address for correspondence: Sonja J. Olsen, CDC, Box 68, American Embassy, APO AP 96546; fax: 66-2-580-0911; email: SOlsen@cdc.gov

Imported Tickborne Relapsing Fever, France

To the Editor: Tickborne relapsing fevers caused by *Borrelia* species are characterized by ≥ 1 recurrent episodes of fever accompanied by headache, myalgia, arthralgia, abdominal pain, and eventually by hepatic or neurologic manifestations. In the Old World, *Borrelia duttonii* is endemic in sub-Saharan East Africa (1) and *B. crocidurae* and *B. hispanica* are distributed in West Africa and Mediterranean countries (2). In North America, *B. hermsii*, *B. turicatae*, and *B. parkeri* cause mild and sporadic fever cases, although several outbreaks have been reported (3). Relapsing fevers in disease-nonnendemic countries are infrequently diagnosed and probably underdiagnosed (4). We report 3 patients with relapsing fever diagnosed in France in travelers from disease-endemic countries.

Patient 1, a 29-year-old French man, was admitted to Hôtel-Dieu in Paris for a fourth recurrence of a flulike syndrome. Three weeks earlier, he had traveled through Spain and Morocco, when high-grade fever, chills, myalgia, and arthralgia suddenly developed. Symptoms quickly resolved after treatment with salicylate and acetaminophen, but 3 relapses

occurred within 20 days. He had a low-grade fever and persisting myalgia. Results of a clinical examination were normal. Analyses showed elevated levels of C-reactive protein (CRP) (368 mg/L), creatine kinase (269 IU/L), and lactate dehydrogenase (1,149 IU/L). Because of previous travel in Africa, Giemsa-stained blood smears were examined for malaria parasites. They showed helical bacteria suggestive of *Borrelia*. Polymerase chain reaction (PCR) of a blood sample and sequencing of the 16S rRNA gene identified this bacterium as *B. hispanica*. Cefotaxime was administered for 72 hours and replaced with doxycycline, 100 mg twice a day for 10 days. One month later, the patient was free of symptoms.

Patient 2, a 21-year-old Malian woman, was admitted to Hôpital de Mantes in Mantes-la-Jolie and delivered a normal baby with the gestational age of 36.2 weeks. One month earlier, she experienced a spontaneously resolving fever with myalgia. Biologic analyses of the mother showed anemia (hemoglobin 9.8 g/dL) with an inflammatory syndrome (CRP 164 mg/L). Giemsa-stained blood smears showed spirochetes. Molecular analyses identified these as *B. crocidurae*. Results of this analysis in the newborn were negative. The patient was treated with doxycycline, 100 mg twice a day for 10 days, and quickly recovered.

Patient 3, a 21-year-old Mauritanian woman, was admitted to Avicenne Hospital in Bobigny with a febrile illness that lasted 4 days. She had been traveling for 2 months through Senegal and Mauritania. The day of her return to France, high-grade fever (temperature 41°C), chills, headache, diarrhea, and arthralgia developed. Results of a clinical examination were normal. Laboratory investigations showed anemia (hemoglobin 9.8 g/dL) and thrombocytopenia (64,000 platelets/ μ L). Giemsa-stained blood smears showed spiro-

chetes. Molecular analyses identified this bacterium as *B. crocidurae*. The patient was treated with doxycycline, 100 mg twice a day for 10 days, and the patient quickly recovered.

Relapsing fevers caused by *Borrelia* spp. are rarely reported in travelers from disease-endemic countries. Because most infections are benign, cases are probably neglected. Since cultivation of the causative agents can be difficult, diagnosis relies on microscopic detection of helical bacteria in stained blood smears. Blood samples should be obtained during febrile episodes, but as shown in patient 2, spirochetes may be visualized on blood smears when the patient is no longer febrile. Quantitative buffy-coat analysis that increases detection sensitivity has been reported (5). Serologic tests are being developed to diagnose infection with *B. recurrentis* (6).

Detection of *Borrelia* DNA by PCR amplification from the blood is highly sensitive and specific. Identification can be achieved by sequencing the 16S rRNA gene (7)

(Figure). Given the high level of sequence conservation (7), mutations can be informative. The identifying nucleotides for *B. crocidurae*, *B. hispanica*, and *B. duttonii* were at positions 65, 181, 381, and 596. Therefore, sequence analysis of the first 600 nucleotides (nt) in the 16S rRNA gene is sufficient to differentiate *B. crocidurae*, *B. hispanica*, and *B. duttonii*.

The complete *Borrelia* sequence obtained from the patient 1 showed 99.93% identity with *B. hispanica* (1 nt difference), 99.79% with *B. crocidurae* (3 nt differences), and 99.72% identity with *B. duttonii* (4 nt differences). This patient was infected with *B. hispanica* during his travel through Spain or Morocco, which is consistent with the distribution of this species. Comparison of 1,430 nt from sequences from patients 2 and 3 showed 99.93% identity with the sequence of *B. crocidurae* (1 nt difference). *B. crocidurae* occurs mostly in sub-Saharan countries of West Africa (Senegal, Mali, and Mauritania), where patients 2 and 3 were likely to have been infected.

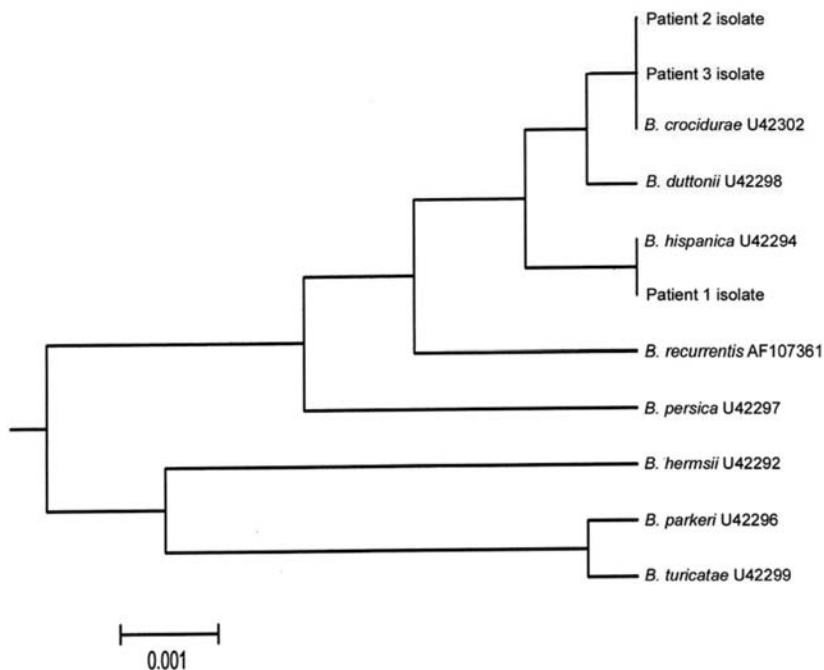


Figure. Unweighted pair group with mathematical average rooted tree of complete sequences of the *Borrelia* 16S rRNA gene. Sequences from databanks are indicated by their accession numbers.

Physicians should be alert for relapsing fever in travelers, and this diagnosis should be considered in febrile patients from disease-endemic regions. Diagnosis relies upon examination of stained blood smears. Where available, molecular methods are highly efficient to detect and identify bacterial species. Other tickborne infections (e.g., those with *Rickettsia* spp.) should also be considered in patients returning from disease-endemic countries (8). The recommended treatment is doxycycline, although it can cause a Jarish-Herxheimer reaction in some patients.

Benjamin Wyplosz,*
Liliana Mihaila-Amrouche,*
Marie-Therese Baixench,*
Marie-Laure Bigel,†
Liliane Berardi-Grassias,†
Camille Fontaine,‡
Michele Hornstein,‡ **Arezki Izri,‡**
Guy Baranton,§
and Daniele Postic§

*Hôtel-Dieu, Paris, France; †Hôpital de Mantes, Mantes-la-Jolie, France; ‡Hôpital Avicenne, Bobigny, France; and §Institut Pasteur, Paris, France

References

1. Barclay AJG, Coulter JBS. Tick-borne relapsing fever in central Tanzania. *Trans R Soc Trop Med Hyg.* 1990;84:852–6.
2. Trape JF, Godeluck B, Diatta G, Rogier C, Legros F, Albergel J, et al. The spread of tick-borne borreliosis in West Africa and its relationship to sub-Saharan drought. *Am J Trop Med Hyg.* 1996;54:289–93.
3. Schwan TG, Policastro PF, Miller Z, Thompson RL, Damrow T, Keirans JE. Tick-borne relapsing fever caused by *Borrelia hermsii*, Montana. *Emerg Infect Dis.* 2003;9:1151–4.
4. McConnell J. Tick-borne relapsing fever under-reported. *Lancet Infect Dis.* 2003;10:604.
5. van Dam AP, van Gool T, Wetsteyn JC, Dankert J. Tick-borne relapsing fever imported from west Africa: diagnosis by quantitative buffy coat analysis and in vitro culture of *Borrelia crocidurae*. *J Clin Microbiol.* 1999;37:2027–30.
6. Porcella SF, Raffel SJ, Schrupf ME, Schriefer ME, Dennis DT, Schwan TG. Serodiagnosis of louse-borne relapsing fever with glycerophosphodiester phospho-

diesterase (GlpQ) from *Borrelia recurrentis*. *J Clin Microbiol.* 2000;38:3561–71.

7. Marti Ras N, Lascola B, Postic D, Cutler SJ, Rodhain F, Baranton G et al. Phylogenesis of relapsing fever *Borrelia* spp. *Int J Syst Bacteriol.* 1996;46:859–65.
8. Jensenius M, Fournier PE, Kelly P, Myrvang B, Raoult D. African tick bite fever. *Lancet Infect Dis.* 2003;3:557–64.

Address for correspondence: Daniele Postic, Laboratoire des Spirochètes, Institut Pasteur, 28 Rue du Dr Roux, 75724 Paris CEDEX 15, France; fax: 33-1-40-61-30-01; email: dpostic@pasteur.fr

Neonatal *Moraxella osloensis* Ophthalmia

To the Editor: *Moraxella osloensis* is an aerobic, gram-negative, lactose-nonfermenting coccobacillus. It is a commensal of the human upper respiratory tract and occasionally of the skin and urogenital tract (1). Unlike *M. catarrhalis*, *M. osloensis* is rarely pathogenic in humans. However, several cases of serious infections caused by this organism have been documented (2–6). While cases of nongonococcal, nonchlamydial, neonatal ophthalmia have been reported in which the causative agent was *M. catarrhalis* (7,8), to our knowledge, this case is the first report of neonatal ophthalmia due to *M. osloensis*.

A 3-week-old, previously healthy boy was seen at the emergency department with a 48-hour history of yellow drainage from and swelling in both eyes. One day before admission, the drainage increased; the child could not open his eyes spontaneously. He had been eating well and was normally active. Aside from mild fussiness, no other symptoms were noted.

The child was born full-term without complications to a gravida 6, para

5–6 mother. He received normal newborn care, including topical erythromycin ointment to the eyes. Aside from some mild jaundice at 6 days of age, he had been healthy. The mother denied any history of sexually transmitted disease.

On examination, the infant's temperature was 38°C rectally, heart rate 144 beats/min, respirations 26/min, and blood pressure 94/60 mm Hg. The child appeared well developed and was fussy but showed no symptoms of toxicity. Both eyelids were markedly swollen and erythematous, and a yellow, purulent discharge was noted bilaterally. The sclera and conjunctivae were injected bilaterally. An ophthalmologist recorded that the red reflex was intact bilaterally and the corneas were clear. Intravenous cefotaxime, oral erythromycin, and topical erythromycin ointment to the eyes were recommended. The leukocyte count was 11,400 cells/mm³ with a normal differential. Hemoglobin level, hematocrit, platelet count, and bilirubin level were all within normal range. Urinalysis results as well as urine, blood, and cerebrospinal fluid cultures were negative. Secretions from the eyes were collected and sent for Gram stain and bacterial culture as well as chlamydial culture. Gram stain showed few gram-variable cocci.

The child's eyes were flushed with copious amounts of normal saline, and a dose of intravenous cefotaxime and ampicillin was administered in the emergency department. He was admitted to the hospital for presumed ophthalmia neonatorum. The following day, decreased lid swelling, erythema, and eye discharge were observed, with trace conjunctival injection and minimal chemosis.

The child's condition improved markedly during the next 24–48 hours. Cultures of the secretions obtained from the eye grew presumed *Neisseria* species as a pure culture. The isolate was sent to the Allegheny