

---

# Distribution of Eosinophilic Meningitis Cases Attributable to *Angiostrongylus cantonensis*, Hawaii

Natasha S. Hochberg,\*<sup>1</sup> Sarah Y. Park,† Brian G. Blackburn,\*<sup>2</sup> James J. Sejvar,\* Kate Gaynor,‡ Heath Chung,§ Karyn Leniek,\* Barbara L. Herwaldt,\* and Paul V. Effler†

During November 2004–January 2005, 5 cases of eosinophilic meningitis (EM) attributable to *Angiostrongylus cantonensis* infection were reported in Hawaii. To determine if this temporal clustering reflected an increased incidence, we ascertained EM and *A. cantonensis* cases by systematic review of statewide laboratory and medical records for January 2001–February 2005 and generalized the data to population estimates. We identified 83 EM cases; 24 (29%) were attributed to *A. cantonensis* infection, which was included in the discharge diagnoses for only 2 cases. Comparison of *A. cantonensis* infection incidence rates (per 100,000 person-years) for the baseline (January 2001–October 2004) and cluster (November 2004–February 2005) periods showed statistically significant increases for the state as a whole (0.3 vs. 2.1), the Big Island of Hawaii (1.1 vs. 7.4), and Maui County (0.4 vs. 4.3). These findings underscore the need to consider the diagnosis of *A. cantonensis* infection, especially in the state of Hawaii.

Eosinophilic meningitis (EM) is a rare clinical entity characterized by meningeal inflammation and eosinophilic pleocytosis in the cerebrospinal fluid (CSF) (1–7). Among the infectious causes of EM, *Angiostrongylus cantonensis* is the most common worldwide. *A. cantonensis*, the rat lungworm, was first described in rats in 1935, in Canton, China. The parasite was first postulated to cause human infection in a fatal case in 1944 in Taiwan and was

confirmed to be pathogenic for humans through investigations in the early 1960s in Hawaii (8–12).

Most of the described cases of symptomatic *A. cantonensis* infection (neurologic angiostrongyliasis) have occurred in regions of Asia and the Pacific Rim (e.g., Taiwan, Thailand, and the Hawaiian and other Pacific Islands) (4–19). However, widespread geographic dispersal of *A. cantonensis* is ongoing, facilitated primarily by infected shipborne rats and the diversity of potential intermediate hosts (9,20–27). Intercontinental movement of rodent definitive hosts and accidental human hosts translates into the need for worldwide awareness of the association between EM and *A. cantonensis* infection.

Humans become infected by ingesting intermediate hosts, such as snails and slugs, or transport/paratenic hosts, such as freshwater crustaceans, that contain viable third-stage larvae (Figure 1). These larvae can migrate to the central nervous system (CNS) and cause EM (6–34). The exposure often is unrecognized and presumptive, such as through ingestion of contaminated produce. The incubation period averages ≈1–3 weeks but has ranged from 1 day to >6 weeks (5–7,16–20,24,27,32–35). Common clinical manifestations include headache, meningismus, and hyperesthesia, which usually resolve spontaneously with supportive care; severe cases can be associated with sequelae (e.g., paralysis and blindness) and death (5,8,11,12,14–19,28,31,33–38). The utility of anthelmintic and corticosteroid therapy remains controversial and may vary among *A. cantonensis*–endemic areas (3,7,16–19,24,27–38).

---

\*Centers for Disease Control and Prevention, Atlanta, Georgia, USA; †Hawaii State Department of Health, Honolulu, Hawaii, USA; ‡Centers for Disease Control and Prevention, Honolulu, Hawaii, USA and §University of Hawaii School of Medicine, Honolulu, Hawaii, USA

<sup>1</sup>Current affiliation: Emory University, Atlanta, Georgia, USA

<sup>2</sup>Current affiliation: Stanford University School of Medicine, Stanford, California, USA

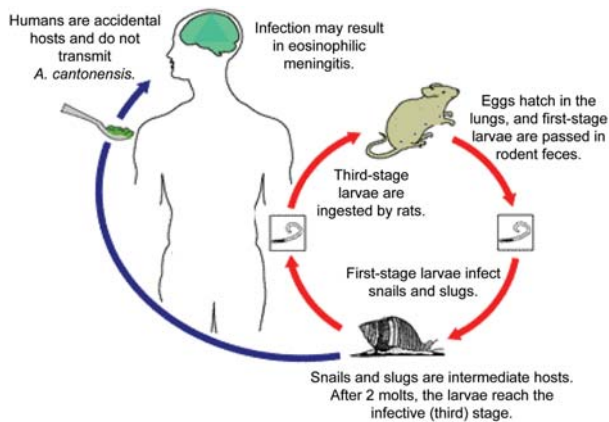


Figure 1. Life cycle of *Angiostrongylus cantonensis*. Source: [www.dpd.cdc.gov/dpdx](http://www.dpd.cdc.gov/dpdx), a website developed and maintained by the Centers for Disease Control and Prevention.

Typically, symptomatic infection is presumptively diagnosed on the basis of epidemiologic and clinical criteria (4,5,7,13), as was done in this investigation. Parasitologic confirmation, by detection of larvae or young adult worms in the CSF, is unusual, albeit slightly more common in young children (particularly in Taiwan) (5,7,13–19,32). Investigational immunoassays for detection of antibodies to *A. cantonensis* antigens have not been sufficiently characterized or validated to be useful for distinguishing infected and uninfected persons, particularly in epidemiologic investigations (3,5,27).

During November 2004–January 2005, 1 parasitologically confirmed and 4 presumptive cases of *A. cantonensis* infection were reported to the Hawaii State Department of Health. The 5 cases included 3 from the Big Island of Ha-

waii and 2 from Oahu; 1 Oahu case was in a visitor to Hawaii whose lumbar puncture (LP) was performed elsewhere. Recognition of these 5 index cases prompted multifaceted investigations of epidemiologic, clinical, and environmental aspects of EM/*A. cantonensis* infection in Hawaii.

To assess whether the unusual temporal clustering of case reports reflected an increased incidence of EM/*A. cantonensis* infection, we ascertained cases through comprehensive review of statewide laboratory and medical records. Although investigations of EM/*A. cantonensis* infection in various Hawaiian Islands have been described since the 1960s (4–6,9–13,20,30,35), to our knowledge, this is the first study to systematically ascertain cases and determine regional incidence rates in this manner.

## Methods

### Ascertainment and Classification of Cases

Our primary means for ascertaining potential cases of EM and *A. cantonensis* infection was a retrospective review of CSF data provided by clinical laboratories in Hawaii for LPs performed during the study period (January 2001–February 2005). In March 2005, we obtained CSF data for 22 of 24 acute-care hospitals, which encompassed ≈93% of the state's hospital beds; for 1 of the 22 facilities (≈7% of beds), data were unavailable for January 2001–December 2002. The total numbers of patients and LPs during the study period were unavailable (e.g., some laboratories provided CSF data only if particular criteria were met). In January 2005, 1 case of EM/*A. cantonensis* infection in a visitor to Hawaii whose LP was performed elsewhere was ascertained by passive physician reporting to the Hawaii State Department of Health and the Centers for Disease

Table 1. Case definitions for eosinophilic meningitis (EM) and *Angiostrongylus cantonensis* infection, Hawaii, January 2001–February 2005

Diagnosis	Inclusionary criteria	Exclusionary criteria
EM	Had lumbar puncture (LP) during January 2001–February 2005* Had cerebrospinal fluid (CSF) with both: ≥6 leukocytes per mm <sup>3</sup> Eosinophil percentage (of leukocyte count) or absolute eosinophil count ≥10	Not in Hawaii during exposure period† Had any of the following:‡ Leukocytes or eosinophils in CSF below inclusionary levels after adjusting for presence of erythrocytes Grossly bloody CSF Diagnosis or signs (e.g., CSF, radiologic) of intracranial hemorrhage
<i>A. cantonensis</i> infection	Met criteria for EM Met parasitologic or clinical criteria for <i>A. cantonensis</i> infection: Parasitologic: <i>A. cantonensis</i> larvae or young adult worms in CSF Clinical: manifestations compatible with <i>A. cantonensis</i> infection and including ≥2 symptoms/signs§	Had intracranial hardware when LP was performed Was <2 mo of age when LP was performed Had been hospitalized from birth through time of LP Had another possible cause of EM identified

\*If a patient had >1 LP, the LP considered in the analyses was the one that met criteria for EM and had the highest absolute eosinophil count.

†The exposure period was defined as the 45-d period before the symptom-onset date (if unknown, the date of the LP).

‡Potential cases of EM were excluded if the eosinophilic pleocytosis was potentially attributable to blood and thus was difficult to evaluate (e.g., traumatic LP, grossly bloody CSF, or intracranial hemorrhage). For CSF specimens with >500 erythrocytes/mm<sup>3</sup>, the leukocyte and eosinophil criteria had to be met after using a correction ratio of a decrease of 1 leukocyte for every 500 erythrocytes.

§The symptoms and signs included headache, neck stiffness or nuchal rigidity, visual disturbance, photophobia or hyperacusis, cranial nerve abnormality (e.g., palsy), abnormal skin sensation (e.g., paresthesia, hyperesthesia), sensory deficit, nausea or vomiting, documented fever, increased irritability (if <4 y of age), and bulging fontanelle (if <18 mo of age).

Control and Prevention (CDC); this case was 1 of the 5 index cases that prompted the investigation.

Our case definitions for EM and *A. cantonensis* infection are provided in Table 1. If the inclusionary criteria for EM were met, we reviewed the patient's medical record to obtain additional information regarding the EM and to categorize cases of EM by known or likely cause (e.g., *A. cantonensis* infection). The information collected during chart review included basic demographic data, pertinent dates (e.g., birth, hospitalization, travel, symptom onset, and LP), medical history, medications, clinical manifestations, additional laboratory and radiologic results, and discharge diagnoses. Because the primary focus of the study was *A. cantonensis* infection, if, at the time of the LP, the patient had intracranial hardware (i.e., a well-established cause of EM) or was <2 months of age (i.e., angiostrongyliasis was epidemiologically unlikely), we collected only demographic data and discharge diagnoses.

We attributed cases of EM to *A. cantonensis* infection only if this diagnosis was epidemiologically and clinically plausible and no other possible cause of EM was identified. Examples of possible alternative causes included CNS infection with other microbes, reaction to foreign material in the CNS (e.g., intracranial hardware or myelography dye), medications (e.g., intrathecal vancomycin or gentamicin), neoplasms, multiple sclerosis, and neurosarcoidosis (1–7). The study neurologist (J.J.S.) facilitated final selection and classification of cases of EM and *A. cantonensis* infection by reviewing the available case data and ensuring that the inclusionary and exclusionary criteria were applied consistently and objectively.

**Statistical Analysis and Human Subjects Protection**

Data entry was performed with Epi Info version 2002 (CDC, Atlanta, GA, USA), and data analyses were conducted with SAS version 9.1 (SAS Institute, Cary, NC, USA). Two-tailed p values were calculated by using the Fisher exact test for binary variables and the Wilcoxon test for continuous variables. Linear and quadratic regression models were evaluated to assess whether eosinophilic pleocytosis varied with time (i.e., the interval from symptom onset to LP). We calculated incidence rates by generalizing hospital-based frequency data to the population at large for various periods and counties in Hawaii using the US Census Bureau's annual population estimates for 2001–2004 (the estimate for 2004 also was used for January and February 2005) (39). We used Poisson regression analyses to compare county-specific annual rates. We defined the 46-month period of January 2001–October 2004 as the baseline period and the 4-month period of November 2004–February 2005 as the cluster period. CDC's policies with regard to human study participants were followed in this investigation.

**Results**

We identified 83 cases of EM for the 50-month study period (January 2001–February 2005); <1% of the patients whose CSF data were reviewed fulfilled the case criteria (Table 1). The 83 cases included 70 (84%) during the 46-month baseline period (17–21 cases per year) and 13 (16%) during the 4-month cluster period. We attributed 24 (29%) of the 83 EM cases to *A. cantonensis* infection and 59 (71%) to other causes (Table 2). Thirty-five of these 59 cases (42% of 83) were in persons with intracranial hardware, and 9 (11% of 83) were in persons without intracranial hardware who had documented bacterial (n = 5) or viral (n = 4) meningoencephalitis.

The 24 cases of EM attributed to *A. cantonensis* infection included 1 parasitologically confirmed case in an 11-month-old child and 23 clinically defined cases (Table 2). EM was noted in the discharge diagnoses for 11 case-patients (46%). *A. cantonensis* infection, as well as EM, was listed for only 2 cases: the parasitologically confirmed case and 1 other case in January 2005. The 24 case-patients had a median age of 31 years (range 11 months–45 years), and 13 (54%) were male. Of the 13 patients for whom race/ethnicity data were available, 6 (46%) were Caucasian, 3 (23%) Filipino, 3 (23%) Hawaiian/part-Hawaiian, and 1 (8%) Samoan.

For the 22 case-patients with known symptom onset dates, the median interval from onset to LP was 3 days

Table 2. Classification of cases of eosinophilic meningitis (EM; n = 83) and *Angiostrongylus cantonensis* infection by cause or category, Hawaii, January 2001–February 2005

Cause or category	No. (%)
Cases attributed to causes other than <i>A. cantonensis</i> infection*	59 (71)
Presence of intracranial hardware	35 (42)
No intracranial hardware	24 (29)
Patient <2 mo of age	
No microbial etiologic agent identified	10
Bacterial meningitis†	3
Enteroviral meningoencephalitis	2
Patient ≥2 mo of age	
Streptococcal meningitis‡	2
Viral meningoencephalitis§	2
Presumptive viral encephalomyelitis	1
Encephalitis not otherwise specified	1
Suspected vertebral artery dissection	1
Cancer	1
Not otherwise specified¶	1
Cases attributed to <i>A. cantonensis</i> infection	24 (29)
Clinically defined	23
Parasitologically confirmed	1

\*The 59 cases include 35 (42%) in patients with intracranial hardware and 24 (29%) in patients without intracranial hardware. All cases of EM in patients with intracranial hardware when the lumbar puncture was done were attributed to the hardware (Table 1), regardless of the reason for implantation. Two of the 35 such cases were in patients <2 mo of age.

†Etiologic agents were *Escherichia coli*, *Klebsiella* sp., and  $\alpha$ -hemolytic *Streptococcus*.

‡Etiologic agents were *S. agalactiae* (group B *Streptococcus*) and *S. pneumoniae*, in 87-y-old and 5-mo-old patients, respectively.

§Etiologic agents were herpes simplex virus and an enterovirus, in 20-y-old and 3-mo-old patients, respectively.

¶Did not meet criteria for *A. cantonensis* infection (Table 1).

(range 0–48 days); the 2 longest intervals were 14 days (2 patients) and 48 days (1 patient). When a linear regression model was applied to data for the intervals  $\leq 14$  days, the longer the interval (between symptom onset and LP), the higher the CSF eosinophil percentage and absolute eosinophil count ( $p = 0.001$  and  $0.005$ , respectively). Compared with patients with other causes of EM, *A. cantonensis* case-patients had significantly higher CSF leukocyte counts (median  $573/\text{mm}^3$  vs.  $304/\text{mm}^3$ ,  $p = 0.03$ ) and absolute eosinophil counts (median  $120/\text{mm}^3$  vs.  $14/\text{mm}^3$ ,  $p < 0.001$ ); they also tended to have higher eosinophil percentages (median 15.0% vs. 12.0%), but the difference was not statistically significant ( $p = 0.08$ ).

The temporal distribution of the 24 cases included 15 (63%) during the baseline period (3–5 cases per year) and 9 (38%) during the cluster period (Figure 2). The mean number of *A. cantonensis* cases per month increased from 0.3 in the baseline period to 2.3 in the cluster period, whereas the mean monthly rates for cases of EM with other causes were essentially unchanged (1.2 and 1.0, respectively). Thus, the proportion of EM cases attributed to *A. cantonensis* increased from 21% (15/70) for the baseline period to 69% (9/13) for the cluster period. The *A. cantonensis* incidence rates for the state as a whole increased from 0.3 per 100,000 person-years in the baseline period to 2.1 in the cluster period ( $p < 0.001$ ) (Figure 2).

The geographic distribution of the 24 cases included 3 counties and 4 islands: Honolulu County (Oahu Island;  $n = 11$  cases, including the case in the visitor), Hawaii County (Big Island of Hawaii;  $n = 9$ , including the parasitologically confirmed case), and Maui County ( $n = 4$ , including 3 cases associated with Maui Island and 1 with Lanai). Although the absolute number of cases was highest for Honolulu, the county-specific incidence rates (per 100,000 person-years) for the study period as a whole were higher for Hawaii (1.4) and Maui (0.7) than Honolulu (0.3) (Figure 3). The case-patients were significantly more likely to have been in Hawaii County than Honolulu County (risk ratio 4.6, 95% confidence interval 1.9–11.1); the comparison between Hawaii and Maui Counties was not significant (data not shown). The increases in annualized incidence rates (cases/100,000 person-years) from the baseline to the cluster periods were statistically significant for Hawaii County (1.1 vs. 7.4;  $p < 0.001$ ) and Maui County (0.4 vs. 4.3;  $p = 0.03$ ) but not for Honolulu County (0.2 vs. 1.0;  $p = 0.07$ ) (Figure 3).

## Discussion

This study was prompted by an unusual temporal clustering of 5 reported cases of EM/*A. cantonensis* infection from 2 Hawaiian Islands during November 2004–January 2005. Our primary goal was to assess whether these voluntarily reported cases reflected an increased incidence. To accomplish this, we used a laboratory- and hospital-based

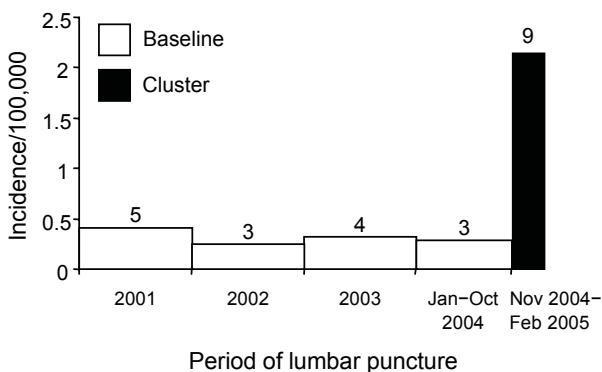


Figure 2. Incidence rates for cases of eosinophilic meningitis attributed to *Angiostrongylus cantonensis* infection, by period, Hawaii, January 2001–February 2005 ( $n = 24$ ). The number over each bar indicates the number of cases during the period. The incidence rates (per 100,000 person-years) for the entire 50-month study period, the 46-month baseline period (January 2001–October 2004), and the 4-month cluster period were 0.5, 0.3, and 2.1, respectively.

approach to ascertain symptomatic cases of EM and *A. cantonensis* infection. To our knowledge, this is the first study to systematically determine incidence rates of EM and *A. cantonensis* infection for the entire state of Hawaii or any angiostrongyliasis-endemic area. We determined that the incidence of angiostrongyliasis was higher during the cluster period (November 2004–February 2005) than the baseline period (January 2001–October 2004). The overall findings of our study support conclusions specific for Hawaii but also highlight general principles about EM and *A. cantonensis* infection. In addition, our study may serve as a useful model in other settings. Surveillance of regional laboratory data, coupled with investigation of medical records of case-patients, may help identify temporal and geographic trends for angiostrongyliasis or other diseases.

Our data underscore that EM is an uncommon entity:  $< 1\%$  of the patients whose CSF data were reviewed fulfilled the laboratory criteria for EM. This diagnosis is commonly missed or dismissed, but the presence of eosinophilic pleocytosis is abnormal and should prompt consideration of both infectious and noninfectious causes. In our study, intracranial hardware was the most frequently identified cause of EM (42% of 83 cases). Although the presence of hardware or other foreign material in the CNS is a well-established cause of EM, the possibility of associated bacterial infection should be considered (2,6). In our study, EM also was associated with confirmed cases of bacterial and viral meningoencephalitis, as well as idiopathic cases (no microbial etiology identified) in infants evaluated because of fever or failure to thrive.

We found that a substantial proportion of the EM cases in Hawaii were attributable to *A. cantonensis* infection (29%) and that the proportion was 3-fold higher during the

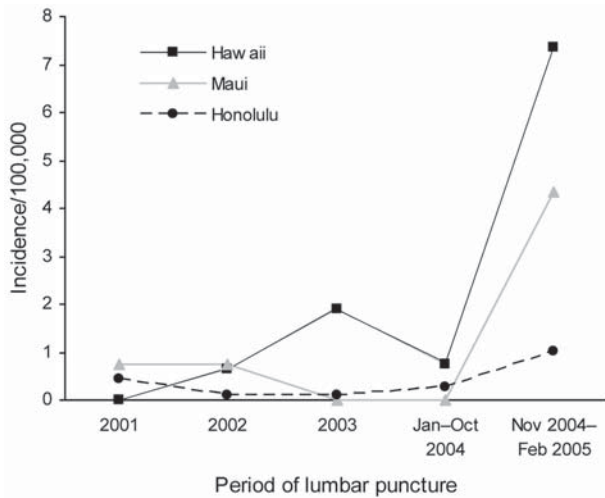


Figure 3. County-specific incidence rates per 100,000 person-years for cases of eosinophilic meningitis attributed to *Angiostrongylus cantonensis* infection, by period, Hawaii, January 2001–February 2005 (n = 24).

cluster than during the baseline period. This rate increase was particularly notable in Hawaii and Maui Counties. Despite the fact that 23 of the 24 cases were clinically defined, the likelihood of misclassification was low. By definition, none of the case-patients had another possible cause of EM identified. In most angiostrongyliasis-endemic areas, parasitologic confirmation is unusual, and a presumptive diagnosis is typical. Furthermore, Hawaii is hyperenzootic for infection with *A. cantonensis* but not *Gnathostoma spinigerum* or *Baylisascaris procyonis*, 2 other parasites commonly associated with EM. Our confidence that the *A. cantonensis* cases were correctly classified as such is further increased by the findings of other components of our multifaceted investigations, which included comprehensive epidemiologic and clinical characterization of patients, with longitudinal evaluation of clinical status and sequelae (N. Hochberg, unpub. data).

One of the limitations of our laboratory/hospital-based study is the likelihood that we underestimated the numbers of cases of EM and *A. cantonensis* infection. By definition, we did not include persons who were asymptomatic, were not medically evaluated, did not have an LP, did not have CSF data that met specified criteria for EM (e.g., if the LP was performed early or late in the course of infection, few eosinophils might have been noted), or did not meet conservative epidemiologic and clinical criteria. In addition, cases of EM/angiostrongyliasis that were associated with exposures in Hawaii but were diagnosed elsewhere were not systematically ascertained. Cases diagnosed after the end of the study period (February 2005) were not included (specifically, 2 cases reported in March and April 2005 that were associated with Hawaii County). Their existence,

however, lends even more credence to the temporal clustering of cases in late 2004–early 2005.

A second limitation is that we cannot exclude the possibility that the temporal increases in frequency of cases were artifactual (e.g., reflected heightened awareness of *A. cantonensis* infection or decreased thresholds for performing LPs). However, the investigation was prompted by clustering of 5 voluntary case reports during November 2004–January 2005, when EM and *A. cantonensis* infection were not reportable conditions, and included a parasitologically confirmed case. In addition, for patients who accessed healthcare and had an LP, our methods for case ascertainment were not dependent upon clinicians considering or listing EM or *A. cantonensis* infection in discharge diagnoses. Our methods were systematic, statewide, and unbiased.

We recognize the limitations and the utility of the incidence data. We calculated incidence rates by generalizing relatively small numbers of cases to the population estimates for particular periods in the state and the pertinent counties. Adjusting the frequency data for the sizes of populations and the durations of periods facilitated comparisons between counties, periods, and causes of EM. The cases of EM not attributed to *A. cantonensis* served as a useful internal control for the conclusion that the incidence of angiostrongyliasis increased: the incidence of *A. cantonensis* infection was significantly higher during the cluster period, whereas the incidence of the other EM cases did not increase.

In conclusion, we demonstrated the utility of a comprehensive, laboratory/hospital-based approach for statewide surveillance of EM and *A. cantonensis* infection in Hawaii. We found a cluster of angiostrongyliasis cases between November 2004 through February 2005 primarily centered in Hawaii and Maui Counties. Furthermore, EM and *A. cantonensis* infection were often not included in the discharge diagnoses for the case-patients. Our study therefore underscores the need to educate clinicians in Hawaii and elsewhere about EM and its causes, most notably *A. cantonensis* infection, a potentially severe but preventable infection. Improved detection and reporting may facilitate recognition of clusters of cases and prompt investigations that yield valuable insights about the epidemiologic and clinical characteristics of *A. cantonensis* infection.

#### Acknowledgments

We thank Eric Brown, Myra Ching-Lee, Rebecca L. Hall, Michele C. Hlavsa, Rob Hollingsworth, Jeffrey L. Jones, Norman O'Connor, James J. Sullivan, Chester Wakida, and John Williamson for invaluable assistance in various aspects of the investigations.

Financial support for this research came from CDC.

Dr Hochberg is an infectious disease fellow at Emory University. She is also a guest researcher with the Division of Parasitic Diseases at CDC, where she was an Epidemic Intelligence Service Officer at the time of this study. Her research currently focuses on the epidemiology of parasitic diseases.

## References

- Weller PF, Liu LX. Eosinophilic meningitis. *Semin Neurol*. 1993;13:161–8.
- Bosch I, Oehmichen M. Eosinophilic granulocytes in cerebrospinal fluid: analysis of 94 cerebrospinal fluid specimens and review of the literature. *J Neurol*. 1978;219:93–105.
- Slom T, Johnson S. Eosinophilic meningitis. *Curr Infect Dis Rep*. 2003;5:322–8.
- Kuberski T. Eosinophils in cerebrospinal fluid: criteria for eosinophilic meningitis. *Hawaii Med J*. 1981;40:97–8.
- Kuberski T, Wallace GD. Clinical manifestations of eosinophilic meningitis due to *Angiostrongylus cantonensis*. *Neurology*. 1979;29:1566–70.
- Hughes PA, Magnet AD, Fishbain JT. Eosinophilic meningitis: a case series report and review of the literature. *Mil Med*. 2003;168:817–21.
- Tangwanicharoen T, Viriyavejakul P, Punpoowong B, Wilairatana P, Kaewkungwal J, Pongponratn E, et al. Cerebrospinal fluid analysis in eosinophilic meningoencephalitis. *Southeast Asian J Trop Med Public Health*. 2001;32:751–9.
- Beaver PC, Rosen L. Memorandum on the first report of *Angiostrongylus* in man, by Nomura and Lin, 1945. *Am J Trop Med Hyg*. 1964;13:589–90.
- Alicata JE. The discovery of *Angiostrongylus cantonensis* as a cause of human eosinophilic meningitis. *Parasitol Today*. 1991;7:151–3.
- Horio SR, Alicata JE. Parasitic meningo-encephalitis in Hawaii: a new parasitic disease of man. *Hawaii Med J*. 1961;21:139–40.
- Rosen L, Chappell R, Laqueur GL, Wallace GD, Weinstein PP. Eosinophilic meningoencephalitis caused by a metastrongylid lungworm of rats. *JAMA*. 1962;179:620–4.
- Rosen L, Loison G, Laigret J, Wallace GD. Studies on eosinophilic meningitis. 3. Epidemiologic and clinical observations on Pacific Islands and the possible etiologic role of *Angiostrongylus cantonensis*. *Am J Epidemiol*. 1967;85:17–44.
- Kuberski T, Bart RD, Briley JM, Rosen L. Recovery of *Angiostrongylus cantonensis* from cerebrospinal fluid of a child with eosinophilic meningitis. *J Clin Microbiol*. 1979;9:629–31.
- Yii CY. Clinical observations on eosinophilic meningitis and meningoencephalitis caused by *Angiostrongylus cantonensis* on Taiwan. *Am J Trop Med Hyg*. 1976;25:233–49.
- Yii CY, Chen CY, Chen ER, Hsieh HC, Shih CC, Cross JH, et al. Epidemiologic studies of eosinophilic meningitis in southern Taiwan. *Am J Trop Med Hyg*. 1975;24:447–54.
- Tsai TH, Liu YC, Wann SR, Lin WR, Lee SJ, Lin HH, et al. An outbreak of meningitis caused by *Angiostrongylus cantonensis* in Kaohsiung. *J Microbiol Immunol Infect*. 2001;34:50–6.
- Tsai HC, Liu YC, Kunin CM, Lee SS, Chen YS, Lin HH, et al. Eosinophilic meningitis caused by *Angiostrongylus cantonensis*: report of 17 cases. *Am J Med*. 2001;111:109–14.
- Punyagupta S, Bunnag T, Juttijudata P, Rosen L. Eosinophilic meningitis in Thailand: epidemiologic studies of 484 typical cases and the etiologic role of *Angiostrongylus cantonensis*. *Am J Trop Med Hyg*. 1970;19:950–8.
- Punyagupta S, Juttijudata P, Bunnag T. Eosinophilic meningitis in Thailand: clinical studies of 484 typical cases probably caused by *Angiostrongylus cantonensis*. *Am J Trop Med Hyg*. 1975;24:921–31.
- Kliks MM, Palumbo NE. Eosinophilic meningitis beyond the Pacific Basin: the global dispersal of a peridomestic zoonosis caused by *Angiostrongylus cantonensis*, the nematode lungworm of rats. *Soc Sci Med*. 1992;34:199–212.
- Prociw P, Spratt DM, Carlisle MS. Neuro-angiostrongyliasis: unresolved issues. *Int J Parasitol*. 2000;30:1295–303.
- Campbell BG, Little MD. The finding of *Angiostrongylus cantonensis* in rats in New Orleans. *Am J Trop Med Hyg*. 1988;38:568–73.
- New D, Little MD, Cross J. *Angiostrongylus cantonensis* infection from eating raw snails [letter]. *N Engl J Med*. 1995;332:1105–6.
- Slom TJ, Cortese MM, Gerber SI, Jones RC, Holtz TH, Lopez AS, et al. An outbreak of eosinophilic meningitis caused by *Angiostrongylus cantonensis* in travelers returning from the Caribbean. *N Engl J Med*. 2002;346:668–75.
- Lindo JF, Waugh C, Hall J, Cunningham-Myrie C, Ashley D, Eberhard ML, et al. Enzootic *Angiostrongylus cantonensis* in rats and snails after an outbreak of human eosinophilic meningitis, Jamaica. *Emerg Infect Dis*. 2002;8:324–6.
- Waugh CA, Shafir S, Wise M, Robinson RD, Eberhard ML, Lindo JF. Human *Angiostrongylus cantonensis*, Jamaica [letter]. *Emerg Infect Dis*. 2005;11:1977–8.
- Chen XG, Li H, Lun ZR. Angiostrongyliasis, Mainland China [letter]. *Emerg Infect Dis*. 2005;11:1645–7.
- Bowden DK. Eosinophilic meningitis in the New Hebrides: two outbreaks and two deaths. *Am J Trop Med Hyg*. 1981;30:1141–3.
- Tsai HC, Liu YC, Kunin CM, Lai PH, Lee SS, Chen YS, et al. Eosinophilic meningitis caused by *Angiostrongylus cantonensis* associated with eating raw snails: correlation of brain magnetic resonance imaging scans with clinical findings. *Am J Trop Med Hyg*. 2003;68:281–5.
- Marsh CM. Eosinophilic meningitis/angiostrongyliasis from eating aquaculture-raised snails: a case report. *Hawaii Med J*. 1998;57:652–4.
- Batmanian JJ, O'Neill JH. Eosinophilic meningoencephalitis with permanent neurological sequelae [letter]. *Intern Med J*. 2004;34:217–8.
- Wan KS, Weng WC. Eosinophilic meningitis in a child raising snails as pets. *Acta Trop*. 2004;90:51–3.
- Tsai HC, Lee SS, Huang CK, Yen CM, Chen ER, Liu YC. Outbreak of eosinophilic meningitis associated with drinking raw vegetable juice in southern Taiwan. *Am J Trop Med Hyg*. 2004;71:222–6.
- Kliks MM, Kroenke K, Hardman JM. Eosinophilic radiculomyeloencephalitis: an angiostrongyliasis outbreak in American Samoa related to ingestion of *Achatina fulica* snails. *Am J Trop Med Hyg*. 1982;31:1114–22.
- Koo J, Pien F, Kliks MM. *Angiostrongylus (Parastrostrongylus)* eosinophilic meningitis. *Rev Infect Dis*. 1988;10:1155–62.
- Chotmongkol V, Sawanyawisuth K, Thavornpitak Y. Corticosteroid treatment of eosinophilic meningitis. *Clin Infect Dis*. 2000;31:660–2.
- Chotmongkol V, Sawadpanitch K, Sawanyawisuth K, Louhawilai S, Limpawattana P. Treatment of eosinophilic meningitis with a combination of prednisolone and mebendazole. *Am J Trop Med Hyg*. 2006;74:1122–4.
- Chotmongkol V, Sawanyawisuth K. Clinical manifestations and outcome of patients with severe eosinophilic meningoencephalitis presumably caused by *Angiostrongylus cantonensis*. *Southeast Asian J Trop Med Public Health*. 2002;33:231–4.
- US Census Bureau. GCT-T1. Population estimates. Geographic area: Hawaii. 2004 [cited 2005 Jul 14]. Available from <http://www.census.gov>

Address for correspondence: Natasha S. Hochberg, Division of Infectious Diseases, Emory University, 69 Jesse Hill Junior Dr SE, Atlanta, GA 30303, USA; email: [natasha\\_hochberg@post.harvard.edu](mailto:natasha_hochberg@post.harvard.edu)