

# WING TIP ANATOMY AND AERODYNAMICS IN FLYING SQUIRRELS

RICHARD W. THORINGTON, JR., KAROLYN DARROW, AND C. GREGORY ANDERSON

*National Museum of Natural History, Department of Vertebrate Zoology,  
Washington, D. C. 20560 (RWT, KD)  
University of Tennessee, Knoxville, TN (CGA)*

Flying squirrels are the only gliding mammals that extend the wing tip by means of a cartilage at the wrist. However, the means by which this styliiform cartilage is extended has been misunderstood, and the significance of the upturned wing tip in flying squirrels has not been appreciated. To understand this mechanism, we examined the wrist anatomy of flying squirrels and compared it with wrists of tree squirrels to determine homologies. We found that the wing tip was extended by the abductor of the thumb on the opposite side of the wrist from the styliiform cartilage. This muscle acts by means of a ligament between the falciform bone and the styliiform cartilage. In tree squirrels, the homologue of the styliiform cartilage is the previously undescribed hypothenar cartilage which supports the hypothenar pad of the hand. The styliiform-falciform ligament is derived from superficial fibers of the transcarpal ligament. Wing tips of flying squirrels are held at an upward angle to the rest of the wing and form airfoils. We propose that they serve the function of reducing induced drag, similar to the winglets of modern aircraft.

**Key words:** *Glaucomys*, *Petaurista*, flying squirrels, gliding, winglet, wrist anatomy

Gliding has evolved among recent mammals at least six different times (Thorington, 1984; Walker, 1975). Among these gliding mammals, flying squirrels are probably the most aerodynamically sophisticated. They are able to modify shape of their gliding membranes in flight, and small flying squirrels, in particular, are extremely agile and maneuverable (Muul and Alley, 1963; Scholey, 1986; Walker, 1947). Flying squirrels (Pteromyinae) comprise 43 species in 15 genera in North America, Europe, and Asia (Hoffmann et al., 1993; Thorington et al., 1996). They all glide with their forelimbs and hind limbs extended, between which stretches a gliding membrane, the plagiopatagium (Muul and Alley, 1963; Scholey, 1986; Walker, 1947, 1975; Wells-Gosling, 1985). A smaller gliding membrane, the propatagium, is supported between the cheek and the wrist in front of the forelimb. Another portion, the uropatagium, extends between hind limbs and tail (Gupta, 1966; Johnson-Murray, 1977) and

varies greatly in size among genera of flying squirrels. The plagiopatagium is supported at the wrist by a finger-like projection, the styliiform cartilage, which is bent back into a curve by the tibiocarpalis muscle that runs along the lateral edge of the gliding membrane (Johnson-Murray, 1977). This curved cartilage forms the wing tip which in flight is usually held at an upward angle to the plane of the rest of the gliding membrane and resembles the winglets of modern aircraft (Fig. 1—Whitcomb, 1976). When the animal is not gliding, the styliiform cartilage is folded back, reputedly by the flexor carpi ulnaris muscle (Bryant, 1945), and held against the forearm, and the plagiopatagium is folded in against the body, probably by transversus cutaneus and the humerodorsalis I muscles (Gupta, 1966; Johnson-Murray, 1977). Our objectives were to determine the mechanism by which the wing tip is extended and how its position is controlled by the animal, the aero-

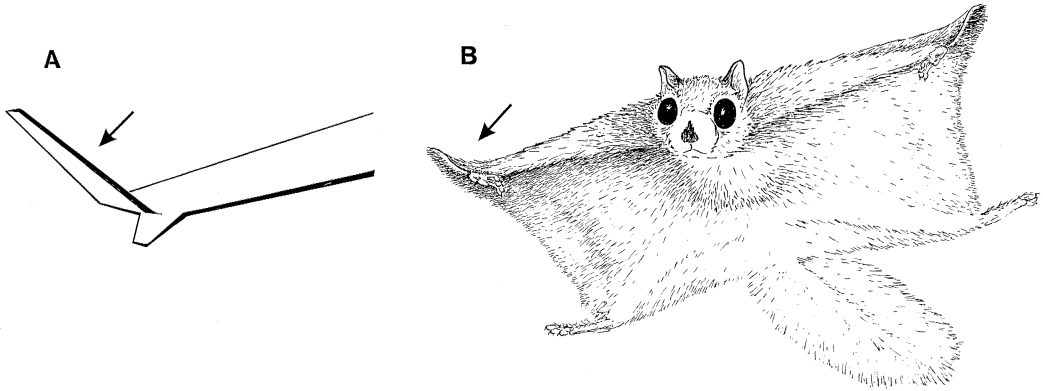


FIG. 1.—A) NASA winglet based on illustration in Whitcomb (1976), and B) *Glaucomys volans* showing upturned wing tips (based on photographs by Wells-Gosling, 1985). Arrows indicate the primary surface of the NASA winglet, and the analogous wing tip supported by the styliform cartilage in the flying squirrel. The smaller secondary surface of the NASA winglet angles down and away from the body of the airplane; the hand of the flying squirrel angles down and toward the midline.

dynamic significance of this morphology, and its evolutionary derivation.

#### METHODS

We dissected forelimbs of the following specimens from the collections of the Smithsonian Institution (USNM) and the Field Museum of Natural History (FMNH): flying squirrels—*Belomys pearsoni*, 258345, 359595; *Eoglaucomys fimbriatus*, FMNH 140501, 140505; *Eupetaurus cinereus*, uncatalogued wrist; *Glaucomys volans*, 457978, 457979; *Glaucomys sabrinus*, 563737; *Hylopetes spadiceus*, uncatalogued, IMR 89799; *Petaurista philippensis*, 334352, 334359; *Pteromys volans*, 527926; tree squirrels—*Callosciurus notatus*, 521151; *Callosciurus prevostii*, FMNH 141467; *Funisciurus lemniscatus*, 539418; *Sciurus carolinensis*, 522976, 396002. Details of the wrist morphology were studied under a dissecting microscope.

#### RESULTS

The abductor pollicis longus in flying squirrels is a prominent muscle, despite the fact that the thumb is minuscule. It takes origin from the extensor surfaces of the radius and ulna, as in other squirrels, and the tendon passes through the radial compartment of the wrist superficial to the tendons of the extensor carpi radialis brevis and longus muscles. The tendon of the abductor

pollicis longus bifurcates with one part inserting on the metacarpal of the thumb and the other part inserting on the falciform bone; the tendon to the falciform bone is the larger of the two. Between the dorsal surface of the falciform bone and the palmar surface of scapholunate, there is an arthrodiar joint. The falciform is connected to the styliform cartilage on the opposite side of the wrist by a styliform-falciform ligament, which lies superficial to the transcarpal ligament (Fig. 2). The thin transcarpal ligament extends between the scapholunate and pisiform bones and functions as the flexor retinaculum. The styliform cartilage itself is connected by ligaments both to the pisiform bone and to the base of the fifth metacarpal, which together form a hinge permitting the cartilage to be extended to a position at about right angles to the wrist (Fig. 1b). The styliform-falciform ligament attaches to the styliform cartilage distal to its hinge.

Because the falciform bone in flying squirrels is relatively mobile, this anatomical arrangement should allow the abductor of the thumb to pull the falciform bone toward the radial side of the hand, which in turn will pull on the styliform-falciform lig-

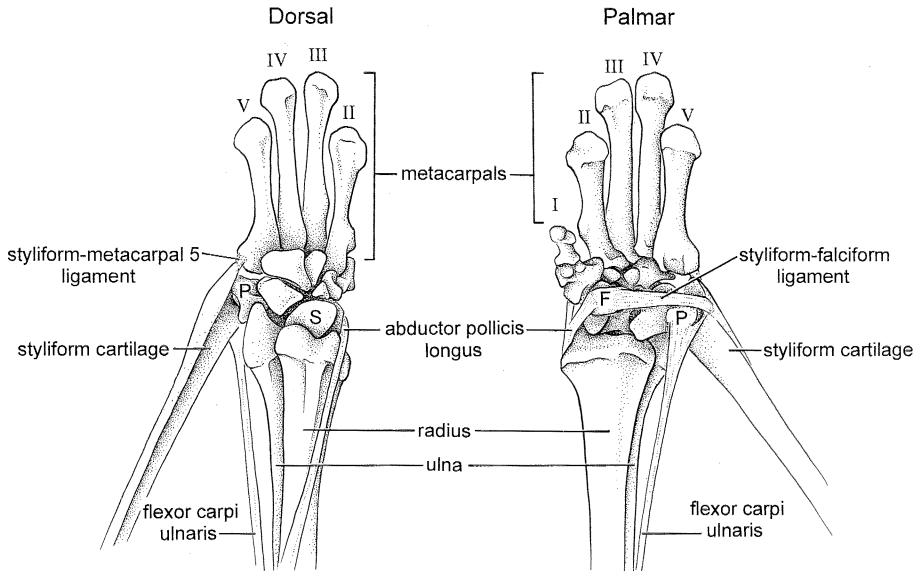


FIG. 2.—Dorsal and palmar views of the bones of the left hand of the southern flying squirrel, *Glaucomys volans*, showing tendons and ligaments involved in extending the styliiform cartilage. The transcarpal ligament is not shown; it lies deep to the styliiform-falciiform ligament between the pisiform and the scapholunate bones. The flexor carpi ulnaris muscle is a flexor of the wrist and one of the retractors of the styliiform cartilage (F = falciiform bone; P = pisiform bone; S = scapholunate bone).

ament and extend the cartilage to support the curved wing tip. We tested this in preserved specimens of *Petaurista* and in both preserved and fresh specimens of *Glaucomys* by pulling on the tendon of the abductor pollicis longus to simulate flexion of this muscle. With the hand abducted and dorsiflexed, a pull on the tendon of the abductor caused the wing tip to extend and to be held in a normal gliding position.

The flexor carpi ulnaris muscle, innervated by the ulnar nerve, takes origin by two heads: one from the medial side of the proximal end of the ulna and one from the medial epicondyle of the humerus. These fuse, slightly distal to their origins, and give rise to a single tendon that inserts on the pisiform bone and the proximal edge of the base of the styliiform cartilage (Fig. 2). The palmaris longus muscle also is innervated by the ulnar nerve and originates from the medial epicondyle of the humerus, immediately adjacent to the epicondylar head of

the flexor carpi ulnaris. This origin is tendinous in tree squirrels, but it is muscular in flying squirrels. The muscle gives rise to a tendon that fans out to insert on the skin in the region of the hypothenar pad and the palmar surface of the base of the styliiform cartilage. We simulated contraction of the flexor carpi ulnaris muscle by pulling on the tendon, which demonstrated that it retracts the styliiform cartilage in *Glaucomys*, but we were not able to demonstrate this in *Petaurista*. Movement of the styliiform cartilage in both genera caused tension and relaxation of the palmaris longus tendon. We contend that both muscles may be involved in the retraction of the styliiform cartilage and the wing tip but the degree of involvement of the flexor carpi ulnaris muscle may vary among genera of flying squirrels.

There is no styliiform cartilage in tree squirrels. Instead, the hypothenar pad on the heel of the hand is supported by a cartilage that is attached to the pisiform bone

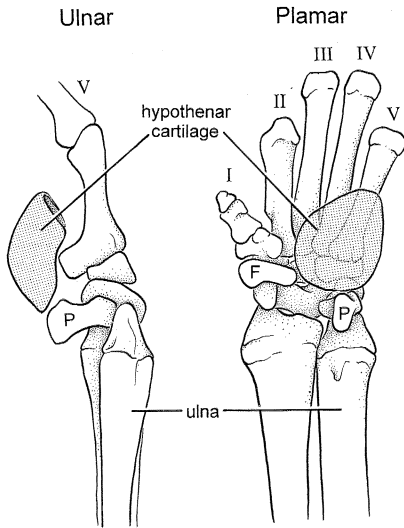


FIG. 3.—Ulnar and palmar views of the bones of the left hand of the tree squirrel, *Sciurus carolinensis*, showing the hypothenar cartilage, the homologue of the styloform cartilage of flying squirrels (F = falciform bone; P = pisiform bone).

and the base of the fifth metacarpal (Fig. 3), just like the styloform cartilage of flying squirrels. Neither this hypothenar cartilage nor the styloform cartilage takes up the alcian blue that stains the hyaline cartilage of carpal bones. The hypothenar pad in flying squirrels is supported by the base of the styloform cartilage, not by a separate hypothenar cartilage. The falciform bone in tree squirrels is incorporated into the transcarpal ligament, but the falciform bone in flying squirrels, and also the styloform-falciform ligament, lies superficial to it.

#### DISCUSSION

The means by which flying squirrels extend the styloform cartilage to form the curved wing tip has been misunderstood (Bryant, 1945; Gupta, 1966; Johnson-Murray, 1977). Bryant (1945) claimed that the abductor pollicis muscle did not insert on the falciform bone in *Glaucomys*, but we saw a falciform insertion on every flying squirrel that we dissected. Gupta (1966) illustrated the insertion of the abductor pol-

licis muscle on the flexor retinaculum and existence of a ligament from the retinaculum to the styloform cartilage. He seems to have misidentified the falciform bone as the flexor retinaculum in his dissections and missed the thin intercarpal ligament lying deep to it. Johnson-Murray (1977) correctly identified and illustrated the styloform-falciform ligament, but she did not remark on the insertion of the abductor pollicis muscle on the falciform bone. She described a small muscle inserting on the distal surface of the styloform cartilage in *Petaurista*, which she identified as the palmaris brevis muscle and attributed to it the function of extending this cartilage. This muscle is variable among genera of flying squirrels, however, so it seems unlikely to function in this way. In our dissections, fibers of the palmaris brevis inserted onto the base of the styloform cartilage, as described by Johnson-Murray (1977), only in *Glaucomys* and *Hylopetes*. In *Petaurista* and *Eoglaucomys*, it inserted into the hypothenar pad; in *Belomys*, it inserted into the fascia of the palm; and in *Pteromys*, it was absent. Thus, in those four genera, the palmaris brevis muscle cannot function to extend the wing tip.

If the hand of an anesthetized flying squirrel is held in the gliding position, the styloform cartilage will not be extended automatically. When the wrist is held abducted and dorsiflexed, flexion of the abductor pollicis longus muscle will cause the wing tip to extend as in life. We contend that this is the mechanism by which living squirrels extend their wing tips. When the wing tip is extended in this way, it forms an airfoil that is held at an upward angle to the plane of the rest of the wing, as can be seen in photographs of gliding squirrels (Muul and Alley, 1963; Walker, 1947, 1975; Wells-Gosling, 1985). The angle at which the wing tip can be held relative to the plane of the rest of the gliding membrane can be controlled by the squirrel by pronating or supinating the forearm, for which flying squirrels have the normal mammalian mus-

cles. Position of the wing tip would appear to be of major aerodynamic significance.

Aerodynamically, three regions of the gliding membrane are very important. The propatagium forms the leading edge of the wing that determines patterns of airflow over the airfoil. The uropatagium forms the trailing edge of the airfoil and is analogous to the rear flaps on the wings of aircraft, which are used to modify the lift and drag of the wing. Flying squirrels can modify the position of the uropatagium by moving their tails up or down. The plagiopatagium is the major surface of the airfoil and probably provides most of the lift. As in all wings, the wing tips of the plagiopatagium have undesirable aerodynamic characteristics. Vortices of wing tips result from airflow over the tip of the wing due to the pressure differential between the upper and lower surfaces, and these vortices produce drag. This induced drag is defined as:  $C_{D,i} = C_L^2 / \pi e AR$ , in which  $C_L$  is the coefficient of lift,  $e$  is the span efficiency factor, and  $AR$  is the aspect ratio (Anderson, 1985). Using values of  $C_L$ ,  $e$ , and  $AR$  from wind tunnel models of aircraft wings (Whitcomb, 1976) and comparing them with estimates of these values for flying squirrels (Scholey, 1986; Thorington and Heaney, 1981), we conclude that induced drag is a more significant aerodynamic problem for flying squirrels than for modern aircraft, by more than an order of magnitude. This results from the fact that the almost-square wing of flying squirrels causes them to have a very low  $AR$ , and the pressure differential between the upper and lower surfaces, which can produce vortices, extends from the wrist to the ankle. Aircraft have narrow wings, much higher  $AR$ , and the pressure differential produces vortices just at the narrow tip. In wind tunnel tests, a National Aeronautics and Space Administration (NASA) winglet (Fig. 1) (Whitcomb, 1976) reduced induced drag by 20% and increased the wing lift-drag ratio by 9%. The up-turned wing tips of flying squirrels should serve a similar function of reducing in-

duced drag by diffusing vortices and directing them away from the edge of the gliding membrane.

Both flying squirrels and the NASA design have a secondary surface that is below and in front of the winglet (Fig. 1). The secondary surface of the NASA wing tip points down and away from the body of the airplane. It significantly increases the lift-drag ratio at high coefficients of lift (Whitcomb, 1976). The secondary surface in flying squirrels is formed by the hands, which are strongly dorsiflexed and abducted, such that palms are held perpendicular to the plane of the gliding membrane and digits are pointed forward and slightly toward the midline. This different orientation of the hand of the flying squirrel probably redirects air flow at the leading edge of the wing tip and may similarly increase the lift-drag ratio.

Retraction of the wing tip is effected by contraction of both the flexor carpi ulnaris and the palmaris longus muscles. This is misrepresented in the literature, in which this role of the palmaris longus muscle is not recognized. Gupta (1966) shows two separate tendons of flexor carpi ulnaris, the first inserting on the pisiform and the second inserting on the proximal end of the styloform cartilage. Johnson-Murray (1977) also describes two tendons of flexor carpi ulnaris, the first inserting solely on the pisiform, the second inserting on both the pisiform and proximal dorsal surface of the styloform cartilage. The purported second tendon of the flexor carpi ulnaris is actually the tendon of palmaris longus and inserts into skin and connective tissue in the region of the hypothenar pad and palmar surface of the base of the styloform cartilage. The innervation of the palmaris longus muscle in squirrels by the ulnar nerve, not by the median nerve as in most other mammals (Woods, 1972), may have contributed to its misidentification.

The styloform cartilage is a unique and distinctive feature of flying squirrels. Gupta (1966) suggested that it was homologous

with an ulnar sesamoid of other rodents, but it is unlikely to be derived from a sesamoid because it is a different type of cartilage. Instead, it appears to be derived from the hypothenar cartilage in the palm of tree squirrels, which bears the same relationship to the pisiform bone and metacarpal V (Fig. 3). Both of these are probably elastic cartilage. The hypothenar cartilage is in close proximity to the transcarpal ligament, which connects pisiform and falciform bones in tree squirrels. The hypothenar pad in flying squirrels is supported by the base of the styliiform cartilage. Therefore, we deduce that the styliiform cartilage has been derived from the hypothenar cartilage of tree squirrels and the styliiform-falciform ligament has been derived from superficial fibers of the transcarpal ligament.

It has been argued and generally accepted that flying squirrels are monophyletic and gliding developed only once among squirrels (Corbet and Hill, 1992; Hoffmann et al., 1993; Thorington, 1984). This hypothesis is being tested and perhaps challenged by molecular data, particularly the cytochrome-b sequence that differs greatly between *Petaurista* and *Glaucomys* (J. M. Mercer and V. L. Roth, in litt.). This indicates that either flying squirrels are diphyletic or the divergence of lineages occurred very early. The latter interpretation is in agreement with the fossil record (Mein, 1970), which suggests that there were already three lineages of flying squirrels during the Miocene. Similar wrist anatomy and the identical mechanism for extending the wing tip in these flying squirrels suggest that these features evolved before the divergence of these lineages, in which case flying squirrels have probably been using winglets in gliding since the Oligocene or Miocene epochs, at least  $20 \times 10^6$  years ago.

#### ACKNOWLEDGMENTS

We thank R. S. Hoffmann, B. J. Stafford, and two anonymous reviewers for helpful comments on earlier versions of the manuscript. We also thank J. D. Anderson for advice on aerodynam-

ics. L. R. Heaney and W. Stanley loaned specimens from the Field Museum of Natural History, and P. Zahler provided us with a *Eupetaurus* wrist for dissection. The figures were drawn by K. Darrow.

#### LITERATURE CITED

- ANDERSON, J. D., JR. 1985. Introduction to flight. 2nd ed. McGraw-Hill, New York, 560 pp.
- BRYANT, M. D. 1945. Phylogeny of Nearctic Scuriidae. *The American Midland Naturalist*, 33:257-390.
- CORBET, G. B., AND J. E. HILL. 1992. The mammals of the Indomalayan region: a systematic review. Natural History Museum Publications, Oxford University Press, Oxford, United Kingdom, 481 pp.
- GUPTA, B. B. 1966. Notes on the gliding mechanism in the flying squirrel. *Occasional Papers of the Museum of Zoology, University of Michigan*, 645:1-7.
- HOFFMANN, R. S., C. G. ANDERSON, R. W. THORINGTON, JR., AND L. R. HEANEY. 1993. Family Scuriidae. P. 419-466, in *Mammal species of the world: a taxonomic and geographic reference* (D. E. Wilson and D. M. Reeder, eds). Second ed. Smithsonian Institution Press, Washington, D.C., 1206 pp.
- JOHNSON-MURRAY, J. L. 1977. Myology of the gliding membranes of some Petauristine rodents (genera: *Glaucomys*, *Pteromys*, *Petinomys*, and *Petaurista*). *Journal of Mammalogy*, 58:374-384.
- MEIN, P. 1970. Les sciuropteres (Mammalia, Rodentia) neogenes d'Europe occidentale. *Geobios*, 3:7-77.
- MUUL, I., AND J.W. ALLEY. 1963. Night gliders of the woodlands: vociferous *Glaucomys* rarely appears. *Natural History Magazine*, 72(5):18-25.
- SCHOLEY, K. 1986. The climbing and gliding locomotion of the giant red flying squirrel, *Petaurista petaurista* (Scuriidae). *Biona*, 5:187-204.
- THORINGTON, R. W., JR. 1984. Flying squirrels are monophyletic. *Science*, 225:1048-1050.
- THORINGTON, R. W., JR., AND L. R. HEANEY. 1981. Body proportions and gliding adaptations of flying squirrels (Petauristinae). *Journal of Mammalogy*, 62:101-114.
- THORINGTON, R. W., JR., A. L. MUSANTE, C. G. ANDERSON, AND K. DARROW. 1996. Validity of three genera of flying squirrels: *Eoglaucmys*, *Glaucomys* and *Hylotetes*. *Journal of Mammalogy*, 77:69-83.
- WALKER, E. P. 1947. "Flying" squirrels, nature's gliders. *National Geographic*, 91:662-674.
- . 1975. *Mammals of the world*. Third ed. Johns Hopkins University Press, Baltimore, Maryland, 1500 pp.
- WELLS-GOSLING, N. 1985. Flying squirrels: gliders in the dark. Smithsonian Institution Press, Washington, D.C., 128 pp.
- WHITCOMB, R. T. 1976. A design approach and selected wind-tunnel results at high subsonic speeds for wing-tip mounted winglets. National Aeronautics and Space Administration Technical Note, D-8260: 1-30.
- WOODS, C. A. 1972. Comparative myology of the jaw, hyoid, and pectoral appendicular regions of New and Old World hystricomorph rodents. *Bulletin of the American Museum of Natural History*, 147:115-198.

Submitted 12 February 1997. Accepted 15 April 1997.

Associate Editor was Robert K. Rose.