

# Chapter 19

## Avian Pox

### Synonyms

*Fowl pox, avian diphtheria, contagious epithelioma, and poxvirus infection*

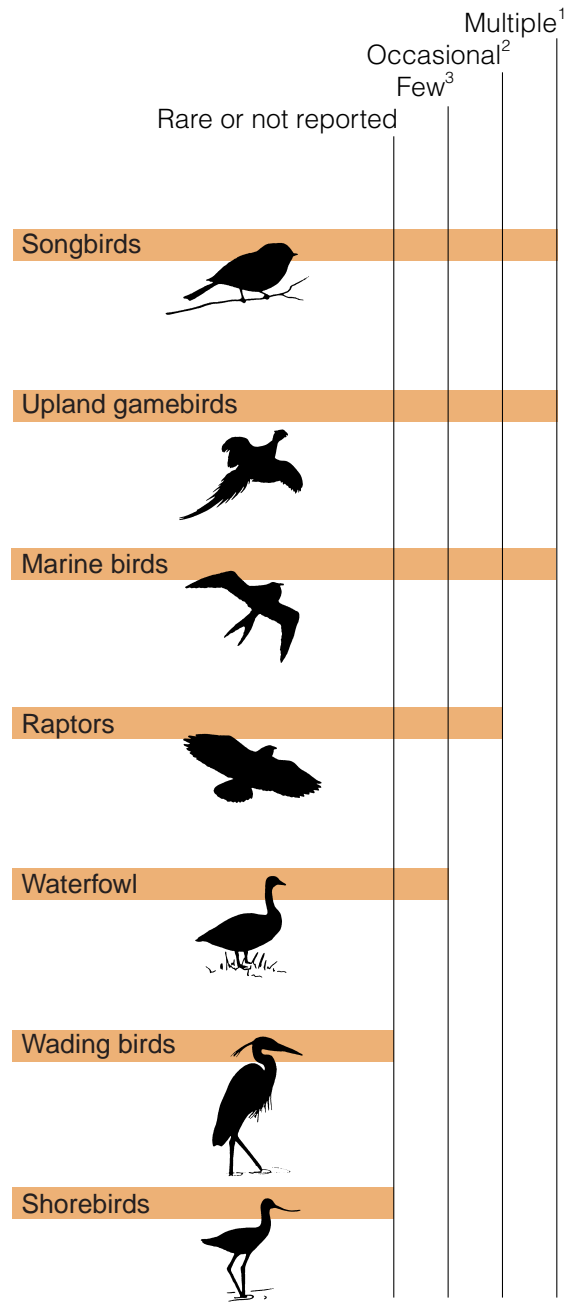
### Cause

Avian pox is the common name for a mild-to-severe, slow-developing disease of birds that is caused by a large virus belonging to the avipoxvirus group, a subgroup of poxviruses. This group contains several similar virus strains; some strains have the ability to infect several groups or species of birds but others appear to be species-specific. Mosquitoes are common mechanical vectors or transmitters of this disease. Avian pox is transmitted when a mosquito feeds on an infected bird that has viremia or pox virus circulating in its blood, or when a mosquito feeds on virus-laden secretions seeping from a pox lesion and then feeds on another bird that is susceptible to that strain of virus. Contact with surfaces or exposure to air-borne particles contaminated with poxvirus can also result in infections when virus enters the body through abraded skin or the conjunctiva or the mucous membrane lining that covers the front part of the eyeball and inner surfaces of the eyelids of the eye.

### Species Affected

The highly visible, wart-like lesions associated with the featherless areas of birds have facilitated recognition of avian pox since ancient times. Approximately 60 free-living bird species representing about 20 families have been reported with avian pox. However, the frequency of reports of this disease varies greatly among different species (Fig. 19.1). Avian pox has rarely been reported in wild waterfowl, and all North American cases have been relatively recent (Table 19.1). The first case was in a free-living green-winged teal in Alaska. Single occurrences have also been documented in a Canada goose in Ontario, Canada, a mallard duck in Wisconsin, a feral mute swan cygnet in New York, and a tundra swan in Maryland. Three cases in American goldeneye have been reported in Saskatchewan, Canada, and New York. Avian pox also appeared in Wisconsin among captive-reared trumpeter swans that were part of a reintroduction program. Zoological garden cases include common scoter in the Philadelphia Zoo and a Hawaiian goose in the Honolulu Zoo.

Avian pox in a bald eagle was first diagnosed in 1979 in Alaska and it was a lethal infection. Since then, additional bald eagles in Alaska and at other locations have been diagnosed with this disease (Fig. 19.2). The severity of infection resulted in several of these cases being lethal. Poxvirus infections have been reported in other raptors, most recently



<sup>1</sup>Reports often involve a number of birds in a single event.

<sup>2</sup>Reports tend to involve individuals rather than groups of birds.

<sup>3</sup>Small number of reports, generally involving individual birds.

**Figure 19.1** Reported avian pox occurrence in wild birds in North America.

**Table 19.1** Waterfowl in North America reported to have avian pox.

Species	Locations	Year of first report in species
Harlequin duck	Alaska	1994
Blue-winged teal	Wisconsin	1991
Wood duck	Wisconsin	1991
Redhead duck	Wisconsin	1991
Trumpeter swan	Wisconsin	1989
Common goldeneye	New York	1994
	Saskatchewan	1981
Tundra swan	Maryland	1978
Green-winged teal	Alaska	1978
Mallard	Wisconsin	1978
Canada goose	Ontario	1975
Common scoter	Pennsylvania	1967
Mute swan	New York	1964

(Fig. 19.3) frequently have been reported to have been struck by avian pox epizootics. Avian pox is suspected as a factor in the decline of forest bird populations in Hawaii and northern bobwhite quail in the southeastern United States, where it is also an important disease of wild turkey.

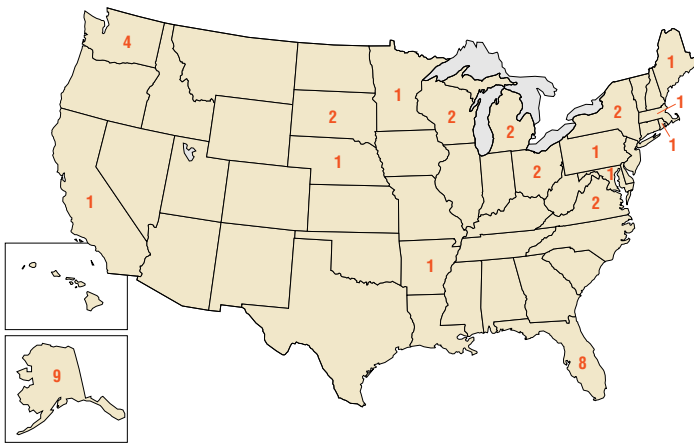
## Distribution

Avian pox occurs worldwide, but little is known about its prevalence in wild bird populations. The increased frequency of reported cases of this highly visible disease and the involvement of new bird species during recent years suggests that avian pox is an emerging viral disease. Birds can become disease carriers and spread avian pox among local populations, such as between birdfeeding stations, and along migratory routes used by various bird species. Mosquitoes that feed on birds play the most important role for both disease transmission and long term disease maintenance. However, contamination of perches and other surfaces used by captive birds can perpetuate disease in captivity. Pox outbreaks are commonly reported at aviaries, rehabilitation centers, and other places where confinement provides close contact among birds. The disease can spread rapidly when avian pox is introduced into such facilities. Species that would not ordinarily have contact with avian pox virus in the wild often become infected in captivity if the strain of virus present is capable of infecting a broad spectrum of species. Common murre rescued from an oil spill in California developed pox-virus lesions while they were in a rehabilitation center. Endangered avian species also have been infected during captive rearing.

## Seasonality

Although wild birds can be infected by pox virus year-round (Fig. 19.4), disease outbreaks have been associated with the environmental conditions, the emergence of vector populations, and the habits of the species affected. Environmental factors such as temperature, humidity, moisture, and protective cover all play a role in the occurrence of this disease by affecting virus survival outside of the bird host. Avian pox virus can withstand considerable dryness, thereby remaining infectious on surfaces or dust particles. Mosquitoes that feed on birds are the most consistent and efficient transmitters of this disease. Mosquito populations are controlled by breeding habitat and annual moisture.

The time of appearance and magnitude of vector populations varies from year to year, depending on annual weather conditions. This influences the appearance and severity of the disease in any given year. Only limited studies have been carried out to assess the relations between avian pox and insect vector populations. Studies on the Island of Hawaii disclose a close relation between the prevalence of poxvirus infections in forest birds and seasonal mosquito cycles. The lowest prevalence of pox virus infection in California quail in Oregon was reported in the dry summer months and the



**Figure 19.2** Number of bald eagles with cutaneous pox by State, 1979–97. (From National Wildlife Health Center records.)

in the eastern screech owl and barred owl in Florida (Table 19.2).

On Midway Atoll, large numbers of colonial nesting birds, such as the Laysan albatross, have become infected with avian pox. Red-tailed tropicbirds on Midway Atoll previously had been affected by avian pox. The shift in predominant species infected relates to the dramatic shift in population densities for the two species over time (1963–1978). Mourning dove, finches, and other perching birds using backyard feeders

highest was reported during the wetter fall and winter months. In Florida, reports of avian pox in wild turkey correspond to the late summer and early fall mosquito season. On Sand Island of the Midway Atoll, avian pox was first reported in September 1963 in the nestlings of the red-tailed tropicbird. In March and April of the late 1970s, this disease was found in nestling Laysan albatross on Sand Island. This is an example of disease seasonality influenced by dramatic shifts in predominant species populations.

Birdfeeding stations have been the source of numerous poxvirus outbreaks in the continental United States (Fig. 19.3). Contact transmission of the virus through infected surfaces and close association of birds using those feeders is the likely means of transmission during cooler periods of the year when mosquitoes are not a factor, and birdfeeders provide additional sources of infection when mosquitoes are present.

### Field Signs

Birds with wart-like nodules on one or more of the featherless areas of the body, including the feet, legs, base of the beak, and eye margin should be considered suspect cases of avian pox (Fig. 19.5). The birds may appear weak and emaciated if the lesions are extensive enough to interfere with their feeding. Some birds may show signs of labored breathing if their air passages are partially blocked. Although the course of this disease can be prolonged, birds with extensive lesions are known to completely recover if they are able to feed.

### Gross Lesions

Avian pox has two disease forms. The most common form is cutaneous and it consists of warty nodules that develop on the featherless parts of the bird. This form of the disease is usually self-limiting; the lesions regress and leave minor scars. However, these nodules can become enlarged and clustered, thus causing sight and breathing impairment and feeding difficulty (Figs. 19.6A and B). Secondary bacterial and other infections are common with this form of the disease, and these infections can contribute to bird mortality. In some birds, feeding habits result in the large warty nodules becoming abraded and then infected by bacterial and fungal infections (Figs. 19.6C and D).

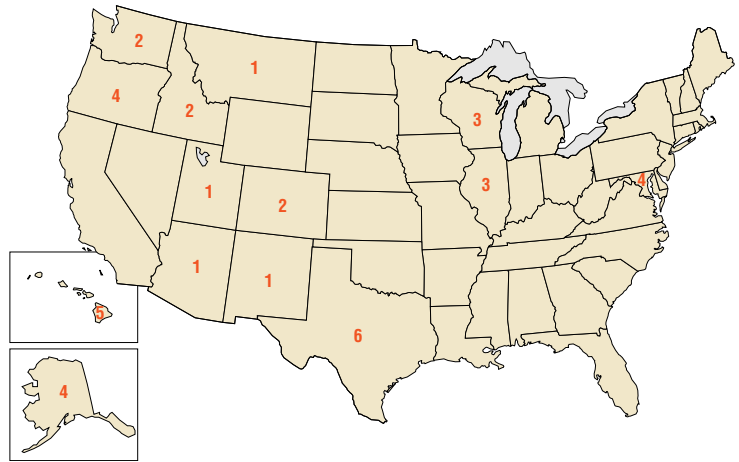
The internal form of disease is referred to as wet pox and it is primarily a problem of young chickens and turkeys. This diphtheritic form appears as moist, necrotic lesions on the mucus membranes of the mouth and upper digestive and respiratory tracts (Fig. 19.7), and it has occasionally been reported in wild birds (Fig. 19.8). This form of avian pox probably occurs more frequently in wild birds than it is reported because it is less observable than the cutaneous form. Also, the more severe consequences of wet pox undoubtedly causes greater morbidity and mortality, thereby leading to removal of infected birds by predators and scavengers.

**Table 19.2** *Birds of prey from North America reported to have contracted avian pox.*






Species	Locations	Year of first report in species	
Barred owl	Florida	1995	
	Bald eagle	Maine	1995
		Ohio	1995
		Rhode Island	1993
		Michigan	1992
		Minnesota	1989
		California	1987
		Nebraska	1987
		Maryland	1986
		Massachusetts	1986
		South Dakota	1986
		Wisconsin	1986
		Pennsylvania	1985
		Arkansas	1984
		New York	1983
Florida		1982	
Virginia	1981		
Washington	1981		
Alaska	1978		
Eastern screech owl	Florida	1994	
Peregrine falcon	New York	1994	
Ferruginous hawk	Texas	1993	
Golden eagle	Missouri	1989	
	Kansas	1986	
	California	1976	
	British Columbia	1970	
Red-tailed hawk	Nebraska	1988	
	Wisconsin	1985	
	Washington	1981	
	Missouri	1970	
Rough-legged hawk	North Dakota	1971	

### Diagnosis

A presumptive diagnosis of avian pox can be made from the gross appearance of the wart-like growths that appear on body surfaces. However, these observations must be confirmed by examining lesions microscopically for character-



**Figure 19.3** Number of avian pox outbreaks involving passerines at birdfeeding stations by State, 1975–79. (National Wildlife Health Center Database.)

Species group	Season			
	Spring	Summer	Fall	Winter
Marine birds 	●	○	●	
Raptors 	○	○	○	○
Upland gamebirds 		○	●	●
Songbirds 	○	○		●
Hawaiian forest birds 		○	●	●

High prevalence of infection ●  
 Low prevalence of infection ○

**Figure 19.4** Seasonal avian pox outbreaks in wild birds.



Photo by Wallace Hansen

**Figure 19.5** (A) Avian pox lesions typically are found on featherless parts of the body. This Laysan albatross chick has small pox nodules on the face and eyelid. (B) As the disease progresses, these lesions become more extensive. (C) Lesions also are commonly seen on the legs and (D) feet.

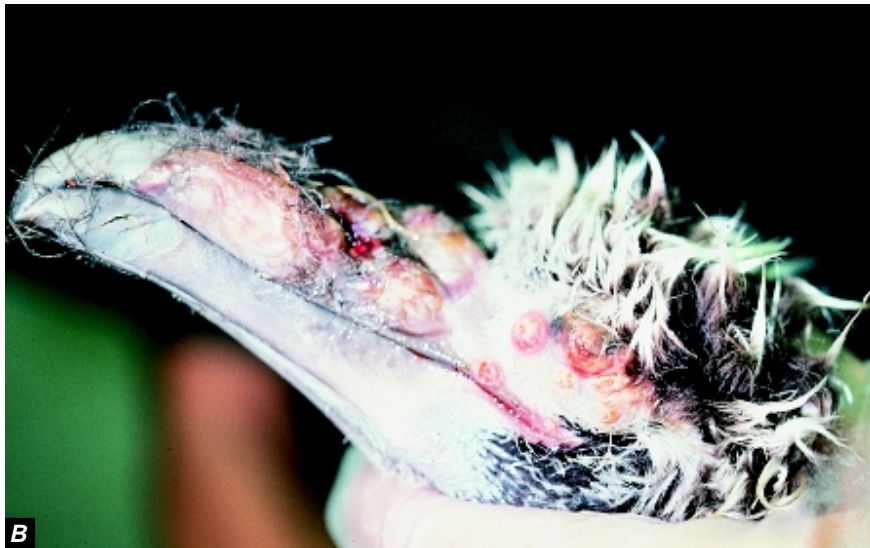

Photo by Milton Friend

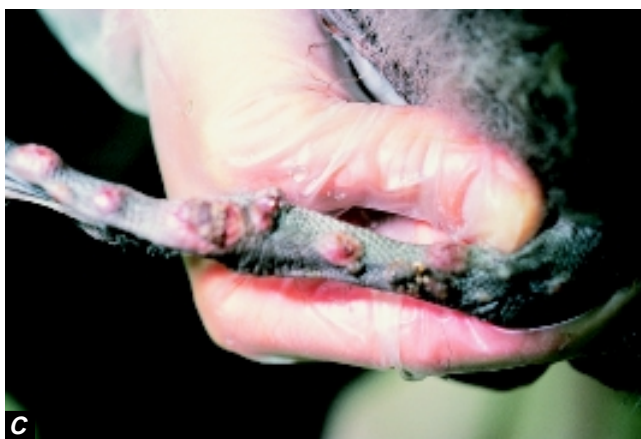

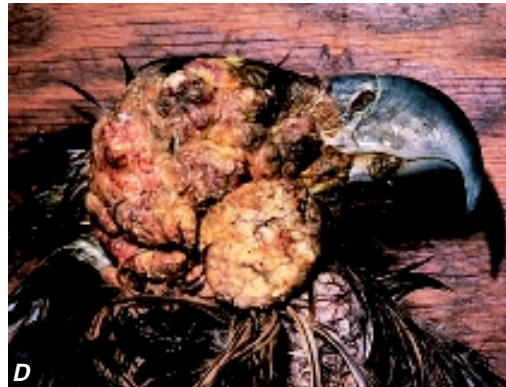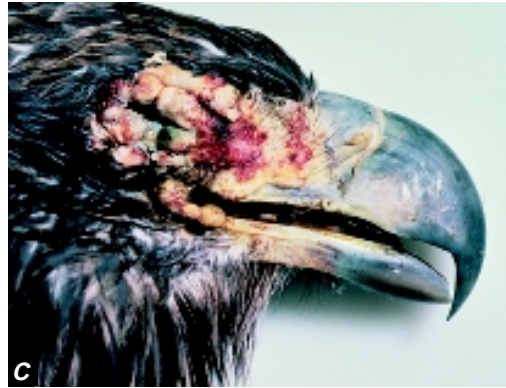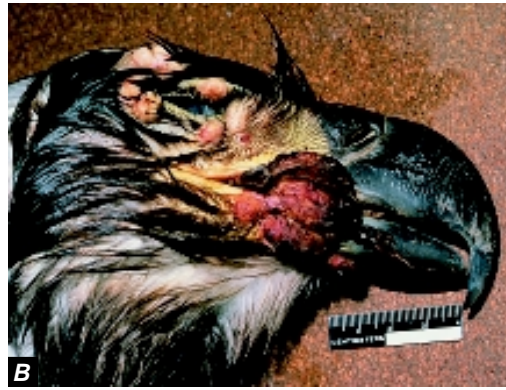Photo by Milton Friend



Photo by Wallace Hansen



Photos by James Rummigen



**Figure 19.6** Pox lesions can be so extensive that they impair breathing, sight, and feeding as seen in these bald eagles: (A) extensive infection of both sides of the face, (B) obstruction to feeding due to the size and location of these lesions at the base of the bill, and (C) obstruction of sight due to complete occlusion of the eye. (D) Massive facial lesions often become abraded and subject to secondary infections.

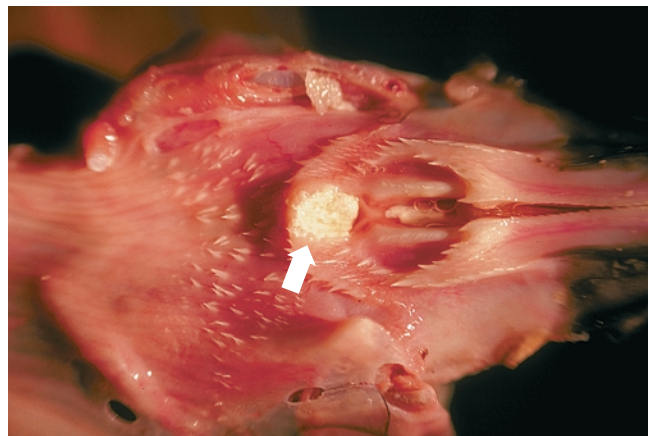





Photo by Lou Sileo

**Figure 19.7** Diphtheritic form of avian pox (arrow) in a Laysan albatross at Midway Atoll.

Species group	Species
Marine birds 	White-tailed tropicbird Laysan albatross Common murre
Upland gamebirds 	Morning dove Ruffed grouse Northern bobwhite quail
Songbirds 	Bullfinch House finch

**Figure 19.8** Wild bird species in which wet pox has been reported.

istic cellular inclusion bodies. Avian pox is confirmed by virus isolation and serological identification. Submit the whole bird or the affected body part (for example, the feet or head) to a disease diagnostic laboratory that has virus isolation capabilities. Immediately freeze samples that must be held for more than 24 hours before shipment. Virus isolation can be attempted from a live bird by collecting samples from the affected area. However, consult with the diagnostic laboratory staff before collecting samples.

## Control

The fundamental principle for controlling avian pox is to interrupt virus transmission. The difficulty in applying control procedures is related to the type of transmission taking place, the mobility of the infected birds, and the size of the affected area. The more confined a population at risk, the more effective the control procedures will be. Therefore, prevention is the first method for controlling this disease. Vector control (primarily mosquitoes) in and around the disease area should be considered first. Identifying and eliminating vector breeding and resting sites together with controlling adult mosquito populations are most desirable. Removing heavily infected animals is also helpful because it diminishes the source of virus for vector populations. This also reduces the opportunity for contact transmission between infected and noninfected birds.

Special vigilance of captive birds is needed, especially when threatened and endangered species are involved. Because poxvirus is resistant to drying, disease transmission by contaminated dust, food, perches, cages, and clothing can pose a continuing source of problems. Therefore, these items

need to be decontaminated with disinfectant, such as a 5 percent bleach solution, before they are disposed of or reused.

The poultry industry uses modified live vaccines to prevent avian pox, but their safety and effectiveness in wild birds have not been determined. In addition, strain differences in the virus, host response to those different strains, and logistical problems of a vaccination program further complicate using vaccines for wild birds. The greatest potential use of vaccination is for protecting captive-breeding populations of threatened and endangered species and for providing immunity in birds that are to be released into areas where pox is a problem.

## Human Health Considerations

Avian poxvirus is part of a larger family of poxviruses that includes the human disease known as variola or smallpox. However, there is no evidence that avipoxviruses can infect humans.

*Wallace Hansen*

## Supplementary Reading

- Karstad, L., 1971, Pox, in Davis, J.W. and others, eds., *Infectious and parasitic diseases of wild birds*: Ames, Iowa, Iowa State University Press, p. 34–41.
- Kirmse, P., 1967, Pox in wild birds: an annotated bibliography: *Journal of Wildlife Diseases*, v. 3, p. 14–20.

