
SEER Program

Self Instructional Manual for Cancer Registrars
Human Anatomy as Related to Tumor Formation

Book Four

Second Edition

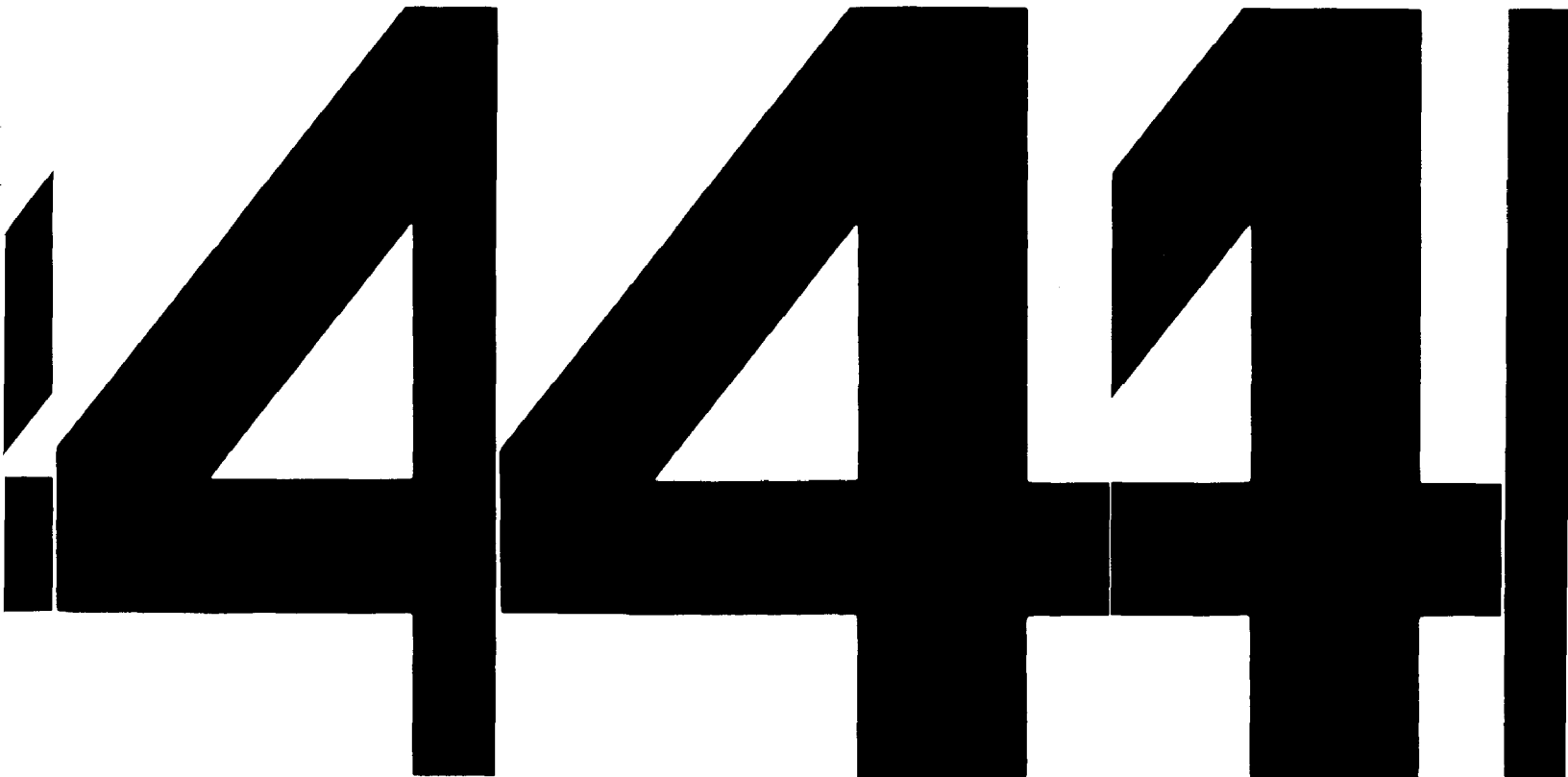4444

SEER Program

**Self Instructional Manual for Cancer Registrars
Human Anatomy as Related to Tumor Formation**

Book Four

Second Edition



SEER PROGRAM
SELF-INSTRUCTIONAL MANUAL FOR CANCER REGISTRARS

Book 4 - Human Anatomy as Related to Tumor Formation

Second Edition

Prepared by:

**SEER Program
Cancer Statistics Branch
National Cancer Institute**

Editor in Chief:

**Evelyn M. Shambaugh, M.A., CTR
Cancer Statistics Branch
National Cancer Institute**

Assisted by Self-Instructional Manual Committee:

**Dr. Robert F. Ryan, Emeritus Professor of Surgery
Tulane University School of Medicine
New Orleans, Louisiana**

**Mildred A. Weiss
Los Angeles, California**

**Mary A. Kruse
Bethesda, Maryland**

**Jean Cicero, ART, CTR
Health Data Systems Professional Services
Riverdale, Maryland**

**Pat Kenny
Medical Illustrator for
Division of Research Services
National Institutes of Health**

CONTENTS

BOOK 4: HUMAN ANATOMY AS RELATED TO TUMOR FORMATION

	Page
Section A--Objectives and Content of Book 4	1
Section B--Terms Used to Indicate Body Location and Position	5
Section C--The Integumentary System	19
Section D--The Lymphatic System	51
Section E--The Cardiovascular System	97
Section F--The Respiratory System	129
Section G--The Digestive System	163
Section H--The Urinary System	241
Section I--The Reproductive System	271
Section J--The Endocrine System	327
Section K--The Skeletal System	341
Section L--The Muscular System	375
Section M--The Nervous System	391
Section N--Sensory Organs	409
Appendix A--Histologic Type/Primary Site	439
Appendix B--Rules for Determining Multiple Primaries For Lymphatic and Hematopoietic Disease	443
Appendix C--Other ICD-O-2 Codes To Be Considered One Primary When Determining Multiple Primaries	469
Selected Bibliography	473
Index	477

ILLUSTRATIONS (Figures 1-82)

	Page
Section B	
1A. Planes of Reference and Directional Terms	7
1B. Main Body Cavities	11
2. Abdominal Quadrants	13
3. Anatomic Divisions of the Abdomen	14
Section C	
4A. Layers of the Epidermis	22
4B. Layers of the Skin: Epidermis and Dermis	23
5. Clark's Classification of Malignant Melanoma	41
6. Lymphatics of the Skin	47
Section D	
7. Relationship Between the Blood and Lymph Circulating Systems	53
8A-8B. Lymphatic Drainage of Various Parts of the Body	58
9A-9B. Structure of a Lymph Node	61
10. Spleen	67
11. Thymus Gland	67
12A. Lymph Nodes of the Head and Neck	73
12B. Lymph Nodes of the Thorax	77
13. Lymph Nodes of the Abdomen and Pelvis	80
Section E	
14A. Blood Flow Through the Body	98
14B. Heart	99
14C. Muscle Wall of Heart	99
14D. Blood Flow Through Heart	100
14E. Portal Circulation	100
Section F	
15. Respiratory System	131
16. Nasopharyngeal Region and Paranasal Sinuses	139
17A. Larynx	143
17B. The Anatomic Subsites of the Larynx	144
18. Lungs	153
Section G	
19. Principal Parts of the Digestive System	165
20. Structure of the Intestinal Wall	166
21. Oral Cavity	169
22. Lips	170
23. Dorsal Surface of Tongue	173
24. Floor of Mouth	177
25. Gingiva	178
26. Hard and Soft Palates	181
27. Salivary Glands	185

ILLUSTRATIONS (Figures 1-82, cont'd)

	Page
Section G (cont'd)	
28. Oral Cavity Lymph Node Regions	192
29. Oropharynx and Hypopharynx	193
30. Divisions of the Esophagus	203
31. Measurements of the Esophagus (from the incisors to the stomach)	204
32. Esophageal Lymph Nodes	205
33. Cross-Section of Esophagus	205
34. Stomach and Adjoining Structures	209
35. Structure of Colonic Wall	220
36. Relationship of Bowel Wall and Serosa to Pericolic/Mesenteric Fat	220
37. Lymphatic Drainage of the Colon and Rectum	222
38. Biliary System	230
Section H	
39. Principal Parts of the Urinary System	242
40. Kidney	243
41. A Nephron	248
42. Urinary Bladder	261
43. Lymphatic Drainage of the Bladder	263
Section I	
44. Female Pelvis (frontal view)	272
45. Female Pelvis (sagittal view)	273
46. Breast (sagittal view)	297
47. Quadrants of the Breast	301
48. Male Pelvis (sagittal view)	312
49. Testis (sagittal view)	313
50. Prostate Gland (sagittal view)	317
51. Prostate Gland (frontal view)	318
52. Lymphatic Drainage of the Prostate and Testes	322
Section J	
53. Endocrine Glands	328
54. Thyroid Gland and Parathyroid Glands	332
55. Pineal Gland	332
56. Adrenal Gland	334
57. Thymus Gland	334

ILLUSTRATIONS (Figures 1-82 cont'd)

Section K

58.	Axial Skeleton	342
59.	Osseous Tissue	347
60.	Hyaline Cartilage	347
61.	Classification of Bones	351
62.	Haversian System of the Bone, Adult Femur	355
63.	Cranial Bones	359
64.	Facial Bones	360
65.	Bones of the Thorax	362
66.	Vertebral Column	362
67.	Appendicular Skeleton	366

Section L

68.	Muscle Types	376
69.	Histological Comparisons of Muscle Types	378

Section M

70.	Nerve Cell (neuron)	394
71.	Cerebrum	398
72.	Spinal Cord	398
73.	Diagram Showing Brain, Ventricles, Meninges, Intermeningeal spaces	400
74.	Cranial Nerves	402

Section N

75.	Eye	415
76.	Eyeball (sagittal view)	419
77.	Eyeball (frontal view)	419
78.	Lacrimal Apparatus	419
79.	Lymphatic Drainage of the Head (sensory organs)	423
80.	Tongue: Areas of Taste	428
81.	Nose: Olfactory Receptors	431
82.	Ear: Coronal Section	435

ACKNOWLEDGEMENTS

Portions of Book 4 were originally prepared for the Louisiana Regional Medical Program under the direction of C. Dennis Fink, Ph.D., Program Director, HumRRO, and Robert F. Ryan, M.D., Chairman, School of Medicine, Tulane University, who served as Technical Advisor to HumRRO.

We would like to thank one person in particular for his careful review of this text and his guidance and support. His suggestions have contributed much to this manual. We deeply appreciate the assistance of J. David Bergeron, Assistant Professor, Department of Natural Sciences, Longwood College, Farmville, Virginia.

The Committee members gratefully acknowledge the continuing assistance of Dr. Charles E. Platz, Associate Professor, Department of Pathology, College of Medicine, University of Iowa, Iowa City, Iowa, as our advisor.

SECTION A
OBJECTIVES AND CONTENT OF BOOK 4

SECTION A

OBJECTIVES AND CONTENT OF BOOK 4

The purpose of this book is to introduce you to human anatomy and to the neoplasms associated with the various anatomical structures. If you thoroughly studied Book 3, *The Composition of Medical Terms*, you will be prepared for the anatomical terms you will encounter in this book. If you acquire a good background in anatomy, your work in abstracting will become easier. However, these manuals can give you only a cursory glance at human anatomy. You will need to supplement your knowledge with independent study. A bibliography of suggested texts and references is provided at the end of this manual.

You will recall from the chapter on "Derivation of Cells and Tissues" (Section E of Book 2) that as the cells of the embryo divide, they change their shape, structure, and their relationship to each other to form three embryonic layers. From these three layers develop all the tissues, organs, and organ systems of the body, each of which is specialized for the performance of specific functions.

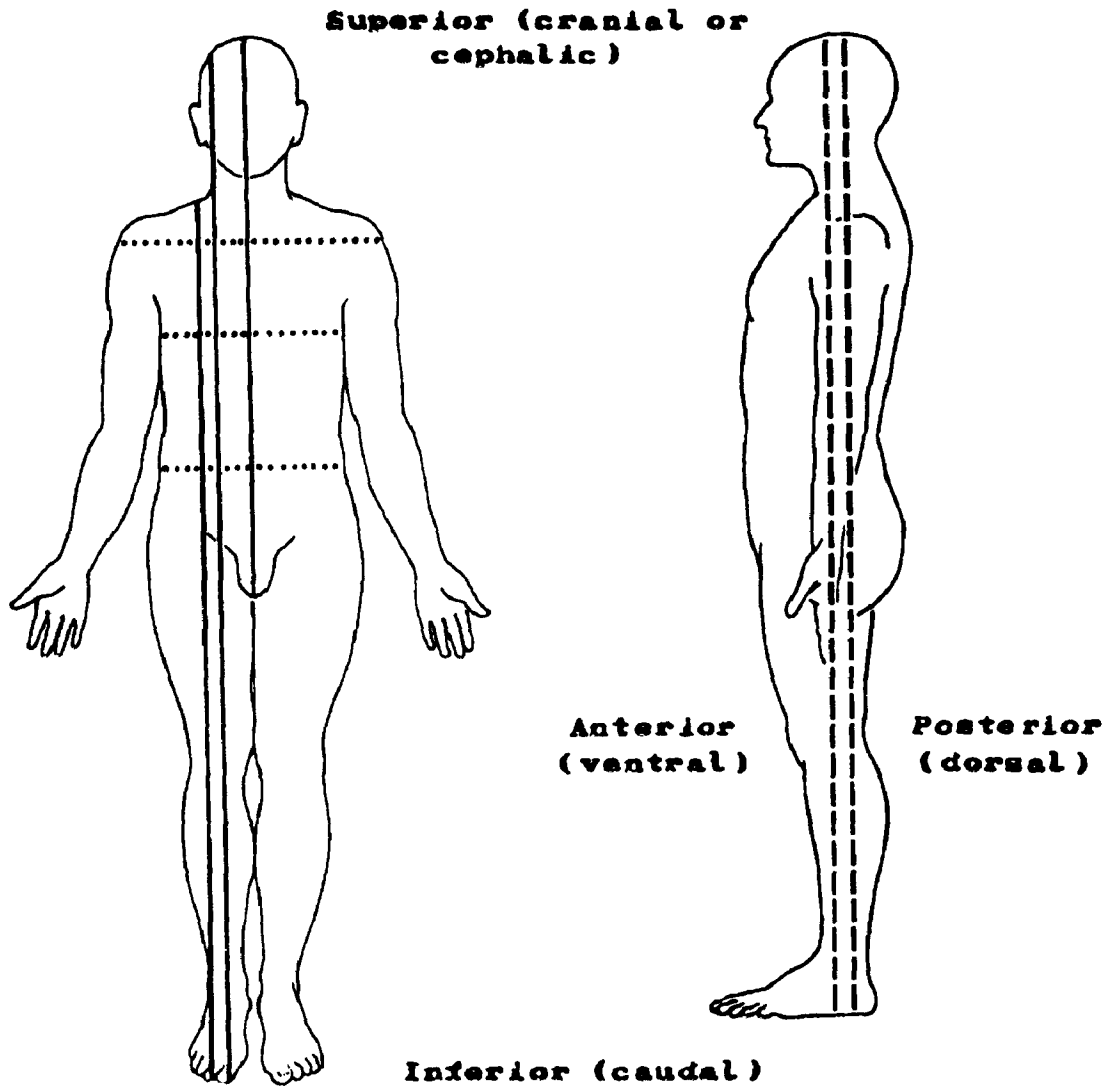
Our study of anatomy will begin with the integumentary system (skin and its derivatives) followed by the lymphatic, cardiovascular, respiratory, and digestive systems and continue with the urinary, reproductive, endocrine, skeletal, muscular, nervous systems, and the sensory organs. However, as an introduction to human anatomy, you will first study terms describing location and position within the body.

SECTION B

TERMS USED TO INDICATE BODY LOCATION AND POSITION

SECTION B

TERMS USED TO INDICATE BODY LOCATION AND POSITION



Solid lines = sagittal, midsagittal (median)
Dotted lines = transverse (horizontal)
Dashed lines = frontal (coronal)

Figure 1A. PLANES OF REFERENCE AND DIRECTIONAL TERMS

SECTION B

TERMS USED TO INDICATE BODY LOCATION AND POSITION

Positional Terms

There are a number of words commonly used to describe body location such as, posterior (in back of), anterior (in front of), lateral (at the side of), and medial (near the middle of). There are also prefixes which are commonly used to describe location and position. As examples, the prefix *bi* means "both" or "double," therefore, the term bilateral means "affecting both (two) sides." The prefix *para* means "beside, near or adjacent," *sub* means "under," and *supra* means "above or over."

To understand the verbal descriptions contained within a medical record, it is necessary to know the meaning of words and prefixes which refer to location and position. This will enable you to abstract more accurately the reports contained in a medical record.

Some positional terms refer to the location of an anatomical part relative to another body part or location. The reference may be general; for example, *cephal(o)* is used as a prefix to denote "towards the head." *Caudal* is often used as a prefix to denote "towards the tail (feet)."

Sometimes the location reference may be quite specific. For example, the reference may denote a body organ or a specific structure such as the heart, *cardi(o)*, or the rectum, *proct(o)*.

There is no need for you to memorize long lists of these terms. As you encounter them, look them up in your medical dictionary or in a book on medical terminology. Before long, you will be familiar with most of them. It is recommended that every registry purchase at least one book on medical terminology.

Anatomical Position

By world-wide agreement, the position of body organs and structures is described as though the body were in *anatomical position*, that is, standing, looking straight ahead, arms at the side with palms of the hands facing frontward (see Figure 1A).

The following list gives the "directional planes" and some of the relative positional terms used to describe anatomical location. You are most apt to encounter these terms while reading an operative record (report of surgery). Also, these terms often are used in the physical examination (see Figure 1A).

Directional Planes of the Body

Sagittal plane	Any vertical section of the body which divides it into right and left portions.
Midsagittal plane (Median)	A vertical section at the midline of the body such that the body is divided into equal right and left halves.
Frontal plane (Coronal)	A vertical section of the body dividing it into front (anterior) and back (posterior) portions.
Transverse plane (Horizontal)	Any horizontal section of the body dividing it into upper and lower portions.

Cavities of the Body

The spaces within the body which contain the internal organs are called the body cavities. There are two main body cavities: the dorsal cavity and the ventral cavity (see Figure 1B).

- The *dorsal cavity* is divided into:

The *cranial cavity* containing the brain and the *vertebral cavity* containing the spinal cord. Protective membranes covering the brain and spinal cord are called meninges.

- The *ventral cavity* is divided by the diaphragm into:

The *thoracic* and *abdominopelvic cavities*.

The *thoracic cavity* is subdivided into the right and left *pleural portions* and the *pericardial* portion. The pleural portions contain the lungs covered by serous membranes called pleurae. The pericardial portion encompasses the heart. In addition to the heart, the area between the lungs (called mediastinum) contains the trachea, esophagus, thymus, blood vessels, and lymphatic vessels and nodes.

The *abdominopelvic cavity* is subdivided into the *abdominal portion* containing the liver, gallbladder, stomach, spleen, pancreas, small and large intestines, kidneys, ureters; and the *pelvic portion* containing the bladder, rectum, sigmoid colon, and reproductive organs. Supportive and protective serous membranes covering these organs are classified, in general, as peritoneum.

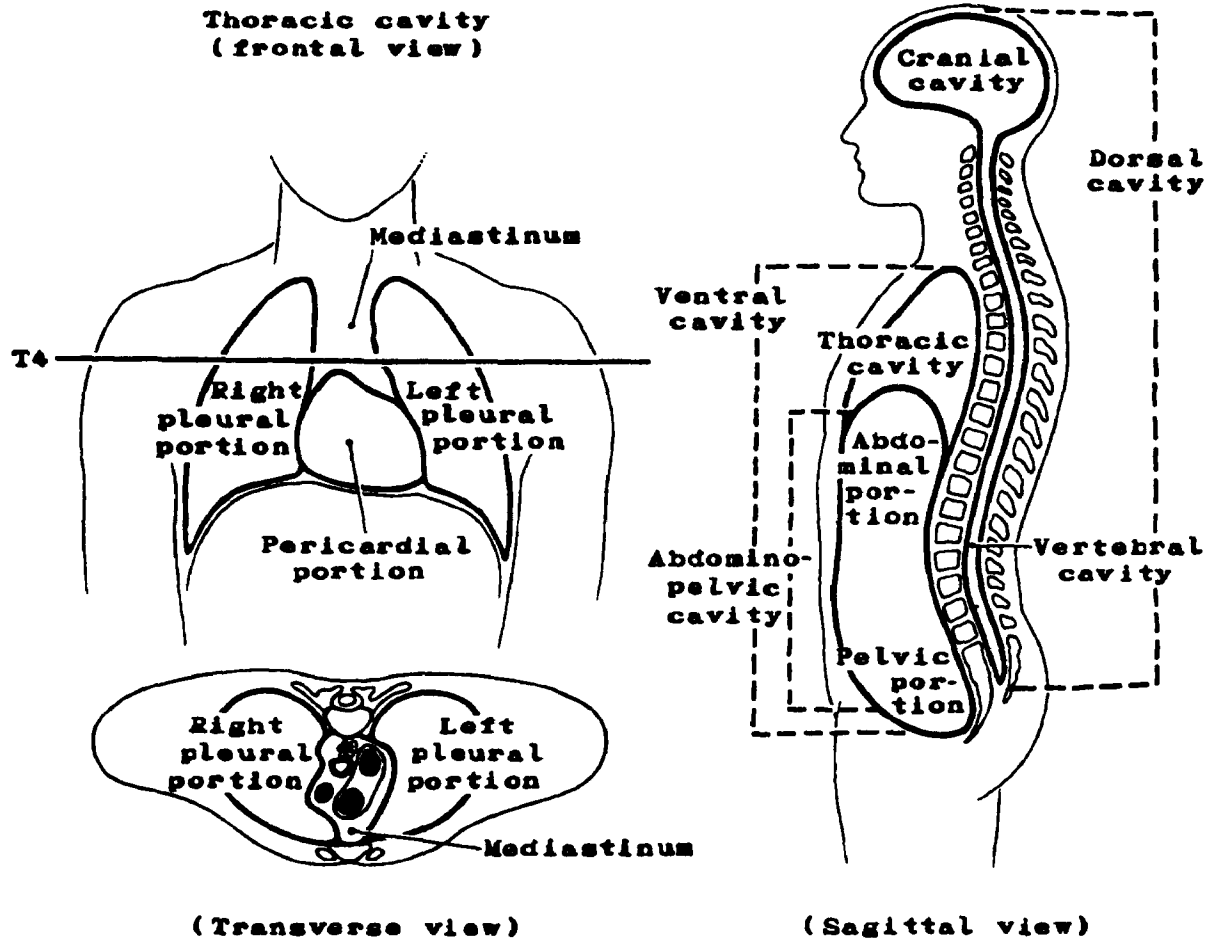


Figure 1B. MAIN BODY CAVITIES

Relative Positional and Directional Terms

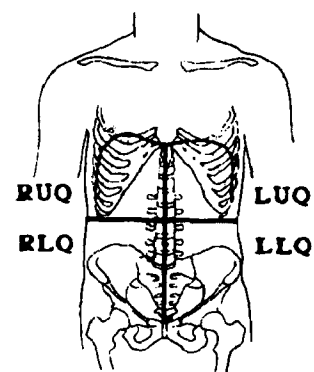
Anterior (ventral)	Refers to the front (frontal plane) of or abdominal portion of the body. The trachea lies anterior (ventral) to the esophagus. Note: In official anatomical nomenclature the terms anterior and ventral are used in reference to the ventral or belly surface of the body. When speaking about the trunk of the body, the term anterior or ventral can be used to mean "in front of." However, for parts of the head, the ventral structure is the underside or the side nearer to the belly. For instance, the ventral surface of the brain is the lower surface.
Posterior (dorsal)	Refers to the rear or back of the body. The kidneys are posterior (dorsal) to the stomach.
Superior (cranial or cephalic)	Refers to points nearer to or towards the head. The heart is superior to the stomach.
Inferior (caudal)	Refers to points nearer to or towards the tail or feet. The pancreas is inferior (caudal) to the heart.
Medial	Refers to a position nearer the middle (midsagittal plane) of the body. The heart is medial to the lungs.
Lateral	Refers to positions to the side of the body, to positions farther away from the midsagittal plane. The ascending colon is lateral to the small intestine; the lungs are lateral to the heart.
Proximal	Refers to positions nearer the origin, an attachment, or a reference point. The cecum is proximal to the ascending colon.
Distal	Refers to positions farther away from the origin, a reference point, source, or attachment. The rectum is located at the distal end of the digestive system.
Superficial	Refers to locations near the surface of the body or a specific organ. Most palpable lymph nodes are located superficially.
Deep	Refers to locations within the body or organ. Lymph nodes which drain organs and structures located in the abdominal cavity are deep nodes.

External	Refers to locations which are toward the outside of a body or a specific organ, or outside a reference point. The ribs are external to the thoracic cavity.
Internal	Refers to locations which are within the inner portion of the body, a specific organ, or a reference point. Internal may be synonymous with deep. The lungs are an internal reference point deep within the body.
Central	Refers to the primary parts of the central nervous system (the brain and spinal cord) or to any axis of symmetry.
Peripheral	Refers to that part of a system outside the central portion. The peripheral nervous system refers to the nerves connecting the central nervous system to all other parts of the body. A peripheral lesion is located away from (medially, laterally, superior or inferior to) the middle of the organ.
Parietal	Refers to the walls of a cavity. The parietal pleura is that portion of the pleura closest to the chest wall.
Visceral	Refers to the organs within the thoracic and abdominopelvic cavities. The visceral pleura is that portion of the pleura investing the lungs themselves.
Quadrant (quarter)	One of the four corresponding parts, regions, or quarters into which the body or its parts may be divided for a more precise reference, such as the abdomen or each breast.

The abdominal quadrants¹ are abbreviated as follows:

- RUQ - right upper quadrant
- RLQ - right lower quadrant
- LUQ - left upper quadrant
- LLQ - left lower quadrant

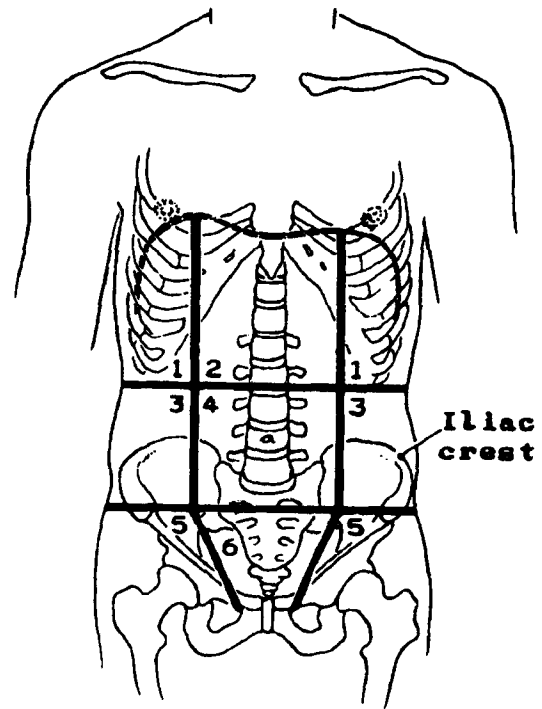
Figure 2. ABDOMINAL QUADRANTS



¹See Section I, The Reproductive System, for specific use of quadrant location for cancers of the breast.

Figure 3. ANATOMIC DIVISIONS OF THE ABDOMEN

1. Hypochondriac regions (upper lateral regions)
2. Epigastric region (upper mid-region medial to the hypochondriac regions)
3. Lumbar regions (midlateral regions)
4. Umbilical (navel) region
5. Inguinal or iliac regions (lower lateral regions)
6. Hypogastric or pelvic region (region inferior to the lower border of the iliac crest and medial to the inguinal regions)



On the following page is a practical exercise containing some commonly used terms. Use this test to identify those terms which you need to study.

As you study each body system, you will be asked questions which require you to use your knowledge about location terms. The questions might be something like this:

- Q. Does the word suprarenal refer to a gland which is located above, below, distal to, or lateral to the kidney?

Answer: above--the prefix *supra* means "above."

- Q. Does the clavicle lie inferior to or superior to the maxilla (upper jaw)?

Answer: inferior to--*inferior* means "situated below or directed downward."

Practical Exercise

Listed below on the left are terms used to denote anatomic position and location. Match the terms on the left with the definitions on the right. **Caution:** This is a somewhat difficult exercise because two or more definitions may define a term in whole or in part. So, for each term, select all the definitions which fit it at least in part.

	<u>Terms</u>	<u>Definitions</u>
a.	_____ anterior (ventral)	1. towards the side, away from the middle
b.	_____ distal	2. within
c.	_____ endo-	3. towards the back, in back of
d.	_____ epi-	4. above, beyond, excessive
e.	_____ extra-	5. away from the beginning of a structure
f.	_____ hyper-	6. near the surface of the body or a specific organ
g.	_____ hypo-	7. towards the head, above
h.	_____ inferior (caudal)	8. outside of, in addition to
i.	_____ inter-	9. towards the middle vertical body plane
j.	_____ intra-	10. within the body cavities
k.	_____ juxta-	11. near to front, in front of
l.	_____ lateral	12. above, superior to
m.	_____ medial	13. near, beside
n.	_____ para-	14. before, in front of
o.	_____ peri-	15. nearer to the beginning of, closer to
p.	_____ posterior (dorsal)	16. behind, back of, backward
q.	_____ pre-	17. around, about
r.	_____ proximal	18. near, adjoining
s.	_____ retro-	19. between
t.	_____ sub-	20. under, below, beneath
u.	_____ superficial	21. on, upon, over
v.	_____ superior (cephalic)	22. below, under, deficient
w.	_____ supra-	23. inside, within
x.	_____ visceral	24. towards the tail (feet), below, away from the head

Answers to Practical Exercise

Note that the preferred definition is underlined when there is more than one possible answer.

<u>Terms</u>	Definitions
a. anterior (ventral)	11. <u>near to front, in front of</u> 14. before, in front of
b. distal	15. away from the beginning of a structure
c. endo-	2. <u>within</u> 23. inside, within
d. epi-	21. on, upon, over
e. extra-	4. above, beyond, excessive 8. <u>outside of, in addition to</u> 12. above, superior to
f. hyper-	4. <u>above, beyond, excessive</u> 12. above, superior to
g. hypo-	20. under, below, beneath 22. <u>below, under, deficient</u>
h. inferior (caudal)	20. under, below, beneath 22. below, under, deficient 24. <u>towards the tail (feet), below, away from the head</u>
i. inter-	19. between
j. intra-	2. within 23. <u>inside, within</u>
k. juxta-	13. near, beside 18. <u>near, adjoining</u>
l. lateral	1. towards the side, away from the middle
m. medial	9. towards the middle vertical body plane

Answers to Practical Exercise (continued)

Terms	<u>Definitions</u>
n. para-	13. <u>near, beside</u> 18. near, adjoining
o. peri-	13. near, beside 17. <u>around, about</u>
p. posterior (dorsal)	3. <u>towards the back, in back of</u> 16. behind, back of, backward
q. pre-	11. near to front, in front of 14. <u>before, in front of</u>
r. proximal	13. near, beside 15. <u>nearer to the beginning of, closer to</u> 18. near, adjoining
s. retro-	3. towards the back, in back of 16. <u>behind, back of, backward</u>
t. sub-	20. <u>under, below, beneath</u> 22. below, under, deficient
u. superficial	6. near the surface of the body or a specific organ
v. superior (cephalic)	4. above, beyond, excessive 7. <u>towards the head, above</u> 12. above, superior to
w. supra-	4. above, beyond, excessive 7. towards the head, above 12. <u>above, superior to</u>
x. visceral	10. within the body cavities

SECTION C
THE INTEGUMENTARY SYSTEM

SECTION C

THE INTEGUMENTARY SYSTEM

The skin (integument) covers the entire surface of the body. It consists of two layers (Figures 4A and 4B): a thin outer layer called the epidermis¹ and an underlying thick layer, the dermis.² The skin forms a pliable covering for the body and provides a barrier in preventing injury to underlying tissues. Unbroken skin keeps out ever-present bacteria and other microorganisms and essentially prevents body infections. It provides a nearly waterproof covering which enables the body to resist dehydration at normal temperatures. Pigmentation (melanin) in the skin gives the body protection against solar radiation.

Humans need to maintain a constant body temperature. Heat is continually produced in the body by the oxidation of fats and carbohydrates. The blood transfers the heat throughout the body. The skin's complex vascular pattern plays an important role in the regulation of the body temperature. The surface evaporation of sweat is another mechanism for heat control. The skin has an excretory function because of the rich supply of sweat and sebaceous glands that are embedded in the dermis.

¹epidermis--The protective, outer layer of the skin.

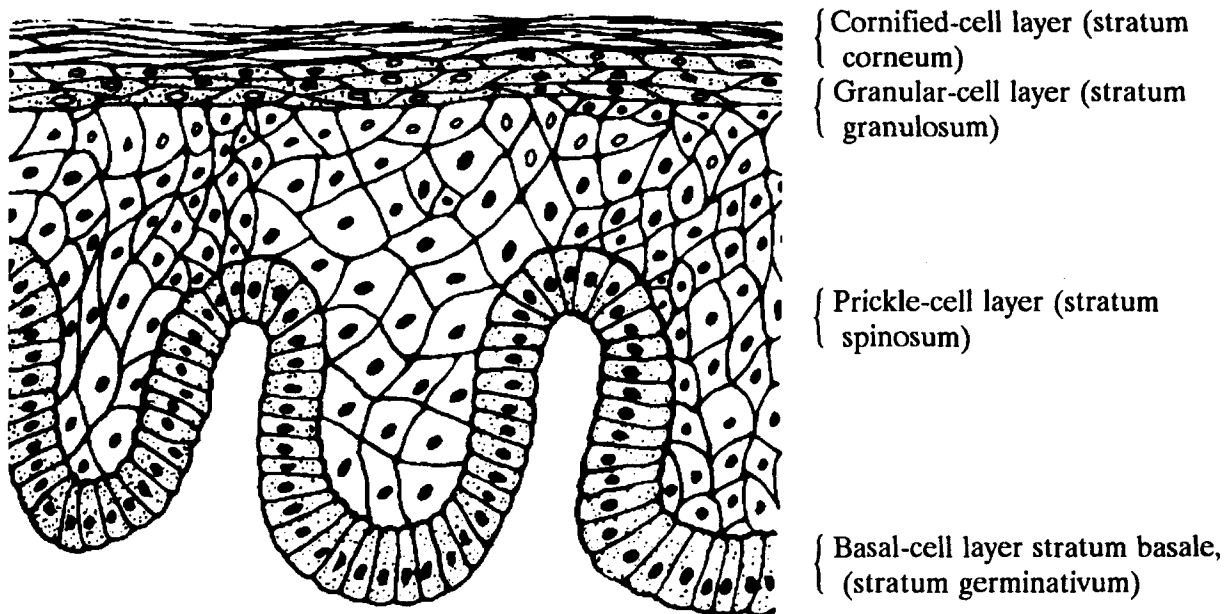
²dermis--The layer of skin under the epidermis consisting of dense vascular connective tissue; also known as the corium.

Epidermis

The epidermis (Figure 4A) is composed of stratified squamous epithelium. It has several layers. The cells of each of these layers change as they move from the basal layer up to the surface of the skin. The layers (from the surface inward) are:

- Cornified (horny) cell layer (stratum corneum): An outer layer of overlapping flattened scale-like (squamous) remnants of cells which have lost their nuclei and which are filled with keratin, a water-insoluble protein.
- Clear-cell layer (stratum lucidum): A thin transparent layer consisting of a substance called eleidin, a precursor of keratin. Since it is found only on the palms of the hands and the soles of the feet, this layer does not appear in Figure 4A below.
- Granular-cell layer (stratum granulosum): A layer of cells containing granules of keratohyalin, an earlier precursor of keratin.
- Prickle-cell layer (stratum spinosum)
- Basal-cell layer (stratum basale, formerly called stratum germinativum, also called Malpighian layer): A layer of actively dividing columnar cells attached to a basement membrane (basal lamina) which marks the junction of the dermis and epidermis.

Figure 4A. LAYERS OF THE EPIDERMIS



The keratinized surface-cell remnants are continually worn away or shed while new cells are being formed by the lower layers of the epidermis. As they are formed, they are pushed outward to the surface, gradually flattened, and become filled with keratin. Keratin is a term derived from the Greek word *keras* meaning "horny."

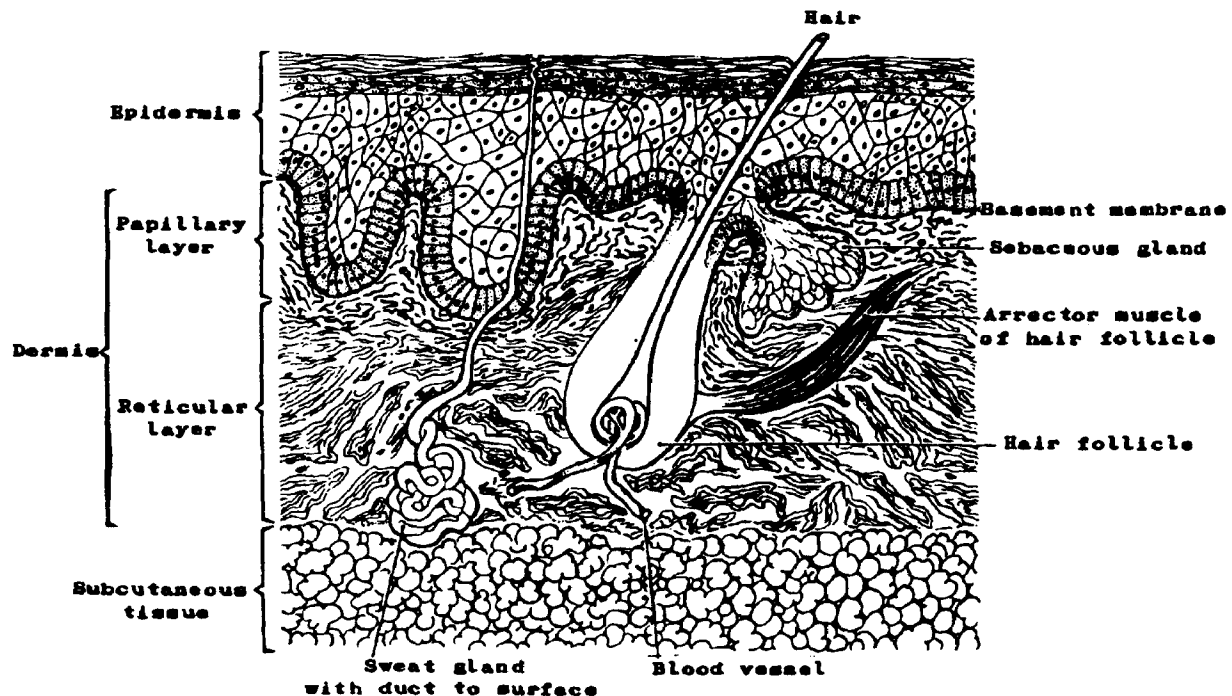
Melanocytes (pigment cells), located primarily in the basal layer of the epidermis, produce melanin (a dark pigment). The presence of melanin is one of the factors which determine skin color. All individuals except albinos have some melanin in their skins. It is vital for protection against the harmful effect of ultraviolet radiation.

Dermis

The *dermis* (corium) constitutes the greater part of total skin thickness and contributes strength and elasticity to the skin. The thickness of the dermis varies from 3 to 4 millimeters on the palms of the hands and the soles of the feet to less than 1/2 millimeter on the eyelids. It is composed of two layers of dense connective tissue:

- Papillary layer (stratum papillare): A thin layer which includes blood vessels, lymphatics, and nerve endings.
- Reticular layer (stratum reticulare): A thicker, deep layer consisting of connective tissue and containing sweat glands, sebaceous glands, and hair follicles. (The reticular layer of the dermis merges with the subcutaneous tissue¹.)

Figure 4B. LAYERS OF THE SKIN: EPIDERMIS AND DERMIS



¹subcutaneous tissue--The loose connective tissue under the dermis.

Q1

a. What are the two primary layers of the skin?

1. _____

2. _____

b. A lack of what component of the basal-cell layer of the epidermis causes persons with fair skin to sunburn more readily than those with darker skin?

c. Match the skin layer with the tissue type:

_____ 1. epidermis

a. epithelium

_____ 2. dermis

b. connective tissue

Answer: Q1

- a. The two primary layers of the skin are:
 - 1. epidermis
 - 2. dermis or corium
- b. Melanin. It causes the pigmentation of skin. It is produced by melanocytes. People with fair skin who have little melanin will sunburn easily.
- c. The skin layers and tissue type match as follows:
 - a 1. epidermis - epithelium
 - b 2. dermis - connective tissue

Epidermis is epithelial tissue derived from ectoderm; it contains no blood vessels. Dermis is dense connective tissue which contains blood vessels, nerves, and glands.

Accessory Organs

The accessory organs or appendages of the skin are: sebaceous¹ glands, sweat or sudoriferous² glands, ceruminous³ glands, and the nails and hair. (The mammary glands are specialized accessory glands of the skin and will be discussed in The Reproductive System.)

¹sebaceous--Secreting an oily substance, sebum; glands are situated in the dermis.

²sudoriferous--Secreting sweat; glands are situated in the dermis and subcutaneous tissue.

³ceruminous--Secreting a waxlike substance, cerumen; glands are located in the skin of the external auditory canal.

Q2

Name the three glands of the skin:

1. _____

2. _____

3. _____

Answer: Q2

The three glands of the skin are:

1. Sebaceous glands
2. Sweat or sudoriferous glands
3. Ceruminous glands

- The *sebaceous* glands are widely distributed in the skin except in the palms of the hands and the soles of the feet. They develop from the follicular epithelium of the hair. Several of these glands grow out from each hair follicle with direct connection to the hair root by a short duct. Through these ducts is secreted sebum, an oil which coats the body hair at the surface of the skin.

- The sweat or *sudoriferous* glands are simple coiled tubular glands. The secreting portion of the gland is coiled into a ball and lies in the deep part of the dermis. Sweat, the product of this gland, passes upward through its duct into a pore which opens on the surface of the skin. Sweat glands are controlled by the central nervous system. Afferent¹ nerves carry impulses from the skin to the brain informing it of environmental temperatures. The efferent² nerves, in turn, carry impulses from the brain to the skin causing a reflex emergency mechanism to trigger the sweat glands to begin cooling the body temperature by evaporation. This reflex action is also responsible for an immediate withdrawal of your hand when you touch a hot surface.

- The *ceruminous* glands are thought to be modified sweat glands. The secretory portions of these glands open directly into the skin or into the ducts of the sebaceous glands. Their function is to lubricate the surfaces of the ear canals and the ear drum membranes (tympanic membranes) by secreting ear wax.

- A hair is composed of keratinized cells compactly cemented together. Hair is distributed over almost the entire body. It consists of the root, or portion below the surface, and the shaft, or portion extending above the surface. The root is embedded in a pit-like depression called the hair follicle. It widens at its lower end to include small vascular papillae (small loops of blood vessels). These papillae provide nutrition for the growth of hair. Hair grows as a result of the division of the cells of the root. The hair follicle is placed obliquely in the skin, and a small smooth muscle called the arrector muscle, fastened to the side, causes the hair to stand up in cold or fright and gives the appearance of goose flesh to the skin.

- *Nails* are comparable to the horny-cell layer (stratum corneum). Nail beds underlying the nail consist of the deeper layers of the epidermis and the dermis. Blood in the dermal capillaries is responsible for the nails' pink color. The white halfmoons at the base of the fingernails are called lunulae.

¹afferent--Conveying towards a center.

²efferent--Conveying away from a center.

Q3

Accessory skin organs are found mainly in the papillary/reticular layer of the dermis. (Circle one.)

Q4

- a. Sebaceous glands secrete sweat/oil/wax. (Circle one.)
- b. Sudoriferous glands secrete sweat/oil/wax. (Circle one.)
- c. Ceruminous glands secrete sweat/oil/wax for the ear canals and the eardrum membranes.
(Circle one.)

Answer: Q3

Accessory skin organs are found mainly in the reticular layer of the dermis.

Answer: Q4

- a. Sebaceous glands secrete oil.
- b. Sudoriferous glands secrete sweat.
- c. Ceruminous glands secrete a wax for the ear canals and the eardrum membranes.

Benign Tumors

There is a large group of benign skin tumors appearing as moles or birthmarks which are designated by the term "nevus"¹ or "nevi" (plural). These tumors are proliferations of melanocytes and are probably of neural crest² origin. They may be 1) junctional (at the dermal-epidermal junction), 2) intradermal, or 3) compound (both). They may be pigmented or nonpigmented. The giant pigmented nevi which are present at birth may become malignant.

Connective tissue tumors, such as dermatofibroma, fibroxanthoma, hemangioma, and lymphangioma may arise in the dermis. Adenomas may arise in the glandular epithelium of the sebaceous, sweat, or ceruminous glands.

¹nevus--A benign tumor composed of melanocytes.

²neural crest--A cellular band dorsolateral to the neural tube that gives rise to the cerebrospinal ganglia. (For further information, study the embryology of the nervous system.)

Malignant Tumors

A variety of malignant tumors also arise in the skin and may derive from epithelial and/or connective tissue of the skin and its appendages. Many of these are felt to be related to prolonged exposure to sun rays. Individuals with light skin/decreased melanin are more susceptible. The most common tumors are listed and described briefly below:

- Basal cell carcinoma: A malignant skin tumor composed of cells similar to those in the basal layer of the epidermis
- Squamous cell (epidermoid) carcinoma: A malignant tumor having characteristics of squamous cells
- Basosquamous cell carcinoma: A malignant skin tumor of mixed basal and squamous cells
- Bowen's disease: Intraepidermal (in-situ) squamous cell carcinoma
- Dermatofibrosarcoma (protuberans): A fibrosarcoma of the skin, a low grade malignant tumor of the fibrous tissue of the dermis
- Sweat gland adenocarcinoma: A malignant tumor of sudoriferous glandular epithelium
- Sebaceous gland adenocarcinoma: A malignant tumor of sebaceous glandular epithelium
- Kaposi's (multiple idiopathic hemorrhagic) sarcoma: A multifocal malignant vascular tumor characterized by bluish-red or brown plaques and nodules. Kaposi's sarcoma appears to be an opportunistic carcinoma in the presence of AIDS (acquired immune deficiency syndrome).
- Mycosis fungoides: A malignant lymphoma of the skin characterized by erythema, scaling, tumor formation, and ulceration
- Malignant melanoma: A malignant tumor of the melanin-producing cells (melanocytes), usually black-brown, although lesions may be nonpigmented (amelanotic)

Many cancer registries do not register basal and squamous cell carcinomas of the skin except for selected sites, such as skin of external genital organs: vulva, penis, and scrotum.

Q5 Match the malignant tumors of the skin on the left with the best description on the right.

- | | | |
|-----|------------------------|---|
| ___ | 1. Bowen's disease | a. A malignant lymphoma of the skin |
| ___ | 2. Dermatofibrosarcoma | b. Intraepidermal squamous cell carcinoma |
| ___ | 3. Kaposi's sarcoma | c. A multifocal malignant tumor characterized by bluish red or brown plaques or nodules |
| ___ | 4. Mycosis fungoides | d. A malignant tumor of the fibrous tissue of the dermis |
| ___ | 5. Melanoma | e. A malignant tumor of the melanin-producing cells |

Answer: Q5

- | | | |
|----------|------------------------|--|
| <u>b</u> | 1. Bowen's disease | Intraepidermal squamous cell carcinoma |
| <u>d</u> | 2. Dermatofibrosarcoma | A malignant tumor of the fibrous tissue of the dermis |
| <u>c</u> | 3. Kaposi's sarcoma | A multifocal malignant tumor characterized by bluish red or brown plaques or nodules |
| <u>a</u> | 4. Mycosis fungoides | A malignant lymphoma of the skin |
| <u>e</u> | 5. Melanoma | A malignant tumor of the melanin-producing cells |

Malignant Melanoma

Malignant melanomas may arise directly from melanocytes at the dermal- epidermal junction or within the basal cell layer and not from pre-existing moles. There are, however, some pre-existing lesions in which melanomas are known to develop, namely:

giant hairy (pigmented) nevus
blue nevus
junctional nevus
intradermal nevus.

The B-K mole syndrome has recently been described by Clark and associates. Familial melanomas frequently arise from the large, irregular moles which have been called "B-K moles" after the first two families in which this syndrome was observed. Thus, if the diagnosis is made, all nevi should be removed in these individuals to prevent the lesions from becoming invasive.

Most melanomas occur in the skin; however, they may occur elsewhere in the body, often in the eye. Subungual melanoma, that is, melanoma beneath the nail, is not uncommon. When abstracting a case of melanoma, or any skin cancer for that matter, the primary site of the lesion should be carefully identified. Primary site classifications taken from the *International Classification of Diseases for Oncology (ICD-O)*, Second Edition, are as follows:

TOPOGRAPHY CODE FOR MELANOMAS (M-8720-8790)

C44.0 Skin of lip, NOS
C44.1 Eyelid
C44.2 External ear
C44.3 Skin of other and unspecified parts of face
C44.4 Skin of scalp and neck
C44.5 Skin of trunk
C44.6 Skin of upper limb and shoulder
C44.7 Skin of lower limb and hip
C44.8 Overlapping lesion of skin (overlaps the boundaries of two or more sub-
categories and whose point of origin cannot be determined)
C44.9 Skin, NOS
C51.0 - C51.2, C51.9 Skin of vulva
C60.0 - C60.1, C60.9 Skin of penis
C63.2 Skin of scrotum

Skin of the lip should not be confused with the lip itself which is considered to be part of the digestive system. The skin of the upper lip extends from the vermilion border to the anterior nares; the lateral borders are the nasolabial sulci¹. The skin of the lower lip extends from the lower vermilion border to the lateral semicircular groove where the chin begins.

¹nasolabial sulcus--A groove which runs downwards and laterally from the side of the nose to the angle of the mouth.

The classification of cutaneous melanoma as to histologic type and depth of invasion has undergone considerable study in recent years, particularly in the United States and Australia with the evolution of similar classification schemes. The generally defined types of cutaneous melanoma are described as follows:

- **Lentigo maligna melanoma:** A melanoma arising in a Hutchinson's melanotic freckle. The atypical melanocytes are confined to the basal layer of the epidermis during the radial growth phase. The entity is known as lentigo maligna or Hutchinson's melanotic freckle during the period of its intraepidermal growth. It is found primarily in elderly persons.
- **Superficial (radial) spreading type malignant melanoma:** A melanoma characterized by gradual radial enlargement over a period of several months or even years before the onset of its vertical growth phase.
- **Acral lentiginous melanoma:** A specific biologic form of melanoma occurring commonly on the palms of the hands and the soles of the feet. It may also occur in areas other than skin, i.e., in the mucous membranes and subungual areas.
- **Nodular melanoma:** A malignant tumor characterized by early and rapid dermal invasion with no radial growth phase as a developmental stage. These tumors are in vertical growth from onset.
- **Malignant melanoma, unclassified:** A malignant melanoma for which the radial growth phase has not been determined.

Breslow¹ has emphasized the importance of measuring the *thickness* (vertical growth) of penetration of the melanotic lesion. The measurement represents the thickness of invasion in millimeters from the granular layer of the epidermis to the greatest depth of penetration of the tumor into the dermis.

The measurement categories for thickness are as follows:

- ≤ 0.75 mm.
- 0.76 - 1.50 mm.
- 1.51 - 3.00 mm.
- 3.01 - 4.00 mm.
- > 4.00 mm.

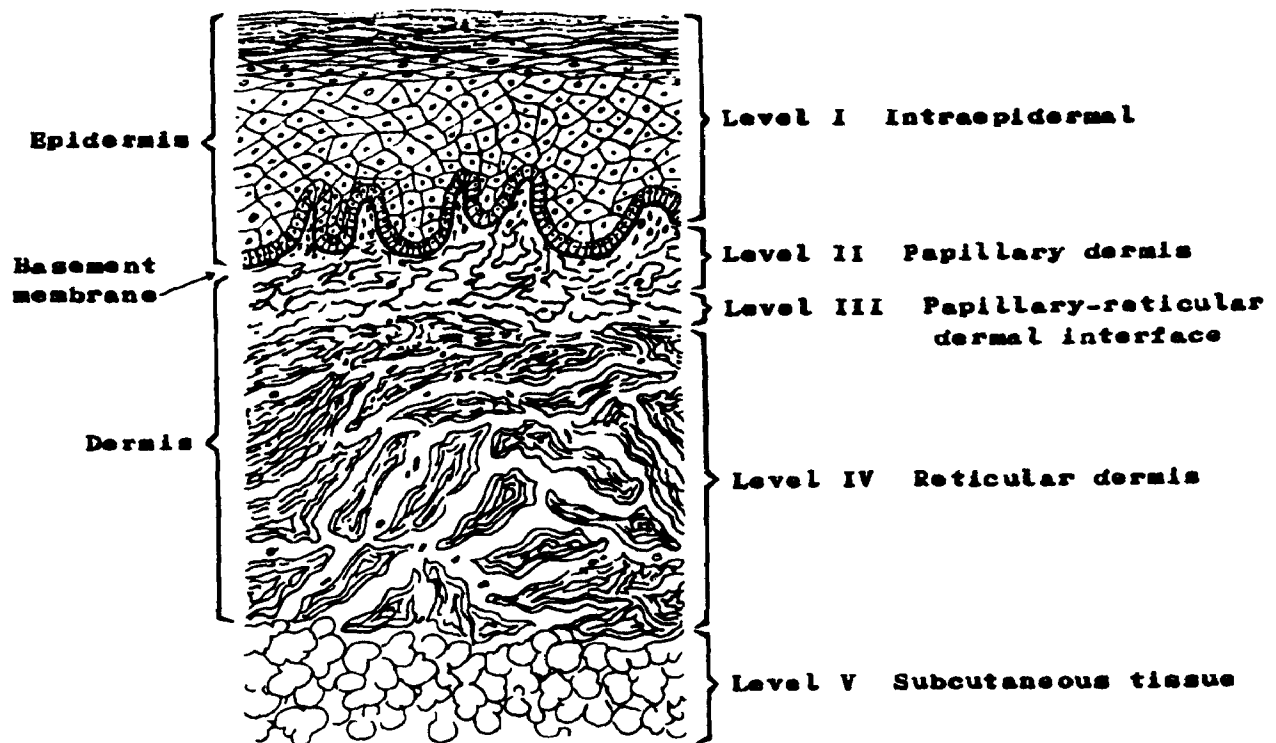
Note: < = less than, > = greater than, and the symbol ≤ = less than or equal to

¹Breslow, Alexander--He initiated the measurement of tumor thickness to evaluate the incidence of recurrent disease in relationship to depth of invasion of the melanoma into the dermis.

The description of the level¹ of invasion of melanoma, sometimes called "Clark's² Classification," describes five levels of invasion. The definitions of each level are as follows:

- Level I Intraepidermal: Tumor confined to epidermis (in-situ) and does not penetrate the basement membrane (basal lamina)
- Level II Papillary dermis: Tumor invades only the superficial or papillary zone of the dermis
- Level III Papillary-reticular dermal interface: Tumor fills and expands the papillary dermis extending to the interface of the papillary and reticular layers without invading the reticular layer
- Level IV Reticular dermis: Tumor invades the deep or reticular layer of the dermis
- Level V Subcutaneous tissue: Tumor invades through the reticular dermis into the subcutaneous tissue

Figure 5. CLARK'S CLASSIFICATION OF MALIGNANT MELANOMA



¹For melanomas, it is recommended that the abstractor record both thickness (in mm.) and level of invasion.

²Clark, Wallace H., Jr.--A pathologist identified with the classification of primary malignant melanoma by "level" of invasion.

Q6

In which of the following would you not expect to find a primary malignant melanoma?

(Check one.)

Skin of ear

Eye

Liver

Vulva

Q7

Subungual melanoma occurs under the tongue/beneath the nail. (Circle one.)

Q8

Match each histologic type of melanoma on the left with the appropriate description on the right.

- | | |
|--|---|
| ___ 1. Lentigo maligna melanoma | a. Characterized by radial growth phase for months or years prior to onset of vertical growth phase |
| ___ 2. Superficial (radial) spreading malignant melanoma | b. No radial growth phase |
| ___ 3. Acral lentiginous melanoma | c. Confined to the basal layer of the epidermis during its radial growth phase |
| ___ 4. Nodular melanoma | d. Occurring commonly on the palms of the hands and the soles of the feet |

Q9

"Clark's Classification" of malignant melanoma describes five levels of invasion. Place the following terms in order from least invasive (I) to most invasive (V): papillary-reticular dermal interface, subcutaneous tissue, papillary dermis, intraepidermal, and reticular dermis.

I _____

II _____

III _____

IV _____

V _____

Answer: Q6

Liver. Malignant melanomas may metastasize to the liver, but generally would not arise there.

Answer: Q7

"beneath the nail" should have been circled. The term for "under the tongue" is sublingual.

Answer: Q8

- | | | |
|----------|--|--|
| <u>c</u> | 1. Lentigo maligna melanoma | Confined to the basal layer of the epidermis during its radial growth phase |
| <u>a</u> | 2. Superficial (radial) spreading malignant melanoma | Characterized by radial growth phase for months or years prior to onset of vertical growth phase |
| <u>d</u> | 3. Acral lentiginous melanoma | Occurring commonly on the palms of the hands and the soles of the feet |
| <u>b</u> | 4. Nodular melanoma | No radial growth phase |

Answer: Q9

Clark's Classification:

- I Intraepidermal
- II Papillary dermis
- III Papillary-reticular dermal interface
- IV Reticular dermis
- V Subcutaneous tissue

Lymphatic Drainage of the Skin

The lymphatic drainage of the skin is to the superficial lymph nodes rather than to those situated deep within the body. If these superficial lymph nodes are involved with tumor, they frequently can be palpated.

The lymph nodes which receive direct (ipsilateral) lymphatic drainage from the skin are:

REGIONAL LYMPH NODES OF SKIN BY PRIMARY SITE

Head and Neck - cervical for all subsites

Lip:

preauricular (parotid), facial, submental, submandibular

Eyelid/canthus:

preauricular (parotid), facial, submandibular, infra-auricular

External ear/auditory canal:

preauricular (parotid), postauricular (mastoid)

Face, Other*:

preauricular (parotid), facial, submental, submandibular

Scalp/neck:

preauricular (parotid), occipital, spinal accessory (posterior cervical), postauricular (mastoid) for scalp, supraclavicular, axillary for neck

Thorax/chest wall/upper back

axillary

internal mammary

intercostal

supraclavicular

Abdomen/lower back

femoral (superficial inguinal)

Arm/shoulder

axillary

spinal accessory for shoulder

epitrochlear for hand, forearm

Leg/hip

femoral (superficial inguinal)

except for heel

popliteal for heel and calf

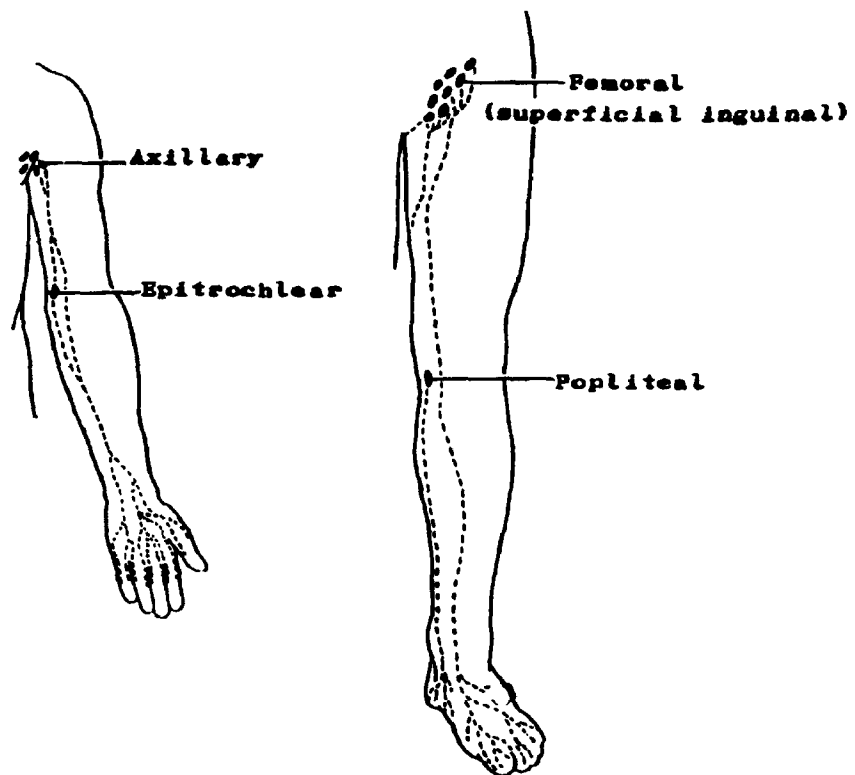
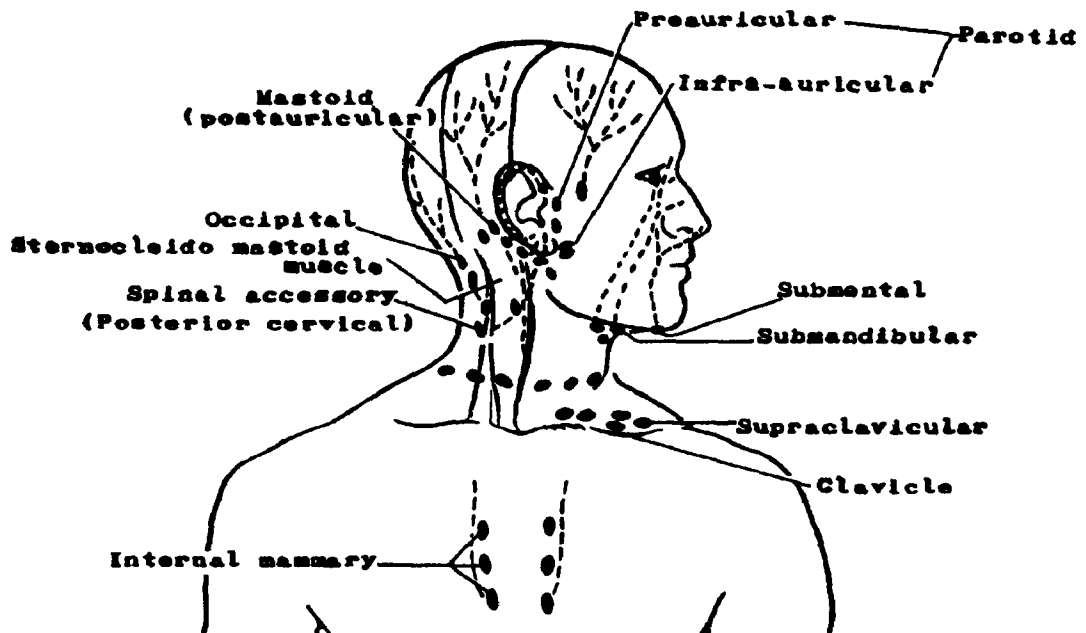
Scrotum/perineum

femoral

inguinal

*Includes the skin of the cheek, chin, forehead, jaw, nose, temple

Figure 6. LYMPHATICS OF THE SKIN



Q10

Match the regions of the skin on the left with the lymph node drainage on the right.

- | | |
|-----------------------|---|
| ___1. Head | a. Supraclavicular and axillary lymph nodes |
| ___2. Upper extremity | b. Submandibular and postauricular (parotid) lymph nodes |
| ___3. Lower extremity | c. Axillary and epitrochlear lymph nodes |
| ___4. Chest wall | d. Femoral (superficial inguinal) and popliteal lymph nodes |

Answer: Q10

The skin locations on the left match the lymph nodes on the right as follows:

- | | | |
|----------|--------------------|--|
| <u>b</u> | 1. Head | Submandibular and postauricular (parotid) lymph nodes |
| <u>c</u> | 2. Upper extremity | Axillary and epitrochlear lymph nodes |
| <u>d</u> | 3. Lower extremity | Femoral (superficial inguinal) and popliteal lymph nodes |
| <u>a</u> | 4. Chest wall | Supraclavicular and axillary lymph nodes |

SECTION D
THE LYMPHATIC SYSTEM

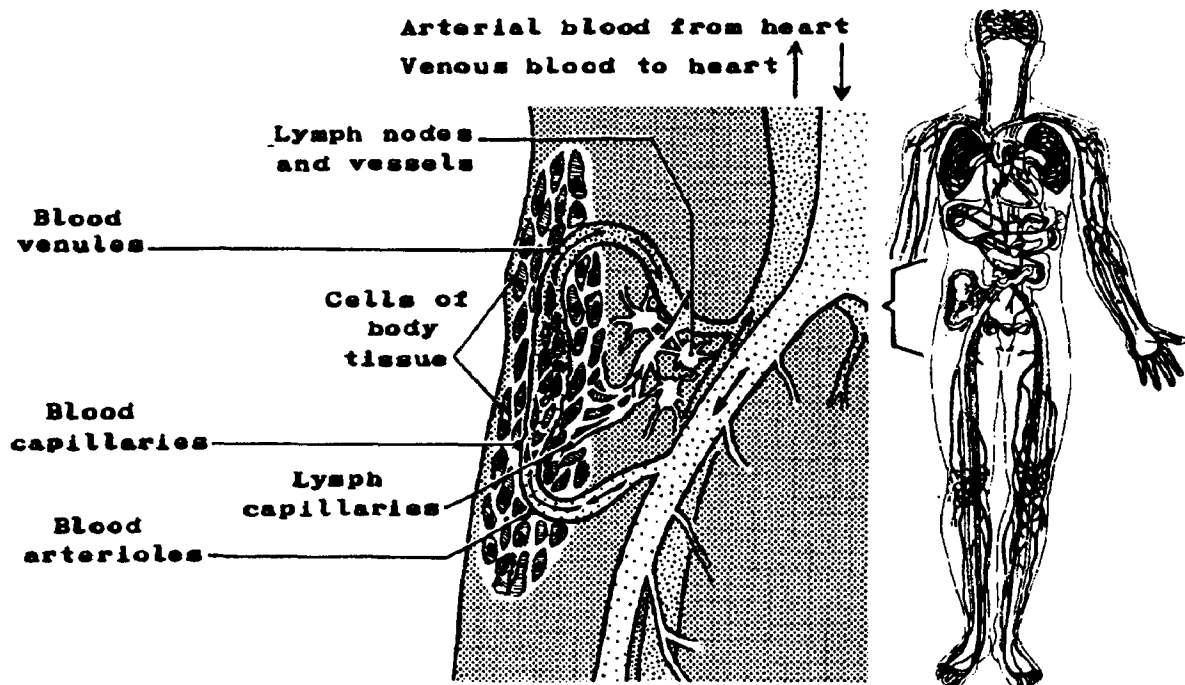
SECTION D

THE LYMPHATIC SYSTEM

The lymphatic system and the cardiovascular system (Section E) together provide the internal environment of the body. The blood carries food and oxygen to, and waste products from, the cells of the body. The lymphatic system consists of a set of vessels and aggregations of lymphatic tissue which collect and carry lymph¹ from the body tissues to the veins of the blood circulatory system.

Lymph vessels, like blood vessels, are distributed to nearly all parts of the body. The lymphatic system carries fluid away from, and not to the tissues; consequently, it is not a continuous closed circulation system as is the cardiovascular system. The lymph enters the system via the lymph capillaries and flows into larger and larger collecting vessels until it finally empties into the subclavian veins. Interposed along the lymphatics (lymph vessels) are many lymph nodes, structures which serve as filters to clear the lymph of particulate matter. Lymphatic organs and tissues include lymph nodes, the spleen, thymus, tonsils, and Peyer's patches of the small intestine. The lymph nodes, spleen, and thymus have roles as hematopoietic² (lymphopoietic)³ centers mainly producing lymphocytes.

Figure 7. RELATIONSHIP BETWEEN THE BLOOD AND LYMPH CIRCULATORY SYSTEMS



¹lymph--A clear watery fluid found in the lymph vessels (See page 63 for a more detailed discussion).

²hematopoiesis--(hemopoiesis)--Formation and development of blood cells.

³lymphopoiesis--Formation and development of lymphatic tissue or cells (lymphocytes).

T-Cells Versus B-Cells

The two principal classes of lymphocytes that can be recognized in an immune system are T and B lymphocytes. In recent years an attempt has been made to relate malignant lymphoma to the normal cells of the immune system and to understand which parts of the immune system are involved.

The T-cells mature in the thymus and are involved in cell-mediated immunity, that is, the cells themselves mediate the immune effect.

The B-cells derive from a bone-marrow precursor and mature in the chicken in an organ known as the bursa Fabricius. In humans and other mammals there is no bursa Fabricius, but B-cells mature in a bursa equivalent, which may be fetal liver. The B-cells, through their progeny, differentiate into plasma cells. These are cells which can secrete antibodies and are known to form the humoral component of the immune system, that is, they secrete products which mediate the effect; it is not the cell itself that is involved in the immune mechanism.

Q1

The lymphatic system collects _____ from the tissues of the body via the lymphatic _____. Lymph is filtered through the _____, and finally it empties into the _____ veins of the blood circulatory system.

Q2

Some specific lymphoid organs and tissues are:

1. _____
2. _____
3. _____
4. _____
5. _____

Answer: Q1

The lymphatic system collects lymph from the tissues of the body via the lymphatic capillaries. Lymph is filtered through the lymph nodes, and finally it empties into the subclavian veins of the blood circulatory system.

Answer: Q2

Some specific lymphoid organs and tissues are:

1. Lymph nodes
2. Spleen
3. Thymus
4. Tonsils
5. Peyer's patches

Lymphatic Vessels

The function of the lymphatic vessels is to return lymph from the interstitial fluid¹ to the blood circulatory system where it may be purified and recharged with nutrients and oxygen. In general, lymphatic vessels resemble veins in structure, but have thinner walls, many more valves, and lymph nodes located at intervals along their course. The valves are usually semilunar pairs with free edges in the direction of current flow. In case of blockage, the valves are often unable to withstand much increase in pressure and reverse (retrograde) flow may occur.

Lymphatics originating in the villi (finger-like projections) of the small intestine are called lacteals and the fluid found in them after digestion is called chyle.² This fluid is milky in appearance from absorbed fats.

The lymphatic capillaries originate as microscopic blind-end vessels which are located in the intercellular spaces and are widely distributed throughout the body. Small lymphatics merge with larger ones and they, in turn, with still larger vessels until they join (much like the branches of a tree) to form the main lymphatic trunks: the *right lymphatic duct* and the *thoracic duct*. Lymph from the entire body, except the right upper quadrant, drains eventually into the thoracic duct which flows into the left subclavian vein at the point where it joins the left internal jugular vein. Lymph from the upper right quadrant of the body empties into the right subclavian vein by way of the right lymphatic duct.

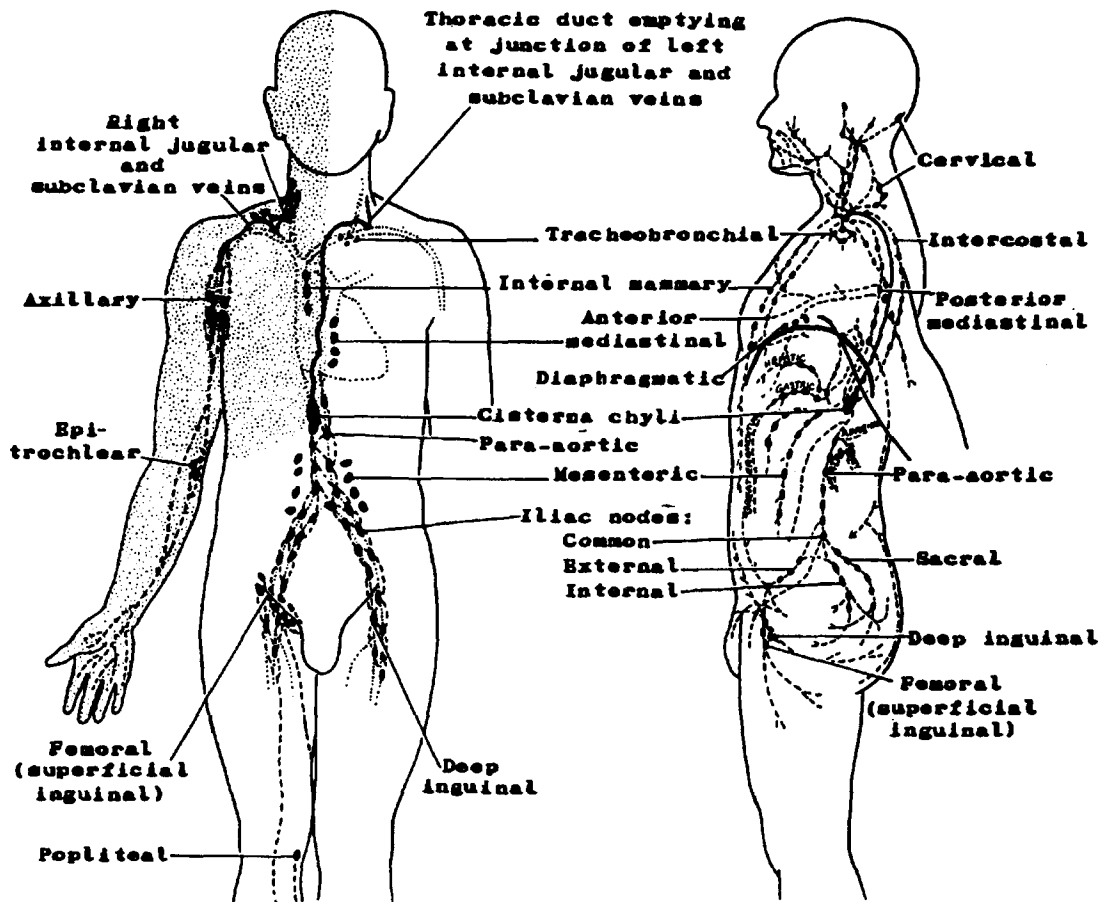
Since most of the body lymph returns to the bloodstream via the thoracic duct, this vessel is much larger than the right lymphatic duct--but it is much smaller than the large veins which it resembles in structure. The thoracic duct varies in length from 35 to 48 cm. It originates as a dilated structure, the *cisterna chyli*, in the lumbar region of the abdominal cavity, and ascends by a winding course to the root of the neck where it joins the left subclavian vein. Diagrammatic representation of lymphatic drainage is shown for different parts of the body in Figures 8A and 8B.



¹interstitial fluid--The extra-cellular fluid which bathes the cells and is drained away as lymph.

²chyle--The milky fluid taken up by the lacteals from the food in the small intestine during digestion. It passes into the thoracic duct at the cisterna chyli.

Figures 8A-8B. LYMPHATIC DRAINAGE OF VARIOUS PARTS OF THE BODY



The shaded area is drained by the right lymphatic duct.

Q3

The lymphatic system collects lymph from body tissues in an ever-enlarging system of lymphatic vessels to form terminal lymphatic ducts which empty into _____ that carry the lymph back to the blood circulatory system.

Q4

The main lymphatic trunks are the _____ and the _____.

Which of these ducts drains the greater part of the body?

Q5

The structure of the lymphatic vessels resembles veins with the major difference being that the lymphatics have _____ along their course.

Answer: Q3

The lymphatic system collects lymph from body tissues in an ever-enlarging system of lymphatic vessels to form terminal lymphatic ducts which empty into veins that carry the lymph back to the blood circulatory system.

Answer: Q4

The main lymphatic trunks are the right lymphatic duct and the thoracic duct.

The thoracic duct drains the greater part of the body.

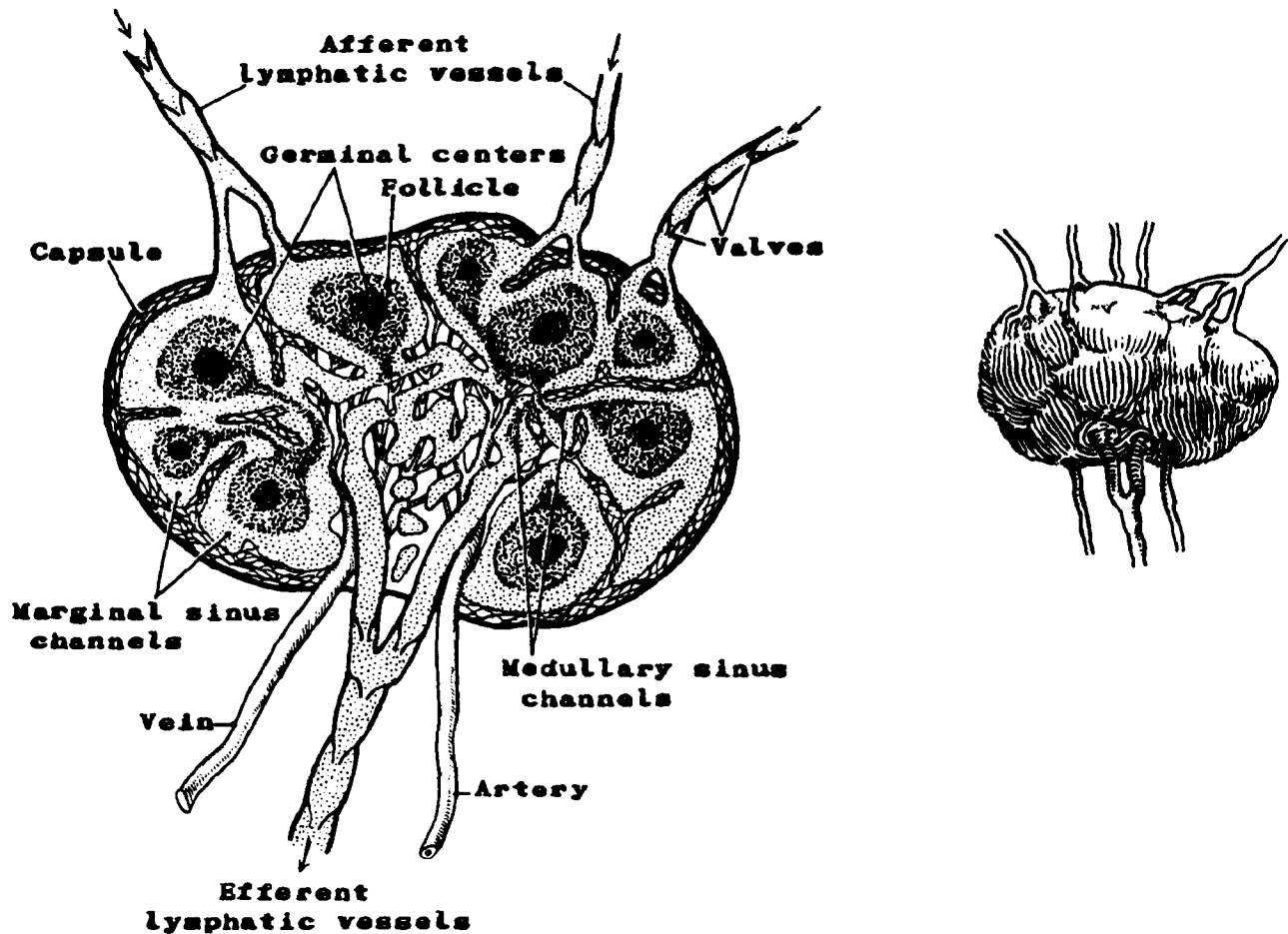
Answer: Q5

The structure of the lymphatic vessels resembles veins with the major difference being that the lymphatics have lymph nodes along their course.

Lymph Nodes

Lymph nodes are oval or bean-shaped masses of lymphoid tissue, densely packed with lymphocytes. They vary in size from a pinhead to a lima bean. They are each covered by a capsule of fibrous connective tissue. The lymph moves through the afferent (towards the node) lymphatic vessels into the node where it is filtered through sinus channels lined with reticuloendothelial cells¹ (or histiocytes) and emerges by an efferent (away from the node) vessel (see Figure 9A for the internal structure of a lymph node, and Figure 9B for the external view).

Figures 9A and 9B. STRUCTURE OF A LYMPH NODE



¹reticuloendothelial cells (or histiocytes)--Special cells which ingest and destroy old erythrocytes and foreign substances; found mainly in the lymph nodes, liver, spleen, and bone marrow.

Lymph nodes accomplish two separate functions--defense and hematopoiesis.

- The defense functions are filtration and phagocytosis.¹ The lymph slowly filters through the intricate structure of the sinus channels which remove the microorganisms and injurious particles--for example, cancer cells and soot. Blockage of lymph nodes with obstruction of the normal flow of lymph may cause edema, inflammation, and retrograde flow of lymph. Thus, metastasis may occur in adjacent lymph nodes as a result of direct flow, or may occur in lymph nodes accessible only by retrograde flow.
- The lymphoid tissue of the nodes produces nongranular white blood cells--lymphocytes. It also produces plasma cells (plasmacytes) which are the cells that create gamma globulins (antibodies). Production of these different blood cells is the hematopoietic (or lymphopoi-etic) function of the lymph nodes.

Lymph nodes tend to be grouped in certain areas of the body and are named according to their location. For example, axillary nodes are located in the axilla, cervical nodes in the neck, mesenteric nodes in the mesentery of the intestines, and so forth. It is essential that the cancer registrar be familiar with the location of lymph nodes and the organs and tissues each lymphatic basin drains.

¹phagocytosis--The engulfing of microorganisms, other cells, and foreign particles by certain cells (phagocytes).

Lymph and Tissue Fluid

Tissue fluid (interstitial fluid) is the clear watery fluid which surrounds all cells. It is sometimes referred to as "lymph," but technically lymph is derived from interstitial fluid. The word lymph should only be used in reference to that tissue fluid which has entered the vessels of the lymphatic system.

Both lymph and tissue fluid resemble blood plasma in composition since tissue fluid reaches the cells in the first place from the capillaries of the blood circulatory system. Tissue fluid fills the microscopic spaces between the cells and carries oxygen and nutrients from the blood to the cells. In returning with waste products from the cells, it enters the microscopic lymphatic capillaries as "lymph" and, as described on page 49, returns to the blood circulatory system via the subclavian veins. Thus, there is a continuous exchange of materials between the blood and the cells through the interstitial fluid.

Q6

The lymph nodes have two main functions:

1. _____
2. _____

Q7

Lymph nodes often have names specific to the area of the body in which they are located. See if you can match the named nodes in the left-hand column with the location described in the right-hand column. (Refer to Figures 6 and 8A and 8B, if necessary.)

Lymph Nodes

Location Description

_____	1. Axillary	a. Behind and slightly above the elbow
_____	2. Buccal	b. In the mesentery of small intestine and colon
_____	3. Cervical	c. Lateral portions of neck
_____	4. Epitrochlear	d. In front of the sacrum
_____	5. Iliac	e. Face, around the cheeks
_____	6. Inguinal	f. Under the armpit
_____	7. Intercostal	g. Between the ribs
_____	8. Mesenteric	h. In the groin
_____	9. Sacral	i. Under the chin
_____	10. Submental	j. Around iliac blood vessels

Q8

The fluid located within the lymphatic system is called _____; the fluid which surrounds the cells and which carries oxygen and nutrients from the _____ to the cells is called _____.

Answer: Q6

The lymph nodes have two main functions:

1. Defense
2. Hematopoiesis (or lymphopoiesis)

Answer: Q7

- | | | |
|----------|-----------------|---|
| <u>f</u> | 1. Axillary | Under the armpit (axilla) |
| <u>e</u> | 2. Buccal | Face, around the cheeks |
| <u>c</u> | 3. Cervical | Lateral portions of neck |
| <u>a</u> | 4. Epitrochlear | Behind and slightly above the elbow |
| <u>j</u> | 5. Iliac | Around iliac blood vessels |
| <u>h</u> | 6. Inguinal | In the groin |
| <u>g</u> | 7. Intercostal | Between the ribs |
| <u>b</u> | 8. Mesenteric | In the mesentery of small intestine and colon |
| <u>d</u> | 9. Sacral | In front of the sacrum |
| <u>i</u> | 10. Submental | Under the chin |

Answer: Q8

The fluid located within the lymphatic system is called lymph; the fluid which surrounds the cells and which carries oxygen and nutrients from the blood (or capillaries) to the cells is called interstitial fluid (tissue fluid).

Spleen

The *spleen*, the largest lymphoid organ in the body, is located beneath the diaphragm in the left upper quadrant directly posterior to the greater curvature of the stomach. It is designed to filter blood. It is also a reservoir for blood cells--lymphocytes, plasma cells, and monocytes. Its reticuloendothelial cells phagocytize old, worn-out red blood cells. The spleen produces antibodies for the defense of the body against microorganisms. Despite its many functions, the spleen can be removed without causing death since most of its functions can be assumed by lymphoid tissue and reticuloendothelial cells elsewhere. There is some evidence that spleen regeneration may occur when cells spill from the pulp of a damaged spleen, implant in the body, and grow. Sometimes several functional mini-spleens develop following splenectomy for trauma.

Figure 10. SPLEEN

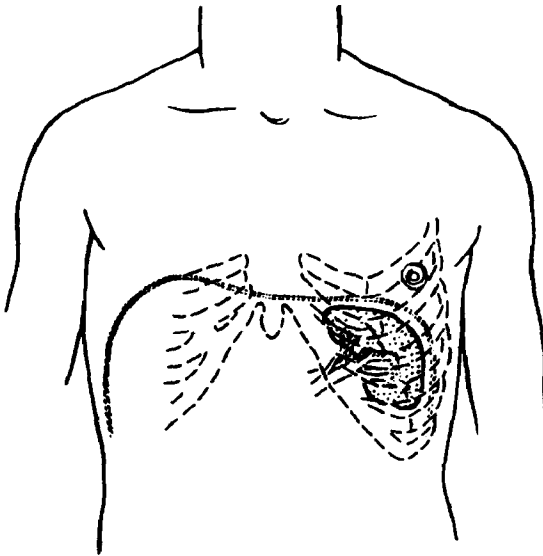
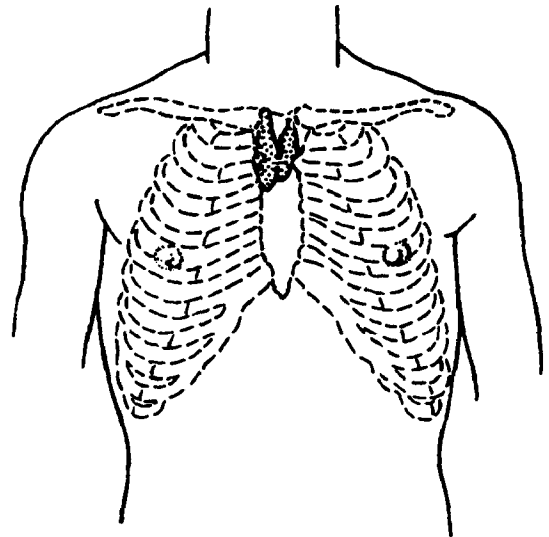


Figure 11. THYMUS GLAND



Thymus

The thymus is situated in the anterior mediastinal portion of the thoracic cavity and may extend up to the lower edge of the thyroid gland. It is a two-lobed gland composed of lymphocytic and epithelial tissue. A ductless gland, it is assumed to have an endocrine function, but the mechanism of that endocrine function, if any, is really unknown at this time. The thymus is believed to play a vital part in hematopoiesis and in immunity against infection. It manufactures or activates specific lymphocytes called *T-cells*. The T-cells themselves mediate an immune effect. They seek out malignant cells that have on their surface particular antigens lacking in normal cells, attach to the surface antigen, and destroy the tumor cell.

Recent immunotherapy makes use of a complex interaction between macrophages¹ and T-cells in protection against or treatment of specific cancers. Macrophages and T-cells are also largely responsible for the rejection of tissue transplants and for skin reactions to poison ivy and other allergens.

The thymus probably completes most of its work by infancy or in early childhood and is largest, relative to the rest of the body, when a child is about two years old. Its absolute size is largest at puberty after which the thymus gradually atrophies until in very old age it becomes largely replaced by fat. There is thought to be some association between thymic tumors and myasthenia gravis, a neuromuscular disease (see Figure 11 for a diagram of the thymus gland).

Tonsils

The *tonsils* are small rounded masses of lymphoid tissue located in or about the entrance to the pharynx. The *palatine* (faucial) *tonsils* are located in the lateral pharyngeal walls, the *lingual tonsils* are located at the base of the tongue, and the *pharyngeal tonsils* (adenoids) in the posterior wall of the nasopharynx. The circle of lymphoid tissue formed by these tonsillar areas is called *Waldeyer's ring*. This tissue is believed to act as a supply source of phagocytes to the mouth and pharynx for the purpose of destroying bacteria (see Figures 21A and 21B and Figure 23 for clarifying diagrams on the location of the tonsils).

Peyer's patches

Peyer's patches are small aggregates of lymphoid tissue found in the lamina propria of the small intestine, principally in the distal ileum.

¹macrophage--A phagocytic cell belonging to the reticuloendothelial system.

Q9

Match each lymphatic organ or tissue on the left with the appropriate description on the right.

- | | |
|--------------------------|------------------------------|
| _____ 1. Spleen | a. Waldeyer's ring |
| _____ 2. Peyer's patches | b. Located in the intestines |
| _____ 3. Thymus | c. Filters blood |
| _____ 4. Lymph nodes | d. Manufactures T-cells |
| _____ 5. Tonsils | e. Filters lymph |

Q10

What lymphatic organ may also be an endocrine gland?

Answer: Q9

<u>c</u>	1. Spleen	Filters blood
<u>b</u>	2. Peyer's patches	Located in the intestines
<u>d</u>	3. Thymus	Manufactures T-cells
<u>e</u>	4. Lymph nodes	Filters lymph
<u>a</u>	5. Tonsils	Waldeyer's ring

Answer: Q10

The thymus is a lymphatic organ and may also be an endocrine gland.

Lymphatic Drainage

Lymph nodes, most of which occur in groups and/or chains, are arranged along the lymphatic vessels. The lymphatic drainage from the organs and tissues of the body is through these nodes--first to regional nodes, then to more distant nodes. The lymphatics tend to parallel major blood vessels (arteries and veins) and the groups of lymph nodes along these vessels are so named, e.g., the superior mesenteric nodes are located along the superior mesenteric artery; the internal (upper deep) jugular nodes follow the internal jugular veins.

The major groups of lymph nodes will be discussed briefly in this section. Within some of these major categories are more specific groups of nodes which you will learn when we discuss the lymphatic drainage of specific organs. All of the organs and tissues of the body have known drainage patterns which are important in the spread of cancer. There may be several names for a particular group of lymph nodes. Check with your medical consultant to avoid confusion over synonymous names. Also see Book 6, Comparative Staging Systems for Cancer.

While blood-borne metastasis is most common for sarcomas, carcinomas tend to spread by way of the lymphatics before entering the bloodstream. Primary tumors of the lymphatic system tend to involve multiple areas of lymphoid tissue before blood-borne metastasis occurs.

The diagnostic workup for most cancer patients will include an inspection or exploration of the most likely lymph-node drainage areas. Some lymph nodes are amenable to palpation by the examining physician while others are located deep within the body and can only be examined at the time of surgery or by lymphangiography,¹ CAT² scans, or MRI.³ Lymph nodes may therefore be termed "accessible" or "inaccessible" depending on whether or not they are palpable by the physician without surgical intervention.

¹lymphangiography--Radiographic visualization of lymphatic vessels and lymph nodes following injection of radiopaque material.

²CAT--Computerized axial tomography.

³MRI--Magnetic resonance imaging.

Q11

Lymphatics tend to parallel _____ forming groups or chains of nodes which usually carry the same names as the blood vessels.

Q12

Sarcomas tend to spread by way of the _____, while carcinomas first tend to spread by way of the _____.

Q13

The diagnostic workup of a cancer patient should always include _____ of accessible lymph nodes. Inaccessible lymph nodes may be visualized at exploratory surgery or by _____, _____, or _____.

Answer: Q11

Lymphatics tend to parallel blood vessels forming groups or chains of nodes which usually carry the same names as the blood vessels.

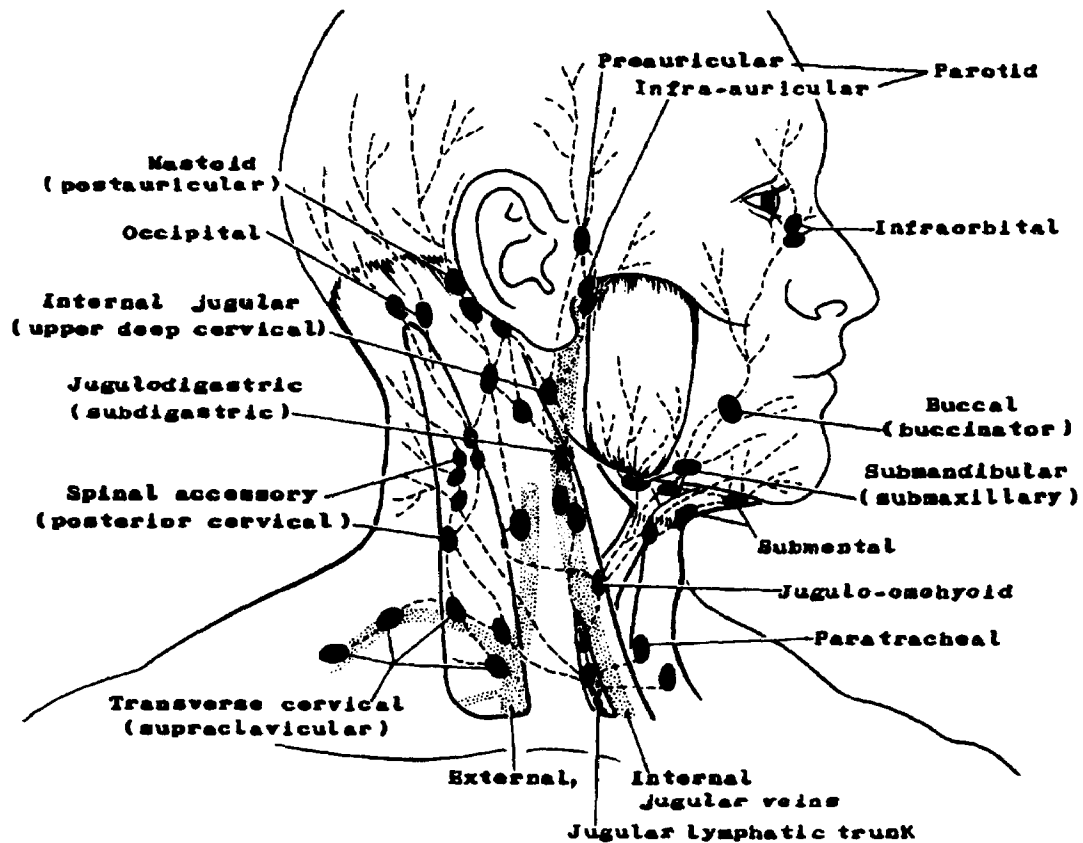
Answer: Q12

Sarcomas tend to spread by way of the blood, while carcinomas first tend to spread by way of the lymph. Lymph node involvement is a frequent occurrence for carcinomas.

Answer: Q13

The diagnostic workup of a cancer patient should always include palpation of accessible lymph nodes. Inaccessible lymph nodes may be visualized at exploratory surgery, by lymphangiography, CAT scan, or MRI.

Figure 12A. LYMPH NODES OF THE HEAD AND NECK



Lymph Nodes of Head and Neck

The lymph node drainage for most sites within the head and neck will be to cervical¹ nodes. This is a general term for nodes located in the neck or draining into the nodes of the neck. More specifically, cervical nodes may be identified as:

- Occipital
- Mastoid (postauricular)
- Facial: infra-orbital, maxillary, buccinator, supramandibular
- Parotid: preauricular, subparotid, infra-auricular
- Sublingual (lingual)
- Retropharyngeal

- Submental
- Submandibular (submaxillary)
- Anterior cervical: prelaryngeal, pretracheal, paratracheal, laterotracheal (recurrent laryngeal nerve chain)
- Internal jugular: upper and lower deep cervical (jugulodigastric and jugulo-omohyoid)
- Spinal accessory (posterior cervical)
- Transverse cervical (supraclavicular)

The term "supraclavicular nodes" is commonly used to include the transverse cervical nodes and the lowest nodes of the internal jugular and spinal accessory chains.

The regional nodes for some of the anatomic sites in the head and neck area are, for example:

- Occipital and mastoid lymph nodes - skin of posterior scalp and neck
- Parotid lymph nodes - parotid gland, buccal mucosa, tympanic cavity, eyelids

- Retropharyngeal lymph nodes - pharynx, palate, nasal cavity

- Submental and submandibular lymph nodes - lip, anterior two-thirds of tongue, floor of mouth, submandibular gland

- Internal jugular (upper and lower deep cervical) lymph nodes, tongue, floor of mouth, palate, pharynx, larynx, thyroid gland

Refer to the Figures 6 and 28 if you need help in clarifying the locations of these lymph nodes.

¹cervical--Pertaining to the neck, or to the neck of any organ or structure.

Q14

A general term for lymph nodes located in the neck is _____.

Q15

A general term for lymph nodes of the transverse cervical chain and of the lowest nodes of the internal jugular (upper and lower deep cervical) and spinal accessory chains is _____.

Q16

List five examples of specific cervical nodes:

1. _____
2. _____
3. _____
4. _____
5. _____

Q17

What is another name commonly used for submandibular nodes?

Answer: Q14

A general term for lymph nodes located in the neck is cervical. You will learn more about the specific names of cervical nodes in Book 6, Comparative Staging Systems for Cancer.

Answer: Q15

A general term for lymph nodes of the transverse cervical chain and of the lowest nodes of the internal jugular (upper and lower deep cervical) and spinal accessory chains is supraclavicular.

Answer: Q16

Any of the neck nodes mentioned on page 74 are considered cervical lymph nodes.

Answer: Q17

The submandibular nodes and submaxillary nodes are the same.

Lymph Nodes of the Thorax

The lymph nodes of the thorax may be classified as parietal¹ or visceral² depending upon whether they are near the walls of the thoracic cavity or within the thorax, respectively. The primary regional lymph nodes and the sites which these nodes drain in each of the areas of the thorax are:

- **Parietal Area**

Internal mammary (parasternal) lymph nodes - breast and chest wall

Intercostal lymph nodes - chest wall and pleura

Diaphragmatic lymph nodes - diaphragm, pleura

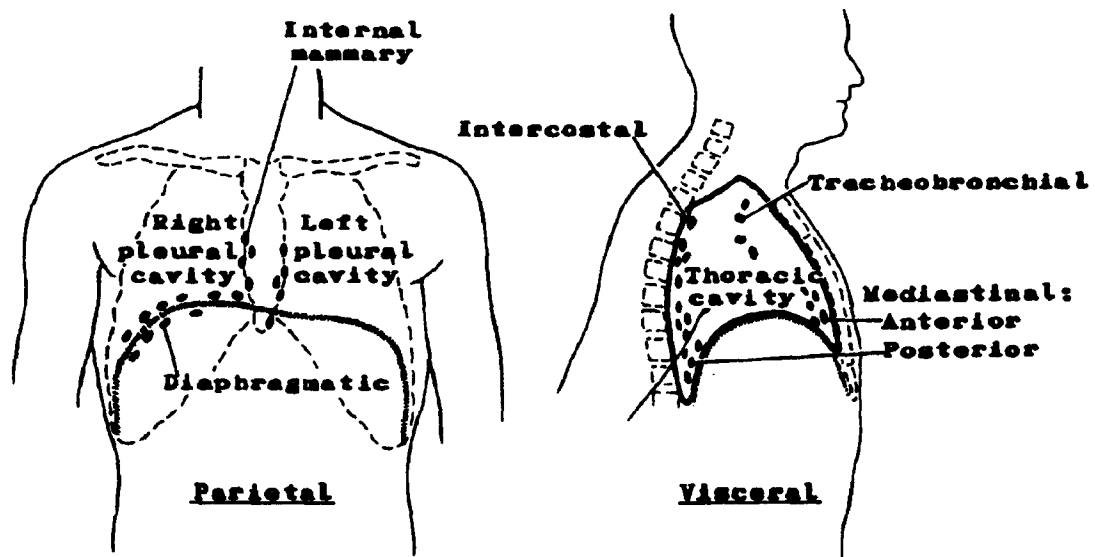
- **Visceral Area**

Anterior mediastinal lymph nodes - lung, pleura, trachea, thyroid, thymus, pericardium

Posterior mediastinal lymph nodes - lung, pleura, esophagus, pericardium

Tracheobronchial (carinal, peritracheal, hilar) lymph nodes - trachea, bronchus, lung, upper esophagus

Figure 12B. LYMPH NODES OF THE THORAX



¹parietal--Of or pertaining to the walls of a cavity.

²visceral--Contained within a body cavity; pertaining to the internal organs or viscera.

Q18

Lymph nodes of the thorax may be classified as _____ if located in relation to (near) the chest wall or _____ if located deeper within the thoracic cavity.

Q19

Indicate whether the following lymph nodes are parietal or visceral using the initial letters P and V:

_____ Intercostal

_____ Posterior mediastinal

_____ Diaphragmatic

_____ Tracheobronchial

_____ Internal mammary

Answer: Q18

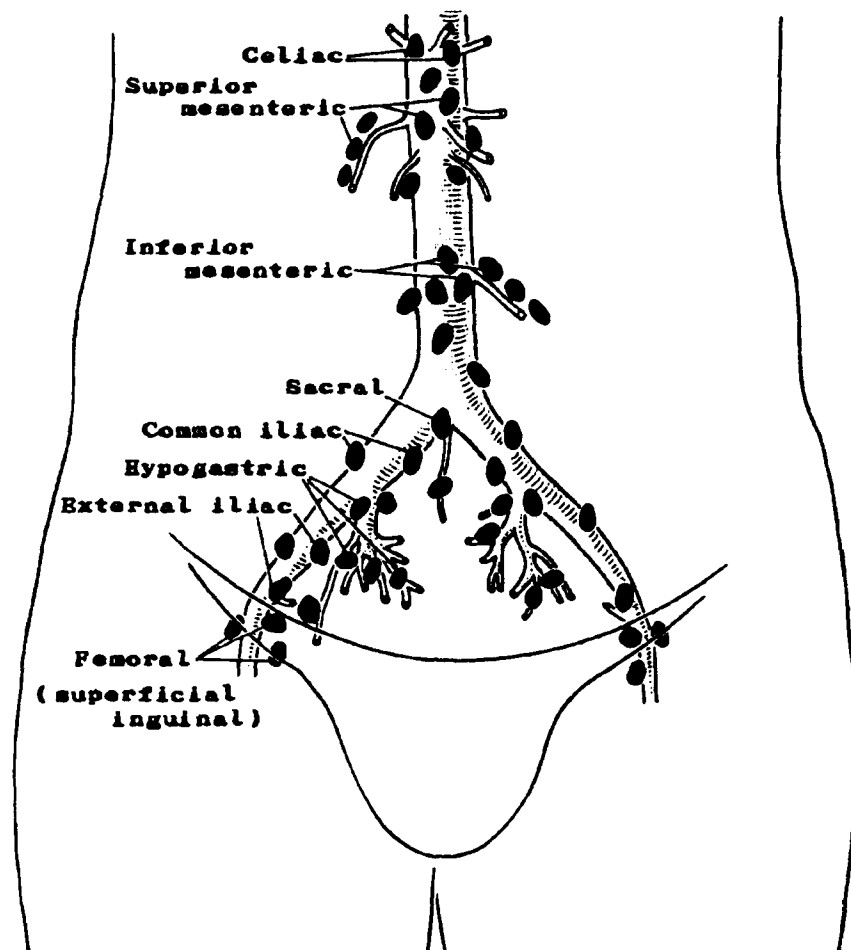
Lymph nodes of the thorax may be classified as parietal if located in relation to (near) the chest wall or visceral if located deeper within the thoracic cavity.

Answer: Q19

The parietal and visceral lymph nodes are indicated by P or V as follows:

- P Intercostal
- V Posterior mediastinal
- P Diaphragmatic
- V Tracheobronchial
- P Internal mammary

Figure 13. LYMPH NODES OF THE ABDOMEN AND PELVIS



Lymph Nodes of the Abdomen and Pelvis

The parietal nodes of the abdomen and pelvis are situated behind the peritoneum¹ and are commonly called retroperitoneal nodes. These nodes lie parallel to the aorta and the iliac arteries (below the bifurcation² of the aorta). The principal parietal nodes and some of the sites whose lymphatics drain directly into these nodes are:

- Aortic (para-aortic) lymph nodes: kidney, suprarenal (adrenal) gland, ovary, testis, corpus uteri
- Iliac (common, internal, external) lymph nodes: uterus, vagina, ovary
- Sacral lymph nodes: rectum, uterus, prostate gland

The visceral nodes of the abdomen are located along the branches of the celiac artery (left gastric, hepatic and splenic arteries) and the superior and inferior mesenteric arteries. These three major arteries branch off the aorta as it passes through the abdomen. The regional lymph nodes which drain the abdominal viscera and some of the sites which they drain are:

- Superior or left gastric lymph nodes: stomach, intrathoracic esophagus
- Inferior or right gastric lymph nodes: stomach, duodenum
- Splenic lymph nodes: stomach, spleen, body and tail of pancreas
- Superior mesenteric lymph nodes: jejunum, ileum, pancreas, ampulla of Vater
- Inferior mesenteric lymph nodes: descending colon, splenic flexure, sigmoid colon, rectosigmoid, rectum

Refer to Figure 13 for a diagram of abdominal and pelvic lymph nodes.

The lymphatics following the course of the above named arteries carry the lymph back to nodes located along the aorta; however, the aortic nodes are considered distant nodes for abdominal sites.

¹peritoneum--The serous membrane lining the interior abdominal cavity and investing (covering) the abdominal viscera.

²bifurcation--Division into two branches; in this example, division of the aorta into the right and left common iliac arteries.

Q20

Lymph nodes of the abdomen may also be classified as visceral or parietal. The _____ lymph nodes are located along branches of the celiac, superior, and inferior mesenteric arteries. Specific names for the lymph nodes located along branches of the celiac artery are:

1. _____
2. _____
3. _____

Q21

The _____ lymph nodes are located behind the peritoneum along the aorta and the iliac arteries. They are commonly called _____ lymph nodes. Specific names for these lymph nodes are:

1. _____
2. _____
3. _____

Answer: Q20

Lymph nodes of the abdomen may also be classified as visceral or parietal. The visceral lymph nodes are located along branches of the celiac and superior and inferior mesenteric arteries. Specific names for the lymph nodes located along branches of the celiac artery are:

1. Inferior or right gastric
2. Splenic
3. Superior or left gastric

Answer: Q21

The parietal lymph nodes are located behind the peritoneum along the aorta and the iliac arteries. They are commonly called retroperitoneal lymph nodes. Specific names for these lymph nodes are:

1. Aortic (periaortic)
2. Iliac
3. Sacral

Lymph Nodes of Upper and Lower Extremities

Located deep within the underarm and upper chest, the axillary nodes receive lymphatic drainage from the breast, skin, and other tissues of the arm, hand, shoulder, chest wall, and upper back. The lymphatics of the hand and forearm first drain through a few epitrochlear nodes situated just above the bend of the elbow, dorsally.

Analogous to the epitrochlear nodes are the popliteal nodes located behind the knee. These nodes drain the skin of the heel and posterior leg. The other lower extremity nodes are the femoral (superficial inguinal) nodes located in the groin (the area between the abdomen and upper thigh). The nodes associated with the upper and lower extremities and the sites which drain into these nodes are:

- Axillary lymph nodes: Arm, hand, shoulder, chest wall, upper back, breast
- Epitrochlear lymph nodes: Forearm, hand
- Femoral (superficial inguinal) lymph nodes: Vulva, penis, anus, scrotum, perineum,¹ anterior abdominal wall, lumbar region, lower back, lower extremities (excluding heel)
- Popliteal lymph nodes: Posterior leg, heel

See Figures 8A and 8B, for a diagram of lymph nodes of the upper and lower extremities.

¹perineum--The skin-covered muscular region between the vagina and the anus in the female and between the scrotum and the anus in the male.

Q22

Match the lymph nodes on the left with their most appropriate description of drainage on the right:

<u>Lymph Nodes</u>	<u>Description of Drainage</u>
1. ____ Popliteal	a. Arm
2. ____ Axillary	b. Forearm
3. ____ Epitrochlear	c. Heel
4. ____ Superficial inguinal	d. Thigh

Answer: Q22

- | | | |
|----------|-------------------------|---------|
| <u>c</u> | 1. Popliteal | Heel |
| <u>a</u> | 2. Axillary | Arm |
| <u>b</u> | 3. Epitrochlear | Forearm |
| <u>d</u> | 4. Superficial inguinal | Thigh |

Malignant and Benign Tumors

Benign tumors of lymphoid tissue are rare. Those of the lymphatic vessels, as you have already learned, are known as lymphangiomas. Cancer registries may, or may not, elect to include these tumors.

Malignant Lymphomas

Lymphomas are malignancies of the lymph nodes and other lymphatic structures, such as the spleen, thymus, Waldeyer's ring (tonsils), Peyer's patches (ileum) of the small intestine, and lymphoid nodules of the appendix as well as extralymphatic/extranodal sites such as stomach and skin.

There are two principal kinds of lymphomas:

1) Hodgkin's disease, which commonly arises in lymph nodes and other lymphatic structures, makes up 19% of all lymphomas. Of the Hodgkin's disease cases reported, 99% are nodal.

2) Non-Hodgkin's lymphoma (NHL), which frequently arises in extralymphatic/extranodal sites as well as in lymph nodes and other lymphatic structures, makes up 81% of all lymphomas. Of the non-Hodgkin's lymphoma cases reported, 77% are nodal and 23% are extranodal.

The classification of NHL is discussed in detail in ICD-O-2 including a discussion of extranodal and nodal lymphomas.

Hodgkin's disease. The histologic classification of Hodgkin's disease has changed over the years. The original classification of Hodgkin's disease by Jackson and Parker in 1947 consisted of paraganuloma, granuloma, and Hodgkin's sarcoma. These all have specific code numbers in ICD-O, first edition, and ICD-O-2. However, such terms are rarely used any more. The Lukes-Butler classification came into existence in the early 1960's and was modified at the Rye, NY Conference in 1966 and was then called the Rye classification or modification. It represents a spectrum based on the relative proportion of malignant cells seen, as follows:

- Lymphocytic predominance type (LP)
- Nodular sclerosis type (NS)
- Mixed cellularity type (MC)
- Lymphocytic depletion type (LD)
- Unclassified type (NOS)

Further additions or splits can be seen in ICD-O-2, such as splitting lymphocytic predominance by whether it is diffuse or nodular.

One of the requirements for a diagnosis of Hodgkin's disease is the identification by the pathologist of Reed-Sternberg cells¹ (malignant cells) in an appropriate cellular environment.

There is indirect evidence that Hodgkin's disease involves the T-cell component of the immune system.

¹Reed-Sternberg cell--Characteristic giant cell with large, inclusion-like nucleoli and double or multiple nuclei.

Q23

Benign tumors of lymphoid tissue are frequent/rare. (Circle one.)

Q24

Malignant tumors of the lymphoid tissue may be divided into two general categories:

1. _____

2. _____

Q25

Name the four major types of Hodgkin's disease according to the histologic classification:

1. _____

2. _____

3. _____

4. _____

Q26

One requirement for a diagnosis of Hodgkin's disease is identification by the pathologist of the presence of _____ cells.

Answer: Q23

Benign tumors of lymphoid tissue are rare. Tumor registries may, or may not, elect to include these tumors.

Answer: Q24

The two general categories for lymphomas are:

1. Hodgkin's disease
2. Non-Hodgkin's lymphomas

Answer: Q25

The four major types of Hodgkin's disease according to the current histologic classification are:

1. Lymphocytic predominance
2. Mixed cellularity
3. Lymphocytic depletion
4. Nodular sclerosis

Answer: Q26

One requirement for a diagnosis of Hodgkin's disease is the presence of Reed- Sternberg cells.

Non-Hodgkin's Malignant Lymphoma. The classification of non-Hodgkin's lymphoma has undergone many changes. Most diagnostic schemes will describe it in terms of two parameters: pattern of growth and cell type. The most commonly used schemes describe the proliferative pattern of growth as:

- Nodular (follicular)
- Diffuse

There are six systems used throughout the world to classify non-Hodgkin's lymphoma:

Rappaport classification
BNLI--British National Lymphoma Investigation
Dorfman Classification
Kiel Classification
Lukes-Collins
World Health Organization

Several special conferences and meetings have been held to resolve the confusion that resulted from the various systems used and to reconcile the differences among them.

In 1979, the National Cancer Institute planned and sponsored a multi-institutional study of the six histopathologic systems used in the classification of non-Hodgkin's lymphoma to assess their clinical applicability and reproducibility. The results of the study, based on clinical correlations (survival curves, age, sex, presenting sites, and stage of disease), were published as a summary and description of a working formulation for clinical usage.¹ The summary does not represent a new classification system, but rather, is "intended as a means of translation among all systems." It is discussed in detail in the ICD-O-2 on pages xxxii-xxxvi.

¹Cancer 49: 2112-2135, 1982.

Extralymphatic/Extranodal Sites

Lymphoid tumors may be described as "nodal" or "extralymphatic," sometimes called "extranodal," in reference to their sites of origin. Tumors classified as "nodal" include those arising in lymphatic tissue, such as in the spleen or Waldeyer's ring, as well as those originating in lymph nodes. Waldeyer's ring includes:

Base of tongue (lingual tonsil)
Oropharynx (palatine tonsil)
Nasopharynx (pharyngeal tonsil)

"Extralymphatic" refers to tumors originating in sites which are not primarily composed of lymphoid tissue. The most common extralymphatic sites are:

Stomach
Skin (mycosis fungoides)
Small intestine (ileum) and appendix

These extralymphatic sites may represent the primary site of lymphoma or may be involved as areas of metastatic spread from primary lymph node tumors. The cancer registrar must attempt to determine from all of the evidence in the medical record whether the lymphoid tumor has originated in or spread to these areas. This is not always readily determined. If in doubt, an opinion should be sought from the clinician or pathologist to determine how the case can most accurately be entered in the registry.

Rules for Determining Multiple Primaries for Lymphatic and Hematopoietic Diseases:

The tables entitled *Introduction and General Instructions* at the back of this manual are to be used to help determine multiple primaries of the lymphatic and hematopoietic diseases.

RULES to follow are:

1. No topography (site) is to be considered in determining multiple primaries of lymphatic and hematopoietic diseases. Multiple primaries are determined by histology (see the tables at the back of this manual).

2. The interval between diagnoses is NOT to enter into the decision.

Example: A lymphocytic lymphoma (M-9670/3) diagnosed in March, 1987 and an unspecified non-Hodgkins's lymphoma (M-9590/3) diagnosed in April, 1988 would be considered one primary, a lymphocytic lymphoma diagnosed in March, 1987 (the earlier diagnosis).

Q27

Non-Hodgkin's lymphomas may be described in terms of the predominant _____
_____ and the degree of _____. The proliferative pattern may
also be described as _____ or _____.

Q28

Lymphomas are primarily of _____ origin, but two common
extralymphatic sites are _____ and _____.

Answer: Q27

Non-Hodgkin's lymphomas may be described in terms of the predominant cell type and the degree of differentiation. The proliferative pattern may also be described as nodular or diffuse.

Answer: Q28

You might have said lymphomas are primarily of lymph node origin, but two common extralymphatic sites are the stomach and small intestine or any of the extralymphatic sites listed on page 94.

SECTION E
THE CARDIOVASCULAR SYSTEM

THE CARDIOVASCULAR SYSTEM

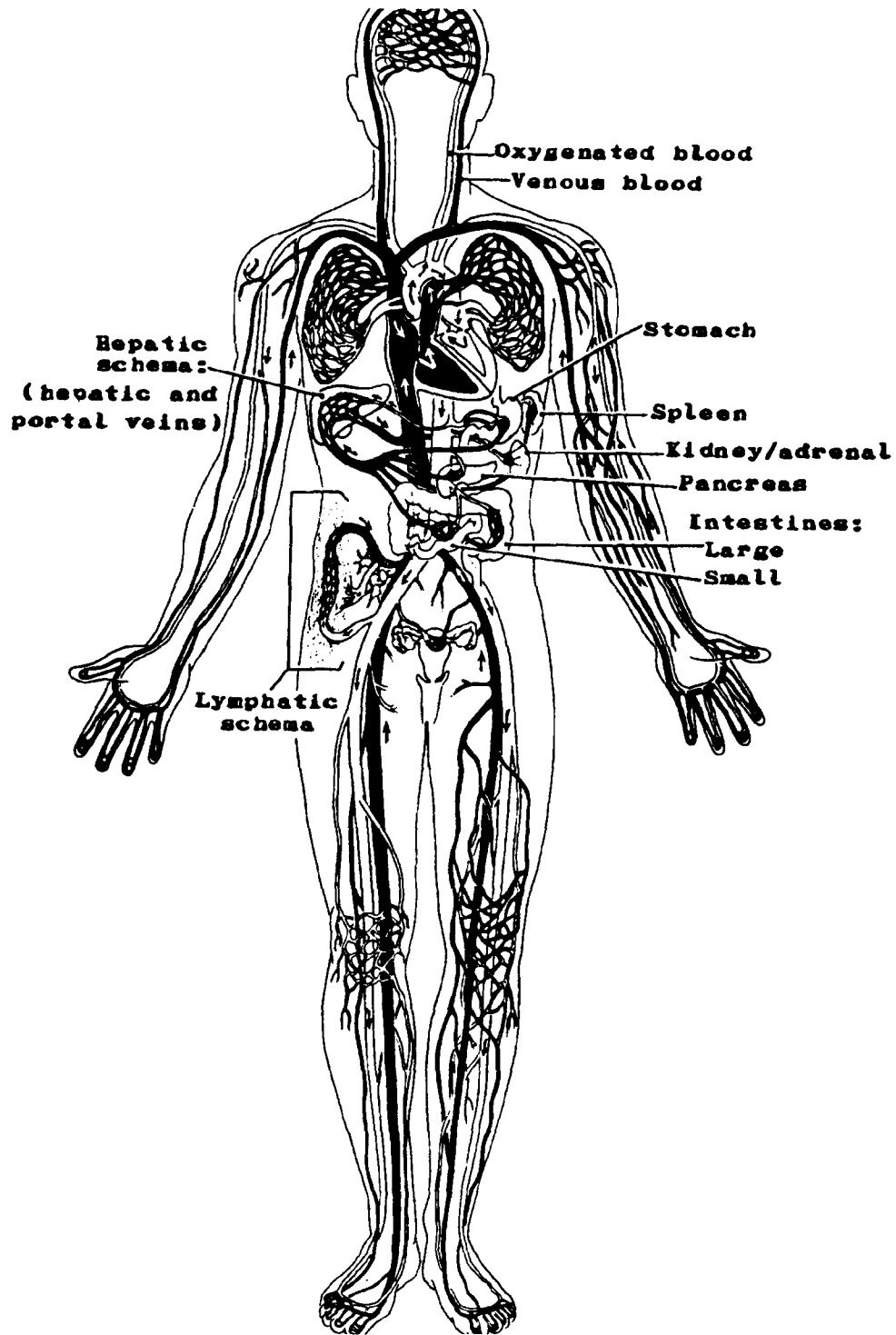


Figure 14A. BLOOD FLOW THROUGH THE BODY
(schematic approximation; not anatomic location of organs)

SECTION E

THE CARDIOVASCULAR SYSTEM

The cardiovascular (circulatory) system consists of the heart and a system of blood vessels (arteries, capillaries, veins) through which blood is transported from the heart to the tissues of the body and back again. Actually, the heart is a double pump, driving the blood through two circuits (Figures 14A-D):

- The *pulmonary circuit* conveys blood from the right side of the heart to the lungs and then returns it to the left side of the heart (see page 105).
- The *systemic circuit* carries blood from the left side of the heart to the rest of the body and returns it to the right side of the heart (see page 105).

If there were no mechanism for constantly changing or freshening the tissue fluid of the body, it would soon become depleted of food and oxygen and become saturated with waste products. In addition to its primary function of transporting various substances to and from body cells, the circulatory system contributes to cellular metabolism, balance (homeostasis) of fluid volume, balance of Ph (hydrogen-ion concentration), homeostasis of body temperature, and defense against microorganisms.

Figure 14B. HEART

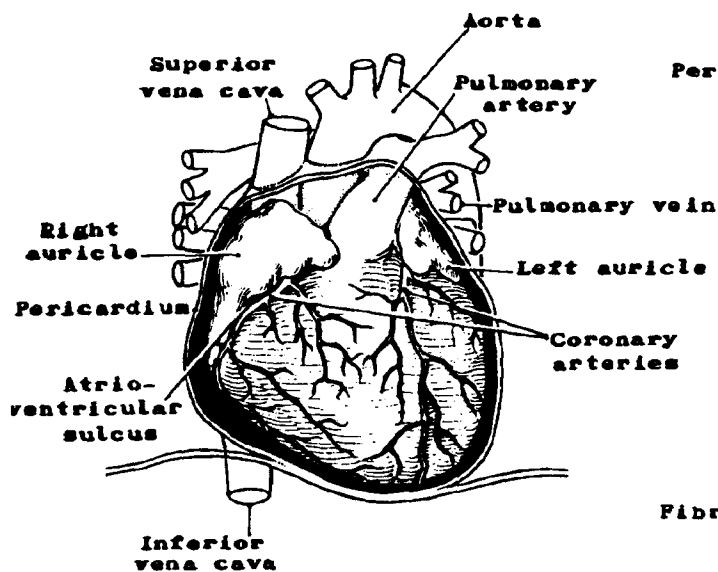
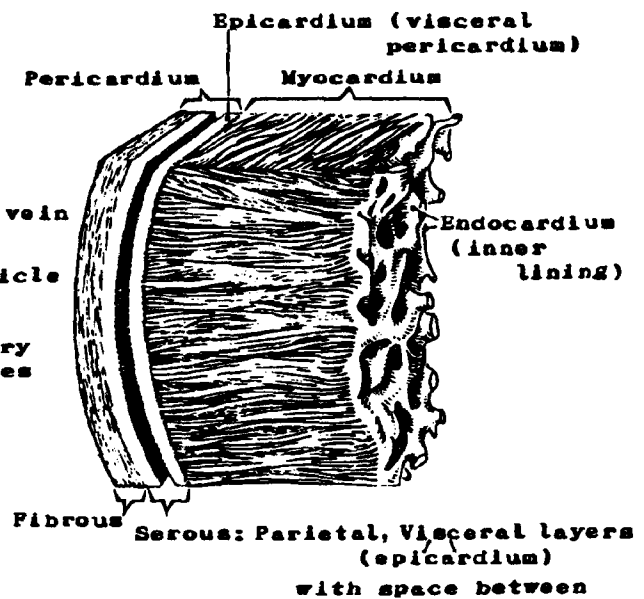


Figure 14C. MUSCLE WALL OF HEART



CIRCULATORY SYSTEM

Figure 14D. BLOOD FLOW THROUGH HEART

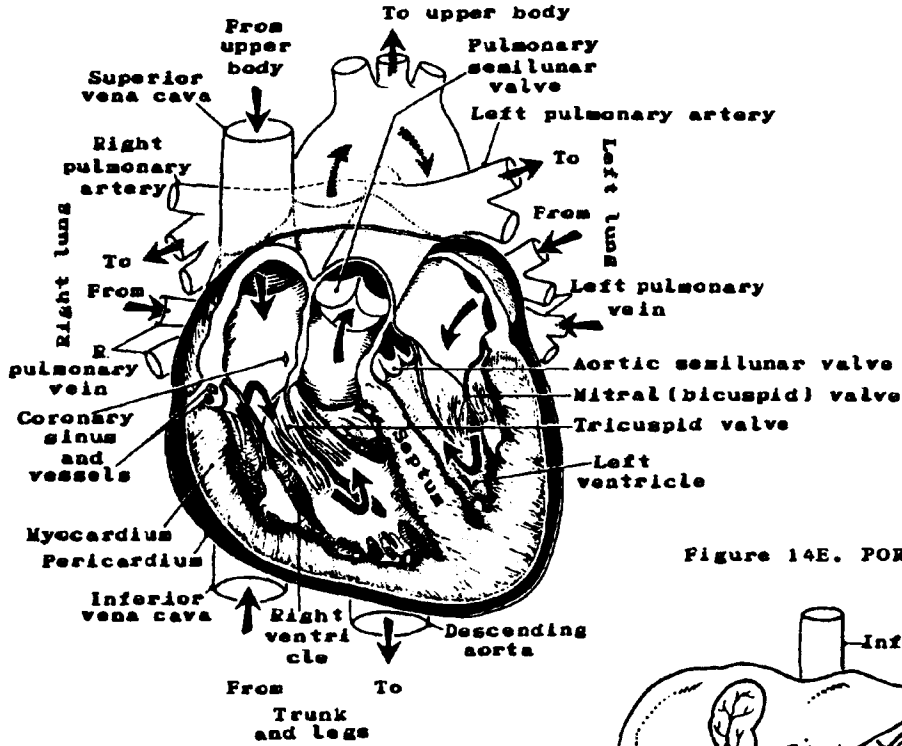
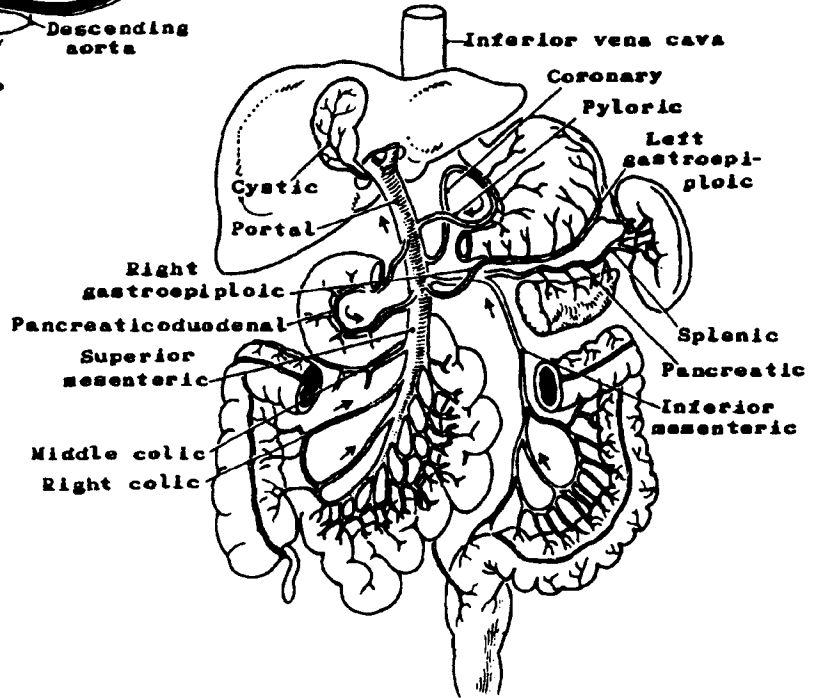


Figure 14E. PORTAL CIRCULATION



Q1

The cardiovascular system consists of an organ called the _____ and a system of blood vessels:

_____, _____, and _____.

Q2

The cardiovascular system is comprised of two separate circuits:

1. The _____ circuit conveys blood to the lungs and then returns it to the _____ side of the heart.

2. The _____ circuit conveys blood to the rest of the body and then returns it to the _____ side of the heart.

Q3

The primary function of the cardiovascular system is to _____ blood to and from the body cells thus providing them with _____ and _____ and carrying away _____

_____.

Q4

The cardiovascular system also contributes to:

1. _____
2. _____
3. _____
4. _____
5. _____

Answer: Q1

The cardiovascular system consists of an organ called the heart and a system of blood vessels: arteries, capillaries, and veins.

Answer: Q2

- 1) The pulmonary circuit conveys blood to the lungs and then returns it to the left side of the heart.
- 2) The systemic circuit conveys blood to the rest of the body and then returns it to the right side of the heart.

Answer: Q3

The primary function of the cardiovascular system is to transport (carry) blood to and from the body cells thus providing them with food (nutrients) and oxygen, and carrying away waste products.

Answer: Q4

The cardiovascular system also contributes to:

- 1) Cellular metabolism

"Metabolism" is usually the term applied to the over-all series of chemical reactions taking place within the body cells in which oxygen and nutrients are consumed and carbon dioxide and other wastes are produced in the release of energy.

- 2) Balance (homeostasis) of fluid volume
- 3) Balance of pH (a measure of hydrogen-ion concentration: A pH of 7.0 is neutral; above 7.0 alkalinity increases and below 7.0 acidity increases.)
- 4) Homeostasis of body temperature
- 5) Defense against microorganisms

Heart and Pericardium

The heart is a hollow muscular organ about the size of a human fist lying within the mediastinum, between the lungs, with its apex on the diaphragm. It has four chambers (see Figure 14B).

- Right and left atria

The atria are small receiving chambers much like big veins. The right atrium, which receives blood from the systemic circulation, is larger than the left atrium, which receives blood from the lungs only. Both atria have thinner walls than do the ventricles since they have less pressure exerted on them than do the ventricles, just as veins have thinner walls than do arteries.

- Right and left ventricles

The ventricles are large, contracting chambers with thick walls. The walls of the left ventricle are thicker because the left ventricle must pump blood to the most distant parts of the body; the right ventricle pumps blood only to the lungs.

The openings between the atria and ventricles, the atrioventricular orifices, are controlled by cuspid valves:

- The tricuspid valve controls the opening between the right atrium and the right ventricle.
- The mitral (bicuspid) valve controls the opening between the left atrium and the left ventricle.

Semilunar valves control the opening from the right ventricle into the pulmonary artery and the opening from the left ventricle into the great aorta.

The heart muscle (myocardium) receives its blood supply from the branches of the right and left coronary arteries (Figure 14B). These vessels come off the ascending aorta just as this structure exits from the left ventricle.

A small mass of modified cardiac muscle called the sinoatrial node and an additional mass now termed the atrioventricular junction, along with an abundant nerve supply, contribute to the stimulation and regulation of heart action.

The heart lies in a loose-fitting sac called the *pericardium*. This sac is composed of an outer fibrous portion and an inner serous portion. The inner portion consists of two layers:

- The parietal layer lining the inside of the fibrous pericardium
- The visceral layer (epicardium) adhering to the exterior surface of the heart.

Between the parietal and visceral layers is a potential space, the pericardial space, which contains a few drops of pericardial fluid. This fluid reduces friction during movement of the heart.

The walls of the heart are composed of three layers:

- The *epicardium* or outer layer of the heart (the visceral layer of the serous pericardium described above)
- The *myocardium* or heart muscle
- The *endocardium* or inner lining of the four chambers of the heart.

The Heart As a Pump. You will recall that the heart receives blood from both systemic and pulmonary circuits.

- The **DEOXYGENATED BLOOD RETURNS** to the right atrium of the heart **FROM THE SYSTEMIC CIRCUIT** via the superior and inferior vena cavae. From the right atrium, the blood moves through the tricuspid valve into the right ventricle. When the right ventricle contracts, the tricuspid valve closes and the blood is forced through the pulmonary semilunar valve into the pulmonary trunk which divides into the right and left pulmonary arteries. The blood flows through the pulmonary arteries to the pulmonary capillaries where it absorbs oxygen and releases carbon dioxide.
- The **OXYGENATED BLOOD RETURNS** to the left atrium of the heart **FROM THE PULMONARY CIRCUIT** via the pulmonary veins. From the left atrium, the blood moves through the mitral (bicuspid) valve into the left ventricle. When the left ventricle contracts, the mitral valve closes, and the blood is forced through the aortic semilunar valve into the aorta and into the systemic circulation.

The pumping action of the heart creates pressure on the walls of the blood vessels which can be measured when your blood pressure is taken. Both the systolic¹ and the diastolic² values are measured.

¹systolic blood pressure--The force with which the blood is pushing against the artery walls when the ventricles are contracting.

²diastolic blood pressure--The force with which the blood is pushing against the artery walls when the ventricles are relaxed.

Q5

The heart has four chambers called right and left _____ and right and left _____.

Q6

The heart lies within a loose-fitting sac call the _____ and is located in the _____ between the _____ with its apex on the _____.

Q7

The serous covering of the heart has two layers:

- 1) the _____ layer
- 2) the _____ layer

Q8

The heart walls are thickest in ventricles/atria because of the pumping action of these chambers.

(Circle one.)

Q9

Which veins contain oxygenated blood?

Answer: Q5

The heart has four chambers called the right and left atria and the right and left ventricles.

Answer: Q6

The heart lies within a loose-fitting sac called the pericardium and is located in the mediastinum between the lungs with its apex on the diaphragm.

Answer: Q7

The serous covering of the heart has two layers:

- 1) The parietal layer
- 2) The visceral layer (epicardium)

Answer: Q8

The heart walls are thickest in the ventricles because of the pumping action of these chambers.

Answer: Q9

The right and left pulmonary veins contain oxygenated blood.

Q10

Deoxygenated blood from the body returns to the _____ (side) by way of two major veins: the _____ and the _____. The blood from these vessels enters into the _____ (chamber). Blood is moved through the _____ valve into the _____ (chamber). When this chamber contracts, it forces blood through the _____ valve into the _____ (vessel), sending blood to the _____ to be oxygenated.

The oxygenated blood returns to the _____ (side) of the heart by way of the _____ (vessels) and enters into the _____ (chamber). Blood is then moved through the _____ valve into the _____ (chamber). When this chamber contracts, it forces blood through the _____ valve into the _____, sending blood out into the _____ circulatory system.

Answer: Q10

Deoxygenated blood from the body returns to the right (side) of the heart by way of two major veins: the superior vena cava and the inferior vena cava. The blood from these vessels enters into the right atrium (chamber). Blood is moved through the tricuspid valve into the right ventricle (chamber). When this chamber contracts, it forces blood through the pulmonary semilunar valve into the pulmonary artery (vessel), sending blood to the lungs to be oxygenated.

The oxygenated blood returns to the left (side) of the heart by way of the pulmonary veins (vessels) and enters into the left atrium (chamber). Blood then is moved through the mitral valve into the left ventricle (chamber). When this chamber contracts, it forces blood through the aortic semilunar valve into the aorta, sending blood out into the systemic circulatory system.

Blood Vessels

There are three kinds of blood vessels:

- *Arteries*--vessels that convey blood away from the heart. The pulmonary arteries carry deoxygenated blood from the heart to the lungs; all other arteries carry oxygenated blood from the heart to all other parts of the body.
- *Veins*--vessels that convey blood towards the heart. The pulmonary veins carry oxygenated blood from the lungs to the heart; all other veins carry deoxygenated blood from all the other parts of the body to the heart.
- *Capillaries*--microscopic vessels that carry blood from small arteries (arterioles) to small veins (venules). More importantly, they are the site of exchange of oxygen, nutrients, carbon dioxide, and waste products between the blood and the interstitial fluid.

The function of arteries¹ and arterioles² is to carry blood away from the heart to the capillaries. Capillary blood delivers oxygen and nutrients to the tissue fluid and collects carbon dioxide and other wastes from it. Finally, veins³ and venules⁴ return the blood from the capillaries to the heart. Arteries have thicker walls than do veins since the arteries have more pressure exerted on them.

¹artery--A vessel which conveys blood away from the heart to the various parts of the body.

²arteriole--A minute arterial branch, especially one just proximal to a capillary.

³vein--A vessel which conveys blood to or towards the heart from various parts of the body.

⁴venule--A minute vein, especially one distal to a capillary.

Portal System (portal circulation)

Veins from the spleen, stomach, pancreas, and intestines converge to form the portal vein which carries blood and nutrients to the liver. The portal vein is formed by the joining of the splenic and the superior mesenteric veins. However, blood from the gastric, pancreatic, and inferior mesenteric veins drains into the splenic vein before it merges with the superior mesenteric vein.

In the liver the venous blood is processed in special structures called sinusoids. It mingles with the arterial blood in the capillaries, exchanges nutrient material with the liver cells, and is eventually drained from the liver by the hepatic veins that join the inferior vena cava.

If the portal circulation is interfered with (by certain types of liver disease, cancerous obstruction, or heart failure), venous drainage from most of the abdominal organs is decreased or shut off. This results in increased capillary pressure causing ascites (fluid in the abdominal cavity).

The liver is a frequent site of blood-borne metastasis because those tumors of the intestinal tract which drain into the portal system are filtered out in the liver.

Primary malignancies of the liver (including intrahepatic bile ducts) are relatively rare in the United States. They include:

- Hepatocellular carcinoma or hepatoma (arising from the liver cell)
- Intrahepatic bile duct carcinoma or cholangiocarcinoma (arising from the bile duct cell).

Q11

Name the three kinds of blood vessels and state their functions:

1. _____: _____

2. _____: _____

3. _____: (a) _____

(b) _____

Q12

What is the relationship of the portal system and the venous system?

Q13

What happens if the portal circulation is interfered with or blocked?

Answer: Q11

The three kinds of blood vessels and their functions are as follows:

1. Arteries: Carry blood away from the heart
2. Veins: Carry blood towards the heart
3. Capillaries: a) Carry blood from small arteries (arterioles) to small veins (venules)
b) Exchange nutrient material, oxygen, carbon dioxide, and waste products between blood and interstitial fluid.

Answer: Q12


The portal system is part of the venous system. It is comprised of veins from the spleen, stomach, pancreas, and intestines which converge to form the portal vein which carries blood to the liver and the hepatic veins which convey the blood from the liver to the inferior vena cava.

Answer: Q13

If portal circulation is interfered with, venous drainage from most abdominal organs is shut off. This results in increased capillary pressure causing ascites.

Blood

Blood is the fluid which circulates through the heart, arteries, veins, and capillaries carrying food and oxygen to all the cells in the body and returning waste products to points of separation from the blood, i.e., the kidneys, lungs, and sweat glands. The composition of the blood is as follows:



The blood cells, or formed elements of the blood, are suspended in the fluid medium called plasma which normally represents fifty-five to sixty percent of blood volume. The blood test which measures the percent of cells compared to the total volume is called the hematocrit.

The clear liquid that separates from the blood when it is allowed to clot completely is called "serum." Serum is essentially blood plasma from which fibrinogen has been removed in the process of clotting.

Erythrocytes or red blood cells transport oxygen picked up in the lungs to tissues throughout the body and return carbon dioxide to the lungs. The formation of red blood cells (erythropoiesis) takes place in the bone marrow. After an average life of about four months, the red blood cells (erythrocytes) are destroyed in the liver and spleen. The blood count (RBC) is normally 4.5-6.0 million cells per cu. mm. of blood for men and 4.5-5.5 million for women.

The *hemoglobin* or oxygen-carrying component of blood is measured in terms of grams percent (gm. %) or grams per 100 milliliters (gm./100 ml.) of blood. The hemoglobin content of the blood determines the amount of oxygen that it carries and is responsible for the red color of the erythrocyte and of the blood.

The red blood cell count may be lowered due to anemia or hemorrhage. It may be increased as a result of dehydration or of polycythemia¹ vera.

¹polycythemia--Excess in the number of erythrocytes in the blood.

Q14

What are the three main types of blood cells?

1. _____

2. _____

3. _____

Q15

The blood cells are suspended in a fluid called _____.

Q16

The blood test which measures the percent of cells compared to total volume is called the _____.

Q17

By way of hemoglobin, erythrocytes or _____ _____ _____ transport oxygen picked up in the lungs to tissues in the body and return carbon dioxide to the lungs.

Answer: Q14

The three main types of blood cells are:

1. Red blood cells or erythrocytes
2. White blood cells or leukocytes
3. Platelets or thrombocytes

Answer: Q15

The blood cells are suspended in a fluid called plasma.

Answer: Q16

The blood test which measures the percent of cells compared to total volume is called the hematocrit.

Answer: Q17

By way of hemoglobin, erythrocytes or red blood cells transport oxygen picked up in the lungs to tissues in the body and return carbon dioxide to the lungs.

Leukocytes, or white blood cells, function as a defense against invading microorganisms. The total white blood cell count (WBC) is normally 5,000-10,000 per cu. mm. of blood, but may increase to very high levels in cases of infection or as a reaction to treatment by radiation and/or chemotherapy. There are several types of white blood cells. The relative percentages of the various cells found in blood is called the white cell differential (see *Book 5, Abstracting a Medical Record*).

Leukocytes are produced in the bone marrow and in lymphoid tissue. Granulocytes (granular leukocytes), lymphocytes and monocytes (agranular leukocytes or mononuclear leukocytes) originate in the bone marrow, but multiply in the lymphoid tissue.

Platelets (thrombocytes) are formed in the bone marrow by fragmentation of large cells (megakaryocytes). Platelets normally number 200,000 to 500,000 per cu. mm. of blood. Upon disintegration they release a substance, thromboplastin, which combines with blood proteins and calcium to form prothrombin which initiates the production of fibrin to form blood clots (coagulation). Sometimes a blood clot will form within the heart or blood vessels partially or totally obstructing the vessel. Such a blood clot is called a *thrombus*. When a thrombus is dislodged and moves to another location, it is called an *embolus* (thromboembolus).

Q18

White blood cells which are known as _____ function as a defense or protection against invading microorganisms (infection).

Q19

When a blood clot forms in and clogs a vessel, it is called a _____.

Answer: Q18

White blood cells which are known as leukocytes function as a defense or protection against invading microorganisms (infection) or as a reaction to treatment by radiation and/or chemotherapy.

Answer: Q19

When a blood clot forms in and clogs a vessel, it is called a thrombus. When a blood clot breaks loose from an area in a vein and travels to another area and becomes lodged there, it is called an embolus.

Leukemia

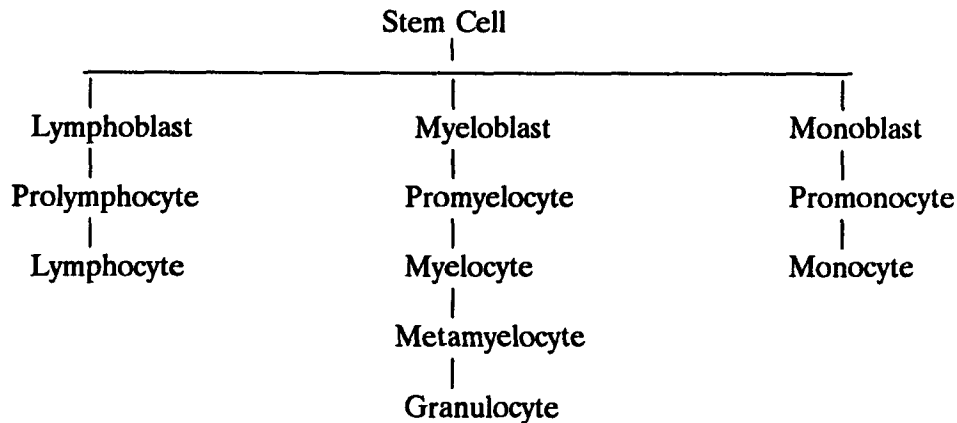
Leukemia is a malignant disease of the blood-forming organs. As with other malignant diseases, leukemia is characterized by an uncontrolled proliferation of cells, in this case the white blood cells or leukocytes. However, an elevated leukocyte count usually represents a nonneoplastic reaction to infection or treatment by radiation and/or chemotherapy.

Leukemias are classified according to the type and number (percent) of abnormal cells and the rapidity of the clinical course. The predominant cell types are:

- Lymphocytic
- Myeloid/Granulocytic
- Monocytic

Leukemias are diagnosed by the microscopic detection of abnormal cells in the circulating (peripheral) blood and in the bone marrow. These abnormal cells may be described as atypical, immature, or "blast forms"--lymphoblasts, myeloblasts, or monoblasts. These are terms for immature cells which have not yet developed into the mature forms, namely, lymphocytes, granulocytes, or monocytes. The presence of myelocytes, metamyelocytes, or promyelocytes indicates granulocytic (myelocytic) leukemia; prolymphocytes indicate lymphatic (or lymphocytic) leukemia, and promonocytes indicate monocytic leukemia. In some cases the cells may be so undifferentiated or immature that they are impossible to identify and the disease may be classified as stem cell or blastic leukemia. You will recognize these terms in the outline (page 124) showing the development of white blood cells from stem cells. During the development of blood cells in the bone marrow, the primitive immature (unspecialized) stem cells change shape and structure several times in the course of becoming mature differentiated (specialized) blood cells.

DEVELOPMENT OF WHITE BLOOD CELLS



Leukemias may also be categorized as acute, subacute, or chronic. In acute leukemia the white cell population will show a high proportion of blast forms, while in chronic leukemia the majority of cells will be more mature. The clinical progression of disease is extremely rapid in acute leukemia, but in chronic leukemia it may remain unchanged for a long period of time even without treatment.

The total white blood cell count (WBC) will be significantly elevated in most cases of leukemia (leukocytosis). However, particularly in chronic leukemia, the leukocyte count may be normal or actually below normal (leukopenia) in which case the disease may be classified as aleukemic (subleukemic) leukemia.

A decreased platelet count (thrombocytopenia) and a decreased hemoglobin level are characteristic of patients with a diagnosis of leukemia.

There are variants of the major types listed above. Consult your medical dictionary and other reference books for descriptions of unfamiliar terms. There are also diagnoses such as erythroleukemia (Di Guglielmo's disease) and plasma cell leukemia which, although termed leukemias, are actually neoplasms involving other blood cells and not leukocytes.

See *Book 5, Abstracting A Medical Record* for a review of definitions of hematologic terms and normal values.

Note: Other neoplasms arising in bone marrow (multiple myeloma, plasmacytoma, plasma cell myeloma) are closely related to the leukemias and will be discussed later in Section K, The Skeletal System.

Q20

Malignant diseases of the blood-forming organs are called _____.

Q21

Leukemias are characterized by uncontrolled _____ of _____
_____ and/or especially the presence of _____
or _____ cells.

Q22

The classification of leukemias is determined by the:

1. _____
2. _____
3. _____

Q23

What are three predominant cell types?

1. _____
2. _____
3. _____

Q24

Leukemias may also be categorized as follows:

1. _____
2. _____
3. _____

Answer: Q20

Malignant diseases of the blood-forming organs are called leukemias.

Answer: Q21

Leukemias are characterized by uncontrolled proliferation of white blood cells and/or especially the presence of abnormal or immature cells.

Answer: Q22

The classification of leukemia is determined by the:

1. Type of abnormal white blood cells
2. Number of abnormal white blood cells
3. Rapidity of the clinical course

Answer: Q23

Three predominant cell types are:

1. Lymphocytic
2. Granulocytic
3. Monocytic

Answer: Q24

Leukemias may also be categorized as follows:

1. Acute
2. Subacute
3. Chronic

Q25

Match the disease on the left with the characteristic on the right.

Disease

Characteristic

____ 1. Leukemia

a. An uncontrolled excess of red blood cells

____ 2. Polycythemia vera

b. An uncontrolled excess of white blood cells

Answer: Q25

- | | | |
|----------|----------------------|---|
| <u>b</u> | 1. Leukemia | An uncontrolled excess of white blood cells |
| <u>a</u> | 2. Polycythemia vera | An uncontrolled excess of red blood cells |

SECTION F
THE RESPIRATORY SYSTEM

SECTION F

THE RESPIRATORY SYSTEM

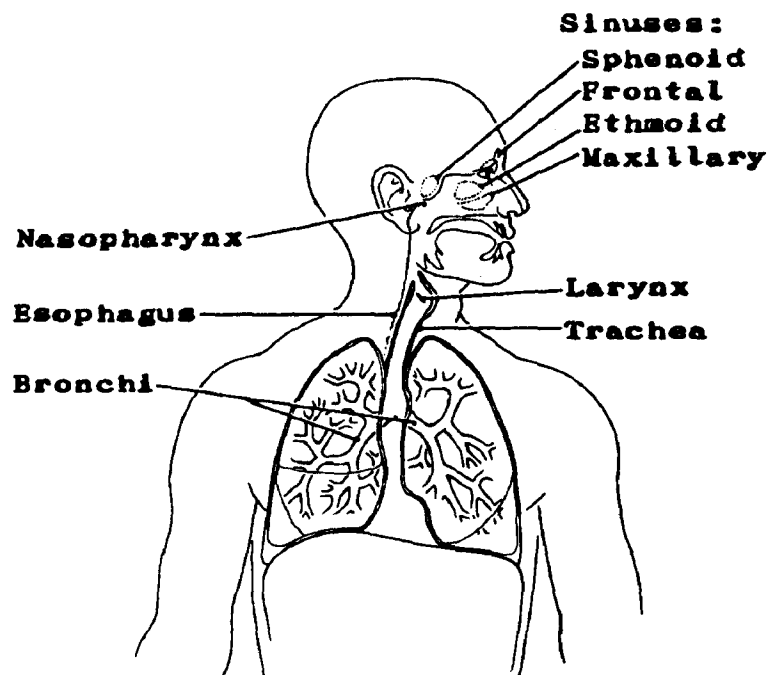
The respiratory system consists of those organs and parts of the body that make it possible to breathe. Respiration can be divided into two distinct phases: 1) external respiration and 2) internal respiration.

- External respiration involves both inspiration (inhaling) and expiration (exhaling) of air. Inspiration is the means by which oxygen is carried from the air into the lungs and then into the blood. Expiration is the means by which carbon dioxide is returned from the blood to the lungs and then expelled into the air.

- Internal respiration is concerned with the exchange of oxygen and carbon dioxide at the tissue level: the passage of oxygen from the blood to the tissues and the return of carbon dioxide from the tissues to the blood. First the oxygen is carried from the lungs by the red blood cells. Then carbon dioxide is carried by the red blood cells to the lungs. The utilization of oxygen and the elimination of carbon dioxide by the cells is called cellular respiration.

The respiratory system begins with the nose; at the other end of the system are the lungs. In between the nose and the lungs are the nasopharynx, oropharynx, larynx, trachea, and bronchi. The thorax, which houses most of the organs of the respiratory system, plays a major role in respiration. The elliptical shape of the ribs and the angle of their attachment to the spine allows the thorax to expand during inspiration. Thus, the lungs provide a place where large amounts of oxygen can be taken from the air and quickly absorbed into the bloodstream. Conversely, large amounts of carbon dioxide are discharged into the lungs where it is exhaled.

Figure 15. RESPIRATORY SYSTEM



Q1

Name the parts of the respiratory system between the nose and the lungs:

1. _____

2. _____

3. _____

4. _____

5. _____

Q2

The lungs are located in a body cavity called the _____.

Q3

The primary purpose of the respiratory system is to make it possible for _____ and _____ to exchange gases, namely, _____ and _____.

Answer: Q1

The parts of the respiratory system between the nose and the lungs are:

1. Nasopharynx
2. Larynx
3. Trachea
4. Bronchi
5. Oropharynx

Answer: Q2

The lungs are located in a body cavity called the thorax.

Answer: Q3

The primary purpose of the respiratory system is to make it possible for blood and air to exchange gases, namely, carbon dioxide and oxygen.

Nose and Paranasal (Accessory) Sinuses

The nose consists of the two nasal cavities formed by the maxilla and palatine bones and the nasal, frontal, ethmoid, and sphenoid bones. On the lateral walls are three bony structures, one above the other, which are called conchae (superior, middle and inferior), so-called because they resemble shells. They may also be referred to as turbinates. The external orifices of the nose are the nostrils; the posterior orifice, or the opening into the nasopharynx, is called the choana. The nasal cavities are lined with mucous membrane.

The nose serves as a passageway for air going to and coming from the lungs. Air passes through the nose and, then, into the nasopharynx. The nose filters the air of certain impurities, warms it, and moistens it. In addition, the nose can detect the presence of certain types of chemicals which might be irritating to the mucous lining of the respiratory tract. The nose serves also as the organ for the sense of smell. Olfactory (odor) receptors are located in the nasal mucosa. The nose aids also in phonation (the making of vocal sounds).

The paranasal sinuses are air cavities lined with mucous membrane. The frontal sinuses are located in the bone of the forehead above the orbital cavities. The ethmoid sinuses are made up of small air cells located between the upper nasal cavities and the orbits. The sphenoid sinuses are wedge-shaped sinuses in the bone at the back of the orbital cavities. The maxillary sinuses (antrum of Highmore) are located in the upper jawbone.

The external and internal carotid arteries supply blood to the nose and the paranasal sinuses. The venous blood returns to the internal and external jugular veins.

The lymphatic vessels from the nose and the paranasal sinuses enter the retropharyngeal, submental, submandibular (submaxillary), and the internal jugular (upper and lower deep cervical) lymph nodes.

Malignant Tumors

While tumors of the nasal cavities are rare, the most common type is squamous cell (epidermoid) carcinoma. Other types which occur less frequently are adenocarcinoma, adenoid cystic carcinoma, melanoma, and lymphoma. A malignant tumor known as esthesioneuroblastoma or esthesioneuroepithelioma, which arises in the olfactory nerve, will be found occasionally in the nasal cavities.

Ninety percent of the neoplasms of the paranasal sinuses are located in the maxillary sinuses. Histologically, the tumors are similar to those found in the nasal cavities.

Q4

What are the purposes of the nose?

1. _____
2. _____
3. _____
4. _____
5. _____

Q5

Name the paranasal sinuses:

1. _____
2. _____
3. _____
4. _____

Q6

What is the most common histologic type of malignant tumor which you would expect to find in the nasal cavities and paranasal sinuses?

Answer: Q4

1. Serves as a passageway for air going to and from the lungs.
2. Filters the air of impurities, warms it, and moistens it.
3. Detects the presence of chemicals which might be irritating to the mucous lining of the respiratory tract.
4. Serves as the organ of smell.
5. Aids in phonation (the making of vocal sounds).

Answer: Q5

The paranasal sinuses are:

1. Frontal
2. Ethmoid
3. Sphenoid
4. Maxillary

Answer: Q6

The most common histologic type of malignant tumor which you would expect to find in the nasal cavities and paranasal sinuses is squamous cell carcinoma.

Nasopharynx

The pharynx is a muscular structure lined with mucous membrane. It is divided into *three parts*: the nasopharynx, located *behind the nasal cavities*; the oropharynx, located behind the oral cavity; and the hypopharynx (laryngopharynx), located behind and lateral to the larynx. The oropharynx and the hypopharynx are considered part of the digestive system and are discussed in Section G.

The *nasopharynx* is considered part of the respiratory system. Its subsites are:

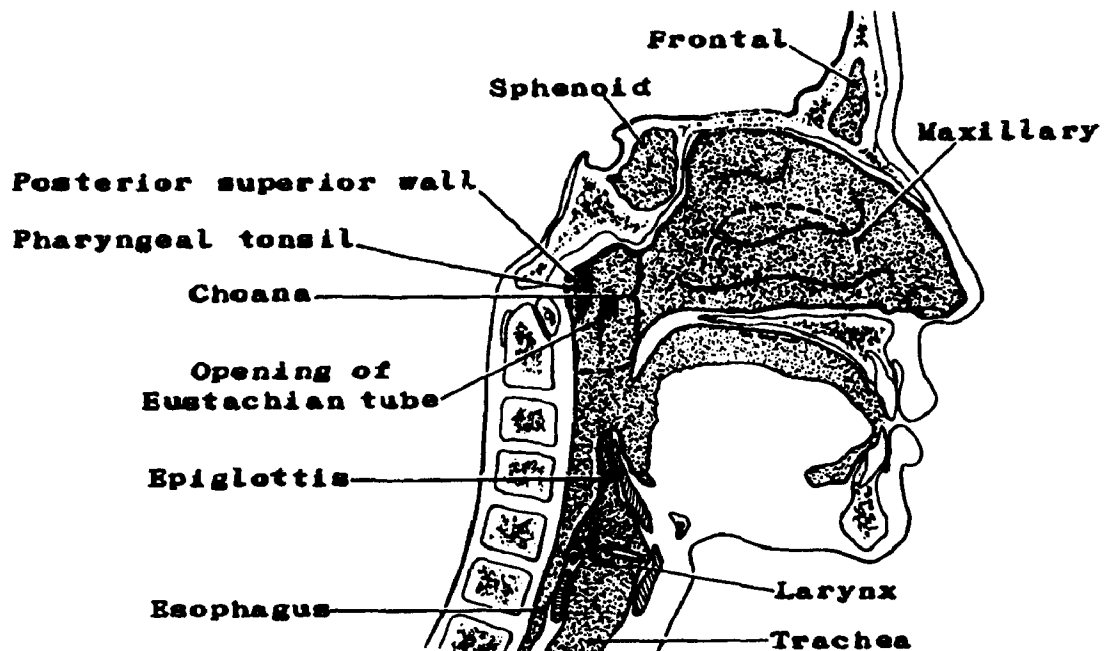
- *Posterior superior wall (vault)* extends from the *choana*, or the opening of the nasal cavities into the nasopharynx, posteriorly to a level opposite the soft palate. The pharyngeal tonsils (adenoids) are located in this part of the nasopharynx.
- *Lateral wall* extends from the base of the skull on each side to the level of the soft palate. The auditory (eustachian) tube from the middle ear opens into the lateral wall just anterior to Rosenmuller's fossa (pharyngeal recess).

Lymphatics of the nasopharynx drain into submental, submandibular (submaxillary), and internal jugular (upper and lower deep cervical): jugulodigastric, jugulo-omohyoid, and retropharyngeal lymph nodes. The blood supply is via the external carotid arteries and internal jugular veins.

Malignant Tumors

Nasopharyngeal tumors are usually squamous cell carcinoma, lymphoepithelioma, salivary gland type tumors, and, occasionally, lymphoma.

Figure 16. NASOPHARYNGEAL REGION AND PARANASAL SINUSES



Q7

The pharynx can be divided into three parts called the:

1. _____
2. _____
3. _____

Q8

The framework of the pharynx is composed of _____ and lined with a _____

_____.

Q9

The lymphoid tissue found in the nasopharynx is located in the _____
also known as the _____.

Answer: Q7

The pharynx can be divided into three parts called the:

1. Nasopharynx
2. Oropharynx
3. Hypopharynx (laryngopharynx)

Answer: Q8

The framework of the pharynx is composed of muscle and lined with a mucous membrane.

Answer: Q9

The lymphoid tissue found in the nasopharynx is located in the pharyngeal tonsils also known as the adenoids.

Larynx

The larynx or voice box is a small but complex structure situated in front of the hypopharynx and contiguous with the upper end of the trachea. The larynx consists of nine pieces of cartilage. The three single and more prominent pieces are:

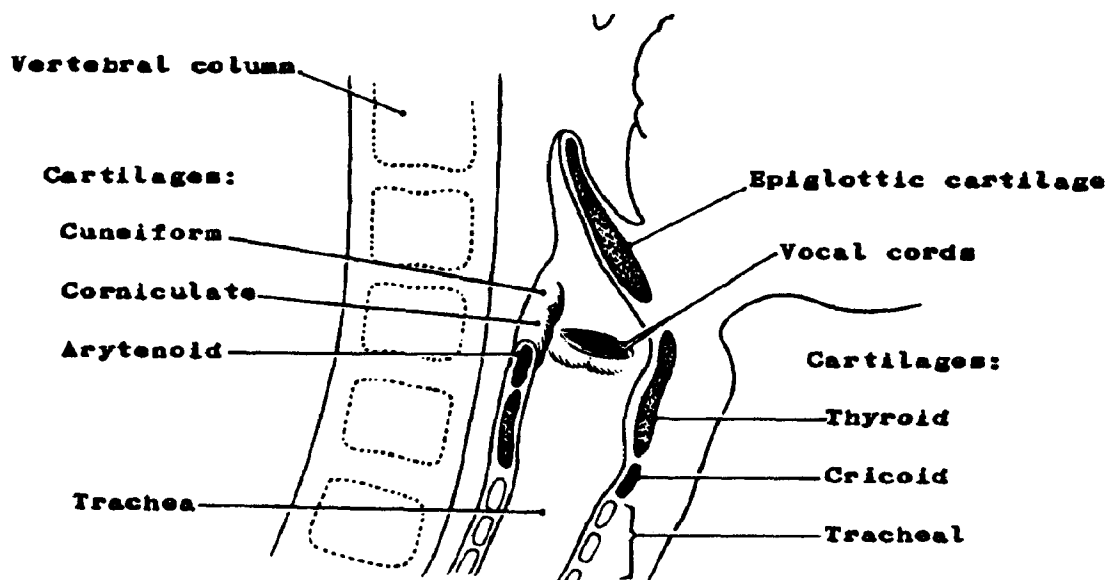
- *Thyroid cartilage* (Adam's apple)
- *Epiglottis* which has a hinge-like action and forms a kind of lid over the opening of the larynx when swallowing takes place
- The *cricoid (signet-ring) cartilage*, so named because it resembles a signet ring in shape. The cricoid cartilage forms the inferior border of the larynx.

In addition there are three paired cartilages:

- Arytenoid cartilages (jar-like)
- Corniculate cartilages (horn-like)
- Cuneiform cartilages (wedge-like)

These cartilages are united by joints strengthened by various membranes and ligaments. The mucous membrane lining of the larynx forms two horizontal folds, the false vocal cords. Below these are the true vocal cords which are fibrous bands stretched across the hollow interior of the larynx. The space between the true vocal cords is called the glottis. Air forced through these cords produces sound.

Figure 17A. LARYNX



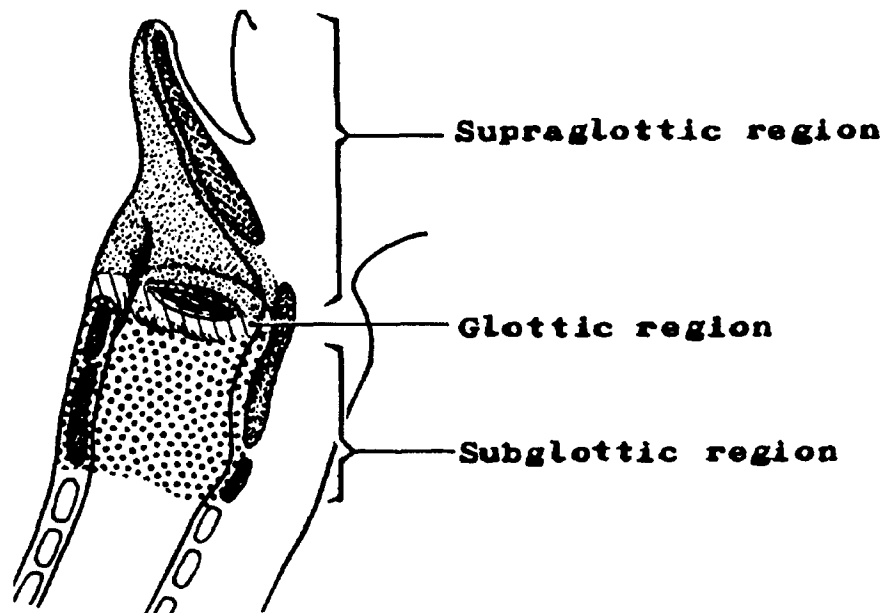
The larynx can be divided into three anatomic subsites: the supraglottis, glottis, and subglottis.

- The *supraglottis* includes the posterior (laryngeal) surface of the epiglottis, the aryepiglottic folds, the arytenoids, and the ventricular bands (false cords). The epiglottis guards the superior opening of the larynx. The aryepiglottic folds are folds of tissue which border the epiglottis and make up the sides of the entrance to the larynx.
- The *glottis* consists of the true vocal cords including the anterior and posterior commissures. The vocal cords stretch across the cavity of the larynx from the thyroid cartilage to the anterior borders of the arytenoid cartilages.
- The *subglottis* lies below the true cords and extends to the inferior border of the cricoid cartilage.

The laryngeal branches of the thyroid arteries supply the blood for the larynx. The venous drainage is by way of the laryngeal tributaries of the thyroid veins into the internal jugular veins.

The principal lymph node drainage for the larynx is to the internal jugular and anterior cervical nodes. Anterior cervical nodes are the prelaryngeal, pretracheal, paratracheal, and lateral tracheal (recurrent laryngeal) nodes. Bilateral involvement is common, and spread to submandibular and submental nodes may sometimes occur.

Figure 17B. THE ANATOMIC SUBSITES OF THE LARYNX



Malignant Tumors

The glottic region is the area of the larynx most commonly involved with cancer; however, these tumors have the most favorable prognosis. The true vocal cords contain very few lymphatics, so the probability of metastasis to regional nodes of an early cancer is small. In contrast, the supraglottis has an abundant supply of lymphatics. Cancers of the supraglottis quickly spread to the cervical lymph nodes. The subdigastric nodes of the internal jugular chain are commonly involved as well as the prelaryngeal nodes. Thus, although supraglottic cancers rank second to glottic cancers in frequency, the prognosis is worse for patients with these cancers. The rarest form of laryngeal cancer arises in the subglottic region. Squamous cell carcinoma is the most common cell type of all laryngeal cancers.

Q10

The three single cartilages in the larynx are the _____, _____, and _____.

Q11

The three paired cartilages in the larynx are the _____, _____, and _____.

Q12

The _____ vocal cords are formed by folds of mucous membrane; the _____ vocal cords are fibrous bands stretched across the hollow interior of the larynx.

Q13

The three major anatomical subsites of the larynx are:

1. _____
2. _____
3. _____

Answer: Q10

The three single cartilages in the larynx are the cricoid, thyroid, and epiglottis.

Answer: Q11

The three paired cartilages in the larynx are the arytenoid, corniculate, and cuneiform.

Answer: Q12

The false vocal cords are formed by folds of mucous membrane; the true vocal cords are fibrous bands stretched across the hollow interior of the larynx.

Answer: Q13

The three major anatomical subsites of the larynx are:

1. Supraglottis
2. Glottis
3. Subglottis

Trachea

The trachea or windpipe is a tube composed of smooth muscle lined with mucous membrane, and C-shaped rings of cartilage are embedded in the muscle. The trachea extends from below the cricoid cartilage of the larynx to the carina, and is about 2.5 cm in diameter and about 10 cm long. The trachea forms a major part of the passageway through which external air reaches the lungs, the simple but vital function of this structure. The trachea is a rare tumor site.

Bronchi

At its lower end, the trachea divides into the right main stem bronchus and left main stem bronchus (primary bronchi) at the carina. The walls of the bronchi are made of cartilage with a ciliated mucous lining. The extrapulmonary portion of each bronchus enters the lung on its own side and immediately divides into branches called lobar (secondary) bronchi. The secondary bronchi continue to branch, forming bronchioles which become smaller and smaller, forming microscopic branches which divide into alveolar ducts. At the terminal ducts are grape-like formations known as alveolar sacs which provide surfaces where the exchange of air and carbon dioxide takes place.

The intrapulmonary (lobar) bronchi are lined with ciliated columnar, mucin-producing epithelium. The walls are composed of a submucosa, smooth muscle, fibrous tissue and cartilage.

Q14

The windpipe or _____ serves as a _____ by which air can reach the _____.

Q15

The trachea divides into the _____ and _____ which in turn divide into smaller branches called _____, _____, _____, and _____.

Answer: Q14

The windpipe or trachea serves as a passageway by which air can reach the lungs.

Answer: Q15

The trachea divides into the right main stem bronchus and left main stem bronchus which in turn divide into smaller branches called lobar/secondary bronchi, bronchioles, alveolar ducts, and alveolar sacs.

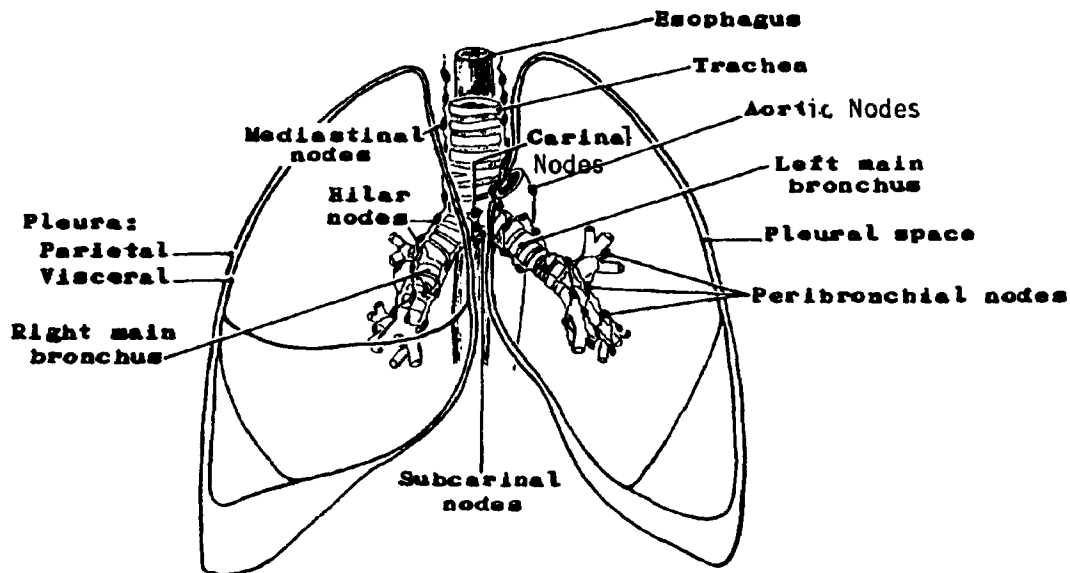
Lungs

The lungs are cone-shaped organs of respiration which lie in the thoracic cavity, one on either side of the mediastinum.

The rounded upper portion of each lung is called the apex; the base is the concave lower portion resting on the diaphragm; and the hilus is the area on the medial surface through which the main bronchus, pulmonary artery, pulmonary vein, nerves, and lymph vessels enter and leave each lung. The left lung is partially divided by a fissure into an upper and lower lobe. Projecting from the lower portion of the left upper lobe is an area called the lingula (coded to left upper lobe). The right lung is divided by two fissures into three lobes (upper, middle, and lower).

Visceral pleura or mesothelium covers the outer surfaces of the lungs and adheres to them (See Figure 18). Parietal pleura or mesothelium lines the thorax. The potential space between the visceral and parietal pleura is called the (inter)pleural space or pleural cavity. The pleural space contains a lubricating pleural fluid which eliminates friction during the breathing process. This fluid drains to the mediastinal nodes. When the mediastinal nodes become inflamed or involved with a disease process such as a malignancy, a pleural effusion develops. Breathing then becomes labored and painful.

Figure 18. LUNGS



The lungs provide a place where large amounts of oxygen can be loaded quickly into the blood and large amounts of carbon dioxide can be removed from it. The PULMONARY ARTERY from the right side of the heart branches into two arteries which carry DEOXYGENATED blood to both lungs. Each artery continues dividing and subdividing within the lungs forming smaller and smaller vessels which end in capillaries which surround the alveolar sacs of the respiratory bronchioles. As the blood passes through the pulmonary capillaries, it absorbs oxygen and releases carbon dioxide. Then the newly OXYGENATED blood immediately returns through the venules (small veins) to the PULMONARY VEINS which return to the left side of the heart.

The lung itself gets its nutriment supply from the bronchial arteries which branch off the aorta.

All regional lymph nodes for the lung and the pleura are above the diaphragm. They include the intrathoracic, scalene, and supraclavicular. The intrathoracic lymph nodes can be divided into two main groups: intrapulmonic and mediastinal.

1. Intrapulmonic:

- Intrapulmonary (incl. interlobar, lobar, segmental)
- Hilar (proximal lobar, pulmonary roots)
- Peribronchial

2. Mediastinal:

- Carinal (subcarinal/precarinal)
- Mediastinal (anterior, posterior)
- Peri/paratracheal (incl. tracheobronchial, lower peritracheal, azygos)
- Pretracheal and retrotracheal (incl. precarinal)
- Peri/paraesophageal
- Aortic (peri/para aortic, subaortic, aorticopulmonary window, ascending aorta or phrenic), above the diaphragm
- Pulmonary ligament

If any of the above nodes are contralateral or bilateral, they are still considered regional, by the American Joint Committee on Cancer (AJCC), but are put in a separate category (N3) along with the supraclavicular and scalene nodes. Historically, these lymph nodes have been classified as "distant."

"Vocal cord paralysis," "superior vena cava syndrome," and "compression of the trachea or the esophagus" are classified as mediastinal lymph node involvement unless there is a statement of involvement by direct extension from the primary tumor.

Q16

The main bronchus, pulmonary artery and veins, nerves and lymph vessels enter and leave through the _____ of the lung.

Q17

Describe the lobes of the lung:

a. Right lung: _____

b. Left lung:

Q18

_____ covers the outer surface of the lung, while _____
_____ lines the thorax.

Answer: Q16

The main bronchus, pulmonary artery and veins, nerves and lymph vessels enter and leave through the hilus of the lung.

Answer: Q17

The lobes of the lung may be described as follows:

- a. Right lung: The right lung has three lobes--upper, middle, and lower.
- b. Left lung: The left lung has two lobes--upper and lower.

Answer: Q18

Visceral pleura covers the outer surface of the lung, while parietal pleura lines the thorax.

Malignant Tumors

Carcinoma of the lung originates in the mucosal lining of the bronchi, bronchioles, and alveoli. The tumors may grow into the lumen of the bronchus or they may invade the wall of the bronchus into the lung parenchyma. Most bronchogenic carcinomas arise near the hilus of the lung and will extend along the main bronchus towards the carina into the mediastinum involving the organs and structures located in the mediastinum--the pericardium, major blood vessels and nerves, trachea, and esophagus--or they may extend peripherally to invade the pleura, chest wall, and ribs.

The histologic types of neoplasms which are commonly found in the lung are listed below:

- *Squamous cell carcinoma* is the most common type of bronchogenic carcinoma. It is believed to arise as a result of irritation of the bronchial mucosa causing squamous metaplasia progressing to squamous cell carcinoma. Cigarette smoking has been linked to the increasing incidence of squamous cell carcinoma of the lung.
- *Adenocarcinoma* may arise from the mucous glands embedded in the submucosa, or, since both adenocarcinoma and squamous cell carcinoma arise in the bronchus, it is thought that all bronchogenic carcinomas may arise from the multipotential reserve cells¹ of the bronchial epithelium. Adenocarcinomas tend to occur more peripherally than do squamous cell carcinomas.
- *Adenosquamous carcinoma* (adenoacanthoma) is a tumor of mixed histologic type.
- *Undifferentiated carcinoma*, which is indistinguishable as either squamous cell carcinoma or adenocarcinoma, probably arises from the reserve cells. It may occur, for example, as large cell, small cell, or oat cell variants. These carcinomas have a worse prognosis than any of the above.
- *Bronchiolar (alveolar) carcinoma* arises in the terminal bronchioles or alveoli and is a rare tumor type.
- *Bronchial adenoma* is somewhat of a misnomer for a tumor that is frequently invasive. Variants are the carcinoid or cylindroid which are invariably malignant.
- *Mesothelioma* arises in the pleura or mesothelium that lines the pleural cavities and covers the lungs. It may be either benign or malignant.
- Carcinoids arise from enterochromaffin (EC) cells which occur primarily in the submucosa of the main bronchi.

The lung is one of the most common sites of metastatic disease since the body's blood flows directly into this organ and all lymphatic drainage, whether direct or retrograde, eventually flows into the lungs.

¹reserve cells--Cells of the basal or germinal layer of the bronchial epithelium.

Clinical Manifestations

Clinical manifestations which are significant in the diagnosis of lung cancer are:

- Atelectasis (incomplete expansion--airless/functionless)
- Obstructive pneumonitis (inflammation)
- Superior vena cava syndrome (edema of the face, neck, and upper arms) caused by compression of the superior vena cava (most often by enlarged mediastinal lymph nodes)
- Vocal cord paralysis caused by involvement of the recurrent laryngeal nerve
- Paralysis of the diaphragm as a result of phrenic nerve involvement
- Pleural effusion (accumulation of fluid in the interpleural space (pleural cavity))

These findings are used in the clinical assessment of lung cancer.

Q19

What is the interpleural space (pleural cavity)?

Q20

Name the two groups of intrathoracic lymph nodes which drain the lung and pleura:

1. _____

2. _____

Q21

The most common type of bronchogenic carcinoma is _____.

Q22

The type of cancer which may arise from mucous glands embedded in the submucosa is

_____.

Q23

_____ is the most virulent type of bronchogenic carcinoma.

Answer: Q19

The interpleural space may be described as the space between the visceral pleura and parietal pleura.

Answer: Q20

The two groups of intrathoracic nodes which drain the lung and pleura that you might have mentioned are:

1. Intrapulmonary
2. Mediastinal

Answer: Q21

The most common type of bronchogenic carcinoma is squamous cell carcinoma.

Answer: Q22

Adenocarcinoma may arise from mucous glands embedded in the submucosa.

Answer: Q23

You might have said oat cell carcinoma or undifferentiated carcinoma is the most virulent type of bronchogenic carcinoma.

Match the description on the left with one of the terms on the right:

- | | | |
|-----------|---|-------------------------------|
| _____ 1. | Exchange of oxygen and carbon dioxide at the tissue level | a. thorax |
| _____ 2. | Smallest branches of bronchi | b. paranasal sinuses |
| _____ 3. | Houses most organs of the respiratory system | c. external respiration |
| _____ 4. | The beginning part of the respiratory system | d. hypopharynx |
| _____ 5. | A gaseous waste produced by body cells when oxygen and food combine | e. trachea |
| _____ 6. | The part of the pharynx located behind and lateral to the larynx | f. right lung |
| _____ 7. | The region of the larynx which houses the true vocal cords | g. internal respiration |
| _____ 8. | Thin hair-like structures which are attached to the mucous membrane epithelium lining the respiratory tract | h. nose |
| _____ 9. | A passageway extending from the larynx to the bronchi | i. left lung |
| _____ 10. | Cartilage which acts as a lid for the larynx | j. glottis |
| _____ 11. | Lung having three lobes | k. visceral pleura |
| _____ 12. | Exchange of gases between air and blood in the lungs | l. undifferentiated carcinoma |
| _____ 13. | Covering of the outer surface of the lung | m. supraglottis |
| _____ 14. | Region between the lungs in chest cavity which contains heart, aorta, esophagus, and trachea | n. parietal pleura |
| _____ 15. | Collection of lymphoid tissue in nasopharynx called pharyngeal tonsils | o. oat cell carcinoma |
| _____ 16. | Branches from the trachea which act as passageways into the air spaces of the lung | p. epiglottis |
| _____ 17. | The potential space between the visceral and and parietal pleura | q. mediastinum |
| | | r. respiratory bronchioles |
| | | s. adenoids |
| | | t. carbon dioxide |
| | | u. interpleural space |
| | | v. main bronchi |
| | | w. cilia |

Answer: Q24

- | | | |
|----------|--|-------------------------|
| <u>g</u> | 1. Exchange of oxygen and carbon dioxide at the tissue level | internal respiration |
| <u>r</u> | 2. Smallest branches of bronchi | respiratory bronchioles |
| <u>a</u> | 3. Houses most organs of the respiratory system | thorax |
| <u>h</u> | 4. The beginning part of the respiratory system | nose |
| <u>t</u> | 5. A gaseous waste produced by body cells when oxygen and food combine | carbon dioxide |
| <u>d</u> | 6. The part of the pharynx located behind and lateral to the larynx | hypopharynx |
| <u>j</u> | 7. The region of the larynx which houses the true vocal cords | glottis |
| <u>w</u> | 8. Thin hair-like structures attached to the mucous membrane epithelium lining the respiratory tract | cilia |
| <u>e</u> | 9. A passageway extending from the larynx to the bronchi | trachea |
| <u>p</u> | 10. Cartilage which acts as a lid for the larynx | epiglottis |
| <u>f</u> | 11. Lung having three lobes | right lung |
| <u>c</u> | 12. Exchange of gases between the air and the blood in the lungs | external respiration |
| <u>k</u> | 13. Covering of the outer surface of the lung | visceral pleura |
| <u>q</u> | 14. Region between the lungs in chest cavity which contains heart, aorta, esophagus, and trachea | mediastinum |
| <u>s</u> | 15. Collection of lymphoid tissue in nasopharynx called pharyngeal tonsils | adenoids |
| <u>v</u> | 16. Branches from the trachea which act as passageways into the air spaces of the lung | main bronchi |
| <u>u</u> | 17. The potential space between the visceral and parietal pleura | interpleural space |

SECTION G
DIGESTIVE SYSTEM

DIGESTIVE SYSTEM: Esophagus-Rectum

PRIMARY SITE	MUCOSA				SUB-MUCOSA	MUSCULARIS PROPRIA	SEROSA
	Epithelium	: : :	Lamina Propria	Muscularis Mucosae			
Esophagus (C15._)	Yes	: B A S E M E N T : M E M B R A N E : :	Yes	Yes	Yes	Yes	No
Stomach (C16._)	Yes		Yes	Yes	Yes	Yes	Yes
Sm. Intestine (C17._)	Yes		Yes	Yes	Yes	Yes	Yes
Colon (C18._)	Yes		Yes	Yes	Yes	Yes	Yes
Rectosigmoid (C19.9)	Yes		Yes	Yes	Yes	Yes	Yes
Rectum (C20.9)	Yes		Yes	Yes	Yes	Yes	No

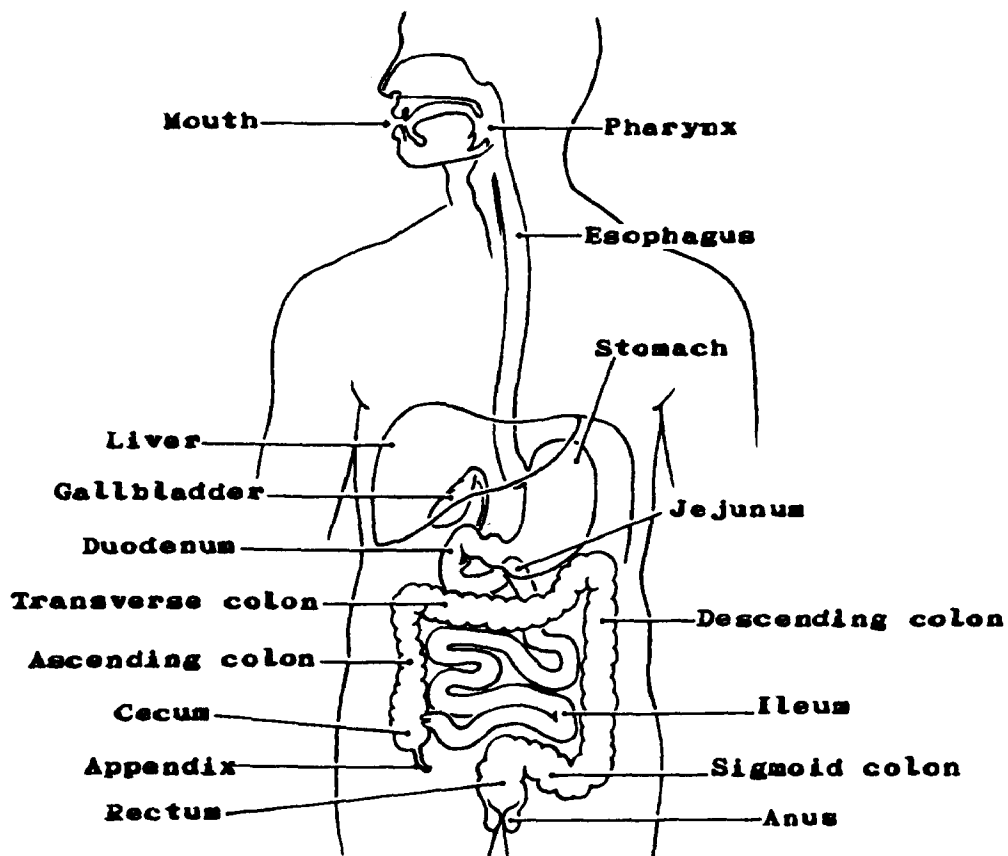
SECTION G

DIGESTIVE SYSTEM

The main organs of the digestive system form a muscular tube extending from the lips to the anus. This tube is open at both ends and is referred to as the alimentary canal or the gastrointestinal (GI) tract.

Organs which compose the GI tract are the mouth, pharynx, esophagus, stomach, small intestine, colon, rectum and anus. There are other accessory organs and structures derived from the primitive gut and located in either the main digestive tract or opening into it. These include the tongue, teeth, gums, salivary glands, pancreas, gallbladder, bile ducts, liver, and appendix. The principal parts of the digestive system are shown in Figure 19 below.

Figure 19. PRINCIPAL PARTS OF THE DIGESTIVE SYSTEM



The organs of the digestive system perform the vital function of altering the food so that it can be used as nourishment by the body cells. The process of changing the chemical and physical composition of food so that it can be utilized by the body is called digestion. The digestive system provides the source of energy required for growth, maintenance, and function of the body. This energy is derived from the assimilation of food by the cells of the body through a series of chemical reactions called metabolism.

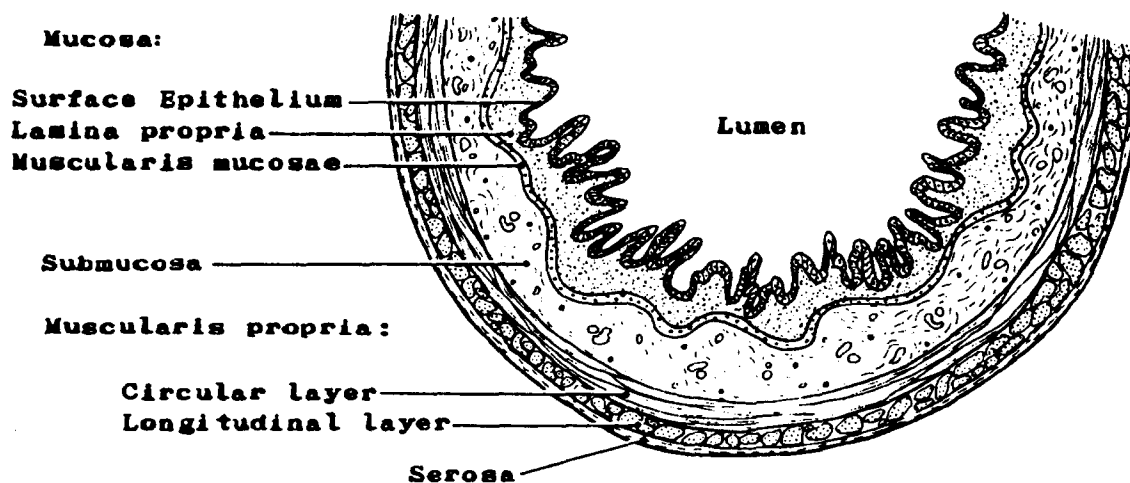
The walls of most of the organs of the gastrointestinal tract are made up of three main layers of tissue:

- A mucous lining called the *mucosa*. It consists of a surface epithelium, a lamina propria, and, in most of the length of the GI tract (lower esophagus, stomach, small intestine, colon, and rectum), a muscularis mucosae.
- A *submucosa* of connective tissue in which are embedded blood and lymph vessels
- A *muscularis propria* or muscular layer

Most of the organs have a *serosa* or covering layer of visceral peritoneum which invests the organ to a varying extent depending on the particular segment of the organ and its mesenteric attachments. The cecum, transverse colon and sigmoid are almost completely invested with peritoneum, while the ascending colon and descending colon are covered only on their anterior surfaces. The posterior portions of these two segments of the colon are covered by loose areolar tissue.

Study the diagram below carefully so that you will recognize the names of the various tissue layers of the organ wall. The depth of invasion of a neoplasm into the various layers of the wall is an important measure of the spread of the tumor. You will utilize this information in Book 6 when you study extent of disease and the staging of malignant tumors.

Figure 20. STRUCTURE OF INTESTINAL WALL



Q1

The main organs of the digestive system form a tube extending from the lips to the anus called the _____ canal or _____ tract.

Q2

The main structures which compose the digestive/alimentary tract are the:

- | | |
|----------|----------|
| 1. _____ | 5. _____ |
| 2. _____ | 6. _____ |
| 3. _____ | 7. _____ |
| 4. _____ | 8. _____ |

Q3

The three main tissue layers of the walls of the organs which make up the gastrointestinal tract and their peritoneal covering (if present) are called:

1. _____
2. _____
3. _____
4. _____

Q4

The mucosa may be made up of three layers which are:

1. _____
2. _____
3. _____

Answer: Q1

The main organs of the digestive system form a tube extending from the lips to the anus called the alimentary canal or digestive tract.

Answer: Q2

The main structures of the digestive/alimentary tract are:

1. Mouth
2. Pharynx
3. Esophagus
4. Stomach
5. Small intestine
6. Colon
7. Rectum
8. Anus

Answer: Q3

The three main tissue layers of the walls of the organs which make up the gastrointestinal tract and their peritoneal covering (if present) are called:

1. Mucosa
2. Submucosa
3. Muscularis propria
4. Serosa

Answer: Q4

The three layers of the mucosa are:

1. Surface epithelium
2. Lamina propria
3. Muscularis mucosae

Mouth

The gastrointestinal tract begins with the mouth (oral cavity). The lips form the anterior wall of the oral cavity; the cheeks (buccal mucosa) form the lateral walls; the hard and soft palates form the roof; the floor of the mouth forms the base of the cavity. Structures within the mouth are the tongue, gums (gingiva), and teeth. The entire cavity is lined with mucous membrane, but the muscularis mucosae found in other parts of the gastrointestinal tract is not present in the mouth or pharynx. The lamina propria and submucosa are, therefore, generally indistinguishable.

Food enters through the lips and is broken up and crushed by the action of the tongue and the teeth. At the same time, it is mixed with the saliva produced by the salivary glands. Mastication thus begins the first step in the digestive process.

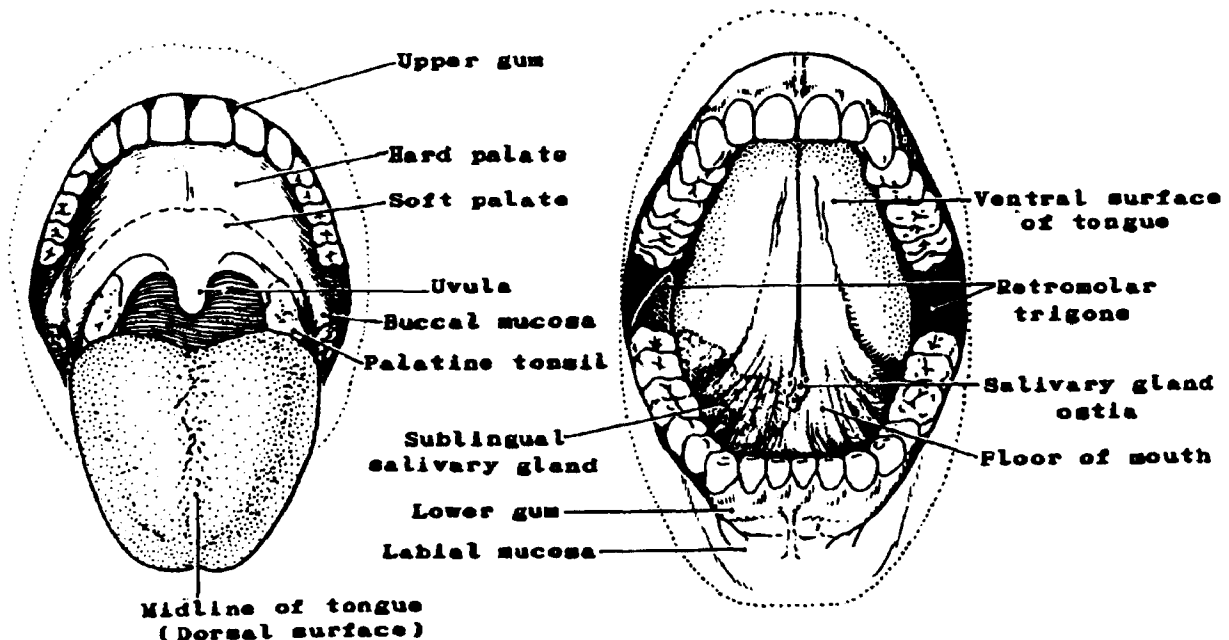
The blood supply to structures of the oral cavity is from various branches of the external carotid artery. The venous blood drains into the superficial or deep jugular veins.

Ninety percent of the malignant tumors arising in the oral cavity are squamous cell carcinoma.

Figure 21. ORAL CAVITY

A. ABOVE THE TONGUE

B. BENEATH THE TONGUE



- *Lips*. The lips form the upper and lower anterior walls of the oral cavity. Each lip consists of an exposed surface of modified epidermis known as the *vermilion border* and a *labial mucosa** (mucous membrane) which lines the inner surface of the lip. Striated muscle and fibroelastic connective tissue lie beneath the surface.

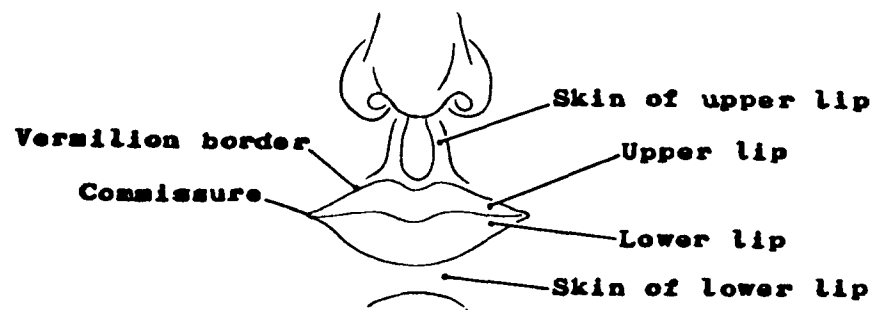
"Lip" should not be confused with "skin of lip" which is not part of the digestive system.

The *commissure* is the point of union of the upper lip and the lower lip (corner of the mouth).

Malignant Tumors

The lower lip is the most common site of malignancy in the oral cavity. Malignant tumors of the upper lip are relatively rare. The most common type of malignant tumor of the lip is squamous cell (epidermoid) carcinoma.

Figure 22. LIPS



*Note: The latest revisions of the American Joint Committee define the lip as the vermilion surface only. The mucosa of the lip is included with the buccal mucosa. The ICD-O provides separate code numbers for labial mucosa (C00.3, C00.4) and vermilion surface (C00.0, C00.1) of the lip. You can combine or separate as you wish. Historically, the mucosa of the lip has been defined as part of the lip.

Q5

The lip consists of an exposed surface of modified epithelium called the _____
_____ and an inner mucosal surface called the _____.

Q6

The point of union of the upper and lower lips is called the _____.

Q7

Lip lesions occur most frequently on the _____ lip.

Answer: Q5

The lip consists of an exposed surface of modified epithelium called the vermilion border and an inner mucosal surface called the labial mucosa.

Answer: Q6

The point of union of the upper and lower lips is called the commissure.

Answer: Q7

Lip lesions occur most frequently on the lower lip.

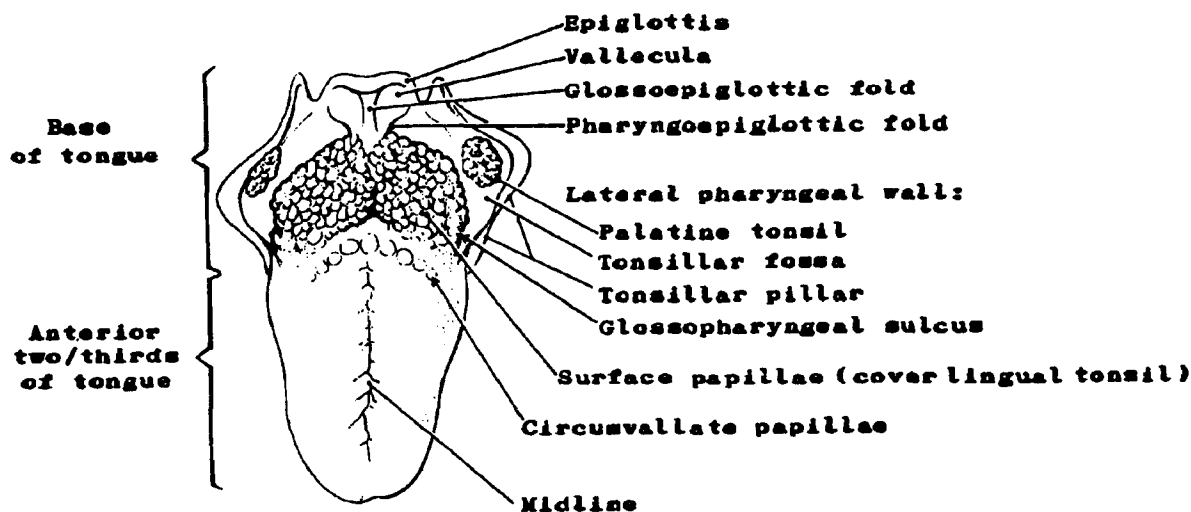
• *Tongue.* The tongue is a mobile mass of striated muscle covered by mucous membrane. It attaches to the floor of the mouth and practically fills the oral cavity. The membrane on the undersurface of the tongue is thin and forms a fold at the midline called the frenulum which extends from near the tip of the tongue to the floor of the mouth. The mucous membrane on the dorsum of the tongue is thick; and, over the anterior two-thirds, it is studded with papillae.¹ Functions of the tongue are mastication, deglutition (swallowing) and articulation (in reference to speech). It also has the faculty for producing the sense of taste.

The *anterior two-thirds of the tongue* is the freely movable portion which extends anteriorly from the line of circumvallate papillae to the tip of the tongue and then posteriorly along the undersurface to its junction with the floor of the mouth. Its topographical subdivisions are:

1. Lateral borders and tip (apex)
2. Dorsal (upper) surface
3. Ventral (under) surface

The *base of the tongue* (posterior one-third) is less mobile and extends posteriorly from the line of circumvallate papillae to the base of the epiglottis. The hollow formed at the junction of the base of the tongue with the epiglottis is called the vallecula. The lingual tonsils are aggregates of lymphoid tissue located in the base of the tongue (see page 68 for a detailed discussion).

Figure 23. DORSAL SURFACE OF TONGUE



¹papilla (plural - papillae)--Small nipple-shaped projection or elevation on which are located numerous taste buds.

Malignant Tumors

Malignant lesions are more common on the anterior two-thirds than on the posterior one-third of the tongue. Along with the lower lip, carcinoma of the anterior tongue is one of the most common sites of malignant tumors of the oral cavity.

Squamous cell carcinomas constitute 90 percent of all malignant tumors of the tongue. The other 10 percent are made up primarily of lymphoepitheliomas and lymphosarcomas. Lymphosarcomas will arise in the lymphoid tissue (lingual tonsil) found in the base of the tongue.

Q8

The tongue is composed of _____ covered by _____

_____.

Q9

What marks the division of the anterior two-thirds of the tongue and the base of the tongue?

Q10

Which part of the tongue has the most malignant tumors?

Answer: Q8

The tongue is composed of muscle covered by mucous membrane.

Answer: Q9

The division of the anterior two-thirds of the tongue and the base of the tongue is the (circum)vallate papillae.

Answer: Q10

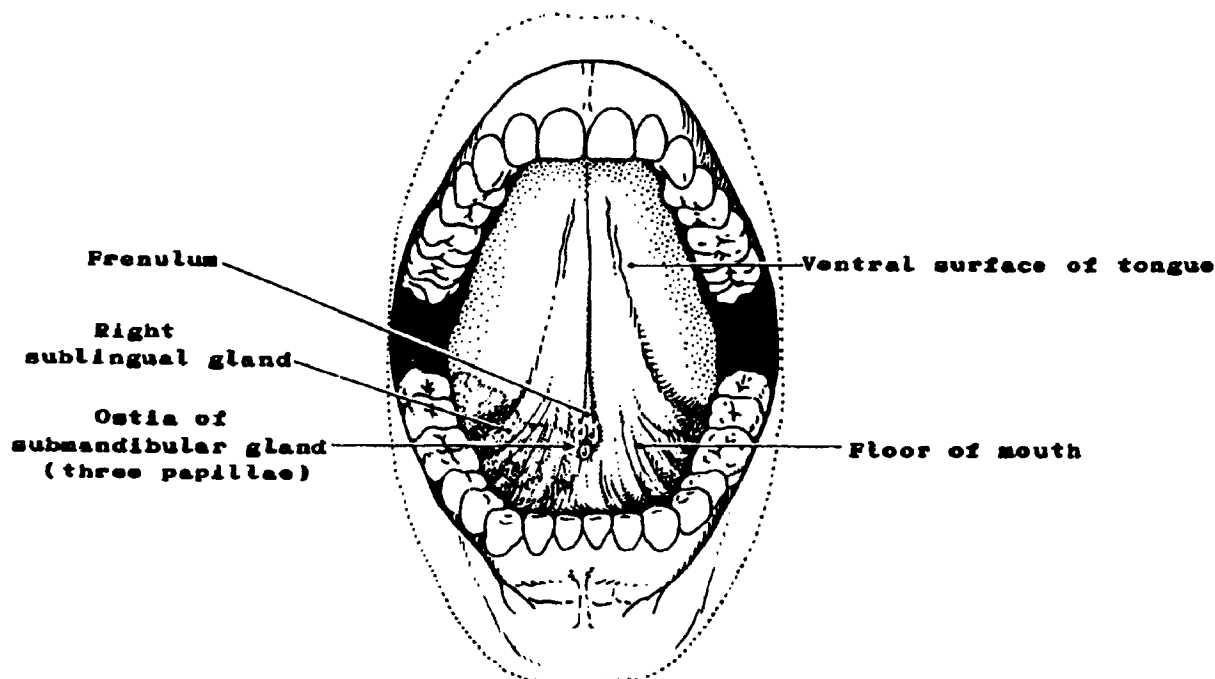
The anterior two-thirds of the tongue has more malignant tumors than does the base of the tongue.

- *Floor of mouth.* The floor of the mouth consists of a semilunar shaped area of loose, movable mucosa, an underlying subserosa and the mylohyoid and hypoglossus muscles. It extends from the inner surface of the lower alveolar ridge to the undersurface of the tongue. Its posterior boundary on each side is the base of the anterior pillar of the tonsil. It is divided anteriorly into two sides by the frenulum of the tongue and contains the ostia¹ of the submandibular (submaxillary) and sublingual salivary glands.
- *Retromolar area.* The retromolar area (retromolar trigone) is the attached mucosa overlying the ascending ramus of the mandible from the level of the posterior surface of the last molar tooth to the apex superiorly (see Figure 24).

Malignant Tumors

The floor of the mouth is a relatively common site for intra-oral malignancies. Most of the floor of the mouth lesions are squamous cell carcinomas. The remaining five percent are adenocarcinomas arising in the minor salivary glands.

Figure 24. FLOOR OF MOUTH



¹ostium (plural - ostia)--An opening into a tubular organ, in this case, an opening through which the secretions of the salivary glands flow into the mouth.

- *Gums (gingiva)*. The gums are folds of mucosa which surround the base of the teeth. The lamina propria is firmly attached to the underlying bone thus forming a fusion of mucous membrane and periosteum called "mucoperiosteum."

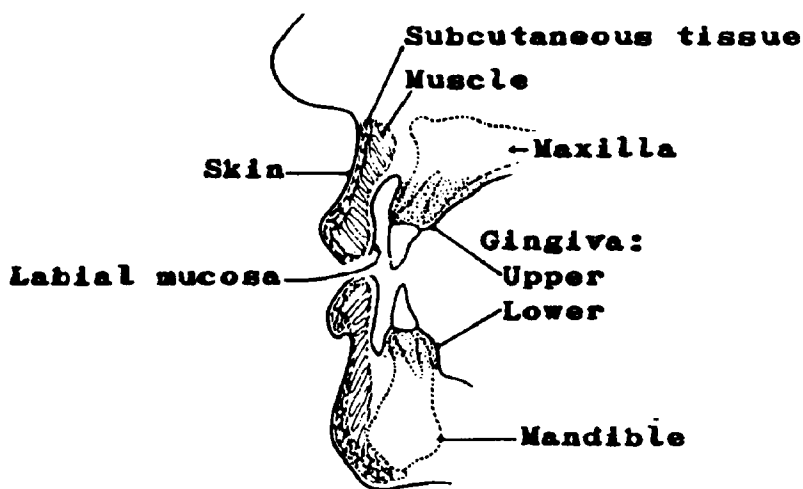
The *lower gum* is the mucosa covering the alveolar process of the mandible. It extends from the line of attachment of mucosa in the buccal gutter (sulcus) on the outer margin to the line of free mucosa of the floor of the mouth on the inner side. Posteriorly it extends to the ascending ramus of the mandible (retromolar trigone).

The *upper gum* is the mucosa covering the alveolar process of the maxilla. It extends from the line of attachment of mucosa in the gingival buccal sulcus to the junction with the mucosa of the hard palate. Its posterior margin is the upper end of the palatoglossal (pterygopalatine) arch.

Malignant Tumors

Cancer occurs more frequently on the lower than on the upper gingiva. It will sometimes invade underlying bone, but can be distinguished from tumors originating in bone on the basis of the histology. Malignant tumors of the gingival mucosa are almost always squamous cell carcinoma. A rare odontogenic tumor (ameloblastoma, adamantinoma) originating in the tissues which form the teeth may arise in the bone underlying the gingival mucosa.

Figure 25. GINGIVA



Q11

Match the structures on the left with their descriptions on the right:

- | | |
|-------------------------|--|
| _____ 1. Gum | a. A muscular organ covered with papillae attached to the floor of the mouth |
| _____ 2. Floor of mouth | b. Mucosal covering of alveolar process (ridge) |
| _____ 3. Tongue | c. Area of loose, movable mucosa extending from the undersurface of the tongue to the alveolar ridge |
| _____ 4. Lip | d. Anterior wall of the oral cavity |

Answer: Q11

- | | | |
|----------|-------------------|---|
| <u>b</u> | 1. Gum | Mucosal covering of the alveolar process (ridge) |
| <u>c</u> | 2. Floor of mouth | Area of loose, movable mucosa extending from the tongue to undersurface of the alveolar ridge |
| <u>a</u> | 3. Tongue | A muscular organ covered with papillae attached to the floor of the mouth |
| <u>d</u> | 4. Lip | Anterior wall of the oral cavity |

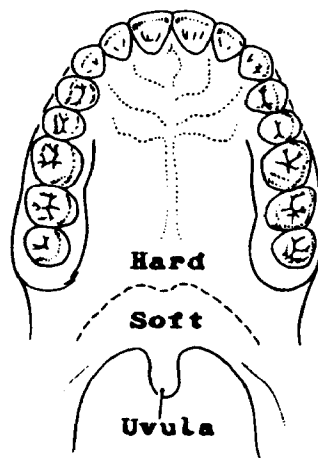
- *Palate.* The palate is the roof of the mouth separating the oral cavity from the nasal cavity and nasopharynx.

The *hard palate* consists of a mucosa and periosteum (mucoperiosteum). It covers the palatine processes of the maxillary palatine bones. The submucosa and muscularis are absent from the hard palate. It is a semilunar area which extends from the inner surface of the upper (superior) alveolar ridge to the posterior edge of the palatine bone.

The *soft palate* consists of mucosa, submucosa, and the underlying palatine muscles. It extends posteriorly from the edge of the hard palate to its free border. A soft tissue projection, located medially on its free border, is the uvula.

- *Buccal mucosa.* The buccal mucosa lines the inner surface of the cheeks, the structure of which is formed by the buccinator muscles. The anatomic limits of the buccal mucosa are the upper and lower gingival buccal sulci, the labial (lip) mucosa anteriorly, and the anterior tonsillar pillars posteriorly. Again, squamous cell carcinoma is the predominant cell type of the malignant tumors arising in this area. (See the note on page 170 for grouping of mucosa of lip in the various staging and coding systems.)

Figure 26. HARD AND SOFT PALATES



Q12

What is the palate? _____

Q13

In what way is the mucosa of the oral cavity different from that of the remainder of the digestive tract? _____

Q14

What is the most common type of malignancy found in the oral cavity?

Q15

Match the structure on the left with the description on the right:

- | | |
|------------------------|---|
| _____ 1. Buccal mucosa | a. Covers the palatine muscles |
| _____ 2. Gum | b. Lines the inner surface of the cheeks |
| _____ 3. Soft palate | c. Covers the palatine processes of the maxillary bones |
| _____ 4. Hard palate | d. Surrounds the base of the teeth |

Q16

The ostia of the submandibular and sublingual glands are located in the _____ of the _____.

Q17

What are the main structures which form the oral cavity?

- | | |
|----------|----------|
| 1. _____ | 2. _____ |
| 3. _____ | 4. _____ |
| 5. _____ | 6. _____ |
| 7. _____ | 8. _____ |

Answer: Q12

The palate is the roof of the mouth separating the oral cavity from the nasal cavity and nasopharynx.

Answer: Q13

You might have said that the mucosa of the oral cavity is different from the remainder of the digestive tract because it has no muscularis mucosae.

Answer: Q14

The most common type of malignancy found in the oral cavity is squamous cell carcinoma.

Answer: Q15

- b 1. Buccal mucosa Lines the inner surface of the cheeks
- d 2. Gum Surrounds the base of the teeth
- a 3. Soft palate Covers the palatine muscles
- c 4. Hard palate Covers the palatine processes of the maxillary bones

Answer: Q16

The ostia of the submaxillary and sublingual glands are located in the floor of the mouth.

Answer: Q17

The main structures forming the oral cavity are:

- 1. Lips
- 2. Cheeks (buccal mucosa)
- 3. Tongue
- 4. Hard palate
- 5. Soft palate
- 6. Floor of mouth
- 7. Gingiva
- 8. Retromolar area (trigone)

Salivary Glands

There are three pairs of major salivary glands: the parotid, submandibular (submaxillary), and sublingual glands.

- The *parotid* glands, the largest of the major salivary glands, lie below and in front of the ears. They secrete primarily serous substances into the mouth by way of the parotid duct (Stensen's duct).
- The *submandibular* glands lie in contact with the inner surface of the mandible. They secrete primarily serous substances into the mouth by way of the submandibular duct (Wharton's duct).
- The *sublingual* glands lie beneath the mucosa of the floor of the mouth. They pour mucous secretions into the mouth.

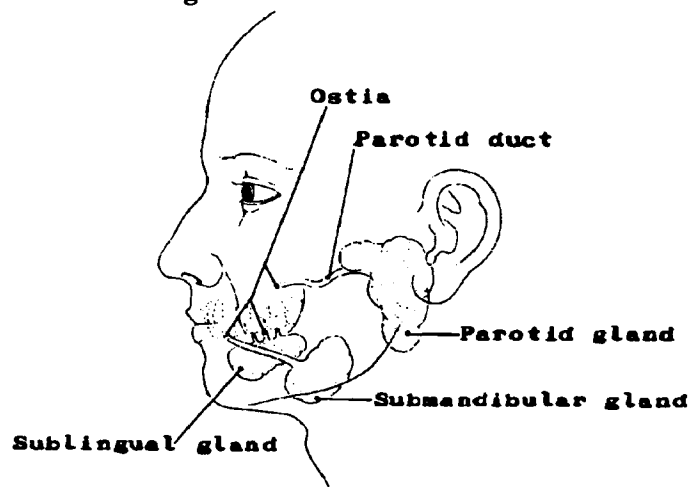
In addition, there are minor salivary glands scattered throughout the mucous membrane covering of the lips, cheeks, palate, and tongue. The salivary secretions may be thin and watery (produced by serous cells) or thick and viscid (produced by mucous cells).

The salivary glands moisten and lubricate the mouth with continuous secretions of saliva.

Malignant and Benign Tumors

Neoplasms arising in salivary gland tissue are predominantly mixed tumors (pleomorphic adenomas). Since approximately 75 percent of these tumors are benign, they will not be reported by most registries. Malignant tumors which you are likely to find are: mucoepidermoid carcinoma, squamous cell carcinoma, adenoid cystic carcinoma, and adenocarcinoma. These tumors arise most frequently in the parotid.

Figure 27. SALIVARY GLANDS



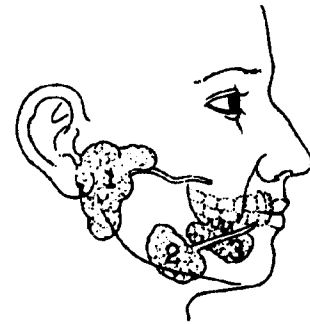
Q18

Identify the major salivary glands below:

1. _____

2. _____

3. _____



Q19

Most tumors arising in salivary gland tissue are _____

(type) tumors which are benign 75 percent of the time.

Q20

In which of the major salivary glands do most of the malignant tumors arise?

Answer: Q18

The major salivary glands are as follows:

1. Parotid
2. Submandibular (submaxillary)
3. Sublingual

Answer: Q19

Most tumors arising in salivary gland tissue are mixed tumors which are benign 75 percent of the time.

Answer: Q20

Most of the malignant tumors which arise in the major salivary glands occur in the parotid gland.

Lymph Node Drainage

The regional lymph nodes for the various parts of the oral cavity and salivary glands are the upper cervical nodes which may be identified more specifically in relation to their areas of drainage.

Facial Lymph Nodes

Lip
Gum
Buccal mucosa

Parotid Lymph Nodes

Upper lip and commissure
Parotid gland
Buccal mucosa

Submental Lymph Nodes

Lip
Tongue
Gum
Floor of mouth
Submandibular (submaxillary) gland
Palate
Buccal Mucosa

Submandibular (submaxillary) Lymph Nodes

Lip
Buccal mucosa
Floor of mouth
Gum
Tongue, all parts
Palate
Submandibular (submaxillary) gland

Sublingual Lymph Nodes

Anterior 2/3 of tongue
Floor of mouth

Retropharyngeal Lymph Nodes

Upper gum
Palate (hard and soft)

Internal jugular (upper and lower deep cervical)

Lip
Tongue, all parts
Floor of mouth
Gum
Buccal mucosa
Palate
Submandibular (submaxillary) gland

The supraclavicular (transverse cervical) lymph nodes are distant nodes for most sites, including the head and neck, except for *skin* of the lower neck and chest wall (see Figure 27 and Figure 28 for locations of lymph nodes).

Q21

Match the sites on the left with the lymph nodes on the right:

- | | |
|------------------------|---------------------|
| _____ 1. Gum | a. Facial |
| _____ 2. Buccal mucosa | b. Internal jugular |
| _____ 3. Lip | c. Retropharyngeal |
| _____ 4. Tongue | d. Submandibular |

Q22

Except for skin of the lower neck and chest wall, the _____ lymph nodes are always considered distant nodes.

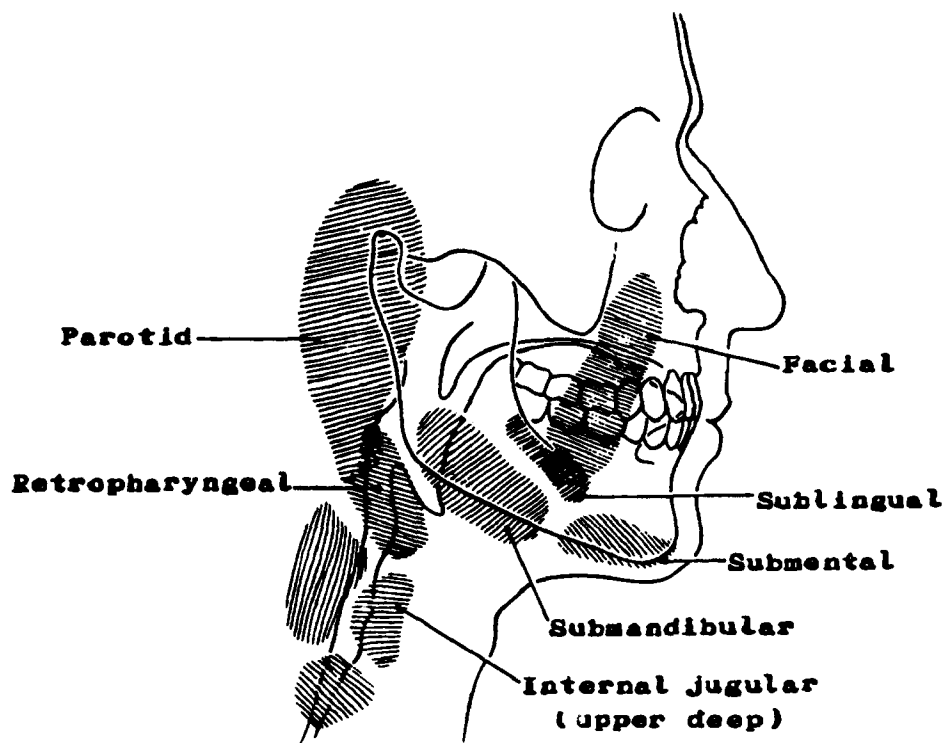
Answer: Q21

<u>c</u>	1. Gum	Retropharyngeal
<u>a,b,d</u>	2. Buccal mucosa	Facial, internal jugular, and submandibular
<u>a,b,d</u>	3. Lip	Facial, internal jugular, and submandibular
<u>b,d</u>	4. Tongue	Internal jugular (upper deep) and submandibular

Answer: Q22

Except for skin of the lower neck and chest wall, the supraclavicular (transverse cervical) lymph nodes are considered distant nodes for all sites.

Figure 28. ORAL CAVITY LYMPH NODE REGIONS



Pharynx

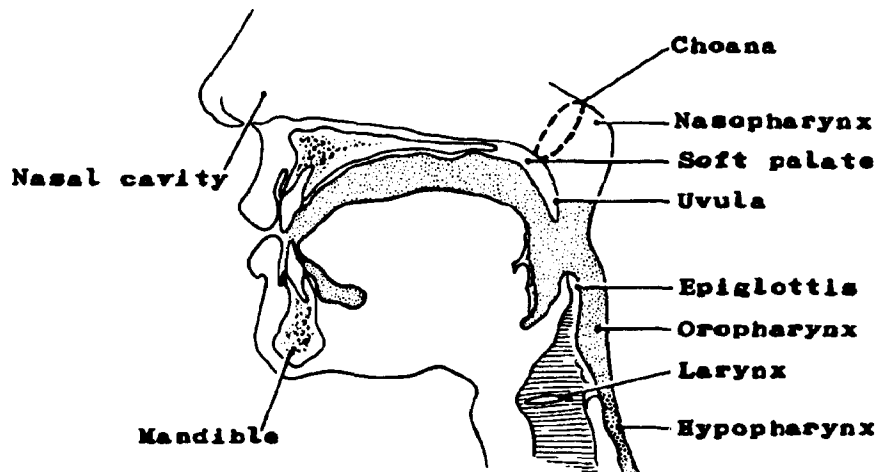
The pharynx is divided into three regions: the nasopharynx, the oropharynx, and the hypopharynx (laryngopharynx).

The *nasopharynx* lies behind the nasal cavities, above the soft palate, and below the base of the skull. The *oropharynx* lies behind the buccal cavity, below the soft palate, and above the opening to the larynx. The *hypopharynx* (laryngopharynx) is located behind, lateral and inferior to the larynx. The nasopharynx has been discussed in detail in Section F, The Respiratory System.

The pharynx (throat) serves as a passageway for the respiratory and digestive tracts, since air must pass through this structure before reaching the lungs, and food must pass through it to get to the stomach. The pharynx is also important for phonation because by changing its shape the different vowel sounds are formed. The pharynx is made of muscle which is lined with mucous membrane. Embedded within this muscle are the palatine and pharyngeal tonsils. The tonsils are composed of lymphoid tissue and may be considered part of the lymphatic system. However, they are located within the respiratory and digestive systems. The adenoids or pharyngeal tonsils are located in the nasopharynx. The faucial or palatine tonsils are located in the oropharynx. (The lingual tonsils, as we have learned, are in the base of the tongue. It is the palatine tonsils that are commonly removed by a tonsillectomy.)

The lymphatics for the pharynx drain into the cervical lymph nodes, namely, the internal jugular (upper and lower deep cervical), and retropharyngeal lymph nodes. The blood supply is via the external carotid arteries and internal jugular veins.

Figure 29. OROPHARYNX AND HYPOPHARYNX



Oropharynx. The air and food passageways cross in the oropharynx. The oropharynx extends from the level of the free borders of the soft palate to the tip of the epiglottis.

The anatomical limits are as follows:

- The *posterior oropharyngeal wall* is that part of the posterior pharyngeal wall that extends from a level opposite the free borders of the soft palate to the tip of the epiglottis.
- The *lateral walls* include the tonsillar pillars, tonsillar fossae, and the palatine (faucial) tonsils. On each side, the anterior pillar (glossopalatine fold) extends from the base of the tongue to the soft palate lying in front of the tonsillar fossa. The posterior tonsillar pillar (pharyngopalatine fold) lies in back of the tonsillar fossa. The area between the two pillars, the tonsillar fossa, houses the palatine tonsil, sometimes called the faucial tonsil.
- The *anterior wall* consists of the lingual (anterior) surface of the epiglottis and the pharyngoepiglottic and glossoepiglottic folds which bound the vallecula (the hollow formed at the junction of the base of the tongue and the epiglottis--see base of tongue).

Note: The latest revisions of the American Joint Committee include base of tongue and soft palate in the oral pharynx rather than in the oral cavity. ICD-O provides separate code numbers in the oral grouping: base of tongue (C01.9), soft palate (C05.1), and uvula (C05.2). Thus, these sites can be grouped with the oral cavity (as they have been historically) or they can be included in the oral pharynx.

Hypopharynx (laryngopharynx). The function of the hypopharynx is purely alimentary providing a passage behind the larynx. The sites within the hypopharynx are the pyriform sinus, the postcricoid area, and the posterior pharyngeal wall. The anatomical limits are as follows:

- The *pyriform sinus* extends from the pharyngoepiglottic fold to the upper edge of the esophagus between the inner surface of the thyroid cartilage and the posterior lateral surface of the thyroid and cricoid cartilages.
- The *postcricoid area* extends from the posterior surface of the arytenoid cartilages and the aryepiglottic folds to the inferior surface of the cricoid cartilage. The lateral margin is the anterior part of the pyriform sinus.
- The *posterior hypopharyngeal wall* is that part of the posterior pharyngeal wall that extends from the level of the tip of the epiglottis to the inferior margin of the cricoid cartilage and laterally to the posterior margins of the pyriform sinus.

Malignant Tumors

Malignant tumors of the pharynx are usually squamous cell carcinoma. Although tumors of lymphoid tissue do arise in these areas, the frequency is relatively low compared to tumors of this histologic type occurring elsewhere in the body.

Q23

What is another name for the hypopharynx?

Q24

What histologic type of malignant tumor do you usually expect to find in the pharynx?

Answer: Q23

Another name for the hypopharynx is the laryngopharynx.

Answer: Q24

You usually expect to find squamous cell carcinoma in the pharynx.

Q25

Match each structure on the left with its function on the right:

- _____ 1. Hypopharynx a. Serves as a passageway for food only
_____ 2. Oropharynx b. Serves as a passageway for air only
_____ 3. Nasopharynx c. Serves as a passageway for both food and air (crossover)

Q26

Match each structure on the left with its location on the right:

- _____ 1. Nasopharynx a. Behind the nasal cavities and above the soft palate
_____ 2. Oropharynx b. Behind the buccal cavity and below the soft palate
_____ 3. Hypopharynx c. Behind and lateral to the larynx

Q27

The pharynx is composed of _____ and is lined with

_____.

Answer: Q25

- a 1. Hypopharynx Serves as a passageway for food only
- c 2. Oropharynx Serves as a passageway for both food and air (crossover)
- b 3. Nasopharynx Serves as a passageway for air only

Answer: Q26

- a 1. Nasopharynx Behind the nasal cavities and above the soft palate
- b 2. Oropharynx Behind the buccal cavity and below the soft palate
- c 3. Hypopharynx Behind and lateral to the larynx

Answer: Q27

The pharynx is composed of muscle and is lined with mucous membrane.

Q28

To which segment of the pharynx would you code a malignancy of each of the following?

- a. Tonsillar pillar _____
- b. Postcricoid region _____
- c. Pyriform sinus _____
- d. Anterior surface of the epiglottis _____
- e. Pharyngeal tonsil _____
- f. Laryngopharynx _____
- g. Glossopalatine fold _____
- h. Aryepiglottic fold _____

Q29

Match the tonsil on the left with its location on the right:

- | | |
|-------------------|-----------------------|
| _____ 1. Adenoids | a. Oropharynx |
| _____ 2. Palatine | b. Base of the tongue |
| _____ 3. Lingual | c. Nasopharynx |

Answer: Q28

- | | |
|---------------------------------------|---------------|
| a. Tonsillar pillar | - Oropharynx |
| b. Postcricoid region | - Hypopharynx |
| c. Pyriform sinus | - Hypopharynx |
| d. Anterior surface of the epiglottis | - Oropharynx |
| e. Pharyngeal tonsil | - Nasopharynx |
| f. Laryngopharynx | - Hypopharynx |
| g. Glossopalatine fold | - Oropharynx |
| h. Aryepiglottic fold | - Hypopharynx |

Answer: Q29

- | | |
|----------------------|--------------------|
| <u>c</u> 1. Adenoids | Nasopharynx |
| <u>a</u> 2. Palatine | Oropharynx |
| <u>b</u> 3. Lingual | Base of the tongue |

Esophagus

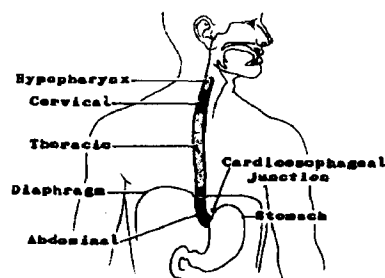
The esophagus is a muscular tube about ten inches (25 cm.) long extending from the hypopharynx to the stomach. The peristaltic¹ motion of the esophagus moves food along to the stomach. The esophagus lies posterior to the trachea and the heart, and passes through the mediastinum and the hiatus, an opening in the diaphragm, in its descent from the thoracic to the abdominal cavity. The esophagus can be divided into three segments or regions: 1) cervical, 2) thoracic, and 3) abdominal. The location of esophageal lesions is frequently measured from the incisors (front teeth) and may be approximated as follows:

- The *cervical* esophagus begins at the lower border of the cricoid cartilage and ends at the thoracic inlet (suprasternal notch) approximately 18 cm measuring from the upper incisors.
- The upper *thoracic* esophagus extends from the thoracic inlet to the level of the tracheal bifurcation, approximately 24 cm from the upper incisors.
- The *mid-thoracic* portion is the proximal half of the esophagus between the tracheal bifurcation and the esophago-gastric junction. The lower level is approximately 32 cm from the upper incisor teeth.
- The *lower thoracic* portion, 8 cm in length (includes the abdominal esophagus), is the distal half of the esophagus between the tracheal bifurcation and the esophago-gastric junction, approximately 40 cm from the upper incisor teeth.

The esophagus may also be described in terms of upper, mid, and lower thirds. This measurement is *not* equivalent to the one just described as you can see from Figure 31. It may be approximated as follows:

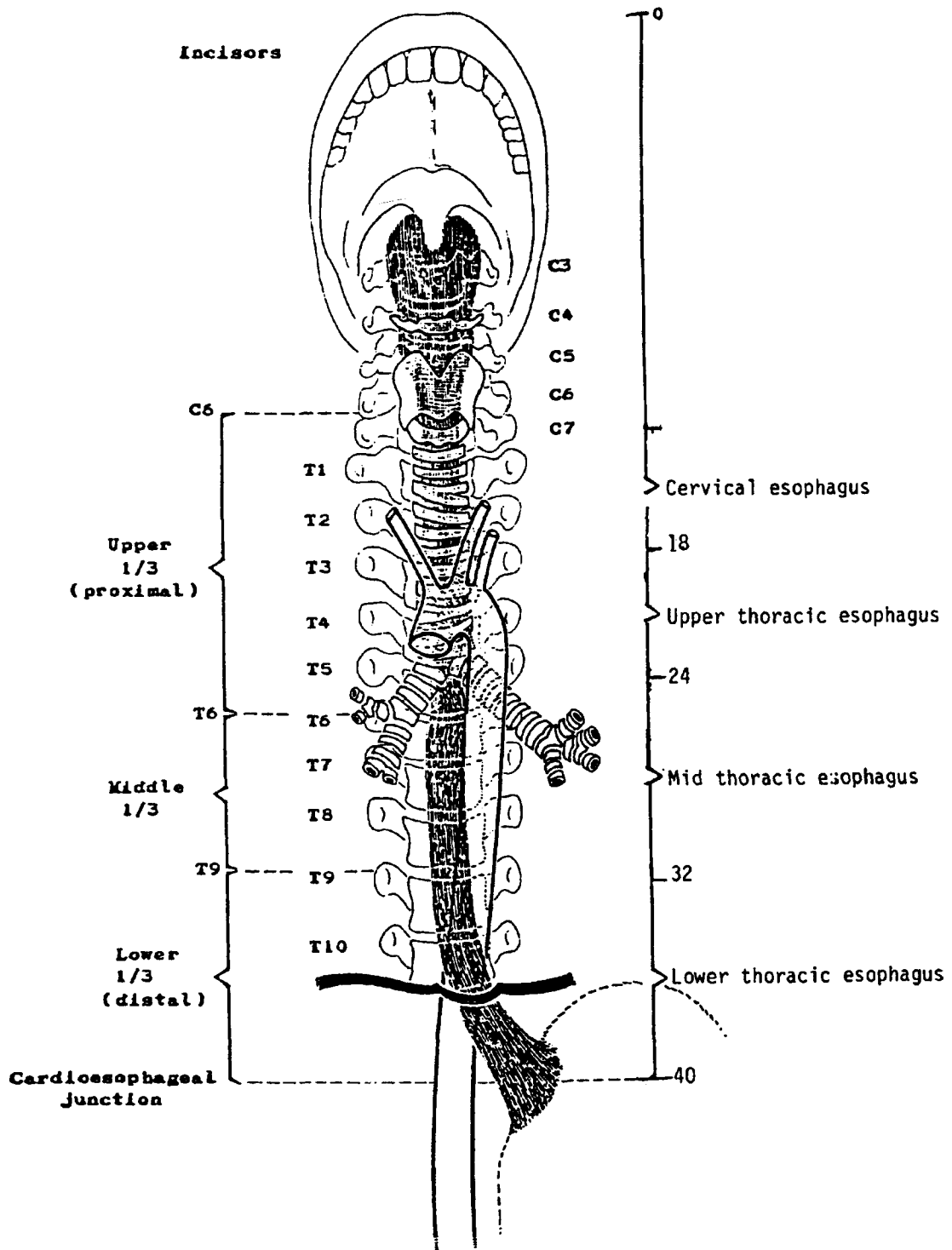
- The *upper* (proximal) third extends from the sixth cervical vertebra to the sixth thoracic vertebra.
- The *mid* third extends from the sixth thoracic vertebra to the ninth thoracic vertebra.
- The *lower* (distal) third extends from the ninth thoracic vertebra to the cardioesophageal junction.

Figure 30. DIVISIONS OF THE ESOPHAGUS



¹peristalsis (n); peristaltic (adj)--Wavelike, involuntary contractions provided by the combination of longitudinal and circular muscles which propel the contents of the gastrointestinal tract.

**Figure 31. MEASUREMENTS OF THE ESOPHAGUS
(FROM THE INCISORS TO THE STOMACH)**



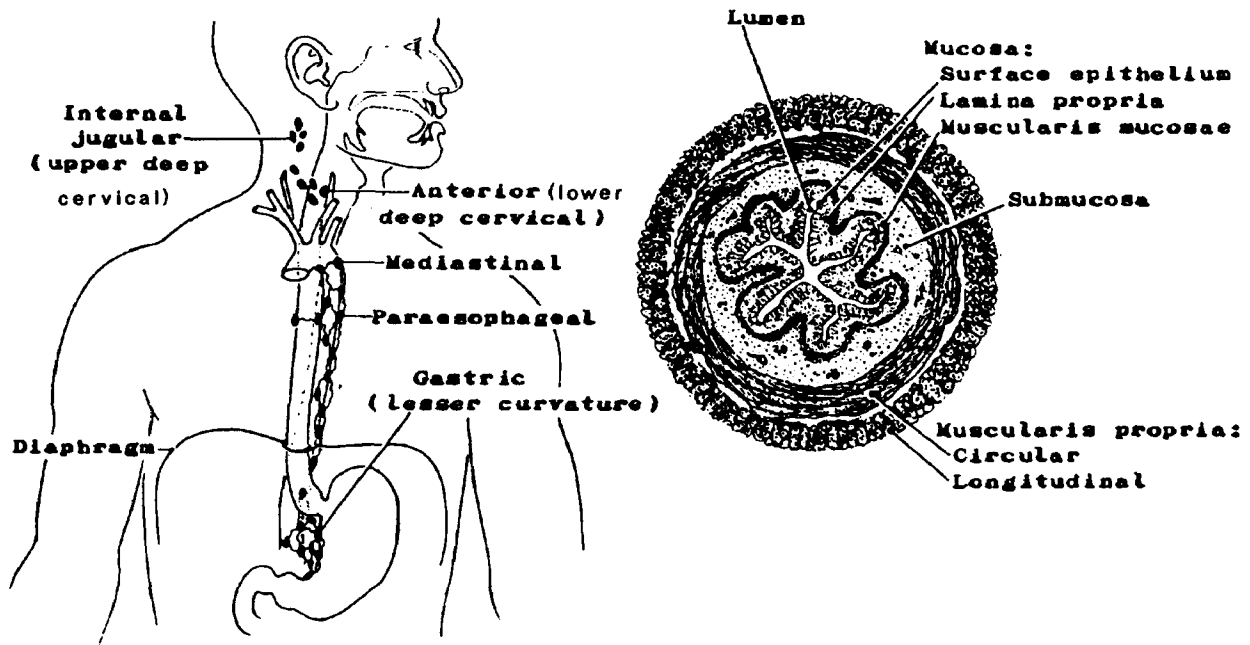
The inner wall of the esophagus is lined with *mucosa*. The *mucosa* can be subdivided into surface epithelium, lamina propria, and muscularis mucosae. Beneath the mucosa lies the *submucosa* which contains mucous glands, blood vessels, lymphatics, and nerves. The *muscularis propria* lies beneath the submucosa. It consists of two layers of muscle, an inner circular and outer longitudinal layer. This muscular layer is composed of striated muscle in the upper third, mixed striated and smooth muscle in the middle third, and smooth muscle only in the lower third. There is no serosa on the esophagus, but rather an external adventitia of fibrous connective tissue. The lack of a serosa facilitates the spread of cancer beyond the primary site into adjacent tissues and lymph nodes.

Branches of the aorta and celiac artery supply blood to the esophagus. The venous drainage is to the azygos, thyroid, and left gastric veins. The lymphatic vessels drain into the cervical, mediastinal, and gastric lymph nodes depending on the segment of the esophagus from which they originate.

Malignant Tumors

The neoplasms arising in the esophagus are primarily squamous cell (epidermoid) carcinomas. Leiomyosarcomas of the muscle layers arise less frequently. The esophagus, despite its length, is an uncommon tumor site.

Figure 32. ESOPHAGEAL LYMPH NODES Figure 33. CROSS-SECTION OF ESOPHAGUS



Q30

The esophagus is a muscular tube about ten inches long extending from the _____
to the _____ and is divided into four anatomic segments:

1. _____

2. _____

3. _____

4. _____

Q31

The esophagus passes through the _____ in its descent from the _____
cavity to the _____ cavity.

Q32

The three main tissue layers of the wall of the esophagus are:

1. _____

2. _____

3. _____

Answer: Q30

The esophagus extends from the pharynx to the stomach and can be divided into four anatomic segments:

1. Cervical
2. Upper thoracic portion
3. Mid-thoracic
4. Lower thoracic portion, including abdominal

Answer: Q31

The esophagus passes through the diaphragm (or hiatus in the diaphragm) in its descent from the thoracic cavity to the abdominal cavity.

Answer: Q32

The three main tissue layers of the wall of the esophagus are:

1. Mucosa
2. Submucosa
3. Musculature (muscularis propria)

Remember there is no serosa on the esophagus, only an adventitia of loose connective tissue.

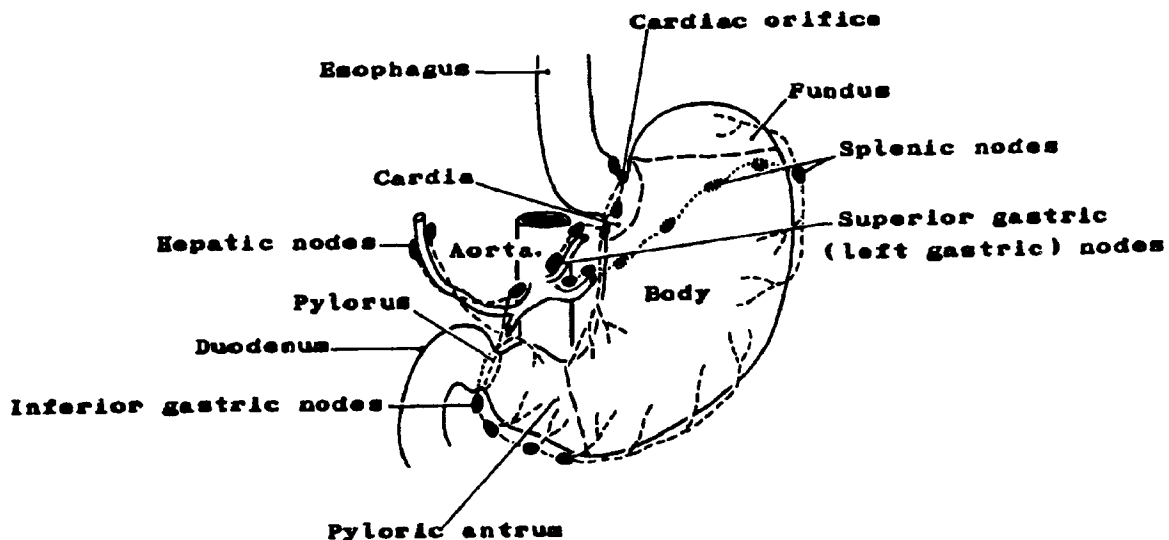
Stomach

The stomach lies just below the diaphragm in the upper part of the abdominal cavity primarily to the left of the midline under a portion of the liver. Factors which influence the precise location are food ingestion and respiration (inspiration and expiration). Food leaves the esophagus and enters into this elongated pouch-like structure by way of the cardiac orifice. The role of the stomach is the mixing of food with gastric secretions by way of peristalsis to form chyme¹ and the ejection of the chyme into the small intestine.

The main divisions of the stomach (Figure 34, below) are the cardia, the fundus (fornix), the body (corpus), and the antrum:

- The *cardia* is the portion of the stomach surrounding the cardioesophageal junction, or cardiac orifice (the opening of the esophagus into the stomach).
- The *fundus* is the enlarged portion to the left and above the cardiac orifice.
- The *body*, or corpus, is the central part of the stomach.
- The *pyloric antrum* is the lower or distal portion above the duodenum. The opening between the stomach and the small intestine is the *pylorus*, and the very powerful sphincter which regulates the passage of chyme into the duodenum is called the pyloric sphincter.

Figure 34. STOMACH AND ADJOINING STRUCTURES



¹chyme--The fluid content of the stomach after food has undergone gastric digestion.

The medial border of the stomach is called the lesser curvature, and the lateral border is called the greater curvature. These designations are important in pinpointing the location of neoplasms.

A large fold of peritoneum called the *greater omentum*, or gastrocolic omentum, extends down from the anterior surface of the stomach connecting the abdominal viscera. It contains fat cells, blood and lymphatic vessels, and nerves. A similar fold called the *lesser omentum*, or gastrohepatic omentum, extends between the liver and the lesser curvature of the stomach.

The *mucosa* (described earlier) is composed of three layers: the surface epithelium, the lamina propria, and the muscularis mucosae. This middle layer (lamina propria) is thick and filled with glands which secrete both mucous and enzymes. When the stomach is empty, the mucosa forms folds called rugae¹. The *submucosa* is composed of dense connective tissue with large blood and lymph vessels. The *muscularis propria* is composed of three muscular layers as compared to two in the esophagus. These are called the *longitudinal*, *circular*, and *oblique* layers. This muscular wall serves as a churn to help break up and mix food with the gastric juices. A *serosa* of visceral peritoneum invests the outer surface of the stomach.

The blood supply to the stomach is derived from branches of the celiac artery. The venous drainage is into the portal vein, either directly or by way of the splenic and superior mesenteric veins.

The regional lymph nodes are as follows:

Inferior (right) gastric:

- Greater curvature
- Greater omental
- Gastroduodenal
- Gastrocolic
- Gastroepiploic, right
- Gastrohepatic
- Pyloric, incl. sub-/infrapyloric
- Pancreaticoduodenal (Anteriorly along first part of the duodenal)

Splenic:

- Gastroepiploic, left
- Pancreaticolienal
- Peripancreatic
- Splenic hilar

Superior (left) gastric:

- Lesser curvature
- Lesser omental
- Gastropancreatic, left
- Gastric, left
- Paracardial; cardiac
- Cardioesophageal
- Celiac
- Hepatic (excl. gastrohepatic)

¹rugae--ridges, wrinkles, or folds, as of mucous membrane.

The functions of the stomach are to:

1. Absorb water and glucose into the blood stream.
2. Secrete gastric enzymes. For example, rennin to clot milk; lipase to initiate the splitting of fats; pepsinogen, which in the presence of hydrochloric acid forms pepsin, to begin protein breakdown.
3. Secrete hydrochloric acid (HCl) which kills bacteria, changes some minerals to salts which are suitable for absorption in the intestine, and adjusts the pH of the chyme to permit the opening of the pyloric sphincter.
4. Produce, in the gastric mucosa, the intrinsic factor which is necessary for the absorption of Vitamin B12.
5. Secrete, in the pyloric glands, an alkaline mucous to neutralize the HCl.
6. Churn the food into a semi-liquid substance (chyme) and force it through the pyloric sphincter into the duodenum.

Malignant and Benign Tumors

- Adenocarcinoma is the most frequent malignant lesion of the stomach. The spread of the tumor is usually to regional lymph nodes and the liver. Later metastasis frequently occurs in the lungs, brain, bone, and ovaries. A tumor known as Krukenberg tumor is found in the ovary which represents a metastasis of adenocarcinoma of the gastrointestinal tract, usually of the stomach, to the ovary.
- Lymphomas arise more frequently in the stomach than in any other extranodal site. Any histologic type of lymphoma, including Hodgkin's disease, may occur.
- Leiomyosarcoma arises in the smooth muscles of the stomach wall.
- Squamous cell carcinoma occurs at the cardioesophageal junction.
- Linitis plastica is an advanced form of cancer which is characterized by a thickening of the stomach wall causing it to lose its elasticity and become rigid like a leather bottle. It has, therefore, been referred to as leather-bottle stomach.
- Leiomyomas and adenomas are the two most common benign tumors of the stomach.

Q33

The stomach lies just below the _____ in the upper part of the abdominal cavity. The main divisions of the stomach are the:

1. _____
2. _____
3. _____
4. _____

Q34

The three tissue layers of the stomach wall and its peritoneal covering are:

1. _____
2. _____
3. _____
4. _____

Q35

The three major regional lymph node chains are:

1. _____
2. _____
3. _____

Q36

Name three general functions the stomach performs:

1. _____

2. _____

3. _____

Q37

The most frequent malignant neoplasm of the stomach is _____.

Answer: Q33

The stomach lies just below the diaphragm. Its main divisions are the:

1. Cardia
2. Fundus
3. Body or corpus
4. Pyloric antrum

Answer: Q34

The three tissue layers of the stomach wall and its peritoneal covering are:

1. Mucosa
2. Submucosa
3. Muscularis propria
4. Serosa

Answer: Q35

The three major regional lymph node chains are:

1. Superior (left) gastric
2. Inferior (right) gastric
3. Splenic

Answer: Q36

Some functions of the stomach are:

1. It churns or mixes food into a semi-liquid and forces it into the duodenum.
2. It secretes gastric juices (enzymes, hydrochloric acid, mucous, intrinsic factor).
3. It absorbs water and glucose.

Answer: Q37

The most frequent malignant neoplasm of the stomach is adenocarcinoma.

Small Intestine

The small intestine is a tube measuring about 2.5 cm. in diameter and over 20 feet (600 cm.) in length coiled in loops which fill most of the abdominal cavity. It has three divisions--duodenum, jejunum, and ileum:

- The duodenum is just below the pyloric portion of the stomach and is about 25 cm. long and shaped somewhat like the letter C. It receives chyme from the stomach, bile from the gallbladder, and pancreatic secretions from the pancreas. The common bile duct and pancreatic duct join the duodenum at the ampulla of Vater. The duodenum becomes the jejunum where the tube turns forward and downward.
- The jejunum continues for over 200 cm. and then becomes the ileum, although there is no demarcation between the two divisions.
- The ileum is over 300 cm. long and joins the large intestine at the ileocecal valve.

The wall of the small intestine is composed of the same three main layers of tissue as the rest of the gastrointestinal tract and is covered with serosa. Small aggregates of lymphoid tissue called Peyer's patches are found in the lamina propria of the small intestine, principally in the distal ileum.

The small intestine completes the digestion of the material received from the stomach and moves it along in peristaltic waves to the colon. Increased epithelial surface needed for absorption is provided by circular folds and villi.¹ The absorbed material which reaches the blood stream via the intestinal capillaries and lymphatics includes 1) water, 2) carbohydrates, 3) fat, and 4) protein.

The lymphatic drainage of the small intestine is to lymph nodes along the branches of the superior mesenteric and hepatic arteries. Duodenal nodes, in particular, may be described in terms of their location in relation to adjacent organs, such as, the stomach (pyloric), gallbladder (cystic), bile ducts (pericholedochal), pancreas (pancreaticoduodenal) and ampulla of Vater. The terminal ileum drains to posterior cecal and ileocecal nodes of the superior mesenteric group.

Malignant and Benign Tumors

In spite of the relatively long length of the small intestine, tumors are rare. Thirty-five percent of all tumors of the small intestine are benign. Only one-fourth of all tumors in this site are adenocarcinomas, most frequently found in the duodenum. Lymphoma is the next most frequently diagnosed tumor of the small intestine with carcinoid tumors (argentaffinomas) and leiomyosarcomas accounting for the remainder.

¹villus--(plural - villi)--A small vascular process or protrusion, usually covered by epithelium, especially such a protrusion from the free surface of a membrane.

Q38

The small intestine is about _____ in length and is composed of three parts

which are:

1. _____

2. _____

3. _____

Q39

Name two functions of the small intestine:

1. _____

2. _____

Q40

What are some of the most common types of tumors found in the small intestine?

1. _____

2. _____

3. _____

4. _____

Answer: Q38

The small intestine is about twenty feet (600 cm.) long. It is composed of three parts which are:

1. Duodenum
2. Jejunum
3. Ileum

Answer: Q39

Two functions of the small intestine are:

1. Digestion
2. Absorption

Answer: Q40

Some of the most common types of tumors found in the small intestine are:

1. Adenocarcinoma
2. Lymphoma
3. Leiomyosarcoma
4. Carcinoid tumor

Large Intestine

The large intestine (the colon, rectum, and anus) is approximately five feet (150 cm.) long with a diameter of about 6 cm., decreasing towards the lower end. The by-products of digestion pass from the small intestine through the ileocecal valve to the large intestine. The ileocecal valve projects into the large intestine preventing the contents of the colon from regurgitating into the small intestine.

The large intestine is divided into the following segments:

- The *cecum* is a large cul-de-sac at the lower end of the ascending colon (proximal to the entrance of the ileum into the colon). It comprises the first 5 to 7 cm. of the large intestine. The *appendix* is a blind sac opening into the cecum just below the ileocecal orifice.
- The *ascending colon* extends upward from the cecum on the right side of the abdomen to the under surface of the right lobe of the liver where it turns to the left forming the hepatic flexure.
- The *transverse colon* begins at the *hepatic flexure* passing horizontally across the abdomen, below the liver and stomach and above the small intestine. On the left side of the abdomen near the spleen, the colon turns downward at the junction of the transverse and descending colon forming the *splenic flexure*.
- The *descending colon* starts at the splenic flexure and passes downward until it turns towards the midline at the rim of the pelvis and continues downward to become the sigmoid colon.
- The *sigmoid colon*, sometimes called the pelvic colon, is curved like the letter S. The lower part of the curve joins the rectum at the rectosigmoid junction.
- The *rectum* extends down to the anal canal. The upper part of the rectum, generally that part above the peritoneal reflection, is often called the *rectosigmoid*. It extends from approximately 10 cm. up to 15 cm (measuring from the anal verge). The lower rectum is devoid of a peritoneal covering and, therefore, has no serosa. It extends to approximately 10 cm. (measuring from the anal verge).
- The *anal canal* constitutes the final 2.5 cm of the digestive tract. It begins at the anorectal junction (dentate or pectinate line) and ends at the anal verge where the anal tube turns outward to blend with the perianal skin. In contrast to the rest of the large intestine, the anal canal is lined with squamous epithelium.

The main functions of the large intestine are reabsorption of water, minerals, and salts into the blood stream and movement of unabsorbed solid material along until it is eventually eliminated from the body as feces. Absorption takes place principally in the right colon; storage in and expulsion of fecal material from the left colon.

The large intestine receives the fluid by-products of digestion from the small intestine. The water is absorbed into the blood stream. However, the unabsorbed solid material is merely stored in the colon and moved along by peristaltic action for elimination. Therefore, there are no villi present as there are in the small intestine. The tissue layers are similar to those in the stomach: a *mucosa* of surface epithelium, lamina propria and muscularis mucosae, a *submucosa* layer, and a *muscularis propria*. The muscularis propria differs from other parts of the gastrointestinal tract in that the longitudinal muscle layer is arranged in three flat bands called taenia coli. These bands are not as long as the intestine; consequently, it gives the wall a gathered (shirred) effect and creates sacs (haustra). Little pouches of fat called appendices epiploica hang from the wall of the intraperitoneal colon distending the serosa.

The colon is attached to the posterior abdominal wall by folds of peritoneum called mesenteries. The cecum, transverse colon, and sigmoid are almost completely invested by peritoneum, but the ascending and descending colon which lie along the posterior body wall (retroperitoneum) are covered on the anterior surfaces only. This covering is called the *serosa*. The lower *rectum* is called the extraperitoneal portion of the large intestine, lying as it does below the peritoneal reflection, i.e., outside of the peritoneal cavity.

Figure 35. STRUCTURE OF COLONIC WALL

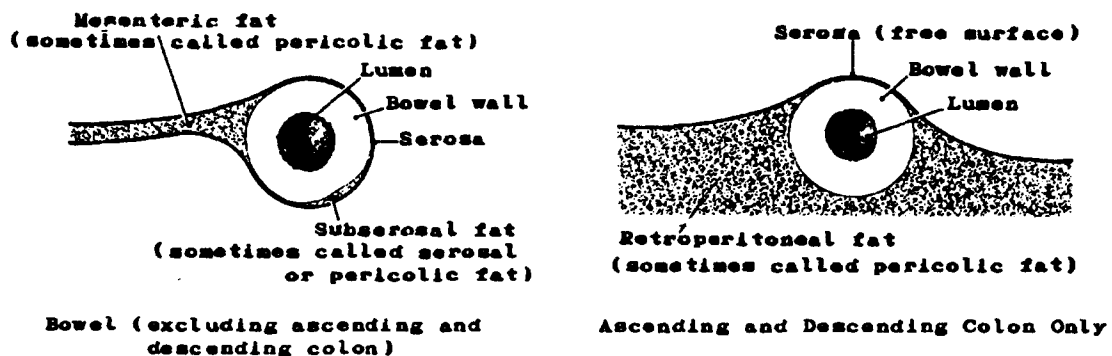
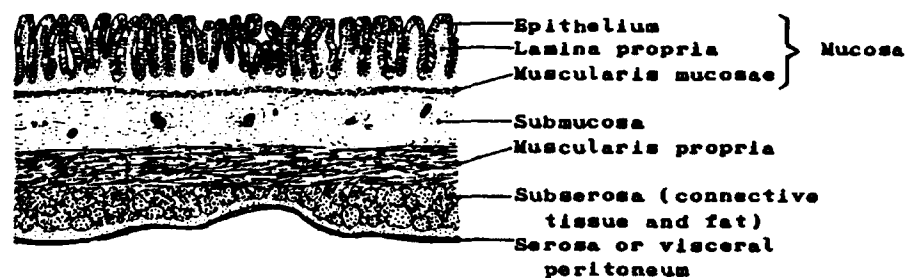


Figure 36. RELATIONSHIP OF BOWEL WALL AND SEROSA TO PERICOLIC/MESENTERIC FAT

The blood supply to the wall of the large intestine is derived from branches of the superior and the inferior mesenteric arteries. The superior mesenteric artery and its branches supply the right side of the colon, hepatic flexure and just beyond the midline of the transverse. The inferior mesenteric artery and its branches supply the left side of the colon and a portion of the left transverse. The veins enter the inferior mesenteric vein and eventually the portal vein.

The lymphatics of the large intestine drain primarily into the superior and inferior mesenteric lymph nodes before eventually reaching the cisterna chyli and thoracic duct. To refresh your memory, turn to page 58 of the lymphatic system.

Epicolic lymph nodules lying beneath the serosa and paracolic lymph nodes in the adjacent mesentery are found along the length of the colon. Lymph collected in the paracolic nodes drains through the lymphatic vessels and intercalating lymph nodes in the mesentery toward the branching of the superior and inferior mesenteric arteries from the aorta.

Perirectal lymph nodes drain, in addition, to nodes along branches of the internal iliac artery and to sacral promontory nodes.

The branches of the major arteries and lymphatics are:

Superior Mesenteric

ileocolic
right colic
mid-colic
cecal, anterior/posterior

Inferior Mesenteric

left colic
hemorrhoidal, superior
sigmoidal (sigmoid mesenteric)

Internal Iliac (Hypogastric)

sacral (lateral sacral)
hemorrhoidal, middle

Often lymph nodes whose configurations have been obliterated by tumor are described by the pathologist as tumor nodules in pericolic fat. These are not to be confused with Peyer's patches which are areas of lymphoid tissue in the mucosa.

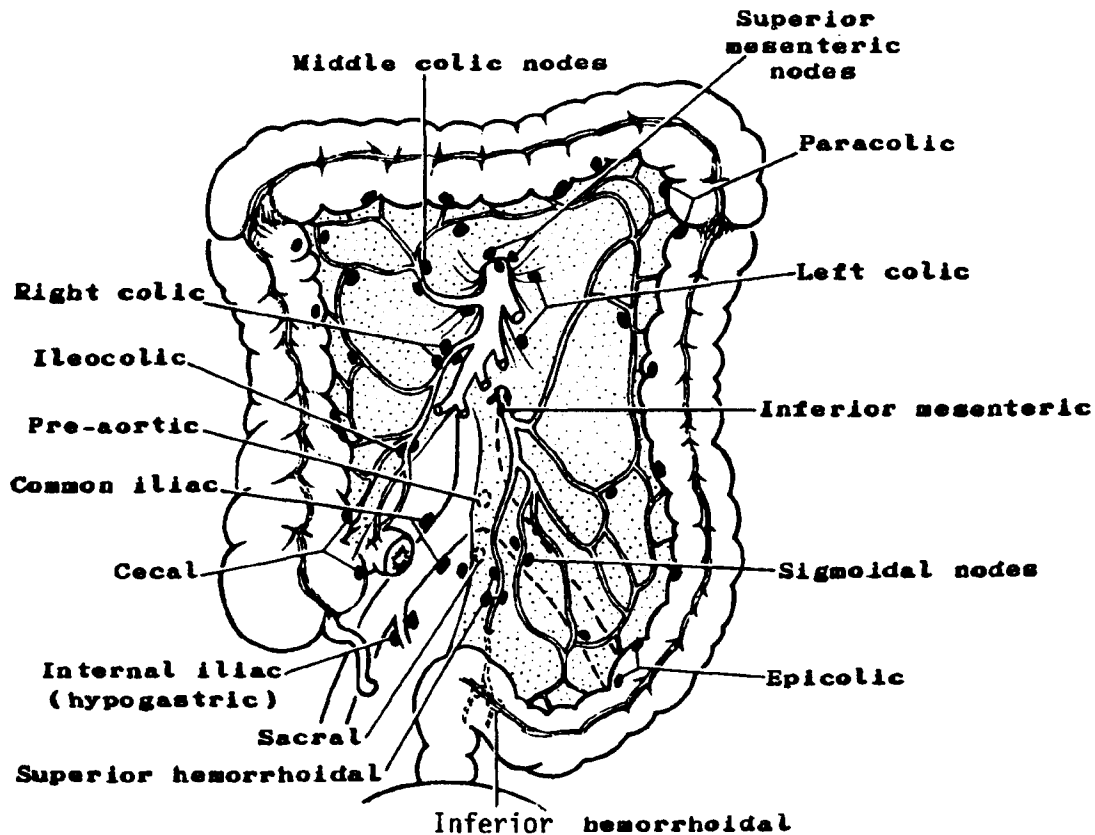
Malignant and Benign Tumors

The usual histologic type of intestinal malignancy is adenocarcinoma. Squamous cell carcinoma arises in the anus; cloacogenic transitional cell carcinoma arises at the anorectal junction. Tumors arising on the right side of the colon tend to be cauliflower-type lesions; those on the left encircling or "napkin-ring" type.

Carcinoids are the most common appendiceal tumors. They rarely metastasize. There is a difference of opinion among pathologists as to the criteria for determining their malignancy.

There are some premalignant conditions of which you should be aware. Adenomatous polyps are small reddish lesions, frequently on a stalk, which are important because of the possibility of their becoming malignant. Villous adenomas are soft, spongy, sessile lesions which arise from the bowel wall and have an even higher likelihood of becoming malignant. Familial polyposis, a hereditary polyloid disease, has a marked tendency to undergo malignant change. Ulcerative colitis may also be a precursor of malignancy. You may be required to include some of these diagnoses in your registry, or, at least, record these conditions if they are mentioned in the history of a patient with malignant disease of the colon.

Figure 37. LYMPHATIC DRAINAGE OF THE COLON AND RECTUM



The distribution of malignant tumors in the large intestine is as follows:

<u>Subsite</u>	<u>Percent of all Colorectal Cancers*</u>
Appendix	1
Cecum	16
Ascending colon	9
Transverse colon incl. flexures	13
Descending colon	5
Sigmoid	25
Rectosigmoid	10
Rectum	18
Colon, NOS	<u>3</u>
	100

*Special SEER tabulation update: Cancer Incidence, 1988. Surveillance, Epidemiology, and End Results Program.

Q41

The large intestine is about _____ feet long and is composed of three major parts:

1. _____

2. _____

3. _____

Q42

The colon is usually subdivided into five major segments:

1. _____

2. _____

3. _____

4. _____

5. _____

Answer: Q41

The large intestine is about five feet long and is composed of the following parts:

1. Colon
2. Rectum
3. Anus

Answer: Q42

The five major segments of the colon are:

1. Cecum
2. Ascending colon
3. Transverse colon
4. Descending colon
5. Sigmoid colon

Q43

The ileocolic nodes are regional nodes for which one of the following sites?

- 1) Transverse colon
- 2) Splenic flexure
- 3) Ascending colon
- 4) Rectum

Q44

Match the site on the left with the appropriate regional nodes on the right:

- | | |
|---------------------------|--------------------------|
| _____ 1) Ascending colon | a. Right colic |
| _____ 2) Descending colon | b. Inferior hemorrhoidal |
| _____ 3) Sigmoid colon | c. Left colic |
| _____ 4) Rectum | d. Inferior mesenteric |

Answer: Q43

3. The ileocolic lymph nodes are regional for the ascending colon.

Answer: Q44

- | | | |
|------------|---------------------|--|
| <u>a</u> | 1) Ascending colon | - Right colic |
| <u>c,d</u> | 2) Descending colon | - Left colic, inferior mesenteric |
| <u>d</u> | 3) Sigmoid colon | - Inferior mesenteric |
| <u>b,d</u> | 4) Rectum | - Inferior hemorrhoidal, inferior mesenteric |

Liver

The liver is the largest internal organ of the body, weighing three to four pounds (1.4-1.8 kg.). It lies immediately under the diaphragm in the right upper abdomen. Its visceral surface is molded over the stomach, duodenum, gallbladder, hepatic flexure of the colon, right kidney, and right suprarenal gland. It is divided into right and left lobes. The right lobe has three parts called the right lobe proper, the caudate lobe, and the quadrate lobe. The small bile ducts within the liver (intrahepatic ducts) join to form two larger ducts which emerge from the under surface of the liver at the porta hepatis as the right and left hepatic ducts.

The liver is one of the most vital organs in the body and plays a crucial role in the digestion and absorption of food. It breaks down protein, stores glycogen, iron, and vitamins, maintains the composition of the blood, and secretes products of detoxification. It continuously produces bile which is important in the digestion of fat and protein. The liver assists in keeping the amount of glucose (sugar) in the blood at a normal level. The liver manufactures plasma proteins. It destroys worn-out erythrocytes and foreign materials (phagocytosis). It produces heparin, an anticoagulant. It removes nitrogen from amino acids and converts it into urea. The urea then enters the blood stream and is carried to the kidneys where it is concentrated in urine and eliminated from the body.

The liver secretes certain bile salts which aid in digestion. These substances pass through the bile ducts and may be stored in the gallbladder. With the stimulation of eating, these chemicals then pass through the cystic duct and the common bile duct to enter the duodenum at the ampulla of Vater. All of these ducts and the gallbladder are referred to as the "extra-hepatic biliary system."

The lymphatic drainage from the liver is to hilar nodes, hepatic and periportal nodes below the diaphragm, and to cardiac, pericardial, posterior mediastinal, and aortic nodes above the diaphragm. Lymphatic vessels reach all parts of the organ.

Malignant and Benign Tumors

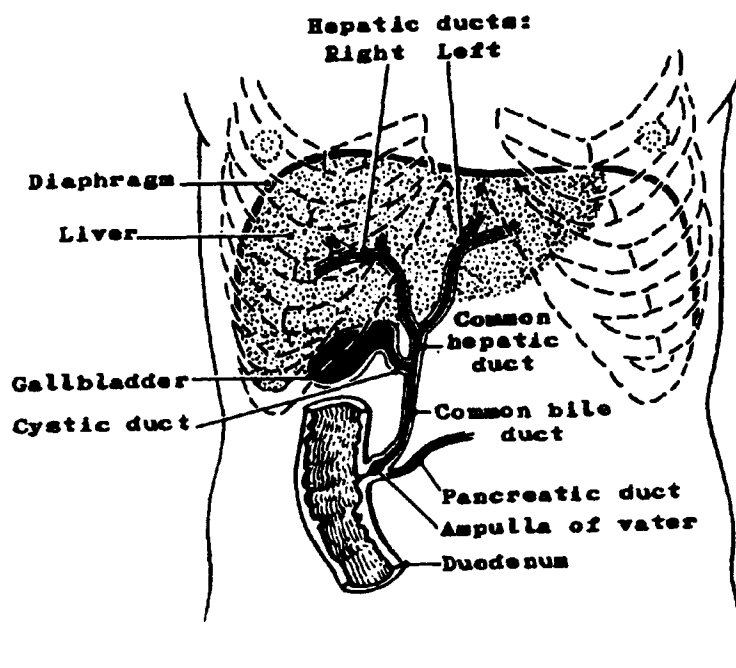
Malignant tumors of the liver are of glandular origin, i.e., adenocarcinomas. Benign liver tumors are of current interest because of a suggested association with oral contraceptive use. Primary liver tumors are rare, but may be classified as follows:

- *Hepatocellular carcinoma* (hepatoma, liver cell carcinoma) arises in the parenchymal cells of the liver. It is the predominant type of primary malignant liver tumor and is associated with pre-existing cirrhosis of the liver.
- *Cholangiocarcinoma* (bile duct carcinoma) arises in the intrahepatic bile ducts. Consequently, you may find cholangiocarcinomas of the liver as well as of the extrahepatic bile ducts.
- *Hemangioma* is a benign tumor which arises in the blood vessels of the liver; it is the most common benign liver tumor.
- *Adenomas* may arise in either the liver cells or the bile ducts of the liver.

Metastatic tumors involving the liver are much more common than primary liver tumors. Both venous and arterial blood may transport tumor cells to the liver. Section E, The Cardiovascular System, describes the transport of blood to the liver more fully.

Extrahepatic bile ducts. The right and left hepatic ducts emerging from the liver immediately join to form one common hepatic duct. The common hepatic duct merges with the cystic duct from the gallbladder to form the common bile duct. At a point seven to ten cm. below the pylorus the common bile duct enters the duodenum at the ampulla of Vater.

Figure 38. BILIARY SYSTEM



Q45

The most common primary tumor of the liver is _____ or _____. The most common malignancy found in the liver is usually a _____ tumor.

Answer: Q45

The most common primary tumor of the liver is hepatocarcinoma or hepatoma. The most common malignancy found in the liver is usually a metastatic tumor.

Gallbladder

The gallbladder is a pear-shaped sac 7 to 10 cm. long and about 2.5 cm. wide. It lies on the undersurface of the right lobe of the liver. The wall of the gallbladder is composed of three layers: a *mucosa*, a *muscular layer*, and an outer covering of peritoneum called the *serosa* which coats the gallbladder except where it is in immediate contact with the liver. The mucous lining is arranged in folds called rugae which are similar in structure and function to those of the stomach. The gallbladder stores and regulates the flow of bile manufactured by the liver. The bile enters the gallbladder via the hepatic and cystic ducts. The cystic duct from the gallbladder unites with the hepatic duct to form the common bile duct. During the digestive process the gallbladder ejects concentrated bile into the duodenum by way of the common bile duct. The duodenum receives a mixture of bile and pancreatic juice.

Lymph nodes for the gallbladder and extrahepatic bile ducts accompany the cystic and hepatic arteries to the celiac axis region. Nodes are located in relation to the common bile duct (pericholedochal), hilus of liver (hilar), the duodenum (periduodenal), liver (periportal), pancreas (peripancreatic), and cystic duct. A node of the anterior border of the foramen of Winslow¹ may be identified specifically.

Adenocarcinoma is the most common tumor of gallbladder or bile duct origin. Those arising in bile ducts may be called cholangiocarcinomas.

¹foramen of Winslow--an epiploic (omental) foramen, an opening in the omentum.

Q46

The function of the gallbladder is to _____ and _____.

Q47

The histologic type of the malignant tumors of bile duct origin, whether intrahepatic or extrahepatic, is called _____.

Answer: Q46

The function of the gallbladder is to store and regulate bile.

Answer: Q47

The histologic type of malignant tumors of bile duct origin, whether intrahepatic or extrahepatic, is called cholangiocarcinoma.

Pancreas

The pancreas is a gland shaped somewhat like a fish. It is located behind the stomach with its *head* situated in the C-shaped curve of the duodenum, its *body* extending horizontally across the posterior abdominal wall and its *tail* touching the spleen. The pancreas is both an *exocrine* and *endocrine gland*. Its exocrine functions are in manufacturing and secreting pancreatic juice which empties into the duodenum via the main pancreatic duct (duct of Wirsung). This juice helps to break down all types of food. For example, it contains lipase which helps in the digestion of fats, and it makes amylase which helps in the digestion of sugars and starches. Its endocrine functions involve certain cells (beta) of the islets of Langerhans scattered all over the gland, which secrete insulin, a hormone that plays a major role in carbohydrate metabolism. When these cells begin to lose their ability to produce insulin, the disease known as diabetes mellitus results. Other cells (alpha) of the pancreas secrete glucagon, another hormone involved in carbohydrate metabolism.

The blood supply is derived from the splenic, superior mesenteric, and hepatic arteries. The veins accompany the arteries and drain into the portal vein by way of the splenic and superior mesenteric tributaries.

Peripancreatic lymph nodes may be located superior, inferior, anterior or posterior to the organ, and the drainage will differ depending on whether it is from the head or body and tail of the pancreas. The lymph nodes for the pancreas are the:

Splenic: pancreaticolienal (body and tail)

Hepatic: infrapyloric/subpyloric (head)
pancreaticoduodenal

Superior mesenteric

Celiac axis (head)

Lateral aortic/retroperitoneal

Malignant and Benign Tumors

Adenocarcinomas make up the majority of all malignant tumors of the pancreas. Two-thirds are located in the head of the pancreas. Usually these tumors spread to adjacent organs or have metastasized by the time the diagnosis is made. Islet cell tumors may arise from the cells of the islets of Langerhans, and may be further subdivided as insulinomas, glucagonomas, or gastrinomas on the basis of their hormonal activity. These tumors may be malignant.

Q48

The pancreas plays an important role in _____ because it secretes _____
_____ found in pancreatic juices.

Q49

The three anatomic subdivisions of the pancreas are the _____,
_____, and _____.

Q50

The _____ duct and the _____ duct carry digestive juices to the intestine emptying
into the _____ by way of the _____.

Answer: Q48

The pancreas plays an important role in digestion because it secretes digestive enzymes found in pancreatic juices. *Beta* cells produce insulin (hormone), and *alpha* cells produce glucagon (hormone) into the *blood stream*. Both are involved in carbohydrate metabolism and assist in controlling glucose levels. Diabetes occurs when *beta* cells malfunction.

Answer: Q49

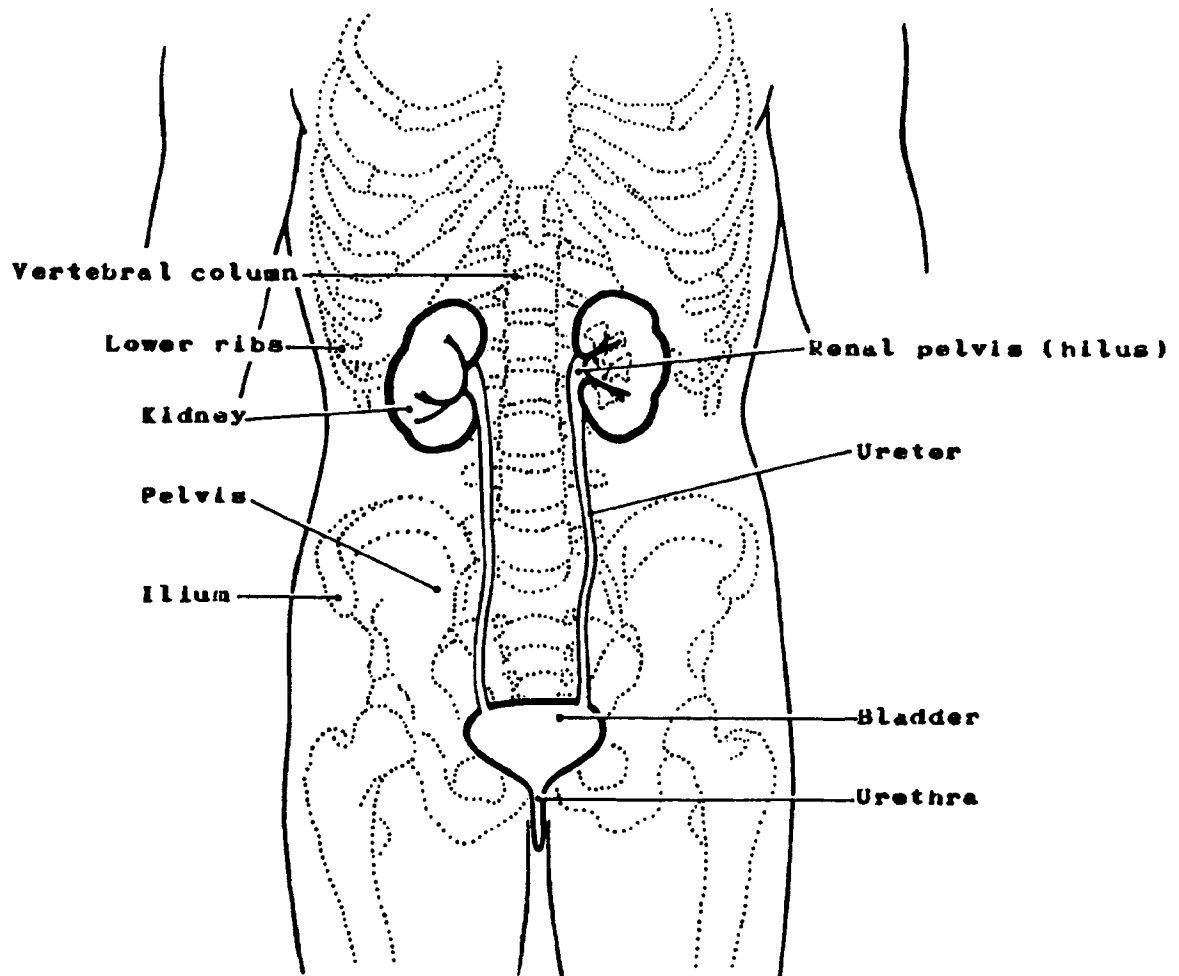
The three anatomic subdivisions of the pancreas are the head, body, and tail.

Answer: Q50

The hepatic duct and the cystic duct carry digestive juices to the intestine emptying into the duodenum by way of the common bile duct.

SECTION H
THE URINARY SYSTEM

Figure 39. PRINCIPAL PARTS OF THE URINARY SYSTEM



SECTION H

THE URINARY SYSTEM

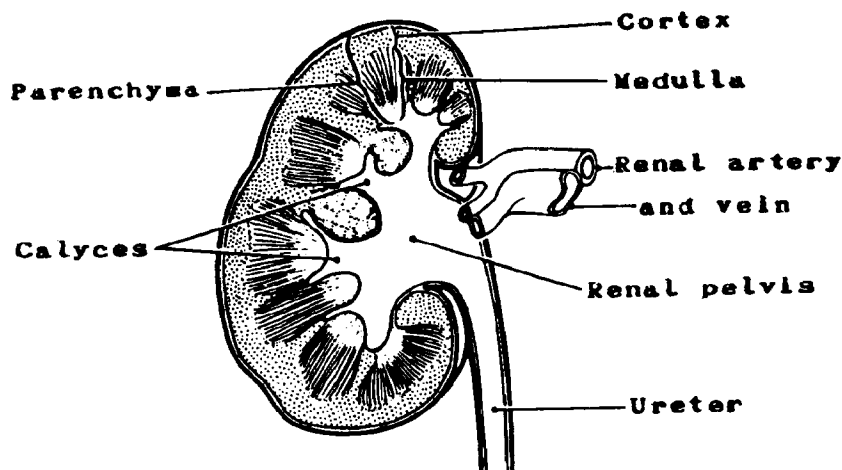
The urinary system in both males and females consists of two kidneys, two ureters, a urinary bladder, and a urethra. It is part of the excretory system of the body which also includes the respiratory, integumentary, and digestive systems.

Kidney

Each kidney is located lateral to the spinal column in the lumbar region behind the abdominal cavity. Each is, therefore, retroperitoneal, or in back of the peritoneal cavity. Each is embedded in a mass of fatty tissue which is surrounded by a fibrous covering called the renal fascia or Gerota's fascia. The renal pelvis represents extensions of the ureter and the kidney parenchyma¹ at the hilus which is located on the inner, or medial side of each kidney. The structures of the kidney parenchyma and kidney pelvis are quite different:

- The *kidney parenchyma* is the glandular part of the organ where the filtration of blood takes place and urine is produced. The outer connective tissue layer is called the cortex; the inner structure is called the medulla. The medulla consists of renal (medullary) pyramids which are separated from one another by extensions of the cortex into the medulla called renal columns.
- The *renal pelvis* and calyces² collect the urine which is then transported by the ureters from the kidney to the urinary bladder for storage.

Figure 40. KIDNEY



¹parenchyma--the functional working elements of an organ.

²calyces--(plural of calyx--cuplike organs or cavities.

The microscopic structure of the renal pelvis is similar to that found in parts of the gastrointestinal tract as well as the bladder and ureter and is as follows:

- MUCOSA

The EPITHELIAL LAYER contains no blood vessels or lymphatics.

The BASEMENT MEMBRANE is a sheet of extracellular material that functions as a filtration barrier and a boundary which helps to generate and maintain tissue structure.

- LAMINA PROPRIA, composed of areolar connective tissue, contains blood vessels, nerves, and, in some regions, glands. Once tumor has broken through the basement membrane into the lamina propria, it can spread by way of the lymphatics and blood vessels to the other parts of the body.

The urinary sites have NO MUSCULARIS MUCOSAE, and therefore, the lamina propria and the submucosa tend to merge; these terms will be used interchangeably.

- The SUBMUCOSA is a thick layer of either dense or areolar connective tissue. It contains blood vessels, lymphatic vessels, nerves, and, in some regions, glands.
- The MUSCULARIS PROPRIA is composed of two layers of smooth muscle tissue; it constitutes the wall of the organ.
- The SEROSA, the outermost layer covering, is a serous membrane, part of the visceral peritoneum. There is no serosa on the renal pelvis or ureters. Where there is no serosa, the connective tissue of surrounding structures merges with the connective tissue of the organ and is called ADVENTITIA.

Q1

The urinary system consists of two _____, two _____, a urinary _____, and a _____.

Q2

The kidneys are located in back of the peritoneal cavity or retroperitoneally, specifically, lateral to the _____ in the _____ region behind the abdominal cavity.

Q3

The glandular (working) part of the kidney is called the _____, while the part of the kidney that collects the urine which is then transported by way of the ureter to the urinary bladder is called the _____.

Answer: Q1

The urinary system consists of two kidneys, two ureters, urinary bladder, and a urethra.

Answer: Q2

The kidneys are located in back of the peritoneal cavity or retroperitoneally, specifically, lateral to the spinal column in the lumbar region behind the abdominal cavity.

Answer: Q3

The glandular (working) part of the kidney is called the parenchyma, while the part of the kidney that collects the urine which is then transported by way of the ureter to the urinary bladder is called the renal pelvis.

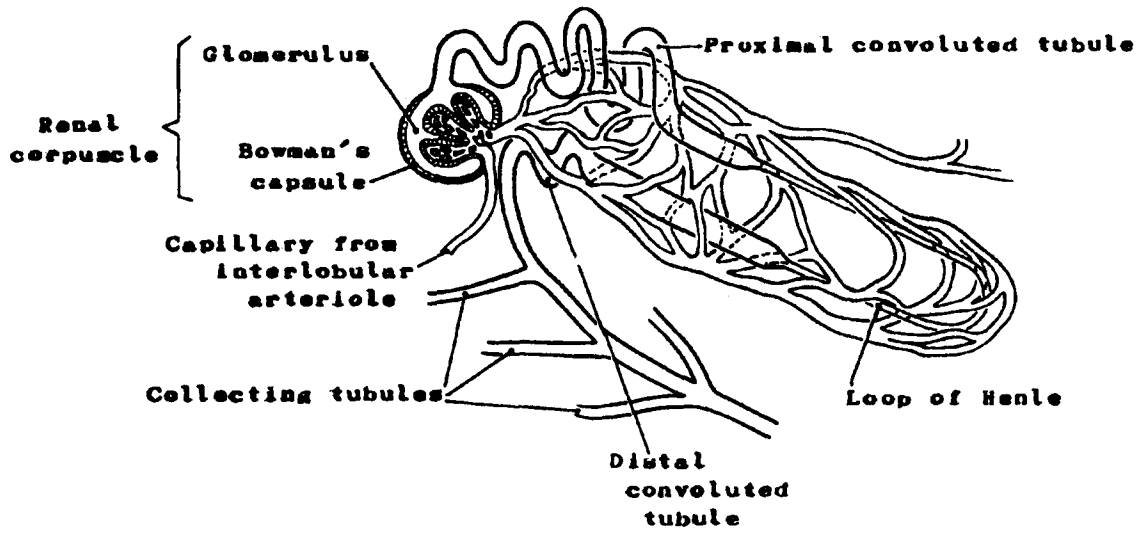
The Structural and Functional Unit of the Kidney

The structural and functional unit of the kidney is called a *nephron*. Each kidney has hundreds of thousands of nephrons, each of which is composed of a *glomerulus* (a knot of coiled capillaries¹ arising from the renal artery) and a *renal tubule*:

- The *glomerulus* and a surrounding *Bowman's capsule* are called the *renal corpuscle*. The renal corpuscles are located in the cortex of the kidney.
- The *renal tubule* begins in the glomerular capsule and has three different designations along its course: the proximal convoluted tubule, the descending loop of Henle, and the distal convoluted tubule (the end of the nephron). The proximal and the distal convoluted tubules are located in the cortex of the kidney; the loop of Henle is located in the medulla. The proximal tubules form the double-walled cup known as *Bowman's capsule*. The distal tubules of several nephrons empty into a common *collecting tubule* that transports urine back into the renal pyramids of the medulla and then into a minor calyx of the renal pelvis.

¹capillary--a minute blood vessel.

Figure 41. A NEPHRON



The function of the kidney is to remove metabolic waste products from the blood and to maintain the electrolyte¹ balance. This is accomplished by the production of urine.

The formation of urine and the regulation of the internal environment of the body by the kidneys are a composite of four processes:

- *Filtration* of the blood through the capillaries of the glomerulus into Bowman's capsule
- Selective *reabsorption* by the renal tubules of materials required to maintain the internal environment of the body, i.e., the fluid and electrolyte balance
- *Secretion* of certain substances produced in the distal and collecting tubules causing potassium, hydrogen ions, and other substances to be taken from the blood and added to the tubular filtrate
- *Maintenance of acid-base balance* (pH² 7.4) by regulating the amount of acid or base which the kidneys eliminate in the urine.

The Production of Urine

The *aorta* brings waste-filled blood from the *heart* to the kidneys by way of the *renal arteries*. Here in the kidneys the waste products of metabolism and toxic substances are eliminated. Blood enters the glomerulus through the afferent arteriole which divides into capillaries. These will later unite to form the efferent arteriole that drains blood from the glomerulus. As the blood passes through the glomerulus, water, glucose, salts, and nitrogenous wastes are filtered into Bowman's capsule which is the beginning of the renal tubule. The contents of the distal portion of the tubule pass to branches of the collecting tubule which empties into the calyces of the renal pelvis. These contents are then transported through the ureters from the renal pelvis to the bladder. Certain substances required to maintain fluid and electrolyte balance are reabsorbed by the peritubular capillaries³ (e.g., sodium, glucose, water) and returned to the blood. Secretions produced in the distal and collecting tubules cause other substances to be added to the tubular filtrate from the blood (e.g., potassium, hydrogen ions, and ammonia).

Some abnormal constituents found in the urine are albumin, blood, calculi, melanin, and malignant cells.

Through the capillaries of the glomeruli, approximately 120 milliliters (ml) of water and salts are filtered from the blood each minute. Most of the water is reabsorbed as are other essential substances unless their concentration in the body happens to be too high. The urine passes out through the collecting tubules at a rate of approximately 1.0 milliliter per minute, so that a healthy person will excrete about 1 to 1 and 1/2 liters per day.

¹electrolytes--mainly, ions such as sodium, potassium, ammonium chloride, bicarbonate, phosphate, and sulfate. Levels vary with diet and other factors.

²pH--refers to the hydrogen ion concentration expressing both acidity and alkalinity on a scale whose values run from 0 to 14 with 7 representing neutrality, numbers less than 7 increasing acidity, and numbers greater than 7 increasing alkalinity.

³peritubular capillaries--capillary beds that surround the renal tubules.

Q4

Why is blood circulated through the kidneys?

a. _____

b. _____

Q5

What is the structural and functional unit of the kidney?

Q6

Through which parts of the kidney are water and salts filtered?

Q7

Give the names of the major structures involved in the urinary process from the point at which blood enters the capillaries in the cortex of the kidney until it enters the calyces of the renal pelvis.

1. _____ 2. _____

3. _____ 4. _____

Answer: Q4

The blood is circulated through the kidneys:

- a. To excrete waste products of metabolism and toxic substances from the body.
- b. To help maintain the fluid and electrolyte balance.

Answer: Q5

The nephron is the structural and functional unit of the kidney.

Answer: Q6

Water and salts are filtered through the capillaries of the glomeruli.

Answer: Q7

The major structures involved in the urinary process from the point at which blood enters the capillaries in the cortex of the kidney until it enters the calyces of the renal pelvis are:

1. Glomerulus
2. Bowman's capsule
3. Renal tubule
4. Collecting tubule

Regional Lymph Nodes

The lymphatics of the kidney and renal pelvis drain to retroperitoneal nodes along the abdominal aorta and vena cava (paracaval), primarily to those near the origin of the renal arteries. Perirenal nodes are those at the renal hilus.

Malignant Tumors

Tumors which arise in the kidney parenchyma or the renal pelvis usually can be distinguished by the histologic type:

Malignant tumors of the *kidney* parenchyma:

- *Adenocarcinoma* makes up 80 per cent of renal tumors. It may also be called hypernephroma, renal cell carcinoma, and Grawitz's tumor.
- *Wilms' tumor* or nephroblastoma is the most common abdominal malignancy in children. It is almost exclusively a disease of children under six years of age. It is a mixed tumor histologically made up of embryonal tissue, probably of nephrogenic origin. It is highly malignant but often is successfully treated.

Malignant tumors of the *renal pelvis*:

- *Transitional cell carcinoma* is the most common tumor of the renal pelvis.
- *Squamous cell carcinoma* is rare.

Tumors of the renal pelvis comprise 15-18 percent of the renal malignancies.

Q8

The regional lymph node drainage for the kidney parenchyma is to:

1. _____
2. _____
3. _____

The regional lymph node drainage for the renal pelvis is to:

1. _____
2. _____
3. _____

Q9

Indicate whether the following tumors would most likely arise in the kidney parenchyma (use symbol k) or in the renal pelvis (use symbol r):

- ___ 1. Transitional cell carcinoma
- ___ 2. Wilms' tumor
- ___ 3. Adenocarcinoma
- ___ 4. Squamous cell carcinoma

Q10

What is the major kidney tumor occurring in childhood?

Q11

What is the most common type of kidney cancer?

Answer: Q8

The regional lymph node drainage for the kidney parenchyma is to:

1. Renal hilar lymph nodes
2. Paracaval lymph nodes
3. Para-aortic or retroperitoneal lymph nodes

The regional lymph node drainage for the renal pelvis is to:

1. Renal hilar lymph nodes
2. Paracaval lymph nodes
3. Para-aortic or retroperitoneal lymph nodes

Answer: Q9

The following tumors would most likely arise in the kidney parenchyma (indicated by k) or the renal pelvis (indicated by r):

- r 1. Transitional cell carcinoma
- k 2. Wilms' tumor
- k 3. Adenocarcinoma
- r 4. Squamous cell carcinoma

Answer: Q10

The major kidney tumor occurring in childhood is Wilms' tumor.

Answer: Q11

The most common type of kidney cancer is adenocarcinoma. It may also be called a renal cell carcinoma, hypernephroma, or Grawitz's tumor.

Ureters

Each kidney is connected to the urinary bladder by a *ureter*. These muscular tubes are about 26 to 28 cm in length, beginning at the renal pelvis. They transport urine from the kidney to the bladder.

The microscopic structure of the ureter is similar to that of the renal pelvis consisting of a mucosa of epithelium and lamina propria, a submucosa, a muscularis propria, and an outer adventitia of fibroelastic connective tissue.

Regional Lymph Nodes

The regional lymph node drainage for the ureters is to the:

- Periureteral
- Renal hilar
- Common iliac
- Internal iliac (hypogastric)
- External iliac
- Paracaval

Malignant Tumors

Primary cancer of the ureter is rare. When cancer does occur, it is usually transitional cell carcinoma, resembling cancer of the renal pelvis; it often presents as an ureteral obstruction.

Q12

What is the tube which carries urine from the kidney to the bladder?

Q13

What are the tissue layers of the renal pelvis excluding the basement membrane?

1. _____ }
2. _____ } Mucosa
3. _____
4. _____
5. _____

Answer: Q12

The tube which carries urine from the kidney to the bladder is the ureter.

Answer: Q13

The tissue layers of the renal pelvis are:

1. Epithelium } Mucosa
- }
2. Lamina propria }
3. Submucosa
4. Muscularis propria (or two layers of smooth muscle)
5. Adventitia

Urinary Bladder

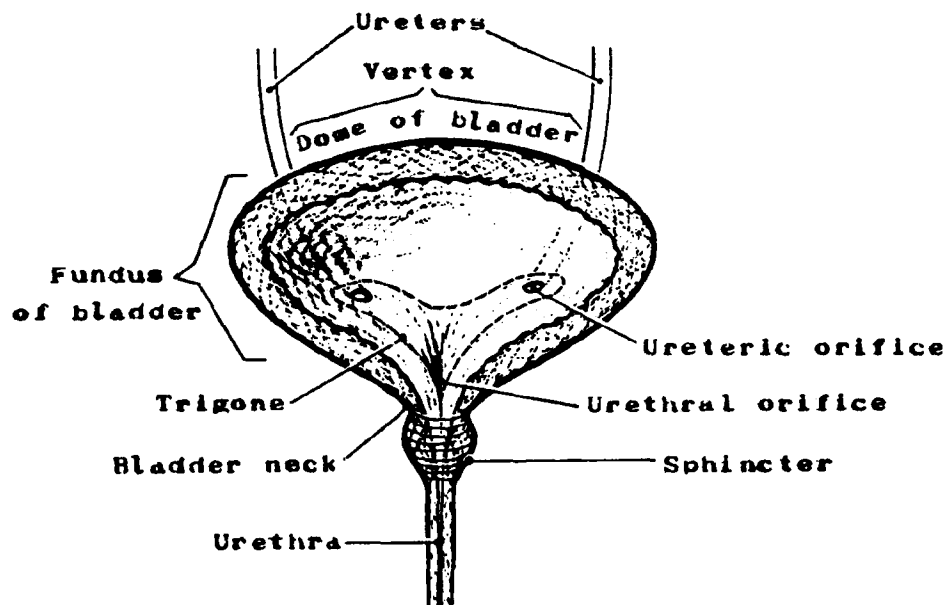
The urinary bladder is a hollow muscular organ which serves as a reservoir for urine. It lies in the pelvis behind the pubic bone. The adult urinary bladder has a capacity of 300-350 milliliters.

Three openings mark off a triangular area called the *trigone* at the base of the bladder. These are the orifices of the two ureters and the urethra. The trigone is smooth even when the bladder is empty; the remainder of the bladder wall is in folds allowing for expansion when the bladder is full. The superior surface of the bladder may be referred to as the dome; other subsites are the lateral, anterior, and posterior walls. The trigone may also be referred to as the floor or base.

In the female, the bladder is located in front of and below the uterus being separated from the anterior part of the uterus by a fold of peritoneum called the uterovesical pouch. Posteriorly, it is connected to the cervix and upper vagina by a thick layer of connective tissue.

In the male, the inferior surface of the bladder which is not covered by peritoneum is in proximity to the upper rectum and is separated from it by the rectovesical fascia which contains the seminal vesicles and vas deferens. The prostate lies just below the bladder and surrounds the proximal part of the urethra as it emerges from the urinary bladder.

Figure 42. URINARY BLADDER



URINARY BLADDER, RENAL PELVIS AND URETERS

PRIMARY SITE	MUCOSA			MUSCULARIS PROPRIA	SEROSA
	Epithelium	B A S E : M E M B R A N E :	Lamina Propria/ Submucosa		
Urinary Bladder (C67. __)	Yes	B A S E : M E M B R A N E :	Yes	Yes	Yes, on superior surface
Renal pelvis (C65.9)	Yes		Yes	Yes	No
Ureter(s) (C66.9)	Yes		Yes	Yes	No

The bladder wall has the same three tissue layers as the renal pelvis and ureter:

The EPITHELIAL LAYER (mucosa) contains no blood vessels or lymphatics.

The BASEMENT MEMBRANE is a sheet of extracellular material that functions as a filtration barrier and a boundary which helps to generate and maintain tissue structure.

- LAMINA PROPRIA, composed of areolar connective tissue, contains blood vessels, nerves, and, in some regions, glands. Once tumor has broken through the basement membrane into the lamina propria, it can spread by way of the lymphatics and blood vessels to the other parts of the body.

The urinary sites have NO MUSCULARIS MUCOSAE, and therefore, the lamina propria and the submucosa tend to merge; these terms will be used interchangeably.

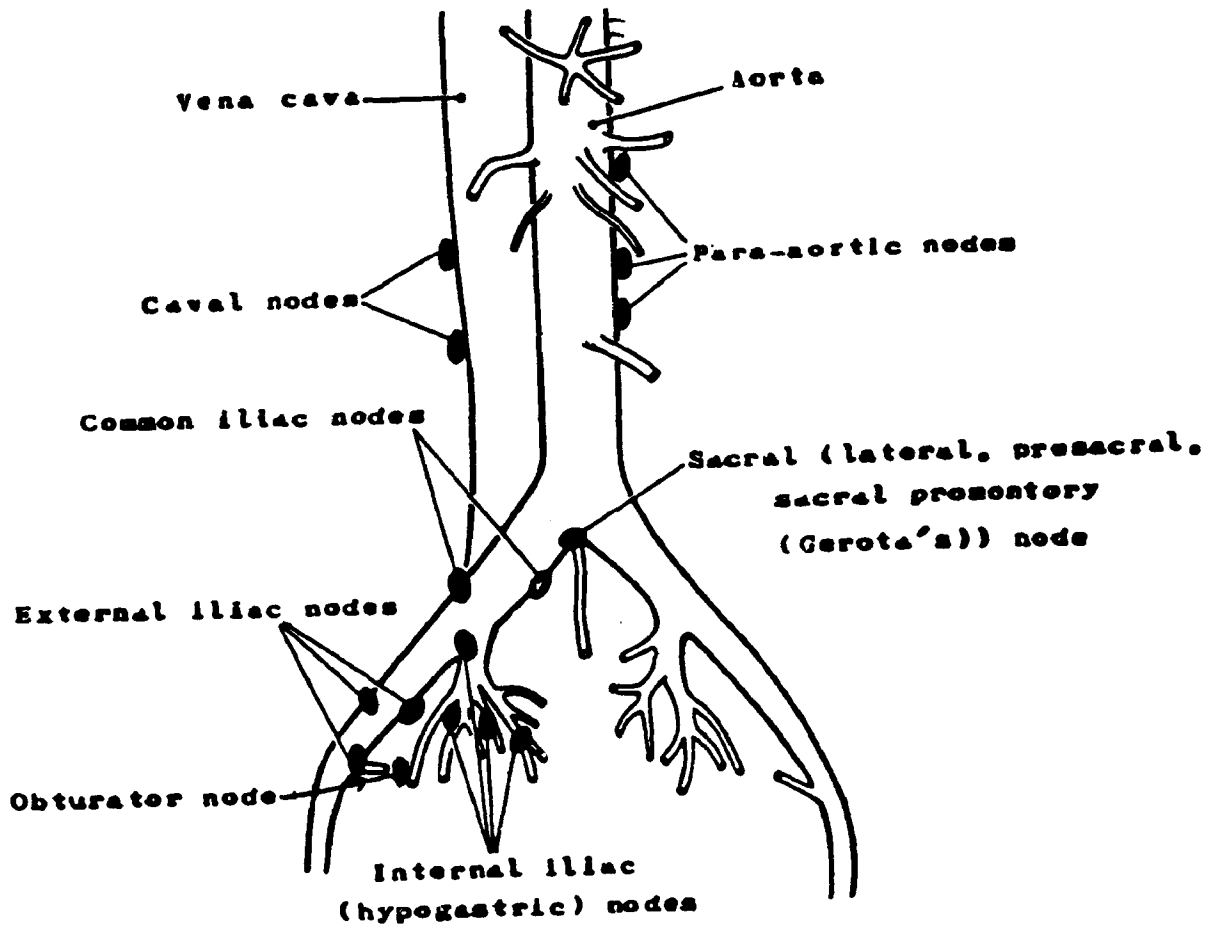
- The SUBMUCOSA is a thick layer of connective tissue. It contains blood vessels, lymphatic vessels, nerves, and in some regions, glands.
- MUSCULARIS PROPRIA consists of three layers of smooth muscle which provide the ability to expand and contract.
- The superior and posterior aspects of the bladder have a *serosal covering* (peritoneum) which is not found inferiorly.

Regional Lymph Nodes

The regional lymph nodes draining the bladder are:

- Perivesical
- Internal iliac (hypogastric) including obturator
- External iliac
- Sacral (lateral, presacral, promontory (Gerota's))

Figure 43. LYMPHATIC DRAINAGE OF THE BLADDER



Malignant Tumors

Bladder cancer is the most frequent malignancy of the urinary tract, and it is more common in men than in women. Most bladder tumors are papillary in appearance and will often occur and recur in multiple sites within the bladder. The lateral and posterior walls are involved with tumor more frequently than is the trigone. There is a high frequency of bladder cancer in heavy smokers.

- *Transitional cell carcinoma* is the most common bladder cancer accounting for 90-95 percent of bladder tumors. The grading, as well as the staging, of these tumors is of particular significance in prognosis, there being a high level of correlation between grade (differentiation) and stage (invasiveness).

There are different grading systems. Using Broders'¹ Classification, bladder tumors may be diagnosed as carcinoma Grades I - IV. In other classifications, Broders' Grade I tumor is called a papilloma, with further subdivision into carcinoma Grades I - III.

Foci of squamous cell carcinoma and adenocarcinoma may be found in association with transitional cell carcinoma, especially in high-grade tumors.

- *Squamous cell carcinoma* occurring in a pure form is rare, less than 10 percent of all bladder carcinomas.
- *Adenocarcinoma* of the bladder is rarely found in pure form and is almost impossible to distinguish from prostatic carcinoma with extension to the bladder.
- *Leiomyosarcoma* is a rare tumor arising in the smooth muscle of the bladder.

¹Broders, Albert C.--a pathologist who formulated a four-grade classification of malignancy based on the degree of cellular dedifferentiation.

Q14

What is the term for the muscular sac which serves as a reservoir for urine?

Q15

What is the trigone area of the organ referred to in Q14 above?

Q16

Which of the following lymph nodes are regional for the bladder?

- a. Supraclavicular
- b. External iliac
- c. Inguinal
- d. Obturator
- e. Aortic (para-, peri-, lateral) (retroperitoneal)

Q17

What are the layers of the bladder wall (interior to exterior)?

1. _____ of (a) _____ and (b) _____
2. _____
3. _____
4. _____

Answer: Q14

The urinary bladder is a reservoir for urine.

Answer: Q15

You might have said: The trigone area of the bladder is a triangular area at the base of the bladder marked off by orifices of the two ureters and urethra.

Answer: Q16

Regional nodes for the bladder are:

- b. External iliac
- d. Obturator

Answer: Q17

The layers of the bladder wall (interior to exterior) are:

1. Mucosa of (a) epithelium and (b) lamina propria
2. Submucosa
3. Muscularis propria or musculature (three layers of smooth muscle)
4. Serosa (superior surface only)

Urethra

The urethra is a membranous tube which conveys urine from the urinary bladder to the exterior of the body.

At the proximal end is a circular smooth muscle which surrounds the bladder neck and is known as the *internal sphincter*. It is controlled by the autonomic nervous system. The *external sphincter* of the urethra is a circular striated muscle which is under voluntary control. In the female, the external sphincter is located in the vulva; in the male it is in the glans penis.

The urethra differs in men and women:

The female urethra is a part of only the excretory system and is approximately 2.5 - 3.0 cm long.

The male urethra is a part of both the excretory system and the reproductive system. It has three regions:

- The *prostatic urethra* which passes through the prostate gland is approximately 2.5 cm long.
- The *membranous urethra* which comprises the external muscular section is approximately 1.3 cm long.
- The *penile* (spongy or cavernous) *urethra* which passes through the penis is approximately 9.0 - 15.0 cm long.

Regional Lymph Nodes

The regional lymph nodes for the urethra are:

Common iliac
Internal iliac (hypogastric) including obturator
External iliac
Inguinal (superficial or deep)
Presacral

Malignant tumors are rare and are almost always transitional cell carcinomas.

Q18

The _____ is a membranous tube which conveys urine from the urinary bladder to the exterior of the body.

Q19

Match the terms on the left with the descriptions on the right.

- | | | |
|-----|---------------------|---|
| ___ | 1. Bowman's capsule | a. Tubules leading from Bowman's capsule to the collecting tubules |
| ___ | 2. Renal tubules | b. Tube carrying urine from the bladder to the outside of the body |
| ___ | 3. Glomerulus | c. Muscular sac which serves as a reservoir for urine |
| ___ | 4. Urethra | d. Tubes carrying urine from the kidney to the urinary bladder |
| ___ | 5. Ureters | e. Collection of capillaries through which blood is filtered |
| ___ | 6. Bladder | f. Structure in the kidney which receives the filtered materials directly from the glomerulus |
| ___ | 7. Nephron | g. The structural and functional unit of the kidney |

Q20

The renal pelvis is:

- a. a muscular sac which serves as a reservoir for urine.
- b. the central urine-collecting structure of the kidney from which urine is delivered to the bladder via the ureters
- c. a structure which receives the filtered materials directly from the glomerulus.
- d. the outer layer of the kidney.

Answer: Q18

The urethra is a membranous tube which conveys urine from the urinary bladder to the exterior of the body.

Answer: Q19

<u>f</u>	1.	Bowman's capsule	Structure in the kidney which receives the filtered materials directly from the glomerulus
<u>a</u>	2.	Renal tubules	Tubules leading from Bowman's capsule to the collecting tubules
<u>e</u>	3.	Glomerulus	Collection of capillaries through which blood is filtered
<u>b</u>	4.	Urethra	Tube carrying urine from the bladder to the outside of the body
<u>d</u>	5.	Ureters	Tubes carrying urine from the kidney to the urinary bladder
<u>c</u>	6.	Bladder	Muscular sac which serves as a reservoir for urine
<u>g</u>	7.	Nephron	The structural and functional unit of the kidney

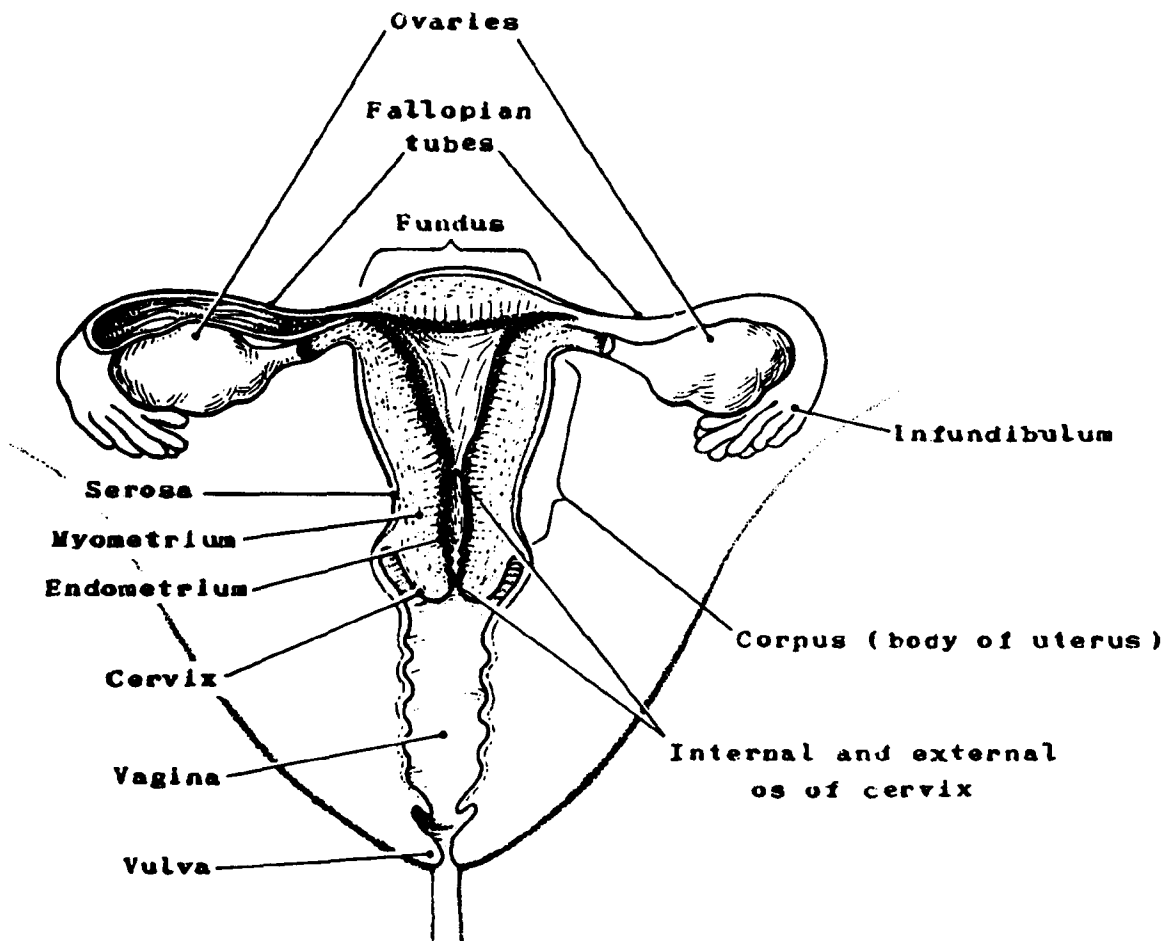
Answer: Q20

The renal pelvis is:

- b. The central urine-collecting structure of the kidney from which urine is delivered to the bladder via the ureters.

SECTION I
THE REPRODUCTIVE SYSTEM

Figure 44. FEMALE PELVIS (frontal view)



SECTION I

THE REPRODUCTIVE SYSTEM

Female Reproductive System

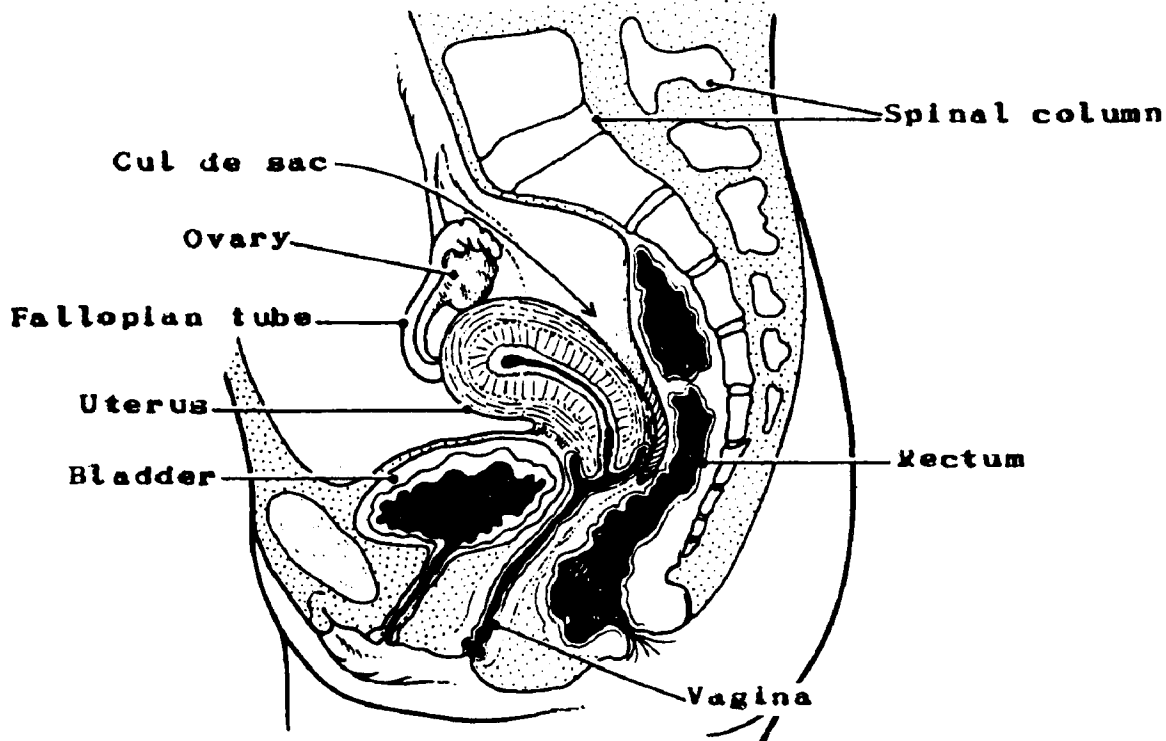
The female reproductive system is made up of the uterus and two ovaries, two fallopian tubes (uterine tubes or oviducts), a vagina, and a vulva (pudendum or external genitalia). Two breasts (or mammary glands) are considered to be accessory organs of the female reproductive system and will be discussed in this section.

Uterus

The uterus is a hollow, pear-shaped, muscular organ located in the pelvic cavity between the bladder and the rectum. The uterus plays a role in three important functions: menstruation, pregnancy, and parturition. It is composed of two parts, an upper portion called the *corpus* (or body), and a lower, narrow part called the *cervix*. The fundus is that portion of the corpus which rounds into a bulging prominence at about the level at which the fallopian tubes enter the corpus.

Midway between the uterus and the rectum is a region in the abdominal cavity known as the *cul de sac*. It is important that you remember this term because it will be examined for the presence of cancer.

Figure 45. FEMALE PELVIS (sagittal view)



CORPUS UTERI

PRIMARY SITE	ENDOMETRIUM (mucosa)		MYOMETRIUM (3 muscle layers)	SEROSA (Perimetrium)
Corpus Uteri (C54. __)	Columnar Epithelium	B A S E M E M	Stroma (Lamina Propria)	Yes
	Yes		Yes	

The wall of the uterine corpus is composed of the following microscopic layers:

- The EPITHELIAL LAYER contains no blood vessels or lymphatics.

The BASEMENT MEMBRANE is a sheet of extracellular material that functions as a filtration barrier and boundary which helps to generate and maintain tissue structure.

The LAMINA PROPRIA, composed of areolar connective tissue, contains blood vessels, nerves, and, in some regions, glands. Once tumor has broken through the basement membrane into the lamina propria, it can spread by way of the lymphatics and blood vessels to other parts of the body.

- There is NO MUSCULARIS MUCOSAE OR SUBMUCOSA in the endometrium.
- The MYOMETRIUM, the thick middle layer, is composed of three layers of smooth muscle fibers: longitudinal, transverse, and oblique, that extend in all directions and give great strength to the uterus. It contains an abundance of blood vessels, lymphatics, and nerves.

The uterine cervix is composed of:

- A MUCOSA of columnar glandular epithelium in the upper portion of the cervical canal (endocervix) which is continuous with that of the corpus. It becomes stratified squamous epithelium at the lower end of the canal extending onto the lip of the cervix (ectocervix or exocervix).
- A LAMINA PROPRIA (stroma) of dense connective tissue which contains a few smooth muscle fibers and the cervical glands.

Q1

The female reproductive organs are:

1. _____
2. _____
3. _____
4. _____
5. _____

Q2

The uterus is located in the _____ cavity between the _____ and the _____.

Q3

The uterus is composed of two parts, an upper portion called the _____ and a lower, narrow portion called the _____.

Q4

The portion of the body of the uterus which rounds into a bulging prominence at about the level at which the fallopian tubes enter is called the _____.

Q5

The three tissue layers of the body of the uterus are:

1. _____
2. _____
3. _____

Answer: Q1

The female reproductive organs are:

1. The uterus
2. Two ovaries
3. Two fallopian tubes (uterine tubes or oviducts)
4. A vagina
5. A vulva

Answer: Q2

The uterus is located in the pelvic cavity between the bladder and the rectum.

Answer: Q3

The uterus is composed of two parts, an upper portion called the body (or corpus) and a lower, narrow portion called the cervix.

Answer: Q4

The portion of the body of the uterus which rounds into a bulging prominence at about the level at which the fallopian tubes enter is called the fundus.

Answer: Q5

The three tissue layers of the body of the uterus are:

1. Endometrium (mucosa)
2. Myometrium
3. Serosa (Perimetrium)

The uterus has thick walls and a small, flat, triangular-shaped cavity. Its apex is directed downward and forms the *internal os* which opens into the cervical canal. The cervical canal narrows at its lower end and forms the *external os* opening into the vagina. The mucosa of the vaginal wall is contiguous with the mucosa of the cervix. A circular recess around the cervix at its junction with the vagina is called the fornix. It is divided into four fornices or parts: anterior, posterior, and two lateral. The fallopian tubes join the uterine cavity at the upper, outer angles. A generous blood supply is received by the uterus from the uterine arteries which are branches of the internal iliac arteries. Eight ligaments which hold the uterus in place but allow considerable movement are two broad ligaments, two uterosacral ligaments, the posterior ligament, the anterior ligament, and two round ligaments.

Parametrium, connective tissue which surrounds the uterus, separates the cervix from the bladder and extends between the two serosal layers of the broad ligaments as well as to and over the pelvic walls.

Regional Lymph Nodes

The regional lymph nodes for both the corpus and the cervix uteri are:

Pelvic Nodes:

- Paracervical
- Parametrial
- Common iliac
- Internal iliac (hypogastric, including obturator)
- External iliac
- Sacral (lateral, presacral, promontory (Gerota's), uterosacral)
- Aortic (para-, peri-, lateral)--regional for corpus uteri only

The major lymphatic trunk is the utero-ovarian (infundibulo-pelvic), which drains into the iliac and sacral nodes.

Malignant Tumors

The histologic types of cancer arising in the uterus are:

- Adenocarcinoma arising in the glandular epithelium of the endometrium and of the upper two-thirds of the cervical canal
- Leiomyosarcoma arising in the smooth muscle of the myometrium
- Adenosquamous carcinoma arising at the squamous columnar junction
- Squamous cell carcinoma arising in the lower one-third of the cervical canal and the lip of the cervix, and often extending into the vagina. The majority of the neoplasms arising in the cervix will arise in the lower one-third. These will be chiefly in situ, i.e., there will be no stromal invasion. Lesions with stromal invasion of 3 mm or less may be described as micro-invasive.
- Endometrial stromal sarcoma

- Choriocarcinoma, a highly malignant tumor composed of chorionic (placental) type tissue
- Muellierian mixed tumor (mixed mesenchymal or mesodermal sarcoma), a relatively large group of sarcomas with no single histologic pattern
- Carcinosarcoma, a tumor of the endometrium which is composed of carcinomatous elements as well as stroma with characteristics of sarcoma.

Q6

For each of the sites below, list four lymph node groups that drain these sites.

Corpus:

Cervix

Answer: Q6

For corpus uteri you might have said:

- Common iliac
- Internal iliac or hypogastric or obturator
- External iliac
- Parametrial
- Paracervical
- Aortic (para-, peri-, lateral)
- Sacral

For cervix uteri you might have said:

- Common iliac
- Internal iliac or hypogastric or obturator
- External iliac
- Sacral
- Paracervical
- Parametrial

Ovaries

The ovaries, female gonads¹, are the shape and size of large almonds and are located one on either side of the uterus, below and behind the fallopian tubes. Each ovary lies between the folds of the broad ligament and is attached to its posterior surface by the mesovarian ligament. The ovarian ligament anchors it to the uterus. The distal portion of the fallopian tube curves about the ovary so that a fimbriated cup hangs over each ovary but is not actually attached to it. The ovary is an example of a gland whose duct is detached from it.

Microscopically, the ovary consists of a layer of germinal epithelial cells and a layer of connective tissue in which structures known as graafian follicles are embedded. When a graafian follicle matures (usually one per month alternating between right and left ovaries), it expels an ovum. This process is called ovulation. After ovulation, the wall of the follicle is transformed into an endocrine gland, the corpus luteum, which secretes progesterone and some estradiol. The corpus luteum lasts only about 12-14 days if the ovum is not fertilized; it then deteriorates into a small fibrous cicatrix.² When the ovum has been fertilized, it travels to the uterus and becomes embedded in endometrial tissue. The developing trophoblast³ produces hormones (chorionic gonadotrophins) which stimulate the corpus luteum to increase in size and to prolong its production of progesterone which furthers the developing of the endometrium and the anchoring and nurturing of the embryo. Near the end of pregnancy, the corpus luteum shrinks and over a period of months undergoes the same degenerative changes as when the ovum is not fertilized.

The development and activities of the graafian follicle and of the corpus luteum are triggered by hormones secreted by the pituitary gland. However, as indicated above, the ovary itself has a hormonal function. During the maturation of the graafian follicle, certain cells (thecal and granulosa) surrounding or sheathing the developing ovum produce estrogenic hormones, mainly estradiol and estrone. These cells are replaced by the luteal cells after ovulation. The normal cyclical process of menstruation, with development and degeneration of endometrial cells, is governed by these hormonal activities of the pituitary and the ovaries.

Regional Lymph Nodes

Regional lymph node metastasis from the ovary is infrequent, but when it occurs it is primarily to the para-aortic nodes. However, any of the following may be considered regional lymph nodes draining the ovaries:

Pelvic lymph nodes:

Common iliac

Internal iliac (hypogastric, including obturator)

External iliac

Lateral sacral

Aortic (para-, peri-, lateral)

Inguinal (rare)

¹gonads--organs which produce sex cells--ovaries and testes.

²cicatrix--scar resulting from formation and contraction of fibrous tissue.

³trophoblast--the ectodermal layer covering and attaching the embryo to the uterine wall and supplying nutrition for it.

Fallopian tubes

The fallopian tubes, also called oviducts and uterine tubes, are attached to the uterus at its upper, outer angles. They lie between the folds of the broad ligaments and extend upward and outward toward the pelvic sidewalls and then curve downward and backward.

The walls of the tubes are composed of the same three tissue layers as the uterine corpus.

- A ciliated mucous lining of epithelial tissue. (The cilia propel the ovum from the ovary to the uterus.)
- Smooth muscle
- Serosa (or external peritoneal covering)

At the distal end, each tube expands into a funnel-like portion (the infundibulum) which resembles a fringe or is "fimbriated." Here the mucous lining of the tubes is directly continuous with the peritoneum. The fallopian tubes serve as ducts for the ova produced by the ovaries. Fertilization (union of a spermatozoon and an ovum) normally occurs in the fallopian tubes. Tumors of the fallopian tubes are extremely rare.

Regional Lymph Nodes

The regional lymph nodes for the fallopian tubes are:

Pelvic lymph nodes
Common iliac
Internal iliac (hypogastric, including obturator)
External iliac
Lateral sacral
Aortic (para-, peri-, lateral)
Inguinal

Q7

Match the sites on the left with the descriptions on the right.

- | | | |
|-------|--------------------|--|
| _____ | 1. Uterus | a. Ducts through which ova travel into the uterus |
| _____ | 2. Fallopian tubes | b. Pear-shaped muscular organ in the pelvic cavity in which the embryo develops after fertilization |
| _____ | 3. Ovaries | c. Organs which produce ova and hormones associated with female reproduction and secondary sex characteristics |

Answer: Q7

- | | | |
|----------|--------------------|---|
| <u>b</u> | 1. Uterus | Pear-shaped muscular organ in the pelvic cavity in which the embryo develops after fertilization |
| <u>a</u> | 2. Fallopian tubes | Ducts through which ova travel into the uterus |
| <u>c</u> | 3. Ovaries | Organs which produce ova and hormones associated with female reproduction and secondary sex characteristics |

Malignant Tumors

Common histologic types of ovarian tumors are as follow:

- Cystadenocarcinoma is a malignant tumor growing within a cyst, the walls of which are lined with columnar epithelial cells. This glandular epithelium may be serous-secreting or mucinous-secreting giving rise to:
 1. *Serous cystadenocarcinoma*, a cystic cavity which is lined with ciliated epithelial cells and contains serous fluid. It is the most common malignant tumor of the ovary.
 2. *Mucinous cystadenocarcinoma*, a cystic cavity which is lined with ciliated epithelial cells and contains mucin. These mucinous cystadenocarcinomas sometimes rupture and spill their contents into the peritoneal cavity. This spillage can cause a clinical condition called *pseudomyxoma peritonei* in which tumor is implanted on all serosal surfaces and the abdominal contents are matted together.
- Endometrioid carcinoma is an ovarian tumor of epithelial origin that microscopically resembles a tumor originating in the endometrium.
- Dysgerminoma is a relatively uncommon tumor of germ cell origin, the counterpart of seminoma of the testis.
- Teratocarcinoma or malignant teratoma is a tumor of germ cell origin composed of embryonic tissue which is differentiated into bone, hair, teeth, cartilage, and skin. All these types of tissues may be found in the tumor. A benign tumor with these characteristics is called a dermoid.
- Granulosa cell and theca cell tumors arise from cells of the early ovarian mesenchyme in the ovarian stroma which surrounds the developing ovum. They are sometimes called feminizing or estrogen-producing tumors.
- Krukenberg tumor is a metastatic tumor of the ovary, usually from a primary in the stomach or other gastrointestinal site, with a marked ovarian tissue proliferation.

Less common tumors of the ovary are: Brenner tumors, arrhenoblastoma (masculinizing tumor), fibrosarcoma, and mesonephric tumors.

Ovarian tumors are frequently bilateral. They spread by implantation to the peritoneum, omentum, and serosal surfaces. They may also arise as independent primaries with no evidence of intraperitoneal spread.

Q8

Name the three openings of the uterus:

1. _____
2. _____
3. _____

Q9

The walls of the fallopian tubes are composed of the same three tissue layers as the uterus except that the mucosa is _____ to propel the ovum.

Q10

What is the purpose of the fallopian tubes? _____

Q11

The regional lymph nodes which drain the fallopian tubes and the ovaries are:

1. _____
2. _____
3. _____
4. _____
5. _____

Q12

In relation to the uterus, the ovaries are located _____.

Q13

The fimbriae of the fallopian tubes cup over the ovaries but are not actually attached to them.

This is an example of a gland whose _____ is detached.

Answer: Q8

In naming the three openings of the uterus, you might have said the openings of two fallopian tubes (oviducts or uterine tubes) and the opening into the vagina (or the external os).

Answer: Q9

The walls of the fallopian tubes are composed of the same three tissue layers as the uterus except that the mucosa is ciliated to propel the ovum.

Answer: Q10

You might have said the fallopian tubes serve as ducts to carry the ova produced by the ovaries to the uterus.

Answer: Q11

The regional lymph nodes draining the fallopian tubes and the ovaries are:

- Common iliac
- Internal iliac or hypogastric or obturator
- External iliac
- Lateral sacral
- Aortic (para-, peri-, lateral)
- Inguinal (rare)

Answer: Q12

The ovaries are located on either side of the uterus below and behind the fallopian tubes.

Answer: Q13

The fimbriae of the fallopian tubes cup over the ovaries but are not actually attached to them. This is an example of a gland whose duct is detached.

Vagina

The vagina is situated posterior to the bladder and anterior to the rectum. It extends upward and backward from the vaginal orifice to the uterus. The vagina is a collapsible tube, capable of great distension, composed mostly of smooth muscle lined with a mucous membrane of stratified squamous epithelium and connective tissue (stroma) arranged in rugae¹. It is about 3 inches (7.5 cm) in length. A fold of mucous membrane, the hymen, forms a border around its external opening in the virginal state. The functions of the vagina include: 1) receiving semen from the male; 2) serving as the lower part of the birth canal; and 3) acting as the excretory duct for uterine secretions and the menstrual flow.

The region between the vaginal orifice and the anus is called the *perineum*.

Vulva

The external female genitalia (or vulva) consist of the following structures:

- The *mons pubis* (mons veneris) is a skin-covered pad of fat over the symphysis pubis (pubic bone).
- *Labia majora* (large lips) are covered with pigmented skin and hair on the outer surface, smooth and free from hair on the inner surface, and composed mainly of fat and glands.
- *Labia minora* (small lips) are located within the labia majora and are covered with a modified skin. (These labia come together anteriorly in the midline, and the area between them is called the vestibule of the vagina.)
- The *clitoris*, a small organ composed of erectile tissue located just behind the upper junction of the labia minora, corresponds in structure to the corpora cavernosa and glans of the penis in the male. The prepuce or foreskin covers the clitoris as it does the glans penis in the male.
- The urinary (urethral) meatus, the small opening of the urethra located between the clitoris and the vaginal orifice.
- The vaginal orifice, the opening into the vagina, located posterior to the urinary meatus.
- Bartholin's glands (greater vestibular glands), two bean-shaped glands, one on either side of the vaginal orifice. Each gland opens by means of a single, long duct into the space between the hymen and the labia minora and corresponds to the bulbourethral glands in the male. They secrete a lubricating fluid.
- Skene's glands (lesser vestibular glands) open into the vestibule of the vagina near the urinary meatus through two small ducts. They are a group of tiny mucous glands.

¹rugae--ridges, wrinkles, or folds of mucous membrane.

Regional Lymph Nodes

The regional lymph nodes draining the vagina are:

Upper two-thirds of vagina:

Pelvic lymph nodes:

Common iliac

Internal iliac (hypogastric, including obturator)

External iliac

Sacral promontory

Lower one-third of vagina and vulva:

Superficial Inguinal or Femoral (unilateral or bilateral)

Deep inguinal: Rosenmuller's or Cloquet's node (vulva only)

Malignant Tumors

The most common histologic type of malignant neoplasm found in the vulva and vagina is squamous cell carcinoma. The usual spread of disease from the vagina is to the cervix, vulva, rectum, and bladder. For tumors arising in the vulva, the usual spread of disease is to the vagina, urethral orifice, and perineum.

Q14

The vagina is situated between the _____, which is posterior to it, and the _____, which is anterior to it.

Q15

The vagina is a collapsible tube, the walls of which are composed of _____ lined with _____.

Q16

The female external genitalia are called the _____. Match each of its parts (on the left) with the descriptions on the right.

- | | | |
|-------|------------------------------|---|
| _____ | 1. Mons pubis (mons veneris) | a. A small organ composed of
erectile tissue |
| _____ | 2. Labia majora | b. The external opening of the vagina |
| _____ | 3. Labia minora | c. A skin-covered pad of fat over the
pubic bone |
| _____ | 4. Clitoris | d. Tiny mucous glands opening into
the vestibule near the urinary
meatus |
| _____ | 5. Urinary meatus | e. Covered with pigmented skin on
outer surface and composed
mainly of fat and glands |

- | | |
|----------------------------------|---|
| <p>___ 6. Vaginal orifice</p> | <p>f. Glands that secrete a lubricating fluid into the space between the hymen and the labia minora</p> |
| <p>___ 7. Bartholin's glands</p> | <p>g. The small opening of the urethra located between the clitoris and the vaginal orifice</p> |
| <p>___ 8. Skene's glands</p> | <p>h. Located within the labia majora and covered with modified skin.</p> |

Q17

Match the neoplasms on the left with the descriptions on the right:

- | | |
|----------------------------------|--|
| <p>___ 1. Cystadenocarcinoma</p> | <p>a. A metastatic ovarian tumor, usually a primary of the gastrointestinal tract, especially of the stomach</p> |
| <p>___ 2. Dysgerminoma</p> | <p>b. Malignant tumor derived from more than one type of germ cell and containing several tissue types</p> |
| <p>___ 3. Krukenberg tumor</p> | <p>c. An epithelial tumor that microscopically resembles a tumor of endometrial origin</p> |
| <p>___ 4. Teratocarcinoma</p> | <p>d. A tumor derived from the germ cells of the ovary comparable to seminoma of the testis in the male</p> |

- _____ 5. Endometrioid carcinoma e. An adenocarcinoma growing within a
cyst, serous or mucinous

Q18

The most common histologic type of malignant tumor found in the vulva and vagina is

_____.

For both sites, lymph node drainage is to the _____ and _____
_____ nodes.

Answer: Q14

The vagina is situated between the rectum which is posterior to it, and the bladder which is anterior to it.

Answer: Q15

The vagina is a collapsible tube, the walls of which are composed of smooth muscle lined with mucous membrane.

Answer: Q16

The female external genitalia are called the vulva. Match each of its parts (on the left) with the descriptions on the right.

<u>c</u>	1. Mons pubis (mons veneris)	A skin-covered pad of fat over the pubic bone
<u>e</u>	2. Labia majora	Covered with pigmented skin on the outer surface and composed mainly of fat and glands
<u>h</u>	3. Labia minora	Located within the labia majora and covered with modified skin.
<u>a</u>	4. Clitoris	A small organ composed of erectile tissue
<u>g</u>	5. Urinary meatus	The small opening of the urethra located between the clitoris and the vaginal orifice
<u>b</u>	6. Vaginal orifice	The external opening of the vagina
<u>f</u>	7. Bartholin's glands	Glands that secrete a lubricating fluid into the space between the hymen and the labia minora
<u>d</u>	8. Skene's glands	Tiny mucous glands opening into the vestibule near the urinary meatus

Answer: Q17

Match the neoplasms on the left with the descriptions on the right:

<u>e</u>	1. Cystadenocarcinoma	An adenocarcinoma growing within a cyst, serous or mucinous.
<u>d</u>	2. Dysgerminoma	A tumor derived from the germ cells of the ovary comparable to seminoma of the testis in the male

- a 3. Krukenberg tumor A metastatic ovarian tumor, usually a primary of the gastrointestinal tract, especially of the stomach.
- b 4. Teratocarcinoma Malignant tumor derived from more than one type of germ cell and containing several tissue types
- c 5. Endometrioid carcinoma An epithelial tumor that microscopically resembles a tumor of endometrial origin

Answer: Q18

The most common histologic type of malignant tumor found in the vulva and vagina is squamous cell carcinoma.

For both sites, lymph node drainage is to the external and internal iliac nodes.

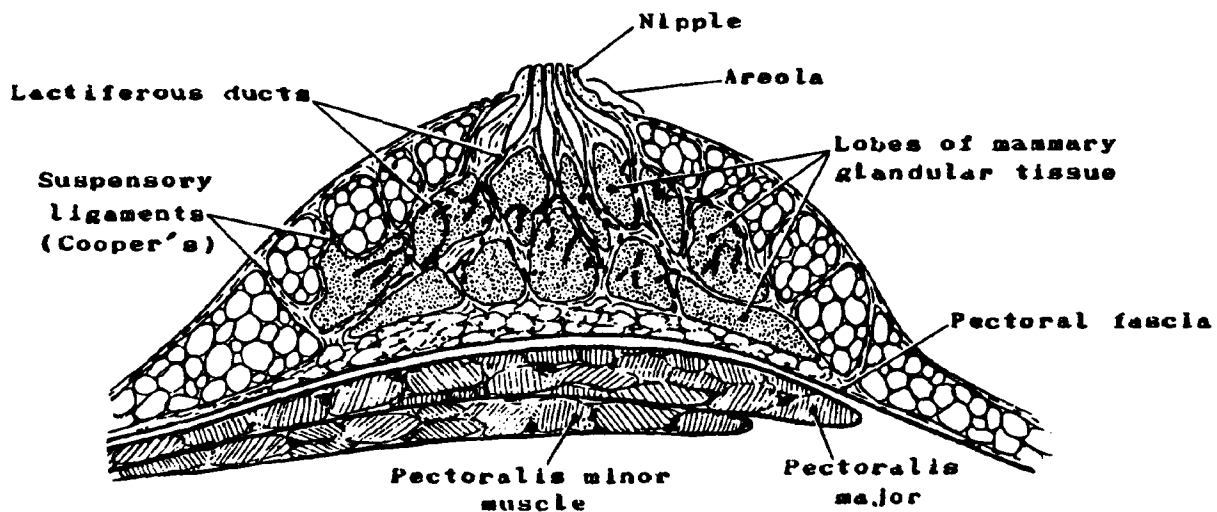
Breast

The breasts, or mammary glands, are modified sweat glands and, in some of the earlier classification systems, were grouped with the integumentary system. The breasts lie on top of the chest wall immediately over the pectoral muscles¹, pectoralis major and pectoralis minor, and are attached to the pectoralis major by a layer of connective tissue, the pectoral fascia. On the lower lateral aspect of the chest wall, the breasts are in contact with the serratus anterior muscles².

Each breast consists of many separate glands that are connected by individual ducts (lactiferous ducts) to the nipple. These glands constitute the lobes of the breast, 15 to 20 lobes (glands) for each breast. Each lobe is composed of many lobules which are formed from minute ducts and contain secreting cells (alveoli). The lobes are separated from each other by dense connective tissue and are surrounded by quantities of adipose tissue (fat). Suspensory ligaments (Cooper's ligaments) run from the corium of the skin through the breast to the fascia overlying the chest wall.

Located in the center of each breast is a nipple bordered by a circular pigmented area of skin called the areola. The lactiferous ducts from the lobes of the breast converge in the nipple. During pregnancy, hormonal changes in the body stimulate the production of milk in the lobes (mammary glands); the ducts transport the milk to the nipple.

Figure 46. BREAST (sagittal view)



¹pectoral muscles--The function of the pectoralis major muscle is to adduct, flex, and rotate the humerus inward. The pectoralis minor lies between the pectoralis major and serves to depress the tip of the shoulder and help rotate the scapula downward and forward.

²serratus anterior muscles--These muscles draw the scapula forward and rotate it to raise the tip of the shoulder.

Q19

The breasts overlie the _____ muscles.

Q20

Each breast consists of multiple glandular _____ which are further subdivided into _____ formed from minute ducts surrounded by alveoli.

Q21

The circular area bordering each nipple is called the _____.

Answer: Q19

The breasts overlie the pectoral muscles.

Answer: Q20

Each breast consists of multiple glandular lobes which are further subdivided into lobules formed from minute ducts surrounded by alveoli.

Answer: Q21

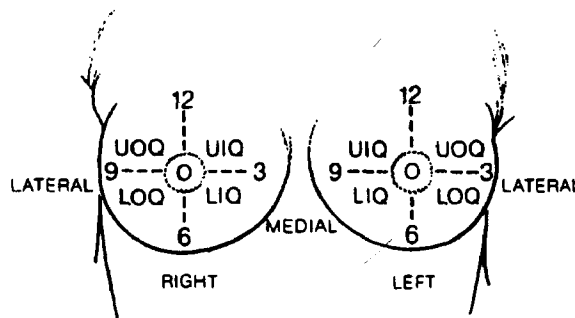
The circular area bordering each nipple is called the areola.

The female breast is classified according to the following subsites in ICD-O:

- Nipple/areola C50.0
- Central portion (subareolar, retroareolar) C50.1
- Upper-inner quadrant (UIQ) C50.2
- Lower-inner quadrant (LIQ) C50.3
- Upper-outer quadrant (UOQ) C50.4
- Lower-outer quadrant (LOQ) C50.5
- Axillary tail C50.6
- Inner/outer/lower/upper breast, midline C50.8

You will sometimes find the location described in terms of hours on the clock; it is important to note that this designation will be different for the inner and outer quadrants of the right and left breast.

Figure 47. QUADRANTS OF THE BREAST



One shortcoming of our present classification system is that *midline tumors*, tumors at 3, 6, 9, and 12 o'clock, are grouped in a single category (C50.8) in ICD-0, and thus lose their identification. Since a substantial number of tumors arise in these locations, we may be obscuring useful information by including all of them in code C50.8. Medial lesions, for instance, have a poorer prognosis because of their potential for metastasis to the internal mammary nodes.

A tumor specified as "subareolar" is coded to the central portion of the breast (C50.1) indicating that the tumor is located directly under the nipple.

Extending outward from the nipple and areola and covering the entire surface of the breast is a layer of skin. Skin changes are significant in the clinical evaluation of breast cancer and indicate involvement of parenchymal tissue as well as invasion of the skin itself. Changes such as dimpling, tethering, and nipple retraction are presumed to be due to tension on Cooper's ligaments and not to actual skin involvement; adherence, attachment, fixation, induration, and thickening are usually due to extension of tumor to the skin or subcutaneous tissue. Edema, peau d'orange,¹ en cuirasse,² and ulceration clinically indicate extensive skin involvement.

The blood supply to the breast is from both the internal thoracic (subclavian) and the lateral thoracic (axillary) arteries. The veins form both superficial and deep plexuses and correspond in general to the arterial pattern.

Regional Lymph Nodes

The lymph nodes of the breast may be divided into the following categories:

Axillary lymph nodes (ipsilateral)

Low axillary (Level I): area adjacent to the tail of the breast

Mid axillary (Level II): central, interpectoral (Rotter's node)

High axillary (Level III): apex of the axilla including those designated as subclavicular, infraclavicular, and apical nodes

Internal mammary (parasternal) lymph nodes (ipsilateral): in the intercostal spaces along the edge of the sternum in the endothoracic fascia

Nodules of cancer cells found in the axillary fat which are not specifically identified as lymph nodes are considered to be nodes which have lost their architectural configuration or to be intransit metastases in the lymphatics.

Contralateral or bilateral involvement of any of the above lymph nodes is considered distant lymph node metastasis.

All other lymph node metastases are coded as distant metastases, including any supraclavicular, scalene, and cervical lymph nodes.

¹peau d'orange--a dimpled skin condition resembling the skin of an orange.

²en cuirasse--an inflammatory process in which skin involvement resembles armor plate.

Q22

One of the first and most frequent areas of nodal metastasis in breast cancer patients is the _____ lymph nodes.

Q23

Match the axillary lymph node levels on the left with the descriptions on the right.

- | | | |
|-----|---------|--|
| ___ | 1. Low | a. Area next to the tail of the breast |
| ___ | 2. Mid | b. Apex of the axilla |
| ___ | 3. High | c. Area under the pectoralis minor muscles |

Q24

What are the most frequently involved distant lymph nodes for breast cancer?

Answer: Q22

One of the first and most frequent areas of nodal metastasis in breast cancer patients is the axillary lymph nodes.

Answer: Q23

- | | | |
|----------|---------|---|
| <u>a</u> | 1. Low | Area adjacent to the tail of the breast |
| <u>c</u> | 2. Mid | Area under the pectoralis minor muscles |
| <u>b</u> | 3. High | Apex of the axilla |

Answer: Q24

The most frequently involved distant lymph nodes for breast cancer are the supraclavicular (transverse cervical) lymph nodes.

Malignant Tumors

Ninety percent of all breast cancers arise from the glandular epithelial lining of the ducts. Thus, most tumors are intraductal in origin. The epithelium is supported by a basement membrane and an incomplete layer of myoepithelial cells. Invasion takes place when the tumor penetrates the basement membrane of the duct and grows into the supporting stroma. The histologic types of tumors generally described are:

- *Intraductal (adeno)carcinoma*, is a noninfiltrating or in situ lesion.
- *Ductal (duct cell) (adeno)carcinoma* is a general term denoting an infiltrating tumor of ductal origin.
- *Medullary (adeno)carcinoma* is a well-differentiated tumor of epithelial origin which will often have evidence of lymphoid infiltration in the stroma.
- *Mucinous (adeno) carcinoma* is a mucin-producing tumor which may have a gelatinous or colloid (glue-like) appearance when sufficient amounts of mucin are present.
- *Lobular (adeno) carcinoma* arises in the lobules of the breast as the name implies. It is most often diagnosed in situ but will eventually invade the parenchyma. Multiple foci are frequently found including foci in both breasts.
- *Inflammatory carcinoma* is a clinical term used to describe a condition in which there is diffuse involvement of the breast, particularly of the skin, causing widespread erythema, edema, and discoloration. It is generally inoperable and has a poor prognosis.
- *Scirrhou (adeno) carcinoma* is a tumor of ductal epithelial origin in which fibrous connective tissue has formed giving it a hard consistency.
- *Paget's disease* presents as a weeping eczematoid lesion of the nipple and areola. It occurs as the result of nipple invasion from an underlying ductal carcinoma. The presence of Paget's disease does not alter the staging of the original tumor.
- *Cystosarcoma phyllodes*, also known as cellular intracanalicular fibroma, is usually a benign disease contrary to the inclusion of "sarcoma" in the name of this tumor. It is one of the rare stromal tumors of the breast and, although it may become very large, cystic, and hemorrhagic, it only infrequently becomes invasive.

REVIEW TEST

Match the descriptions on the left with the organs on the right:

- | | | |
|-----|--|---------------------|
| ___ | 1. Gonads in the female | a. Perineum |
| ___ | 2. Muscular layer of the uterus | b. Cul de sac |
| ___ | 3. Fringe bordering opening of the fallopian tube | c. Myometrium |
| ___ | 4. Area between the vagina and anus | d. Ovaries |
| ___ | 5. External genitalia of female | e. Fallopian tubes |
| ___ | 6. Ducts through which the ova travel into the uterus | f. Female genitalia |
| ___ | 7. Region of abdominal cavity midway between the rectum and uterus | g. Vulva |
| | | h. Fimbria |

ANSWERS TO REVIEW TEST

<u>d</u>	1.	Gonads in the female	Ovaries
<u>c</u>	2.	Muscular layer of the uterus	Myometrium
<u>h</u>	3.	Fringe bordering opening of the fallopian tube	Fimbria
<u>a</u>	4.	Area between the vagina and anus	Perineum
<u>g</u>	5.	External genitalia of female	Vulva
<u>e</u>	6.	Ducts through which the ova travel into the uterus	Fallopian tubes
<u>b</u>	7.	Region of abdominal cavity midway between the rectum and uterus	Cul de sac

Male Reproductive System

The male reproductive system, like that of the female, consists of those organs whose function is to produce a new individual, i.e., to accomplish reproduction. This system consists of a pair of testes and a network of excretory ducts (epididymis, ductus deferens (vas deferens), and ejaculatory ducts), seminal vesicles, the prostate, the bulbourethral glands, and the penis.

Scrotum

The scrotum is a skin-covered pouch of muscle and fascia suspended on the outside of the body. It is one of the supporting structures of the male reproductive system. The scrotum is divided internally into two (left and right) sacs by a septum (partition) so that each sac contains a testis, epididymis, and the lower part of the spermatic cord.

Testes

The testes are two small ovoid glands, male gonads, which lie in the scrotum. These glands are not developed within the scrotal sac, but descend from the abdominal cavity during fetal development. A thick fibrous capsule (tunica albuginea) encases each testis, extensions of which (septa) partition the interior into lobules. Each lobule contains tiny coiled seminiferous tubules and many interstitial (Leydig) cells which lie between the seminiferous cells. The interstitial cells are glandular cells that produce the hormone testosterone.

The primary functions of the testes are:

- Production of male reproductive cells by the seminiferous tubes (spermatozoa or sperm)
- Secretion of hormones, mainly testosterone, by the interstitial cells of Leydig.

Testosterone is an androgen secreted by the Leydig cells of the testicle. Testosterone is responsible for the development of male secondary sex characteristics and genital growth; it also influences the retention of nitrogen, potassium, phosphorous, and calcium, required for building protoplasm. Androgens also have important growth-regulating functions.

Regional nodes for the testis are found on page 322.

Q25

The male gonads consist of a pair of _____ enclosed in a sac called the _____ lying outside of the body cavity.

Q26

A major hormone secreted by the interstitial cells of the testes is _____. It is responsible for the development of the male sex characteristics.

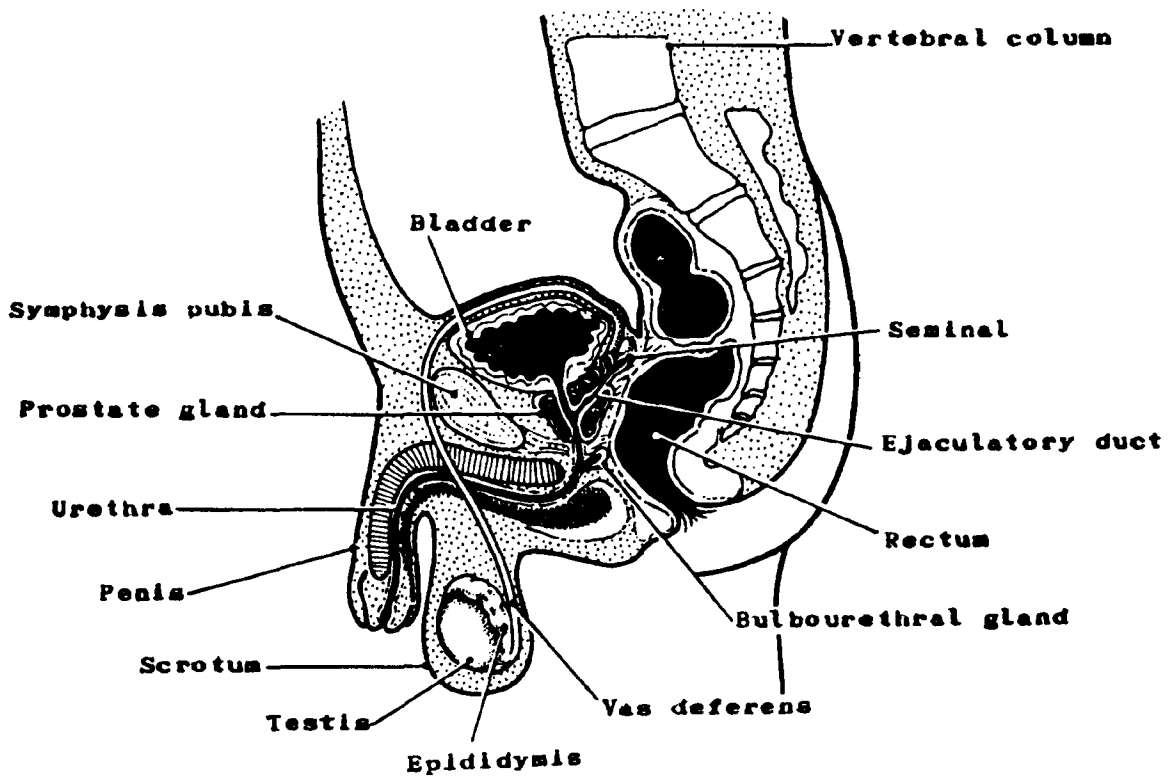
Answer: Q25

The male gonads consist of a pair of testes enclosed in a sac called the scrotum lying outside of the body cavity.

Answer: Q26

A major hormone secreted by the interstitial cells of the testes is testosterone. It is responsible for the development of the male sex characteristics.

Figure 48. MALE PELVIS (sagittal view)



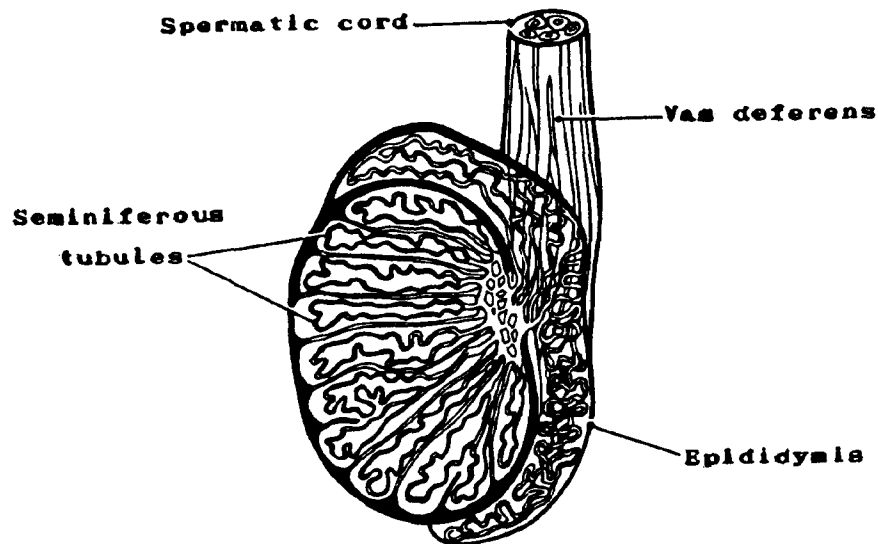
The internal structure of the testis is composed of *seminiferous tubules*. The seminiferous tubules are narrow, coiled tubules located within the lobules of the testis and composed of parenchymal tissue. Thus, these tubules perform the essential, active work of the organ, that is, *production of the sperm cells* by two types of cells: 1) the spermatogenic cells and 2) the Sertoli cells which support and protect the developing sperm cells and may even contribute to their nourishment. The Sertoli cells are resistant to heat, radiation, and other agents that prove toxic to germ cells.

Epididymis. Each epididymis consists of a single coiled tube or duct encased in a fibrous covering. It is about 20 feet long with a very small diameter and lies along the top and side of the testis. The *sperm cells* are temporarily *stored* in the epididymis after leaving the testis.

Vas deferens. The vas deferens (seminal duct or ductus deferens) is really an extension of the epididymis. It carries sperm from the epididymis to the urethra. The vas deferens passes from the scrotal sac through the opening of the pelvic body wall called the *inguinal canal* and into the pelvic cavity. There it extends over the top and down the posterior surface of the bladder where it joins the duct from the seminal vesicle on each side to form the *ejaculatory ducts*. These short tubes, the ejaculatory ducts, pass through the prostate gland and terminate in the prostatic portion of the urethra.

The aggregate of vas deferens and associated blood vessels, lymphatics, and nerves is bound within a connective tissue sheath called the *spermatic cord*.

Figure 49. TESTIS (sagittal view)



Q29

Match the structures on the left with its function on the right.

- | | | | |
|-----|-------------------------|----|--|
| ___ | 1. Epididymis | a. | Narrow tubes which carry sperm from the epididymis to the urethra |
| ___ | 2. Vas deferens | b. | Narrow, coiled tubules in the testes which produce sperm |
| ___ | 3. Seminiferous tubules | c. | Tube located on top of each testis which carries and stores sperm before they enter the vas deferens |

Q28

The _____ are the parenchymal (essential) tissue of the testes because they produce the sperm.

Answer: Q27

- | | | |
|----------|-------------------------|--|
| <u>c</u> | 1. Epididymis | Tube located on top of each testis which carries and stores sperm before they enter the vas deferens |
| <u>a</u> | 2. Vas deferens | Narrow tubes which carry sperm from the epididymis to the urethra |
| <u>b</u> | 3. Seminiferous tubules | Narrow, coiled tubules in the testes which produce sperm |

Answer: Q28

The seminiferous tubules are the parenchymal (essential) tissue of the testes because they produce the sperm.

Seminal Vesicles

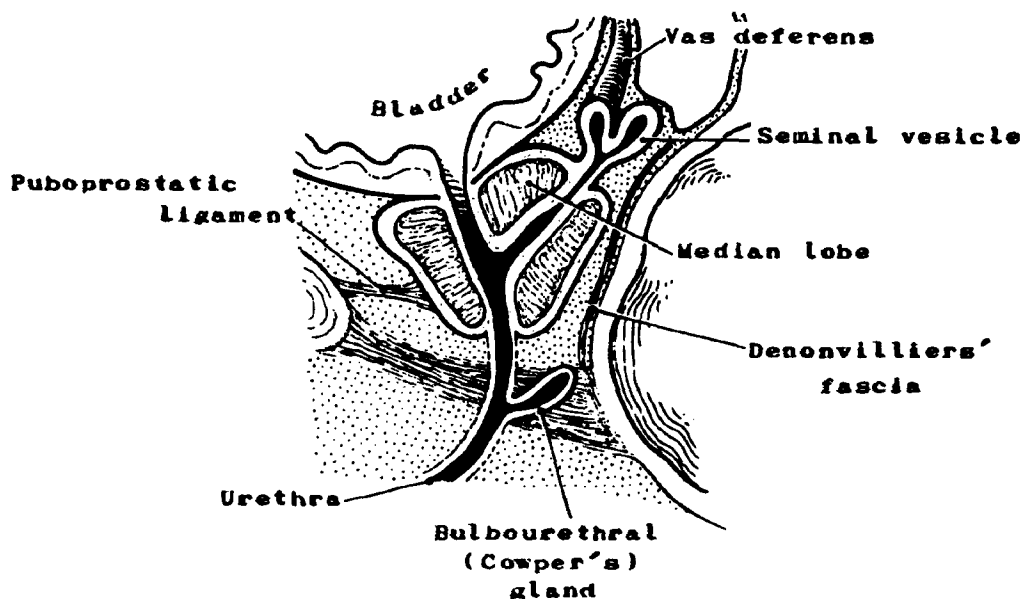
The seminal vesicles are two glands located on the posterior surface of the urinary bladder between the bladder and the rectum. They secrete a substance that *nourishes the sperm cells*. Approximately 30 percent of the semen is composed of the secretion produced by the seminal vesicles.

Prostate Gland

The prostate gland is located on the inferior surface of the urinary bladder encompassing the prostatic portion of the urethra. It lies behind the symphysis pubis (to which it is connected by the puboprostatic ligament), above the urogenital diaphragm (pelvic floor), and in front of the rectum. It is separated from the rectum by Denovilliers' fascia¹. The adult prostate weighs about 20 grams and is typically divided into three lobes: the right and left lateral lobes and the middle lobe. These lobes consist of alveoli lined with columnar epithelium encased in a thin capsule of connective tissue and embedded in a thick fibromuscular stroma. The prostate secretes an alkaline substance which constitutes the largest part (60 percent) of the seminal fluid. This establishes a suitable pH environment for sperm reaching the vagina and protects the ejaculated semen from mechanical damage. The seminal fluid is drained from the navel by a system of branching ducts which open into the prostatic portion of the urethra.

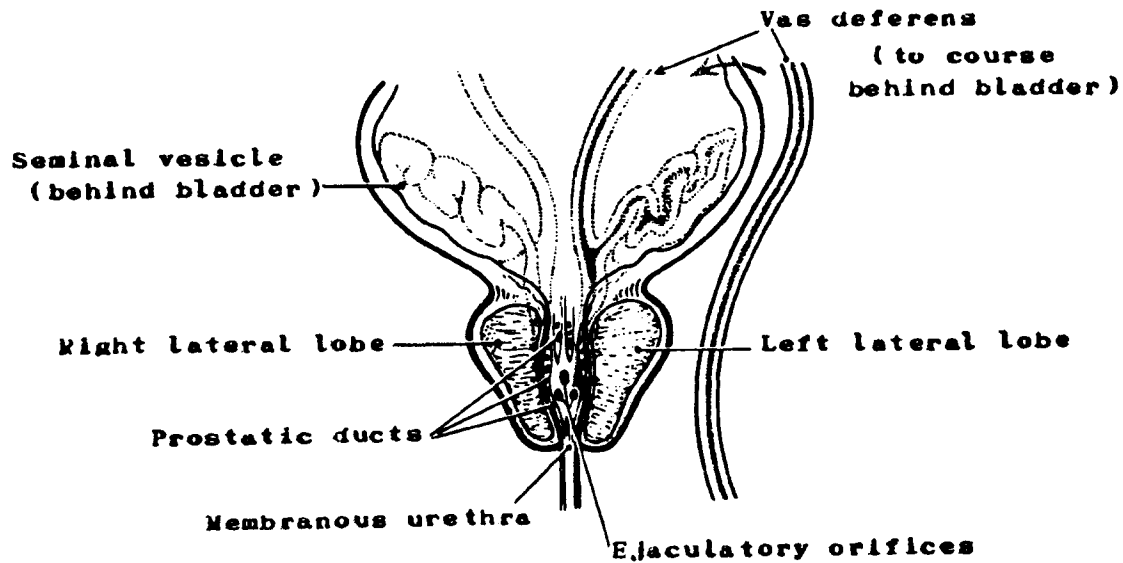
Acid phosphatase is present in the prostatic secretions. Patients with prostatic carcinoma which is still confined within the prostatic capsule usually have a normal serum acid phosphatase level. However, elevated serum levels are seen in patients with carcinoma of the prostate that has extended beyond the prostatic capsule. Acid phosphatase determination is used diagnostically to help determine the spread of the disease. See page 116 of Book 5 for normal values.

Figure 50. PROSTATE GLAND (sagittal view)



¹Denovilliers' fascia--a portion of the rectovesical fascia between the rectum and prostate gland.

Figure 51. PROSTATE GLAND (frontal view)



Relationship of Prostatic Hypertrophy, Hyperplasia, and Prostatic Cancer

Hypertrophy means an increase in size of the prostate due to the increase in the *size* of the individual cells. In contrast, hyperplasia means an increase in the size of the prostate due to an increase in the *number* of its cells.

Benign prostatic hypertrophy (enlargement of the prostate) is very common in elderly men. Its exact etiology is not known, although there is some evidence to show that part of it is hormonally mandated. Benign prostatic hypertrophy increases with age as does prostatic cancer; and both require testosterone to grow and divide. In general, prostatic cancer originates in the periphery of the prostate where benign prostatic hypertrophy occurs. That is why it is possible for the physician to palpate these tumors via the rectum. A clinical diagnosis of benign prostatic hypertrophy may be made when a man has symptoms of prostatic disease. Then a TUR is done, and only then may a diagnosis of cancer be made based on the increase in the number of cells, hyperplasia.

Bulbourethral (Cowper's) Glands

The Cowper's glands are located below the prostate on either side of the membranous urethra. They resemble peas in both size and shape. A duct about 2.5 cm long connects each of them with the urethra. Cowper's glands, like the prostate, secrete an alkaline, mucous fluid which makes up about 5 percent of the semen. These glands are also supplied with muscular tissue which aids in expulsion of sperm during ejaculation.

Q29

Match the structures on the left with the descriptions on the right

- | | | |
|-----|---------------------|--|
| ___ | 1. Prostate | a. Glands which nourish sperm cells by their secretions |
| ___ | 2. Bulbourethral | b. Gland which secretes an alkaline substance (60 percent of seminal fluid) providing protective environment for sperm |
| ___ | 3. Seminal vesicles | c. Glands which aid in ejaculation because of their muscular tissue |

Answer: Q29

- | | | | |
|----------|----|------------------|---|
| <u>b</u> | 1. | Prostate | Gland which secretes an alkaline substance (60 percent of seminal fluid) providing protective environment for sperm |
| <u>c</u> | 2. | Bulbourethral | Glands which aid in ejaculation because of their muscular tissue |
| <u>a</u> | 3. | Seminal vesicles | Glands which nourish sperm cells by their secretions |

Penis

The penis consists of erectile and connective tissue sheathed in skin. There are three distinct bands of the erectile tissue within the penis: The two *corpora cavernosa* and the single *corpus spongiosum*. At the distal end is the *glans penis* over which there is a double fold of skin called the prepuce or foreskin. The penis contains the penile (spongy or cavernous) segment of the urethra which is the terminal duct for both the urinary and the reproductive tracts in the male.

The penile blood supply is from the internal iliac and femoral arteries by way of the pudendal arteries. Blood drains to the internal iliac veins. During erection, the blood vessels of the penis undergo a change; the arteries become dilated and the veins constricted.

The penis serves two purposes:

- An excretory organ for liquid wastes
- The male copulatory organ

Regional Lymph Nodes

The regional lymph node drainage for the prostate is:

- Periprostatic
- Internal iliac: (hypogastric, including obturator)
- External iliac
- Sacral (lateral, presacral, promontory (Gerota's))

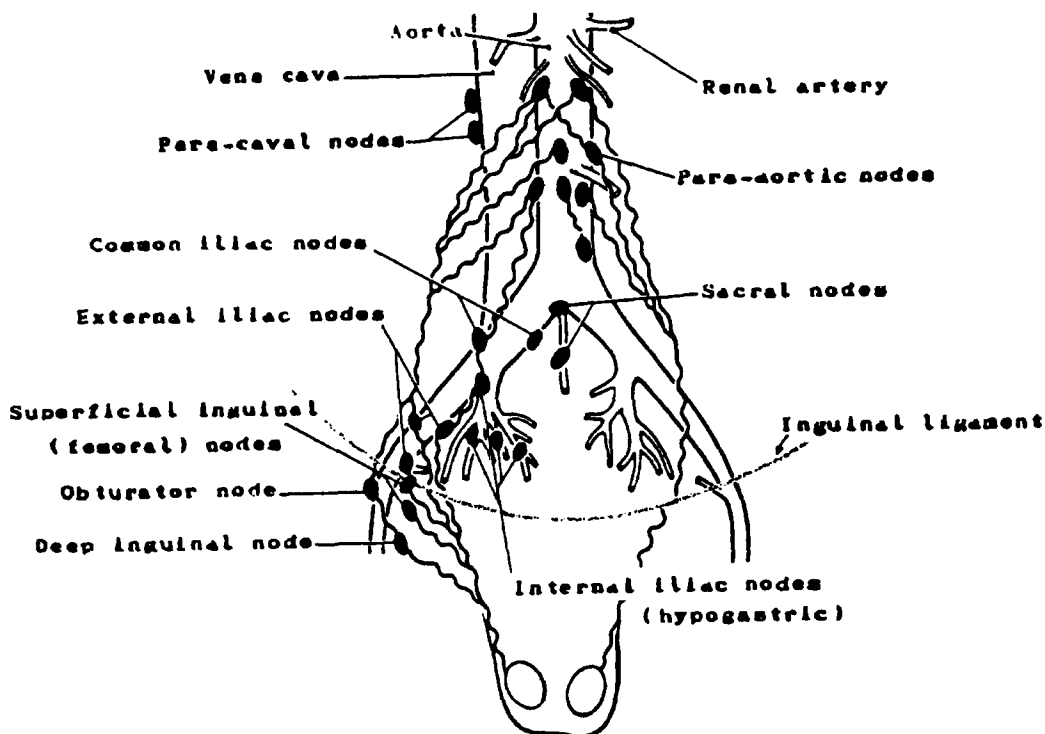
The regional lymph node drainage for the testis is:

- Paracaval
- Aortic (para-, peri-, lateral)
- External iliac (intrapelvic)

The regional lymph node drainage for the penis is:

- External iliac
- Internal iliac (hypogastric)
- Superficial inguinal (femoral)
- Deep inguinal: Rosenmuller's or Cloquet's node

Figure 52. LYMPHATIC DRAINAGE OF THE PROSTATE AND TESTES



Malignant Tumors

The most common malignant neoplasms which occur in the male reproductive systems are as follows:

- Adenocarcinoma of the prostate gland, diagnosed primarily in men over 65 years of age.
- Testicular tumors occurring primarily in young men. The classification of testicular tumors is highly controversial and complicated by the frequent occurrence of tumors of mixed cell types. Tumors arising in the germinal epithelium (germ cell types) account for 97 percent of testicular tumors. The most frequent histologic types are as follows:

Seminoma is the most common testicular tumor. It also has the best prognosis as it is slow to spread. Foci of the more malignant types of germ cell tumors, embryonal carcinoma and choriocarcinoma, may be found in the seminoma. Then the prognosis is similar to the more malignant tumor rather than to the pure seminoma. Variants of seminoma are the anaplastic type of seminoma and the spermatocytic seminoma, both of which are rare.

Teratocarcinoma or malignant teratoma is the second most common testicular tumor. Teratomas are tumors of germ cell origin composed of embryonic tissue which is differentiated into bone, hair, teeth, cartilage, and skin. All these types of tissues may be found in the tumor.

Embryonal carcinoma is a more infiltrative type of testicular tumor and consequently has a poorer prognosis. It arises from the primitive or multipotential cells of the germinal epithelium and occurs in a variety of cellular patterns.

Choriocarcinoma (chorioepithelioma) is a rare tumor in its pure form although foci of choriocarcinoma may be found in any of the other germinal tumors. It is highly malignant and metastasizes rapidly. It is derived from primitive cells differentiating as trophoblastic cells¹. High levels of gonadotropin hormone may be found in the urine with the tumor.

Nongerminial tumors of the testes are extremely rare. Tumors arising in the gonadal stroma include: interstitial cell (Leydig cell) tumors and Sertoli cell tumors. These tumors are seldom malignant.

¹trophoblastic cells--pertaining to the layer of extraembryonic ectodermal tissue which covers the embryo.

Q30

Male hormones are produced primarily in the _____.

Q31

Which of the following are regional nodes for the prostate? (Check as appropriate.)

- 1. Aortic (para-, peri-, lateral)
- 2. Internal iliac (hypogastric)
- 3. Sacral
- 4. External iliac
- 5. Periprostatic

Q32

Which of the following are regional nodes for the testes?

- 1. Portal
- 2. Aortic (para-, peri-, lateral)
- 3. External iliac
- 4. Inguinal
- 5. Internal iliac (hypogastric)

Answer: Q30

Male hormones are produced primarily in the testes (or in the interstitial cells of Leydig of the testes).

Answer: Q31

The regional nodes for the prostate are:

2 Internal iliac (hypogastric)

3 Sacral

4 External iliac

5 Periprostatic

Answer: Q31

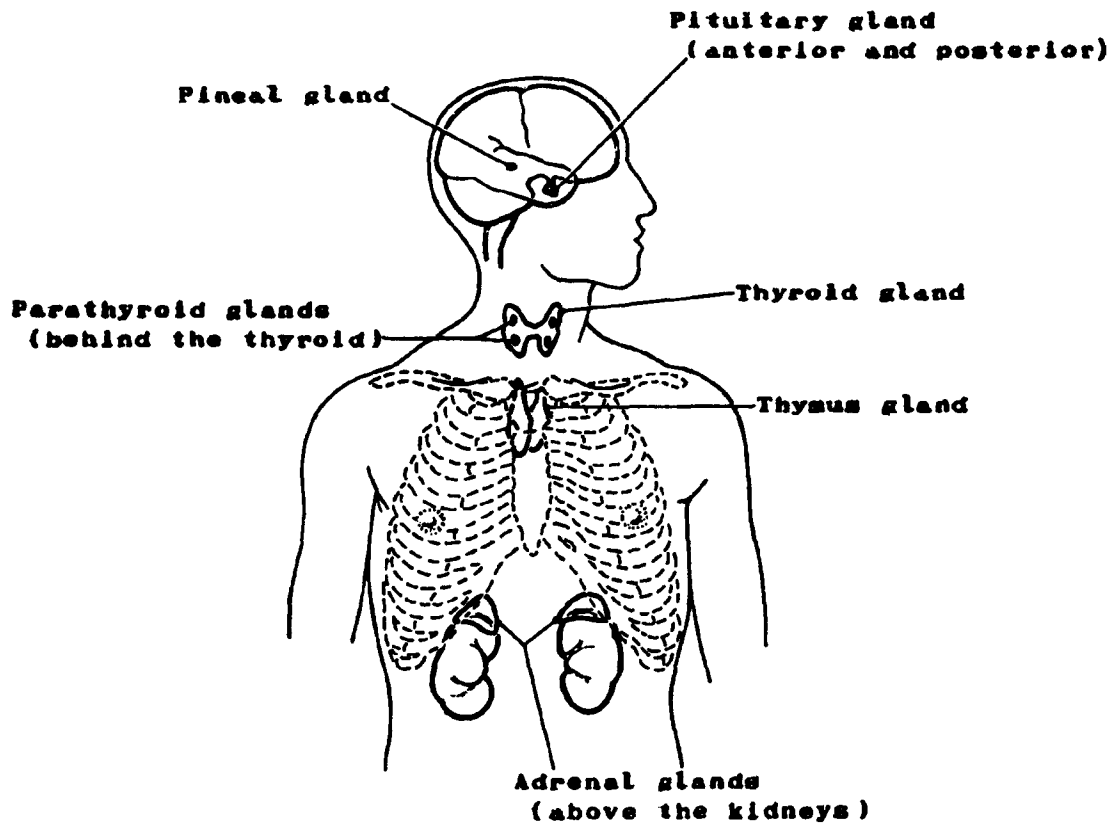
The regional nodes for the testes are:

2 Aortic (para-, peri-, lateral)

3 External iliac

SECTION J
THE ENDOCRINE SYSTEM

Figure 53. ENDOCRINE GLANDS



SECTION J

THE ENDOCRINE SYSTEM

The endocrine system is comprised of ductless glands which manufacture and release specific organic secretions called hormones directly into the bloodstream to be carried to various parts of the body where they perform their particular functions. The individual glands are located in widely separated parts of the body and form a system only from a functional point of view. In contrast, the exocrine glands, such as the tear, digestive, and sweat glands release their secretions into ducts leading to the body cavities or outside the body as appropriate. (You may wish to review the pancreas, ovary, and testis which are also part of the endocrine system.)

The islets of Langerhans of the pancreas are part of the endocrine system and have already been described under the digestive system. The endocrine functions of the ovaries and testes were described under the reproductive system. The remaining endocrine glands and their distinct functions as well as their interesting relationships with each other are described below.

Pituitary Gland (Hypophysis)

The pituitary gland (hypophysis) is controlled by the hypothalamus of the brain and links the nervous system to the endocrine system. Located at the base of the brain behind the eyes in the sella turcica of the sphenoid bone, the pituitary is only the size of a pea. It is referred to as the master gland since it controls all secretions of hormones within the body. The pituitary gland has two lobes, the anterior lobe (the adenohypophysis) and the posterior lobe of the neurohypophysis). Each lobe has definite functions.

The anterior lobe is responsible for producing at least the following hormones:

- Adrenocorticotrophic hormone: ACTH controls the development and secretory activity of the adrenal cortex for secretion of the glucocorticoids (primarily cortisol).
- Thyrotrophic (thyroid-stimulating) hormone: TSH stimulates the growth and development of the thyroid gland and stimulates it to secrete thyroxin and triiodothyronine (together called thyroid hormone).
- Follicle-stimulating hormone: FSH stimulates the development of ovarian follicles which secrete estrogen in the female. In the male, FSH stimulates the development of the seminiferous tubules and promotes spermatogenesis.
- Male gonadotrophic hormone (interstitial cell-stimulating hormone): ICSH stimulates the development of the interstitial cells (cells of Leydig) of the testes and the secretion of testosterone.
- Female luteinizing hormone: LH stimulates the secretion of progesterone by the corpus luteum in the ovaries.
- Growth or somatotrophic hormone: GH or STH accelerates growth of bone, muscle, kidney, liver, and adipose tissues.

- Prolactin (luteotrophic hormone): LTH is concerned with initialization and maintenance of lactation in the mammary glands. LH stimulates the ovary to release the developed ovum and prepares the uterus for implantation of a fertilized ovum. It also stimulates formation of the corpus luteum in the ovary, which secretes progesterone and readies the mammary glands for milk secretion.
- Melanocyte-stimulating hormones: MSH and ACTH are thought to produce increased pigmentation of the skin.

The function of the posterior lobe of the pituitary is to produce the following:

- Oxytocin (pitocin) which stimulates the uterine muscles to contract during childbirth and causes the secretion of milk in lactating breasts.
- Antidiuretic hormone (vasopressin) (ADH) which has several effects on the body:

It has an antidiuretic effect stimulating the reabsorption of water by the kidney tubules.

It is thought to have a pressor effect increasing blood pressure by constriction of the arterioles.

It also is believed to have an effect on the smooth muscle of the intestinal tract.

Tumors

Tumors of the pituitary are almost always benign; malignant tumors are rare. These benign tumors may produce hormonal changes in the body or may simulate the symptoms of a brain tumor.

- *Adenomas*, representing about three-fourths of the pituitary tumors, are of three main types: acidophilic (eosinophilic), basophilic, and chromophobe.
- *Craniopharyngioma* (Rathke's pouch tumor) arises along the craniopharyngeal duct and is benign.

Thyroid Gland

The thyroid gland consists of two lateral lobes united by a strip of glandular tissue called the isthmus. It is covered by two capsules: an inner capsule of fibroelastic tissue and an outer capsule continuous with and part of the deep cervical fascia. The thyroid is located on either side of the trachea just below the thyroid cartilage. The unit structure of the thyroid gland is the follicle. A thin, continuous basal membrane surrounds each follicle. Between the follicles are capillaries, fibroblasts, and small bundles of collagenous fibers. This gland produces the hormones thyroxin and tri-iodothyronine which are necessary to maintain a normal level of metabolism in all body cells. These hormones are synthesized in the thyroid gland from iodine. Another hormone produced by the thyroid gland is thyrocalcitonin which aids in maintaining the proper level of calcium in the blood. In summary, the main physiological actions of this gland are to assist in regulating the metabolic rate in concert with growth and tissue regulation.

Lymphatic drainage is to cervical and mediastinal nodes:

Delphian node

Anterior cervical: prelaryngeal, pretracheal, laterotracheal (recurrent laryngeal nerve chain)

Internal jugular: jugulodigastric and jugulo-omohyoid

Tracheoesophageal

Mediastinal, upper anterior and posterior (tracheoesophageal)

Retropharyngeal

Tumors

Malignant tumors of the thyroid are primarily of two main types:

- *Papillary adenocarcinoma* is the most common thyroid cancer. It is generally well differentiated and characterized by well-defined papillary fronds. Spread is usually via the lymphatics to the cervical lymph nodes. Prognosis is good following excision of the involved lobe(s). Lymph node dissection may be deferred until there is clinical evidence of nodal involvement.
- *Follicular adenocarcinoma* is the second most common type of thyroid malignancy. It has well-developed follicles resembling normal thyroid tissue. Dissemination is usually via the blood stream to distant sites.

Mixed papillary and follicular carcinoma is common. It behaves like papillary carcinoma.

- *Medullary carcinoma* with amyloid stroma is a rare tumor.
- *Anaplastic carcinoma* is also rare; it occurs predominantly in older patients.

The most common benign tumor of the thyroid is the adenoma of which there are several types, such as: papillary, follicular, colloid, fetal, and Hurthle cell. These benign tumors are not generally included in the cancer registry unless they are of special interest to the medical staff.

Parathyroid Gland

There are four parathyroid glands located immediately behind the thyroid gland beneath its outer capsule. There is, however, little correlation between the functions of the thyroid and the parathyroids. Although each parathyroid is only about the size of a grain of rice, its function is essential to life.

The chief cells of the parathyroid secrete a hormone, parathormone, which maintains the normal phosphorous and calcium levels in the body. Parathormone controls the excretion of phosphorus in the kidney and also mobilizes calcium and phosphorus in bone. It also increases the absorption of calcium from the intestinal tract when necessary.

An excess of parathormone may cause Recklinghausen's disease of the bone (osteitis fibrosa cystica). Excessive parathormone draws calcium from the bone and raises this level in the blood. Pathological fractures may result.

Tumors of the parathyroid are extremely rare; most are benign adenomas.

Pineal Gland

The pineal gland (epiphysis) is located in the brain attached to the roof of the third ventricle (epithalamus). It secretes the hormone melatonin, which contributes to the process of skin pigmentation, and is thought to secrete serotonin and adrenoglomerulotropin. Although its true functions remain a mystery, it is also believed to serve as a "biological clock."

Tumors of the pineal gland are called pinealomas and are usually benign. Since these tumors are located in the brain, you may be requested to include them in the registry together with benign brain tumors.

Figure 54. THYROID AND PARATHYROID GLANDS

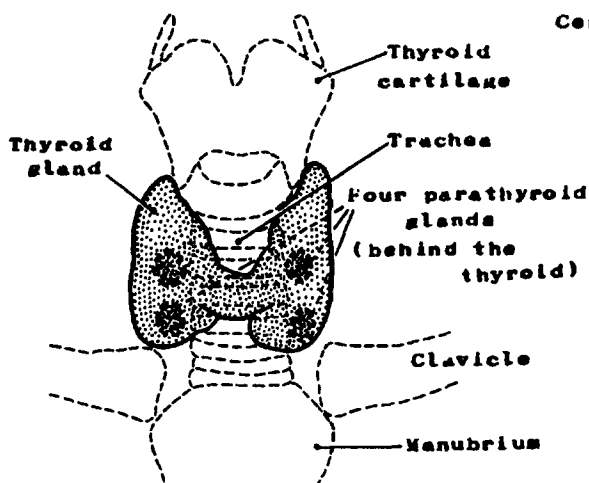
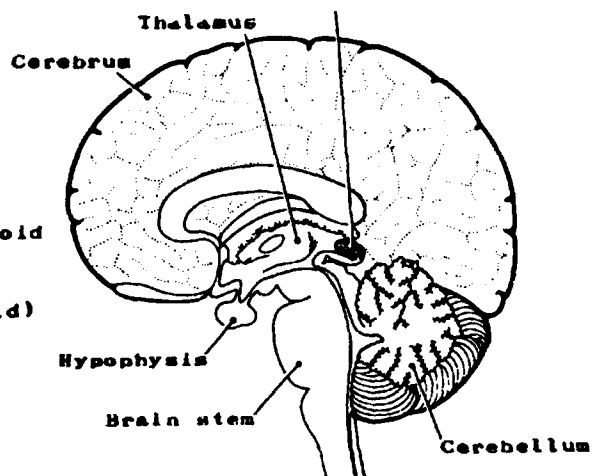


Figure 55. PINEAL GLAND



Adrenal (Suprarenal) Glands

There are two adrenal (suprarenal) glands, about the size of the last digit of the little finger, each paired with and located on top of a kidney and behind the peritoneum. Each adrenal gland consists of two parts, an inner medulla and an outer cortex.

- The adrenal *medulla* secretes hormones called catecholamines, i.e., epinephrine and norepinephrine. These are hormones produced by stress and were once referred to only as adrenalin.

Epinephrine (adrenalin) increases heart rate and cardiac activity, dilates the bronchial tubes, and stimulates the production of glucose from glycogen.

Norepinephrine (acetylcholine) constricts blood vessels and raises blood pressure.

- The adrenal *cortex* secretes hormones called steroids. Some of the more important ones are:

Aldosterone, a mineralocorticoid, promotes sodium retention and potassium loss in the urine and vice versa as needed to balance the body fluids.

Cortisol increases the ability of the cells to make new sugars out of fats and proteins. (Cortisone is a hormone similar to cortisol but is produced synthetically.)

Androgens, estrogens, and progestin (male and female hormones) are secreted by the adrenal cortex in small amounts. They promote normal development of bones and reproductive organs.

Tumors

Adrenal tumors may be divided into those arising from the cortical cells and those from the medullary cells of the glands.

- *Neuroblastoma*, which arises in the medulla, is the most common malignant tumor of the adrenal gland. It is found most frequently in children and young adults and is, in fact, one of the most common childhood tumors. Neuroblastomas can also arise from neural tissue elsewhere in the body.
- *Pheochromocytoma* and *ganglioneuroma* are benign, rarely malignant, tumors of the adrenal medulla.
- *Adrenal cortical adenocarcinoma* arises in the adrenal cortex. Its benign counterpart is the cortical adenoma.

Thymus Gland

The thymus gland is located behind the sternum in the mediastinum. It is large in childhood, but shrinks in adults. Its structure is lymphoepithelial. It is a source of lymphocytes. T lymphocytes mature in the thymus and are involved in cell-mediated immunity, that is, the cells themselves mediate the immune effect. The thymus is also included in the section on the Lymphatic System.

Tumors of the thymus, *thymomas*, are rare and most often benign. As a lymphoid organ, the thymus may be primarily or secondarily involved in lymphomas of the mediastinum.

The condition of myasthenia gravis, which is characterized by muscular weakness and fatigue, may be associated with tumors of the thymus.

Other Hormone Producers

The stomach wall secretes a hormone called *gastrin* which stimulates the blood vessels and secretions of the stomach glands.

The upper part of the small intestine secretes a hormone called *secretin* which stimulates the pancreas and causes the gallbladder to contract.

The placenta produces *chorionic gonadotropic hormones* which help to maintain pregnancy.

Figure 56. ADRENAL GLAND

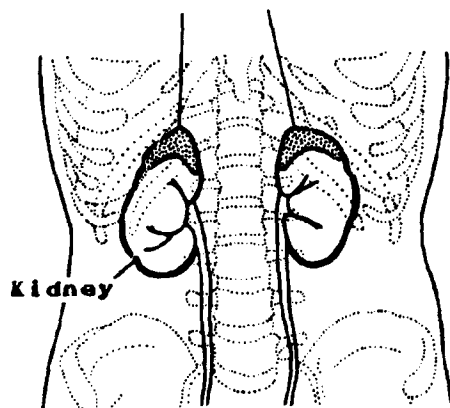
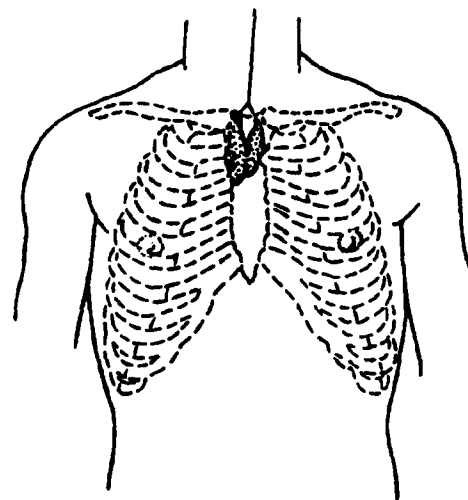


Figure 57. THYMUS GLAND



Q1

Match the terms on the left with the descriptions on the right.

- | | | | |
|-----|---------------------|----|--|
| ___ | 1. Hormones | a. | An endocrine gland which lies at the base of the brain; the pituitary |
| ___ | 2. Hypophysis | b. | Ductless glands which secrete substances into the bloodstream |
| ___ | 3. Exocrine glands | c. | A narrow strip of tissue connecting two parts |
| ___ | 4. Isthmus | d. | Organic secretions originating in a ductless gland and conveyed to another part of the body by the bloodstream |
| ___ | 5. Endocrine glands | e. | Glands which secrete substances through ducts in the body surfaces or into body cavities |
| ___ | 6. Steroids | f. | Hormones produced by the adrenal cortex, such as aldosterone, cortisol, and androgens |

Q2

Match the hormone on the left with the appropriate endocrine gland on the right. The same gland may be selected more than once.

- | | |
|---|-----------------------|
| ___ 1. FSH (follicle-stimulating hormone) | a. Pancreas |
| ___ 2. Androgens | b. Pituitary |
| ___ 3. Cortisol | c. Ovaries |
| ___ 4. Insulin | d. Adrenals (medulla) |
| ___ 5. Thyroxin | e. Testes |
| ___ 6. Parathormone | f. Adrenals (cortex) |
| ___ 7. Epinephrine | g. Thyroid |
| ___ 8. Estrogen | h. Parathyroid |
| ___ 9. Steroids | |

Q3

The endocrine system consists of glandular tissue which secretes _____ directly into the blood stream from its _____ (type) glands.

Q4

Match the endocrine glands on the left with their locations in the body on the right:

- | | |
|--------------------------|--|
| ___ 1. Ovaries (paired) | a. In the mediastinum |
| ___ 2. Testes (paired) | b. On top of each kidney |
| ___ 3. Adrenals (paired) | c. In the middle brain |
| ___ 4. Parathyroids | d. At the base of the brain |
| ___ 5. Thyroid | e. Behind the stomach |
| ___ 6. Pancreas | f. On the dorsal aspect of the thyroid |
| ___ 7. Pineal | g. In the lower abdominal region of the female |
| ___ 8. Thymus | h. On either side of the trachea just below the thyroid cartilage |
| ___ 9. Pituitary | i. Suspended by the spermatic cord and surrounded by the scrotal sac |

Q5

Match the tumor on the left with the typical gland of origin on the right. The same gland may be selected more than once.

- | | |
|----------------------------------|--------------------|
| ___ 1. Neuroblastoma | a. Pituitary gland |
| ___ 2. Papillary adenocarcinoma | b. Thyroid gland |
| ___ 3. Craniopharyngioma | c. Adrenal gland |
| ___ 4. Follicular adenocarcinoma | |

Answer: Q1

- d 1. Hormones Organic secretions originating in a ductless gland and conveyed to another part of the body by the bloodstream
- a 2. Hypophysis An endocrine gland which lies at the base of the brain; the pituitary
- e 3. Exocrine glands Glands which secrete substances through ducts to the body surface or into body cavities
- c 4. Isthmus A narrow strip of tissue connecting two parts
- b 5. Endocrine glands Ductless glands which secrete substances into the bloodstream
- f 6. Steroids Hormones produced by the adrenal cortex, such as aldosterone, cortisol, and androgens

Answer: Q2

- b 1. FSH (follicle-stimulating hormone) Pituitary
- e/f 2. Androgens Testes, adrenals (cortex)
- f 3. Cortisol Adrenals (cortex)
- a 4. Insulin Pancreas
- g 5. Thyroxin Thyroid
- h 6. Parathormone Parathyroid
- d 7. Epinephrine (adrenalin) Adrenals (medulla)
- c/f 8. Estrogen Ovaries, adrenals (cortex)
- f/e 9. Steroids Adrenals (cortex), testes

Answer: Q3

The endocrine system consists of glandular tissue which secretes hormones directly into the blood stream from its ductless glands.

Answer: Q4

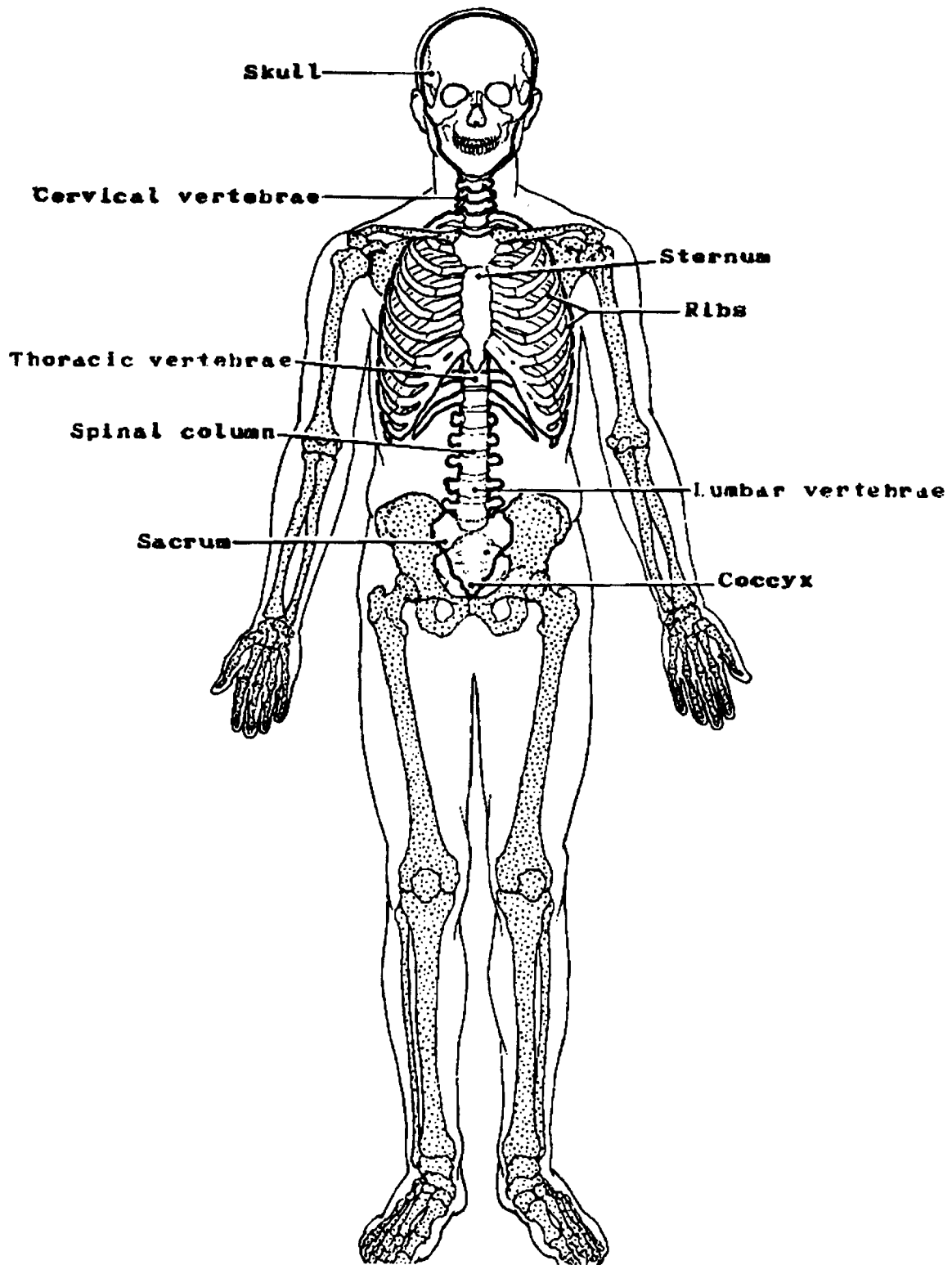
- | | | |
|----------|----------------------|---|
| <u>g</u> | 1. Ovaries (paired) | In the lower abdominal region of the female |
| <u>i</u> | 2. Testes (paired) | Suspended by the spermatic cord and surrounded by the scrotal sac |
| <u>b</u> | 3. Adrenals (paired) | On top of each kidney |
| <u>f</u> | 4. Parathyroids | On the dorsal aspect of the thyroid |
| <u>h</u> | 5. Thyroid | On either side of the trachea just below the thyroid cartilage |
| <u>e</u> | 6. Pancreas | Behind the stomach |
| <u>c</u> | 7. Pineal | In the middle brain |
| <u>a</u> | 8. Thymus | In the mediastinum |
| <u>d</u> | 9. Pituitary | At the base of the brain |

Answer: Q5

- | | | |
|----------|------------------------------|-----------------|
| <u>c</u> | 1. Neuroblastoma | Adrenal gland |
| <u>b</u> | 2. Papillary adenocarcinoma | Thyroid gland |
| <u>a</u> | 3. Craniopharyngioma | Pituitary gland |
| <u>b</u> | 4. Follicular adenocarcinoma | Thyroid gland |

SECTION K
THE SKELETAL SYSTEM

Figure 58. AXIAL SKELETON



SECTION K

THE SKELETAL SYSTEM

The skeletal system is composed of bones and cartilage. Most of the bones and much of the cartilage form joints which are held together by *ligaments* of tough, fibrous connective tissue. Joints can be classified as immovable (synarthrosis), slightly movable (amphiarthrosis), and freely movable (diarthrosis).

There are a total of 206 bones in the adult human body. Eighty of these bones form the upright axis of the body, the *axial skeleton*, which is the basic framework of the body. It includes the skull, vertebral column, and the bones (ribs) which encase the thorax. The other 126 bones comprise the *appendicular skeleton* which is made up of bones that are attached or appended to the axial skeleton: the upper and lower extremities (arms and legs) including the shoulder and pelvic girdles (clavicle, scapula, and hip bones). The main bones that compose the skeletal system can be located in Figures 58 and 67.

This complex skeletal system has a variety of functions.

- It provides a supporting framework for the body.
- It affords protection for the vital organs: heart, lungs, brain, spinal cord, as well as sensory organs, and soft tissues.
- It provides a leverage system for muscle action with the bones providing attachments for the muscles, ligaments,¹ tendons,² and fascia.³
- It serves as a storehouse (within the bone) for minerals, and supplies calcium and phosphorus to the blood.
- It contains bone marrow which produces millions of red blood cells and thousands of white cells (hemopoiesis).

¹ligament--a fibrous band of connective tissue that connects bones to bones serving to support and strengthen joints.

²tendon--a fibrous cord of connective tissue by which a muscle is attached to bone.

³fascia--a fibrous sheet of connective tissue covering and separating muscles.

Q1

The skeletal system is composed of _____ and _____
which may be held together by _____ at their joints.

Q2

Five functions of the skeletal system are:

1. _____
2. _____
3. _____
4. _____
5. _____

Q3

The 206 bones of the skeleton may be grouped into two skeletal divisions:

1. _____ (the basic framework of the body).
2. _____ (the appendage of this
framework).

Answer: Q1

The skeletal system is composed of bones and cartilage which may be held together by ligaments at their joints.

Answer: Q2

You might have said:

1. It provides a supporting framework for the body.
2. It protects the vital organs.
3. It provides leverage for muscle action.
4. It serves as a storehouse for minerals and supplies calcium and phosphorus to the blood.
5. The bone marrow produces blood cells.

Answer: Q3

The 206 bones of the skeleton may be grouped into two skeletal divisions:

1. Axial skeleton (the basic framework of the body).
2. Appendicular skeleton (the appendage of this framework).

Bone/Cartilaginous Tissue

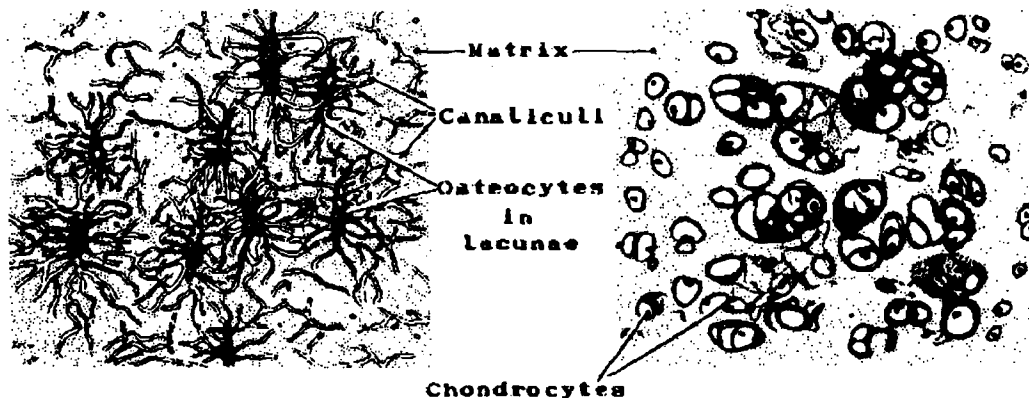
Bone, or osseous tissue, is a form of dense connective tissue in which the intercellular substance, or matrix, is infiltrated with calcium salts. It differs from cartilage in that bone is a vascular tissue permeated with canaliculi. The canaliculi are tiny canals that connect the lacunae (in which bone cells lie) with each other and serve as a transport system (Haversian system) between the blood capillaries and the bone cells. Tissue fluid in the canaliculi diffuses oxygen and nutrient material from the blood to the bone cells and carries their waste material back to the circulatory system. Thus the bone cells (osteocytes) may remain alive although surrounded by calcified intercellular substance (bone matrix). No bone cell is more than 0.1 mm from a blood capillary.

In contrast, cartilage is nonvascular connective tissue. Its cells (chondrocytes) are nourished by means of blood vessels in the outer layer of *perichondrium* which covers the surface of the cartilage. There are three types of cartilage:

- *Hyaline cartilage*, the most abundant, may become calcified and replaced by bone. However, much of it remains uncalcified as part of the ears, nose, larynx, trachea, and larger bronchi, and as a covering of the articulating¹ bones in freely moving joints where it has a cushioning effect.
- *Elastic cartilage* is rare; it occurs primarily in the external ear and in the epiglottis.
- *Fibrocartilage* (fibrous cartilage) is found in the areas where tendons insert into bone.

Figure 59. OSSEOUS TISSUE

Figure 60. HYALINE CARTILAGE



¹articulation--the place of union or junction between two or more bones.

Q4

One characteristic which distinguishes bone from cartilage is that bone is _____ while cartilage is _____.

Q5

Bone cells are called _____.

Q6

Cartilage cells are called _____.

Q7

Match the types of cartilage on the left with the descriptions on the right:

- | | | | | |
|-----|----|---------|----|--|
| ___ | 1. | Hyaline | a. | Rare, occurring only in external ear and epiglottis |
| ___ | 2. | Elastic | b. | Occurs in areas of insertion of tendons into bone |
| ___ | 3. | Fibrous | c. | Most abundant, may become calcified and be replaced by bone or remain uncalcified as a covering of articulating bones. |

Answer: Q4

One characteristic which distinguishes bone from cartilage is that bone is vascular while cartilage is nonvascular.

Answer: Q5

Bone cells are called osteocytes.

Answer: Q6

Cartilage cells are called chondrocytes.

Answer: Q7

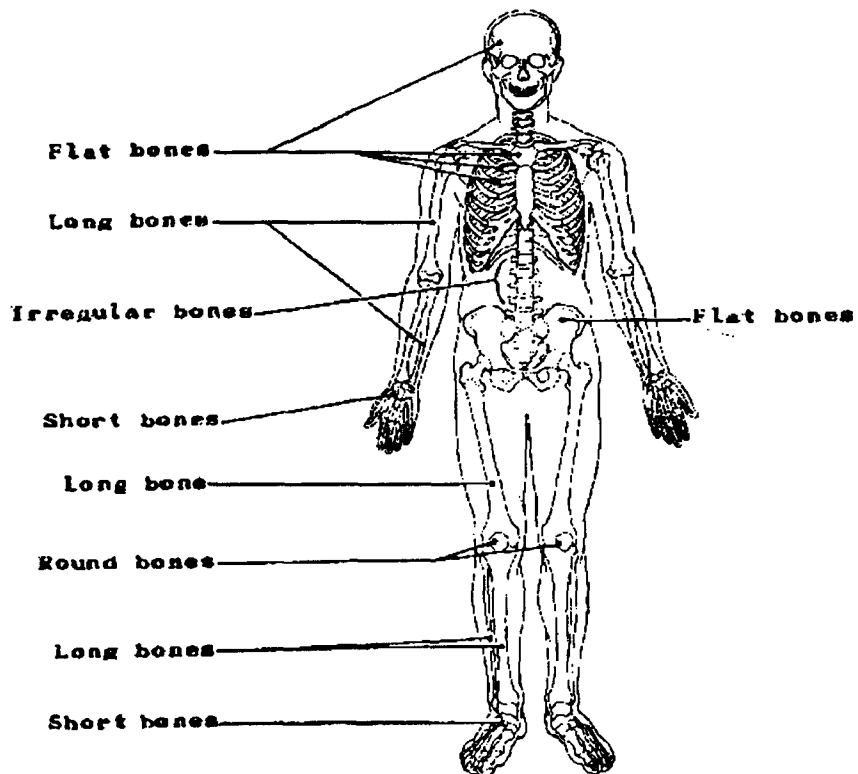
- | | | |
|----------|------------|--|
| <u>c</u> | 1. Hyaline | Most abundant, may become calcified and be replaced by bone or remain uncalcified as a covering of articulating bones. |
| <u>a</u> | 2. Elastic | Rare, occurring only in external ear and epiglottis. |
| <u>b</u> | 3. Fibrous | Occurs in areas of insertion of tendons into bone |

Classification of Bones

Bones may be classified by shape as follows:

- *Long bones* are found in the arms and legs. Examples: humerus, radius, ulna, phalanges, femur, tibia and fibula.
- *Short bones* are short and cuboid or irregular in shape. The three dimensions (length, width, and depth) are all about the same. Examples: wrist and ankle bones (carpal and tarsal).
- *Flat bones* are protection for the soft body parts. Examples: ribs, sternum, scapulae, and bones of the pelvis and skull (e.g., temporal, frontal).
- *Irregular bones* are similar in structure to flat bones, but because of their peculiar shape they are included in their own classification. Examples: vertebrae, sacrum, ethmoid, sphenoid, and ear bones of the skull.
- *Round bones* are small, flat round sesamoid bones, so named because of their resemblance to sesame seeds. Because the number of these bones varies greatly with the individual, only a few are reflected in the total bone count. The function of round bones is to eliminate or reduce friction. Example: The patella or kneecap is the largest sesamoid bone of the body and is embedded in the tendon of the quadriceps femoris muscle at each knee.

Figure 61. CLASSIFICATION OF BONES



Q8

The purpose of the sesamoid bones is to _____.

Q9

Match the following bones with the appropriate descriptions of their shapes.

- | | | |
|-----|-------------|---------------------|
| ___ | 1. Femur | a. Short |
| ___ | 2. Temporal | b. Flat |
| ___ | 3. Sacrum | c. Irregular |
| ___ | 4. Carpal | d. Round (sesamoid) |
| ___ | 5. Patella | e. Long |

Q10

The _____ consists of both flat and irregular bones.

Answer: Q8

The purpose of the sesamoid bones is to eliminate (or reduce) friction.

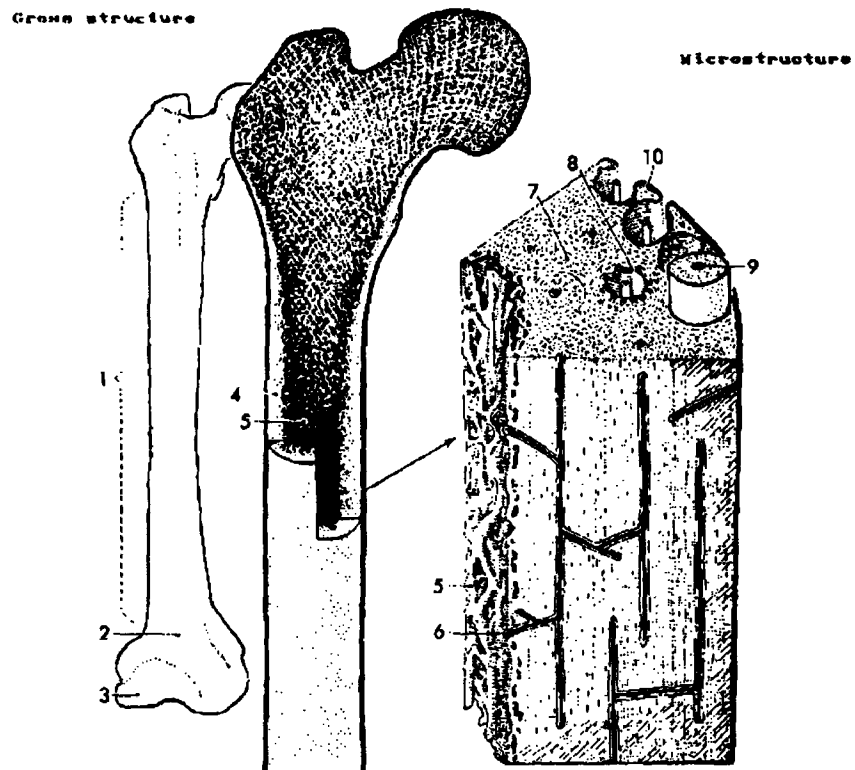
Answer: Q9

<u>e</u>	1. Femur	Long
<u>b</u>	2. Temporal	Flat
<u>c</u>	3. Sacrum	Irregular
<u>a</u>	4. Carpal	Short
<u>d</u>	5. Patella	Round (sesamoid)

Answer: Q10

The skull consists of both flat and irregular bones.

**Figure 62. HAVERSIAN SYSTEM OF THE BONE
ADULT FEMUR**



- | | |
|---|---|
| <ol style="list-style-type: none"> 1. Diaphysis (main shaft) 2. Metaphysis (shaft end) 3. Epiphysis (has separate center of bone growth) 4. Compact bone 5. Medullary cavity (with trabecular, cancellous spongy bone, and marrow) | <ol style="list-style-type: none"> 6. Blood vessel (from marrow) 7. Inter-Haversian lamellae 8. Osteocyte within lacunae (enlarged to show canaliculi) 9. Central canal of Haversian system 10. Periosteum |
|---|---|

Structure of Bone

Each long bone of the body is made up of several parts (Figure 62). The main shaft is called the *diaphysis*. It provides strong support without undue weight, and consists mainly of compact bone,¹ although the innermost portion is composed of cancellous², or spongy, bone. At the ends of a bone are structures known as *epiphyses* which are bulbous in shape, allowing ample space for muscle attachments near joints.

- Short bones consist of a core of cancellous bone encased in a thin layer of compact bone.
- Flat bones are made up of a layer of cancellous bone containing red marrow between two plates of compact bone.
- Irregular bones are similar in structure to short bones in that they are composed of a thin layer of compact bone forming a casing over cancellous bone.
- Round (or sesamoid) bones are made of dense fibrous tissue, cartilage, and bone in varying proportions. They are found embedded in tendons in close relation to articulating surfaces where they modify pressure and reduce friction.

The outside of the bone is covered by a fibrous membrane, the *periosteum*. Blood vessels, lymphatic vessels, and nerves are present in the periosteum and enter the Haversian³ canals of the compact bone to become vessels of the Haversian system permeating the entire bone.

The Haversian system is a series of small canals containing blood vessels which bring oxygen and nutrients to the bone and remove waste products such as carbon dioxide.

Bone Marrow

In the adult there are two types of bone marrow: yellow and red. In the center of the diaphysis there is a large space called the *medullary cavity* which is filled with yellow or fatty bone marrow. Red marrow fills the cancellous spaces in the upper (proximal) epiphyses of the humerus and femur, the iliac crest, body of the vertebra, bones of the skull (diploe), ribs, sternum, clavicle, and scapula. Red bone marrow is the source of red cells and granular leukocytes as well as platelets and monocytes. Marrow is changed from red to yellow by the replacement of myeloid cells by fat cells, a process which begins soon after birth.

Special lymphocytes, B cells, are formed in the bone marrow. Mature B cells are responsible for the manufacture of antibodies which circulate in blood or other body fluids and respond to antigens found on the surface of viruses and bacteria, thus preventing the spread of infection.

¹compact bone--continuous dense, hard structure in which spaces can only be distinguished with the aid of a microscope

²cancellous bone--spongy or lattice-like structure surrounding intercommunicating spaces filled with bone marrow.

³Haversian--the canal or system named after Clopton Havers (1650-1702) an English anatomist, who first described the structure of osseous tissue.

Q11

Name each of the five numbered parts of the gross structure of the long bone in Figure 62:

1. _____
2. _____
3. _____
4. _____
5. _____

Q12

The outer covering of the bone is known as the _____.

Q13

Periosteum contains _____ vessels, _____ vessels, and _____ which enter the compact bone to become vessels of the _____ system.

Q14

Bone marrow is found in the _____ of long bones and in spaces of _____ bones.

Answer: Q11

The numbered parts of the gross structure of the long bone listed in Figure 62 are:

1. Diaphysis
2. Metaphysis
3. Epiphysis
4. Compact bone
5. Medullary cavity

7. Cancellous (spongy) bone

Answer: Q12

The outer covering of the bone is known as the periosteum.

Answer: Q13

Periosteum contains blood vessels, lymph vessels, and nerves which enter the compact bone to become vessels of the Haversian system.

Answer: Q14

Bone marrow is found in the medullary cavity of long bones and in spaces of cancellous bones.

AXIAL SKELETON

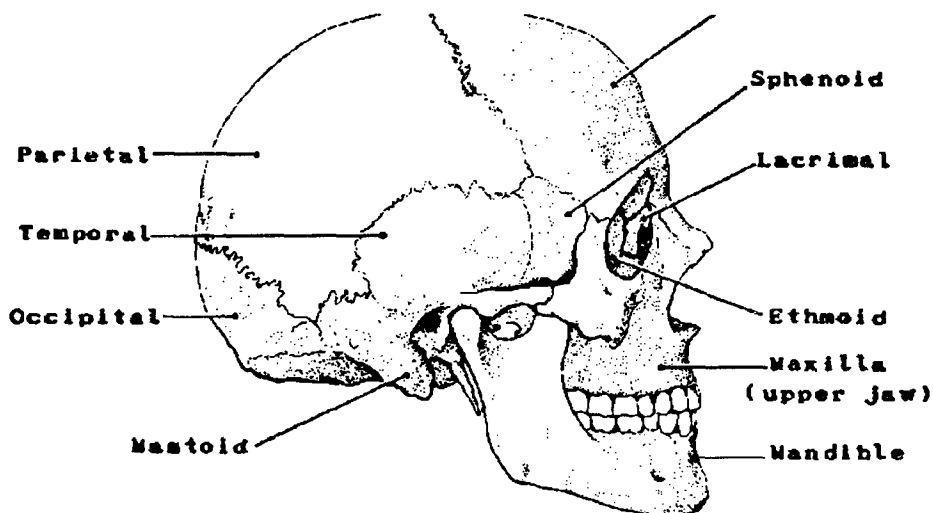
There are a total of eighty bones in the axial skeleton. It is composed of the skull (29 bones), the thorax (25 bones) and the vertebral column (26 bones).

Bones of the Skull. The skull is the skeleton of the face and head. These bones protect the brain and related structures. The skull is composed of 29 bones, 8 forming the cranium, 14 forming the bones of the face, 6 forming the small bones in the middle ear, and 1 hyoid bone.

Cranial bones. The cranial bones are the frontal, occipital, sphenoid, ethmoid, 2 temporal, and 2 parietal bones. They are joined together by suturæ¹ and are immovable.

- The *frontal* bone is located at the front of the skull. It contains the frontal sinuses and forms the upper rim of the orbit.
- The *occipital* bone makes up the framework of the lower, posterior part of the skull.
- The *sphenoid* bone houses the pituitary gland in a depression in its upper surface, the sella turcica, and forms a part of the roof of the nose with its undersurface. It contains the sphenoidal sinuses.
- The *ethmoid* bone is a light, spongy bone located at the base of the cranium, between the orbits, and at the roof of the nose. It contains the ethmoid air cells (sinuses).
- The *temporal* bones (2 bones) form part of the sides and part of the base of the skull.
- The *parietal* bones (2 bones) form the roof and upper part of the sides of the cranium.

Figure 63. CRANIAL BONES



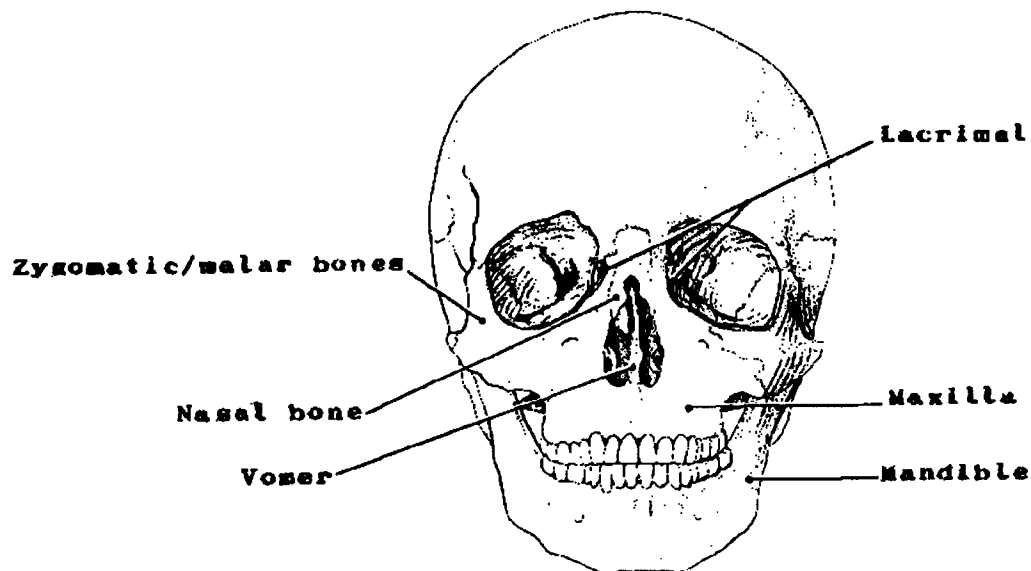
¹suturæ--fibrous joints in which the apposed bony surfaces are so closely united by a very thin layer of fibrous connective tissue that no movement can occur.

Facial bones. The facial bones are the paired zygomatic, lacrimal, nasal, maxillae, palatine, conchae, and the unpaired vomer and mandible. All the facial bones except the mandible are joined together by suturae so that they are immovable.

- The *zygomatic/malar* bones form the cheek bones and part of the orbit.
- The *lacrimal* bones are the smallest and most fragile bones of the face. The tear ducts pass through them in the lacrimal canal.
- The *nasal* bones support the bridge of the nose.
- The *maxillae* compose the massive upper jaw bones. Joined by a sutura in the median plane, they contain the maxillary sinuses. A condition known as cleft palate results when the two bones do not grow together normally before birth.
- The *vomer* is a thin, flat bone which forms the lower portion of the nasal septum.
- The *mandible* is the lower jaw bone. It is movable for chewing and speaking purposes.
- The *palatine* bone forms part of the wall and floor of the nasal cavity and part of the roof of the mouth.
- The *conchae* (turbinates) are thin bony plates with curved margins which form the lower part of the lateral wall of the nasal cavity.

Bones of the ear. A chain of three small bones extend across the middle ear on each side: the *malleus*, the *incus*, and the *stapes*. These bones transmit sound waves from the eardrum membrane to the fluid of the inner ear.

Figure 64. FACIAL BONES



Bones of the Thorax. There are 25 bones in the thorax: the sternum, and 12 pairs of ribs.

- *Sternum* (breast bone) is a flat bone extending down the middle of the chest. It articulates on the sides with the clavicle and ribs.
- *Ribs.* There are 12 pairs of ribs.

The first 7 pairs of ribs articulate with the sternum by cartilaginous attachments. These are called the true ribs.

The last 5 pairs of ribs are called false ribs because they do not join the sternum directly. Instead, the first 3 (the 8th, 9th, and 10th) have cartilage which converges before the sternum is reached. The last two are floating ribs which end in the midchest; they are not attached to the sternum at all.

All the ribs are attached to the vertebral column dorsally and form a cage-like structure enclosing and protecting the heart, lungs, and other thoracic structures.

Vertebral column. The vertebral column is made up of 26 bones.

- *Cervical vertebrae* (7 bones) constitute the skeleton of the neck.
- *Thoracic vertebrae* (12 bones) are situated between the cervical and lumbar vertebrae. They are attached to the 12 pair of ribs and form part of the posterior wall of the thorax.
- *Lumbar vertebrae* (5 bones) are situated between the thoracic vertebrae and the sacrum.
- The *sacrum* is formed by 5 vertebrae fused into a triangular-shaped bone in the adult.
- The *coccyx* (tailbone) is formed by four fused vertebrae.

Figure 65. BONES OF THE THORAX
(frontal view)

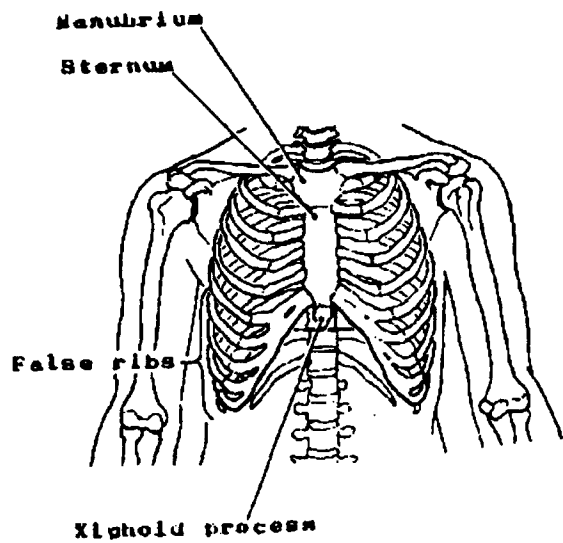
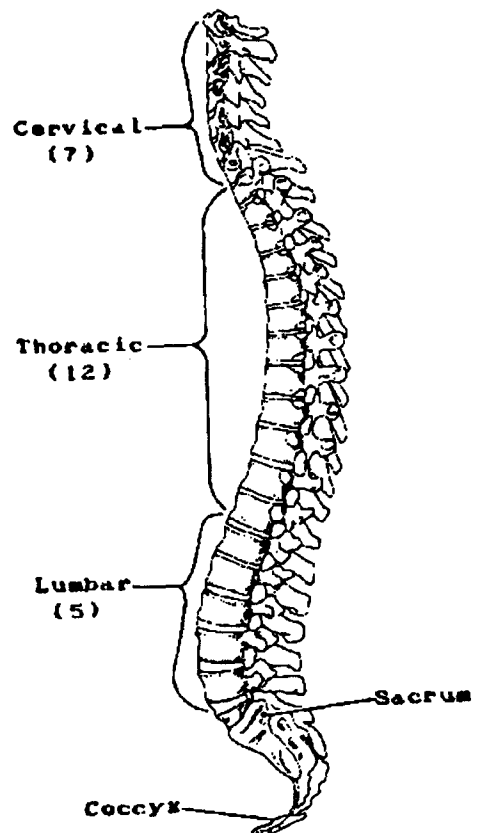


Figure 66. VERTEBRAL COLUMN
(sagittal view)



Q15

Name the cranial bones:

1. _____
2. _____
3. _____
4. _____
5. _____
6. _____

Q16

Name six facial bones:

1. _____
2. _____
3. _____
4. _____
5. _____
6. _____

Q17

Match the bones on the left with the descriptions on the right.

- | | | |
|-----|--------------|---|
| ___ | 1. Occipital | a. Bones which form part of the sides and part of the base of the skull |
| ___ | 2. Hyoid | b. Houses the pituitary gland and sphenoid sinuses |
| ___ | 3. Lacrimal | c. Framework of lower, posterior part of the skull |
| ___ | 4. Temporal | d. The tear ducts pass through them |
| ___ | 5. Sphenoid | e. Bone of attachment for muscles which move the tongue |

Answer: Q15

The cranial bones are:

1. Frontal
2. Occipital
3. Sphenoid
4. Ethmoid
5. Temporal (2 bones)
6. Parietal (2 bones)

Answer: Q16

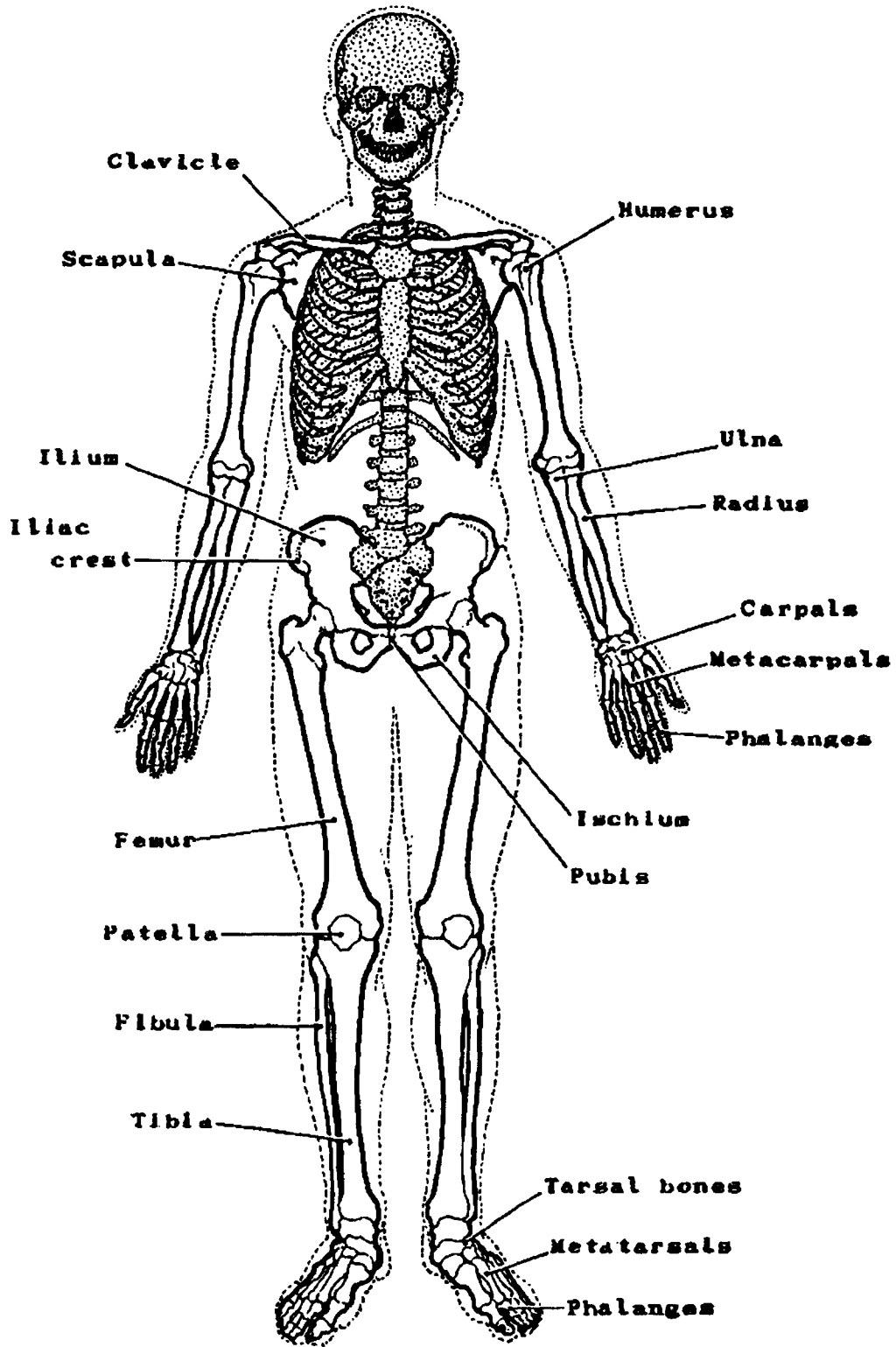
You might have mentioned any 6 of the following facial bones:

1. Zygomatic
2. Lacrimal
6. Maxillae
4. Nasal
5. Palatine
6. Vomer
7. Mandible
8. Conchae

Answer: Q17

- | | | |
|----------|--------------|--|
| <u>c</u> | 1. Occipital | Framework of lower, posterior part of the skull |
| <u>e</u> | 2. Hyoid | Bone of attachment for muscles which move the tongue |
| <u>d</u> | 3. Lacrimal | The tear ducts pass through them |
| <u>a</u> | 4. Temporal | Bones which form part of the sides and part of the base of the skull |
| <u>b</u> | 5. Sphenoid | Houses the pituitary gland and sphenoid sinuses |

Figure 67. APPENDICULAR SKELETON



APPENDICULAR SKELETON

The appendicular skeleton is composed of 126 bones.

Upper extremity (32 bones on each side):

- **Clavicle:** collar bone connects the sternum to the scapula
- **Scapula:** shoulder blade lies on the upper part of the back
- **Humerus:** upper arm bone articulates with the scapula at the upper end and with the ulna and radius at its lower end
- **Ulna:** medial lower arm bone
- **Radius:** lateral lower arm bone
- **Carpals:** wrist bones in 2 rows of 4 bones (total of 8 bones on each hand)
- **Metacarpals:** bones which form the bony structure of the palm of the hand (total of 5 bones on each hand)
- **Phalanges:** bones which form the fingers. Each finger, except the thumb, has 3 phalanges; the thumb has only 2 (total of 14 bones on each hand).

Lower extremity (31 bones on each side)

- **Hip bones:** ilium, ischium, and pubis form the lateral and anterior walls of the pelvis
- **Femur:** thigh bone articulates with the tibia at the distal end
- **Patella:** kneecap
- **Tibia (shin bone):** The larger of the two lower leg bones articulates with the femur at upper end and with the fibula at both upper and lower ends.
- **Tarsals:** ankle bones, the highest of which articulates with the tibia and fibula (total of 7 bones on each foot)
- **Metatarsals:** bones which form the bony structure of the foot (total of 5 bones on each foot)
- **Phalanges (toe bones):** Each toe, except the big toe, has 3 phalanges; the big toe has only 2 (total of 14 bones on each foot).

Malignant Tumors

Bone is derived from three cell lines each of which can produce tumors: osteogenic, chondrogenic, and collagenic¹. Bone also houses the marrow which contains hematopoietic precursors of myelogenic tumors. All are derived from mesoderm. Only malignant tumors are discussed here.

- *Osteogenic Sarcoma* (osteosarcoma) is the second most common bone malignancy after myeloma. It occurs mainly in males between the ages of 10 and 20 years. It grows rapidly in the long bones of the extremities and metastasizes quickly via the blood stream to the lungs. It may perforate the periosteum and invade the surrounding soft tissues.
- *Periosteal Sarcoma* is a rare, slow-growing malignancy. It arises from periosteal fibrous tissue. The posterior aspect of the distal femur is the most common site.
- *Giant Cell Tumor, Malignant* (malignant osteoclastoma) is a tumor which arises from the connective tissue of the medullary cavity. The malignant type expands rapidly.
- *Chondrosarcoma* is a tumor arising from the chondrogenic line. There are two distinct types of this tumor: peripheral, which develops on the surface of the bone, and central, which develops in the interior. The peripheral chondrosarcoma tends to affect flat bones such as ilium, sacrum, or scapula. The central chondrosarcoma occurs most often in the femur, tibia, or humerus.
- *Ewing's Sarcoma* is a highly malignant sarcoma usually occurring in males under 25 years of age. It is multicentric, originates from the reticulum cell, and usually begins in the metaphysis or wide part at the extremity of a long bone.

Closely associated with bone tumors are the following soft tissue tumors:

- *Fibrosarcoma* and *Angiosarcoma*: Malignant tumors which come from the connective tissue line. *Fibrosarcoma*, affecting mainly young adults, causes local bone destruction, particularly of the long bones. *Angiosarcoma* is a rare tumor arising primarily from capillary endothelial cells (vascular tissue within the bone).

Tumors of *myelogenic* (bone marrow) origin, other than the myeloproliferative disorders, are malignant, for example:

- *Multiple Myeloma*: A systemic disease found most often between ages 40 to 60 years. It originates in the reticular stem cell in the marrow spaces of the bone and is characterized by overproduction of plasma cells by the marrow. It is the most common bone tumor.

Bone is a common metastatic site for malignant cancer cells which are usually transported by way of the blood stream. The primary sites from which metastases to bone most often occur are breast, prostate, lung, colon, stomach, and urinary bladder.

¹collagenic--containing fibrous connective tissue.

Q18

Match the descriptions on the left with the terms on the right.

- | | | | | |
|-----|-----|--|----|-------------|
| ___ | 1. | A bone which connects the sternum to the scapula | a. | Carpals |
| ___ | 2. | The 8 bones of the wrist | b. | Patella |
| ___ | 3. | The 5 bones which form the bony structure of the hand | c. | Hip |
| ___ | 4. | The kneecap | d. | Clavicle |
| ___ | 5. | The smaller of the 2 lower leg bones | e. | Tarsals |
| ___ | 6. | The ankle bones | f. | Metacarpals |
| ___ | 7. | The ilium, ischium, and pubis | g. | Femur |
| ___ | 8. | The bones of the toes | h. | Humerus |
| ___ | 9. | The shoulder blade | i. | Fibula |
| ___ | 10. | The lateral lower arm | j. | Scapula |
| ___ | 11. | The bone which articulates with the tibia at the
distal end | k. | Phalanges |
| ___ | 12. | The bones which form the fingers | l. | Tibia |
| ___ | 13. | The bones which form the long structure of the foot | m. | Metatarsals |
| ___ | 14. | The shin bone | n. | Radius |
| ___ | 15. | The upper arm bone | o. | Ulna |
| ___ | 16. | The medial lower arm bone | p. | Long |

Q19

Primary malignancies elsewhere in the body frequently metastasize to the bone via the _____

_____.

Q20

Sites from which metastases to bone most frequently occur are:

1. _____
2. _____
3. _____
4. _____
5. _____
6. _____

Q21

Match each of the tumors on the left with its description on the right.

- | | | |
|-----|------------------------|---|
| ___ | 1. Angiosarcoma | a. A tumor composed of both osteogenic and chondrogenic elements |
| ___ | 2. Giant cell tumor | b. A rare, slow-growing malignancy arising from fibrous tissue of the periosteum |
| ___ | 3. Osteosarcoma | c. A malignant tumor arising in the vascular tissue within the bone |
| ___ | 4. Periosteal sarcoma | d. A common bone tumor, second only to myeloma, which occurs mainly in males |
| ___ | 5. Osteochondrosarcoma | e. A bone tumor which arises from connective tissue of the medullary cavity |
| ___ | 6. Multiple myeloma | f. A highly malignant, multicentric sarcoma originating from the reticulum cell |
| ___ | 7. Ewing's sarcoma | g. A systemic disease originating in the reticular stem cell in the marrow spaces of the bone |

Q22

Match the description on the left with one of the terms on the right.

- | | | | | |
|-----|----|--|----|------------------|
| ___ | 1. | Outer membrane covering bone tissue | a. | Epiphysis |
| ___ | 2. | Flexible, connective tissue found in the ribs, nasal septum, external ear, joints, and respiratory tubes of an adult | b. | Diarthrosis |
| ___ | 3. | Skull bones: parietal, occipital, frontal, ethmoid, sphenoid, and temporal bones | c. | Fascia |
| ___ | 4. | Shaft of the long bone | d. | Cartilage |
| ___ | 5. | Bones found in sternum, pelvis, and ribs; | e. | Diaphysis |
| ___ | 6. | Bone cell | f. | Osteocyte |
| | | | g. | Tendon |
| | | | h. | Ligament |
| | | | i. | Haversian system |
| | | | j. | Cranial bones |
| | | | k. | Flat bones |
| | | | l. | Conchae |
| | | | m. | Periosteum |
| | | | n. | Joints |
| | | | o. | Fossa |
| | | | p. | Sulcus |

Answer: Q18

<u>d</u>	1.	A bone which connects the sternum to the scapula	Clavicle
<u>a</u>	2.	The 8 bones of the wrist	Carpals
<u>f</u>	3.	The 5 bones which form the bony structure of the hand	Metacarpals
<u>b</u>	4.	The kneecap	Patella
<u>i</u>	5.	The smaller of the 2 lower leg bones	Fibula
<u>e</u>	6.	The ankle bones	Tarsals
<u>c</u>	7.	The ilium, ischium, and pubis	Hip
<u>k</u>	8.	The bones of the toes	Phalanges
<u>j</u>	9.	The shoulder blade	Scapula
<u>n</u>	10.	The lateral lower arm	Radius
<u>g</u>	11.	The bone which articulates with the tibia at the distal end	Femur
<u>k</u>	12.	The bones which form the fingers	Phalanges
<u>m</u>	13.	The bones which form the long structure of the foot	Metatarsals
<u>l</u>	14.	The shin bone	Tibia
<u>h</u>	15.	The upper arm bone	Humerus
<u>o</u>	16.	The medial lower arm bone	Ulna

Answer: Q19

Primary malignancies elsewhere in the body frequently metastasize to the bone via the blood stream.

Answer: Q20

Sites from which metastases most frequently occur are:

1. Breast
2. Prostate
3. Lung
4. Colon
5. Stomach
6. Urinary bladder

Answer: Q21

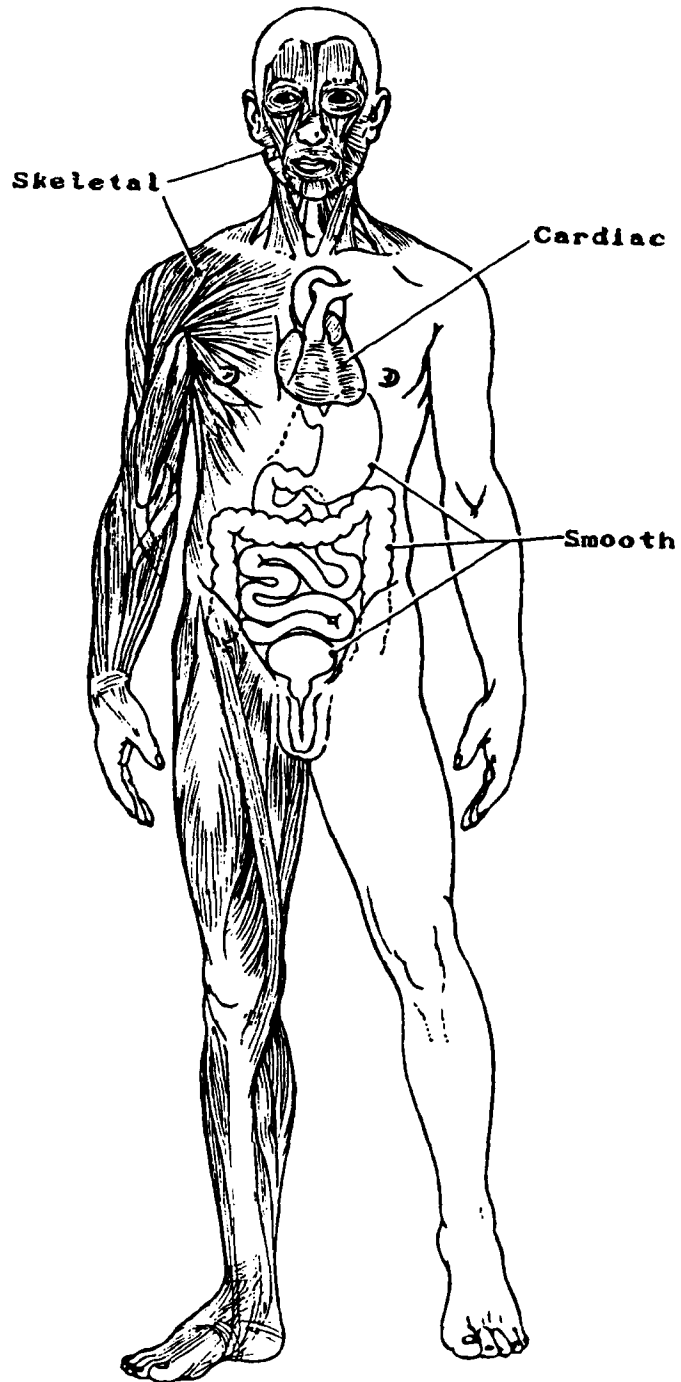
- | | | | |
|----------|----|---------------------|--|
| <u>c</u> | 1. | Angiosarcoma | A malignant tumor arising in the vascular tissue within the bone |
| <u>e</u> | 2. | Giant cell tumor | A bone tumor which arises from connective tissue of the medullary cavity |
| <u>d</u> | 3. | Osteosarcoma | A common bone tumor, second only to myeloma, which occurs mainly in males |
| <u>b</u> | 4. | Periosteal sarcoma | A rare, slow-growing malignancy arising from fibrous tissue of the periosteum |
| <u>a</u> | 5. | Osteochondrosarcoma | A tumor composed of both osteogenic and chondrogenic elements |
| <u>g</u> | 6. | Multiple myeloma | A systemic disease originating in the reticular stem cell in the marrow spaces of the bone |
| <u>f</u> | 7. | Ewing's sarcoma | A highly malignant, multicentric sarcoma originating from the reticulum cell |

Answer: Q22

- | | | | |
|----------|----|--|---------------|
| <u>m</u> | 1. | Outer membrane covering bone tissue | Periosteum |
| <u>d</u> | 2. | Flexible, connective tissue found in the ribs, nasal septum, external ear, joints, and respiratory tubes of an adult | Cartilage |
| <u>j</u> | 3. | Skull bones: parietal, occipital, frontal, ethmoid, sphenoid, and temporal bones | Cranial bones |
| <u>e</u> | 4. | Shaft of the long bone | Diaphysis |
| <u>k</u> | 5. | Bones found in sternum, pelvis, and ribs; protect soft parts | Flat bones |
| <u>f</u> | 6. | Bone cell | Osteocyte |

SECTION L
THE MUSCULAR SYSTEM

Figure 68. MUSCLE TYPES



SECTION L

THE MUSCULAR SYSTEM

The muscular system is composed of specialized cells called muscle fibers. Their predominant function is contractibility. Muscles, where attached to bones or internal organs and blood vessels, are responsible for movement. Internal movement involves the contraction and relaxation of muscles which are a part of the viscera; external movement is accomplished by the contraction and relaxation of muscles which are attached to bones.

Muscle Types

In the body are found three types of muscle: skeletal, smooth, and cardiac.

- *Skeletal muscle*, attached to bones, is responsible for skeletal movements. The peripheral portion of the central nervous system (CNS) controls the skeletal muscles. Thus, these muscles are under conscious, or voluntary, control. The basic unit is the muscle fiber with many nuclei. These muscle fibers are striated (having transverse streaks) and each acts independently of neighboring muscle fibers.
- *Smooth muscle*, found in the walls of the hollow internal organs such as blood vessels, the gastrointestinal tract, bladder, and uterus, is under control of the autonomic nervous system. Smooth muscle cannot be controlled consciously and thus acts involuntarily. The nonstriated (smooth) muscle cell is spindle-shaped and has one central nucleus. Smooth muscle contracts slowly and rhythmically.
- *Cardiac muscle*, found in the walls of the heart, is also under control of the autonomic nervous system. The cardiac muscle cell has one central nucleus, like smooth muscle, but it also is striated, like skeletal muscle. The cardiac muscle cell is rectangular in shape. The contraction of cardiac muscle is involuntary, strong, and rhythmical.

Muscle tissue receives a rich supply of blood which is carried by the arteries into the very substance of the muscle. Most of the arterioles run parallel with muscle fibers and branch off into capillaries at right angles into the fibers.

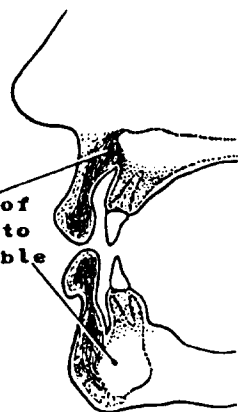
Muscle tumors tend to spread by way of the blood stream rather than to the lymphatics. Lymph node metastasis does not often occur.

Smooth and cardiac muscle are discussed in more detail with respect to their appropriate systems. This section explains mainly the skeletal muscular system.

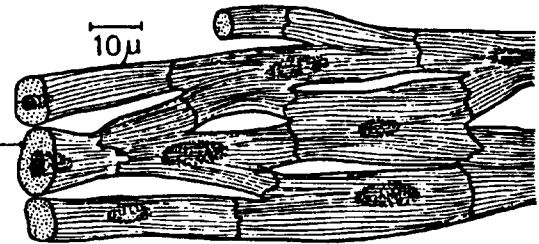
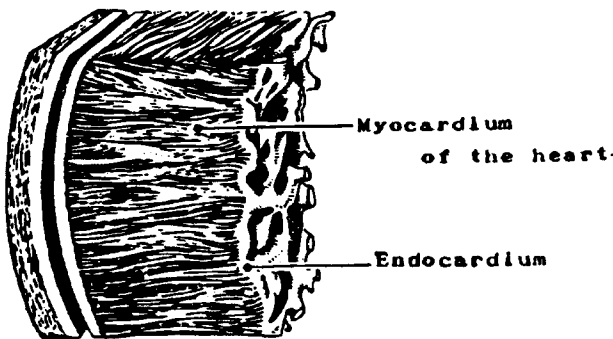
Figure 69. HISTOLOGICAL COMPARISONS OF MUSCLE TYPES
SKELETAL MUSCLE



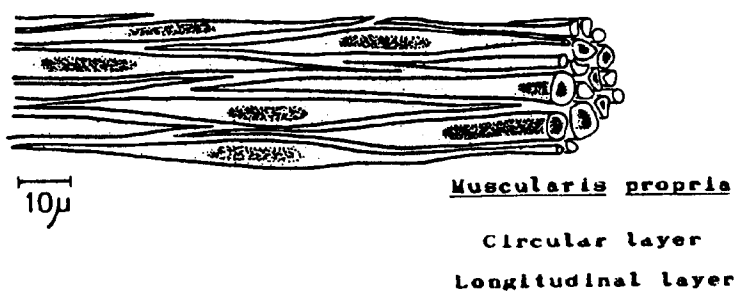
Voluntary muscles of the mouth attach to maxilla and mandible



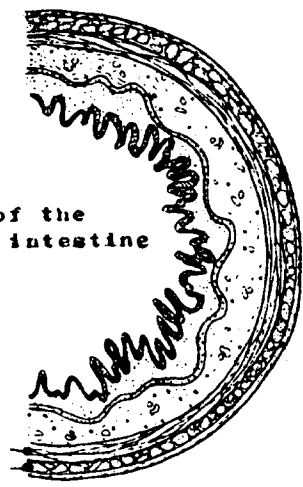
CARDIAC MUSCLE



SMOOTH MUSCLE



Lumen of the small intestine



Q1

Name the three types of muscle found in the body:

1. _____

2. _____

3. _____

Q2

The two types of muscle that act without voluntary control are _____ and _____ muscle.

Q3

_____ muscle is under voluntary control.

Q4

Which muscle types are described as striated and which is described as nonstriated muscle?

Q5

The _____ and _____ muscle cells have one nucleus, while the _____ muscle cell has many nuclei.

Answer: Q1

The three types of muscle found in the body are:

1. Skeletal muscle
2. Smooth muscle
3. Cardiac muscle

Answer: Q2

The two types of muscle that act without voluntary control are smooth and cardiac muscle.

Answer: Q3

Skeletal muscle is under voluntary control.

Answer: Q4

Skeletal and cardiac muscle are described as striated while smooth muscle is described as nonstriated muscle.

Answer: Q5

The smooth and cardiac muscle cells have one nucleus, while the skeletal muscle cell has many nuclei.

Tendons, Fascia, and Ligaments

Each muscle merges into a *tendon*, a tough nonelastic fibrous band of connective tissue which attaches to the fibrous covering of bone (the periosteum), so that the action of the muscle will be transferred to the bone, causing movement of the joint. Perhaps the most well-known is the Achilles tendon, where the posterior muscles of the calf of the leg merge and attach to the calcaneus (heel) bone of the foot.

Fascia is a fibrous sheet of connective tissue which covers and separates muscles. It also encloses the viscera, glands, blood vessels, and nerves. Some fasciae are located superficially under the skin while other fasciae associated with muscles lie deeper within the body.

Ligaments are fibrous bands of connective tissue which anchor bones together thereby strengthening and supporting the joints. Ligaments also serve to hold organs in place.

Q6

- | | | | | |
|--------------------------|------|--------------------------|-------|---|
| <input type="checkbox"/> | True | <input type="checkbox"/> | False | 1. Muscles have a rich blood supply, therefore, malignant tumors of muscle often invade blood vessels by virtue of their proximity. |
| <input type="checkbox"/> | True | <input type="checkbox"/> | False | 2. The periosteum is the outer covering of the bone. |
| <input type="checkbox"/> | True | <input type="checkbox"/> | False | 3. The fascia is a tough fibrous band of connective tissue which attaches to the fibrous covering of the bone. |
| <input type="checkbox"/> | True | <input type="checkbox"/> | False | 4. The force of a muscle contraction is transferred to the bone by way of the tendon. |
| <input type="checkbox"/> | True | <input type="checkbox"/> | False | 5. Fasciae are associated only with skeletal muscles. |

Q7

Match the descriptions on the left with one of the terms on the right.

- | | | |
|-----|--|----------------|
| ___ | 1. A fibrous cord of connective tissue binding muscle to bone | a. Epiphysis |
| ___ | 2. A fibrous sheet of connective tissue covering and separating muscle | b. Diarthrosis |
| ___ | 3. Connective tissue binding bones to bones | c. Fascia |
| | | d. Cartilage |
| | | e. Ligament |
| | | f. Osteocyte |
| | | g. Tendon |

Answer: Q6

1. True Malignant tumors of muscles often invade blood vessels.
2. True The periosteum is the outer covering of the bone.
3. False Tendons, not fasciae, attach to the fibrous covering of bones.
4. True The force of a muscle contraction is transferred to the bone by way of the tendon.
5. False Fasciae are associated with all muscles as well as the viscera, glands, blood vessels, and nerves.

Answer: Q7

- | | | |
|----------|--|----------|
| <u>g</u> | 1. A fibrous cord of connective tissue binding muscle to bone | Tendon |
| <u>c</u> | 2. A fibrous sheet of connective tissue covering and separating muscle | Fascia |
| <u>e</u> | 3. Connective tissue binding bones to bones | Ligament |

Skeletal Muscles

Some of the skeletal muscles are shown in Figure 68. An extensive list of skeletal muscles is found in your medical dictionary under "muscle." Dorland's dictionary also contains five plates which show most of the more than 600 muscles of the body. Two prominent groups of muscles which have been given characteristic names are the hamstrings (lower extremity) and the biceps (upper extremity).

The five functional characteristics of muscle tissue are:

- *Irritability:* ability to respond to a stimulus
- *Conductivity:* ability to transmit impulses
- *Extensibility:* ability to stretch
- *Elasticity:* ability to resume former length when the stretching force is removed
- *Contractibility:* ability to shorten

The three general functions of skeletal muscle are:

- *Movement:* sometimes locomotion and sometimes movement within a given area
- *Heat production:* developed by muscle contraction
- *Posture:* alignment of body parts.

Posture is maintained by a continual pull of muscles on bones in a direction opposite to the pull of gravity, i.e., by the continual partial contraction of muscles, known as muscle tone. Therefore, posture is indirectly dependent on many other factors, such as a normal nervous system and health in general.

The names given to muscles describe one or more of the following features of muscle: action, direction of fibers, location, number of divisions, shape, and points of attachment to bone. Muscles may be classified into groups according to the action or movement performed.

- *Flexors* decrease the angle in a joint.
- *Extensors* increase the angle in a joint and also return a body part to neutral position after flexion.
- *Abductors* move a body part away from the midline.
- *Adductors* move a body part towards the midline.
- *Rotators* cause a body part to pivot on its axis.
- *Levators/elevators* raise a body part.

- *Supinators* turn the palm upward or forward.
- *Pronators* turn the palm downward or backward.
- *Sphincters* reduce the size of an opening.
- *Tensors* make a body part more rigid.

Malignant Tumors

Malignant tumors of muscle tissue are known as sarcomas. Refer to *The International Classification of Diseases for Oncology*, Second Edition, (8890-8920), p. 37, for a list of myomatous (muscle) tumors.

All sarcomas usually present as firm masses in the subcutaneous tissue or deep within or between muscles. However, there are many different varieties of malignant soft tissue tumors:

- Leiomyosarcoma is a tumor of smooth muscle.
- Rhabdomyosarcoma is a tumor of striated muscle.
- Angiomyosarcoma is a tumor composed of blood vessels and muscular tissue.

Malignant tumors closely associated with muscle tissue:

- Synovial sarcoma is a tumor arising in the tendon sheaths, bursa, and joints.
- Fibrosarcoma is a tumor of fibrous tissue which may arise in association with striated muscle or fascia.

Q8

What are the three general functions of the skeletal muscle?

1. _____
2. _____
3. _____

Q9

How is the posture of the body maintained?

Q10

What are the functional characteristics of muscle tissue?

1. _____
2. _____
3. _____
4. _____
5. _____

Answer: Q8

The three general functions of skeletal muscle are:

1. Movement
2. Heat production
3. Posture

Answer: Q9

Posture is maintained by continual partial contraction of the muscles.

Answer: Q10

1. Irritability
2. Conductivity
3. Extensibility
4. Elasticity
5. Contractibility

Q11

Match the muscle groups on the left with the descriptions on the right.

- | | | |
|-----|---------------|---|
| ___ | 1. Supinators | a. Decrease the angle in a joint |
| ___ | 2. Sphincters | b. Move a body part away from the midline |
| ___ | 3. Abductors | c. Lower a body part |
| ___ | 4. Flexors | d. Turn the palm upward or forward |
| ___ | 5. Depressors | e. Reduce the size of an opening |

Q12

Match each description on the left with one of the terms on the right.

- | | | |
|-----|--|---------------------|
| ___ | 1. Heart muscle, involuntary and striated | a. Fasciae |
| ___ | 2. Fibrous sheets of connective tissue which cover the muscles | b. Visceral muscle |
| ___ | 3. The hamstring muscles and the biceps muscles | c. Leiomyosarcoma |
| ___ | 4. A malignant tumor of smooth muscle | d. Striation |
| ___ | 5. A characteristic of skeletal muscle | e. Tendons |
| ___ | 6. Connective tissue binding muscle to bone | f. Rhabdomyosarcoma |
| ___ | 7. Involuntary, visceral muscle | g. Cardiac muscle |
| | | h. Ligaments |
| | | i. Skeletal muscle |
| | | j. Angiomyosarcoma |
| | | k. Smooth muscle |

Answer: Q11

Match the muscle groups on the left with the descriptions on the right.

- d 1. Supinators turn the palm upward or forward
- e 2. Sphincters reduce the size of an opening
- b 3. Abductors move a body part away from the midline
- a 4. Flexors decrease the angle in a joint
- c 5. Depressors lower a body part

Answer: Q12

Match each description on the left with one of the terms on the right.

- g 1. Heart muscle, involuntary and striated Cardiac muscle
- a 2. Fibrous sheets of connective tissue which cover the muscles Fasciae
- i 3. The hamstring muscles and the biceps muscles Skeletal muscle
- c 4. A malignant tumor of smooth muscle Leiomyosarcoma
- d 5. A characteristic of skeletal muscle Striation
- e 6. Connective tissue binding muscle to bone Tendons

SECTION M
THE NERVOUS SYSTEM

SECTION M

THE NERVOUS SYSTEM

The nervous system provides the integration and control of body processes. It is customarily divided into: 1) the central nervous system which consists of the brain and spinal cord and their coverings which are called meninges and 2) the peripheral nervous system which consists of the nerves that connect the brain and spinal cord to the tissues and organs of the body.

Nervous Tissue

Nervous tissue is composed of three types of cells:

- *Neuron*

The nerve cell (neuron) is the basic structural and functional unit of the nervous system. Each neuron consists of a cell body which contains a large nucleus surrounded by cytoplasm and processes called dendrites and axons. These processes are peculiar to neurons and are responsible for the conduction and transmission of neural information. Dendrites carry impulses toward the cell body; a single axon conducts impulses away from the cell body. Axons (nerve fibers) in the peripheral nervous system may be covered by a myelin sheath and by neurilemma, which is a membranous sheath that covers the axon directly or covers the myelin sheath when it is present. Not only does the myelin sheath increase the speed of nerve impulse conduction, but it insulates and maintains the axon; the neurilemma assists in the regeneration of injured axons. Nerve tissue of the brain and spinal cord has no neurilemma, and, thus, it does not regenerate. Instead, the central nervous system contains neuroglial cells, called oligodendrocytes, which form a myelin covering for the brain and spinal cord.

- *Neuroglia* (glial cells)

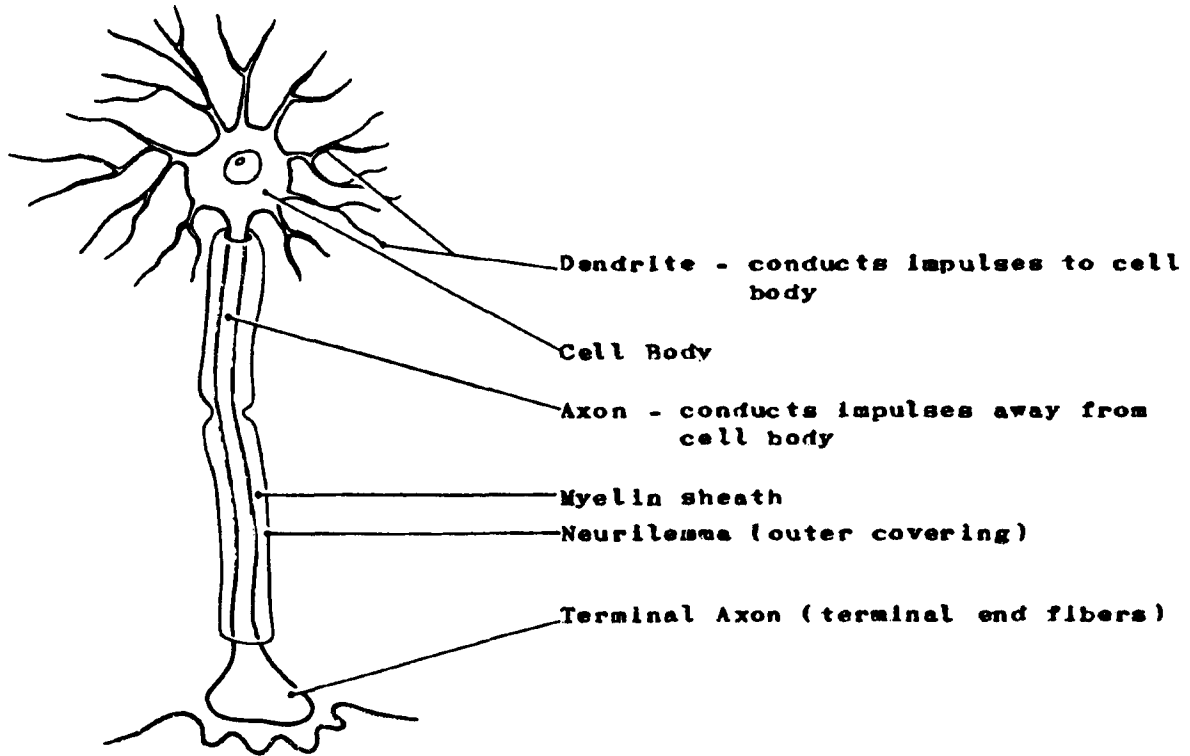
The neuroglial cells of the nervous system provide the connective tissue which binds together the neurons in the central nervous system giving support and protection. They consist of astrocytes, oligodendrites, ependymal cells, and microglial cells. Most central nervous system (CNS) tumors arise in the neuroglial cells.

- *Schwann cells*

The Schwann cells form a sheath (neurilemma) covering the axons of peripheral nerve fibers.

The processes of the neurons (nerve fibers) may serve sensory or motor functions. *Sensory nerve fibers* carry messages of sensation and feeling from the tissues and organs to the brain and spinal cord. *Motor nerve fibers* carry messages pertaining to movement from the brain and spinal cord to tissues and organs.

Figure 70. NERVE CELL (neuron)



Q1

The central nervous system is made up of the _____ and the _____
_____.

Q2

The nerves outside the central nervous system comprise the _____ nervous system.

Q3

Match each nerve on the left with its function on the right.

- | | | |
|-----|-------------------|--|
| ___ | 1. Motor nerves | a. Carry messages to the brain from the tissues and organs |
| ___ | 2. Sensory nerves | b. Carry messages from the brain to the tissues and organs |

Q4

A neurilemma is found only on nerves of the _____ nervous system.

What is the significance of the neurilemma? _____

Q5

Name the parts of the nerve cell:

1. _____
2. _____
3. _____
4. _____
5. _____

Answer: Q1

The central nervous system is made up of the brain and the spinal cord.

Answer: Q2

The nerves outside the central nervous system comprise the peripheral nervous system.

Answer: Q3

<u>b</u>	1.	Motor nerves	Carry messages from the brain to the tissues and organs
<u>a</u>	2.	Sensory nerves	Carry messages from the tissues and organs to the brain

Answer: Q4

A neurilemma is found only on nerves of the peripheral nervous system.

The neurilemma promotes peripheral nerve fiber regeneration.

Answer: Q5

The names of the parts of the nerve cell are as follows:

1. Dendrites
2. Cell body
3. Axons
4. Myelin sheath
5. Neurilemma

CENTRAL NERVOUS SYSTEM

The central nervous system (CNS) consists of the brain (encephalon), spinal cord, and meninges.

Brain

The brain lies within the cranial cavity of the skull. It may be described in terms of three main subdivisions: forebrain, midbrain, and hindbrain.

Forebrain

The forebrain consists of the cerebrum (telencephalon) and the diencephalon.

- The *cerebrum* is the largest part of the human brain, and controls, for example, voluntary muscular activity, speech, thought, memory, vision, taste, and hearing. It is made up of two cerebral hemispheres. The folds on the surface of the brain are known as convolutions. The cerebral hemispheres enclose the lateral ventricles (canals in the interior of the brain filled with cerebrospinal fluid). The two hemispheres are connected by the *corpus callosum*. Each hemisphere consists of:
 1. The *cerebral cortex* forms the outer layer. It contains the cell bodies of *neurons* often called the "gray matter" of the brain. (The inner "white matter" is made up of myelinated nerve fibers.)
 2. The *basal ganglia* lie deep within the hemispheres and are responsible for voluntary muscle movement. Basal ganglia are masses of gray matter.
 3. *Olfactory bulbs* (rhinocephalon) lie on the ventral surface of each cerebral hemisphere and are associated with the sense of smell (cranial nerve I).

The *cerebrum* is divided into lobes designated as frontal, temporal, parietal and occipital (see Figure 71).

- The *diencephalon* or thalamencephalon connects the cerebral hemispheres with the midbrain and forms the walls of the third ventricle.
 1. The *thalamus* is an important relay center for sensory fibers on their way to the cerebral cortex; crude sensation and pain may be registered here.
 2. The *hypothalamus* contains the centers for the autonomic nervous system controlling sleep, water balance, temperature regulation, and secretions from the pituitary gland.
 3. The *epithalamus* contains the pineal body (gland).

Figure 71. CEREBRUM

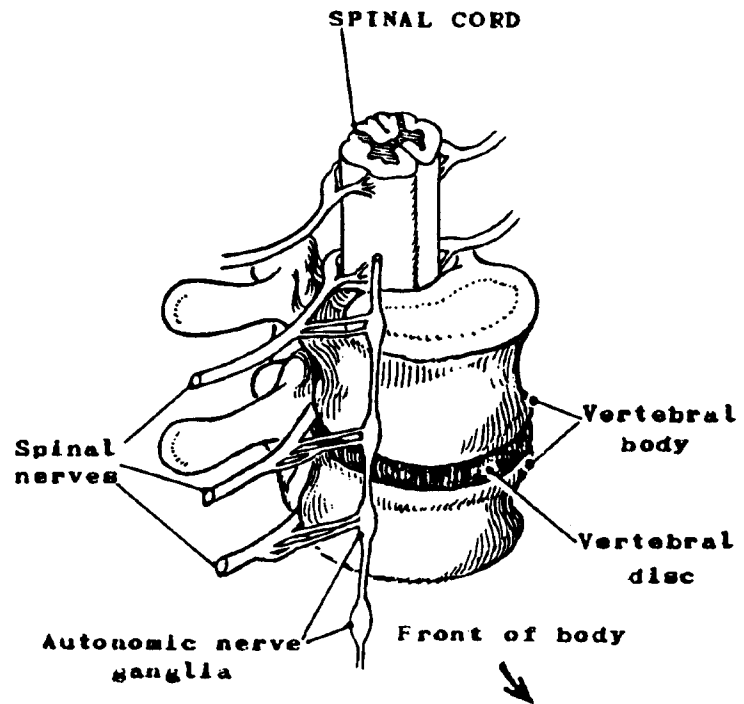
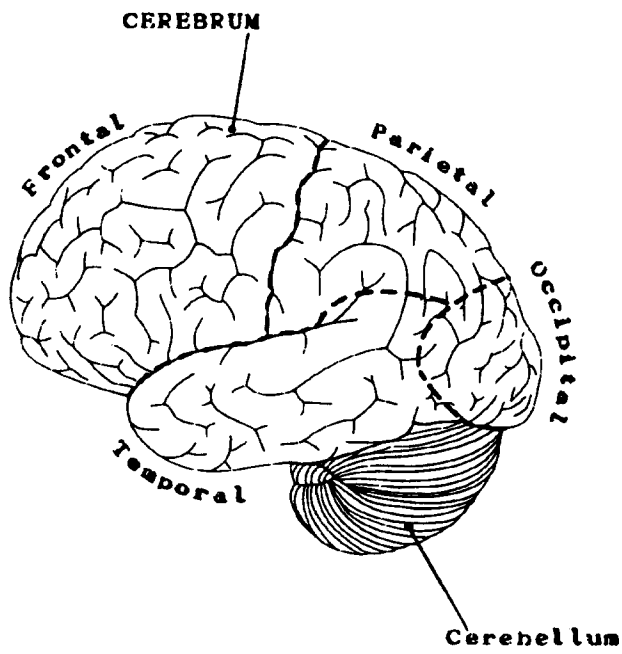


Figure 72. SPINAL CORD

Midbrain (mesencephalon)

The midbrain receives impulses from the eye and ear. It serves as a center for *visual* and *auditory* reflexes. It also connects the forebrain to the hindbrain. Cranial nerves III and IV stem from the midbrain.

Hindbrain (rhombencephalon)

The hindbrain consists of the pons, the cerebellum, and the medulla oblongata. It surrounds the fourth ventricle.

- The *pons* (pons - bridge) bridges the cerebrum and cerebellum. It contains nerve fibers which link the cerebral cortex with the medulla oblongata and the spinal cord.
The *nuclei* of the cranial nerves V, VI, VII, and VIII are situated in the pons.
- The *medulla oblongata* controls breathing and heartbeat. It consists of neurons which form the nuclei of the cranial nerves IX, X, XI, and XII.
- The *cerebellum* has centers which are concerned with balance and equilibrium. The function of the cerebellum is coordinating groups of muscles to work together smoothly.

Spinal Cord

The spinal cord lies in the vertebral canal of the spinal column and extends from the medulla oblongata to the lumbar vertebrae. There are 31 pairs of spinal nerves, both motor and sensory. The spinal cord also serves as a reflex center.

In certain areas of the spinal cord the anterior rami (branches) of the spinal nerves combine to form networks of nerve fibers called plexuses. These are the cervical (first 4 cervical spinal nerves) brachial (last 4 cervical and first thoracic spinal nerve), lumbar (first 4 lumbar nerves), sacral (fourth and fifth lumbar and first sacral nerve), pudendal (third and fourth sacral nerves), and coccygeal (fifth sacral and coccygeal nerve) plexuses.

Meninges

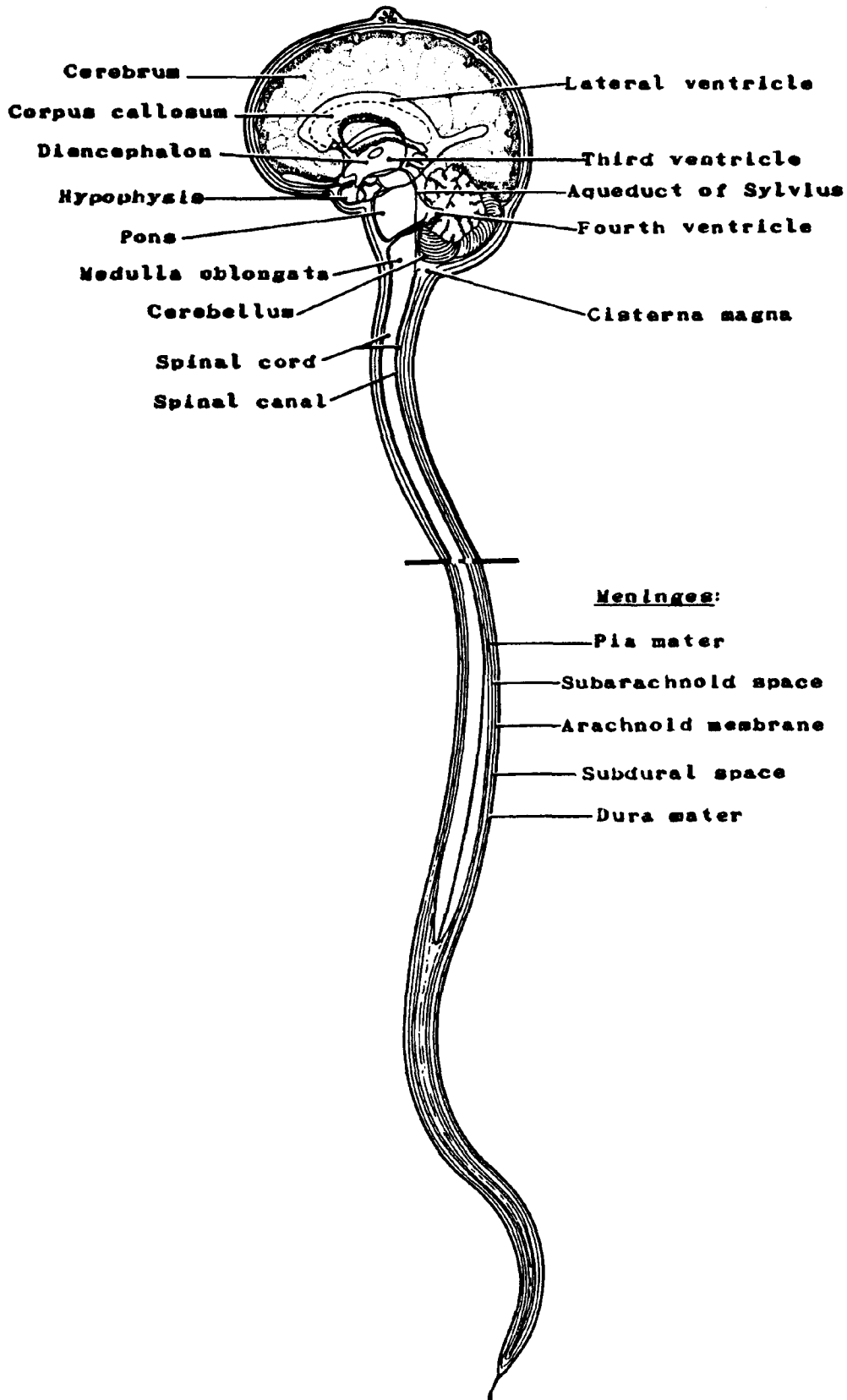
The meninges are comprised of three membranes which surround the brain and spinal cord. The *dura mater* is a thick, tough membrane lining the skull. The *pia mater* is the thin innermost layer which is in contact with the brain. The *arachnoid mater* lies between the two; it is a thin covering and contains the blood vessels.

Cerebrospinal Fluid (CSF)

Cerebrospinal fluid is found in each ventricle and is formed by filtration out of the blood in networks of capillaries known as choroid plexuses.¹

¹choroid plexus--vascular fringed folds in the pia mater of the cerebral ventricles.

Figure 73. DIAGRAM SHOWING BRAIN, VENTRICLES, MENINGES AND INTERMENINGEAL SPACES



PERIPHERAL NERVOUS SYSTEM

The peripheral nervous system (PNS) consists of nerves and ganglia outside the brain and spinal cord. It (PNS) serves to interconnect all other tissues with the central nervous system.

Peripheral nerves are connected to the spinal cord by two roots: the anterior, ventral, or motor root and the posterior, dorsal, or sensory root.

Peripheral nervous system innervates all voluntary muscles and transmits the sensory impulses from the whole body. It is largely under conscious (cerebral) control.

Thus, injury or disease of peripheral nerves usually results in both sensory and motor loss. Because of the regenerative ability of the neurilemma, however, eventual recovery is possible if the nerve is largely intact or the ends of the divided nerve are placed close together.

Autonomic Nervous System

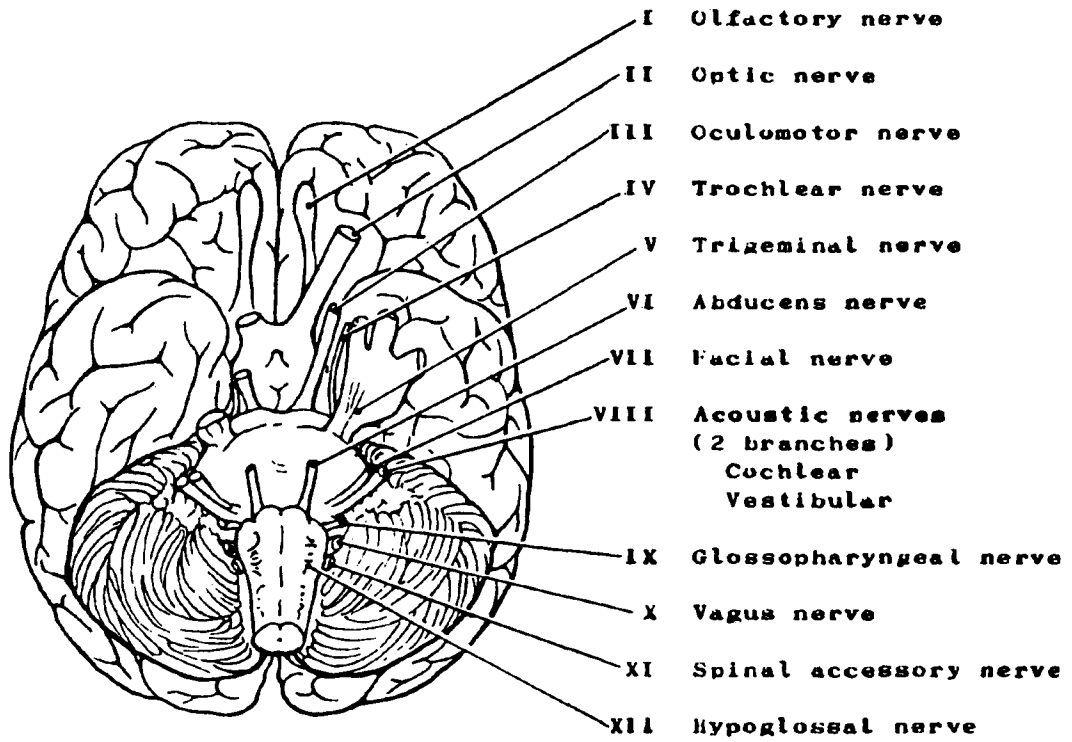
The autonomic nervous system is a subdivision of the peripheral nervous system and carries impulses from the brain and spinal cord to body organs. It controls and regulates largely by involuntary action of the glands, heart, and smooth muscle tissues (e.g., smooth muscle in the intestines and blood vessel walls).

Autonomic nerves arise at different levels of the central nervous system. The autonomic nerves arising from the spinal cord comprise the sympathetic (thoracolumbar) and parasympathetic (craniosacral) nervous system.

Spinal Nerves

There are 31 pairs of spinal nerves: 9 pairs of cervical nerves, 12 pairs of thoracic nerves, 5 pairs of lumbar nerves, 5 pairs of sacral nerves, and 1 pair of coccygeal nerves. All spinal nerves carry impulses between the spinal cord and the abdomen, chest, and extremities.

Figure 74 CRANIAL NERVES



Cranial Nerves

The cranial nerves carry impulses to or from the brain.

	<u>Cranial Nerves</u>	<u>Motor Function</u>	<u>Sensory Function</u>
I	Olfactory	None	Smell
II	Optic	None	Sight
III	Oculomotor	All eye muscles except the superior oblique and the external rectus; also innervates the iris and ciliary body	
IV	Trochlear	Superior oblique muscle Eye movement	
V	Trigeminal	Muscles of mastication	Sensations from eye, face, sinuses, and teeth
VI	Abducens	External rectus muscle Eye movement	
VII	Facial	Facial muscles, submaxillary and sublingual salivary glands	Tactile and taste sensations from the anterior 2/3's of tongue and soft palate
VIII	Acoustic: (2 branches) Cochlear Vestibular	None	Hearing Equilibrium/balance
IX	Glossopharyngeal	Pharyngeal muscles and parotid gland	Tactile and taste sensations from the posterior 1/3 of tongue, tonsils, pharynx, and carotid sinuses
X	Vagus	Pharynx, larynx, heart, lungs, bronchi, and digestive tract	Sensations to the heart, lungs, bronchi, trachea, pharynx, digestive system, and external ear
XI	Spinal Accessory	Sternomastoid, trapezius, and constrictor muscles of pharynx, larynx, and soft palate	
XII	Hypoglossal	Strap muscles of neck and tongue muscles	

Malignant Tumors

Gliomas are tumors of the neuroglia which comprise the non-nervous, supporting tissue of the brain derived chiefly from ectoderm. The most frequently occurring types are:

- *Astrocytoma* arises from glial cells known as astro- (star-shaped) cytes (cells). Glial cells (neuroglia), which may be either protoplasmic or fibrous, provide the connective tissue which binds together the neurons of the central nervous system. This tumor generally occurs in the cerebrum of adults and the cerebellum of children and is the most common type of glioma.
- *Glioblastoma* (multiforme) is derived from embryonal astrocytes and is sometimes called Grade IV astrocytoma. It is the most malignant of all brain tumors and occurs most frequently in adults arising in the cerebral hemispheres.
- *Oligodendroglioma* arises from glial cells known as oligo- (small, few) dendro- (branching) glia. These supporting cells are located as satellites about the nerve cells, between nerve fibers, and along blood vessels. These tumors occur more commonly in the cerebral hemispheres of adults.
- *Medulloblastoma* is composed of undifferentiated neuroepithelial cells. It is one of the most frequent gliomas of childhood and tends to occur at the midline of the cerebellum; in young adults it is found more often in the lateral lobes of the cerebellum. These tumors have a proclivity for intercranial or intraspinal metastases.
- *Ependymoma* arises from the ependymal cells which line the ventricles of the brain and the central canal of the spinal cord. It is found most often in the fourth ventricle occurring in children and young adults.

Nerve Sheath Tumors

- *Neurilemmoma* (neurinoma, schwannoma) arises from the neur- (nerve) (e)lemma (covering) which is the thin membrane covering the peripheral nerves, also called the sheath of Schwann. These tumors are usually benign, but may occasionally occur in a malignant form. In the cranial cavity, they frequently arise at the root of the VIIIth nerve (cerebellopontine angle) and are called acoustic neuromas.
- *Neurofibrosarcoma* is composed of interlacing bundles of anaplastic spindle-shaped cells which resemble those of nerve sheaths.

Neuroepitheliomatous Neoplasms

- *Neuroblastoma* is derived from embryonic nerve tissue (neuroblasts) arising primarily in the autonomic nervous system and adrenal medulla, but not in the brain or spinal cord.
- *Meningiomas* arise in the meninges, the membranes that envelop the brain and spinal cord: the dura mater, pia mater, and arachnoid. These are slow growing tumors and are most always benign. They are rare in children.

Benign Tumors

Benign tumors of the brain, while not invasive, do consume space and press upon vital tissues. These tumors are, thereby, potentially lethal, although they do allow for more prolonged survival than do malignant brain tumors. Consequently, cancer registries generally collect information on benign brain tumors as well as malignant brain tumors.

Some benign tumors are collected because they arise in the cranial vault, although they are not central nervous system (CNS) tumors.

- *Hemangioblastoma* is a hemangioma of the brain derived from blood vessel-forming cells (angioblasts).
- *Craniopharyngioma* is a tumor arising from embryonic cells of the craniopharyngeal canal (Rathke's pouch) and involving the pituitary gland. The tumor usually occurs in children.
- *Chromophobe Adenoma* is a benign tumor of the anterior pituitary gland. It is associated with hypopituitarism and occurs mainly in adults.

Q6

Match each term on the left with one of the descriptions on the right.

- | | | | | |
|---|----|-----------------|----|--|
| — | 1. | Astrocytoma | a. | Tumor of the membranes surrounding the brain and spinal cord |
| — | 2. | Neuroglia | b. | The most common malignant brain tumor |
| — | 3. | Medulloblastoma | c. | The most malignant of all brain tumors |
| — | 4. | Meningioma | d. | Non-nervous tissue which supports the nerve cells |
| — | 5. | Glioblastoma | e. | Tumor of the brain which is most common in the cerebellum of children. |

Q7

Which of the following are nerves of the autonomic nervous system?

- a. Sympathetic nerves
- b. Spinal nerves
- c. Cranial nerves

Answer: Q6

Match each term on the left with one of the descriptions on the right.

- | | | | |
|----------|----|-----------------|--|
| <u>b</u> | 1. | Astrocytoma | The most common malignant brain tumor |
| <u>d</u> | 2. | Neuroglia | Non-nervous tissue which supports the nerve cells |
| <u>e</u> | 3. | Medulloblastoma | Tumor of the brain which is most common in the cerebellum of children. |
| <u>a</u> | 4. | Meningioma | Tumor of the membranes surrounding the brain and spinal cord |
| <u>c</u> | 5. | Glioblastoma | The most malignant of all brain tumors |

Answer: Q7

The sympathetic nerves are nerves of the autonomic nervous system.

SECTION N
SENSORY ORGANS

SECTION N

SENSORY ORGANS

There are five major senses of the body: vision, taste, smell, hearing, and touch. The body, however, has literally millions of sensory organs (or receptors), each associated with one or more nerves whose function is to convert the energy of a stimulus into a sensation or reflex. Receptors detect changes in our external and internal environment and initiate the responses necessary for adjusting the body to these changes. It is the dendrite portion of the sensory neuron which serves as the receptor of a sense organ.

Receptors may be classified according to their locations as follows:

Exteroceptors are surface receptors. They are located in the skin, mucosa, eye, and ear.

Visceroceptors (interoceptors) are located in the walls of the blood vessels in the stomach, intestines, and various other organs.

Proprioceptors are located in muscles, tendons, joints, and the internal ear.

In this section, we will not cover all the body senses. Rather, the discussion will be restricted to four of the major senses: vision, taste, smell, and hearing.

Q1

What are the five major senses of the body?

1. _____
2. _____
3. _____
4. _____
5. _____

Q2

Match the receptors on the left with a location on the right.

	<u>Receptors</u>	<u>Location</u>
___	1. Exteroceptors	a. Located in the walls of blood vessels in the stomach, intestines, and other organs
___	2. Proprioceptors	b. Located in the skin, mucosa, eye, and ear
___	3. Visceroceptors	c. Located in the muscles, tendons, joints, and the internal ear

Answer: Q1

The five major senses of the body are:

1. Vision
2. Hearing
3. Taste
4. Smell
5. Touch

Answer: Q2

- | | | |
|----------|-------------------|--|
| <u>b</u> | 1. Exteroceptors | Located in the skin, mucosa, eye, and ear |
| <u>c</u> | 2. Proprioceptors | Located in the muscles, tendons, joints, and the internal ear |
| <u>a</u> | 3. Visceroceptors | Located in the walls of blood vessels in the stomach, intestines, and other organs |

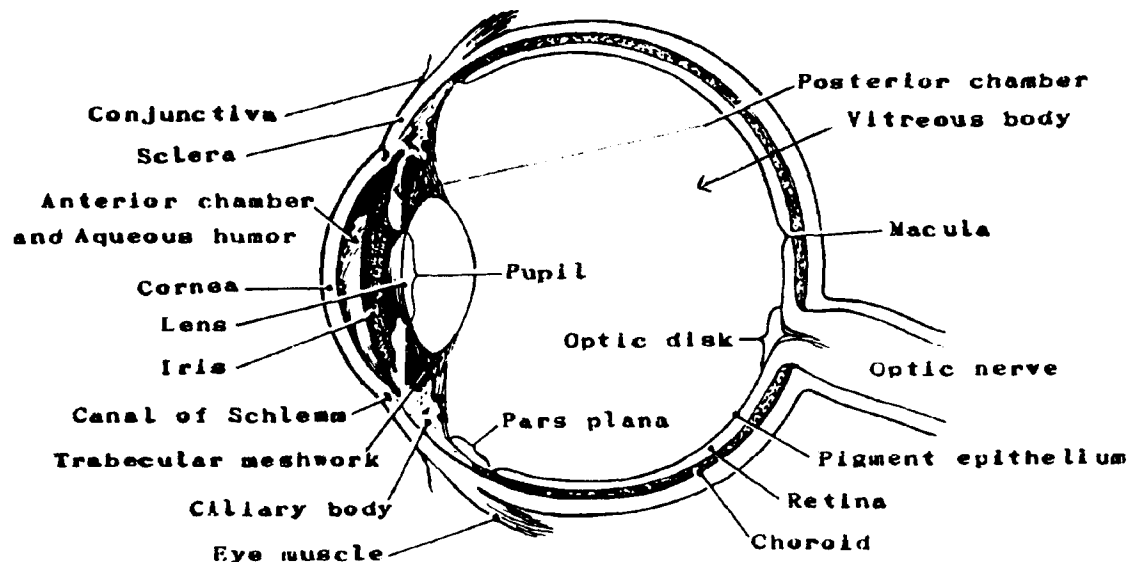
The Sense of Vision (Eye)

The *eye* is set in a bony socket, the orbit. The visible portion of the eye is covered by a thin transparent membrane called the conjunctiva¹.

The *eyeball* is not a solid sphere. It contains a large interior cavity that is divided into two parts, the anterior and posterior cavities. The anterior cavity, in turn, has two subdivisions known as the anterior chamber and the posterior chamber. Most of the eyeball (Figure 76) is recessed in the orbit, protected by the walls of this bony cavity. The wall of the eyeball is composed of three layers; from the outside to the inside, they are the sclera, the choroid, and the retina.

- The *sclera*, composed of tough fibrous tissue, is the protective and supportive layer of the eye. The anterior portion of the sclera, called the cornea, lies over the colored part of the eye (iris) and the pupil. The cornea is transparent and allows passage of light.
- The middle or *choroid* layer (the pigmented vascular coat) of the eye contains a great many blood vessels. The iris, the colored muscular ring, controls the size of the pupil and the amount of light entering the eye. The anterior portion is modified to form the ciliary body, the main part of which is ciliary muscle. Its function is the adjustment of the lens of the eye for vision at different distances. The crystalline lens is suspended from the inner surface of the ciliary body by circular ligaments called the suspensory ligaments. The function of the lens is to bend light rays in order to focus an image on the retina.
- The *retina* is the innermost layer of the eye. It is composed of two sections: the outer is pigmented and attached to the choroid layer, and the inner is composed of nervous tissue. The retina is the light sensitive layer.

Figure 75. EYE



¹conjunctiva--mucous membrane covering the anterior portion of the eyeball, and lining the eyelids.

Q3

What are the three layers which compose the wall of the eyeball?

1. _____
2. _____
3. _____

Q4

The retina is composed of _____ tissue.

Answer: Q3

The three layers which compose the wall of the eyeball are:

1. Sclera
2. Choroid
3. Retina

Answer: Q4

The retina is composed mainly of nervous tissue.

The *accessory structures* of the eye include the eyebrow, eyelashes, and eyelid. The eyebrow and eyelashes serve a protective function. The eyelid is lined with mucous membrane (called conjunctiva) which continues over the surface of the eyeball. The corner where the upper and lower eyelids join is called the *canthus*, the medial canthus being on the innerside, the internal (temporal) canthus being on the outer side. The *lacrimal apparatus* consists of four structures: the lacrimal glands, lacrimal ducts, lacrimal sac, and nasolacrimal duct. These structures perform the functions of secreting and draining tears on the surface of the eyeball (Figures 76 and 77).

Figure 76. EYEBALL (sagittal view)

Figure 77. EYEBALL (frontal view)

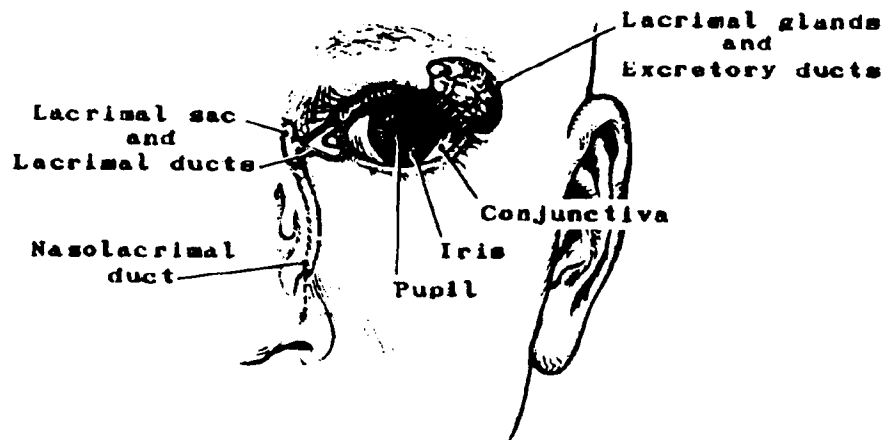
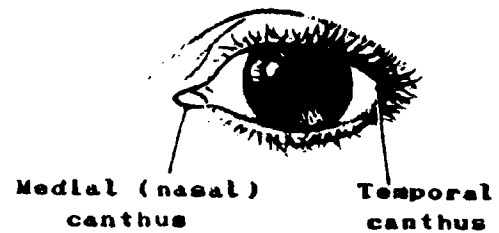


Figure 78. LACRIMAL APPARATUS

Q5

The eyeball is/is not a solid sphere. It is divided into two large _____.

Q6

The corner where the upper and lower eyelids meet is called the _____.

Q7

The _____ apparatus performs the function of secreting tears.

Answer: Q5

The eyeball *is not* a solid sphere. It is divided into two large cavities.

Answer: Q6

The corner where the upper and lower eyelids meet is called the canthus.

Answer: Q7

The lacrimal apparatus performs the function of secreting tears.

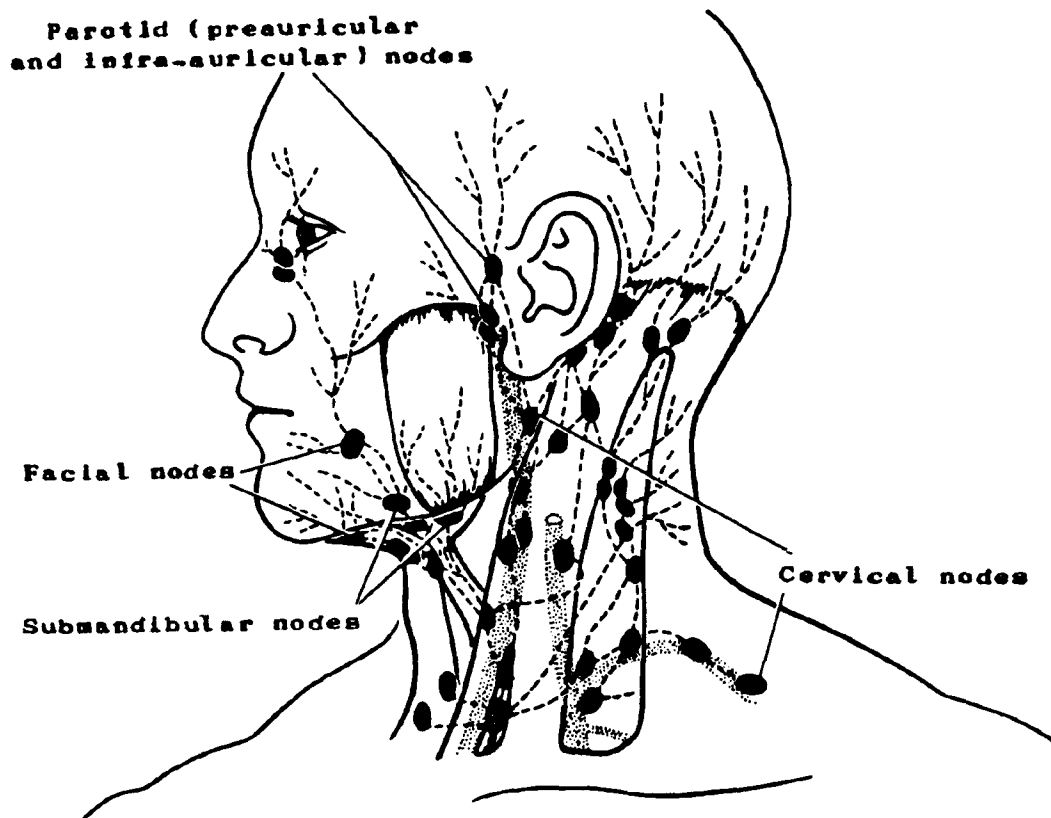
Regional Lymph Nodes

Much of the eye does not have true lymphatics, i.e., cornea, sclera, uveal tract, lens, retina, and orbit. The conjunctiva and the eyelid are drained by the submandibular, preauricular and infra-auricular (parotid) and cervical lymph nodes.

Malignant Tumors

- Malignant melanoma is the most common intraocular tumor.
- Retinoblastoma, a tumor arising from the retinal germ cells, is the most common intraocular neoplasm in children.
- Epidermoid carcinoma may arise from conjunctiva.

Figure 79. LYMPHATIC DRAINAGE OF THE HEAD (sensory organs)



Q8

Name the lymph nodes which drain each of the following areas of the eye:

1. Cornea, sclera, and lens: _____.
2. Eyelid: _____, _____, and _____.

Q9

The most common malignancy of the eye is _____.

Q10

The most common eye malignancy in children is _____.

Answer: Q8

Name the lymph nodes which drain each of the following areas of the eye:

1. Cornea, sclera, and lens: no true lymphatics
2. Eyelid: submandibular, preauricular (parotid), and cervical.

Answer: Q9

The most common malignancy of the eye is malignant melanoma.

Answer: Q10

The most common eye malignancy in children is retinoblastoma.

The Sense of Taste (Gustatory Sense Organ)

Receptors for the sense of taste are known as taste buds. These are located on the tongue, palate, pharynx, and epiglottis. They are most numerous on the tongue. Different taste receptors are stimulated by different kinds of substances. There are separate taste buds for sweet, sour, bitter, and salt substances (see Figure 80). All other qualities of experienced taste are a result of the fusion of two or more of the four primary tastes and as a result of the stimulation of the olfactory receptors. Therefore, the numerous tastes recognized are not taste alone but taste plus odors.

The four kinds of taste buds or corpuscles are not evenly distributed over the tongue. Most of those sensitive to bitter are located at the back of the tongue, those sensitive to sweet at the tip, and those sensitive to salt and sour along the sides and tip. (Refer to the Digestive System for the anatomy of the tongue.)

Regional Lymph Nodes

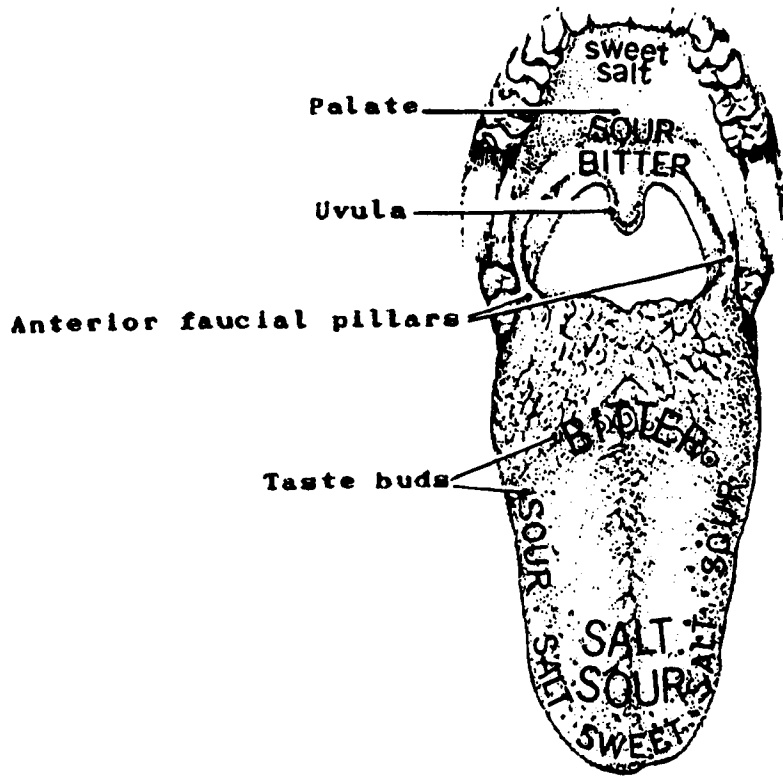
The regional lymph nodes are submandibular (submaxillary), submental and internal jugular (upper and lower deep cervical): jugulodigastric and jugulo-omohyoid.

Malignant Tumors

Malignant lesions are more common on the anterior two-thirds than on the posterior one-third of the tongue. Squamous cell carcinomas constitute 90 percent of all malignant tumors of the tongue. The other 10 percent are made up primarily of lymphoepitheliomas and lymphosarcomas.

Lymphosarcomas will arise in the lymphoid tissue (lingual tonsil) found at the base of the tongue.

Figure 80. TONGUE: Areas of taste



Q11

Receptors for the sense of taste called _____ are most numerous in the _____.

Q12

Separate receptors sense the tastes of _____, _____, _____, and _____; but all other qualities of taste are a result of a fusion of two or more primary tastes and the stimulation of the _____.

Answer: Q11

Receptors for the sense of taste called taste buds are most numerous in the tongue.

Answer: Q12

Separate receptors sense the taste of sweet, sour, bitter, and salt, but all other qualities of taste are a result of a fusion of two or more primary tastes and the stimulation of the olfactory receptors.

The Sense of Smell (Olfactory Sensory Organs)

The receptors for the sense of smell lie in the mucosa of the upper part of the nasal cavity. These receptors respond to chemical stimuli. Their location explains the necessity for sniffing or drawing air forcibly into the nose in order to smell delicate odors. The olfactory sensory organs consist of hair cells which are extremely sensitive to stimulation by even very slight odors. However, they are also easily fatigued. This explains why odors that are at first very noticeable are not sensed at all after a short time.

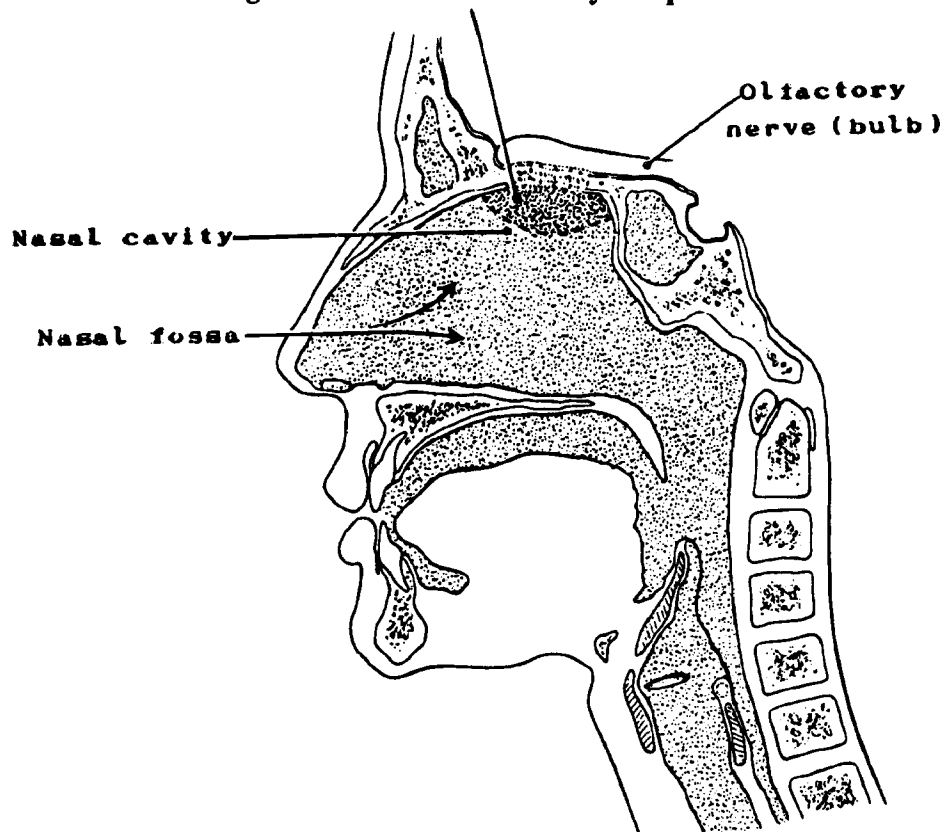
The term "nasal fossa" is the name for the entire nasal chamber. This chamber is divided physiologically into:

- A lower or respiratory portion of the nasal fossa
- An upper or olfactory portion of the nasal fossa. The term "nasal cavity" most properly belongs to this upper portion of the nasal fossa.

Regional Lymph Nodes

The regional lymph nodes are the submental, submandibular (submaxillary), and internal jugular (upper and lower deep cervical) nodes: jugulodigastric and jugulo-omohyoid, and the retropharyngeal.

Figure 81. NOSE: Olfactory receptors



Malignant Tumors

Tumors of the nasal fossa are rare. The most common type is squamous cell (epidermoid) carcinoma. Other types which occur less frequently are:

- Adenocarcinoma
- Adenoid cystic
- Melanoma
- Lymphoma

A malignant tumor known as esthesioneuroblastoma or esthesioneuroepithelioma, which arises in the olfactory nerve, will be found occasionally in the nasal cavities.

Q13

The nasal fossa is divided into a lower or _____ portion and an upper or _____ portion.

Q14

The receptors for the sense of smell lie in the mucosa of the _____ part of the _____ cavity.

Q15

The most common type of tumor in the nasal cavities is _____.

Answer: Q13

The nasal fossa is divided into a lower or respiratory portion and an upper or olfactory portion.

Answer: Q14

The receptors for the sense of smell lie in the mucosa of the upper part of the nasal cavity.

Answer: Q15

The most common type of tumor in the nasal cavities is squamous cell carcinoma.

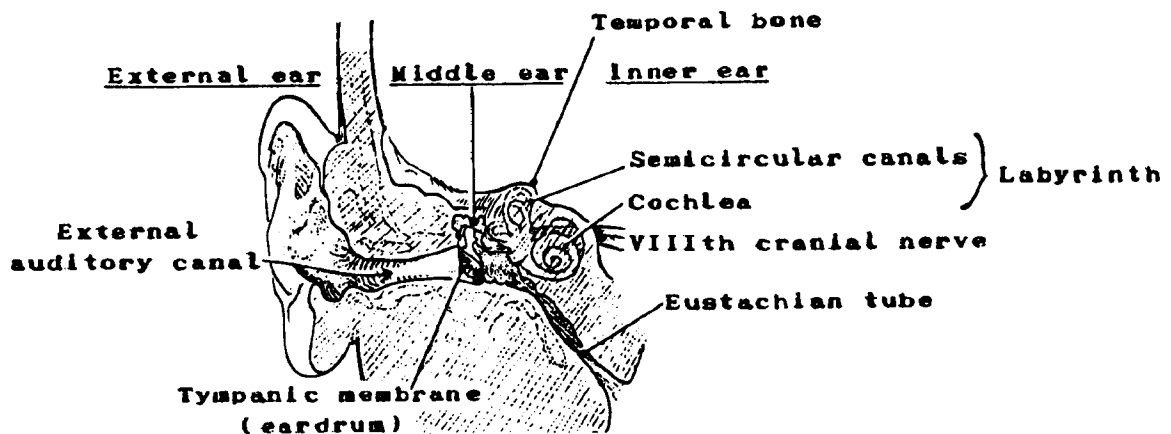
The Sense of Hearing (Ear)

The organ for hearing (see Figure 82) consists of three main parts: the external ear, the middle ear, and the inner ear.

- The *external ear* is made up of the pinna (or auricle) and the auditory canal. The pinna (pinna-wing) is made up of cartilage covered by skin. It collects the sound which is transmitted through the external auditory canal, leading to the tympanic membrane (or eardrum).
- The *middle ear* lies in a cavity in the temporal bone and is separated from the external ear by the tympanic membrane which transmits sounds to the internal ear. The middle ear is connected with the nasopharynx by the Eustachian tube. The function of the Eustachian tube is to equalize pressure on the eardrum. It opens when yawning or swallowing takes place.
- The *inner ear* is comprised of membranous tissue contained within a bony structure. The bony labyrinth has three divisions: the vestibule and two extensions of the vestibule called the cochlea and the semicircular canals. The cochlea is a spiral canal containing a receptor for hearing called the Organ of Corti. It has hair cells which pick up impulses transmitted from the inner ear.

The semicircular canals form the organ of balance. The superior, posterior, and lateral semicircular canals each connect by an ampulla (jug) to the utricle (a small sac), from which impulses travel to the brain by the vestibular branch of the VIIIth cranial nerve.

Figure 82. EAR: Coronal section



Regional Lymph Nodes

The lymphatics of the external and middle ear drain to parotid (preauricular) lymph nodes. The middle ear lymphatics, in addition, drain to retropharyngeal nodes. Lymphatics from both parts of the ear go directly or indirectly to the internal jugular (upper and lower deep cervical) nodes. The inner ear has no lymphatics.

Benign Tumors

Acoustic neuroma, a benign tumor of the auditory nerve, is the most common tumor of the ear.

Q16

Match the parts of the ear on the left with the descriptions on the right.

- | | | | | |
|---|----|--------------|----|---|
| — | 1. | External ear | a. | Contains the receptors for hearing |
| — | 2. | Middle ear | b. | Made up of the auricle and the auditory canal |
| — | 3. | Inner ear | c. | Contains the opening from the Eustachian tube |

Answer: Q16

- | | | |
|----------|-----------------|---|
| <u>b</u> | 1. External ear | Made up of the auricle and the auditory canal |
| <u>c</u> | 2. Middle ear | Contains the opening from the Eustachian tube |
| <u>a</u> | 3. Inner ear | Contains the receptors for hearing |

APPENDIX A
HISTOLOGIC TYPE/PRIMARY SITE

APPENDIX A: HISTOLOGIC TYPE/PRIMARY SITE

HISTOLOGIC TYPE	PRIMARY SITE
Squamous cell carcinoma	Oral and nasal cavities Pharynx and larynx Trachea, bronchus, and lung Esophagus Cervix, vagina, and vulva Anus and penis Skin
Adenocarcinoma	Stomach Small intestine Colon and rectum Pancreas and gallbladder Endometrium and endocervix Breast Prostate
Transitional cell carcinoma	Bladder and urethra Renal pelvis and ureters
Hepatoma Liver cell carcinoma	Liver
Cholangiocarcinoma Hypernephroma Renal cell carcinoma Wilms' Tumor	Bile ducts (intrahepatic and extrahepatic) Kidney parenchyma
Seminoma Dysgerminoma Cystadenocarcinoma Granulosa/theca cell carcinoma	Testis Ovary
Liposarcoma Fibrosarcoma Leiomyosarcoma Rhabdomyosarcoma Mesothelial sarcoma	Adipose soft tissue Fibrous soft tissue Smooth muscle, muscularis of organ walls Striated muscle, skeletal muscle Pleura and peritoneum
Osteogenic sarcoma Ewing's sarcoma Chondrosarcoma	Bone Cartilage
Lymphosarcoma Malignant lymphoma Hodgkin's disease Reticulum cell sarcoma	Lymph nodes and other aggregates of lymphoid tissue
Lymphangiosarcoma Hemangiosarcoma	Lymph vessels Blood vessels

HISTOLOGIC TYPE	PRIMARY SITE
Leukemias	Bone marrow
Multiple myeloma	
Astrocytoma	Brain
Glioblastoma multiforme	
Medulloblastoma	
Melanoma	Skin
	Eye

APPENDIX B

**RULES FOR DETERMINING MULTIPLE PRIMARIES FOR LYMPHATIC AND
HEMATOPOIETIC DISEASES**

APPENDIX B

RULES FOR DETERMINING MULTIPLE PRIMARIES FOR LYMPHATIC AND HEMATOPOIETIC DISEASES

The table on pages 446-468 is to be used to help determine multiple primaries of the lymphatic and hematopoietic diseases. Because of the rarity of subacute leukemias and aleukemias, they have been excluded from this table. Similarly, malignant myeloproliferative and immunoproliferative diseases, except Waldenstrom's macroglobulinemia, are not included.

RULES:

1. No topography (site) is to be considered in determining multiple primaries of lymphatic and hematopoietic diseases.
2. The interval between diagnoses is NOT to enter into the decision.

Example: A lymphocytic lymphoma (M-9670/3) diagnosed in March, 1987 and an unspecified non-Hodgkin's lymphoma (M-9590/3) diagnosed in April, 1988 would be considered one primary, a lymphocytic lymphoma diagnosed in March, 1987 (the earlier diagnosis).

To use this table locate the first diagnosis in the left column of the table, then locate the second diagnosis in the other columns. If the second primary appears in the middle column, the diagnoses are usually considered two separate primaries. If the second diagnosis appears in the right hand column, then the two diagnoses are usually considered one primary. Select the disease mentioned in the first column unless there is an indication in the right hand column to do otherwise. If the pathology report specifically states differently, use the pathology report. Consult your medical advisor or pathologist if questions remain.

For example,

- 1) a. first diagnosis: small cleaved cell, diffuse lymphoma
b. second diagnosis: Hodgkin's disease, mixed cellularity

This case would be considered two primaries.

- 2) a. first diagnosis: small cleaved cell, diffuse lymphoma
b. second diagnosis: acute lymphocytic leukemia

This case would be considered one primary.

**DETERMINATION OF SUBSEQUENT PRIMARIES OF
LYMPHATIC (NODAL AND EXTRANODAL) AND HEMATOPOIETIC DISEASES**

First Primary	Presumably a Second Primary	Presumably NOT a Subsequent Primary (only One Primary)
Hodgkin's disease (9650-9667)	Non-Hodgkin's lymphoma (9591-9595, 9670-9686, 9690-9698, 9702-9714) Burkitt's lymphoma (9687) Mycosis fungoides or Sezary's disease (9700-9701) Malignant histiocytosis or Letterer-Siwe's disease (9720, 9722) True histiocytic lymphoma (9723) Plasmacytoma or multiple myeloma (9731, 9732) Mast cell tumor (9740-9741) Waldenstrom's macroglobulinemia (9761) Any leukemia (9800-9941)	Hodgkin's disease ¹ (9650-9667) Malignant lymphoma, NOS (9590)

¹Code to the term with the higher histology code.

**DETERMINATION OF SUBSEQUENT PRIMARIES OF
LYMPHATIC (NODAL AND EXTRANODAL) AND HEMATOPOIETIC DISEASES**

First Primary	Presumably a Second Subsequent Primary	Presumably NOT a Subsequent Primary (only One Primary)
Malignant lymphoma, NOS ¹ (9590)	Burkitt's lymphoma (9687) Mycosis fungoides or Sezary's disease (9700, 9701) Malignant histiocytosis or Letterer-Siwe's disease (9720, 9722) Mast cell tumor (9740, 9741) Acute leukemia, NOS (9801) Non-lymphocytic leukemias (9840-9842, 9860-9910) Myeloid sarcoma (9930) Acute panmyelosis (9931) Acute myelofibrosis (9932) Hairy cell leukemia (9940) Leukemic reticuloendotheliosis (9941)	Non-Hodgkin's lymphoma ² (9590-9595, 9670-9686, 9690-9698, 9702-9714) Hodgkin's disease ² (9650-9667) True histiocytic lymphoma (9723) Plasmacytoma ² or multiple myeloma (9731, 9732) Leukemia, NOS (9800) Chronic leukemia, NOS (9803) Lymphoid or lymphocytic leukemia (9820-9827) Plasma cell leukemia (9830) Lymphosarcoma cell leukemia (9850) Waldenstrom's macroglobulinemia (9761)

¹If the diagnosis includes "can't rule out leukemia" or "consistent with chronic lymphocytic leukemia," and a bone marrow or peripheral blood study within two months confirms the chronic lymphocytic leukemia diagnosis; then code only to chronic lymphocytic leukemia (9823/3). If not confirmed as chronic lymphocytic leukemia, then code as the lymphoma.

²Presumably this is the correct diagnosis. Code the case to this histology.

**DETERMINATION OF SUBSEQUENT PRIMARIES OF
LYMPHATIC (NODAL AND EXTRANODAL) AND HEMATOPOIETIC DISEASES**

First Primary	Presumably a Second Subsequent Primary	Presumably NOT a Subsequent Primary (only One Primary)
Non-Hodgkin's lymphoma ¹ (9591-9595, 9670-9686, 9690-9698, 9711-9714)	Hodgkin's disease (9650-9667); Burkitt's lymphoma (9687) Mycosis fungoides or Sezary's disease (9700, 9701) Malignant histiocytosis or Letterer-Siwe's disease (9720, 9722) Mast cell tumor (9740-9741) Acute leukemia, NOS (9801) Non-lymphocytic leukemias (9840-9842, 9860-9910) Myeloid sarcoma (9930) Acute panmyelosis (9931) Acute myelofibrosis (9932) Hairy cell leukemia (9940) Leukemic reticuloendotheliosis (9941)	Non-Hodgkin's lymphoma ² (9590-9595, 9670-9686, 9690-9698, 9702-9714) Plasmacytoma ³ or multiple myeloma (9731, 9732) True histiocytic lymphoma (9723) Leukemia, NOS (9800) Chronic leukemia, NOS (9803) Lymphoid or lymphocytic leukemia (9820-9827) Plasma cell leukemia (9830) Lymphosarcoma cell leukemia (9850) Waldenstrom's macroglobulinemia (9761)

¹If the diagnosis includes "can't rule out leukemia" or "consistent with chronic lymphocytic leukemia," and a bone marrow or peripheral blood study within two months confirms the chronic lymphocytic leukemia diagnosis; then code only to chronic lymphocytic leukemia (9823/3). If not confirmed as chronic lymphocytic leukemia, then code as the lymphoma.

²Code to the term with the higher histology code.

³Presumably this is the correct diagnosis. Code the case to this histology.

**DETERMINATION OF SUBSEQUENT PRIMARIES OF
LYMPHATIC (NODAL AND EXTRANODAL) AND HEMATOPOIETIC DISEASES**

First Primary	Presumably a Second Subsequent Primary	Presumably NOT a Subsequent Primary (only One Primary)
Burkitt's lymphoma (9687)	Specific non-Hodgkin's lymphoma (9593-9594, 9670-9686, 9690-9698, 9702-9714)	Malignant lymphoma, NOS (9590-9591, 9595)
	Hodgkin's disease (9650-9667)	Lymphosarcoma (9592)
	Mycosis fungoides or Sezary's disease (9700, 9701)	Burkitt's lymphoma (9687)
	Malignant histiocytosis or Letterer-Siwe's disease (9720, 9722)	Burkitt's leukemia (9826)
	Plasmacytoma or multiple myeloma (9731, 9732)	Lymphoid or lymphocytic leukemia (9820-9822, 9824-9825, 9827)
	True histiocytic lymphoma (9723)	
	Mast cell tumor (9740, 9741)	
	Waldenstrom's macroglobulinemia (9761)	
	Leukemia, NOS (9800)	
	Acute leukemia, NOS (9801)	
	Chronic leukemia, NOS (9803)	
	Chronic lymphocytic leukemia (9823)	
	Non-lymphocytic leukemias (9840-9842, 9860-9910)	

**DETERMINATION OF SUBSEQUENT PRIMARIES OF
LYMPHATIC (NODAL AND EXTRANODAL) AND HEMATOPOIETIC DISEASES**

First Primary	Presumably a Second Subsequent Primary	Presumably NOT a Subsequent Primary (only One Primary)
Burkitt's lymphoma (9687) (cont'd)	Plasma cell leukemia (9830) Lymphosarcoma cell leukemia (9850) Myeloid sarcoma (9930) Acute panmyelosis (9931) Acute myelofibrosis (9932) Hairy cell leukemia (9940) Leukemic reticuloendotheliosis (9941)	

**DETERMINATION OF SUBSEQUENT PRIMARIES OF
LYMPHATIC (NODAL AND EXTRANODAL) AND HEMATOPOIETIC DISEASES**

First Primary	Presumably a Second Subsequent Primary	Presumably NOT a Subsequent Primary (only One Primary)
Cutaneous and peripheral T-cell lymphomas (9700-9709)	Specific non-Hodgkin's lymphoma (9593-9594, 9670-9687, 9690-9698, 9711-9714)	Malignant lymphoma, NOS (9590-9591, 9595) Lymphosarcoma (9592)
	Hodgkin's disease (9650-9667)	Cutaneous and peripheral T-cell lymphomas (9700-9709)
	Malignant histiocytosis or Letterer-Siwe's disease (9720, 9722)	Leukemia, NOS (9800)
	True histiocytic lymphoma (9723)	Acute leukemia, NOS (9801)
	Plasmacytoma or multiple myeloma (9731, 9732)	Chronic leukemia, NOS (9803)
	Mast cell tumor (9740, 9741)	Lymphoid or lymphocytic leukemia unless specifically identified as B-cell (9820-9827)
	Waldenstrom's macroglobulinemia (9761)	
	Lymphoid or lymphocytic leukemia specified as B-cell (9820-9827)	
	Plasma cell leukemia (9830)	
	Non-lymphocytic leukemia (9840-9842, 9860-9910)	
	Lymphosarcoma cell leukemia (9850)	
	Myeloid sarcoma (9930)	
	Acute panmyelosis (9931)	
	Acute myelofibrosis (9932)	

**DETERMINATION OF SUBSEQUENT PRIMARIES OF
LYMPHATIC (NODAL AND EXTRANODAL) AND HEMATOPOIETIC DISEASES**

First Primary	Presumably a Second Subsequent Primary	Presumably NOT a Subsequent Primary (only One Primary)
Cutaneous and peripheral T-cell lymphomas (9700-9709) (cont'd)	Hairy cell leukemia (9940) Leukemic reticuloendotheliosis (9941)	

**DETERMINATION OF SUBSEQUENT PRIMARIES OF
LYMPHATIC (NODAL AND EXTRANODAL) AND HEMATOPOIETIC DISEASES**

First Primary	Presumably a Second Subsequent Primary	Presumably NOT a Subsequent Primary (only One Primary)
<p>Malignant histiocytosis or Letterer-Siwe's disease (9720, 9722, 9723)</p>	<p>Specific non-Hodgkin's lymphoma (9592-9594, 9670-9686, 9690-9698, 9702-9714)</p> <p>Hodgkin's disease (9650-9667)</p> <p>Burkitt's lymphoma (9687)</p> <p>Mycosis fungoides or Sezary's disease (9700, 9701)</p> <p>Plasmacytoma or multiple myeloma (9731, 9732)</p> <p>Mast cell tumor (9740, 9741)</p> <p>Waldenstrom's macroglobulinemia (9761)</p> <p>Leukemia except hairy cell and leukemic reticuloendotheliosis (9800-9932)</p>	<p>Non-Hodgkin's lymphoma, NOS (9590-9591, 9595)</p> <p>Malignant histiocytosis or Letterer-Siwe's disease (9720, 9722, 9723)</p> <p>Hairy cell leukemia (9940)</p> <p>Leukemic reticuloendotheliosis (9941)</p>

**DETERMINATION OF SUBSEQUENT PRIMARIES OF
LYMPHATIC (NODAL AND EXTRANODAL) AND HEMATOPOIETIC DISEASES**

First Primary	Presumably a Second Subsequent Primary	Presumably NOT a Subsequent Primary (only One Primary)
Plasmacytoma or multiple myeloma (9731, 9732)	Non-Hodgkin's lymphoma except immunoblastic or large-cell lymphoma (9592-9594, 9670, 9672-9677, 9683, 9685-9686, 9690-9697, 9702-9713) Hodgkin's disease (9650-9667) Burkitt's lymphoma (9687) Mycosis fungoides or Sezary's disease (9700, 9701) Malignant histiocytosis or Letterer-Siwe's disease (9720, 9722) True histiocytic lymphoma (9723) Mast cell tumor (9740, 9741) Leukemia except plasma cell (9800-9827, 9840-9941)	Malignant lymphoma, NOS (9590, 9591, 9595) Immunoblastic or large cell lymphoma ¹ (9671, 9680-9682, 9684, 9698, 9714) Plasmacytoma or multiple myeloma (9731, 9732) Waldenstrom's macroglobulinemia (9761) Plasma cell leukemia (9830)

Occasionally multiple myeloma develops an immunoblastic or large cell lymphoma phase. This is to be considered one primary, multiple myeloma. Consult your medical advisor or pathologist if questions remain.

**DETERMINATION OF SUBSEQUENT PRIMARIES OF
LYMPHATIC (NODAL AND EXTRANODAL) AND HEMATOPOIETIC DISEASES**

First Primary	Presumably a Second Subsequent Primary	Presumably NOT a Subsequent Primary (only One Primary)
Mast cell tumor (9740, 9741)	Non-Hodgkin's lymphoma (9590-9595, 9670-9687, 9690-9698, 9702-9714)	Mast cell tumor (9740, 9741)
	Hodgkin's disease (9650-9667)	Leukemia, NOS (9800)
	Mycosis fungoides or Sezary's disease (9700, 9701)	Acute leukemia, NOS (9801)
	Malignant histiocytosis or Letterer-Siwe's disease (9720, 9722)	Chronic leukemia, NOS (9803)
	True histiocytic lymphoma (9723)	Monocytic leukemia (9890-9894)
	Plasmacytoma or multiple myeloma (9731, 9732)	Mast cell leukemia (9900)
	Waldenstrom's macroglobulinemia (9761)	
	Chronic lymphocytic leukemia (9823)	
	Plasma cell leukemia (9830)	
	Non-lymphocytic leukemias (9840-9842, 9860-9880, 9910)	
	Lymphosarcoma cell leukemia (9850)	
	Myeloid sarcoma (9930)	
	Acute panmyelosis (9931)	

**DETERMINATION OF SUBSEQUENT PRIMARIES OF
LYMPHATIC (NODAL AND EXTRANODAL) AND HEMATOPOIETIC DISEASES**

First Primary	Presumably a Second Subsequent Primary	Presumably NOT a Subsequent Primary (only One Primary)
Mast cell tumor (9740, 9741) (cont'd)	Acute myelofibrosis (9932) Hairy cell Leukemia (9940) Leukemic reticuloendotheliosis (9941)	

**DETERMINATION OF SUBSEQUENT PRIMARIES OF
LYMPHATIC (NODAL AND EXTRANODAL) AND HEMATOPOIETIC DISEASES**

First Primary	Presumably a Second Subsequent Primary	Presumably NOT a Subsequent Primary (only One Primary)
<p>Waldenstrom's macroglobulinemia (9761)</p>	<p>Non-Hodgkin's lymphoma except immunoblastic or large cell lymphoma (9593-9594, 9673-9677, 9683, 9685-9686, 9690-9697, 9702-9713)</p> <p>Hodgkin's disease (9650-9667)</p> <p>Burkitt's lymphoma (9687)</p> <p>Mycosis fungoides or Sezary's disease (9700, 9701)</p> <p>Malignant histiocytosis or Letterer-Siwe's disease (9720, 9722)</p> <p>True histiocytic lymphoma (9723)</p> <p>Mast cell tumor (9740, 9741)</p> <p>Leukemia except plasma cell (9800-9827, 9840-9941)</p>	<p>Malignant lymphoma, NOS (9590, 9591, 9595)</p> <p>Lymphosarcoma (9592)</p> <p>Immunoblastic or large cell lymphoma (9671, 9680-9682, 9684, 9698, 9714)</p> <p>Malignant lymphoma, lymphocytic (9670, 9672)</p> <p>Plasmacytoma or multiple myeloma (9731, 9732)</p> <p>Waldenstrom's macroglobulinemia (9761)</p> <p>Plasma cell leukemia (9830)</p>

**DETERMINATION OF SUBSEQUENT PRIMARIES OF
LYMPHATIC (NODAL AND EXTRANODAL) AND HEMATOPOIETIC DISEASES**

First Primary	Presumably a Second Subsequent Primary	Presumably NOT a Subsequent Primary (only One Primary)
Leukemia, NOS (9800)	Non-Hodgkin's lymphoma ¹ (9590-9595, 9670-9687, 9690-9698, 9702-9714) Hodgkin's disease (9650-9667) Mycosis fungoides (9700) Malignant histiocytosis or Letterer-Siwe's disease (9720, 9722) True histiocytic lymphoma (9723) Plasmacytoma or multiple myeloma (9731, 9732) Mast cell tumor (9740, 9741) Waldenstrom's macroglobulinemia (9761)	Any leukemia ² (9800-9941) Sezary's disease ³ (9701)

¹If the diagnosis includes "can't rule out leukemia" or "consistent with chronic lymphocytic leukemia," and a bone marrow or peripheral blood study within two months confirms the chronic lymphocytic leukemia diagnosis; then code only to chronic lymphocytic leukemia (9823/3). If not confirmed as chronic lymphocytic leukemia, then code as the lymphoma.

²Note: Leukemia, NOS (9800) should be upgraded to a more specific leukemia diagnosis (higher number) when it is found but not considered a second primary.

³Presumably this is the correct diagnosis. Code the case to this histology.

**DETERMINATION OF SUBSEQUENT PRIMARIES OF
LYMPHATIC (NODAL AND EXTRANODAL) AND HEMATOPOIETIC DISEASES**

First Primary	Presumably a Second Subsequent Primary	Presumably NOT a Subsequent Primary (only One Primary)
Acute leukemia, NOS (9801)	Non-Hodgkin's lymphoma (9590-9595, 9670-9687, 9690-9698, 9702-9714) Hodgkin's disease (9650-9667) Mycosis fungoides (9700) Malignant histiocytosis Letterer-Siwe's disease (9720, 9722) True histiocytic lymphoma (9723) Plasmacytoma or multiple myeloma (9731, 9732) Mast cell tumor (9740, 9741) Waldenstrom's macroglobulinemia (9761)	Any leukemia ¹ (9800-9941) Sezary's disease ² (9701)

¹Note: Acute leukemia, NOS (9801) should be upgraded to a more specific type of acute leukemia (higher number) when it is found, but not considered a second primary.

²Presumably this is the correct diagnosis. Code the case to this histology.

**DETERMINATION OF SUBSEQUENT PRIMARIES OF
LYMPHATIC (NODAL AND EXTRANODAL) AND HEMATOPOIETIC DISEASES**

First Primary	Presumably a Second Subsequent Primary	Presumably NOT a Subsequent Primary (only One Primary)
Chronic leukemia, NOS (9803)	Hodgkin's disease (9650-9667) Malignant histiocytosis or Letterer-Siwe's disease (9720, 9722) Mast cell tumor (9740, 9741)	Non-Hodgkin's lymphoma ¹ (9590-9595, 9670-9686, 9690-9698, 9702-9714) Burkitt's lymphoma (9687) Mycosis fungoides or Sezary's disease (9700, 9701) True histiocytic lymphoma (9723) Plasmacytoma or multiple myeloma (9731, 9732) Waldenstrom's macroglobulinemia (9761) Any leukemia ² (9800-9941)

¹If the diagnosis includes "can't rule out leukemia" or "consistent with chronic lymphocytic leukemia," and a bone marrow or peripheral blood study within two months confirms the chronic lymphocytic leukemia diagnosis; then code only to chronic lymphocytic leukemia (9823/3). If not confirmed as chronic lymphocytic leukemia, then code as the lymphoma.

²Note: Chronic leukemia, NOS (9803) should be upgraded to a more specific type of chronic leukemia (higher number) when it is found, but not considered a second primary.

**DETERMINATION OF SUBSEQUENT PRIMARIES OF
LYMPHATIC (NODAL AND EXTRANODAL) AND HEMATOPOIETIC DISEASES**

First Primary	Presumably a Second Subsequent Primary	Presumably NOT a Subsequent Primary (only One Primary)
Lymphocytic leukemia (9820-9827)	Hodgkin's disease (9650-9667) Malignant histiocytosis or Letterer-Siwe's disease (9720, 9722) Plasmacytoma or multiple myeloma (9731, 9732) Mast cell tumor (9740, 9741) Waldenstrom's macroglobulinemia (9761) Non-lymphocytic leukemias ¹ (9840-9842, 9860-9910) Myeloid sarcoma ¹ (9930) Acute panmyelosis ¹ (9931) Acute myelofibrosis ¹ (9932)	Non-Hodgkin's lymphoma ² (9592-9595, 9670-9687, 9690-9698, 9702-9714) Malignant lymphoma, NOS ² (9590-9591) Mycosis fungoides or Sezary's disease ³ (9700, 9701) True histiocytic lymphoma (9723) Leukemia, NOS (9800) Acute leukemia, NOS (9801) Chronic leukemia, NOS (9803) Lymphocytic leukemia ³ (9820-9827)

¹If any of these diagnoses are made within 4 months of lymphocytic leukemia, NOS (9820) or acute lymphocytic leukemia (9821), one of the two diagnoses probably is wrong. The case should be reviewed.

²If the diagnosis includes "can't rule out leukemia" or "consistent with chronic lymphocytic leukemia," and a bone marrow or peripheral blood study within two months confirms the chronic lymphocytic leukemia diagnosis; then code only to chronic lymphocytic leukemia (9823). If not confirmed as chronic lymphocytic leukemia, then code as the lymphoma.

³Note: Lymphocytic leukemia, NOS (9820) should be upgraded to a more specific diagnosis that is not considered a second primary.

**DETERMINATION OF SUBSEQUENT PRIMARIES OF
LYMPHATIC (NODAL AND EXTRANODAL) AND HEMATOPOIETIC DISEASES**

First Primary	Presumably a Second Subsequent Primary	Presumably NOT a Subsequent Primary (only One Primary)
Lymphocytic leukemia (9820-9827) (cont'd)		Plasma cell leukemia ¹ (9830) Lymphosarcoma cell leukemia ¹ (9850) Hairy cell leukemia ¹ (9940) Leukemic reticuloendotheliosis ¹ (9941)

¹Note: Lymphocytic leukemia, NOS (9820) should be upgraded to a more specific diagnosis that is not considered a second primary.

**DETERMINATION OF SUBSEQUENT PRIMARIES OF
LYMPHATIC (NODAL AND EXTRANODAL) AND HEMATOPOIETIC DISEASES**

First Primary	Presumably a Second Subsequent Primary	Presumably NOT a Subsequent Primary (only One Primary)
<p>Plasma cell leukemia (9830)</p>	<p>Non-Hodgkin's lymphoma (9590-9595, 9670-9686, 9690-9698, 9702-9714)</p> <p>Hodgkin's disease (9650-9667)</p> <p>Burkitt's lymphoma (9687)</p> <p>Mycosis fungoides or Sezary's disease (9700, 9701)</p> <p>Malignant histiocytosis or Letterer-Siwe's disease (9720, 9722)</p> <p>True histiocytic lymphoma (9723)</p> <p>Mast cell tumor (9740, 9741)</p> <p>Non-lymphocytic leukemia (9840-9842, 9860-9910)</p> <p>Myeloid sarcoma (9930)</p> <p>Acute panmyelosis (9931)</p> <p>Acute myelofibrosis (9932)</p>	<p>Plasmacytoma or multiple myeloma (9731, 9732)</p> <p>Waldenstrom's macroglobulinemia (9761)</p> <p>Leukemia, NOS (9800)</p> <p>Acute leukemia, NOS (9801)</p> <p>Chronic leukemia, NOS (9803)</p> <p>Lymphocytic leukemia (9820-9827)</p> <p>Plasma cell leukemia (9830)</p> <p>Lymphosarcoma cell leukemia (9850)</p> <p>Hairy cell leukemia (9940)</p> <p>Leukemic reticuloendotheliosis (9941)</p>

**DETERMINATION OF SUBSEQUENT PRIMARIES OF
LYMPHATIC (NODAL AND EXTRANODAL) AND HEMATOPOIETIC DISEASES**

First Primary	Presumably a Second Subsequent Primary	Presumably NOT a Subsequent Primary (only One Primary)
Lymphosarcoma cell leukemia (9850)	Hodgkin's disease (9650-9667) Mycosis fungoides or Sezary's disease (9700, 9701) Malignant histiocytosis or Letterer-Siwe's disease (9720, 9722) Mast cell tumor (9740, 9741) Non-lymphocytic leukemia (9840-9842, 9860-9941)	Non-Hodgkin's lymphoma (9590-9595, 9670-9687, 9690-9698, 9702-9714) True histiocytic lymphoma (9723) Plasmacytoma or multiple myeloma (9731-9732) Waldenstrom's macroglobulinemia (9761) Leukemia, NOS (9800) Acute leukemia, NOS (9801) Chronic leukemia, NOS (9803) Lymphocytic leukemia (9820-9827) Plasma cell leukemia (9830) Lymphosarcoma cell leukemia (9850)

**DETERMINATION OF SUBSEQUENT PRIMARIES OF
LYMPHATIC (NODAL AND EXTRANODAL) AND HEMATOPOIETIC DISEASES**

First Primary	Presumably a Second Subsequent Primary	Presumably NOT a Subsequent Primary (only One Primary)
<p>Non-lymphocytic leukemias (9840-9842, 9860-9894, 9910-9932)</p>	<p>Non-Hodgkin's lymphoma (9590-9595, 9670-9686, 9690-9698, 9702-9714)</p> <p>Hodgkin's disease (9650-9667)</p> <p>Burkitt's lymphoma (9687)</p> <p>Mycosis fungoides or Sezary's disease (9700, 9701)</p> <p>Malignant histiocytosis or Letterer-Siwe's disease (9720, 9722)</p> <p>True histiocytic lymphoma (9723)</p> <p>Plasmacytoma or multiple myeloma (9731, 9732)</p> <p>Mast cell tumor (9740, 9741)</p> <p>Waldenstrom's macroglobulinemia (9761)</p> <p>Lymphocytic leukemia (9820-9827)</p> <p>Plasma cell leukemia (9830)</p> <p>Lymphosarcoma cell leukemia (9850)</p>	<p>Leukemia, NOS (9800)</p> <p>Acute leukemia, NOS (9801)</p> <p>Chronic leukemia, NOS (9803)</p> <p>Non-lymphocytic leukemia¹ (9840-9842, 9860-9894, 9910-9932)</p>

¹Code to the term with the higher histology code.

**DETERMINATION OF SUBSEQUENT PRIMARIES OF
LYMPHATIC (NODAL AND EXTRANODAL) AND HEMATOPOIETIC DISEASES**

First Primary	Presumably a Second Subsequent Primary	Presumably NOT a Subsequent Primary (only One Primary)
Non-lymphocytic leukemias (9840-9842, 9860-9894, 9910-9932) (cont'd)	Mast cell leukemia (9900) Hairy cell leukemia (9940) Leukemic reticuloendotheliosis (9941)	

**DETERMINATION OF SUBSEQUENT PRIMARIES OF
LYMPHATIC (NODAL AND EXTRANODAL) AND HEMATOPOIETIC DISEASES**

First Primary	Presumably a Second Subsequent Primary	Presumably NOT a Subsequent Primary (only One Primary)
Mast cell leukemia (9900)	<p>Non-Hodgkin's lymphoma (9590-9595, 9670-9686, 9690-9698, 9702-9714)</p> <p>Hodgkin's disease (9650-9667)</p> <p>Burkitt's lymphoma (9687)</p> <p>Mycosis fungoides or Sezary's disease (9700, 9701)</p> <p>Malignant histiocytosis or Letterer-Siwe's disease (9720, 9722)</p> <p>True histiocytic lymphoma (9723)</p> <p>Plasmacytoma or multiple myeloma (9731, 9732)</p> <p>Waldenstrom's macroglobulinemia (9761)</p> <p>Any other leukemia (9820-9894, 9910-9941)</p>	<p>Mast cell tumor (9740, 9741)</p> <p>Leukemia, NOS (9800)</p> <p>Acute leukemia, NOS (9801)</p> <p>Chronic leukemia, NOS (9803)</p> <p>Mast cell leukemia (9900)</p>

**DETERMINATION OF SUBSEQUENT PRIMARIES OF
LYMPHATIC (NODAL AND EXTRANODAL) AND HEMATOPOIETIC DISEASES**

First Primary	Presumably a Second Subsequent Primary	Presumably NOT a Subsequent Primary (only One Primary)
<p>Hairy cell leukemia or leukemic reticuloendotheliosis (9940, 9941)</p>	<p>Non-Hodgkin's lymphoma (9590-9595, 9670-9686, 9690-9698, 9702-9714)</p> <p>Hodgkin's disease (9650-9667)</p> <p>Burkitt's lymphoma (9687)</p> <p>Mycosis fungoides or Sezary's disease (9700, 9701)</p> <p>True histiocytic lymphoma (9723)</p> <p>Plasmacytoma or multiple myeloma (9731, 9732)</p> <p>Mast cell tumor (9740, 9741)</p> <p>Waldenstrom's macroglobulinemia (9761)</p> <p>Any non-lymphocytic leukemia (9800-9804, 9830-9932)</p> <p>Lymphocytic leukemia (9821-9827)</p>	<p>Malignant histiocytosis or Letterer-Siwe's (9720, 9722)</p> <p>Lymphocytic leukemia, NOS (9820)</p> <p>Hairy cell leukemia or leukemic reticuloendotheliosis (9940, 9941)</p>

APPENDIX C

**OTHER ICD-O-2 CODES TO BE CONSIDERED ONE PRIMARY SITE
WHEN DETERMINING MULTIPLE PRIMARIES**

APPENDIX C

**OTHER ICD-O-2 CODES TO BE CONSIDERED ONE PRIMARY SITE
WHEN DETERMINING MULTIPLE PRIMARIES**

ICD-O-2 Codes	Site Groupings
C01 C02	Base of tongue Other and unspecified parts of tongue
C05 C06	Palate Other and unspecified parts of tongue
C07 C08	Parotid gland Other and unspecified salivary glands
C09 C10	Tonsil Oropharynx
C12 C13	Pyriform sinus Hypopharynx
C23 C24	Gallbladder Other and unspecified parts of biliary tract
C30 C31	Nasal cavity and middle ear Accessory sinuses
C33 C34	Trachea Bronchus and lung
C37 C38.0 C38.1-.3 C38.8	Thymus Heart Mediastinum Overlapping lesion of heart, mediastinum, and pleura
C38.4	Pleura
C51 C52 C57.7 C57.8-.9	Vulva Vagina Other specified female genital organs Unspecified female genital organs
C56 C57.0 C57.1 C57.2 C57.3 C57.4	Ovary Fallopian tube Broad ligament Round ligament Parametrium Uterine adnexa

**OTHER ICD-O-2 CODES TO BE CONSIDERED ONE PRIMARY SITE
WHEN DETERMINING MULTIPLE PRIMARIES (Cont.)**

ICD-O-2 Codes	Site Groupings
C60 C63	Penis Other and unspecified male genital organs
C64 C65 C66 C68	Kidney Renal pelvis Ureter Other and unspecified urinary organs
C74 C75	Adrenal gland Other endocrine glands and related structures

SELECTED BIBLIOGRAPHY

SELECTED BIBLIOGRAPHY

Ackerman, L.V.; Del Regato, J.A.; and Spjut, H.J. Ackerman and Del Regato's Cancer: Diagnosis, Treatment, and Prognosis. 6th ed. St. Louis: Mosby, 1985.

Ackerman, L. V. and Rosai, J. Ackerman's Surgical Pathology. 7th ed. St. Louis: Mosby, 1989.

Basmajian, J. V. Primary Anatomy. 8th ed. Baltimore: Williams and Wilkins, 1982.

Beahrs, O. H.; Henson, D.E.; Hutter, R.V.P; and Kennedy, B.J., eds. Manual for Staging of Cancer. 4th ed. American Joint Committee on Cancer. Philadelphia: Lippincott, 1992.

Chaffee, E. E. and Greisheimer, E. M. Basic Physiology and Anatomy. 3rd ed. Philadelphia: Lippincott, 1974.

Clark, W. H., Jr.; From, L.; Goldman, L. I.; and Mastrangelo, M.J. "Human Malignant Melanoma." New York: Grune & Stratton, Inc., 1979.

Crouch, J. E. Functional Human Anatomy. 4th ed. Philadelphia: Lea and Febiger, 1985.

DeVita, V. T., Jr.; Hellman, S.; and Rosenberg, S. A. Cancer: Principles and Practice of Oncology. Philadelphia: Lippincott, 1992.

Grant, J.C.B.; Agur, A.M.R.; and Ming, J.L., eds. Grant's Atlas of Anatomy. 9th ed. Baltimore: Williams and Wilkins, 1991.

Gray, H. and Williams, P.L., eds. Gray's Anatomy. 37th ed. New York: Churchill Livingstone, 1989.

Haagensen, C. D. et al. The Lymphatics in Cancer. Philadelphia: W.B. Saunders, 1972.

Haskell, C. M. and Berek, J.S. Cancer Treatment. 3rd ed. Philadelphia: Saunders, 1990.

Hermanek, P. and Sobin, L.H. TNM Classification of Malignant Tumours. 4th ed. New York: Springer-Verlag, 1976.

Holleb, A.L.; Fink, D.J.; and Murphy, G.P., eds. American Cancer Society Textbook of Clinical Oncology. 1st ed. Rochester, New York: American Cancer Society, 1991.

Holland, J. F. and Frei, E., III, eds. Cancer Medicine. 2nd ed. Philadelphia: Lea & Febiger, 1982.

International Classification of Diseases for Oncology, Second Edition. World Health Organization: Geneva, 1990

Netter, F. H. Atlas of Human Anatomy. Summit, N. J.: CIBA-GEIGY Corp., 1989.

Pansky, B. Review of Gross Anatomy: Text and Illustrations. 5th ed. New York: Macmillan, 1984.

SELECTED BIBLIOGRAPHY (cont'd)

- Paul, L.W. and Juhl, J.H. Paul and Juhl's Essentials of Roentgen Interpretation. 4th ed. Hagerstown, MD: Harper and Row, 1981.
- Rappaport, H. Tumors of the Hematopoietic System. Atlas of Tumor Pathology, Section III, Fascicle 8. Washington D.C.: Armed Forces Institute of Pathology, 1966.
- Robbins, S. L. and Cotran, R. S. Pathologic Basis of Disease. 4th ed. Philadelphia: Saunders, 1989.
- Schlossberg, L. and Zuidema, G.D. The Johns Hopkins Atlas of Human Functional Anatomy. 3rd ed. Baltimore: The Johns Hopkins University Press, 1986.
- Spence, A.P. Basic Human Anatomy. Menlo Park, California: The Benjamin/Cummings Publishing Company, Inc., 1982.
- Spiessl, B.; Behrs, O.H.; Hermanek, P.; Hutter, R.V.P.; Scheilie, O.; Sobin, L.H.; and Wagner, H., eds. TNM Atlas. 3rd ed. New York: Springer-Verlag, 1992.
- Taylor, G. W. and Nathanson, I. T. Lymph Node Metastases. London: Oxford University Press, 1942. Ann Arbor: University Microfilms.

INDEX

INDEX

- Abdomen (abdominal), 12, 13, 85, 112, 208, 209, 219, 220, 229, 237, 243, 245, 246, 253, 273, 307, 309, 401
 - Aortic (para-, peri-) lymph nodes, 81, 84, 229
 - Ascites, 112, 114
 - Cavity, 10, 12, 57, 112, 203, 208, 212, 215, 243, 245, 246, 273, 307, 309, 401
 - Gastric lymph nodes, 81, 84
 - Hepatic lymph nodes, 81
 - Iliac (common, external, internal, hypogastric) lymph nodes, 65, 66, 81, 84
 - Lymphatic drainage from, 71, 81
 - Mesenteric (inferior, superior) lymph nodes, 62, 65, 66, 71, 81
 - Parietal lymph nodes, 77, 81, 83, 84
 - Pelvic cavity, 10, 12
 - Pelvic lymph nodes, 12, 65, 71, 80, 81, 84
 - Sacral lymph nodes, 65, 66, 81, 84
 - Splenic lymph nodes, 81, 84
 - Tumors of, 253
 - Viscera, 81, 210
 - Visceral lymph nodes, 77, 81, 83, 84
- Abdominopelvic cavity, 10, 13
- Abducens nerve (VI), 399, 403
- Abductor muscle, 385, 389
- Achilles tendon, 381
- Acid phosphatase, 317
- Acid-base balance (pH), 249, 317
- Acidophilic (eosinophilic) tumors, 330
- Acoustic (cochlear, vestibular nerve (VIII)), 399, 402-404, 435, 436
 - Tumor (neuroma, neurilemmoma) of, 404, 436
- Acral lentiginous melanoma, 40, 43, 45
- ACTH (see Adrenocorticotrophic hormone), 329
- Adamantinoma (odontogenic tumor), 178
- Adductor muscle, 385
- Adenoacanthoma (adenosquamous carcinoma), 157
- Adenocarcinoma, 36, 135, 157, 160, 177, 185, 211, 214, 215, 218, 222, 229, 233, 237, 253, 255, 256, 264, 277, 285, 292, 293, 294, 323, 331, 333, 339, 432, 441
 - Adrenal cortical, 333
 - Cystadenocarcinoma, 285, 292-294
 - Ductal, 305
 - Follicular, 331, 337, 339
 - Grawitz's tumor, 253
 - Hypernephroma, 253
 - Intraductal, 305
 - Krukenberg metastatic, 211, 285, 292, 295
 - Lobular, 305
 - Medullary, 305
 - Mucinous, 305
 - Papillary, 331, 337, 339

Adenocarcinoma (continued)
 Primary site for, 441
 Renal cell carcinoma, 253
 Scirrhous, 305
 Serous, 285, 293, 294
 Squamous, 277, 432
Adenohypophysis (anterior lobe, pituitary gland), 329
Adenoid (see Pharyngeal tonsil), 68, 193, 201, 202
Adenoid cystic carcinoma, 135, 185, 432
Adenoma, 35, 185, 211, 222, 229, 330-333, 405
 Acidophilic (eosinophilic), 330
 Basophilic, 330
 Bronchial (carcinoid, cylindroid), 157
 Chromophobe, 330, 405
 Colloid, 331
 Cortical, 333
 Fetal, 331
 Follicular, 331
 Hurthle cell, 331
 Liver, 229
 Papillary, 331
 Parathyroid, 332
 Pituitary, 330, 405
 Pleomorphic, 185
 Villous, 222
Adenomatous polyp, 222
Adenosquamous carcinoma (adenoacanthoma), 157, 277
ADH (antidiuretic hormone), 330
Adipose (fat) tissue, 289, 297, 302, 329, 441
 Histologic type of cancer, 441
Adrenal (suprarenal) gland, 229, 328, 333-339
 Adrenalin (epinephrine), 333, 336, 338
 Cortex, 329, 333, 335, 336, 338
 Cortisol, 333
 Epinephrine (Adrenalin), 333
 Location of, 333
 Lymphatic drainage from, 81
 Medulla, 333, 336, 338
 Norepinephrine, 333
 Tumors of, 333, 404
Adrenal cortical adenocarcinoma, 333
Adrenalin (see Epinephrine), 333
Adrenocorticotrophic hormone (ACTH), 329
Adventitia, 205, 208, 244, 257, 260
Aldosterone, 333, 335, 338
Aleukemic (subleukemic), 124
Alimentary canal (see also Digestive system), 165, 168
Allergens, 68

Alveolar, 297, 299, 300, 317
 Alveoli, 157
 Breast, 297, 299, 300
 Bronchiolar (alveolar) carcinoma, 157
 Lung, 154, 157, 161, 162
 Process (mucosa covering mandible, maxilla), 178
 Prostate, 317
 Ridge (mucosa covering mandible, maxilla), 177
 Sacs, 152, 154
 Tumors of, 157
 Ameloblastoma, 178
 Ammonia, 249
 Ampulla of Vater, 81, 215, 229, 230
 Amylase, 237
 Anal verge, 219
 Anaplastic neoplasm (carcinoma, seminoma, spindle cell), 323, 331, 404
 Anatomic divisions (quadrants, regions, cavities), 14
 Anatomical position, 9, 15
 Androgens, 309, 333, 335, 336, 338
 Angiosarcoma, 368, 371, 375
 Ankle (tarsals), 351, 367, 369, 373
 Anorectal junction, 219, 222
 Anterior (ventral) plane, 12
 Anterior ligament, 277
 Antibodies (gamma globulins) (see also Immunity), 54, 62, 67, 356
 Antidiuretic hormone (ADH), 330
 Antigens, 68, 356
 Antrum of Highmore (maxillary sinus), 135, 138
 Anus, 85, 165, 167, 168, 219, 222, 226, 289, 307, 308, 441
 Histologic type of cancer, 441
 Lymphatic drainage from, 85, 87
 Tumors of, 222
 Aorta (ascending, great), 81, 103, 105, 110, 154, 161, 162, 205
 Appendices epiploica, 220
 Appendicular bones (see also Bone), 366, 367, 369, 373
 Classification of, 367
 Appendix, 89, 94, 165, 219
 Tumors of, 94, 222, 223
 Arachnoid mater, 399, 404
 Areola (breast), 297, 299-301, 305
 Argentaffinoma (carcinoid tumor), 215, 218, 222
 Arm (humerus, radius, ulna) bones, 343, 351, 367, 369, 373
 Arm and armpit, and/or lymphatic drainage from, 9, 39, 46, 65, 66, 85, 87, 88, 158
 Arrhenoblastoma (masculinizing tumor), 285
 Arteries (see also Vessels), 71, 81, 99, 102, 103, 111, 114, 115, 154, 249, 302, 321
 Aorta, 81, 83, 84, 103, 105, 110, 249
 Arterioles, 111, 114

Arteries (see also Vessels) (continued)

- Axillary, 302
- Bronchial, 154
- Carotid (external, internal), 135, 139, 169, 193
- Celiac, 81, 83, 84, 205, 210
- Coronary (left, right), 103
- Femoral, 321
- Gastric, 81
- Hepatic, 81, 237
- Iliac (internal, left, right), 81, 83, 84, 277, 321
- Mesenteric (inferior, superior), 71, 81, 83, 84, 221, 237
- Pudendal, 321
- Pulmonary (deoxygenated blood) trunk, 103, 105, 110, 111, 153-156
- Renal, 249
- Splenic branch, 81, 237
- Subclavian, 302
- Thoracic (internal, lateral subclavian), 302
- Thyroid (inferior, superior), 144
- Uterine, 277

Arterioles (see also Arteries), 111, 114, 249, 330

Articulating bones, 347, 349, 350

Articulation, 173

Aryepiglottic fold (see also Hypopharynx), 195, 201, 202

Arytenoid cartilage, 143, 144, 147, 148, 195

Ascending colon, 12, 166, 219, 220, 223, 226-228

Ascites (abdominal), 112, 114

Astrocytoma, 404, 407, 408, 442

- Primary site for, 442

Atelectasis, 158

Atrioventricular orifice, node, and/or function, 103

Atrium (atria, heart), 103, 105, 110

Auditory (eustachian) tubes, 46, 139

Auditory canal and nerve, 404

- Acoustic neuroma, 404, 436

Autonomic nervous system, 267, 377, 397, 401, 404, 407, 408

- Urethra control by, 267

Axial skeleton, 342, 343, 346, 359

- Classification of, 359

Axilla, 49, 62, 65, 66

Axillary and/or axillary lymph node, 46, 50, 65, 85, 87, 88, 302-304

Axon (nerve fiber), 393-396

B-Cells, 54, 356

B-K mole syndrome, 39

Back (posterior) of body, and/or lymphatic drainage from, 85

Bartholin's gland (greater vestibular), 289, 292, 294

Basal cell carcinoma, 36

Basal cell layer of the epidermis, 22, 23, 25, 36, 39-41, 43, 45

Basal ganglia, 397

Basement membrane (basal lamina), 22, 41, 244, 262, 274, 276, 305, 331
 Bladder wall, 262
 Corpus uteri, 274-276
 Renal pelvis, 244, 259, 262
 Ureter, 262
 Basophilic tumors, 330
 Basosquamous cell carcinoma, 36
 Belly (anterior, ventral), 12
 Bi- (bilateral), 9
 Bicep muscle, 385, 390
 Bifurcation, 81, 203
 Bile (see Ducts, Gallbladder), 165, 215, 229, 230, 233, 236, 240
 Tumors of, 229, 233, 235, 236, 441
 Bile duct carcinoma (intrahepatic, extrahepatic), 441
 Histologic type of cancer, 441
 Biliary system, 229, 230
 Birthmarks (see also Nevus), 35
 Bladder (see also Urinary system), 242-246, 261, 262, 264-268, 441
 Dome, 261
 Fundus, 261
 Histologic type of cancer, 441
 Location of, 10, 261
 Lymphatic drainage, 263, 265, 266
 Metastases, 368, 374
 Muscle wall, 261, 262, 264-266
 Neck (internal sphincter), 267
 Orifices, 261
 Serosal covering (peritoneum), 261, 262
 Sphincter (internal and external), 261, 267
 Structure of, 262
 Tissue layers, 262, 265, 266
 Trigone (orifices), 261, 264, 265
 Tumors of, 264, 441
 Ureter, 242-246, 249, 257, 260-262, 266, 268-270
 Urethra, 243, 261, 266-268, 270
 Urine, formation and transportation of, 247, 249
 Vertex, 261
 Wall (lateral and posterior), 261, 262, 264-266
 Blood (see also Cardiovascular system), 73, 103, 105, 114, 115, 125, 131, 134, 135, 139,
 144, 157, 161, 162, 166, 193, 210, 211, 215, 219-221, 237, 244, 247, 249, 251,
 252, 262, 268, 270, 274, 313, 329, 331, 335, 336, 338, 343, 345, 346, 356
 Abnormal (leukemia), 123, 126
 Anemia, 115
 Arterial, 110-112, 114, 230
 B-cell, 54
 Blast form (immature, unspecified), 123, 124
 Capillaries, 249, 251, 252, 268, 270, 347
 Cell production, 343, 345, 346, 368

Blood (see also Cardiovascular system) (continued)
 Cells, 54, 61, 62, 67-70, 90-92, 115, 117-119, 121-128, 131
 Circulation of, 249, 251, 252, 277
 Clot (coagulation), 115, 119, 121, 122
 Composition of, 63, 115, 229
 Counts (RBC, WBC), 115, 119, 123, 124
 Deoxygenated blood (see also Venous system), 105, 109-111, 154
 Differential, 119
 Embolus (clot), 119, 122
 Erythrocyte (RBC), 67, 115, 117, 118, 127, 229
 Erythropoiesis, 115
 Fibrinogen, 115
 Filtration through kidney, 243, 247, 249, 252, 268-270
 Flow through body and/or heart, 100, 102, 105
 Functions of, 99, 101, 102, 113, 114, 119, 121, 122
 Granulocyte, 119, 123, 124
 Hematocrit, 115, 117, 118
 Hemoglobin, 115, 117, 118, 124
 Histologic type of cancer, 441
 Leukocyte (WBC), 62, 115, 118, 119, 122-124, 126, 127, 356
 Life cycle, 115
 Lymphoblast, 123, 124
 Lymphocyte, 53, 54, 62, 67, 68
 Metastasis, blood-borne, 112, 331, 368, 369, 373
 Monoblast, 123, 124
 Monocyte, 67
 Myeloblast, 123, 124
 Myeloproliferative disorders (see also Bone marrow), 127
 Nutriments, 249, 343, 345, 346
 Oxygenated blood, 105, 107-111, 154
 Peripheral (circulating) blood, 123
 Plasma (plasmacyte), 54, 62, 63, 67, 115, 118, 124, 229
 Platelets (thrombocytes), 115, 118, 119, 356
 Polycythemia vera, 115, 127, 128
 Portal circulation, 100, 112-114, 210, 221, 237
 Pressure (diastolic, systolic), 105, 111
 Protein, 115, 119, 229
 Prothrombin, 119
 Reabsorption, 249
 Secretion of antibodies into, 356
 Secretion of hormones into, 329, 331, 333, 335, 336, 338, 339
 Serum, 115
 T-cell, 54, 68-70, 90
 Thrombocyte (platelet), 115, 118, 119
 Thrombus (clot, embolus), 119, 122
 Tumors of, 368
 Values (normal), 124
 Vascular papillae, 31

Blood (see also cardiovascular system) (continued)

- Venous (deoxygenated), 111-114, 135, 144, 169, 205, 210, 230
- Vessels (see also Venous system), 23, 27, 31, 53, 65, 66, 71-73, 99, 101-103, 105, 109-111, 113, 114, 119, 154, 157, 205, 229, 244, 249, 262, 274, 313, 321, 347, 356-358, 377, 381, 383, 384, 386, 441
- Volume, 115, 118

Blood vessels, 399, 401, 404, 411, 441

- Arachnoid mater containing, 399, 404
- Autonomic nervous system, 401
- Muscle (smooth) of, 401
- Tumors of, 404
- Viscerceptors (interoceptors), 411, 413, 414

Blue nevus, 39

Body cavities, 10, 15, 17

Body temperature (homeostasis), 21, 31, 99, 102

Bone marrow, 115, 119, 123, 124, 343, 346, 356-358, 368

- B-cell, 356
- Erythropoiesis, 115
- Leukemia diagnosis, 123, 124, 126
- Leukocyte (granular, polymorphonuclear) production in, 115, 119
- Platelet production in, 119
- Polycythemia vera, 115, 127, 128
- Tumors of, 125, 126, 368, 371, 375, 442

Bone tissue (osseous, vascular tissue), 242, 261, 289, 291, 294, 329, 332, 334, 343, 346, 347, 349-369, 371-373, 375, 381, 441

- Articulating bones, 347, 349, 350
- Bone marrow, histologic type of cancer, 442
- Cancellous (spongy), 355, 356, 358
- Cell (osteocyte), 347, 350, 355, 372, 375
- Classification (long, short, flat, irregular, round), 351, 352, 354
- Compact, 356
- Development (growth), 329, 333
- Diaphysis (long bone), 356-358, 372, 375
- Flat (pelvis, ribs, sternum, skull), 351, 353
- Functions of, 343, 359
- Haversian system, 347, 355, 356, 358
- Histologic type of cancer, 441
- Irregular (ear, vertebra), 347, 351
- Long (arm, leg), 351, 356-358, 368
- Marrow (red and yellow), 343, 346, 355-358, 368, 371, 375, 442
- Matrix, 347
- Medullary cavity, 355, 356, 358, 368
- Metaphysis, 355, 368
- Metastases, 368, 370
- Mineral stabilization, 343
- Muscle attachment to, 377, 381, 383
- Number of bones in body, 343, 345, 346, 351, 359-361, 367
- Nutriments (calcium, oxygen, phosphorus), 309, 332, 343, 345-347

Bone tissue (osseous, vascular tissue) (continued)

- Pelvis (ilium, ischium, pubis, hip bones), 242, 261, 272, 312, 343, 351, 366, 375
 - Periosteum, 355, 356, 358, 368, 381, 383
 - Phalange (finger, toe), 367, 373
 - Pubic, 261, 289, 291, 294
 - Radius (lower arm), 367
 - Recklinghausen's disease, 332
 - Rib, 343, 356, 361, 372, 375
 - Round (sesamoid, kneecap), 351, 353, 354, 356
 - Sacrum, 351, 353, 354, 361
 - Scapula (shoulder), 369
 - Sesamoid, 351, 353, 354, 356
 - Short (ankle, wrist), 351
 - Skeletal system, 341, 343, 345-347, 349-352, 354-369, 371-373, 375
 - Sphenoid (cranial, paranasal bone), 329
 - Sternum, 351, 356, 361, 367, 369, 373, 375
 - Structure of bone, 351, 356-358
 - Suturæ, 359, 360
 - Tibia (shin bone), 351
 - Tumors of, 368, 371, 375
 - Ulna (lower arm), 367
- Bone tissue, Appendicular (appendages - - extremities), 343, 345, 346, 366, 367, 369
- Cancellous (spongy), 355, 356, 358
 - Carpal (wrist bone), 351, 353, 354, 366, 367, 369, 373
 - Clavicle (collar bone), 343, 356, 361, 366, 367, 369, 373
 - Femur (thigh), 351, 353-356, 366, 367, 369, 373
 - Fibula (leg), 343, 351, 367, 369, 373
 - Hip, 343, 367, 369, 373
 - Humerus (upper arm), 351, 356, 366-369, 373
 - Marrow (red and yellow), 343, 346, 355-357, 368, 371, 375
 - Metatarsal (foot), 366, 367, 369, 373
 - Patella (kneecap), 351, 354, 366, 367, 369, 373
 - Pelvis (ilium, ischium, pubis, hip bones), 351, 366, 367
 - Phalange (finger, toe), 351, 366, 367, 369, 373
 - Radius (lower arm), 343, 351, 366, 367, 369, 373
 - Rib, 343, 351, 356, 361, 372, 375
 - Sacrum, 351, 353, 354, 361, 368
 - Scapula (shoulder), 343, 366, 367
 - Sternum, 334, 351, 356, 361, 366, 367, 369, 373
 - Tarsal (ankle), 351, 366, 367
 - Tibia (shin bone), 351, 366-369, 373
 - Ulna (lower arm), 351, 366, 367, 369, 373
- Bone tissue, Axial (axis), Skull (diploe), 342, 343, 351, 354, 356, 359, 363-365, 372
- Cranial (ethmoid, frontal, occipital parietal, sphenoid), 343, 351, 354, 359, 363-365, 372
 - Ear (middle, incus, malleus, stapes) bones, 351, 360
 - Facial, 360
 - Frontal (skull), 351

- Bone tissue, Axial (axis), Skull (diploe) (continued)
 - Hyoid, 359, 364, 365
 - Rib, 343
 - Temporal (skull), 343, 351, 354, 359, 363-365, 372
- Bone tissue, Axial (axis), Thorax, 342, 343, 359, 362
 - Manubrium, 362
 - Ribs, 361, 362, 372, 373
 - Sternum, 361, 362, 373
- Bone tissue, Axial (axis), Vertebral column, 343, 359, 361, 362
 - Cervical, thoracic, lumbar, sacrum, coccyx, 342, 361, 368
- Bone, metastasis to, 211, 368
- Bowel (see Intestine), 221, 222
- Bowen's disease, 36-38
- Bowman's capsule, 249, 252, 268, 270
- Brain (CNS, encephalon), 12, 13, 329, 368, 397, 399, 400, 442
 - Cerebellum, 399
 - Cerebral cortex, 397, 399
- Brain (CNS, encephalon) (continued)
 - Cerebral hemispheres, 397
 - Cerebrospinal fluid (CSF), 399
 - Cerebrum (frontal, parietal, occipital, temporal lobe), 397, 398
 - Diencephalon (thalamencephalon), 397
 - Epithalamus (third ventricle), 332, 397
 - Forebrain (prosencephalon), 397
 - Fourth ventricle (hindbrain), 399
 - Hindbrain (rhombencephalon), 399
 - Histologic type of cancer, 442
 - Hypothalamus, 329, 397
 - Medulla oblongata (hindbrain), 399
 - Meninges (dura mater, pia mater, arachnoid mater), 10, 397, 400, 404
 - Metastases, 31, 211, 370, 404
 - Midbrain (mesencephalon), 397, 399
 - Nervous system (control of sense and movement), 31, 393-401, 404, 407, 408
 - Neurons (gray matter), 393, 394, 397, 399, 404
 - Pineal (epiphysis) gland, 332, 337, 339, 397
 - Pons (hindbrain), 399
 - Prosencephalon (forebrain), 397
 - Rhombencephalon (hindbrain), 399
 - Thalamus, 397
- Breast (mammary gland), 273, 297, 299-305, 441
 - Areola, 297, 300-302, 305
 - Axillary tail, 301-303
 - Blood supply for, 302
 - Clinical evaluation of tumors, 302
 - Cooper's ligament, 297, 302
 - Duct (lactiferous), 297
 - Gland (lobe) of, 297, 300

Breast (mammary gland) (continued)
 Histologic type of cancer, 441
 Ligament, 297, 302
 Lymphatic drainage from, 77, 85, 302-304
 Metastatic sites, 301-304
 Muscle (pectoral) of, 297
 Nipple, 297, 299-302
 Parenchymal, 302
 Quadrant, 13, 301
 Skin (dimpling, tethering, retraction, peau d'orange), 302
 Spread of cancer, 302, 305
 Subsites, 301
 Tumors of, 302, 305
Brenner tumor, 285
Broad ligament, 277, 281, 282
Broders' classification of bladder tumors, 264
Bronchial adenoma (carcinoid, cylindroid), 157
Bronchioles (see also Bronchi, Lung), 154, 157, 161, 162
 Tumors of, 157
Bronchogenic carcinoma, 157, 159, 160
Bronchus (bronchi), 149, 153, 155, 156, 333, 347, 403, 441
 Cranial nerve (motor, sensory) functions, 403
 Extrapulmonary, 149
 Histologic type of cancer, 441
 Intrapulmonary, 149
 Lobar (secondary), 149, 152
 Lumen, 157
 Lymphatic drainage from, 77
 Main stem (primary, left, right), 149, 152
 Sensations from, 403
 Tube, 333
 Tumors of, 157-160
Buccal cavity (see also Cheek and Mouth), 193, 199, 200
 Anatomic limits, 181
 Buccal gutter, 178
 Buccal mucosa (cheek), 65, 66, 74, 181, 183, 184, 189, 191
 Buccal sulcus (gingival) (see also Palate), 178
 Glands (minor salivary), 177, 185
 Lymphatic drainage from, 65, 66, 74, 189
Bulbourethral (Cowper's) gland, (See Reproductive system, male 289, 309, 318-320
Bursa Fabricius, 54
Calcium levels, 332
Cancellous (spongy), 355, 356, 358, 359
Cancer (see Tumor), 62, 68, 71-73, 76, 145, 158, 159, 178, 205, 211
Canthus, lymph node drainage from, 46
Capillaries, 31, 53, 56, 57, 63, 66, 99, 102, 105, 111, 112, 114, 115, 154, 249, 251, 252, 268,
 270, 331, 377
 Blood, 63, 66, 99, 102, 111, 112, 114, 115

Capillaries (continued)

- Bowman's capsule, 252
 - Dermal, 31
 - Fascia, 377
 - Glomeruli, 249, 252
 - Intestinal, 215
 - Lymphatic, 53, 56, 57, 63
 - Pulmonary, 105, 154
 - Renal peritubular, 249
 - Renal, Bowman's capsule, 249, 251, 252, 268, 270
 - Thyroid gland, 331
- Carbohydrate metabolism, 215, 237
- Carbon dioxide exchange, 102, 105, 111, 114, 115, 117, 118, 131, 134, 154, 161, 162
- Carcinoid tumor (argentaffinoma), 157, 215, 218, 222
- Carcinoma (see also Tumor or specific histologic type), 253, 264, 285, 293, 295, 305, 323, 441
- Adenoid cystic, 432
 - Anaplastic, 323, 331
 - Cystadenocarcinoma, 441
 - Embryonal, 323
 - Endometrioid, 285, 293, 295
 - Epidermoid, 423, 425
 - Inflammatory, 305
 - Liposarcoma, 441
 - Medullary, 305, 331
 - Spread of, 71-73
 - Squamous, 253, 264, 277, 290, 295, 427
 - Transitional cell, 253
- Cardi(o), 9
- Cardia, 209, 214
- Cardiac (heart rate) stimulant, 333
- Cardiac (heart) muscle, 377, 380, 389, 390
- Cardioesophageal junction (cardiac orifice), 203, 211
- Cardiovascular system, 249
- Aorta, 249
- Carina (see also Carinal lymph node), 149, 157
- Carinal (see Tracheobronchial), 77
- Carpal (wrist) bone, 351, 353, 354, 367, 369, 373
- Cartilage (nonvascular tissue), 147-149, 285, 323, 343, 346, 347, 349, 350, 356, 361, 372, 375, 383, 441
- Arytenoid, 143, 148, 195
 - Attachment to bone, 343, 346, 383
 - C-shaped rings (trachea), 149
 - Cell (chondrocyte), 347, 349, 350
 - Corniculate, 143, 148
 - Cricoid (signet-ring), 143, 148, 195, 203
 - Cuneiform, 143, 148
 - Elastic, 347, 349, 350

- Cartilage (nonvascular tissue) (continued)
 - Epiglottis (see also Larynx), 143, 148, 161, 162
 - Fibrous, 347, 349, 350, 356
 - Histologic type of cancer, 441
 - Hyaline, 347, 349, 350
 - Laryngeal, 143
 - Perichondrium, 347
 - Thyroid (Adam's apple), 143, 148, 195
- Catecholamine (hormone), 333
- Caudal, 12
- Cavities of the body, 15, 17, 243, 245, 246, 329, 401, 441
 - Abdominal, 243, 245, 246, 273, 307-309, 401
 - Abdominopelvic, 13
 - Anterior and posterior (eye orbit), 415, 423
 - Cranial, 13, 397, 404
 - Dorsal, 13
 - Eye orbit (anterior and posterior), 415, 423
 - Nasal, 431-434, 441
 - Oral, 441
 - Pelvic, 272, 273, 275, 276, 283, 284, 313
 - Peritoneal, 243, 245, 246, 285
 - Pleural, 13
 - Thoracic, 13
 - Uterine, 277
 - Ventral, 13
 - Vertebral, 13
- Cecum (large intestine), 166, 219, 223, 226
 - Ileocecal orifice (valve), 219
 - Lymphatic drainage from, 222
 - Tumors of, 223
- Cell type (see also Blood, Lymphatic system), 23, 25, 31, 36, 38, 244, 262, 329, 393, 404
 - Angioblast, 405
 - Atypical (abnormal), 123-126
 - B-cells, 54, 356
 - Blastic (immature, unspecified), 123, 124
 - Blood, 343, 345, 346
 - Bone (osteocyte), 347, 349, 350
 - Chondrocytes, 347, 349, 350
 - Ciliated epithelial, 285
 - Columnar epithelial, 285, 317
 - Duct, 305
 - Embryo (see also Germ cell), 281, 283, 285
 - Embryonic (see also Germ cell), 404
 - Endometrial, 281
 - Epithelial tissue, 244, 262, 281, 292, 295, 305
 - Germ cell (embryonic, germinal), 285, 292, 294, 313, 323, 404, 405, 423
 - Giant cell, 368, 371, 375
 - Glial cells (neuroglia), 404

Cell type (see also Blood, Lymphatic system) (continued)

- Granulosa, 281, 285
- Histiocyte (see also Reticulum cell), 61
- Immature (see also Blastic), 123, 126
- Interstitial, 309, 311, 312, 323, 326, 329
- Leydig (interstitial (glandular) cell), 309, 323, 326, 329
- Luteal, 281
- Lymphocyte development and production, 53, 54, 62, 68, 119, 124
- Macrophage, 68
- Mature (differentiated, specialized), 123, 124
- Melanin-producing, 36-38
- Mixed, 36
- Myoepithelial, 305
- Nerve, 393-395, 404
- Neuroepithelial, 404
- Neuroglia (glial cells), 393
- Oat, 157, 160, 161
- Osteocyte (see Bone cell), 393, 404
- Parathyroid, 332
- Phagocyte, 68
- Plasma, 54, 62, 67, 368
- Reed-Sternberg, 90, 92
- Reserve (bronchial epithelium), 157
- Reticuloendothelial (histiocytes), 61, 67
- Reticulum cell, 368, 371, 375
- Secreting (alveoli, mucinous, serous), 297
- Sertoli, 313, 323
- Small cell, 157
- Sperm cell, 313, 317, 319, 320
- Spindle cell (anaplastic), 404
- Stem, 123, 124
- T-cells, 54, 68-70
- Theca, 281
- Trophoblast (trophoblastic), 323
- Undifferentiated, 123, 157, 160, 161
- Cellular intracanalicular fibroma, 305
- Cellular metabolism (homeostasis), 102
 - Balance, Hydrogen-ion concentration (pH), 99
 - Body temperature, 21, 31, 99
- Cellular respiration (see also Metabolism), 99, 102, 131
- Central nervous system (CNS), 377, 393-401, 404, 407, 408
- Cephalic (cephalo-, cranial) plane, 12
- Cerebellum (hindbrain), 399, 404, 407, 408
 - Tumors of, 404, 407, 408
- Cerebral cortex, 397, 399
- Cerebrospinal fluid (CSF), 397, 399
- Cerebrum (forebrain, telencephalon), 397, 399
 - Basal ganglia (cerebral nuclei), 397

Cerebrum (forebrain, telencephalon) (continued)
 Cerebral cortex, 397
 Hemispheres, 397, 404
 Lateral ventricles, 397
 Tumors of, 404
 Cervical (see also Lymph nodes), 62, 65, 66, 74, 75
 Cervical lymph nodes,
 Parotid (infra-auricular, preauricular), 49, 50
 Submandibular (submaxillary), 46, 49, 50
 Supraclavicular (transverse cervical), 46, 49, 50
 Cervix uteri, 273-277, 279, 280, 441
 Cervical canal (endocervix), 274, 275, 277
 Composition of, 273, 274
 Ectocervix (lip), 274, 277
 Endocervix (canal), 274, 277, 441
 Fornices (parts), 277
 Histologic type of cancer, 441
 Lip of cervix (ectocervix), 274
 Lymphatic drainage, 277
 Submucosa (stroma), 277
 Tumors of, 277
 CFS (cerebrospinal fluid), 397
 Cheek (see also Buccal cavity), 46, 169, 181, 183-185
 Lymphatic drainage from, 65, 66, 74, 189
 Chest and chest wall (see also Thorax), 49, 50, 77, 79, 80, 85, 157
 Chin, lymphatic drainage from, 46, 65, 66
 Choana, 135, 139
 Cholangiocarcinoma, 229, 233, 236, 441
 Primary site for, 441
 Chondrocyte, 347, 350
 Chondrogenic (chondrosarcoma, osteochondrosarcoma) tumor, 368, 371, 375, 441
 Primary site for, 441
 Chorionic gonadotrophic hormone, 329
 Choroid (middle layer of eye), 415, 417, 418
 Choroid plexus, 399
 Chromophobe tumors, 330, 405
 Chyle, 57
 Chyme (see also Stomach), 209, 211, 215
 Cicatrix (fibrous), 281
 Cilia, 149, 161, 162
 Cisterna chyli, 57, 221
 Clark's classification, 44, 45
 Clavicle (collar bone), 14, 343, 356, 361, 367, 369, 373
 Cleft palate, 360
 Clitoris (see also Reproductive system, female), 289, 291, 292, 294
 Cloacogenic transitional cell carcinoma, 222
 Clot (coagulation), 122
 Coccyx (tailbone), 361

Colloid adenoma, 331

Colon, 165, 168, 219, 220, 223, 225, 226, 229, 441
 Anus, 165, 167, 168, 219, 222, 226
 Appendix, 165, 219
 Ascending, 12, 166, 219, 220, 223, 226-228
 Cecum, 166, 219, 220, 223, 226
 Cul-de-sac, 219
 Descending, 166, 219, 220, 223, 226, 228
 Hepatic flexure, 219, 229
 Histologic type of cancer, 441
 Lymphatic drainage from, 65, 66, 81, 222
 Rectosigmoid, 219
 Rectum, 10, 12, 165, 166, 168, 219, 220, 222, 226-228
 Sigmoid (pelvic), 10, 166, 219, 220, 223, 226-228
 Splenic flexure, 219, 227
 Tissue layers (see also Digestive system), 166-168, 220
 Transverse, 166, 219, 220, 223, 226, 227
 Tumor nodules in mesenteric fat, 221
 Tumors of, 166, 222, 223

Columnar epithelium cell, 274, 285, 317

Commissure (anterior, posterior),
 Larynx, 134
 Lip, 170, 172, 189

Compact bone, 355-358

Compound nevus, 35

Concha (turbinate, inferior, middle superior, facial bone), 365

Connective tissue (see also Tendon, Cartilage, Fascia), 381, 393
 Areolar, 274

Connective tissue, dermis, subserosa, 27, 35, 36, 61, 166, 170, 205, 208, 210, 381, 383, 384,
 389, 390

Constrictor muscle (cranial nerves, motor, sensory), 403

Cooper's ligament, 297, 302

Cord, 313
 Spermatic, 309, 313
 Spinal, 393

Corium, dermis (see Integumentary system), 26

Cornea (eye), 415, 418, 423, 425

Corniculate cartilage, 148

Coronal (frontal) plane, 10

Corpora cavernosa, 289, 321

Corpus luteum (see also Ovary), 281, 330

Corpus uteri, 272, 273, 275-277, 279, 280
 Lymphatic drainage from, 81, 277
 Mucosa, 274
 Submucosa (stroma), 273
 Tumors of, 277
 Wall, composition of, 273

Cortical adenoma, 333

Cortisol, 329, 333, 336, 338
 Cortisone, 333
 Cowper's (bulbourethral) gland, 289, 309, 318-320
 Cranial (superior) (see also Cephalic), 10, 12
 Cranial bone (see also Cavities of the body), 329, 343, 351, 354, 359, 363-365, 372, 401
 Ethmoid bone, 359, 363-365, 372, 375
 Frontal bone, 351, 359, 372, 375
 Nerve, 399, 401, 435
 Occipital bone, 359, 363-365, 372, 375
 Parietal bone, 359, 363-365, 372, 375
 Sphenoid bone, 329, 359, 363-365, 372, 375
 Temporal bone, 351, 353, 354, 359, 363-365, 372, 375
 Craniopharyngioma (Rathke's pouch tumor), 330, 337, 405
 Cricoid cartilage (signet-ring), 143, 144, 148, 149, 195, 203
 Cuboid (short bones), 351
 Cul de sac (see also Reproductive system, female), 273, 307, 308
 Cuneiform cartilage, 148
 Cylindroid tumors, 157
 Cystadenocarcinoma (mucinous, serous), 285, 441
 Primary site for, 441
 Cystic duct, 229, 230, 233, 240
 Cystosarcoma phyllodes, 305
 Dendrite, 393, 395, 396
 Denonvilliers' fascia, 317
 Deoxygenated blood (see also Venous system), 105, 109-111, 154
 Depressor muscle, 389
 Dermal-epidermal junction (see also Nevus), 35, 39
 Dermatofibroma, 35
 Dermatofibrosarcoma (protuberans), 36-38
 Dermis, connective tissue, corium (see Integumentary system), 21-23, 25-27, 31, 33-38, 40,
 41, 44, 45
 Dermoid tumor, 285
 Descending colon, 166, 219, 220, 223, 226-228
 Di Guglielmo's disease, 124
 Diagnostic workup for cancer, 71-73
 Diaphragm, 67, 77, 79, 80, 103, 108, 153, 158, 203, 208, 209, 214, 229
 Diaphysis (long bone), 356-358
 Diastolic blood pressure, 105
 Diencephalon (thalamencephalon), 397
 Different histologies, 445
 Multiple primaries and, 445
 Digestive system, 12, 243, 403
 Alimentary canal (see Intestine), 165, 168
 Circular, longitudinal and/or oblique muscle, 205, 210, 220
 Cranial nerves, motor, sensory, 403
 Digestion, 166, 215, 218-220, 229, 237, 240
 Gastrointestinal tract (GI, alimentary canal), 165-169, 215, 220

Digestive system (continued)

- Mucosa, 166-172, 177-181, 183-185, 189, 191, 192, 205, 208, 210, 211, 220, 221, 233
- Muscularis mucosae, 166, 168, 169, 181, 184, 205, 210, 220
- Muscularis propria, 166, 168, 205, 208, 210, 214, 220
- Serosa (visceral peritoneum), 166, 168, 205, 208, 210, 214, 215, 219, 220, 233
- Submucosa, 166, 168, 169, 181, 205, 208, 210, 214, 220
- Subserosa (see Connective tissue and Fat), 177
- Surface epithelium, 166, 168, 205, 220
- Tissue layers of wall of GI tract, 166-168, 207, 208, 212, 214, 220
- Tumor spread by depth of penetration, 166
- Wall of intestine (structure), 166
- Dimpling of breast, 302
- Directional planes of the body, 9, 10, 12
- Distal, 12, 14-16
- Dorsal (posterior) plane, 12, 15, 17
- Ductal (duct cell, adeno) carcinoma, 305
- Ducts (see also Endocrine system and Digestive system), 273, 276, 281, 288, 289, 297, 305, 309, 313, 317, 318, 329, 330
 - Bile, 165, 215, 229, 230, 233, 235, 236
 - Breast, 305
 - Carcinoma of bile ducts, 235, 236
 - Cisterna chyli, 221
 - Common bile duct, 215, 229, 230, 233, 240
 - Craniopharyngeal, 330
 - Cystic, 229, 230, 233, 240
 - Ductus deferens (vas deferens), 309, 313
 - Ejaculatory, 309, 313
 - Endocrine (ductless), 281, 329, 335, 338, 339
 - Epididymis, 309, 313
 - Excretory, 289, 309, 317
 - Exocrine, 329
 - Extrahepatic bile, 229, 230, 235, 236, 441
 - Fallopian tube (oviduct), 273, 275-277, 281-284, 286-288, 307
 - Glandular, 318
 - Hepatic (left, right), 229, 230, 233, 240
 - Intrahepatic (see also Bile), 229, 235, 236, 441
 - Lactiferous, 297
 - Lymphatic, 57-60
 - Origin of breast cancer in, 305
 - Pancreatic (duct of Wirsung), 215, 237
 - Parotid (Stensen's), 185
 - Penile, 321
 - Porta hepatis, 229
 - Salts (bile), 229
 - Sebaceous gland, 31
 - Seminal, 313
 - Stensen's (parotid), 185

Ducts (see also Endocrine system and Digestive system) (continued)

- Submandibular (Wharton's), 185
- Sweat gland, 31
- Tear (lacrimal), 329, 419
- Thoracic, 57, 60, 221
- Tumors of, 305, 329
- Wharton's (submandibular), 185
- Wirsung (pancreatic), 237

Ductus deferens (vas deferens), 309, 313, 315, 316

Duodenum (see also Intestine, small), 209, 211, 214, 215, 218, 229, 230, 233, 237, 240

- Lymphatic drainage from, 81
- Tumors of, 215

Dura mater, 399, 404

Dysgerminoma, 285, 292, 294, 441

- Primary site for, 441

Ear (external auditory), 39, 185, 347, 349-351, 359, 360, 372, 375, 413, 414, 435, 436, 438

- Bone (incus, malleus, stapes), 351, 359, 360, 372, 375
- Canal, 31, 33, 34, 46, 435, 438
- Connective tissue, 372
- Drum membrane, 34
- Eustachian (auditory) tube, 46, 139, 435, 438
- Exteroceptor (receptor), 411, 413, 414
- Lymphatic drainage from, 46, 74, 436
- Melanoma of, 39, 43
- Proprioceptor (receptor), 411, 413, 414
- Topography code (skin of), 39
- Tumors of, 436
- Tympanic cavity and/or membrane, 31, 74, 435

Ectocervix (lip), 274

Ectoderm, 27

Eczematoid lesion (Paget's disease), 305

Edema, 62, 158

Ejaculatory duct (see Reproductive system, male), 309, 313, 317

Elbow (epitrochlear lymph nodes), 65, 66, 85

Electrolyte balance, 249, 252

Eleidin, 22

Elevator (levator) muscle, 385

Embolus (thromboembolus), 119, 122

Embryo (see also Germ cell), 281, 283-285, 323

- Tumor of, 285, 323

En cuirasse of breast, 302

Endo-, 15, 16

Endocardium (see also Heart), 104

Endocervix (see Cervix uteri), 274

Endocrine gland, 68-70

Endocrine system (see also specific glands), 327-329, 331-339

Endometrial stromal sarcoma, 277

Endometrioid carcinoma, 285

Endometrium, 274-277, 281, 285, 441
 Histologic type of cancer, 441
 Structure of, 274
 Tumors of, 277, 278, 285
 Eosinophilic tumors, 330
 Ependymoma, 404
 Epi-, 15, 16
 Epicardium (surface covering) (see also Heart), 104, 108
 Epigastric region, 14
 Epiglottis, 143, 148, 161, 162, 194, 195
 Aryepiglottic fold, 144, 195, 201, 202
 Base, 173, 194
 Glossoepiglottic fold, 194
 Lingual (anterior surface), 194, 201, 202
 Pharyngoepiglottic fold, 194, 195
 Epinephrine (Adrenalin), 333, 336, 338
 Epiphysis (bone), 356-358
 Epithalamus, 397
 Epithelial tissue, 27, 36, 68, 161, 162, 274, 281, 282, 285, 292, 295, 305, 334
 Bronchial, 157
 Ciliated, 282
 Columnar, 274, 285
 Ductal, 305
 Fallopian tubes, 282
 Glandular, 274, 277, 285, 305
 Lymphoepithelial, 334
 Mucin-producing (ciliated columnar), 149
 Myoepithelial, 305
 Neuroepithelial, 404
 Ovary, 281
 Squamous, 219
 Stratified squamous, 274, 289
 Surface epithelium, 166, 168, 205, 220
 Tumors, 285, 292, 295
 Uterus, 274, 277
 Erythroleukemia (Di Guglielmo's disease), 124
 Esophagus (see also Digestive system), 12, 154, 157, 161, 162, 165, 166, 168, 195, 203, 205, 207-210
 Adventitia, 205, 208
 Blood supply to, 205
 Histologic type of cancer, 441
 Lymphatic drainage from (lower, mid, upper), 77, 81, 205
 Peristaltic motion of, 203
 Regions and/or segments, 203, 205, 207, 208
 Tissue layers of (see also Digestive system), 207, 208
 Tumors of, 205
 Esthesioneuroblastoma (esthesioneuroepithelioma), 135, 432
 Esthesioneuroepithelioma, 432

- Estradiol, 281
- Estrogen-producing cancer, 285
- Estrogens, 281, 329, 333
- Estrone, 281
- Ethmoid (cranial) bone, 135, 138, 359, 363, 365, 375
- Ethmoid sinus, 135, 138
- Eustachian (auditory) tube (see also Ear), 46, 139, 435
- Ewing's sarcoma, 368, 371, 375, 441
 - Primary site for, 441
- Exocervix, 274
- Exocrine gland, 329, 335, 338
- Expiration (exhaling), 131
- Extensor muscle, 385
- External auditory canal, 435
- External rectus muscle (cranial nerves, motor, sensory), 403
- External, 13
 - Respiration, 131
- Exteroceptor (receptor), 411, 413, 414
- Extra-, 15, 16
- Extrahepatic biliary system, 229, 230, 235, 236
- Extralymphatic sites (see Lymphoma), 94
- Extranodal (extralymphatic) lymphoid tumors, 89, 94
- Extremities (lower, upper), lymph nodes of, 85
 - Axillary, 46, 85, 87
 - Epitrochlear, 46, 85, 87
 - Femoral (superficial inguinal), 46, 85, 87
 - Inguinal (femoral, superficial), 46, 85, 87
 - Popliteal, 46, 85, 87, 88
- Eye (see also Sense organs), 411, 413, 415, 417-419, 421-423, 425, 442
 - Accessory structures, 419, 421, 422
 - Canthus, 419, 422
 - Choroid, 415, 417, 418
 - Cranial nerves, motor, sensory, 403
 - Exteroceptor (receptor), 411, 413
 - Eyeball, 415, 417, 418, 421, 422
 - Histologic type of cancer, 442
 - Lymphatic drainage, 46, 74, 423, 425, 426
 - Melanoma of, 39, 43, 423
 - Proprioceptor (receptor), 413
 - Retina, 415, 417, 418
 - Sclera, 415, 417, 418
 - Tumors of, 423, 425, 426, 442
- Eyeball, 419, 421, 422
 - Composition of, 419
- Face and/or lymphatic drainage from, 39, 46, 65, 66, 158
- Facial, 360, 363, 365
 - Bone (facial), 360, 363, 365
 - Conchae, 360, 363, 365

Facial (continued)
 Lacrimal, 360, 363, 365
 Mandible, 360, 363, 365
 Maxilla, 360, 365
 Muscle (cranial nerves, motor, sensory), 403
 Nasal, 360, 363, 365
 Nerve (VII), 399, 402, 403
 Palatine, 360, 363, 365
 Sensations from, 403
 Zygomatic/malar, 360, 363, 365
 Fallopian tube (uterine tube, oviduct), 273, 275-277, 281, 282
 Composition of, 282
 Fimbria, 281, 282, 287, 288, 307
 Oviduct (uterine tube), 282, 288
 Structure of, 288
 Walls of, 288
 Familial polyposis, 222
 Fascia, 243, 261, 331, 381, 383, 384, 386, 389, 390
 Denonvilliers', 317
 Endothoracic, 302
 Gerota's (renal), 243
 Pectoral, 297
 Rectovesical, 261
 Fat (adipose tissue), 243, 289, 291, 294, 297, 302, 441
 Pericolic (mesenteric) and/or tumor nodules in, 221
 Fat, digestion of, 57, 211, 215, 229, 237
 Feet, acral lentiginous melanoma of, 40, 43, 45
 Skin of, 23
 Female reproductive system (see also specific organs), 273, 275, 277, 279-295, 297, 299-305, 307, 308, 329
 Feminizing (estrogen-producing) tumor, 285
 Femur (thigh), 351, 353-356, 367-369, 373
 Fertilization, 282, 283
 Fetal adenoma, 331
 Fibrinogen, 115
 Fibrosarcoma, 36-38, 285, 368, 371, 375, 386, 441
 Primary site for, 441
 Fibrous tissue (see also Ligament, Tendon), 104, 143, 147-149, 281, 305, 309, 313, 404
 Fibroxanthoma, 35
 Fibula (leg), 351, 367, 369, 373
 Filtration functions of kidney, 243, 247-249, 251, 252, 268, 269
 Fimbria(e), 281, 287, 288, 307, 308
 Flat bones, 351, 353, 354, 356, 361, 368, 375
 Flexor muscle, 385, 389
 Floor of mouth,
 Lymphatic drainage from, 74
 Fluid balance (see also Urine formation), 249, 333
 Follicle-stimulating hormone (FSH), 336, 338

Follicular adenocarcinoma, 331, 337
 Forearm, lymphatic drainage of, 46, 85, 87, 88
 Forebrain, 397, 399

- Basal ganglia, 397
- Cerebral cortex, 397
- Cerebral hemisphere, 397
- Cerebrum (telencephalon), 397
- Diencephalon, 397
- Epithalamus, 397
- Hypothalamus, 397
- Olfactory bulbs (rhinencephalon), 397
- Thalamus, 397

 Forehead (bone) and/or lymphatic drainage from, 46, 135
 Frontal (cranial bone), 343, 354, 359, 365
 Frontal,

- Cranial bone, 135, 138, 351, 359, 363-365, 372, 375
- Lobe of cerebrum, 397
- Paranasal sinus, 135, 138
- Plane, coronal, 12

 Gallbladder, 10, 165, 215, 229, 233, 235, 334, 441

- Bile, 215, 229, 230, 233, 236
- Ducts, 229, 230, 233, 236, 240
- Function of, 236
- Histologic type of cancer, 441
- Tissue layers, 233
- Tumors of, 233

 Gamma globulin (antibodies), 54, 62, 67
 Ganglia, thoracolumbar, sympathetic, and basal, 397, 401
 Ganglioneuroma, 333
 Gastrin hormone, 334
 Gastrinoma, 237
 Gastrointestinal tract (see Anus, Colon, Digestive system, Esophagus, Intestine, Mouth, Pharynx, Rectum, Stomach), 165, 166, 168, 169, 215, 220
 Genitourinary organs (see also Urinary and Reproductive system), 36
 Germ cell tumor, 285, 292, 294, 295, 323, 423
 Gerota's (renal) fascia, 243
 Giant cell tumor, 368
 Giant hairy nevus, 39
 Gland (see also specific gland), 273, 274, 281, 288, 289, 297, 299, 302-305, 309, 313, 319, 328-339, 405

- Accessory, skin, 27
- Adrenal (suprarenal), 14, 81, 329, 333-339
- Bartholin's (greater vestibular), 289, 292, 294
- Breast, 273, 297, 299-305
- Bulbourethral (Cowper's gland), 289, 309, 318-320
- Ceruminous, 27, 29-31, 33-35

Gland (see also specific gland) (continued)

- Cervical, 274
- Ductless, 281, 329, 335, 336, 338, 339
- Endocrine, 281, 328, 329, 335, 336, 338, 339
- Exocrine, 329
- Female gonads, 281, 307, 308
- Hypophysis, 338
- Male gonads, 309, 311, 312
- Mammary, 27, 273, 297, 299-305, 330
- Master, 329
- Mucous, 157, 159, 160, 185, 205, 210, 289, 291, 294
- Ostia of gland, 177, 183, 184, 188
- Ovarian (graafian follicle), 281, 329, 336
- Ovoid, 309
- Pancreas, 337
- Parathyroid, 328, 332, 336, 337
- Parotid, 74, 185, 189, 403
- Pineal, 328, 332, 337, 339, 397
- Pituitary, 281, 329, 330, 335, 337, 339, 397, 405
- Prostate, 309, 313, 317-320, 323
- Pyloric, 211
- Salivary, 139, 165, 169, 177, 185, 187-189
- Sebaceous, 27, 29-31, 33, 34, 36
- Seminal vesicles, 309, 313, 317, 319, 320
- Skene's, 289, 292, 294
- Stomach, 334
- Sweat (sudoriferous), 27, 29-31, 33, 34, 36, 115, 297, 329
- Testes, 336
- Thymus, 53, 54, 56, 67-70, 77, 334, 337, 339
- Thyroid, 68, 74, 77, 328, 329, 331, 337-339
- Tumors of, 331

Glans penis, 289, 321

Glial cells (Neuroglia), 393, 404

Glioblastoma (multiforme), 404, 407, 408, 442

- Primary site for, 442

Gliomas, 404

Glomerulus (glomeruli) capsule, 249, 251, 252, 268-270

- Capillaries, 249, 252

Glossoepiglottic fold and/or sulcus, 194

Glossopalatine fold (anterior tonsillar pillar), 194, 201, 202

Glossopharyngeal nerve (IX), 399, 402, 403

Glottic region (see also Larynx), 145, 148, 161, 162

- Cartilage (Thyroid, Arytenoid), 144
- Commissures, 144
- True vocal cords, 143-145, 148, 161, 162

Glucagon and/or glucagonoma, 237

Glucocorticoids, 329

Glucose, 211, 214, 229, 249

Glycogen, 229
 Gonadotrophic hormone (ICSH), 329
 Chorionic, 329
 Male, 329
 Gonad (see Ovary and Testis)
 Graafian follicle (see Ovary), 281
 Granuloma (see also Hodgkin's disease), 90
 Granulosa (theca) cell tumor, 441
 Primary site for, 441
 Grawitz's tumor, 253, 256
 Groin and/or lymphatic drainage from, 65, 66, 85
 Growth hormone (GH), 329
 Gum (gingiva) (see also Mouth), 165, 169, 178-180, 183, 184, 191
 Alveolar process and ridge, 179, 180, 189
 Lymphatic drainage from, 189, 191, 192
 Process (mandible, palatine), 178, 181, 183, 184
 Tumors of, 169
 Gustatory (Taste) sense organ, 427
 Hair (see also Integumentary system), 23, 27, 31, 285, 323
 Hamstring muscle, 385, 390
 Hand, 31, 46, 85
 Lymphatic drainage of, 85
 Skin of, 22, 23, 40, 43, 45
 Hard palate (see Palate)
 Haustra (sac), 220
 Haversian system of the bone, 347, 355, 356, 358
 Head and neck, 12, 50
 Anterior deep cervical nodes, 74
 Axillary nodes for neck, 46
 Cervical lymph nodes, 46, 62, 65, 66, 74-76, 135, 139, 145, 189, 192, 193, 203, 205
 Facial lymph nodes, 74, 189, 191, 192
 Internal (upper deep) jugular lymph nodes, 71, 74-76, 135, 139, 145, 189, 191-193
 Laterotracheal lymph nodes, 74
 Lymphatic drainage from, 46, 189, 191, 192
 Mastoid (postauricular) lymph nodes, 74
 Occipital lymph nodes, 74
 Parotid (infra-auricular, preauricular) lymph nodes, 74, 189
 Prelaryngeal lymph nodes, 74
 Pretracheal (prelaryngeal) lymph nodes, 74
 Recurrent laryngeal lymph nodes, 74
 Regional lymph nodes, 46
 Retropharyngeal nodes, 135, 189, 191-193
 Spinal accessory (posterior cervical) lymph nodes, 74-76
 Sublingual lymph nodes, 189
 Submandibular (submaxillary) lymph nodes, 74, 75, 135, 139, 189, 191-193
 Submental lymph nodes, 65, 66, 74, 135, 139, 189
 Supraclavicular (transverse cervical) lymph nodes, 74, 76, 189, 192
 Hearing (sense of), 403

Heart (see also Cardiovascular system)

- Aorta, 249
- Apex, 103, 107, 108
- Atria (left, right), 103, 105, 107, 108
- Atrioventricular orifice, node, and/or function, 103
- Blood supply to, 103
- Blood, 99-103, 105, 107-115, 117-119, 121, 122, 124-128, 135, 154
- Chambers, 103, 104, 107, 108
- Circuit (pulmonary, systemic), 99, 101-103, 105
- Circulation, 99, 100, 103, 105, 112-114
- Clot, 115, 119, 121, 122
- Endocardium, 104
- Epicardium, 104, 108
- Failure, 112
- Flow through, 100, 105
- Motor function of, 333, 403
- Myocardium (muscle), 99, 103, 104, 377, 399, 401
- Orifices (see also Valves), 103
- Pericardial fluid, 104
- Pericardium (outer surface, parietal peritoneum, sac), 77, 103, 104, 107, 108, 157
- Portal system, Venous system, 99-105, 107-112, 114, 115, 119
- Pulmonary circuit, 111
- Pulmonary trunk, 105
- Pump, as a, 99, 103, 105, 107, 108
- Sensations from, 403
- Sinoatrial node, 103
- Valve, semilunar (aortic, pulmonary), 103, 105, 110
- Valves, mitral (bicuspid), tricuspid, 103, 105, 110
- Ventricle (left, right), 103, 105, 107, 108, 110

Heel, lymphatic drainage of skin, 46, 85

Hemangioblastoma, 405

Hemangioma, 35, 229

Hemangiosarcoma (primary site for), 441

Hematopoiesis, 62, 66, 68

Henle, descending loop of, 247

Hepatic flexure, 219, 229

Hepatocellular carcinoma, 229, 232

Hepatoma, 229, 232

- Primary site for, 441

Hiatus, 203, 208

Hilus (lung), 153, 156, 157

Hindbrain (rhombencephalon), 397, 399

- Cerebellum, 399
- Cerebrum, 398
- Medulla oblongata, 399
- Pons, 399

Hip, and/or lymphatic drainage from, 39, 46

Histiocyte (see also Cells, reticuloendothelial), 61, 67

Histologic type of cancer, 439-441
 Histologic type/Primary site, 439-441
 Hodgkin's disease, 90-92, 211, 445

- Lymphocytic depletion (LD), 90, 92
- Lymphocytic predominance (LP), 90, 92
- Mixed cellularity (MC), 90, 92
- Nodular sclerosis (NS), 90, 92
- Primary site for, 441
- Reed-Sternberg cells, 90, 92
- Stomach, 211
- Unclassified (NOS), 90

 Homeostasis (see also Cardiovascular system), 99, 102
 Horizontal (transverse) plane, 10
 Hormone, 281, 329, 330, 332-336, 338, 339

- ADH (see antidiuretic), 330
- Adrenalin, 333
- Adrenocorticotrophic (ACTH), 329
- Aldosterone, 333, 338
- Androgen, 333, 336, 338
- Antidiuretic (vasopressin) (ADH), 330
- Catecholamine, 333
- Cell-stimulating (interstitial), 329
- Chorionic gonadotrophin, 281, 334
- Cortisol, 333, 336, 338
- Epinephrine, 333, 336
- Estradiol, 281
- Estrogen, 281, 329, 333, 336
- Estrone, 281
- Female luteinizing (LH), 329
- Gastrin, 334
- Gonadotrophic, male, interstitial cell-stimulating (ICSH), 329
- Growth or somatrophic (GH or STH), 329
- Insulin, 336, 338
- Melanocyte-stimulating (MSH and ACTH), 330
- Melatonin, 332
- Norepinephrine, 333
- Ovarian produced, 281
- Oxytocin (pitocin), 330
- Parathormone, 332, 336, 338
- Progesterone, 281
- Progestin (progesterone), 281, 333
- Prolactin (luteotrophic) LTH, 330
- Secretin, 334
- Steroids, 333, 336
- Testosterone, 309, 312, 318
- Thyrocalcitonin, 331
- Thyrotrophic (thyroid-stimulating) TSH, 329
- Thyroxin, 329, 331, 336, 338

Hormone (continued)
 Tri-iodothyronine, 329, 331
 Humerus (upper arm), 351, 356, 367-369, 373
 Tumors of, 368
 Hurthle cell adenoma, 331
 Hutchinson's freckle, 40, 43, 45
 Hydrogen-ion concentration (pH), 99, 102, 249
 Hymen, 289, 292, 294
 Hyoid bone, 359, 364, 365
 Hyper-, 15, 16
 Hypernephroma, 253, 256, 441
 Histologic type of cancer, 441
 Hyperplasia and Hypertrophy (prostate), 318
 Hypo-, 15, 16
 Hypochondriac region, 14
 Hypogastric region, 14
 Hypoglossal nerve (XII), 399, 402
 Hypopharynx (laryngopharynx), 139, 142, 143, 161, 162, 193, 195, 197-200, 203
 Anatomical limits, 195
 Aryepiglottic fold, 195, 201, 202
 Functions of, 195, 199, 200
 Tumors of, 198
 Hypophysis, (see Pituitary gland) 329
 Hypothalamus, 329, 397
 ICD-O (International Classification of Diseases for Oncology), 39, 170, 194, 301, 302, 386
 ICSH (see Interstitial cell-stimulating hormone), 329
 Ileocecal valve, 215, 219
 Ileum (small intestine), 68, 215, 218, 219
 Extranodal lymphoma, 94, 96
 Lymphatic drainage from, 81
 Tumors of, 215
 Iliac crest (see Inguinal)
 Immunity, lymphatic defense in, 54, 68, 334
 Immunotherapy, 68
 In situ carcinoma (noninfiltrating intraductal), 305
 Incidence (SEER Tabulation), 223
 Inferior (caudal) plane, 12, 14
 Inflammatory carcinoma, 305
 Inguinal (iliac) regions, 14, 65, 66
 Inspiration (inhaling), 131
 Insulin secretion, 237, 336, 338
 Insulinoma, 237
 Integumentary system (skin), 21, 243, 297, 442
 Accessory organs (appendages), tumors of, 27, 33, 34
 Adenocarcinoma of, 36
 Basal cell layer (stratum basale), 39
 Basement membrane (basal lamina), 22, 41
 Ceruminous glands, 27, 30, 31, 33-35

Integumentary system (skin) (continued)
 Clear-cell layer (stratum lucidum), 22
 Cornified-cell layer (horny) (stratum corneum), 22
 Dermis (connective tissue, corium), 21-23, 25, 26, 31, 33-38, 40, 41, 44, 45
 Epidermis (epithelium), 21, 23, 25-27, 31, 36, 40, 41, 43
 Epithelial tissue (see also Epidermis), 27, 36
 Glands, glandular epithelium, 21, 23, 27, 29-31, 33-35
 Granular-cell layer (stratum granulosum), 22
 Hair, 23, 27, 31
 Histologic type of cancer, 441, 442
 Intraepidermal (in-situ), 41, 44, 45
 Lymphatic drainage from, 46, 47, 49, 50, 57
 Malignant melanoma, 36-41, 43-45
 Nails, 27, 31, 39, 43, 45
 Papillary (stratum papillare), 23, 33, 41, 44
 Papillary-reticular dermal interface, 41, 44, 45
 Perianal skin, 219
 Pigmentation (melanin), 21, 26, 332
 Prickle-cell layer (stratum spinosum), 22
 Reticular (stratum reticulare), 23, 33, 34, 41, 44, 45
 Sebaceous glands, 21, 23, 27, 30, 31, 33-36
 Subcutaneous tissue, 23, 41, 44, 45
 Sweat (sudoriferous) glands, 21, 23, 27, 30, 31, 33-36
 Topography code for, 39
 Tumors of, 35-37, 40, 94, 442
Inter-, 15, 16
Internal, 13
 Organs, 10
 Respiration (see also Metabolism), 131, 161, 162
International Classification of Diseases for Oncology (ICD-O), 301, 302, 386
Interstitial (tissue) fluid, 57, 63, 66
Interstitial cell-stimulating hormone, 309, 311, 312
Intestine (see also Digestive system), 10, 12, 69, 70, 165, 166, 168, 209, 211, 215, 217-220,
 225, 226, 239, 240, 332, 377, 441
 Alimentary canal (GI tract), 165, 166, 168
 Appendix, 94
 Blood supply to, 221
 Functions of, 217-219
 Gastrointestinal tract, 166, 168, 220
 Hepatic flexure, 219, 229
 Histologic type of cancer, 441
 Hormone secretions by, 332, 334
 Ileocecal valve, 215, 219
 Large (see also Anus, Colon, Rectum), 10, 65, 66, 81, 85, 215, 219-221, 223, 225,
 226
 Lymphatic drainage from, 65, 66, 81, 221, 222
 Mesentery, 62, 65, 66
 Muscle, smooth, 377

Intestine (see also Digestive system) (continued)

- Peristaltic motion, 215
- Peyer's patches, 53, 56, 68-70, 215, 221
- Portal system, vein, 100, 112-114, 221
- Rectum, 81
- Small (see also Duodenum, Ileum, Jejunum), 10, 12, 53, 57, 65, 66, 68, 94, 96, 165, 166, 168, 209, 215, 217-220
- Splenic flexure, 81, 219, 227
- Tissue layers of (see also Digestive system), 166-168
- Tumors of, 94, 96, 166, 215, 217, 218, 221-223
- Villi, 215, 220
- Wall of (structure), 166

Intra-, 15, 16

Intracanalicular fibroma (cellular), 305

Intradermal nevus, 35, 39

Intraductal (adeno) carcinoma, 305

Intraepidermal (in-situ, squamous cell) carcinoma, 36-38

Involuntary muscle, 377, 389, 390

Iron, 229

Irregular bones, 347, 351, 356, 359, 360

- Structure of, 351, 356

Ischium (see Pelvis)

Islet cell tumor, 237

Islets of Langerhans, 237, 329

Isthmus (thyroid), 331

Jejunum (small intestine), 215, 218, 334

- Lymphatic drainage from, 81

Joint, 343, 381

- Amphiarthrosis (slightly movable), 343
- Connective tissue, 381, 385, 389, 390
- Diarthrosis (freely movable), 343
- Proprioceptor (receptor), 411, 413, 414
- Synarthrosis (immovable), 343

Jugular vein (external, internal, see also Lymph node), 57, 71, 135, 139, 144, 169, 193

Junctional nevus, 35, 39

Juxta-, 15, 16

Kaposi's (multiple idiopathic hemorrhagic) sarcoma, 36-38

Keratin (keras), 22, 31

Kidney (see also Urinary system), 10, 14, 115, 229, 242-247, 249, 252, 253, 255-257, 260-263, 265, 266, 268, 270, 329, 330, 332, 333, 336, 441

- Afferent, efferent, 249
- Arterioles (afferent, efferent), 249
- Bowman's capsule, 249, 252, 268, 270
- Calyx (calyces), 243, 247, 249
- Capillaries, 249, 251, 252
- Capsule (renal), 247, 249, 252, 270
- Cortex, 243, 247, 251, 252
- Electrolyte balance, 249, 252

Kidney (see also Urinary system) (continued)

- Excretion of waste products, 115, 229, 243, 247, 249, 251, 252, 268, 269
 - Fascia (Gerota's), 243
 - Filtration, 243, 244, 248, 249, 251, 252, 268, 269
 - Function of, 243, 251, 252
 - Glomerulus (glomeruli) capsule, 249, 251, 252, 268-270
 - Histologic type of cancer, 441
 - Location of, 243
 - Loop of Henle (tubule, convoluted, distal), 247, 249
 - Lymphatic drainage from, 81, 255-257
 - Medulla, 243
 - Nephron, 247, 248, 252, 268, 270
 - Parenchyma, 243, 246, 253, 255, 256
 - Parenchyma, histologic type of cancer, 441
 - Parenchyma, Tumors of, 253, 255, 256
 - Reabsorption, 249
 - Regional, 263
 - Renal corpuscle, 247
 - Renal pelvis, 242-244, 246, 247, 249, 251, 253, 255
 - Renal pelvis, tumors of, 253
 - Secretions, 249
 - Structure of, 243, 244
 - Tissue layers, 243, 244, 259-262
 - Tubule, distal, 249
 - Tubule, Peritubular capillaries, 249
 - Tumors of, 256
 - Urine, production of, 249
 - Waste products, 249, 251, 252
- Knee, popliteal lymph nodes, 85**
- Krukenberg (metastatic) tumor, 211, 285**
- Labia majora (large lips), 289, 291, 294**
- Labia minora (small lips), 289, 291, 292, 294**
- Labial mucosa, 170, 172, 181**
- Lacrimal apparatus, 360, 419**
- Accessory structures (eyebrows, lashes, lids), 419, 421, 422
 - Bone (facial), 360, 365
 - Canthus, 419, 421, 422
 - Duct, 419
 - Gland, 419
 - Sac, 419
- Lactation, 330**
- Lacteals (see also Lymphatic system), 57**
- Lactiferous duct, 297**
- Lacunae, 347, 355**
- Lamina propria (see also Digestive system), 166, 168, 169, 178, 205, 210, 215, 220, 244, 257, 260, 262, 265, 266, 274**
- Bladder wall, 262, 265, 266
 - Corpus uteri, 274

Lamina propria (see also Digestive system) (continued)
 Renal pelvis, 244, 260
 Ureter, 257

Large cell (undifferentiated carcinoma), 157

Laryngopharynx (see Hypopharynx)

Larynx (see also Respiratory system), 131, 134, 139, 144, 161, 162, 193, 195, 199, 200, 441
 Arytenoid (see Cartilage), 148
 Blood supply to, 144
 Cartilage, 143, 147, 149, 162
 Composition of, 143
 Cricoid cartilage (see Cartilage), 148
 Epiglottis (see Cartilage), 148
 Histologic type of cancer, 441
 Lymphatic drainage from, 144
 Motor functions of, 403
 Subsites of, 143, 144, 147, 148
 Thyroid cartilage (see Cartilage), 148
 Tumors of, 145
 Vocal cords (false, true), 143, 147, 148, 158, 161, 162

Lateral plane, 9, 12, 14-16

Leg (fibula, tibia) bones, 351, 367, 369, 373, 381

Leg and/or lymphatic drainage from, 46, 85

Leiomyoma, 211

Leiomyosarcoma, 205, 211, 215, 218, 264, 277, 386, 389, 390, 441
 Primary site for, 441

Lentigo maligna melanoma (Hutchinson's freckle), 40, 43, 45

Leukemia (leukocytosis), 123-128, 445-461, 463-468
 Acute, 124, 126
 Aleukemic (subleukemic), 124
 Blastic (undifferentiated), 123, 124
 Chronic, 124, 126
 Classification of, 126
 Clinical manifestations, 123, 124, 126
 Di Guglielmo's disease (erythroleukemia), 124
 Diagnosis of, 124
 Granulocytic, 123, 126
 Leukopenia, 124
 Lymphatic (lymphocytic), 123, 126
 Monocytic, 123, 126
 Multiple primaries and, 446-461, 463-468
 Myelocytic (myelogenous), 123
 Plasma cell, 124
 Primary site for, 442
 Stem cell (undifferentiated), 123, 124
 Subacute (aleukemic), 124, 126
 Subleukemic (aleukemic), 124

- Leukocyte (WBC),
 - Agranular, 119
 - B-Cells, 54
 - Development (leukopoiesis) of, 123, 124
 - Differentiated (mature, specialized), 123
 - Granulocyte (granular, polymorphonuclear), 119, 123, 124
 - Immature (blast) unspecialized, 123, 126
 - Lymphoblast, 123, 124
 - Lymphocyte, 53, 54, 61, 62, 67, 68, 119, 123, 124
 - Metamyelocyte, 123, 124
 - Monoblast, 123, 124
 - Monocyte (phagocyte), 67, 119, 123, 124
 - Mononuclear, 119
 - Myeloblast, 123, 124
 - Myelocyte, 123, 124
 - Proliferation of, 126
 - Prolymphocyte, 123, 124
 - Promonocyte, 123, 124
 - Promyelocyte, 123, 124
 - Stem cell, 123, 124
 - T-cell, 54, 68-70
 - White cell differential, 119
- Leukocythemia (see Blood)
- Leukocytosis, 124
- Leukopenia, 124
- Levators/elevator muscle, 385
- Leydig (interstitial) cell, 309, 312, 326, 329
- LH (luteinizing hormone), 329
- Ligaments (anterior, posterior, round), 143, 277, 281, 282, 297, 302, 381, 383, 384
 - Broad, 277, 281, 282
 - Circular, 277
 - Cooper's (suspensory), 297, 302
 - Mesovarian, 281
 - Ovarian (mesovarian), 281
 - Suspensory, 297, 302
 - Uterosacral, 277
- Lingual tonsil, 68, 94, 173, 174, 193, 201, 202
- Lingula (lung), 153
- Linitis plastica, 211
- Lip, 165, 167-169, 171, 179, 180, 184, 185
 - Commissure (mouth corners), 170-172, 189
 - Definitions (American Joint Committee on Cancer), 170
 - Labial mucosa (mucous membrane), 170, 172, 181
 - Lymphatic drainage from, 46, 74, 189, 191, 192
 - Skin of (topography code), 39
 - Tumors of, 170-172, 174, 181
 - Vermilion border, 39, 170, 172
- Lipase, 211, 237

Liposarcoma (primary site for), 441
 Liver, 10, 54, 112, 114, 115, 165, 210, 219, 229, 329, 441
 Arterial blood, 112, 230
 Blood supply to, 112
 Cell carcinoma, 229, 441
 Histologic type of cancer, 441
 Lobes (caudate, quadrate, right), 229, 233
 Lymphatic drainage from, 77, 229
 Phagocytosis of erythrocytes in, 229
 Portal system veins, 112, 210, 221, 237
 Sinusoids, 112
 Tumor and/or metastatic to, 43, 45, 112, 211, 229-232
 Lobular (adeno) carcinoma, 305
 Location reference terms, 9, 12-16
 Long bones, 351, 368, 375
 Structure of, 356-358
 Tumors of, 368
 Loop of Henle, 247
 Lower extremity bones, 367
 LTH (luteotrophic) hormone, 330
 Lumbar region (lower back), 14, 57, 243, 245, 246
 Lymphatic drainage from, 85
 Lung (see also Respiratory system, Bronchus), 13, 99, 101-103, 108, 110, 111, 115, 117, 118, 131, 134, 135, 138, 149, 152-156, 159-161, 193, 403
 Alveolar sac, 154
 Alveoli (see also Alveolar), 154, 157
 Apex, 153
 Bronchioles, 154, 157, 161, 162
 Clinical manifestations (diagnosis of carcinoma), 158
 Cranial nerves to, 399, 403
 Excretion of waste products, 115
 Hilus, 153, 156, 157
 Histologic type of cancer, 441
 Intrapulmonary bronchi, 149
 Lingula, 153
 Lobes (lower, middle, upper), 153, 155, 156, 161, 162
 Lumen of the bronchus, 157
 Lymphatic drainage from, 77, 157
 Mesothelium (see also Pleura), 157
 Metastasis to, 157, 211
 Motor functions of, 403
 Mucosa (bronchial, epithelial), 157
 Pleura (mesothelium, parietal, visceral), 10, 13, 153, 156, 157, 160-162
 Pleural cavity and/or interpleural space, 153, 159, 162
 Pleural effusion, 158
 Respiratory, 131
 Sensations from, 403
 Tumors of, 157, 441

Luteal cell, 281
 Luteinizing hormone (LH), 330
 Luteotrophic hormone, 330
 Lymph (see also Lymphatic system), 77
 Lymph nodes, 12, 46, 71, 81, 135, 139, 145, 154, 158, 159, 189, 191, 205, 253, 255-257, 259, 263, 265-267, 281, 282, 288, 301-304, 331, 423, 441
 Abdominal (see also Abdomen), 12
 Abdominal pelvic lymph nodes (see also Abdomen), 81
 Accessible, 62, 71-73
 Anterior deep cervical, 74
 Aortic (para-, peri-, lateral), 81, 84, 229, 255, 256, 277, 281, 282, 288, 290, 322
 Auricular (pre- and infra-auricular), 423, 425, 426
 Axillary, 46, 49, 50, 62, 65, 66, 85, 87, 88, 302-304
 Bladder, 263, 265, 266
 Breast, 302
 Buccal, 46, 65, 66, 74, 191, 192
 Buccinator, 46, 74, 189, 191, 192
 Capsule, 61
 Carinal (see Tracheobronchial), 77
 Caval (paracaval, lateral) node, 256, 322
 Cecal (cecum), 215, 221-222
 Celiac, 81, 210, 237
 Cervical (anterior deep, para, upper cervical), 331
 Cervical (see also Head and Neck), 62, 65, 66, 74-76, 135, 139, 145, 189, 192, 193, 205, 423
 Cervix uteri, 277, 280
 Chains, groups of, 71
 Cloquet's, 290
 Colic (colon, left, middle, right), 221, 227-228
 Composition of, 63
 Contralateral, 302
 Corpus of uterus, 277, 280
 Cystic, 215
 Delphian, 331
 Diaphragmatic, 77, 79, 80
 Distant, 71, 81, 189, 191, 192
 Epicolic, 221-222
 Epiploic (Foramen of Winslow), 210, 233
 Epitrochlear, 46, 49, 50, 65, 66, 85, 87, 88
 Extremities (lower, upper), 46, 49, 50, 85, 87, 88
 Facial (buccinator, infra-orbital, maxillary, submandibular), 46, 189, 191, 192, 439
 Fallopian tubes, 282, 286, 288
 Femoral (superficial inguinal), 46, 49, 50, 85, 87, 88
 Functions of, 62, 66
 Gastric (inferior, left, right, superior), 81, 84, 205, 214
 Head and neck (see also Head and neck for specific nodes), 46, 49, 50, 73, 74, 189
 Hemorrhoidal (middle, inferior, superior), 221, 227-228

Lymph nodes (continued)

- Hepatic, 81, 229
- Hilar (see also Tracheobronchial), 77, 160, 229, 256
- Histologic type of cancer, 441
- Hypogastric (see also Iliac), 65, 66, 81, 277, 281, 282, 288, 290, 322
- Ileocolic, 227, 228
- Iliac (common, external, hypogastric, internal), 65, 66, 81, 84, 263, 265, 267, 277, 282, 288, 290, 322
- Inaccessible, 71-73
- Infra-auricular (see also Facial), 46, 74, 189, 191, 192, 423
- Infra-orbital (see also Facial), 46, 74, 189, 191, 192
- Inguinal (deep, superficial), 46, 49, 50, 65, 66, 85, 87, 88, 267, 281, 282, 288, 290, 322, 325
- Intercostal, 65, 66, 77, 79, 80
- Internal (upper and lower deep) jugular, 331
- Jugular (internal, upper and lower deep cervical), 71, 74-76, 135, 139, 145, 189, 191-193, 331, 427, 431, 436
- Jugulo-omohyoid (see Jugular), 139, 427
- Jugulodigastric (see Jugular), 139, 331, 427
- Kidney, 257, 259
- Laryngeal (prelaryngeal, pretracheal, laterotracheal), 331
- Laterotracheal (anterior deep cervical, recurrent laryngeal), 74
- Lingual, 74
- Lymphatic drainage from, 57, 58, 71, 74, 85, 87, 189, 205, 222, 229, 277, 288, 423
- Mammary (internal, parasternal) (see also Gland), 46, 77, 79, 80, 301-304
- Mastoid (postauricular), 46, 74
- Maxillary (see also Submandibular), 46
- Mediastinal (anterior, posterior), 68, 77, 79, 80, 154, 158, 160, 205, 229, 331
- Mesenteric (inferior, superior), 62, 65, 66, 71, 81, 84, 221, 227, 228, 233
- Metastasis, 62, 145, 281
- Nasal fossa, 135
- Nodules in pericolic fat, 221
- Obstruction, 62
- Obturator, 265-267, 281
- Occipital, 46, 74
- Ovary, 281, 286, 288
- Para-aortic, 81, 256, 277, 280-281
- Paracervical, 277, 280
- Parametrial, 277, 280
- Parietal, 77, 79-81, 83, 84
- Parotid (infra-auricular, preauricular), 49, 50, 74, 189, 436
- Pelvic, 81
- Penis, 322
- Periaortic (aortic), 84, 229
- Peribronchial, 154
- Pericardial, 229
- Periprostatic, 322
- Peritracheal (see Tracheobronchial), 77

Lymph nodes (continued)

- Perivesical, 263
- Phagocytosis, 62
- Popliteal, 46, 49, 50, 85, 87, 88
- Postauricular (see also Mastoid), 46, 74
- Preauricular, 46, 74, 423, 426
- Prelaryngeal (see also Cervical), 46, 145
- Pretracheal (prelaryngeal), 74
- Prostate, 322, 325
- Recurrent laryngeal nerve chain, 74
- Regional, 71, 74, 77, 81, 145, 154, 189, 211, 212, 214, 227, 228
- Retroperitoneal (NOS), 81, 84, 282
- Retropharyngeal, 74, 135, 189, 191-193, 331, 436
- Rosenmuller's, 290
- Sacral, 65, 66, 81, 84, 263, 277, 280-281, 282, 288, 290, 322
- Sigmoidal (colon), 221
- Skin, 46, 47, 49, 50, 74, 85
- Spinal Accessory (posterior cervical), 46, 75, 76
- Splenic, splenic hilar, 81, 84, 214
- Structure of, 61
- Sublingual (lingual), 74, 189
- Submandibular (submaxillary), 46, 49, 50, 74-76, 135, 139, 189, 191, 192, 423, 426, 431
- Submental, 46, 65, 66, 74, 135, 139, 189, 427
- Supraclavicular (transverse cervical), 74, 76, 189, 192, 304
- Testes, 322
- Thorax (see also Chest wall), 50, 77, 79, 80
- Tracheobronchial (carinal, hilar, peritracheal), 77, 79, 80
- Transverse cervical (see also Supraclavicular), 49, 50, 74-76, 189, 192, 304
- Tumors of, 89, 91, 92, 94
- Ureter (periureteral), 257
- Urethra (pelvic, NOS), 267
- Uterus, 277
- Vagina, 290
- Visceral, 77, 79-81, 83, 84
- Vulva, 290
- Lymphangiography, 71, 73
- Lymphangioma (lymphangiosarcoma), 35, 89
- Lymphangiosarcoma, histologic type of cancer, 441
- Lymphatic (collecting) system, 205, 210, 215, 221
 - Capillary network, 53
 - Drainage (see also specific organs), 46, 49, 57, 58, 71, 74, 85, 87, 189, 193, 205, 221, 222, 229
 - Ducts (right, lymphatic, thoracic), 57, 59, 60, 221
 - Function of, 57, 62, 65-67
 - Interstitial (tissue) fluid, 57, 63, 66
 - Lacteals, 57
 - Lymph node (see specific Lymph node), 46, 49, 50

- Lymphatic (collecting) system (continued)
 - Lymphocytes (B-cells, T-cells), 53, 54, 61, 62, 67, 68
 - Metastasis (distant, regional node), 211
 - Organs and lymphoid tissue, 55, 56, 61, 62, 67, 68, 71, 89, 91, 92, 119, 193
 - Retrograde flow of, 57, 62, 157
 - Trunk (main), 57, 59, 60
 - Tumor (extranodal, nodal) of, (see also Lymphoma), 71, 89, 91, 92, 94, 211
 - Valves (semilunar), 57
 - Vessels (veins), 53, 57, 59-61, 63, 71, 89
- Lymphatic drainage from, 253, 255-257, 263, 331
 - Bladder, 263
 - Cecum, 221
 - Colon (ascending, sigmoid, transverse), 222
 - Ear, 436
 - Kidney, 255, 256
 - Liver, 77, 229
 - Ovary, 81
 - Rectum, 222
 - Renal pelvis, 255, 256
 - Small intestine, 215
 - Thymus, 334
 - Ureter, 257
 - Uterus, 81
 - Vagina, 81
 - Vessels (veins), 244, 262
- Lymphatic vessels,
 - Functions of, 57, 63
 - Internal jugular vein, 57
 - Structure of, 57, 59, 60
 - Subclavian vein, 53, 56, 57
 - Tumors of, 89
- Lymphocytes (hematopoiesis), 334
 - B-cells, 54, 356
 - T-cells, 54, 68-70, 334
- Lymphoepithelioma, 139, 427
- Lymphoid (lymphatic) tissue, 55, 56, 61, 62, 67, 68, 119, 141, 142, 161, 162, 173, 174, 193, 215, 221
 - Tumors of, 71, 89, 91, 92, 94, 174, 195, 211, 215, 218, 221
- Lymphoid tissue and organs (see also Lymphatic System), 334
- Lymphoma (malignant), 432
- Lymphoma, 54, 135, 139, 218, 441, 445-447, 449-461, 463-468
 - Base of tongue (lingual tonsil), (see Waldeyer's ring), 94
 - Differentiation, 96
 - Extralymphatic (nodal), 94-96
 - Extranodal, 94, 211
 - Hodgkin's disease, 91, 92, 445
 - Multiple primaries and, 445-447, 449, 450, 452-461, 463-468
 - Mycosis fungoides, 36-38, 94

Lymphoma (continued)

- Nasopharynx (pharyngeal tonsil), (see Waldeyer's ring), 94, 139
 - Non-Hodgkin's, 92, 95, 96
 - Oropharynx (palatine tonsil), (see Waldeyer's ring), 94
 - Primary site for, 441
 - Skin (see Extralymphatic), 94
 - Small intestine (ileum) and appendix, (see Extralymphatic), 94, 96, 215, 218
 - Stomach (see Extralymphatic), 94, 96, 211
- Lymphopoiesis (hematopoiesis), 66**
- Lymphosarcoma, 174, 427, 441**
- Primary site for, 441
- Macrophage, 68**
- Male reproductive system (see also specific organs), 309, 311, 312, 315-322, 325, 326**
- Mammary gland (see also Breast), 273, 297, 301, 302, 330**
- Mandible (facial bone), 177, 178, 185, 360, 365**
- Marrow, bone (see bone marrow), 343, 346, 355-358, 368**
- Masculinizing (arrhenoblastoma) tumor, 285**
- Mastication, muscles of, 403**
- Maxilla (upper jawbone), 14, 135, 178, 360, 365**
- Maxillary (see also Submandibular), 46, 49, 50, 74, 181, 183, 184**
- Maxillary sinus (antrum of Highmore), 135, 138**
- Medial (median, midsagittal) plane, 9, 10, 12, 14-16, 153**
- Mediastinum, 10, 103, 108, 153, 157, 161, 162, 203**
- Nodes, enlarged, 158
- Medulla (see also Adrenal gland, Bone, Brain, Kidney), 243, 247, 331, 333**
- Medulla oblongata, 399**
- Medullary (adeno) carcinoma, 305**
- Medullary bone cavity, 355, 356, 358, 368**
- Medullary carcinoma, 331**
- Medulloblastoma, 404, 442**
- Primary site for, 442
- Megakaryocyte (large cell), 119**
- Melanocytes (melanin), pigment cells, 23, 26, 35, 36, 39, 40, 330**
- Melanoma (malignant), 36, 38, 40, 45, 135, 423, 425, 426, 432**
- Acral lentiginous, 40, 43, 45
 - Amelanotic (nonpigmented), 36
 - B-K moles (familial), 39
 - Clark's Classification, 41, 44, 45
 - Classification (histologic type), 39, 40, 43
 - Depth of invasion (level, thickness), 40, 41, 44
 - Eye, 39, 43
 - Lentigo maligna (Hutchinson's freckle), 40, 43, 45
 - Nodular, 40, 43, 45
 - Primary site for, 442
 - Radial (superficial spreading), 40, 43, 45
 - Subungual, 39, 40, 43
 - Superficial spreading, 40, 43, 45
 - Unclassified, 40

Melatonin hormone, 332
 Membrane, 10, 143, 243, 244, 257, 259, 262, 404
 Basement (basal lamina), 22, 41, 244, 259, 262
 Bladder, 262, 265, 266
 Conjunctiva of eye, 415, 419
 Frenulum of tongue, 173, 177
 Gland (minor salivary) in, 185
 Labial mucosa, 170, 172
 Mucous, 135, 138, 139, 142, 143, 147-149, 161, 162, 166, 169, 170, 173, 176, 178, 185, 193, 200, 233, 289, 294
 Nerve (neurilemma), 404
 Peritoneum, 81, 83, 84, 166, 210, 220, 233
 Renal pelvis, 244, 262
 Serous (pleura), 10
 Tumors of, 404
 Ureter, 243, 257, 262
 Urethral, 243
 Meninges (dura mater, pia mater, arachnoid mater), 10, 393, 397, 399, 400, 404
 Tumors of, 404
 Meningioma, 404
 Menstruation, 273, 281
 Mesenteric fat (pericollic), 221
 Mesentery (peritoneum), 65, 66
 Mesonephric tumor, 285
 Mesothelial sarcoma, 441
 Primary site for, 441
 Mesothelioma, 157
 Mesothelium,
 Parietal, 153
 Visceral, 153
 Mesovarian ligament, 281
 Metabolism,
 Carbohydrate, 215, 237
 Cellular (see also Cardiovascular system), 99, 102, 131
 Nutrient exchange (see also Carbon dioxide, Oxygen), 57, 63, 102, 105, 111, 114, 115, 117, 118
 Respiration, 131
 Transported via blood and interstitial fluid, 99, 102, 115, 117, 118
 Metacarpals (hand), 367, 369, 373
 Metaphysis (long bone), 355, 368
 Metastases, 62, 71, 230, 302, 368, 370
 Blood-borne, 71, 112, 230, 368, 370
 Carcinoma, 71
 Corpus uteri, 274
 Cul de sac, 273, 307, 308
 Direct, 62, 154, 157
 Distant nodes, 71
 Liver, 112, 230-232

- Metastases (continued)
 - Lymph node, 62, 71, 94
 - Regional nodes, 71, 211
 - Retrograde flow, 62, 157
 - Sarcoma, 71
- Metastasis, blood-borne, 71, 211, 230
- Metatarsal (foot), 367, 373
- Midbrain (mesencephalon), 336, 397-399
- Midline, 10
- Midsagittal (median) plane, 10, 12
- Mineralocorticoid (aldosterone), 333
- Mons pubis (mons veneris), 289, 291, 294
- Motor nerve fibers, 393, 395, 396, 399
- Mouth (see also Buccal cavity (cheek), 165, 168-170)
 - Alveolar process covering, 179
 - Buccal (cheek), 178, 181
 - Composition of floor of mouth, 177
 - Floor of, 169, 173, 177-180, 184, 189
 - Glands located in, 169, 177, 184, 185
 - Lymphatic drainage from, 189
 - Oral cavity, 139
 - Palate (hard, soft), 139
 - Retromolar trigone, 177, 178
 - Roof (see also Palate), 169, 181, 184
 - Salivary gland, 139
 - Teeth, 165, 169, 178, 183, 184, 203
 - Tumors of, 169, 170, 174-178, 181
- MSH (see Melanocyte stimulating hormone), 330
- Mucin-producing (ciliated columnar) epithelium, 149
- Mucinous (adeno) carcinoma, 305
- Mucinous cystadenocarcinoma, 285
- Mucoepidermoid carcinoma, 185
- Mucoperiosteum (mucous membrane, periosteum of gums), 178, 181
- Mucosa (see also Digestive system), 166-168, 183, 184, 205, 214, 221, 244, 257, 259, 260, 262, 274, 275, 282, 285, 286, 288, 411, 413, 414, 431, 434
 - Alveolar process covering, 177-180
 - Bladder, 262, 265, 266
 - Bronchial, 157
 - Buccal (cheek), 169, 170, 178, 181, 183, 184, 189, 191, 192
 - Ciliated, 149, 282, 285, 286, 288
 - Corpus uteri, 274
 - Epithelial (esophageal, surface epithelium), 166, 168, 205, 208, 210, 220
 - Fallopian tube, 282, 286, 288
 - Floor of mouth, 177, 180, 185
 - Gastrointestinal, 166-169, 205, 208, 210, 211, 214, 220, 221, 233
 - Gingival (gum), 178-181
 - Labial, 170, 172, 181
 - Muscularis mucosae (see Digestive system), 166, 168, 169, 184, 205, 210, 220

Mucosa (see Digestive system) (continued)

- Nasal, 135, 431, 433, 434
- Oral cavity, 169, 170, 173, 183, 184
- Pharyngeal, 193
- Renal pelvis, 244, 259, 260, 262
- Ureter, 257, 262
- Uterus, 274-276

Muellerian mixed tumor, 278

Multiple myeloma, 442

- Primary site for, 442

Multiple primaries, 445-447, 449-461, 463-467, 471, 472

- Date of diagnosis and, 445
- Histology and, 445-447, 449-461, 463-468
- Rules for determining, 445-447, 449-461, 463-468, 471, 472
- Single lesion and, 445

Muscle (see also Muscular system), 205, 244, 260, 262, 264, 266, 267, 274, 294, 297, 329, 375-378, 380, 384-387, 390, 441

- Abductor, 385, 388-390
- Adductors, 385
- Arrector, 31
- Attachment to bone, 377, 381, 383-385
- Buccinator, 181
- Cardiac (heart), 99, 103, 104, 376-378, 380, 389, 390, 403
- Characteristics (functional), 385, 387, 388
- Comparisons of types of, 378
- Composition of, 377
- Conductivity, 385, 388
- Constrictor (cranial nerves, motor, sensory), 403
- Contractibility, 385, 388
- Elasticity, 385, 388
- Extensibility, 385, 388
- Extensors, 385
- External rectus (cranial nerves, motor, sensory), 403, 415
- Eye (cranial nerves, motor, sensory), 399, 403, 415
- Facial (cranial nerves, motor, sensory), 399, 403
- Fascia, 381, 383, 384
- Fiber, 377
- Flexor, 385, 389
- Functions (heat production, movement, posture), 385, 388, 389
- Histologic type of cancer, 441
- Hypoglossus, 177
- Involuntary, 377, 389, 390
- Irritability, 388
- Laryngeal (cranial nerves, motor, sensory), 403
- Levators/elevators, 385
- Ligaments, 381, 383, 384
- Longitudinal (taenia coli), 210, 220, 274
- Lung (cranial nerves, motor, sensory), 403

Muscle (see also Muscular system) (continued)

- Mixed, 205
- Muscle types, 376-380
- Mylohyoid, 177
- Oblique (external, internal), 274
- Palatine, 181, 183, 184
- Pectoralis (major and minor), 297
- Pharyngeal (cranial nerves, motor, sensory), 142, 193, 200, 403
- Pronators, 386
- Rotator, 385
- Serratus, 297
- Sinoatrial node, atrioventricular junction, 103
- Skeletal (striated), 377, 378, 380, 385, 388
- Smooth (involuntary), 149, 205, 211, 244, 260, 262, 264, 266, 267, 274, 277, 282, 289, 294, 376-378, 380, 389, 390, 441
- Soft palate (cranial nerves, motor, sensory), 403
- Sphincters, 386, 389
- Sternomastoid (cranial nerves, motor, sensory), 403
- Striated, 170, 173, 176, 205, 267, 376, 389, 390
- Supinator, 386, 389
- Tendons, 381, 383, 384
- Tensors, 386
- Tongue, 173-175
- Transverse, 274
- Trapezius (cranial nerves, motor, sensory), 403
- Tumors of, 174, 386
- Voluntary, 377, 379-380

Muscular system

- Histologic type of cancer, 441
- Skeletal (striated), 441
- Voluntary, 397

Muscularis mucosae (see also Digestive system, Tissue), 166, 168, 169, 181, 184, 205, 210, 220, 244, 262

Muscularis propria (circular longitudinal layer), 166, 168, 205, 208, 210, 214, 220, 244, 262

- Bladder, 262, 266
- Renal pelvis, 244, 260
- Ureter, 257

Myasthenia gravis, 68, 334

Mycosis fungoides, 37, 38, 94

Myelin sheath, 393

Myelogenic, 368

Myeloma (plasma cell), 124, 368

Myeloproliferative disorder (see also Bone marrow), 368

Myocardium (see also Heart muscle), 104

Myometrium, 274, 276, 277, 307, 308

- Structure of, 274

Nails (see also Integumentary system), 27, 31, 43, 45

- Subungual melanoma, 39, 40, 43

Nares (see Nose)
 Nasal bone (facial), 360, 365
 Nasal cavity, tumors of, and/or lymphatic drainage, 74, 135, 137-139, 181, 184
 Nasal fossa, 431-434
 Lymphatic drainage, 431
 Tumors of, 432
 Nasolabial sulcus, 39
 Nasopharynx, 135, 141, 142, 181, 184, 193
 Blood supply to, 139
 Function of, 193, 199
 Location of, 131, 134, 139, 193, 199, 200
 Lymphatic drainage from, 139
 Pharyngeal (adenoid) tonsil in, 68, 94, 139, 142, 161, 162, 193, 201, 202
 Tumor of, 139
 Neck, and/or lymph nodes, 39, 57, 62, 65, 66, 73, 75, 76, 158, 189, 191, 192
 Lymphatic drainage from, 46, 74
 Neck, strap muscle (cranial nerves, motor, sensory), 403
 Nephron, 247, 252, 268, 270
 Major structure, 247, 249
 Nerve (afferent, efferent), 13, 153, 155-157, 205, 210
 Heart action, regulation by, 103
 Olfactory, 135, 432
 Peripheral, 13
 Phrenic, 158
 Recurrent laryngeal, 158
 Tumor (olfactory), 135
 Nerve fiber (white matter), 397
 Nervous system (nerve sheath), 267, 377, 391, 393-401, 403, 404, 407, 408
 Autonomic, 267, 377, 401
 Central nervous system, 393-400, 407, 408
 Cranial, 404
 Meninges, 393
 Motor function, 393, 403
 Parasympathetic, 401
 Peripheral, 393, 401
 Sensory function, 403
 Spinal, 393, 397, 399, 401
 Sympathetic, 401, 407, 408
 Tumors of, 404
 Nervous system, Cranial, 399, 402, 403, 435
 Abducens nerve (VI), 399, 402, 403
 Acoustic (VIII), cochlear, vestibular, 399, 402, 403, 435
 Facial (VII), 399, 402, 403
 Glossopharyngeal (IX), 399, 402, 403
 Hypoglossal nerve (XII), 399, 402, 403
 Oculomotor (III), 399, 403
 Spinal accessory (XI), 399, 402, 403
 Trigeminal (V), 399, 402, 403

Nervous system, Cranial (continued)
 Trochlear (IV), 399, 402, 403
 Vagus (X), 399, 402, 403

Neural crest, 35

Neurilemmoma (neurinoma, schwannoma), 404

Neuroblastoma, 333, 337, 404

Neuroepitheliomatous neoplasms, 404

Neurofibrosarcoma, 404

Neuroglia (glial cells), 393, 404, 407, 408

Neurohypophysis (posterior lobe, pituitary gland), 329

Neuroma, 404

Neurons (gray matter), 393, 394, 399, 404

Nevus (mole, nevi), 35, 39
 Blue, 39
 Compound, 35
 Dermal-epidermal junction, 35, 39
 Giant hairy (pigmented), 35, 39
 Intradermal, 35, 39
 Junctional, 35, 39
 Neural crest origin, 35
 Nonpigmented, 35
 Pigmented (see also Melanoma), 35

Nipple (breast), 297, 300-302, 305

Nodal lymphoid tumor, 94

Nodular melanoma, 40, 43, 45

Non-Hodgkin's lymphoma, 92, 93
 BNLI--British National Lymphoma Investigation, 93
 Cell type predominance, 95, 96
 Diagnostic schemes, 93
 Diffuse, 93
 Dorfman classification, 93
 Extralymphatic, 89
 Extranodal, 89
 Kiel classification, 93
 Lukes-Collins classification, 93
 Multiple primaries, rules for determining, 94
 Rappaport classification, 93
 World Health Organization, 93

Norepinephrine hormone, 333

Nose (see also Respiratory system), 131, 133-135, 161, 162, 431
 Blood supply to, 135
 Cavity (nasal), 135, 137-139, 181, 184, 193, 199, 200, 431-434
 Choana, 135, 139
 Conchae (turbinates), 135
 Functions of, 135, 137, 138
 Lymphatic drainage from, 46, 74, 135, 139, 431
 Membranes (mucous), 135
 Nares (nostril), 39

Nose (see also Respiratory system) (continued)

- Nasolabial sulcus, 39
- Nostrils (see Nares), 135
- Tumors of, 135, 137, 138

Nutrients, 347, 356

Oat cell carcinoma, 157, 160, 161

Occipital (cranial) bone, 359, 363, 365, 375

Occipital lobe of cerebrum, 397

Oculomotor nerve (III), 399, 403

Olfactory (sense organ), 397, 431-434

Olfactory nerve (I), 399, 403, 432

Oligodendroglioma, 404

Optic nerve (II), 399, 403

Oral cavity (see also Buccal mucosa), 139, 169, 173, 181, 183, 184

- Alveolar ridge, process, 177-181
- Anterior wall, 169, 170, 179, 180, 194
- Blood supply to, 169
- Buccal gutter, 178
- Histologic type of cancer, 441
- ICD-O codes for, 194
- Lymphatic drainage from, 74, 139, 189, 192
- Mandible, 177, 178, 185
- Membranes, 169, 170, 173, 176, 178, 185
- Mucosa, 183, 184
- Pterygopalatine arch (palatoglossal), 178
- Retromolar trigone, 177, 178, 184
- Tonsillar fossae, pillar, 177, 181, 194
- Tumors of, 169, 170, 174-178, 181, 184
- Uvula, 194

Organs and lymphoid tissue,

- Lingual tonsil, 173, 174, 193, 201, 202
- Palatine (faucial) tonsil, 193, 194, 201, 202
- Pharyngeal (adenoid) tonsil, 139, 142, 161, 162, 193, 201, 202

Orifices, atrioventricular, 103

Oropharynx (see also Digestive system), 139, 142, 193, 201

- Anatomical limits (anterior, lateral, posterior walls), 194
- Functions of, 194, 199, 200
- Glossopalatine fold (anterior tonsillar pillar), 194, 201, 202
- Palatine (faucial) tonsil in, 68, 94, 193, 202
- Tonsillar fossae, pillar, 194, 201, 202
- Tumors of, 94, 195, 197, 198

Osteitis fibrosa cystica, 332

Osteochondrosarcoma, 371, 375

Osteocytes, 347, 350, 355, 372, 375

- Lacunae, 347

Osteogenic sarcoma, 368, 371, 375, 441

- Primary site for, 441

Ostium (ostia) (see also Salivary gland), 177, 183, 184

Ovary (female gonad), 273, 281, 285, 329, 333, 339
 Endocrine gland (corpus luteum), 281, 329
 Estrogenic hormones of, 281, 285, 329, 333
 Graafian follicles, 281
 Histologic type of cancer, 441
 Krukenberg (metastatic tumor), 211, 285
 Ligaments holding, 281
 Location of, 281
 Lymphatic drainage from, 81, 281
 Mesenchyme, 285
 Ovulation, 281
 Spread of disease from, 285
 Structure of, 281
 Tumors of, 285, 292, 294, 295, 441
 Oviduct (uterine tube), 273, 276, 282, 288
 Ovum (see also Ovary), 281
 Graafian follicle, 281
 Oxidation of fats, carbohydrates, 21
 Oxygen exchange, 53, 57, 63, 65, 66, 99, 102, 105, 107-111, 114, 115, 117, 118, 131, 133, 134, 161
 Oxygenated blood, 53, 63, 66, 105, 107-111, 154
 Oxytocin (pitocin), 330
 Paget's disease, 305
 Palate, 183-185
 Gingival buccal sulcus, 178
 Hard, 178, 181, 183, 184, 189
 ICD-O codes for, 194
 Lymphatic drainage from, 189, 191, 192
 Palatine process, 181
 Soft, 139, 169, 181, 183, 184, 189, 193, 194, 199, 200
 Palatine (faucial) tonsil (see also Tonsil), 68, 94, 193, 194, 201, 202, 365
 Palatine bones and/or process, 135, 181, 183, 184
 Palpation of lymph nodes, 71, 73
 Pancreas (body, tail), 10, 12, 112, 114, 165, 237, 329, 334, 336-339, 441
 Histologic type of cancer, 441
 Islets of Langerhans, 329
 Lymphatic drainage from, 81
 Portal system veins, 112, 114, 237
 Secretions, 215, 237, 239, 240
 Tumors of, 237
 Papillae, 173, 179, 180
 Circumvallate, 173, 176
 Vascular, 31
 Papillary adenocarcinoma, 331, 337, 339
 Para-, 9, 15, 17
 Parametrium (connective tissue surrounding uterus), 277
 Paranasal sinus, frontal, maxillary, sphenoid, 135, 137-139, 161
 Lymphatic drainage from, 135

Paranasal sinus, frontal, maxillary, sphenoid (continued)
 Tumors of, 135, 137, 138
 Parathormone, 332, 336, 338
 Parathyroid gland, 332, 337
 Parenchyma,
 Tumors of, 253, 256
 Parietal, 13, 77, 79-81, 83, 84, 104, 108, 359, 363, 365, 375
 Bone (cranial), 359, 363, 365, 375
 Diaphragmatic lymph nodes, 77, 79, 80
 Heart layers, 104, 108
 Intercostal lymph nodes, 77, 79, 80
 Lobe of cerebrum, 397
 Mammary (internal) lymph nodes, 77, 79, 80
 Pleura, 13, 153, 156, 160-162
 Parotid gland (salivary gland), 185, 188
 Lymphatic drainage from, 74, 189
 Stensen's duct (parotid), 185
 Tumors of, 185, 188
 Patella (kneecap), 351, 354, 367, 369, 373
 Peau d'orange, 302
 Pectoral (major and minor) (see Muscle), 297, 300
 Pelvic cavity (including walls and girdles), 10, 13, 14, 219, 261, 273, 275-277, 282-284, 313,
 317, 343, 351
 Lymphatic drainage from, 81
 Pelvis (ilium, ischium, pubis, hip bones) (see Female pelvis), 242, 261, 272, 312, 343, 351,
 366, 367, 375
 Penile (spongy or cavernous) urethra, 267
 Penis (see also Reproductive system, male), 267, 321, 322, 441
 Basal and Squamous carcinoma, 36
 Blood supply to, 321
 Corpora cavernosa, 321
 Corpus spongiosum, 321
 Foreskin (prepuce), 321
 Glans penis, 267, 321
 Histologic type of cancer, 441
 ICD-O code, skin of, 39
 Lymphatic drainage from, 85, 322
 Prepuce (foreskin), 321
 Tumors of, 323, 441
 Peri- (around), 15, 17
 Pericardial fluid, 104
 Pericardium (see Heart), 103, 104, 108
 Pericollic fat, 221
 Perimetrium (serosa of corpus uteri and bladder), 274, 276
 Perineum, 85, 289, 290, 307, 308
 Periosteal sarcoma, 368, 371, 375
 Periosteum (mucoperiosteum), 178, 181, 355, 356, 358, 368, 384
 Tumors (periosteal sarcoma) of, 368

Peripheral nervous system, 393, 396, 401, 404
 Sheath of Schwann, 393, 404
 Peripheral, 13, 123
 Circulating blood, 123
 Nervous system, 13
 Peristaltic motion, 203, 215, 220
 Peritoneal reflection (see also Rectosigmoid), 219, 220
 Peritoneum (mesentery), lymphatic drainage from, 10, 83, 84, 233
 Visceral, 166, 210, 220
 Peritoneum (uterovesical pouch), 244, 261, 262, 282, 285, 441
 Histologic type of cancer, 441
 Peyer's patches, 53, 56, 68-70
 pH (acid-base balance), 249, 317
 Sperm environment, 317
 Phagocytosis, 62, 67, 229
 Phalange (finger and toe), 351, 367, 369, 373
 Pharyngeal (hypopharyngeal, oropharyngeal) wall, 68, 194, 195
 Pharyngeal tonsil (adenoid), 68, 94, 139, 142, 161, 162, 193, 201, 202
 Pharyngoepiglottic fold, 194, 195
 Pharynx (throat) (see also Hypopharynx, Nasopharynx, Oropharynx), 68, 161, 162, 165,
 168, 169, 181, 184, 194, 195, 197-200, 203, 208, 441
 Blood supply to, 139, 193
 Composition of, 139, 141, 142, 193, 199, 200
 Histologic type of cancer, 441
 Lymphatic drainage from, 74, 139, 193
 Motor functions of, 403
 Muscle functions of, 403
 Oral cavity and/or ICD-O codes for, 194
 Palatine (faucial) tonsil (see Tonsil), 193, 201, 202
 Pharyngeal recess (Rosenmuller's fossa), 139
 Pharyngeal tonsil (adenoid) (see Tonsil), 193, 201, 202
 Structure of, 139, 193
 Tumors of, 195, 197, 198, 201
 Wall, 68, 139, 194, 195
 Pheochromocytoma, 333
 Phosphorous levels, 332
 Pia mater, 399, 404
 Pigment cell (melanin, melanocytes), 21, 23, 26, 35, 36, 39, 40
 Pineal gland (epiphysis), 332
 Location of, 332
 Tumors of, 332
 Pinealoma, 332
 Pitocin (see Oxytocin), 330
 Pituitary gland (Hypophysis), 281, 329, 330, 397
 Function of, 329, 330
 Hormones secreted by, 281, 329
 Lobe of, Anterior (adenohypophysis), 329
 Lobe of, Posterior (neurohypophysis), 329, 330

Pituitary gland (Hypophysis) (continued)
 Location of, 328, 329
 Tumors of, 330
 Placenta, 278, 334
 Hormones secreted by, 334
 Planes of the body, 9, 10
 Plasma (plasmacyte), 54, 62, 63, 67, 115, 118, 124, 229
 Plasma cell myeloma, 124
 Plasmacytoma, 124
 Platelets (see Blood, thrombocytes), 115, 118, 119
 Pleomorphic adenomas, 185
 Pleura (parietal, visceral), 13, 104, 108, 153, 156, 157, 160-162, 441
 Histologic type of cancer, 441
 Lymphatic drainage from, 77
 Serous membrane, 10, 104, 108
 Pleural cavity (left, right) and/or interpleural space, 10, 153, 158-162
 Pleural effusion, 158
 Pneumonitis, 158
 Polycythemia, (primary, rubra vera, secondary, vera), 115, 127, 128
 Porta hepatis, 229
 Portal system (see also Intestine, Pancreas, Spleen, Stomach, Venous system), 100,
 112-114, 210, 221, 237
 Circulation, 100, 112, 113
 Positional terms, 9, 12, 14-17
 Head (cephalo), 9
 Postcricoid area, 195, 201, 202
 Posterior (dorsal) plane, 9, 10, 12, 15, 17
 Posterior (laryngeal) surface, 144
 Posterior ligament, 277
 Posture, 385, 387, 388
 Potassium, 249, 333
 Pre-, 15, 17
 Prefixes for medical terms, 9, 14
 Prepuce (foreskin), 289
 Primary site, 445
 Multiple primaries and, 445, 471, 472
 Process (mandible, palatine), 178-181, 183, 184
 Proct(o)-, 9
 Progesterone, 281
 Progestin, 333
 Prolactin (LTH), 330
 Pronator muscle, 386
 Proprioceptor, 411, 413, 414
 Prostate, 261, 267, 309, 313, 317, 318, 441
 Capsule, 317
 Histologic type of cancer, 441
 Lymphatic drainage from, 81, 322
 Tumors of, 317, 323

Prostate (continued)

- Urethra (prostatic), 313, 316, 318
- Prostatic hyperplasia and prostatic hypertrophy, 318
- Protein, blood and/or water soluble, 115, 119, 211, 215, 229
- Prothrombin (see also Blood), 119
- Proximal, 12, 15, 17
- Pseudomyxoma peritonei, 285
- Pterygopalatine arch (palatoglossal), 178
- Pubic (pelvis) bone, 261
- Puboprostatic ligament, 317
- Pudendum (see also Vulva), 273
- Pulmonary (circulatory) circuit, 99, 102, 103, 105, 108, 110, 111
- Pylorus (pyloric antrum, sphincter), 209, 211, 214, 230
- Pyramidal sinus (see also Hypopharynx), 195, 201, 202
- Quadrants (divisions, quarters), abdominal, 13
- Quadriceps femoris muscle, 351
- Radial (superficial spreading melanoma), 40, 43, 45
- Radius (lower arm), 351, 367, 369, 373
- Rappaport classification for non-Hodgkin's lymphoma, 93
- Rathke's pouch tumor, 330, 405
- Receptor (see Sense organs), 411
- Recklinghausen's disease, 332
- Rectosigmoid colon and/or junction, 219
- Rectum, 9, 10, 12, 165, 168, 219, 220, 226, 261, 290, 441
 - Histologic type of cancer, 441
 - Lymphatic drainage from, 81, 222, 227, 228
 - Metastatic site for, 290
 - Tissue layers (see also Digestive system), 166
- Reed-Sternberg cell, 90, 92
- Relative positions, directional terms, 9, 10, 12
- Renal cell carcinoma, 253, 256, 441
 - Primary site for, 441
- Renal pelvis, 244
 - Histologic type of cancer, 441
 - Structure of, 244
- Reproductive organs, 10
- Reproductive system (female), 261, 267, 272, 273, 275-277, 279-295, 297, 299-305, 307, 308, 329
 - Breast, 297, 299-305
 - Corpus uteri, 274-277, 279, 280
 - External genitalia (pudendum), 273, 289, 291, 294, 308
 - Fallopian tube, 275, 276, 282-288, 307
 - Ovary (female gonad), 273, 275, 276, 281, 284, 285, 288, 329
 - Tumors of, 277, 281, 282, 285, 290, 304, 305
 - Uterus, 261, 273, 275-277, 279, 280, 284, 288
 - Vagina, 261, 275, 289, 290
 - Vulva, 267, 275, 293, 294, 308

Reproductive system (male), 267, 289, 309, 311-313, 315-322, 325, 326, 329
 Bulbourethral gland, 289, 309, 318
 Excretory ducts (epididymis, ductus deferens, ejaculatory), 309, 313, 315, 316
 Functions of, 309
 Hormone secretion, 309
 Penis, 267, 289, 309, 321, 322
 Prostate gland, 309, 317, 318, 320, 323
 Scrotum, 309, 312
 Seminal vesicle, 309, 313, 317, 319, 320
 Testis, 309, 313, 315, 316, 322, 326, 329
 Tumors of, 323, 325
 Respiratory system (see also Nose, Paranasal sinuses, Nasopharynx, Larynx), 243
 Bronchioles, 154, 157, 161, 162
 Bronchus (lungs), 149, 152, 153, 155-157
 Cellular, 131
 External (inhaling, exhaling), 131, 161, 162
 Function of, 131
 Internal, 131, 135, 161, 162
 Reticuloendothelial cell (see also Cell type), 61, 67
 Reticulum cell (stem sarcoma), 368, 371, 375
 Primary site for, 441
 Retina (eye), 415, 417, 418, 423
 Retinoblastoma, 423
 Retraction of the nipple, 302
 Retro-, 15, 17
 Retrograde flow (see also Lymphatic system), 57, 62, 157
 Retromolar trigone (mandible), 177, 178
 Rhabdomyosarcoma, 386, 389, 441
 Primary site for, 441
 Rib, 13, 131, 157, 343, 351, 356, 372, 375
 Connective tissue, 372, 375
 False, 361
 Floating, 361
 True, 361
 Rotator muscle, 385
 Round bones, 351, 353, 354, 356
 Round ligament, 277
 Rugae (see also Stomach), 210, 289
 Gallbladder, 233
 Sacrum, 351, 353, 354, 361, 368
 Lymphatic drainage from, 65, 66
 Tumors of, 368
 Sagittal plane, 10, 12
 Salivary gland (see also Parotid, Sublingual, Submandibular), 165, 185, 187
 Function of, 185
 Lymphatic drainage from, 189
 Mixed type tumors, 185, 188
 Ostia (ostium), 177, 183, 184

Salivary gland (see also Parotid, Sublingual, Submandibular) (continued)
 Saliva secretion from, 169, 185
 Tumors of, 139, 177, 185, 187, 188

Salts, 249, 251, 252, 347

Sarcoma (see also non-Hodgkin's lymphoma), 90, 368, 371, 386, 441
 Angiomyosarcoma, 386
 Angiosarcoma, 368, 371, 375
 Blood-borne metastasis, 71-73, 230, 368
 Chondrosarcoma (osteochondrosarcoma), 368, 441
 Ewing's sarcoma, 368, 371, 375, 441
 Fibrosarcoma, 368, 386, 441
 Giant cell (malignant osteoclastoma), 368, 371, 375
 Hemangiosarcoma, 441
 Leiomyosarcoma, 386, 389, 390, 441
 Liposarcoma, 441
 Lymphangiosarcoma, 441
 Lymphosarcoma, 441
 Mesothelial sarcoma, 441
 Multiple Myeloma, 368, 371
 Osteochondrosarcoma, 371, 375
 Osteogenic, 368, 375, 441
 Osteosarcoma, 371
 Periosteal, 368, 371, 375
 Reticulum cell, 441
 Rhabdomyosarcoma, 386, 441
 Skin, 36, 38
 Synovial, 386

Scalp, and/or lymphatic drainage from, 39, 46, 74

Scapula (upper back), lymphatic drainage from, 85

Schwann cell, 393

Schwannoma, 404

Scirrhous (adeno) carcinoma, 305

Sclera (eye), 415, 417, 418, 425, 426
 Cornea, 415
 Iris, 415
 Pupil, 415

Scrotum (see also Reproductive system, male), 309, 311
 ICD-O codes, skin of, 39
 Lymphatic drainage from, 46, 85, 87, 88
 Malignancies, skin of, 36
 Sac, 309, 339
 Spermatic cord, 309, 339

Sebaceous gland (see also Integumentary system), 21, 23, 27, 30, 31, 33, 34
 Adenocarcinoma, 36

Secretin, 334

SEER incidence tabulation, 223

Sella turcica, 359

Seminal fluid, 317, 319, 320

Seminal vesicle, duct and tubule, 309, 313, 317, 319

Seminoma, 323, 441
 Primary site for, 441

Sense organs (receptors), 409, 410, 413-415, 417-419, 421-423, 425-438
 Classification of, 411
 Exteroceptors, 411, 413, 414
 Gustatory (taste), 410, 413, 414, 427, 429, 430
 Olfactory (smell), 397, 403, 410, 413, 414
 Proprioceptors, 411, 413, 414
 Tactile (touch), 403, 410, 413, 414
 Visceroceptors, 411, 413, 414

Sensory nerve fibers, 393-397, 399, 401, 403
 Functions of, 403

Serosa (see also Digestive system), 166, 168, 205, 208, 210, 214, 215, 219, 220, 233, 244,
 261, 262, 274, 276, 277, 282, 285
 Bladder covering, 244, 261, 262
 Bladder, 266
 Fallopian tube, 282
 Uterine, 276, 277

Serous cystadenocarcinoma, 285

Serratus muscle (see also Muscle), 297

Sertoli cell tumors, 323

Serum acid phosphatase, 317

Sesamoid bone, 351, 353, 354, 356

Sheath of Schwann, 393

Short bones (cuboid, irregular), 351, 356, 367, 369, 373

Shoulder, and/or lymphatic drainage from, 39, 46, 85

Sigmoid colon (pelvic), 10, 166, 219, 220, 223, 226-228

Sinoatrial node, atrioventricular junction, 103

Sinuses, 62
 Ethmoid, 138, 359
 Frontal, 138, 359
 Lymph (sinus) marginal, medullary channels, 62
 Lymphatic drainage from, 135
 Maxillary (antrum of Highmore), 135, 138
 Nasal, Paranasal (accessory), 135, 137-139, 161
 Pyriform, 195, 201, 202
 Sensations from, 403
 Sphenoid, 135, 138, 359
 Tumors of, 135, 138

Sinusoids, 112

Skeletal (voluntary, striated) muscles, 377, 378, 380, 383, 385-390
 Function of, 385, 387

Skeletal system (see also Bone, Cartilage, Connective tissue), 341-343, 345-347, 349-351, 354-369,
 371-373, 375, 377, 378, 380, 383, 386-389

Skene's gland, 289, 292

Skin (see also Integumentary system), 285, 289, 291, 294
 Pigmentation (melanin), 330

Skull (diploe), 351, 354, 356, 359, 360, 363-365, 397
 Base, 193
 Cranium, 359
 Ear (small bones of middle), 359
 Face, 359, 360
 Hyoid, 359, 363, 364
 Smooth (involuntary) muscle, 330, 377, 378, 380, 386, 389, 390, 441
 Histologic type of cancer, 441
 Soft palate, 139, 169, 181, 183, 184, 193, 194, 199, 200, 403
 Somatotrophic hormone, 329
 Spermatic cord, 309, 313, 337, 339
 Spermatogenesis, 313, 329
 Sphenoid (cranial, paranasal bone), 329
 Sphenoid sinus (paranasal), 135, 138
 Sphincter muscle, 386, 389
 Spinal accessory nerve (XI), 399, 402, 403
 Spinal column, 10, 13, 243, 246, 377, 399
 Autonomic nervous system, 377
 Nerve, 404
 Spinal cord, 399, 404
 Spleen (see also Lymphatic system), 10, 67, 69, 70, 112, 114, 115, 219, 237
 Lymphatic drainage from, 81
 Lymphoma (nodal) in, 94
 Phagocytosis, 229
 Portal system veins, 112, 114, 210, 221, 237
 Tumors of, 94
 Splenic flexure, 219, 227
 Spread of cancer (see Metastasis)
 Squamous cell (epidermoid) carcinoma, 36-38, 135, 138, 139, 145, 157, 160, 169, 170, 174,
 177, 178, 181, 184, 185, 195, 198, 205, 211, 222, 253, 255, 256, 264, 277,
 290, 295, 423, 427, 432, 434
 Primary site for, 441
 Renal pelvis, 253
 Squamous columnar junction, 277
 Stem cells, 123, 124
 Stensen's duct (parotid), 185
 Sternomastoid (cranial nerves, motor, sensory), 403
 Sternum (breast bone), 334, 351, 356, 361, 367, 369, 373, 375
 Steroids, 333, 335
 Aldosterone, 333
 Androgens, 333
 Cortisol, 333
 Estrogen, 281, 333
 Progesterin (progesterone), 281, 333
 STH (see Somatotrophic hormone), 329
 Stomach (see also Digestive system), 10, 12, 112, 114, 165, 168, 193, 203, 208, 212, 219,
 229, 233, 237, 285, 334, 441
 Blood supply to, 210

Stomach (see also Digestive system) (continued)
 Cardia (body, corpus), 209, 214
 Cardioesophageal junction (cardiac orifice), 203, 211
 Chyme (fluid content), 209, 211, 215
 Corpus (body), 209, 214
 Curvature (greater, lesser), 67, 210
 Functions, 209, 211, 213, 214
 Fundus (fornix), 209, 214
 Gastrin, 334
 Histologic type of cancer, 441
 Hormone secretions, 334
 Krukenberg metastatic tumor, 211, 285, 292, 295
 Linitis plastica, 211
 Lymphatic drainage from, 81, 210, 212, 214
 Lymphoma (extralymphatic, extranodal), 94, 96, 211
 Omentum (greater, gastrocolic, lesser, gastrohepatic), 210
 Portal system veins, 112, 114, 210
 Pylorus (pyloric antrum, sphincter), 209, 211, 214, 215, 230
 Rugae, 210
 Secretions, 209-211, 214
 Tissue layers (see also Digestive system), 166-168, 210, 212, 214
 Tumors of, 211, 213, 214, 285, 441
Strap muscles of neck, 403
Stratified, 274, 289
Striated muscle (see Muscle, skeletal), 441
 Histologic type of cancer, 441
Stroma, 274, 277, 278, 285, 289, 305, 317, 323, 331
Sub- (under), 9, 15, 17
Subclavian vein (see also Venous system), 53, 56, 57, 63
Subcutaneous tissue, 23, 41, 44, 45
Subglottis (see also Larynx), 144, 148
 Cartilage (Cricoid), 144
Subleukemic (aleukemic), 124
Sublingual (salivary) glands, 185, 188, 189
 Ostia of, 177, 184
Submandibular (submaxillary) salivary gland, 185, 188
 Lymph node, 46, 49, 50, 75, 76, 191, 192
 Lymphatic drainage from, 74, 189
 Ostia of, 177, 183
Submucosa (gastrointestinal), 166, 168, 169, 181, 205, 208, 210, 214, 220, 244, 257, 260, 262, 266
 Bladder (wall), 262, 266
 Renal pelvis, 244, 260
 Ureter, 257
Subserosa (see Connective tissue and Fat)
Sudoriferous (sweat) gland, 27, 30, 31, 115
 Adenocarcinoma, 36
 Excretion of waste products, 33, 34, 115

Sulcus,
 Buccal, 178
 Nasolabial, 39
 Superficial spreading (radial) melanoma, 40, 43, 45
 Superficial, 12, 15, 17
 Superior (cephalic, cranial) plane, 12, 14-17
 Supinator muscle, 386, 389
 Supra- (above), 9, 14, 15, 17
 Supraclavicular (transverse cervical), 74, 76
 Supraglottis (see also Larynx), 144, 148, 161
 Aryepiglottic folds, 144
 Arytenoid (see Cartilage), 144
 Posterior laryngeal surface of epiglottis, 144
 Tumors of, 145
 Ventricular bands (false cords), 144, 148
 Suprarenal (adrenal) gland, 14, 333, 334
 Surface epithelium (see also Digestive system), 166, 168, 205, 210, 220
 Suturae, 359, 360
 Sweat gland (see Sudoriferous), 36
 Synovial sarcoma, 386
 Systemic circulation, 99, 102, 103, 105, 110
 Systolic blood pressure, 105
 T-cell, 54, 68-70, 334
 Tactile (sensations of touch, see also Sense organs), 403, 410, 413, 414
 Taenia coli, 220
 Tarsal (ankle), 351, 356, 367, 369, 373
 Taste (sensations of, see also Sense organs), 403, 410, 413, 414
 Receptors (buds), 410, 413, 414, 427-430
 Teeth (incisors), 165, 169, 178, 183, 184, 203, 403
 Mastication, 169, 403
 Odontogenic tumor, 178
 Sensations from, 403
 Telencephalon (see Forebrain), 397
 Temple, lymphatic drainage from, 46
 Temporal (cranial) bone, 343, 351, 354, 359, 363-365, 372
 Temporal lobe of cerebrum, 397
 Tendon, 381, 383, 384
 Achilles, 381
 Proprioceptors (receptor), 411, 413, 414
 Tensor muscle, 385, 386
 Teratocarcinoma, 292, 295, 323
 Testis (male gonad), 261, 309, 311-313, 329, 441
 Endocrine gland, 329
 Functions of, 308, 309
 Histologic type of cancer, 441
 Hormones secreted by, 309, 311
 Inguinal canal, 313
 Lymphatic drainage from, 81, 322

Testis (male gonad) (continued)
 Seminal fluid, 317, 319, 320
 Seminal vesicles, 309, 317, 319, 320
 Seminiferous tubule duct and gland, 309, 329
 Spermatazoa (sperm), production of, 329
 Spermatic cord, 313, 337
 Tumors of, 323, 441
 Vas deferens, 261, 313, 315, 316
 Testosterone, 309, 329
 Tethering of breast, 302
 Thalamus, 397
 Theca cell, 285
 Tumor, 285
 Thigh, lymph nodes located in, 85, 87, 88
 Thorax (chest), 77, 79, 80, 131, 153, 155, 156, 161, 162, 189, 191, 192, 334, 343, 356, 359,
 361, 362, 369, 375
 Cavity (thoracic), 10, 13, 68, 77, 79, 80, 134, 203, 207, 208
 Cisterna chyli, 57
 Duct (thoracic), 57, 60, 221
 Lymphatic drainage from, 49, 50, 77, 79, 80
 Mediastinal (anterior, posterior), 205, 229
 Parietal nodes, 77, 79, 80
 Skin of lower chest wall, 189, 191, 192
 Sternum, ribs, 334, 343, 356, 361, 367, 369, 373, 375
 Vertebra (thoracic), 203
 Vertebrae (see also Vertebral column), 399
 Visceral nodes, 77, 79, 80
 Thrombocyte (see Blood and/or Platelets), 115, 118, 119
 Thrombocytopenia, 124
 Thrombus (thromboembolus), 119, 122
 Thymoma, 334
 Thymus (see also Lymphatic system), 53, 54, 56, 67-70, 334, 337, 339
 Location of, 68
 Lymphatic drainage from, 77
 Tumors of, 334
 Thyrocalcitonin, 331
 Thyroid gland, 68, 329, 331, 332, 336-339
 Adrenal cortical adenocarcinoma, 333
 Arteries, 144
 Cartilage (Adam's apple), 148, 195
 Ganglioneuroma, 333
 Hormone secretion from, 329
 Lymphatic drainage from, 74, 331
 Pheochromocytoma, 333
 Squamous cell (epidermoid) carcinoma, 264
 Thymomas, 334
 Tumors of, 331
 Thyrotrophic (thyroid-stimulating) hormone (TSH), 329

- Tibia (shin bone), 351, 369
 - Tumors of, 368
- Tissue, 53, 56, 59, 60, 62, 69, 94, 243, 244, 253, 257, 259-262, 285, 313, 329, 331
 - Adipose (fat), 329
 - Ciliated, 282, 285, 288
 - Connective, 61, 166, 170, 205, 208, 210, 243, 244, 257, 261, 262, 277, 289, 313, 321, 347, 368, 381, 383, 384, 389, 390, 393, 441
 - Embryonal, 253
 - Embryonic, 285, 323
 - Endometrial, 275
 - Epithelial, 68, 244, 257, 260, 262, 274, 285, 288, 295
 - Erectile, 321
 - Fluid (interstitial fluid), 63, 66
 - Glandular (isthmus), 331, 336
 - Layers of the GI tract, 166-168, 207, 208, 212, 220
 - Lymphatic drainage from, 85
 - Lymphoid, 53, 55, 56, 61, 62, 67, 68, 71, 89, 91, 92
 - Myometrium, 276
 - Parenchyma, 243, 245, 246, 253, 255, 256
 - Renal pelvis, 244, 259, 262
 - Transplant and rejected tissue, 68
 - Tumors of, 441
 - Ureter, 257, 262
 - Urinary bladder, 262
- Toe, finger (see Phalange)
- Tongue (apex, dorsal, lateral, ventral surface), 165, 169, 175, 176, 179, 180, 184, 189, 427-430
 - Anterior two-thirds, 74, 173-176, 189
 - Base (vallecula), 173-176, 193, 194, 201, 202
 - Circumvallate papillae, 173, 176, 179, 180
 - Frenulum, 173, 177
 - Functions, 173, 403
 - ICD-O code for, 194
 - Lingual tonsil at base of tongue, 68, 94, 173, 174, 193, 427
 - Lymphatic drainage from, 74, 189, 191, 192
 - Midline, 173
 - Muscle motor, sensory function, 403
 - Posterior one-third, 427
 - Salivary glands (minor), 177, 185
 - Sensations (taste), 403
 - Sensations from, 427
 - Tumors of, 94, 174, 175, 427
 - Ventral surface of, 173
- Tonsil (see also Lymphatic system), 53, 56, 69
 - Extralymphatic lymphoma of, 94
 - Fossa, 194
 - Glossopalatine fold, 194, 201, 202
 - Lingual, 94, 173, 174, 193, 201, 202, 427

Tonsil (see also Lymphatic system) (continued)

- Location of, 68
- Palatine (faucial), 68, 94, 193, 194, 201, 202
- Pharyngeal (adenoid), 68, 94, 139, 142, 161, 162, 193, 201
- Pharyngoepiglottic fold (posterior tonsillar pillar), 194, 195
- Pillars (anterior, posterior), 177, 181, 194, 201, 202
- Sensations of, 403
- Tumors of, 181, 427
- Waldeyer's ring, 68-70, 94

Topography code (ICD-O) of skin, 39

Touch (see Sense organs, tactile)

Trachea (windpipe), 12, 131, 134, 143, 151, 152, 154, 157, 161, 162, 203, 331, 337, 339, 403, 441

- Cartilage (tracheal), 149
- Histologic type of cancer, 441
- Lymphatic drainage from, 77
- Sensations from, 403

Transitional cell carcinoma, 222, 253, 255-257, 264, 267, 441

- Primary sites for, 441

Transplant and rejected tissue (see also Tissue), 68

Transverse (horizontal) plane, 10

Transverse colon (see also Colon), 166, 219, 220, 223, 226, 227

Trapezius muscle, motor, sensory function, 403

Tri-iodothyronine, 329, 331

Trigeminal nerve (V), 399, 402, 403

Trochlear nerve (IV), 399, 403

Trophoblast (trophoblastic), 323

Trunk of body (lower, upper), 12

- Lymphatic drainage from, 77, 80
- Topography code for skin of, 39

TSH (see Thyrotrophic hormone), 329

Tubules, 247, 249, 268, 270

- Collection, 247, 268, 270
- Convolutd and distal, 247
- Renal, 247, 268, 270

Tumor (see also specific histologic type), 244, 253, 255-257, 262, 264, 267, 285, 292, 294, 323, 330, 441

- Adenocarcinoma, 253, 255, 256, 264, 277, 331
- Adenoma, 330
- Astrocytoma, 404
- Basophilic, 330
- Benign, 89, 91, 92
- Bladder, 264
- Blood-borne metastasis, 230
- Blood-forming organs, 125, 126
- Buccal mucosa, 181
- Carcinoid, 157, 215, 218, 222
- Chondrosarcoma, 441

Tumor (see also specific histologic type) (continued)

Choriocarcinoma, 278
Craniopharyngioma, 330, 337
Cylindroid, 157
Diagnostic workup for, 71-73
Ependymoma, 404
Esophagus, 205
Esthesioneuroblastoma, 432
Eyelid, 39
Fibrosarcoma, 441
Ganglioneuroma, 333
Germ cell, 285, 292, 294, 323
Giant cell, 368
Glioblastoma, 404
Glottic region (larynx), 145
Grading bladder tumors, 264
Grawitz's, 256
Gum (gingiva), 178
In-situ (intraepidermal), 36
Intestinal, 215, 217, 218, 222, 223
Kidney, 253
Krukenberg, 285, 292, 295
Larynx, 441
Leiomyosarcoma, 264, 277
Leydig (interstitial) cell, 323
Lip, 39
Liver, 211, 229, 231, 232
Lung, 157, 158
Lymphatic metastasis, 211
Lymphatic spread, 72, 73, 94
Lymphoid tissue, 94, 174, 195, 221
Lymphoma, 432
Malignant, 253
Medulloblastoma, 404
Melanoma, 432
Meningiomas, 404
Metastatic process (spread), 157, 229, 230
Multifocal, 36-38
Nasopharynx, 139
Neurilemmoma, 404
Neuroblastoma, 333, 337, 404
Neurofibrosarcoma, 404
Nose, 135, 137, 138
Oligodendroglioma, 404
Oral cavity, 169, 170, 174, 177, 183, 184
Osteogenic, 368
Ovarian, 285
Papillary adenocarcinoma 331

Tumor (see also specific histologic type) (continued)

- Paranasal sinus, 135, 137, 138
- Penetration (measure of spread), 40, 166
- Periosteal sarcoma, 368
- Pharynx, 195, 197, 198, 441
- Pheochromocytoma, 333
- Pinealomas, 332
- Pituitary, 330
- Premalignant, 35, 222
- Rathke's pouch, 330
- Renal pelvis, 253
- Retinoblastoma, 423
- Salivary glands, 177, 185, 187, 188
- Sarcoma, 386
- Sertoli, 323
- Skin, 35-40, 43
- Squamous cell (epidermoid) carcinoma, 253, 255, 256, 264, 427, 432, 441
- Staging bladder tumors, 264
- Stomach, 211, 213, 214, 441
- Thymic, 68
- Thyroid, 331
- Tongue, 174-176, 427
- Transitional cell carcinoma, 256
- Urethra, 267
- Uterus, 277
- Vascular (Kaposi's), 36
- Wilms', 253, 255, 256

Tunica albuginea, 309

Turbinate (concha), 135

Tympanic cavity, membrane, and/or lymphatic drainage from, 31, 74

Ulceration, 302

Ulcerative colitis, 222

Ulna (lower arm), 351, 367, 369, 373

Umbilical region (navel), 14

Underarm lymph nodes, 85

Underside (ventral), 12

Undifferentiated (large cell) carcinoma, 157, 160, 161

Upper extremity, 367

Urea, 229

Ureter, 10, 242-246, 249, 257, 260-262, 266, 268-270, 289, 441

- Histologic type of cancer, 441
- Lymphatic drainage of, 257
- Obstruction, 257
- Orifices, 261, 266
- Structure of, 257
- Tumors of, 257

Urethra (female, male), 242, 243, 246, 261, 266-268, 270, 289

- Histologic type of cancer, 441

- Urethra (female, male) (continued)
 - Location of, 267
 - Meatus, 289
 - Membranes, 267, 268
 - Orifices, 261, 266
 - Penile, 267
 - Prostatic, 267
 - Sphincter (internal, external), 267
 - Tumors of, 267
- Urinary system (female, male), 241-249, 251-253, 255-257, 259-263, 265-270
 - Bladder, 242, 243, 261-263, 265, 266
 - Excretory system, 243
 - Kidney, 242-245, 247, 249, 251, 253, 256, 257, 259, 260
 - Metastases, 290
 - Renal pelvis, 242
 - Tumors of, 253
 - Ureter, 242-246, 249, 257, 260-262, 266, 268-270
 - Urethra, 242, 243, 246, 261, 266-268, 270, 289, 290, 292, 294, 313, 315-318, 321
 - Urethral meatus, 289, 291, 294
- Urine (see also Ureter and Urethra), 243, 249, 252
 - Acid-base balance (pH), 249
 - Excretion of water, 249, 252
 - Formation and production of, 243
- Uterine tube (see Fallopian tube), 282
- Uterosacral ligament, 277
- Uterovesical pouch (peritoneum), 244, 261, 282
- Uterus (see also Reproductive system, female), 261, 272-277, 281, 308, 377
 - Apex, 277
 - Arteries, 277
 - Blood supply to, 277
 - Cervix uteri, 273-277
 - Composition of, 274
 - Corpus uteri, 273-277
 - Cul de sac, 273, 307, 308
 - Endometrium, 275, 276
 - Epithelial tissue, 274
 - Fallopian tube (uterine tube and oviduct), 275-277, 282-284, 286-288, 307, 308
 - Fimbria(e), 308
 - Fundus, 273, 276
 - Ligaments holding, 277
 - Location of, 273
 - Lymphatic drainage of, 81, 277
 - Myometrium, 274-277, 307, 308
 - Os (internal and external), 277, 286-288
 - Ovaries, 273, 275, 276, 281, 283, 284, 307, 308
 - Parametrium, 277
 - Serosa, 276
 - Structure of, 273

Uterus (see also Reproductive system, female) (continued)
 Tumors of, 277
 Walls of, 277
 Uvula, 194
 Vagina, 81, 261, 273, 276, 277, 288, 289, 441
 Composition of, 289, 291, 294
 Function of, 289
 Histologic type of cancer, 441
 Lymphatic drainage from, 290
 Os (internal and external), 277, 286-288
 Tumors of, 277, 290, 293, 295
 Upper, 261
 Vestibule, 289
 Vagus nerve (X), 399, 402, 403
 Vallate papillae, 173, 176
 Vallecula (tongue base), 173, 194
 Valve (see also Heart),
 Ileocecal, 215, 219
 Lymphatic, 57
 Vas deferens (ductus deferens), 261, 313, 315, 316
 Vascular papillae, 31
 Vasopressin, 330
 Vena cava (inferior, superior), 105, 110, 112, 114
 Venous system (see also Cardiovascular, Portal system), 112-114, 169
 Cavity, 10
 Cranial sinuses, 135
 Drainage, 112, 114, 205, 210
 Gastric veins, 112
 Hepatic veins, 112, 114
 Jugular (external, internal), 57, 71, 135, 139, 144, 169, 193
 Lymphatic system, 53, 57, 60
 Mesenteric (superior, inferior), 112, 210, 221
 Metastasis via venous blood, 230
 Pancreatic vein, 112
 Portal system, 100, 112-114, 210, 221, 237
 Pulmonary, 105, 108, 110, 111, 153-156
 Splenic, 112, 114, 210, 237
 Subclavian, 53, 56, 63
 Thyroid, 144, 205
 Veins (see also Vessels), 55, 57, 59, 60, 71, 99, 102, 103, 105, 107, 109-111, 114
 Ventral (anterior, underside), 10, 12, 15, 16
 Ventricle, heart, 103, 105, 107, 108, 110
 Ventricular bands (see Vocal cords)
 Venules (small veins), 111, 114, 154
 Vermilion border (lip), 39, 170, 172
 Vertebra, cervical, 203
 Spinal cord (spine), 10, 13
 Thoracic, 203

Vertebral cavity, 10
 Vertebral column (cervical, thoracic, lumbar, sacral, coccyx), 343, 359, 361, 362
 Vertical plane, 10, 15, 16
 Vessels (see also Arteries, Capillaries), 262, 333, 441
 Blood, 31, 53, 63, 65, 66, 71-73, 99, 101, 102, 105, 109-111, 113, 114, 119, 153-157, 166, 205, 210, 229, 244, 249, 262, 333, 441
 Coronary, 103
 Functions of, 99, 101, 102, 111, 113, 114
 Heart, 103, 109, 111, 114, 115
 Histologic type of cancer, 441
 Lymph (afferent, efferent), 135, 153, 155, 156, 166, 205, 210, 229, 262, 441
 Obstruction (embolus, thrombus), 119, 122
 Pulmonary veins, 101, 102, 105, 108, 110, 111, 153-156
 Skin, 23, 27
 Thrombus, 119, 122
 Tumors of, 229
 Villi (lacteals) (small intestine), 215, 220
 Lymphatics originating in, 57
 Villous adenoma, 222
 Villus (Villi), 57
 Visceral (viscera), 13, 15, 17, 229
 Heart layers, 104, 107, 108
 Lymph nodes (see Abdomen), 81, 83, 84
 Peritoneum (mesentery), 166, 210
 Pleura, 13, 153, 156, 160-162
 Thoracic viscera, 10
 Visceral lymph nodes, 77, 80
 Mediastinal (anterior, posterior), 77, 79, 80, 158, 160
 Tracheobronchial (carinal, hilar, peritracheal), 77, 80
 Visceroceptors (receptors), 411, 413, 414
 Vitamins, 211, 229
 Vocal cords (ventricular bands, voice box), 147
 False, 143, 148
 Paralysis, 154, 158
 True, 143-145, 148, 162
 Tumors of, 145
 Voluntary muscle, 377, 397, 401
 Vomer (facial bone), 360, 365
 Vulva (pudendum, external genitalia), 267, 273, 275, 276, 289, 291, 294, 307, 308, 441
 Clitoris, 289, 291, 294
 Histologic type of cancer, 441
 Labia (majora, minora), 289, 291, 292, 294
 Lymphatic drainage from, 46, 85, 293
 Malignancies, skin of, 36, 43
 Melanoma, skin of, 39
 Mons pubis, 289, 291, 294
 Spread of disease from, 290
 Tumors of, 290, 293, 295

Waldeyer's ring, 68-70, 94
 Lymphoma in, 94
Waste from, 249, 347, 356
 Blood, 249, 347, 356
 Kidneys, 249, 252
Water, 211, 214, 215, 219, 220, 249, 251, 252
Wharton's duct (parotid), 185
White blood cell counts, 119, 123, 124
Wilms' tumor, 253, 255, 256, 441
 Primary site for, 441
Wirsung (pancreatic) duct, 215, 237
Wrist (carpal) bone), 351, 356, 367, 369, 373
Zygomatic/malar (facial) bone, 360, 365