

# Effects of Chronic Topical Application of 12-O-Tetradecanoylphorbol-13-acetate on the Skin and Internal Organs of SENCAR Mice

by Andres J. P. Klein-Szanto,<sup>\*§</sup> Claudio J. Conti,<sup>\*</sup>  
Claudio M. Aldaz,<sup>\*</sup> Neal Clapp,<sup>†</sup> Stephen Nesnow,<sup>\*\*‡</sup> and  
Thomas J. Slaga<sup>\*</sup>

Repetitive topical applications of 2  $\mu$ g 12-O-tetradecanoylphorbol-13-acetate (TPA) twice weekly for 37 to 52 weeks induced a sustained epidermal hyperplasia, hyperplasia of hair follicles, and increased dermal cellularity in SENCAR mice. In addition, after 52 weeks of protracted promoter treatment most animals developed generalized amyloidosis involving liver and spleen, as well as interstitial nephritis. Severe pyelonephritis and papillary necrosis were also frequently seen. Reactive lymphoid hyperplasia was also a frequent finding. Chronic administration of TPA is not an innocuous treatment affecting only the interfollicular epidermis. The general effect of the promoter on the animals was a marked decrease in their longevity, probably through impairment of the immune system.

## Introduction

The *in vivo* effects of tumor promoters, especially those produced by topical application of a single dose of 12-O-tetradecanoylphorbol-13-acetate (TPA), have been extensively described (1-7). The study of the effects of multiple repetitive applications of TPA on initiated skin, the only schedule of administration resulting in significant tumor production, has been partially studied by a few investigators (8-10). Even less is known about the systemic effects of TPA when animals are subjected to protracted promoter treatments.

In two separate studies we have analyzed the effects of chronic, topical applications of 2  $\mu$ g TPA on the uninitiated skin and other organs of SENCAR mice during 37 to 52 weeks of repetitive twice-weekly treatments.

\*University of Texas System Cancer Center, Science Park-Research Division, Smithville, TX 78957.

<sup>†</sup>Oak Ridge National Laboratory, Biology Division, Oak Ridge, TN.

<sup>‡</sup>Environmental Protection Agency, Research Triangle Park, NC 27709.

<sup>§</sup>Present address: Department of Pathology, Fox Chase Cancer Center, Philadelphia, PA 19111.

## Effects of 74 TPA Applications on Mouse Skin

### Epidermal Hyperplasia

The effects of repetitive treatments of TPA on mouse skin were studied using 3HTdr pulse labeling and morphometric techniques. A sustained marked epidermal hyperplasia (4 to 5 times normal values) (Figs. 1 and 2) was a constant feature during chronic exposure to TPA. Only 5% of the animals developed papillomas (with a maximum of two papillomas/animal), and none developed carcinomas. The percentage of dark cells, the labeling index of the basal layer, and the epidermal thickness during chronic TPA treatment are shown in Figures 1a and 1b. The pattern of the curves is similar; both show an early peak after four treatments, descending slightly thereafter. The epidermal thickness values correlated well with number of nucleated cell layers (data not shown) indicating that the increase seen in the first portion of the curve was not due to edema alone. Although an early peak was not seen, the number of hair follicles per length of epidermal surface increased and also reached equilibrium after the eighth TPA application (Fig. 1c).

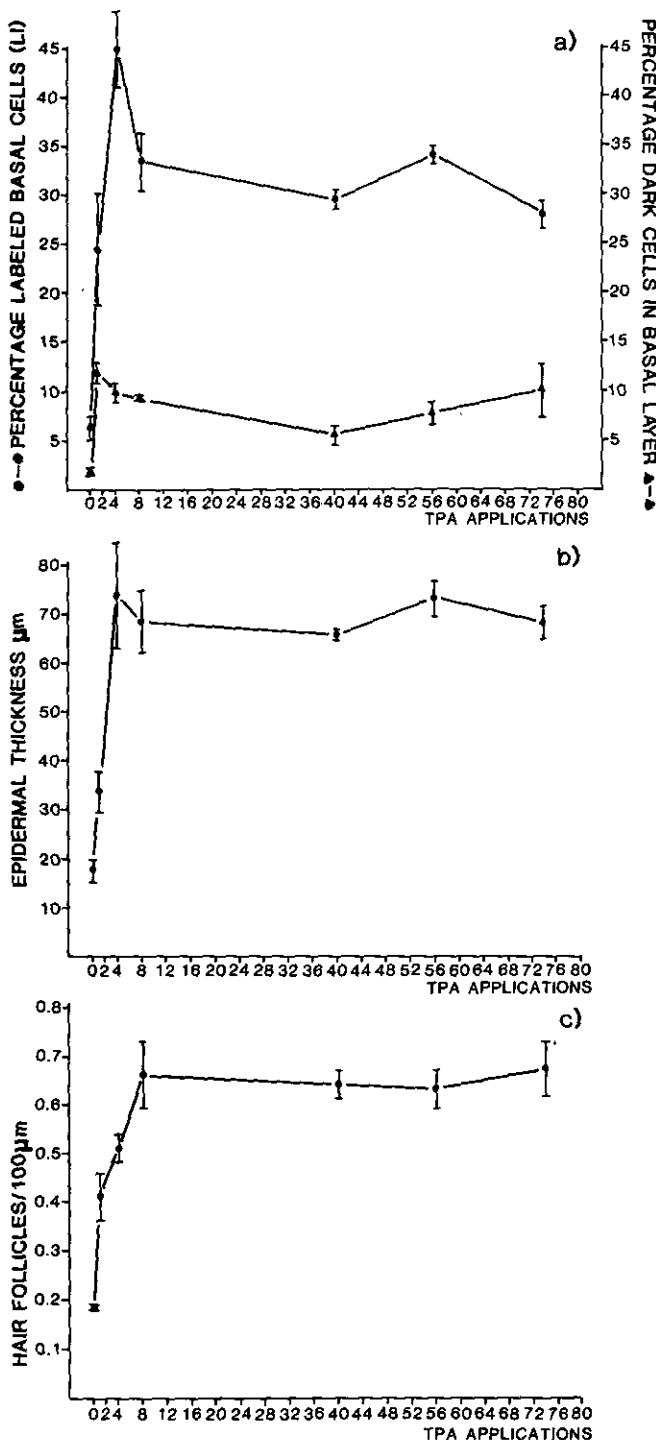


FIGURE 1. Morphometric data of epithelial structures of the skin: (a) percentage of labeled basal cells and percentage of dark basal keratinocytes; (b) epidermal thickness; (c) number of hair follicles. From Aldaz et al. (10) with permission.

## Cellular Changes in the Dermis

The total dermal thickness increased immediately after beginning TPA application. This initial increase of

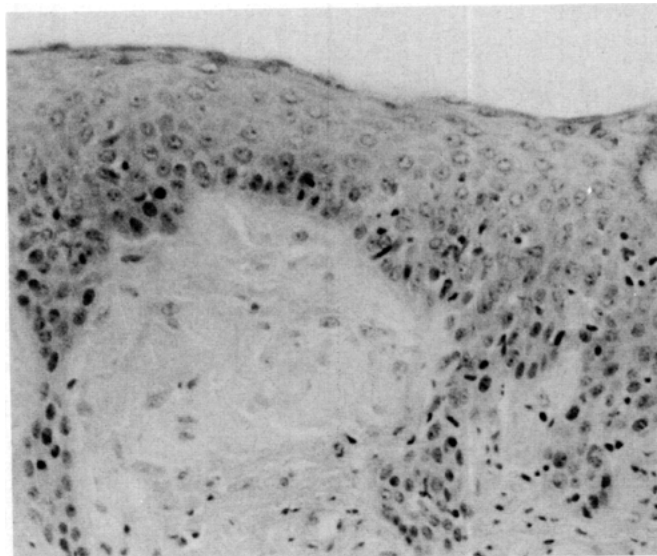


FIGURE 2. Epidermal hyperplasia after 74 applications of 2  $\mu$ g TPA.

approximately 50% was evident after four TPA treatments (Fig. 3a) and was attributed to edema and acute inflammation. Later on, an additional gradual increase was observed. This increase of dermal thickness observed after 40 TPA applications was due to the production of a fibrotic dermis. The total dermal cellularity increased with the number of treatments, reaching a plateau after the eighth application (Fig. 3b). The relative proportion of the different cellular types changed during the course of the treatment. After the first TPA application, the two predominant cellular types were the polymorphonuclear leukocytes and the fibroblasts. The number of polymorphonuclear leukocytes dropped dramatically during the first weeks of treatment. The lymphocytes increased from 2.4% in controls to 15.7% on the eighth application. The macrophages, also involved in the chronic inflammatory reaction, increased slowly during treatment. The number of mast cells was always higher than that in the control tissues (Fig. 3c). During the latter part of the chronic treatment, an increase of fibroblasts and capillary vessels was observed.

## Effects of 104 TPA Applications on Mouse Skin

Figure 4 shows the survival of SENCAR mice treated with 1- and 2- $\mu$ g doses of TPA. After 12 months it became obvious that topical treatment with this tumor promoter, especially with 2- $\mu$ g doses was markedly lethal, approximately equivalent to an LD<sub>50</sub>.

The general characteristics of the cutaneous alterations were the same as those after 80 treatments. However, some additional changes were observed. In some animals, cystic dilatations and atrophic changes were observed in the hair follicles, resulting in a few cases

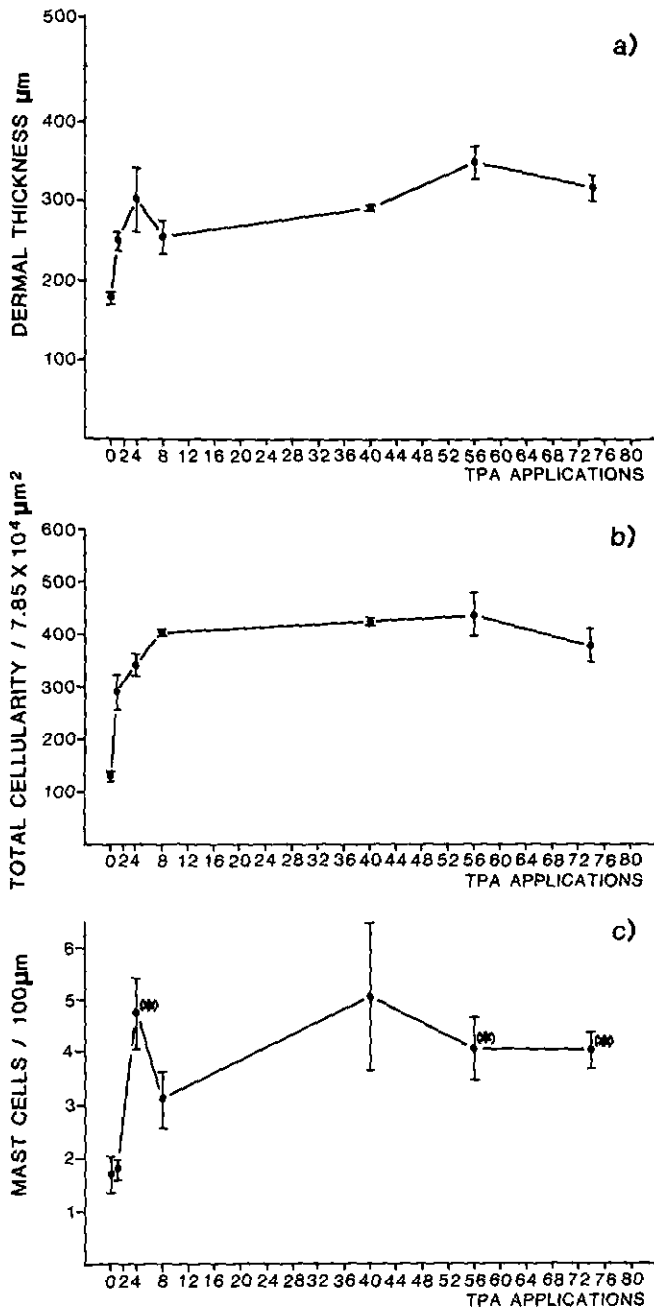


FIGURE 3. Morphometric evaluation of TPA-induced dermal changes: (a) dermal thickness from basement membrane to the subcutaneous adipose tissue; (b) total dermal cellularity per microscopic field; (c) number of mast-cells per length of epidermal surface. From Aldaz et al. (10) with permission.

in the formation of epidermoid cysts of 1- to 10-mm diameter. In addition, and related to the same phenomenon, we could observe the presence of multiple keratinic granulomas in the superficial dermis of six animals (Fig. 5). In seven animals out of 75, marked hyaline and/or amyloid changes of the papillary dermis could be seen. Cutaneous ulcers, sometimes exhibiting exuber-

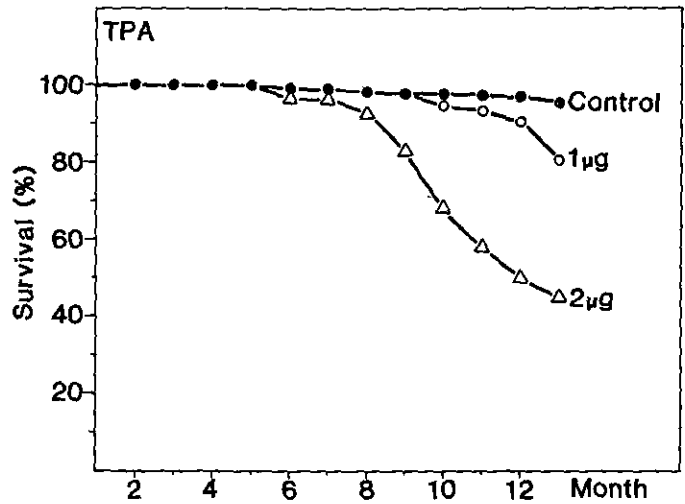


FIGURE 4. Survival curves of SENCAR mice treated topically with TPA.

ant granulation tissue, were also observed. In these cases, as well as in a few others without ulceration, regional lymph nodes showed changes of interfollicular and/or follicular hyperplasia (Table 1).

### Effects of 104 TPA Applications on Other Organs

Table 2 summarizes the general findings after 52 weeks of treatment. Generalized amyloidosis was the most frequently encountered alteration (62% of animals); the liver and spleen were always affected (Fig. 6); kidneys were frequently involved; and adrenals, skin, and intestines contained occasional amyloid deposits. Chronic focal interstitial nephritis was very frequently seen (60%) and in some cases exhibited a clear picture of chronic pyelonephritis. In several cases a nephropathy involving all kidney elements, including glomerular fibrosis and interstitial chronic inflammation, could be seen. Papillary necrosis (Fig. 7) accompanied, very frequently, the most advanced cases of nephritis and/or renal amyloidosis. Systemic lymphadenopathies, mainly of inguinal, axillary, mesenteric, and mediastinal nodes, were observed in many animals. In most cases, the normal lymph node architecture was conserved, and only a reactional (hyperplastic) chronic lymphadenitis could be recognized. However, in several cases, especially in those with cutaneous erosions and/or ulcers, a more dramatic picture with total or partial effacement of the node architecture was observed. These alterations, consistent with the diagnosis of dermatopathic lymphadenopathy, were enlargement of paracortical areas due to the presence of histiocytes and activated lymphocytes.

In 37% of the animals, chronic adenitis with marked proliferation of endothelial cells and capillary vessels, as well as the presence of large, sometimes atypical,

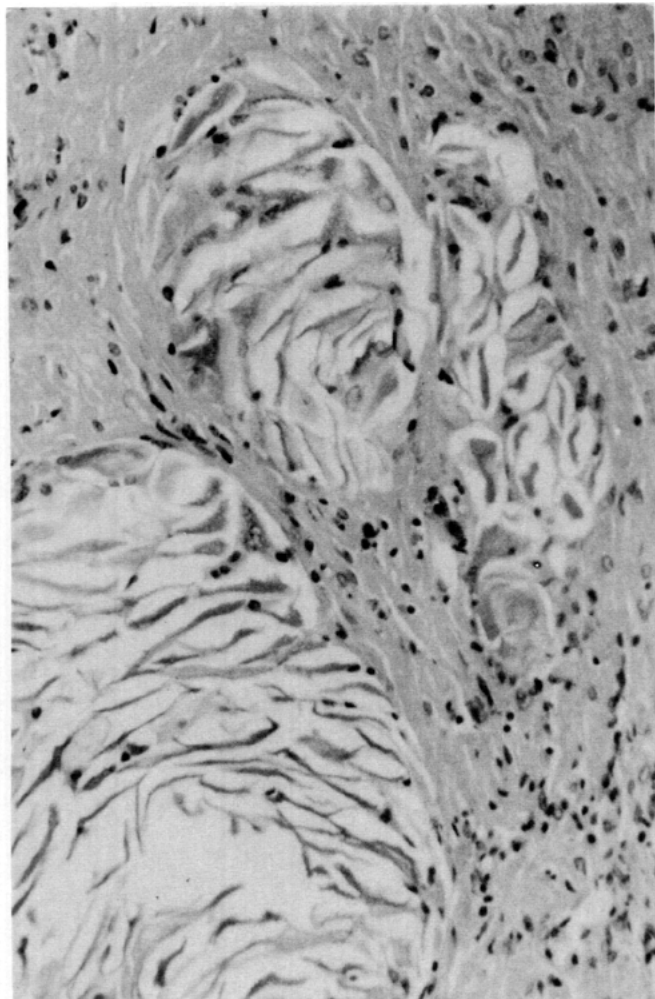


FIGURE 5. Dermal keratinic granuloma with giant cell reaction around horny squames, after 104 applications of 2 µg TPA.

lymphocytes, plasma cells, and immunoblasts, was seen (Fig. 8). This histological picture is similar to that of angioimmunoblastic lymphadenopathy, a human disease characterized by hyperproliferation of B-cells. In two other cases we have seen a similar picture, including cell destruction, presence of polymorphonuclear leukocytes, actively phagocytic macrophages, and mitosis. Frequently these alterations were accompanied by intranodal foci of extramedullary hematopoiesis. Although a few benign tumors and one squamous carci-

Table 1. Percent of animals with skin ulcers and reactive lymphadenopathies.

	Males		Females	
	Died before 1 year	Killed after 104 TPA applications	Died before 1 year	Killed after 104 TPA applications
Lymphadenopathies	45	70	57	71
Skin ulcers	45	18	28	3

Table 2. Pathology of animals killed after 104 TPA application

	Males, %	Females, %
Liver and spleen amyloidosis	63	61
Interstitial nephritis and pyelonephritis	67	54
Papillary necrosis	34	35
Adenopathies (reactive hyperplasia)	40	35
Skin papillomas	4	19
Skin carcinomas	4	0
Lung adenomas	4	4

noma of the skin were seen after 104 TPA applications, this frequency was not significantly different from the spontaneous incidence of malignant skin tumors found in a control group (Table 3). Similarly, no differences were found in the incidence of neoplasias of the lung and hematopoietic organs.

## Discussion

Except for the cases that exhibited ulcers or erosions, repetitive treatment of skin with promoting doses of TPA produces a steady-state epidermal hyperplasia with an increased dermal cellularity. Most dermal cells were fibroblasts and endothelial cells, resulting in a very dense and hypervascularized dermis. It is interesting to note that most authors have focused on the hyperplasiogenic effects of TPA on the epidermis and have overlooked cell proliferation in the dermis. Similarly, with the exception of one group of investigators (9), the effects of promoters on hair follicles were not studied. We were able to confirm, with a different technique, the induction of new hair follicles described in whole-

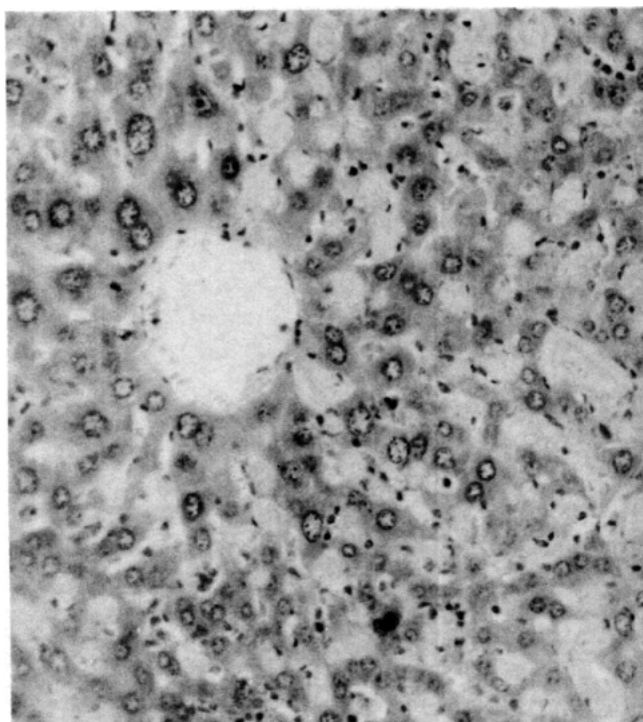


FIGURE 6. Liver amyloidosis after 104 treatments of 2 µg TPA.

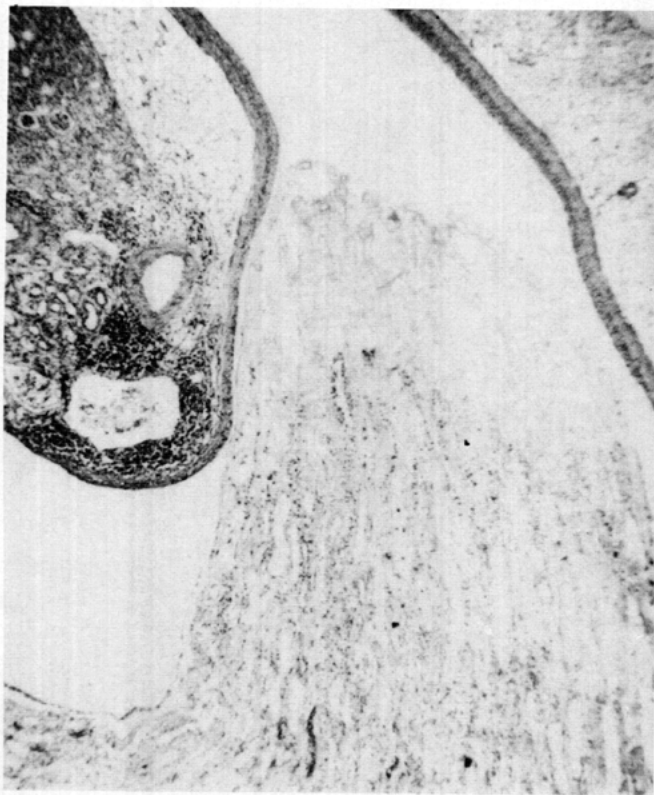


FIGURE 7. Papillary necrosis seen in the kidney with chronic pyelonephritis after 104 TPA applications.

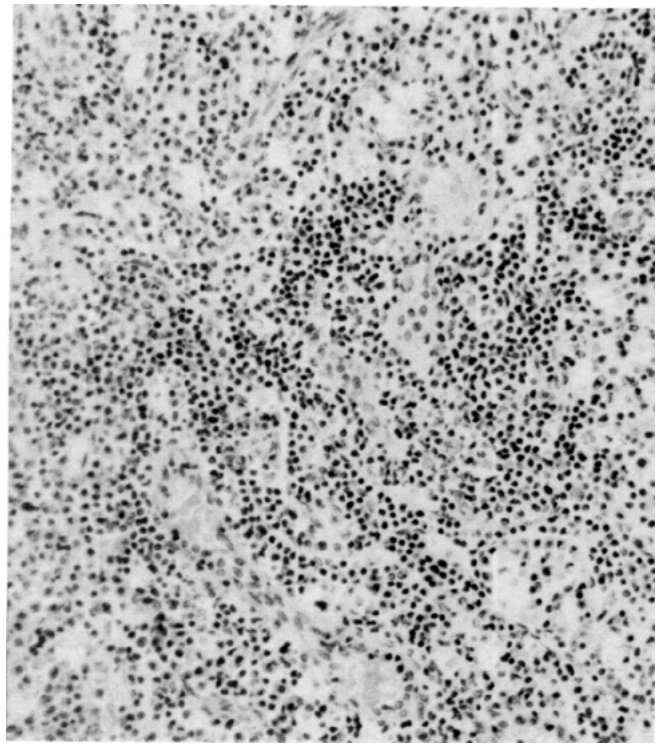


FIGURE 8. Reactive lymphoid tissue hyperplasia with effacement of the normal lymph node architecture after 104 applications of TPA. Note numerous blood vessels.

mounts of TPA-treated skin (9). From these statements, it is easy to conclude that the interfollicular epidermis is not the only target of TPA. The hair follicles, as well as the dermal components, are fully affected by the promoter treatment. Hair follicles have been singled out very frequently as the origin of cutaneous tumors, including papillomas. The effects of the mesenchyme on the differentiation of the epidermis, as well as the possible role of hair follicles, are important facts that should be considered in the pathogenesis of tumors induced by two-stage carcinogenesis in SENCAR mice.

Skin ulcers were seen in many animals after 104 TPA applications and were always accompanied by regional and, sometimes, distant reactive lymph node hyperplasia. This lymph node reaction, although especially evident in these cases, was also seen in most animals without cutaneous ulcers. Table 3 shows that the majority of animals exhibited lymphadenopathies, but only the males exhibited skin ulcers, probably related to biting and fighting. Consequently, it is more than feasible that the reactive lymphadenitis seen in most of these animals is not due to secondary inflammation but is due to the effect of TPA.

The histopathology of lymph node lesions was not uniform. Although all lesions showed components of chronic reactive lymphadenitis, they also included foci of extramedullary myelopoiesis and angioblastic proliferation, as well as the presence of histiocytes and atyp-

ical lymphocytes. Some of these alterations were compatible with lesions observed in human immune system dysfunctions, such as those seen in acquired immunodeficiency syndrome (11), dermatopathic lymphadenopathy (12,13), and angioimmunoblastic lymphadenopathy (14,15). TPA has been shown to modify the response of murine T-lymphocytes and macrophages (16) and to induce the proliferation of the granulocyte macrophage precursor cells (17). Consequently, the lymph node alterations seen in our animals might indicate a direct effect of TPA on lymph node architecture and function that warrants further study.

Another probable evidence of an immunological disturbance is the generalized amyloidosis seen in the liver, spleen, and kidney of most animals and occasionally also observed in the skin, intestines, and other organs. Although the distribution of the amyloid deposits coincides

Table 3. Skin tumors in SENCAR mice.

Treatment	Sex	N	Animals with papillomas	Papillomas per mouse	Animals with carcinosarcomas	Carcinosarcomas per mouse
None	M	127	0	0	4	0.03
	F	220	1	0.004	0	0
104 TPA (2 µg) treatments	M	27	1	0.04	1	0.04
	F	26	5	0.23	0	0

with the secondary (AA) type (18), an accelerated form of systemic senile amyloidosis (AS/SAM) as described by Takeda and colleagues (19) cannot be excluded. This possibility is enhanced by the fact that untreated 18- to 30-month old SENCAR mice are frequently affected by generalized amyloidosis. It is also worthwhile to note that papillary necrosis seen in 35% of TPA-treated animals was described in another mouse strain with renal amyloidosis (20). Interstitial nephritis and chronic pyelonephritis were seen in most animals after prolonged TPA treatment. Whether this effect is primary and directly related to an eventual nephrotoxic property of TPA or secondary, as is more probably the case, remains to be investigated.

Although some authors have described the production of a significant number of skin tumors in mice treated with TPA alone (21,22), we have not been able to find differences between the incidence of carcinomas in untreated and TPA-treated SENCAR mice. Although TPA increased the level of papillomas seen in SENCAR mice, the papilloma yield was 0.23 papillomas per mouse in females and 0.04 papillomas per mouse in males. It has to be pointed out that the tumor yield in initiated animals is much higher, i.e., 7 papillomas/mouse at 15 weeks (23).

This work is supported by the U.S. Environmental Protection Agency contract 79D-X0526, under Interagency Agreement 40-728-78 with the U.S. Department of Energy through the Office of Health and Environmental Research, U.S. Department of Energy, under contract 7405 eng-26 with Union Carbide Corporation. It has been subject to the Agency's review and it has been approved for publication as an EPA document.

## REFERENCES

1. Raick, A. N. Ultrastructural, histological and biochemical alterations produced by 12-O-tetradecanoylphorbol-13-acetate on mouse epidermis and their relevance to skin tumor promotion. *Cancer Res.* 33: 269-286 (1973).
2. Klein-Szanto, A. J. P., Major, S. K., and Slaga, T. J. Induction of dark keratinocytes by 12-O-tetradecanoylphorbol-13-acetate and mezerein as an indicator of tumor promoting efficiency. *Carcinogenesis* 1: 399-406 (1980).
3. Argyris, T. S. Epidermal growth following a single application of 12-O-tetradecanoylphorbol-13-acetate in mice. *Am. J. Pathol.* 98: 639-648 (1980).
4. Argyris, T. S. The nature of the epidermal growth produced by the first application of 12-O-tetradecanoylphorbol-13-acetate on the skin of mice initiated with dimethylbenzanthracene. *J. Invest. Dermatol.* 77: 230-234 (1980).
5. Astrup, E. J., and Iversen, O. H. Cell population kinetics in hairless mouse epidermis following a single topical application of 12-O-tetradecanoylphorbol-13-acetate. *I. Carcinogenesis* 2: 999-1006 (1981).
6. Klein-Szanto, A. J. P., and Slaga, T. J. Numerical variation of dark cells in normal and chemically induced hyperplastic epidermis with age and efficiency of tumor promoter. *Cancer Res.* 41: 4437 (1981).
7. Argyris, T. S. Epidermal growth following a single application of 12-O-tetradecanoylphorbol-13-acetate in mice. *Am. J. Pathol.* 98: 639 (1980).
8. Iversen, O. H., Paulsen, J. E., and Schjolberg, A. The time needed for normalization of hairless mouse epidermis after treatment with twice weekly topical skin application of 10 nmol 12-O-tetradecanoylphorbol-13-acetate in acetone, or acetone alone, for 18 weeks. A morphologic and cell kinetic study. *Carcinogenesis* 2: 1353-1358 (1981).
9. Schweizer, J., and Marks, F. Induction of the formation of new hair follicles in mouse tail epidermis by the tumor promoter 12-O-tetradecanoylphorbol-13-acetate. *Cancer Res.* 37: 4195 (1977).
10. Aldaz, C. M., Conti, C. J., Gimenez, I. B., Slaga, T. J., and Klein-Szanto, A. J. P. Cutaneous changes during prolonged 12-tetradecanoylphorbol-13-acetate application and residual effects after cessation of treatment. *Cancer Res.* 45: 2753 (1985).
11. Ioachim, H. L., Lerner, C. W., and Tapper, M. L. The lymphoid lesions associated with the acquired immunodeficiency syndrome. *Am. J. Surg. Pathol.* 7: 543-553 (1983).
12. Scheffer, E., Meijer, C. J. L. M., and van Vloten, W. A. Dermatopathic lymphadenopathy and lymph node involvement in mycosis fungoides. *Cancer* 45: 137-148 (1980).
13. Burke, J. S., and Colby, T. V. Dermatopathic lymphadenopathy. *Am. J. Surg. Pathol.* 5: 343-352 (1981).
14. Bernengo, M. G., Levi, L., and Zina, G. Skin lesions in angioimmunoblastic lymphadenopathy: histological and immunological studies. *Brit. J. Dermatol.* 104: 131-139 (1981).
15. Seehafer, J. R., Goldberg, N. C., Dicken, C. H., and Su, W. P. D. Cutaneous manifestations of angioimmunoblastic lymphadenopathy. *Arch. Dermatol.* 116: 41-45 (1980).
16. Baxter, C. S., Fish, L. A., Ferguson, T. A., Michael, J. G., and Bash, J. A. Effects of tumor-promoting agents on cells of the murine immune system: Inhibition of antibody synthesis and of macrophage-mediated tumor cell cytotoxicity. *Carcinogenesis* 7: 637-642 (1982).
17. Lawrence, A. T., and Baxter, C. S. *In vivo* and *in vitro* effects of tumor promoters on hematopoietic precursor cell proliferation. *Proc. Am. Assoc. Cancer Res.* 25: 143 (1984).
18. Cohen, A. S., Shirahama, T., Sipe, J. D., and Skinner, M. Amyloid proteins, precursors, mediator, and enhancer. *Lab. Invest.* 48: 1-4 (1983).
19. Higuchi, K., Matsumura, A., Honma, A., Takeshita, S., Hashimoto, K., Hosokawa, M., Yasuhira, K., and Takeda, T. Systemic senile amyloid in senescence-accelerated mice. *Lab. Invest.* 48: 231-240 (1983).
20. Dunn, T. B. *Pathology of Laboratory Rats and Mice*. Blackwell, Oxford, 1967.
21. Chourilinkov, I., and Lazar, P. Action cancerigene et cocancerigene du 12-O-tetradecanoylphorbol-13-acetate sur la peau de souris. *C.R. Acad. Sci. (Paris) D278*: 3027-3030 (1974).
22. Iversen, U. M., and Iversen, O. H. The carcinogenic effect of TPA (12-O-tetradecanoylphorbol-13-acetate) when applied to the skin of hairless mice. *Virch. Arch. B Cell Pathol.* 30: 33-42 (1979).
23. Slaga, T. J., Fischer, S. M., Weeks, C. E. and Klein-Szanto, A. J. P. Cellular and biochemical mechanisms of mouse skin tumor promoters. *Rev. Biochem. Toxicol.* 3: 231-281 (1981).