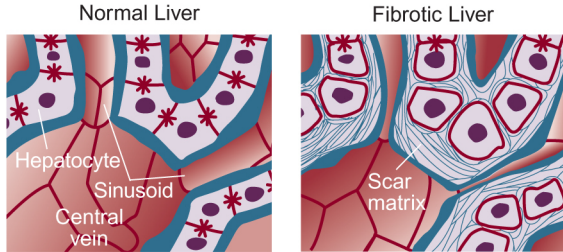


Pericentral fibrosis in alcoholic liver disease



Pericentral fibrosis in alcoholic liver disease. Deposition of scar tissue around the hepatocytes near the central vein constricts blood flow through the sinusoidal channels.

Source: Friedman, S.L. Scarring in alcoholic liver disease: New insights and emerging therapies. *Alcohol Health & Research World* 21(4):310–316, 1997.

Updated: October 2000