

---

**SEER Program**

---

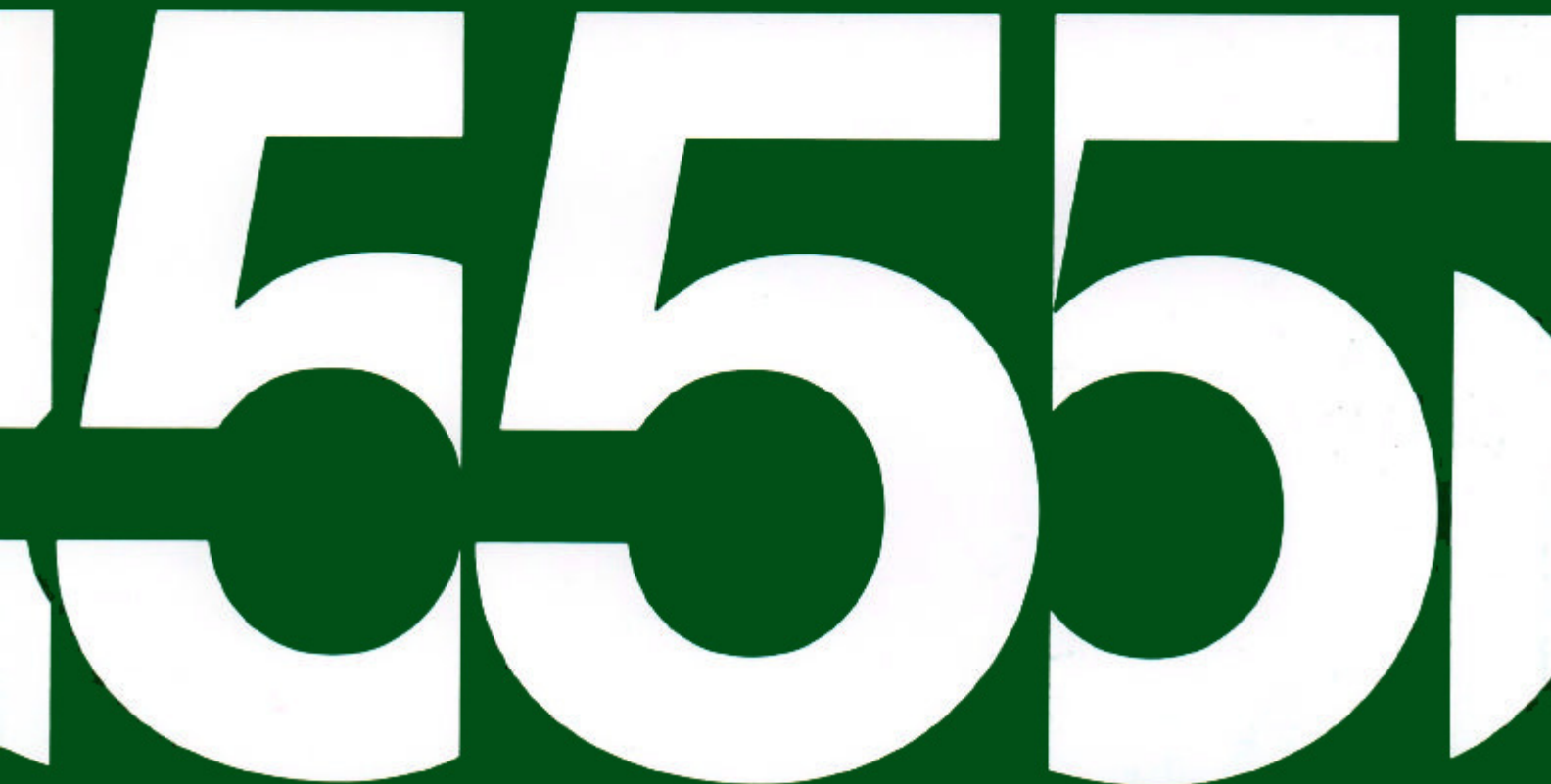**Self Instructional Manual for Cancer Registrars**  
**Abstracting a Medical Record: Patient Identification,  
History and Examinations**

---

**Book Five**

Second Edition

---



NATIONAL INSTITUTES OF HEALTH  
National Cancer Institute

---

# SEER Program

---

## Self Instructional Manual for Cancer Registrars Abstracting a Medical Record: Patient Identification, History and Examinations

---

### Book Five

Second Edition

---

1551

**SELF-INSTRUCTIONAL MANUAL FOR CANCER REGISTRARS**

**Book 5 - Abstracting a Medical Record: Patient Identification, History, and Examinations**

**Originally Prepared for the Louisiana Regional Medical Program Under the Direction of:**

**C. Dennis Fink, Ph.D., Program Director, HumRRO  
Robert F. Ryan, M.D., Technical Advisor, Tulane University**

**Revised by:**

**SEER Program  
Cancer Statistics Branch  
National Cancer Institute**

**Editor in Chief:**

**Evelyn M. Shambaugh, M.A., CTR  
Cancer Statistics Branch  
National Cancer Institute**

**Assisted by Self-Instructional Manual Committee:**

**Dr. Robert F. Ryan, Emeritus Professor of Surgery  
Tulane University School of Medicine  
New Orleans, Louisiana**

**Mildred A. Weiss  
Los Angeles, California**

**Mary A. Kruse  
Bethesda, Maryland**

## TABLE OF CONTENTS

### BOOK 5: ABSTRACTING A MEDICAL RECORD: PATIENT IDENTIFICATION, HISTORY, AND EXAMINATIONS

	Page
Section A--Objectives and Content of Book 5 .....	1
Section B--The Composition and Organization of a Medical Record .....	5
Section C--Abstracting a Medical Record: What, When, and How to Abstract .....	13
Section D--Diagnostic Procedures: General Description .....	23
Section E--Clinical Examinations: Physical, Radiologic, Diagnostic Nuclear Medicine, and Hematologic .....	27
Section F--Manipulative and Operative Procedures .....	121
Section G--Pathological Examinations .....	191
Common Abbreviations .....	255
Common Symbols .....	267
Acronyms of Organizations Concerned with Cancer .....	269
The Automated Cause Coding System .....	272
Acronyms for Study Groups .....	273
Selected Bibliography .....	275
Index .....	277

## ACKNOWLEDGEMENTS

The variety of medical specialties with their ever increasing use of new techniques has made it necessary to seek the advice of specialists in the various areas of medical diagnosis and treatment to ensure adequate and accurate descriptions of these techniques for this Instructional Manual. In every instance the physicians to whom we turned have extended their assistance with the greatest good will. In particular I would like to mention:

Dr. John L. Doppman  
Chief, Department of Radiology  
Clinical Center  
National Institutes of Health

Dr. Harvey R. Gralnick  
Head of Clinical Pathology  
Clinical Center  
National Institutes of Health

Dr. Kenneth R. Hande  
Laboratory of Clinical Pharmacology  
National Cancer Institute

Dr. A. Eric Jones  
Nuclear Medicine  
Clinical Center  
National Institutes of Health

Much effort has gone into making the presentation of the examples interesting as well as realistic. There is a great deal to be learned in this book, and we have tried to make it stimulating and, perhaps, amusing with the play on names.

Evelyn M. Shambaugh  
Editor in Chief

**SECTION A**  
**OBJECTIVES AND CONTENT OF BOOK 5**



**SECTION A**  
**OBJECTIVES AND CONTENT OF BOOK 5**

In this segment of instruction you will begin to learn where to find pertinent information in the medical record and how to record it on your cancer registry abstract. When you finish Book 5, you should have an understanding of the usual methods and procedures used to diagnose cancer as well as an understanding of precisely what should be recorded on your registry abstract.

Section B is concerned with the composition and organization of a medical record.

Sections C, D, E, F, and G are concerned with general to specific instructions for abstracting a medical record. Over 50 sample diagnostic, operative, and pathologic reports are included to teach you how to abstract pertinent information from similar reports in your medical records.





**SECTION B**

**THE COMPOSITION AND ORGANIZATION OF A MEDICAL RECORD**



## SECTION B

### THE COMPOSITION AND ORGANIZATION OF A MEDICAL RECORD

A medical record may be quite simple, containing only a few pages; or it may be extremely complex containing a variety of reports, many of which will be handwritten. It is imperative that you master medical terminology to the best of your ability not only because of the unfamiliar terms you will encounter, but because of the difficulty in deciphering physicians' handwriting. If you know your root words and how to use your medical dictionary, you can generally decipher most medical terms. You may also refer to other portions of the medical record for clues as to what the incomprehensible term might be. Request assistance from your medical consultant if necessary. In any case, familiarize yourself with the diagnostic procedures used in your hospital so that you are aware when information is missing or when a record is incomplete. Medical records have certain characteristics in common. It is these fundamental characteristics which you will study in this block of instruction.

#### COMPOSITION OF A MEDICAL RECORD

The following is a list of specific types of information contained in most medical records. The information will not necessarily appear in this order.

Patient Identification

Referral Information

Biographical Information

Medical History

Chief Complaint (CC) (date of onset and description of symptoms)

Review of Systems (R.O.S.)

Personal Medical History (to include medically-related social history, for example, drinking, drug habits, smoking and exposure to other carcinogens)

Family Medical History (especially history of cancer in the family)

## Physical Examination

- General (general patient description by MD)
- Head
- Eyes
- Ears
- Nose and Sinuses
- Mouth
- Throat
- Neck
- Thorax
- Lymph Nodes
- Cardiovascular System
- Lungs
- Breasts
- Abdomen
- Genitourinary System
- Rectum
- Bones, Joints, and Muscles
- Nervous and Mental State (neurologic condition)
- Extremities

Provisional Diagnosis (admitting diagnosis, first impression)

## Special Examinations

- Radiologic Examinations (diagnostic x-rays)
- EKG (electrocardiogram)
- Diagnostic Imaging Nuclear Examinations (scans)
- Laboratory Reports: Urinalysis, hematologic analysis\* (blood chemistries), other chemistries, serology, and cultures
- Consultation Reports
- Endoscopic Examinations
- Exploratory Surgery

\*Simultaneous Multiple Analysis may be used--This is an automatic analyzer that measures different chemistries. For example, SMA-6 may measure sodium, potassium, chloride, carbon dioxide, BUN, glucose, and creatinine. SMA-12 may measure calcium, alkaline phosphatase, SGOT, bilirubin, phosphate, LDH, uric acid, creatinine, BUN, total protein, albumin, glucose, and cholesterol.

## Pathologist's Reports

### Exfoliative Cytologic Examinations

### Tissue Examinations

Gross (description based on visual examination)

Microscopic (description based on histologic examination)

Pathologic Diagnosis (determining the disease)

Final Diagnosis (made after all routine and special studies have been completed)

## Treatment (therapy) Reports

Medication record (drugs or other medications)

Surgery (report of surgery, operative report)

Radiation therapy

Chemotherapy

Immunotherapy

Physical therapy

## Progress Notes

Doctor's Orders and Notes

Nurses' Notes

## Discharge (Narrative) Summary

## Follow-up Reports

Progress notes added after the patient has been discharged from the hospital:

- (1) Based on patient's return visits to outpatient departments
- (2) Based on replies to correspondence with the patient's physician, other cancer registrars, other medical facilities, with the patient or with the patient's family

## Autopsy Report (gross and microscopic)

All of the major organs and systems are examined unless the autopsy is restricted to certain organs. Any pertinent findings should be recorded on the cancer registry abstract. The information can be of particular value in indicating the primary site of the tumor, which may have been incorrectly diagnosed or unknown prior to autopsy.

Death certificate (when the patient dies in the hospital or when the death certificate is obtained through follow-up activities)

## FORMS USED TO RECORD INFORMATION IN A MEDICAL RECORD

Following is a list of most forms, records, notes, and summary sheets which may be found in your hospital's medical record. Their names are self explanatory. In this book, forms are bordered for easy identification. Some contain little or no information of interest to a cancer registrar. "Starred" (\*) items are most likely to contain relevant information for filling out a cancer registry abstract.

- \* Admission Sheet
- Anesthesia Record
- \* Autopsy (Necropsy; Post Mortem) Report
- \* Chemotherapy Report
- \* Consultation Report (Request for opinions or aid from other physicians or departments)
- \* Cytology (Cytopathology) Report
- \* Death Certificate
- \* Diagnostic Radiology (X-ray) Report
- \* Discharge (Narrative) Summary
- \* Doctor's Order Sheets
- \* Doctor's Progress Notes
- Electrocardiogram (EKG) Report
- \* Electroencephalogram (EEG) Report
- Emergency (Accident) Room Report
- \* Endoscopy Report
- Graphic Reports (Temperature, Pulse, Respiration, Blood Pressure)
- \* Hematology Report
- \* History and Physical Examination
- \* Immunotherapy Report
- Informed Consent to Treatment
- Intake-Output Chart (measured liquids)
- \* Laboratory Reports
- \* Medical Record Data Sheet (Face or Cover Sheet)
- \* Medication Record
- \* Nuclear Medicine Report (Diagnostic Imaging/Scans)
- Nuclear Medicine Report (Radio-Isotope Exposure Record)
- Nurses' Notes
- \* Operation (surgery) Report
- \* Outpatient Clinic Record
- \* Pathology (Histology) Report
- Physical Therapy Report
- \* Protocol Study Report
- \* Radiation Therapy Summary
- Recovery (Post-Anesthesia) Room Report
- \* Referral Letters (From local medical doctors or other institutions)
- Request to Blood Bank Report
- Serology Report
- \* Tumor Board Summary

## ORGANIZATION OF A MEDICAL RECORD

Each hospital has its own procedures for organizing a medical record. Most of the time this will be done by the medical record department. Usually, the record will be organized in terms of the temporal sequence of events with the latest admission located at the front of the medical record. After the patient is discharged from the hospital, a summary of the patient's diagnosis and treatment may be prepared by the attending physician and inserted at the front of the medical record. This can be used as a guide to ensure that you have not overlooked any reports. However, you should abstract directly from the actual reports in the patient's record, *not* from the discharge summary. The discharge summary is an overview of the patient's hospitalization from the point of view of the attending physician. It is usually dictated after the patient is discharged from the hospital, possibly from inadequate notes or an incomplete medical record.

In some hospitals a copy of the cancer registry abstract is kept in the patient's medical record. It acts as a handy summary of the patient's history, diagnosis, and treatment. Not only is this a useful service to physicians, but it makes them aware of the registry as a source of cancer data available in their own hospital.





**SECTION C**

**ABSTRACTING A MEDICAL RECORD: WHAT, WHEN, AND HOW TO ABSTRACT**



## SECTION C

### ABSTRACTING THE MEDICAL RECORD: WHAT, WHEN, AND HOW TO ABSTRACT

#### WHAT CASES TO ABSTRACT

A separate abstract is generally prepared for each independent cancer. Specific rules may modify that general rule for selected sites. For example, in the SEER Program *multiple neoplasms* of the urinary bladder are represented by a single summary abstract since multiple tumors so frequently occur in this site. Skin cancers are also handled in this manner. However, for most multiple primary tumors, each *unrelated* malignancy is abstracted on a separate form. The registry number for patients with multiple primary tumors usually remains the same; a higher sequence number is assigned for each new primary cancer. Sequence number indicates the order in which a primary tumor is discovered in relation to the total number of primaries for a given patient. For example, the sequence number for the first of two primaries is 1; the sequence number for the second of two primaries is 2. Each primary is recorded on a separate abstract.

Hospitals with cancer programs approved by the Commission on Cancer of the American College of Surgeons are required to register all carcinomas, sarcomas, melanomas, leukemias, and lymphomas, all malignancies with a behavior code of 2 or higher in the *International Classification of Diseases for Oncology, Second Edition, (ICD-O-2)*.

#### Inconclusive diagnosis

When the diagnosis is vague or inconclusive, such as probable carcinoma of the lung, the following terms indicate involvement:

compatible with suspicious	suspect probable	consistent with most likely
-------------------------------	---------------------	--------------------------------

The following terms are *not* to be interpreted as involvement:

equivocal worrisome	suggests questionable	possible
------------------------	--------------------------	----------

For example, a diagnosis of probable carcinoma of the left lung would be abstracted as a lung primary. A diagnosis of questionable carcinoma of the left lung with brain metastasis would be abstracted as an unknown primary. A possible carcinoma is not reportable.

#### Changing the diagnosis

Over time, information may be added to the patient's medical chart that was missing in the original record. Therefore, it is the practice to accept the thinking and information about the case based on the latest or most complete information. Thus, it is acceptable to change the primary site, histology, and extent of disease as information becomes more complete.

Benign tumors and borderline malignancies (behavior codes 0 and 1) also may be listed in the registry. These diagnoses are referred to as "reportable-by-agreement" cases.

## WHEN TO ABSTRACT CASES

While it may seem highly desirable to abstract the patient's medical record immediately upon discharge from the hospital, this is usually impractical. There is always the inevitable delay in incorporating into the medical record the various diagnostic and treatment reports which you need for abstracting. Treatment may be continued over a period of weeks or months; and it may well cover more than one admission to your hospital or more than one visit to the outpatient department. Therapy which should be incorporated into your registry record may even be administered at another institution, on an out-patient basis, or in the physician's office. The abstract cannot be completed until the first course of therapy has been given and all the pertinent reports are filed in the medical record.

Some tumor registries may elect to initiate the abstracting process before the completion of the first course of therapy. If this is done, it then becomes necessary to review the patient's medical record again at a later date in order to complete the abstract.

With experience, you will learn that there are certain diagnoses for which you will not anticipate further treatment, and these cases may be abstracted as soon as the medical record is complete. Patients who die will, of course, fall into this category. You may find it necessary, however, to wait for the autopsy report to verify the diagnosis.

## HOW TO ABSTRACT CANCER REGISTRY INFORMATION

Certain information is basic to any abstract, such as the medical record number, diagnosis, date of diagnosis, age, sex, race, treatment, date of last follow-up, and status of the patient at last follow-up. For a detailed list of information requirements for a cancer registry see the Data Acquisition Manual of the Commission on Cancer, American College of Surgeons. Other information is optional depending upon the scope of your registry. The detailed description that follows is designed to fit the needs of all users--hospitals, clinics, and central registry systems.

### *Patient Identification*

#### *Name*

Use full name of patient whenever possible. If middle and maiden names are given, record both. Very often the middle (or maiden) name will be given only as an initial and should be so recorded. However, every effort should be made to avoid the use of initials for first names.

For married women, the first name of the husband should not be used; record the name of married female patients, for example, as Jones, Paula Ann, *not* Jones, Mrs. John T. The husband's name will be recorded under the heading "Spouse."

In recording the name of Catholic clergy, it is preferable to use family names, if known. Use the title (Sister, Brother, Father, Mother) as a family name only until the true family name is known. A cross reference will probably be necessary to facilitate this matching of names and avoid duplication.

For male patients who are Sr., Jr., III, etc., so indicate following the last name. Also, if it is known that the patient has a graduate professional degree (M.D., D.D.S., D.D.), indicate--for example, Smith, III, M.D., Robert Quintin.

#### *Hospital Medical Record Number*

Record the number assigned to the patient by the hospital admitting office. If the hospital has a unit numbering system, all patient records will carry this identifying number. If the hospital has a serial numbering system, a new number is assigned on each admission to the hospital. In this case each registry must work out a system which will best serve as a cross reference to the hospital medical record, for example, an alphabetic card index file. This file can then be checked against the medical record department's alphabetic file to determine the patient's latest admission. You may decide to retain as your registry number, the number assigned the patient by the hospital at the time the neoplasm was first diagnosed. If the hospital has a serial unit system, each admission is given a unique number, such as an accounting number, but the patient's record is filed under a unit number in medical records.

### *Local Registry Number*

A patient's registry number should remain the same regardless of the number of admissions or primary sites. This method is recommended by the American College of Surgeons.

### *Address and Phone Number*

Record the number, street, city, state, and zip code of patient's usual residence. Record phone number, if known.

### *Social Security Number*

Record the patient's Social Security number. In Veterans Administration hospitals and military hospitals, the Social Security number, or a portion of it (last 4 or 6 digits, or first 4 or 6 digits), of the sponsor is the hospital medical record number. For Medicare patients, the Social Security claim number may be that of the primary beneficiary, for example, the number of the husband, not that of the patient.

### *Spouse*

Record the complete name of the husband or wife. For single adults and children, record as "not applicable" (N/A).

### *Nearest Relative or Friend*

Record the name, relationship, address, and telephone number of a person who may help in obtaining follow-up information about the patient.

### *Physicians*

A. *Family*: Name, address, and telephone number of any family physician.

B. *Referral*: Name, address, and telephone number of any referring physician.

C. *Hospital Staff*: Name, department, and the telephone number of the physician who attended the patient. In hospitals where patients are not under the care of a particular physician, record the name of the physician in charge of the *department*.

### *Employer*

Record name, address, department, immediate supervisor, and telephone number. Other applicable entries are: self-employed, not employed, unknown.

## *Biographical Information*

### *Sex*

Record male, female, or unknown. In very rare instances, the sex cannot be determined or there will be a sex change. This information should be recorded.

### *Age at Diagnosis*

This refers to years of age at time of initial diagnosis for the reported cancer. Record age at last birthday; do not round to the next birthday.

### *Birthdate*

Record month, day, and year of patient's birth. If any of this information is unknown, record as Unk--for instance, June, Unk, 1925.

### *Place of Birth*

Record town and state for patients born in the U.S. For foreign born, record country. Some registries and registry systems have developed a code to record city, state, and country. If your registry employs such a code system, record the code as determined from your geographic location code. The SEER Program has developed a system called Geocoding which now appears in both the Data Acquisition Manual of the American College of Surgeons and the SEER Program Code Manual.

### *Race/Ethnic Group*

There may be some problems in classifying individuals of mixed heritage--for instance, a person with a Japanese mother and a black father. Record all the details. Abbreviations on medical records can be misleading. Black is often specified as "B," "C," or "NW"--black, colored, or non-white. However, "C" may also be used to specify Caucasian or Chinese; and Japanese patients may also be classified as "NW." Hence, when abstracting hospital records which utilize abbreviations, be sure you know exactly what the abbreviations mean. It will be of use to note a general rule in trying to distinguish between Chinese and Japanese names: usually, Chinese names have only one syllable and Japanese names have two or more syllables. Latin American and Puerto Rican are designations for ethnic groups, not races. In some sections of the country ethnic groups may be of particular interest to your registry, and you may wish to identify them--for example, Spanish surname or origin, such as Mexican, Puerto Rican, or Cuban.



### *Marital Status*

Select appropriate alternative: single, married, divorced, separated, widowed. Do not assume that a person specified as Miss should be classified as single. Often women who have been separated or divorced use their maiden names. A patient whose only marriage has been annulled should be classified as single. Patients having "common law" marriages should be classified as married. There may be some instances in which this information is unknown, particularly with the more frequent use of "Ms."

### *Occupational History*

Record the patient's usual or major occupation and the industry in which the patient is currently or was previously employed. Also, note a secondary occupation if one is listed in the medical record. This is particularly important for determining possible carcinogenic exposure, for example, people working with asbestos or in the manufacture of polyvinyl chloride.

### *Social History*

Record information on use of or contact with carcinogenic agents, such as history of smoking, drug habits, drinking, and use of birth control pills, or any other information which your Committee on Cancer requests.

### *Medical History*

#### *A. Previous Diagnosis of This Neoplasm*

If the reported neoplasm was first diagnosed (whether clinically or histologically) in a physician's office or at another institution, record the name of the referring physician, the name of the hospital where the diagnosis was made, the date of diagnosis, and the diagnosis (site and type).

#### *B. Previous Treatment for This Neoplasm*

Indicate whether or not treatment was given for this neoplasm before entry to your institution.

Record the date and describe briefly the nature of the treatment. This information may be contained in the referral letter or in the history section of the medical record. Copies of the diagnostic and treatment reports from the other institutions will frequently be appended to your hospital record.

When information concerning previous treatment is missing from the medical record, the registry or registry system should make every effort to contact institutions or physicians who have examined or treated the patient to obtain such information.

### C. *Other Previous Neoplasms*

Some registries prepare separate abstracts for each previously diagnosed primary mentioned in the patient's history. Other registries may elect only to record the fact that the patient has a history of one or more primary cancers if there is no evidence of these earlier cancers at time of admission. Your Cancer Committee will decide how your registry will handle previous neoplasms. Whether entered on a separate abstract or on the abstract of the neoplasm for which the patient is admitted, the date, site, type, and treatment of the earlier diagnosis should be recorded in a uniform manner.

#### *Admission Date*

Record the date the patient was first admitted to your hospital for diagnosis and/or treatment of his or her malignancy. The patient may be readmitted many times for the same primary. Record only the date of the *first* admission. Sometimes the patient may be seen and treated only in an outpatient clinic or in the radiology department. For such cases, record the date the patient first appeared at the outpatient clinic or radiology department for diagnosis and/or treatment of this malignancy.

#### *Diagnosis Date*

Record the *first* diagnosis of this cancer by a recognized medical practitioner. This may be a clinical diagnosis and may not ever be confirmed histologically. When the biopsy is histologically confirmed, the date of diagnosis is the date of the *first clinical diagnosis* and not the date of confirmation.

#### *Discharge Date*

Record the date patient was discharged from the hospital following first admission for this malignancy. For patients seen only as outpatients, leave blank.

### *Abstracting Diagnostic Procedures*

Sections D-G of this manual will begin to teach you how to abstract from copies of actual reports. Fictitious names, dates, and identifying numbers are used.

Always record certain basic information:

1. The date of the examination or procedure
2. The name of the examination or procedure
3. The results of the examination or procedure--any pertinent positive or negative information
4. The diagnostic impression, if one is given.

As you abstract each sample report, compare your results with the suggested abstraction following each example. In this manner you will learn how to recognize pertinent information and how to abstract it. Some reports will state the presence or absence of cancer as a "diagnosis." Other reports will contain a statement of the "impression." Do not attempt to distinguish between the two. Simply use whatever term appears on the report.

**SECTION D**  
**DIAGNOSTIC PROCEDURES: GENERAL DESCRIPTION**



## SECTION D

### DIAGNOSTIC PROCEDURES: GENERAL DESCRIPTION

The cancer registrar must be able to understand the events leading to the diagnosis of a malignancy. In this book you will learn to locate and summarize statements of *diagnostic* procedures and findings. The real-life examples you will be working with in this section were chosen to illustrate typical reports, not ideal reports. To facilitate learning, the reports are typed instead of handwritten as in many medical records.

The medical record begins with the patient's chief complaint (CC), medical history (Hx), and physical examination (PE). In practically all instances the physical examination findings will be followed by a tentative diagnosis or impression. Sometimes the patient will have been diagnosed prior to admission to your hospital. Be sure to look for a letter of referral from an outside source. However, for many patients, the presence of a possible malignancy will be first detected on the initial physical examination in the hospital.

The examining physician will then order a series of diagnostic tests to confirm his clinical impression and to describe more precisely the nature of the disease. Prior to or upon admission to a hospital, patients are automatically given routine examinations of their blood and urine. The findings of these examinations will be noted on one or more laboratory reports. Following this, certain diagnostic examinations may be made for the purpose of specifically identifying the presence or absence of cancer. Depending upon the suspected site of the cancer, the findings will appear on pathology, cytology, x-ray, scan, endoscopic, operative, hematology or other laboratory reports. All reports will be filed in the patient's medical record. You will quickly learn to recognize the relevant reports and how to abstract the diagnostic findings.

For the majority of cancer patients, standard procedures are employed to establish a diagnosis. The most positive way to identify cancer is by the microscopic examination of tissues and cells from the suspected tumor. For internal tumors where it may be difficult to obtain tissues and cells for examination, other diagnostic procedures may be used. Improved diagnostic techniques are constantly being developed while old ones are falling into disuse. As a cancer registrar you will be continually learning about new techniques.

Each diagnostic procedure will be described in detail in a separate report filed in the patient's medical record. Each report will include a description of the technique used together with a statement of the findings. These reports of diagnostic procedures will provide detailed information which you as a cancer registrar will summarize on the abstract. In a later lesson, you will learn that the information contained in diagnostic reports is crucial to the determination of the extent of disease in addition to establishing the diagnosis of cancer.

You will find reports for conditions other than cancer in medical records. These reports should *not* be summarized unless specifically requested by your cancer committee. For example, you may be asked to record specific premalignant conditions or particular symptoms.

**SECTION E**

**CLINICAL EXAMINATIONS: PHYSICAL, RADIOLOGIC, DIAGNOSTIC NUCLEAR  
MEDICINE, OTHER IMAGING, AND HEMATOLOGIC**





## SECTION E

### CLINICAL EXAMINATIONS: PHYSICAL, RADIOLOGIC, DIAGNOSTIC NUCLEAR MEDICINE, OTHER IMAGING, AND HEMATOLOGIC

#### PHYSICAL EXAMINATION

As part of the physical examination, the examining physician will systematically record his findings relative to the various body regions--head and neck, thorax, abdomen, lymph nodes, and extremities. He will closely observe all external surfaces and palpate various portions of the body. The act of palpation involves the application of fingers with light pressure to the body for the purpose of determining the consistency of the parts beneath the surface. For example, some enlarged organs of the body and some lymph nodes can be palpated. Cancer of the skin is quite readily detected by observation and palpation.

One of the most important diagnostic statements is located at the end of the physical examination. This statement records the diagnostic impression(s) of the examining physician.

#### RADIOLOGIC EXAMINATION--PLAIN FILMS

There are a number of indirect diagnostic approaches which can be used to detect cancer. The most common of these methods is known as radiology or roentgenography. Radiology refers to photography by means of roentgen<sup>1</sup> rays, which are electromagnetic radiation of extremely short wave length with great penetrating powers in matter opaque to light. X-rays are produced when high energy beams of electrons strike matter. An x-ray photograph is a negative (like a camera film) rather than a positive (like a print).

Words ending in "-graphy" refer to the act of recording studies of various parts of the body. Words ending in "-gram" refer to the resulting record while "-graph" refers to either the instrument for recording or the resulting record.

**KUB (KIDNEYS, URETER, BLADDER):** A frontal film of the abdomen taken in the supine position (a plain film).

On the following page is an example of a routine chest x-ray (Example E1). Abstract what you think is pertinent using page 22 as a guide, and then compare with the suggested abstraction on page 33.

---

<sup>1</sup>roentgen--The international unit of x- or gamma-radiation, abbreviated r or R; named after the German physicist, Wilhelm K. Roentgen, who discovered roentgen rays in 1895.



EXAMPLE E1

Name: Sarah O. Luckless

Hospital No.: 000001

Age: 68

Sex: Female

Race: White

EXAMINATION DESIRED: Chest Film

REASON FOR EXAM: Chronic respiratory problems

REPORT:

CHEST, PA AND LATERAL, 10/8/91: An approximately 2 to 3 cm irregular poorly marginated mass is located in left midlung laterally. A few strands are seen extending from it toward the left hilum. The patient is noted to have low diaphragm, and an increased AP diameter. This is suggestive of chronic obstructive pulmonary disease. The lungs are clear of any infiltrate and any other definite mass lesions. The heart is not enlarged.

IMPRESSION:

1. 2 to 3 cm irregular, poorly marginated mass, left midlung laterally, probably adenocarcinoma. There are some dense streaky strands extending from this mass toward the left hilum.
2. Chronic lung disease.

RECOMMENDATION: Tomogram might be helpful

Date: 10/8/91

Exam: CHEST

Radiologist: I. C. Pic, MD

X-RAY REPORT



Example E1 can be abstracted as follows:

10/8/91. CXR: 2 to 3 cm mass in left midlung extending toward the left hilum.  
IMP: Probably adenocarcinoma.

#### X-RAY SERIES:

Quite often an x-ray examination will require the taking of a number of pictures. This is referred to as an x-ray series and is summarized in one report. For example, a metastatic series involves x-raying various parts of the body to determine whether or not a cancer has metastasized to any of those parts. The following illustration (Example E2) is a typical x-ray report of a metastatic series. Abstract what you think is pertinent in the report and then compare it with the suggested abstraction on page 37.



EXAMPLE E2

Name: Hector Breathless

Hospital No.: 000002

Age: 55

Sex: Male

Race: White

EXAMINATION DESIRED: Metastatic series

REASON FOR EXAM: Carcinoma of lung

REPORT:

Calcified opacity is noted in the left femoral head and left ilium; also in the skull; these are probably osteoblastic metastatic lesions.

Date: 4/19/91 Exam: Metastatic series

Radiologist: U. C. Picks, MD

X-RAY REPORT





Example E2 can be abstracted as follows:

4/19/91. Met. series:

Left femoral head, left ilium, and skull show probable osteoblastic metastatic lesions.

**Comments:** The following points should be noted with respect to the preceding abstract.

- a. The date is recorded.
- b. The type of x-ray procedure is recorded--metastatic series.
- c. The pertinent findings are described.



## **BODY SECTION RADIOGRAPHY.**

Body section radiography involves taking radiographs of layers of the body, that is, a series of x-rays taken at different depths in order to define images of desired areas. The desired image is brought sharply into focus while blurring out the other areas. These types of radiograms are used to locate lesions accurately in places like the lungs and bones. They are referred to as tomograms, laminograms, and planograms.

**TOMOGRAPHY:** A special x-ray technique to show in detail images of structures lying in a predetermined plane of tissue while blurring or eliminating detail in images of structures in other planes (Same as Laminography).

**LAMINOGRAPHY:** X-ray of a selected layer of the body made by laminography (Picker Ultrasonic Laminograph) (See Tomography).

In the early 1970's, computerized tomography (CT) was introduced into clinical medicine and revolutionized the field of diagnostic imaging.

## **DIGITAL RADIOGRAPHY:**

A system which uses computers to convert the lighter and darker areas of the radiographic image into numbers and then translates these numbers into an image on a cathode ray (television) tube.

## RADIOLOGIC EXAMINATIONS USING CONTRAST MEDIA

Certain materials or gases can be injected into veins, arteries, lymphatics, or hollow cavities to obtain contrast with the surrounding tissues. A contrast medium is a radiopaque substance which obstructs the passage of x-rays so that the structures containing it appear white on the x-ray film thus delineating abnormal pouches or growths and defining the contour of body structures on x-ray. Examples of radiopaque materials are Hypaque and Renografin, dyes used in intravenous pyelogram, and barium, the substance used in a gastrointestinal series. Some of the more common radiographic examinations which use contrast media are:

### A. Angiography: The radiographic study of the vascular system

1. Cerebral angiogram: X-ray of the vessels of the brain
2. Cardiac angiogram: X-ray showing the functions of the heart and large blood vessels
3. Lymphangiogram: X-ray study of the vessels of the lymphatic system
4. Arteriography: X-ray examination of arteries
5. Venography: X-ray examination of veins

### B. Urography: Radiologic study of the urinary tract

1. Urogram (Pyelogram): X-ray of the kidney and ureter with emphasis on the pelvis of the kidney by intravenous injection of a contrast medium
2. Cystogram: X-ray of the urinary bladder by intravenous injection of a contrast medium
3. IVP (Intravenous Pyelography): A succession of x-ray films of the urinary tract following the injection into a vein of an iodine-containing substance which is collected by the kidneys, passing into the ureters and subsequently the bladder, allowing the study of urinary tract function (also known as Intravenous Urography, IVU).
4. Retrograde Urography: (Retrograde Pyelography): Examination of the ureter and renal collecting structures by means of instillation of contrast material through a ureteral catheter passed through a cystoscope into the bladder and ureter.

### C. Bronchography: The radiographic study of the bronchi of the lung

Bronchogram: An x-ray of the bronchial system

### D. Upper GI Series or Barium Swallow: X-ray studies, following ingestion of barium, of the pharynx, esophagus, stomach, duodenum, and small intestine

- E. Lower GI Series or Barium Enema: X-ray studies, following rectal injection of barium, of the large bowel
- F. Cholecystography: Radiologic study of the function of the gallbladder and bile ducts after an opaque medium has been introduced either orally or intravenously
1. Cholangiogram: X-ray of the extrahepatic bile ducts
  2. Cholecystogram: X-ray of the gallbladder
- G. Infusion Nephrotomography: Radiologic visualization of the kidney by tomography after intravenous introduction of contrast medium
- H. Myelography: Radiologic study of the spinal cord
- I. Salpingography: Radiologic study of the uterus and fallopian tubes
- J. Sialography: Radiologic study of the salivary ducts
- K. Pneumocolon: X-ray examination of the colon in which air and barium are used as contrast materials; also known as double contrast enema and air contrast enema.

#### FLUOROSCOPY:

Fluoroscopy is a technique for continuous or intermittent x-ray monitoring. X-ray images may be viewed directly without taking and developing x-ray photographs. This allows observation of certain dynamic body processes and is useful in certain surgical and diagnostic procedures. The radiologist moves the screen up and down the patient's body and observes what is happening within selected parts of the body. Fluoroscopy is especially useful for identifying the presence of restricted or blocked passages in the hollow organs of the body. For example, barium is swallowed and followed through the esophagus, stomach, and the upper intestinal tract. The results of a fluoroscopic examination of the esophagus are reported in the x-ray report on the next page (Example E3). Other examples of fluoroscopic examinations include upper and lower gastrointestinal series, oral cholecystograms, cystourethrograms, fistulograms, and retrograde ileograms. Abstract what you think is pertinent in Example E3 and then compare with the suggested abstraction on page 45.

Renal Flow Study: A fluoroscopic examination to check the flow of blood through the kidneys after contrast material has been injected into the veins

Intraoperative Imaging: An imaging procedure such as X-ray, CT scan, ultrasound, or mammogram that is performed during an operative procedure, e.g., to direct a biopsy or to verify the position of a prosthesis.



EXAMPLE E3

Name: Mr. Noah Reprieve

Hospital No.: 000003

Age: 56

Sex: Male

Race: White

7-14-91 EXAMINATION DESIRED: Esophagram

REASON FOR EXAM: Carcinoma of esophagus

REPORT:

ESOPHAGRAM:

The swallowing mechanism was observed at fluoroscopy, and spot films were obtained. Overhead views were then done in AP, lateral and oblique positions while the patient was swallowing barium. There was an irregularly narrowed area in the midportion of the esophagus at the approximate level of the aortic knob. This has tapering margins and measures approximately 5.5 cm in length. It is consistent with the clinical information of carcinoma of the esophagus. There is no obstruction at this time, and the lumen measures 1.3 cm in its most narrow region.

Radiologist: Helen D'Agnosis, MD

X-RAY REPORT





Example E3 can be abstracted as follows:

7/14/91. Esophagram: Irregular narrowed area 5.5 cm in length in midportion of esophagus at level of aortic knob. No obstruction.

IMP: Carcinoma of the esophagus.

**Comment:** AP means anterior posterior (front to back).

#### ULTRASONOGRAPHY:

Diagnostic ultrasound is a technique for visualizing internal structures of the body by recording the reflection of ultrasonic waves (high frequency sound waves) as they interact with the various tissues of the body. Different densities in tissues cause different sound waves or echoes. The record produced may be called an ultrasonogram, a sonogram, or an echogram. Differences can be detected between normal tissues, benign tumors, and malignant neoplasms. An example of an ultrasound report follows on the next page (Example E4). Abstract what you think is pertinent and then compare with the suggested abstraction on page 49.



EXAMPLE E4

Name: Sonya Heare

Hospital No.: 000004

Age: 56

Sex: Female

Race: White

12/31/91 EXAMINATION DESIRED: Ultrasound of abdomen

REASON FOR EXAM: Retroperitoneal mass

REPORT:

ULTRASOUND OF ABDOMEN:

Examination of the left kidney was performed in both supine and prone positions. There is evidence of a mass lesion in the superior pole causing a bulbous superior pole of the kidney which is fairly homogeneous in consistency but is not cystic. The mass is mainly in the superior pole but also seems to be somewhat more posteriorly placed, displacing the normal midportion of the kidney slightly anteriorly.

An examination of the right kidney is within normal limits.

IMPRESSION: Mass lesion, superior portion and posterior portion of the left kidney, not cystic.

Radiologist: B. Echo, MD

DEPARTMENT OF DIAGNOSTIC RADIOLOGY



Example E4 can be abstracted as follows:

12/31/91 Ultrasound: Mass lesion, superior and posterior portion of left kidney, not cystic. Right kidney WNL.

**Comment:** WNL means within normal limits.

#### MAMMOGRAPHY:

Mammography is a technique for the detection of breast cancer. In this procedure, several x-ray views are taken of one or both breasts and the radiographs are examined for the presence of a lesion. When a lesion is detected, the radiologist often can determine quite accurately whether it is malignant or benign. Mammography is important because very small, early cancers can be diagnosed with this technique before they are large enough to palpate. Mammograms of the opposite breast should be recorded as well as those of the involved breast. The findings of a mammographic examination will be reported on an x-ray report such as Example E5 shown on the next page. Abstract what you think is pertinent and then compare with the suggested abstraction on page 53.

#### XERORADIOGRAPHY:

Xeroradiography, a product of Xerox Corporation, has been known since 1950. The xerographic process is another way of doing mammographic examinations. Its merit is in its greater precision in outlining boundaries of masses and detecting fine calcification often seen in occult neoplasms.

In xeroradiography, the x-rays are developed using the same image-producing process as the Xerox office copier machines. The xeroradiography machine can produce either a positive or negative picture on specially coated white paper that can be read in any light.

Today, xeroradiography is used for x-rays of the skull, limbs (feet, arms, legs), and breast as well as for cervical spinal examination. Also, it can be used for locating foreign objects (wood, glass or metal splinters) in the eye or other parts of the body.



EXAMPLE E5

Name: Mary Secondchance

Hospital No. 000005

Age: 65

Sex: Female

Race: White

EXAMINATION DESIRED: Mammogram of the remaining breast (right)

REASON FOR EXAM: Carcinoma of breast

REPORT:

MAMMOGRAM OF THE REMAINING BREAST (RIGHT):

There is no evidence of skin thickening. In the upper outer quadrant, there is noted a small area of increased opacification with radiating fibrotic strands. There is at least one large vein leading out of this area, as well as two smaller venous channels that are dilated in comparison with the remaining vasculature of this breast. No calcifications can be detected. Incidentally, also, in the axilla on this side are two rounded opacities, suggesting lymph nodes.

IMP: Possibility of an upper outer quadrant carcinoma is surely to be considered. However, I would suggest a repeat mammogram in two or three months.

Date: 1/13/91

Exam: Mammogram Radiologist: O. Roentgen, MD

X-RAY REPORT





Example E5 can be abstracted as follows:

1/13/91. Mammogram (R) breast: In UOQ of breast an area of increased opacification; two opacities in (R) axilla suggesting lymph nodes. IMP: Possible UOQ carcinoma. Suggest repeat mammogram.

**Comment:** (R) means right; UOQ means upper outer quadrant.

### THERMOGRAPHY:

Thermography is a technique for detecting cancer by differentiating regions of hot and cold in the body. The surface temperature (its infrared<sup>1</sup> radiation) is photographically recorded. The thermogram is a mosaic of many thousands of bits of temperature information displayed photographically in shades of gray. The lighter tones indicate hot spots (increased emission of heat); the darker tones indicate cool areas. Since cancer cells usually divide more rapidly than normal cells, they often give off more heat than the normal cells surrounding them. It will be reported on a thermographic report, an example of which is shown on the next page. Abstract what you think is pertinent in Example E6 and then compare with the suggested abstraction on page 57.

---

<sup>1</sup>infrared--Denoting thermal radiation of wave length greater than that of the red end of the spectrum (the recorded band of wave lengths of electromagnetic vibrations of visible light).



EXAMPLE E6

DEPARTMENT OF RADIOLOGY - DIVISION OF THERMOGRAPHY

Name Adeline Graff Hospital No. 000006 X-Ray No. 91-0003  
Address \_\_\_\_\_ Sex: Female Race: White Date: 2/17/91  
Age 45 Physician: Rover Chekup, MD

CLINICAL INFORMATION (To be completed by physician)

SYMPTOMS AND FINDINGS: R/O Breast Cancer

CURRENT MEDICATIONS: None

SMOKING STATUS [ ] Smoker (Refrain from smoking 3 hours prior to exam.)  
[x] Non-smoker

Requesting physician: Rover Chekup, MD

TECHNICAL DATA

Ambient temp. 70% F Delta T 6% C Oral temp. \_\_\_\_\_

REPORT: BREAST THERMOGRAPHY

Breast thermograms were performed with patient in the seated position. The basic thermographic pattern of the breasts is: VASCULAR. There is mild asymmetry of the vascular patterns of the breasts, with a somewhat more prominent vessel which proceeds obliquely across the lower quadrant of the left breast. No evidence of neovascularization is observed.

Background breast temperatures are symmetrically decreased. The thermographic edge sign is not observed. Periareolar temperatures are symmetrical.

IMPRESSION:

This study is slightly atypical because of the more prominent vessel over the lower inner quadrant of the left breast with some extension toward the midline into the upper inner quadrant. As there is no associated neovascularization or vascular anarchy, this is probably within normal limits.

Radiologist: U. C. Viewum, MD



Example E6 might be abstracted as follows:

2/17/91. Thermograms, Bilat.: WNL.

**Comment:** Note R/O means "Rule out" breast cancer. It is a directive, not a diagnosis.

An x-ray report may result from a request for consultation from another department in the hospital. The radiologist will then read the x-ray film and prepare an x-ray consultation report. A request for consultation is illustrated on the next page (Example E7). Abstract what you think is pertinent in the report and then compare with the suggested abstraction on page 61.



EXAMPLE E7

Name: Nancy Etta Feather

Record No. 000007

Ward \_\_\_ Age 79 Sex Female Race White Service Medicine Date 7/15/91

CLINICAL DIAGNOSIS: Carcinoma of esophagus

Summary of Chief Clinical Symptoms and Findings (Specify Duration):

Difficulty swallowing; weight loss 6 mo.

Operation and Date: NA

Previous Radiographs: Yes ( ) No (X) Date \_\_\_\_\_

Type of Patient: Ambulatory ( ) Wheelchair (X) Roller ( ) Portable ( )

May Dressing Be Removed? NA

EXAMINATION DESIRED: PA & Lateral Chest

ESOPHAGRAM

Randy First, MD  
Resident or Staff Signature

7-15-91 PA and lateral view of the chest: The lung fields are thought to show signs of senile fibrotic reaction bilaterally with some minimal abnormal elevation of the left hemidiaphragm. Cardiac silhouette is within normal limits.

Multiple views of the chest with barium swallow show a persistent constricting lesion of the upper 1/3 of the esophagus just below the supraclavicular notch. This is probably a neoplastic process.

Juan Seer, MD  
Department of Diagnostic Radiology

DEPARTMENT OF DIAGNOSTIC RADIOLOGY  
REQUEST FOR CONSULTATION





Example E7 can be abstracted as follows:

7/15/91.           Chest x-ray: Negative for cancer

                  Esophagram:        Lesion of the upper 1/3 of the esophagus just below the supraclavicular notch. Probably a neoplastic process.

**Comments:** The following should be noted:

- a. The date is recorded.
- b. Two different examinations are reported:
  1. Chest x-ray
  2. Esophagram
- c. Each set of findings should be associated with the appropriate examination procedure.
- d. When x-raying the upper gastrointestinal tract, barium salts are swallowed to make the GI tract lining opaque.
- e. The senile fibrotic reaction of the lungs seems unrelated to cancer and need not be reported.

## PRACTICAL EXERCISES

Following are three sample x-ray reports (Examples E8-E10). Abstract what you think is pertinent and then compare with the suggested abstractions on page 69 .



EXAMPLE E8

Name: Lottie Herring

Hospital No.: 000008

Age: 56

Sex: Female

Race: Black

EXAMINATION DESIRED: Upper GI series

REASON FOR EXAMINATION: R/O carcinoma

REPORT:

There is a large mass in the antrum, partially obstructing the gastric outlet. The pylorus and duodenal bulb are not clearly defined or distended with barium. The marked deformity of the antrum with evidence of a mass suggests a lesion extending into the lumen from the greater curvature of the stomach. However, a lesion in the body of the pancreas is also suggested.

IMPRESSION: Carcinoma of the gastric antrum.

Date: 2/24/91

Exam: Upper GI series Radiologist: W. C. Clearly, MD

X-RAY REPORT



EXAMPLE E9

Name: Hardy Smooker

Hospital No.: 000009

Age: 55

Sex: Male

Race: White

EXAMINATION DESIRED: Laryngogram

REASON FOR EXAMINATION: Carcinoma of larynx with dysphagia

REPORT:

Multiple films demonstrate a mass of the left true cord which almost completely fills the left ventricle and involves the false cord as well.

The tumor extends posteriorly to the arytenoid and anteriorly close to the commissure but does not appear to cross the commissure.

There is some subglottic extension in the immediate vicinity of the true cord. I believe this to be posterior. The evidence is not entirely conclusive.

The remainder of the region is normal.

CONCLUSION:

Tumor extensively involving the left true cord, the ventricle and false cord with probable subglottic extension posteriorly.

Date: 4/19/91

Exam: Laryngogram

Radiologist: Emmet Ray, MD

X-RAY REPORT



EXAMPLE E10

Name: Ira Sickmann

Rec. No.: 000010

Ward \_\_\_\_\_ Age 70 Sex Male Race White Service Clinic Rad Date 9/22/91

CLINICAL DIAGNOSIS: Carcinoma of Esophagus

Summary of Chief Clinical Symptoms and Findings (Specify Duration):

Operation and date: NA

Type of Patient: Ambulatory (  ) Wheelchair (  ) Roller (  ) Portable (  )

Previous Radiographs: Yes (  ) No (  ) Date 7/15/91

May Dressing Be Removed?

EXAMINATION DESIRED: PA Chest

C. N. Lear, MD  
Resident or Staff Signature

9/22/91 PA CHEST: There is scoliosis of the thoracic spine with convexity to the left and there is uncoiling of the thoracic aorta. The heart is normal in size. The costophrenic angles are clear and the lungs show a minimal degree of interstitial fibrosis. The bony thorax is intact.

IMP: Essentially normal heart and lungs for the patient's age. There is slight widening of the superior mediastinum which is thought to be secondary to innominate artery.

Ray Radmann, MD  
Department of Diagnostic Radiology

DEPARTMENT OF DIAGNOSTIC RADIOLOGY  
REQUEST FOR CONSULTATION





Examples E8-E10 can be abstracted as follows:

Example E8: 2/24/91.

UGI:

Large mass in the antrum suggesting a lesion from greater curvature of the stomach extending into lumen. A lesion in the body of the pancreas is also suggested.  
IMP: Carcinoma of the gastric antrum.

**Comment:**

Information about extension of a lesion from the greater curvature of stomach and about a possible lesion in the pancreas is important for describing the primary site and the extent of disease. Other reports may corroborate this information.

Example E9: 4/19/91.

Laryngogram:

Mass of the left true cord extends across midline almost filling left ventricle and involving false cord; probable subglottic extension posteriorly.

Example E10: 9/22/91.

PA Chest: Normal.

**Comment:**

This report should be abstracted although it only contains negative information regarding this patient's cancer. Again, record the date, the name of the procedure, and "normal" or "negative." Do not copy details unrelated to cancer.



## COMPUTERIZED (AXIAL) TOMOGRAPHY (CT).

Computerized scanners are used for the examination of body tissues. Most well known are EMI scans, Delta-Scans, and Acta-Scanner. Unlike a conventional x-ray that sends a broad beam of radiation over a large area, the CT scanner's x-ray tube directs a thin, concentrated beam of radiation through a cross-section of the body to detectors. The technique involves recording of "slices" of the body with an x-ray scanner; these records are then integrated by computer to give a cross-sectional image. A complete study of a patient usually takes 8 to 15 separate scans of 13 mm -thick slices of the body.

From the readings, the computer constructs an image which is displayed on a television screen where it can be photographed for a permanent record. The precision of the scanner permits a more accurate diagnosis of the extent of disease than any other external means. It can discover tumors at an early stage and pinpoint their exact location. It may avert the risk of exploratory surgery to determine if an organ is diseased. CT scans can be made with or without the use of contrast media.

## EMISSION COMPUTERIZED TOMOGRAPHY (ECT)

### SPECT: Single photon ECT

Selected planes can be analyzed without interfering overlap from other planes. For example: In liver scanning for metastasis, smaller, deeper lesions can be better identified than with conventional scans.

### PET: Positron Emission Tomography

Some elements, for example, oxygen, carbon and nitrogen, do not have single photon-emitting isotopes suitable for conventional imaging. PET permits investigation of cerebral glucose metabolism and cerebral blood and, thus, measures chemical compounds of the body.

On the next page is a report (Example E11) of a CT (sometimes called CAT) scan of the chest. Abstract what you think is pertinent in the report and then compare with the suggested abstraction on page 75.



EXAMPLE E11

Name: Emma Bronchilli  
Hospital No.: 000011

Age: 48

Sex: Female

Race: Chinese

EXAMINATION DESIRED: CT scan of chest

REASON FOR EXAMINATION: Possible metastatic disease

REPORT:

CT BODY SCAN (No contrast material administered)

Axial tomograms of the superior mediastinum were performed at 2 cm distances. The mediastinum was included from the thoracic inlet to the level of the carina. The examination showed normal mediastinal structures with no evidence of a mediastinal mass. Several abnormal densities were recognized, however, in both upper lungs (at least 6 in the left lung and at least 7 in the right lung) which probably represent nodular infiltration of the lung parenchyma of metastatic origin. No evidence of pleural lesions was demonstrated, however.

The esophagus is visualized on this scan by a minimal amount of air in its lumen and does not appear to be displaced.

IMPRESSION: No evidence of superior mediastinal mass demonstrated. Multiple nodular infiltrations in both upper lobes representing probable metastatic lesions.

B. D. Scanner, MD  
Radiologist

Date: 6/6/91

Exam: CT scan of chest



The CT scan report can be abstracted as follows:

Example E11: 6/6/91. CT scan: No evidence of a superior mediastinal mass. Probable metastatic lesions in both upper lobes.



## DIAGNOSTIC NUCLEAR MEDICINE EXAMINATIONS: Radioisotope Scintillation Scanning (Scintiscan)

In nuclear medicine, radioactive substances known as *radioisotopes* are administered to the patient in order to diagnose disease. A radioactive isotope<sup>1</sup> disintegrates spontaneously (ultimately losing its radioactivity) and emits gamma rays from within the body which enable the physician to visualize internal abnormalities. This differs from x-ray procedures where the x-rays are passed through the body from an external source.

Examples of radioactive isotopes, commonly used for isotope-imaging studies, are gallium, iodine, and technetium. Sometimes non-radioactive compounds are simply labeled or tagged with a radioactive isotope and sometimes radioactive tracers (radioactive pharmaceuticals) are given by mouth or by vein. Some of the isotopes are selectively absorbed by tumors or by specific organs in the body. The concentrated radioisotopes outline the tumor or organ making it visible on the photoscanner by the emission of radioactive energy. Much research in nuclear medicine is concerned with attempts to find new radioisotopes and to develop radioisotope-labeled compounds that will be selectively absorbed in specific parts of the body.

A device called a photoscanner is used to measure the radioactivity from the nuclear substances absorbed by various parts of the body. A two-dimensional representation or map can be made of the rays emitted from the radioisotope which shows where it is concentrated in body tissue. Findings of such an examination are photographically recorded and are referred to as *scans*. The more common scans are illustrated in the diagram on the next page (Figure 1)--bone, kidney, thyroid, brain, salivary glands, heart/lung, liver/spleen, and total body. Bone scanning with various bone-seeking isotopes is advocated for earlier diagnosis of bone metastasis. Other names for these types of scans are scintiscan, gallium scan, and lymphoscintigraphy.

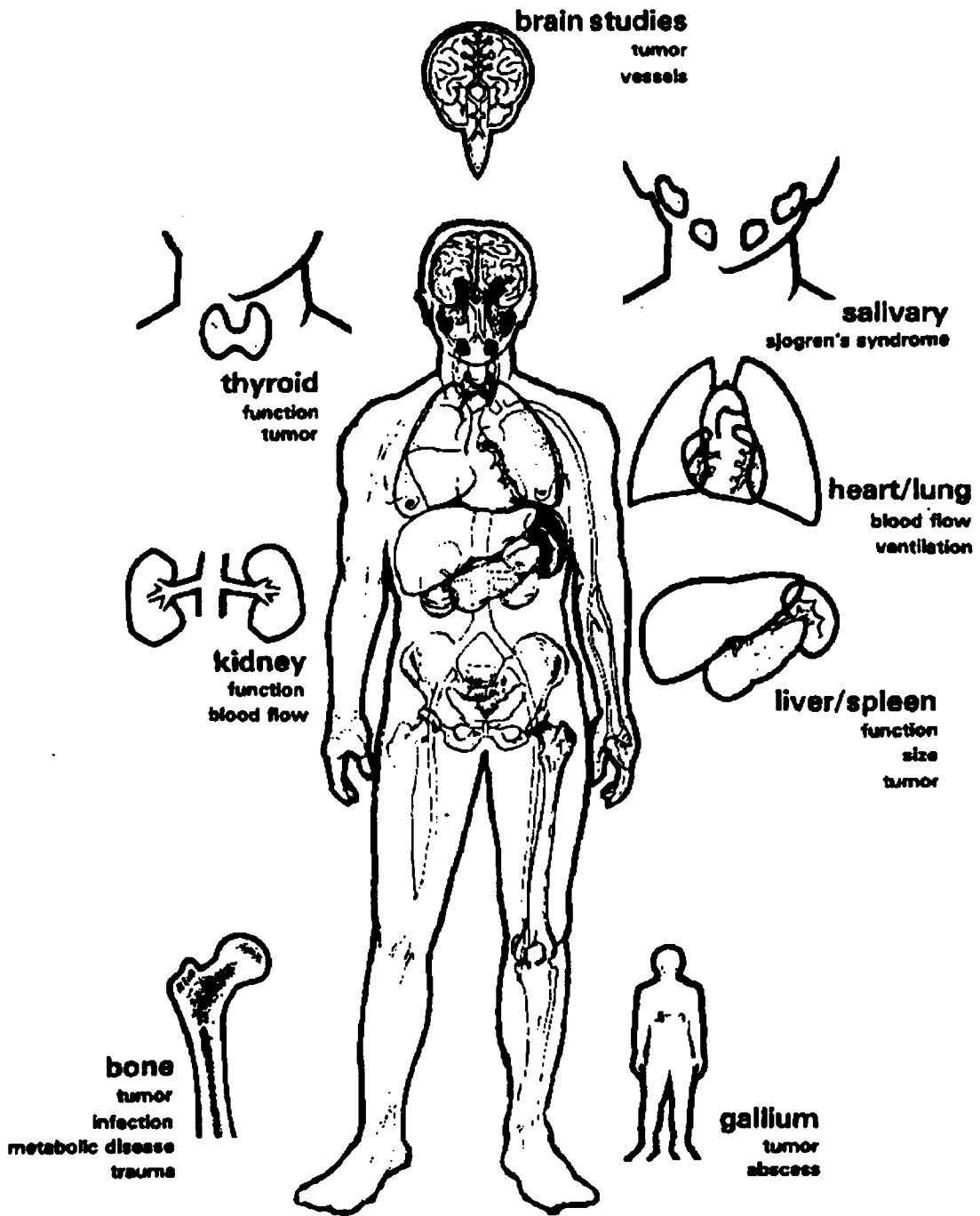
### PRACTICAL EXERCISES

Radioisotope scanning and tracer procedures are used frequently to diagnose cancer. In this section we will concentrate on reports of scans. Abstract Examples E12-E14 and then compare with the suggested abstractions on page 85.

---

<sup>1</sup>isotope--A form of a chemical element which varies from other forms of this element by the number of neutrons in its nucleus. An isotope can be stable or radioactive depending upon the composition of its nucleus.

Figure 1.



## DIAGNOSTIC IMAGING - NUCLEAR MEDICINE



EXAMPLE E12

THE DIVISION OF NUCLEAR MEDICINE RADIOISOTOPE SCAN REPORT

Name: Brenda Brainard

Hospital No.: 000012

Age 40

Sex Female

Race White

Service Neurology

Procedure Performed Brain scan

Date of Scan: 12/2/91

Isotope: Tc-99m

Dose: 10 mCi

Time Isotope Administered 12:40 Isotope Energy 140

Half-Life 6 hrs.

Time Scan Started: 1:20 Instrument: I

Area Scanned: Head

CRD 30 Speed 120 Range 30K Time Constant .01 Dot Factor 16 Density 25

Line Spacing .4

Light H.V. 900 Probe H.V. 521 Window 120-170

Maximum CPM: 22,000

Minimum CP:     

Thyroid Uptake:     

INTERPRETATION:

Brain scans done in multiple projections on the camera with and without perchlorate and by the rectilinear technique reveal a definite peripheral increase in tracer localization on the right seen in the posterior view. This is compatible with subdural disease.

IMPRESSION: Abnormal brain scan - peripheral right abnormality compatible with subdural disease.

Newell Clear, MD  
Nuclear Medicine Service



EXAMPLE E13

THE DIVISION OF NUCLEAR MEDICINE RADIOISOTOPE SCAN REPORT

Name: Megal Largesse Hospital No.: 000013  
Age: 78 Sex: Male Race: White Service: Oncology  
Procedure Performed: Liver Scan

Date of Scan 3/6/91 Isotope: Tc-99m S.C. Dose: 1 mCi  
Time Isotope Administered: 9:55 Isotope Energy: 140 Half-Life: 6 hrs.  
Time Scan Started: 10:55 Instrument: II Area Scanned: Abdomen  
CRD: 80 Speed: 57 Range: 10K Time Constant: .01 Dot Factor: 16 Density: 12  
Line Spacing: .4 Light H.V.: 1000 Probe H.V.: 546 Window: 120-170  
Maximum CPM: 16,000 Minimum: CPM ID: 700 Thyroid Uptake:     

INTERPRETATION: Technetium sulphur colloid liver scan done 3/6/91 reveals a grossly abnormal configuration to the liver in both the anterior and lateral projection of the liver, appearing larger in the lateral projection than it does in the anterior. There is a central decrease in tracer localization compatible with a space-occupying lesion. There is gross irregularity of the liver at the porta hepatis which is consistent with either space-occupying lesions of the liver in this area or possibly extrinsic compression from such things as enlarged lymph nodes.

IMPRESSION: Definitely abnormal liver scan consistent with a central lesion as well as irregularity along the right lower margin. The possibility of metastatic disease is high.

E. Z. Scanlon, MD  
Nuclear Medicine



EXAMPLE E14

Record No.: 000014

Name: Iman Payne

Ward: 709

Date: 10/28/91

REASON FOR EXAMINATION: ? Metastatic prostatic carcinoma

EXAMINATION: Total body bone scan

IMPRESSION: Abnormal Bone Scan

COMMENT: Whole body anterior and posterior views with technetium diphosphonate reveal multiple areas of abnormality. These are located within the skull, the neck, the sternum, the shoulders, multiple areas in the ribs, multiple lesions throughout the entire spine, and multiple lesions in the pelvis, and a discrete lesion in the shaft of the left femur.

Sean Kidd, MD  
Nuclear Medicine

NUCLEAR MEDICINE CONSULTATION REPORT





Examples E12-E14 should be abstracted as follows:

Example E12: 12/2/91. Brain Scan: Imp: Abnormal brain scan compatible with subdural disease on right.

**Comments**

- a. Record date.
- b. Record procedure performed--Brain scan.
- c. Record impression along with any information which seems to clarify or add to the report.
- d. A scan report will seldom contain a positive statement regarding the presence of cancer. Scan findings should be supported by other more definitive procedures. Thus, when you encounter an abnormal scan or isotope tracer report, look for other reports which support or negate the findings.

Example E13: 3/6/91. Liver Scan: Abnormal scan consistent with a central lesion as well as irregularity along (R) lower margin. Imp: High possibility of met. disease.

**Comment:** The various entries in the top portion of the report describe features of the examination procedure. They should not be reported.

Example E14: 10/28/91. Bone scan: Areas of abnormality in skull, neck, sternum, shoulders, ribs, spine, pelvis, and left femur.



## MAGNETIC RESONANCE IMAGING:

Magnetic Resonance Imaging (MRI) has rapidly become a powerful diagnostic tool--the diagnostic imaging method of choice in many clinical situations. It is based on magnetization of the various biological tissues. It does not use any ionizing radiation (such as x-rays) and is capable of direct imaging in any plane without reformatting. It can take multiple slices simultaneously. It can produce cross sections of the brain, spinal cord, heart, lungs, abdomen and blood vessels. In some instances it can chemically analyze body tissues by recording the behavior of atomic nuclei in living cells.

### NMR Chemical-Shift Imaging (or Spectroscopic Imaging)

NMR chemical-shift imaging literally adds a dimension to the potential clinical utility of Magnetic Resonance. Not only images, but chemical analysis of body tissues is possible through the use of magnetic resonance spectroscopy.

On the following pages are two examples of an MRI report. Abstract what you think is pertinent and then compare with suggested abstraction on page 93.



EXAMPLE E15

MAGNETIC RESONANCE IMAGING

Patient ID: 123456 Patient Name: Henry O'Hara Age: 30 Race: White

REFERRING PHYSICIAN: Osay Canusee

REPORT: MRI NECK AND LARYNX

INDICATION FOR EXAM: Primary laryngeal carcinoma with adenopathy

PROCEDURE: The following sequences were obtained:

- 1) Sagittal MPGR TR:500 TE:25 4 mm intervals
- 2) Sagittal PS TR:500 TE:20 5 mm intervals
- 3) Coronal PS TR:500 TE:20 4 mm intervals
- 4) Axial PS TR:400 TE:20 8 mm intervals
- 5) Axial SE TR:2000 TE:20/60 5 mm intervals.

FINDINGS:

There is enlargement of the base of the right aryepiglottic fold which represents the patient's primary tumor. There is otherwise no evidence for primary laryngeal tumor. The thyroid cartilage is normal as are the arytenoids. The true and false cords are normal in appearance. The remainder of the larynx is unremarkable in appearance. Unfortunately the coronal images are marred by a moderate degree of motion artifact associated with swallowing. There is an enlarged right cervical lymph node measuring 2.5 x 2.5 x 3 cm in size. It is closely adherent to the right sternocleidomastoid muscle as well as the right neurovascular bundle. No additional cervical lymph nodes are identified. There is otherwise no evidence for tumor extension into the perilaryngeal soft tissues. The remainder of the examination is unremarkable in appearance.

IMPRESSION:

1. Asymmetric thickening of the base of the right aryepiglottic fold representing the patient's primary tumor. Otherwise normal appearance of the larynx.
2. 2.5 x 2.5 x 3 cm right cervical lymph node with extension into the right sternocleidomastoid muscle and the right neurovascular sheath as described.

Date: 12/10/91

MRI REPORT



EXAMPLE E16

MRI CONSULTATION REPORT

Name: <u>Ina Gateway</u>		DOB: <u>1/10/41</u>	
10020261 mr018 abdomen/180-22-33	Referring Service, Clinic or Floor	DATE: <u>3/20/91</u>	
<input type="checkbox"/> Ambulatory <input type="checkbox"/> Bed <input type="checkbox"/> O <sub>2</sub> <input type="checkbox"/> OR <input type="checkbox"/> Wheelchair <input type="checkbox"/> Portable <input type="checkbox"/> Isolation			
PROCEDURES REQUESTED MRI of Abdomen	PRIMARY DIAGNOSIS (REQUIRED)	OUTPATIENT ICD-9 CODE	
CLINICAL HISTORY PERTINENT TO THIS RADIOLOGY CONSULTATION (REQUIRED)			
(INCLUDE PRECAUTIONS: DIABETES, ALLERGIES, ETC.)		Serum Creatinine or BUN for CT, IVP, Angio	
P L E A S E T	REQUESTING PHYSICIAN NAME	Phone	
	ATTENDING PHYSICIAN NAME	Phone	
Report will be sent to Physician Office, Clinic, Floor & Medical Records			
Address (Street, City, State)			
Date & Time Procedure Completed	Technologist I.D.	Part Exam	Film Count
Contrast Supplies & Comments			7    11
			8    14
			10    PCR
			kVp    Fluoro Time
			MAS    MR
			Distance    Sequences

RADIOLOGY CONSULTATION REPORT

MRN: 180-22-33                      Name: Ina Gateway

Proc: MRI OF ABDOMEN (3-20-91)

MRI was performed on a GE Sigma 1.5 Tesla MRI machine. Axial images with TR of 500 and TE 15, slice thickness of 5 mm were taken from the dome of the diaphragm to the iliac wings. Also taken were axial images with TR 2000 and TE 30/80 with 5-mm thick sections. Coronal sections with TR 500 and TE 15. In addition, axial sections with TR 10 and TE 2.9 with 5-mm thick sections were also included.

CONCLUSION:

1. A left suprarenal perirenal mass with mixed intermediate signal on T1 and T2 with areas of peripheral high signal on T1 and T2. The mass measures approximately 2.5 x 2 x 2 cm. This most likely represents a neuroblastoma with hemorrhage in the left adrenal.
2. No evidence of liver or spleen involvement or metastases.
3. The mass is displacing the left kidney posteriorly, however.
4. No identified skin involvement.

Date 3/20/91

John Doe, M.D.





**Examples E15 and E16 are abstracted as follows:**

**Example E15: 12/10/91 MRI of neck and larynx.**

- Impression:**
- 1. Thickening of base of R aryepiglottic fold represents primary tumor. Otherwise larynx normal.**
  - 2. R cervical lymph node 2.5 x 2.5 x 3 cm extends into R sternocleidomastoid muscle and R neurovascular sheath.**

**Example E16: 3/20/91 MRI of abdomen**

- Impression:**
- 1. Suprarenal mass 2.5 x 2 x 2 cm. Most likely a neuroblastoma. Mass displaces L kidney posteriorly.**

**Liver and spleen: No involvement or metastasis.**

**No skin involvement.**



## HEMATOLOGIC EXAMINATION

A *hematologic* examination is the *microscopic* examination of the cells of the blood or blood-forming tissues (especially bone marrow), looking for changes in the structure of and/or numbers of various types of blood cells, including immature cells.

Peripheral blood is circulating blood obtained from the extremities or from the circulatory system remote from the heart. One of the most frequently used procedures for obtaining blood for a complete blood count is the fingerstick method. Other procedures for obtaining specimens for hematologic examination include *venipuncture*, bone marrow aspiration, and bone marrow biopsy which will be discussed in detail later.

There are three main types of blood cells--*erythrocytes*, *leukocytes*, and *thrombocytes* (platelets)--all suspended in a fluid portion called plasma.

In reviewing what you learned in Book 3, separate the underlined words into their word elements and define each element.

	<u>Word Element</u>	<u>Meaning</u>
a. hematologic	_____	_____
	_____	_____
b. microscopic	_____	_____
	_____	_____
c. venipuncture	_____	_____
	_____	_____
d. erythrocytes	_____	_____
	_____	_____
e. leukocytes	_____	_____
	_____	_____
f. thrombocytes	_____	_____
	_____	_____

	Word Element	Meaning
a. hemat(o)logic	<u>hemato(o)</u>	<u>blood</u>
	<u>logic</u>	<u>pertaining to the study of</u>
b. micr(o)scopic	<u>micr(o)</u>	<u>small</u>
	<u>scopic</u>	<u>visual examination</u>
c. ven(i)puncture	<u>ven(i)</u>	<u>vein</u>
	<u>puncture</u>	<u>puncture</u>
d. erythr(o)cytes	<u>erythr(o)</u>	<u>red</u>
	<u>cytes</u>	<u>cells</u>
e. leuk(o)cytes	<u>leuk(o)</u>	<u>white</u>
	<u>cytes</u>	<u>cells</u>
f. thromb(o)cytes	<u>thromb(o)</u>	<u>clot</u>
	<u>cytes</u>	<u>cells</u>

Before you can begin to abstract from the hematology reports, you must be aware of the terms you will encounter and of their significance. Following are definitions of terms which you will encounter frequently.

### *Red Blood Cells*

There is only one type of mature *erythrocyte* (red blood cell), but there are several types of immature erythrocytes. One common type is called a *reticulocyte*.

*Hemoglobin* is a blood protein found in red blood cells; it transports oxygen to the tissues of the body and returns carbon dioxide to the lungs.

*Hematocrit* measures the volume of erythrocytes. It is expressed as a percentage of the volume of whole blood.

### *White Blood Cells*

*Leukocytes* (white blood cells) are of two main types--granulocytes or granular leukocytes (containing granules in their cytoplasm) and agranular leukocytes (lacking granules in their cytoplasm).

*Granulocytes* or *granular leukocytes* can be further subdivided (based on the staining properties of the granules) into:

*Neutrophils* (purple) - 40-60% of all leukocytes

*Eosinophils* (red) - 1-3% of all leukocytes

*Basophils* (blue) - 0-1% of all leukocytes

A *neutrophil* may be further specified as *segmented* (SEGS), *banded* (STABS), or *juvenile* (a metamyelocyte).

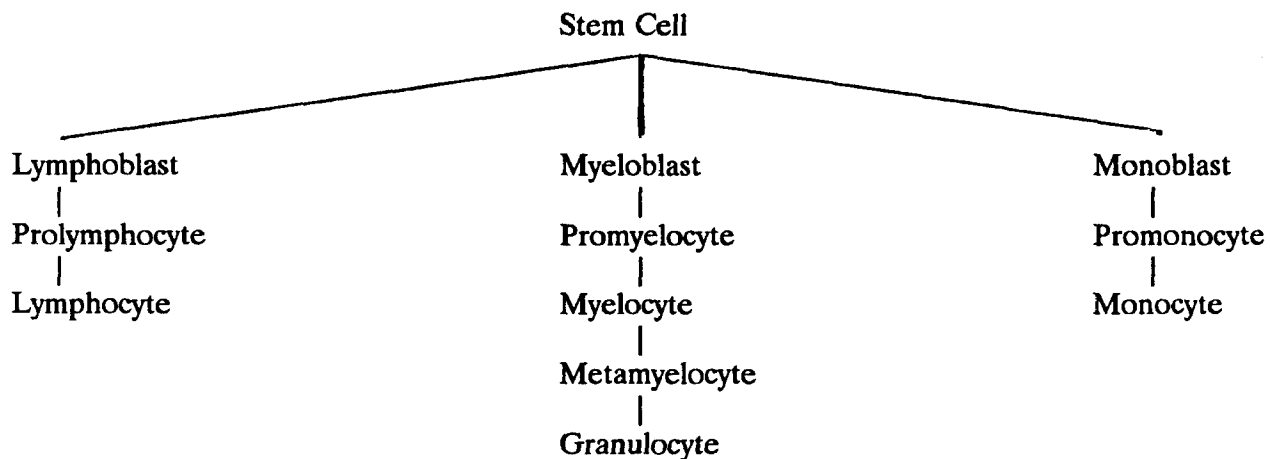
A *myelocyte* is a granulocytic cell.

*Agranular leukocytes* may be further subdivided into two types:

*Monocytes* - 4-8% of all leukocytes

*Lymphocytes* - 20-40% of all leukocytes

#### DEVELOPMENT OF WHITE BLOOD CELLS



#### *Platelets*

*Platelets* (thrombocytes) are tiny cells or discs whose primary function is hemostasis (clotting of blood).

On the next page is a table of normal blood values. Compare the definitions above with the terms and their values in the table.

## NORMAL BLOOD VALUES

The values for blood may vary in relationship to the altitude of your geographic location. Check with your Hematology Department if the normal values do not appear on your hematology report forms. The following values are for sea level.

Hematocrit -	Men:	45% (38-51%)
	Women:	40% (36-47%)
Hemoglobin -	Men:	14-17 gm. %
	Women:	12-16 gm. %
	Children:	12-14 gm. %

---

Blood Counts	Per cu. mm	Percent
Erythrocytes (RBC)		
Men	5.0 (4.5-6.0) million	
Women	4.5 (4.3-5.5) million	
Reticulocytes		1.0%
Differential White Count		
Leukocytes, total (WBC)	5,000-10,000	100%
Lymphocytes	1,000-4,000	20-40%
Segmented neutrophils	2,500-6,000	40-60%
Band neutrophils	0-500	0-5%
Juvenile neutrophils	0-100	0-1%
Myelocytes	0	0%
Eosinophils	50-300	1-3%
Basophils	0-100	0-1%
Monocytes	200-800	4-8%
Platelets	200,000-500,000	

Certain types of disease associated with the abnormality of blood cells are:

- Anemia - Deficiency in erythrocytes or hemoglobin
- Aplastic anemia - A form of anemia in which there is a lack of formation of blood cell elements in the bone marrow
- Leukemia - A progressive, malignant disease of the blood and blood-forming organs characterized by uncontrolled proliferation and development of leukocytes. It is diagnosed by microscopic detection of abnormal cells in the circulating blood and in the bone marrow.
- Leukocytosis - An increase in the number of leukocytes in the blood
- Leukopenia - Reduction in the number of leukocytes in the blood
- Polycythemia - Excessive number of erythrocytes
- Thrombocytopenia - Decrease in the number of blood platelets

Therefore, you can see that the hematology report contains information which the cancer registrar must abstract for leukemias and polycythemia vera.

## PRACTICAL EXERCISES

The examination findings from three routine hematology reports, each using a different format, are demonstrated on the following pages (Examples E17-E19).

Example E17 is a routine form using the abbreviations RBC and WBC instead of writing out erythrocytes and leukocytes. You also may not be familiar with the term "lymphoblast" which means an immature lymphocyte. As a check that you have abstracted the correct values, add the various leukocyte percentages to see if they equal 100%. For example, in Example E17 the differential<sup>1</sup> white count is as follows:

<u>Leukocytes</u>	<u>Percent</u>
Neutrophils	69
Lymphoblasts	23
Monocytes	6
Eosinophils	1
Basophils	<u>1</u>
	100%

---

<sup>1</sup>differential--In performing the blood count, a total of 100 cells are counted. The percent of each type found in these 100 cells is the cell "differential" for each type.



Example E18 simply records the workup and the values obtained in an abbreviated form. Abbreviations frequently used are:

CBC =	complete blood count (RBC and WBC)
RBC =	red blood count
WBC =	white blood count
Hct. =	hematocrit
Hgb. =	hemoglobin
Plat. =	platelets
Retic. =	reticulocytes
PME =	polymorphonuclear <i>eosinophils</i> (leukocytes)
PMN =	polymorphonuclear <i>neutrophils</i> (leukocytes)

Polymorphonuclear leukocytes usually refer only to neutrophils. Notice in Example E18 that the abbreviations PME and PMN are both used.

Promonocytes are immature monocytes.

Check that the differential white count adds to 100%.

<u>Leukocytes</u>	<u>Percent</u>
PMN	90
PME	1
Mature lymphocytes	3
Mature monocytes	5
Promonocytes	<u>1</u>
	100%

Example E19 again is a routine form, but much more detailed and explicit than E17. The leukocytes are subdivided into granulocytes and agranulocytes which are then further subdivided. Check that the differential white count adds to 100%.

<u>Leukocytes</u>	<u>Percent</u>
Granulocytes	59
Neutrophils	57
Eosinophils	1
Basophils	1
Agranulocytes*	41
Monocytes	2
Lymphocytes	39
	<u>100%</u>

\*The term "agranulocyte" will not be found in reports. We have used it here to differentiate the two different types of leukocytes.

On the basis of what you know about the diseases associated with abnormal blood cells, abstract what you think is pertinent from the following hematology reports, then check with the abstractions on page 107.

EXAMPLE E17

HEMATOLOGY LABORATORY

Name: Rudy Blanc Sex Male Age 7 Race White Date 11/14/91

Patient Number 000015 Nursing Unit \_\_\_\_\_

Physician Hemm Allstar, MD

Clinical Data R/O leukemia

<input checked="" type="checkbox"/> WBC 6.1 thousand	<input checked="" type="checkbox"/> RBC 4.6 million/mm <sup>3</sup>
Differential Count	<input type="checkbox"/> Hematocrit
<input checked="" type="checkbox"/> Neutrophils 69%	<input checked="" type="checkbox"/> Hemoglobin 12.6 gms.%
<input type="checkbox"/> Bands	<input type="checkbox"/> Blood Morphology
<input type="checkbox"/> Metamyelocytes	<input type="checkbox"/> Normal
<input type="checkbox"/> Myelocytes	<input checked="" type="checkbox"/> Microcytosis 1+
<input type="checkbox"/> Promyelocytes	<input checked="" type="checkbox"/> Macrocytosis 1+
<input type="checkbox"/> Myeloblasts	<input type="checkbox"/> Hypochromia
<input type="checkbox"/> Lymphocytes	<input type="checkbox"/> Basophils
<input checked="" type="checkbox"/> Lymphoblasts 23%	<input type="checkbox"/> Target Cells
<input checked="" type="checkbox"/> Monocytes 6%	<input checked="" type="checkbox"/> Ovalocytes 1+
<input checked="" type="checkbox"/> Eosinophils 1%	
<input checked="" type="checkbox"/> Basophils 1%	

Other: Platelet count (per cu mm) 238 thousand

REMARKS Diagnosis: Acute lymphocytic leukemia

Reviewed by A. C. Lukes, MD

Date 11/18/91



EXAMPLE E18

HEMATOLOGY LABORATORY

Name Vera Thenia

Date 3/25/91

Hospital No. 000016

Ward \_\_\_\_\_

Drawn 3/25/91 Completed 3/25/91

Diagnosis Polycythemia vera

Determination CBC - RBC

WBC: 9650

Hgb.: 20.3 gms.%

Plat.: 938,000

Retic: 1.2%

PMN: 90

PME: 1

Mature Lymphocytes: 3

Mature Monocytes: 5

Promonocytes: 1

Unable to grade RBC's due to thick smear.

Some hypersegmented neutrophils. Increased platelets on smear.



EXAMPLE E19

HEMATOLOGY LABORATORY

Rec. No. 000017 Name Norm Blasts

Ward W405 Age 53 Sex Male Race Black Hematology No. H91-0100  
Date 8/1/91

Hemoglobin <u>10.8</u> gm%	Sedimentation Rate (Wintrobe)
Erythrocytes _____ /mm <sup>3</sup>	Uncorrected _____ mm/hr.
Hematocrit <u>33</u> %	Corrected _____ mm/hr.
M.C.V. _____	Bleeding Time (Ivy) _____ min.
M.C.H. _____	Clot Retraction _____ hr.
M.C.H.C. _____ %	Capillary fragility _____
Thrombocytes _____ /mm <sup>3</sup>	Prothrombin Time _____ sec. _____ sec.
Leukocytes <u>9,250</u> /mm <sup>3</sup>	Plasma Recalcification Time _____ sec. _____ sec.
Granulocytes <u>59</u> %	Partial Thromboplastin Time _____ sec. _____ sec.
Neutrophils <u>57</u> %	Serum Pro. Time _____ sec. _____ sec.
Bands <u>0</u> %	Screen Fragility (5% saline)
Myelocytes <u>0</u> %	Osmotic Fragility:
Eosinophils <u>1</u> %	Hemolysis begins _____ %saline
Basophils <u>1</u> %	complete _____ %saline
Monocytes <u>2</u> %	Control begins _____ %saline
Lymphocytes <u>39</u> %	complete _____ %saline
_____	Direct Coombs: <u>Negative</u>
_____	
_____	
Reticulocytes <u>2.0</u> %	/100WBC
Normoblasts _____	
Sickle Cell Prep <u>negative</u>	Hemoglobin Electrophoresis _____
_____	

L. E. Prep. \_\_\_\_\_

Peripheral:

Hemoglobin and hematocrit values were low. WBC and differential were normal. Sickle preparation was negative. Reticulocyte count was normal.

Smear:

RBC's were for the most part normocytic, normochromic with anisocytosis. Some of the cells were hypochromic with occasional target cells present. WBC appear normal. Platelets are adequate.

W. B. Counter, MD



## PRACTICAL EXERCISE ANSWERS

Example E17 11/14/91. Hema. Rpt.: Hgb-12.6 gms%. WBC-6,100. Plat.-238,000.  
Lymphoblasts-23%.  
Dx: Acute Lymphocytic Leukemia.

**Comment:** The WBC for this patient is within the normal range, however, the presence of blast (immature) cells called lymphoblasts is diagnostic of leukemia.

Example E18: 3/25/91. Hema. Rpt.: Hgb.-20.3 gms%. WBC-9650. Plat.-938,000.  
Dx: Polycythemia vera.

Example E19: 8/1/91. Hema. Rpt.: Hgb. and Hct. values low; WBC and retic. normal.

**Comment:** This report is not diagnostic of leukemia and probably would not be a reportable case. Hematologic findings generally are not recorded for other than leukemia and lymphoma cases.

Patients with the diagnosis of leukemia often have a hematologic examination performed daily. To report the findings of each examination would be excessive. The best procedure is to extract pertinent findings from the first report upon admission and the most definitive report prior to the beginning of treatment. In addition, reports indicating remission or relapse may be recorded as part of the follow-up information.





**Bone Marrow Studies.** Examination of the bone marrow is critically important in the diagnosis and management of a wide variety of hematologic disorders, for example, leukemia. Circulating blood cells are actively produced in the bone marrow. Bone marrow can be obtained by needle aspiration (cytologic examination), by biopsy of tissue utilizing one of a variety of special needles, or by open surgical biopsy with a trepine<sup>1</sup> (histologic examination). An abnormal cytologic examination will generally be supplemented by a histologic examination.

Example E20 is a report of a bone marrow aspiration for a leukemia patient now in remission. Abstract what you think is pertinent and then compare with the suggested abstraction on page 113.

Bone marrow biopsies are discussed on pages 195 and 225. Example G8 is a report of a bone marrow biopsy of a lymphoma patient.

---

<sup>1</sup>trepine--An instrument for removing a circular disc of bone.



EXAMPLE E20

Name: Bo Comeaway

Hospital No.: 000018

Age: 24 Sex: Male

Race: White

EXAMINATION DESIRED: Bone Marrow Aspiration

ASPIRATE SECTION:

Normocellular  
Megakaryocytes, normal  
Stainable iron is normal

SMEAR:

59% erythroid  
35% granulocytes  
01% lymphoblasts  
02% immature lymphocytes  
03% small lymphocytes  
Moderately megaloblastic erythroid hyperplasia

DIAGNOSIS:

Previously diagnosed acute lymphocytic leukemia  
Moderately megaloblastic erythroid hyperplasia

COMMENT:

Acute lymphocytic leukemia in remission

Spiro Bonne, MD  
Pathologist

Date: 6/5/91

Exam: Bone Marrow Aspiration



Example E20 can be abstracted as follows:

Example E20: 6/5/91. Bone marrow aspiration. Dx: Acute lymphocytic leukemia in remission.



### *Blood Serum Studies*

Automation and modern advances in medical technology enable the physician to obtain a complete battery of laboratory tests from the patient's blood. Listed below are a few of the studies you may want to check to assess the diagnosis or spread of cancer.

*Serum Calcium.* Calcium circulates in the blood in equilibrium with the calcium in the bone. Patients with cancer have a tendency to develop an excess of calcium in the blood (hypercalcemia), particularly with lung and breast cancers, reflecting metastatic disease of the bone. When bone is replaced with malignant cells, calcium is released in an increased amount in the blood circulation. Normal values are 8.5-10.5 mg/100 ml (slightly higher for children).

*Serum Alkaline Phosphatase.* Alkaline phosphatase is an intracellular enzyme which becomes elevated when there is destruction of cells. The key areas where it is produced are the liver and bones. An elevated alkaline phosphatase is indicative of bone and liver abnormalities. See page 116 for normal values.

*Serum Acid Phosphatase.* Elevated serum levels of acid phosphatase are seen in patients with carcinoma of the prostate that has extended beyond the prostatic capsule. Patients with prostatic carcinoma still confined within the capsule usually have a normal serum level. However, patients with benign prostatic hypertrophy may have slight elevations of the serum acid phosphatase level after vigorous prostatic "massage." Since other tissues may also release acid phosphatase into the serum, minor elevations may reflect an origin other than the prostate. Acid phosphatase determination has been used diagnostically to help determine the resectability of prostatic cancers. Cancers which have extended beyond the prostatic capsule, i.e., to the bone, are not generally treated by prostatectomy. See page 116 for normal values.





### *Other Laboratory Studies*

*Marrow Acid Phosphatase.* Accurate staging of prostatic cancer is important for determining treatment. Since the skeletal survey by routine radiography may be negative until approximately 40 percent of bone is involved with tumor, other tests, including *marrow acid phosphatase*, are used for the detection of early bone metastasis in patients with prostatic cancer. An elevated bone marrow acid phosphatase follows dissemination of prostatic cancer to the marrow space and contraindicates radical surgery in these patients. Normal values for marrow acid phosphatase are the same as for serum acid phosphatase.

*Hormonal/Steroid Studies.* Certain malignancies are quite apt to change the level of hormones and/or steroids produced in the body. A study of the hormone/steroid composition of the urine can sometimes be used to infer the presence of such a malignancy.

There will not be many instances when you will have to abstract a report of a hormone or steroid study. Hormone studies may be used as an aid in diagnosing tumors of the adrenal cortex, pancreas, uterus, and testes.

*Bilirubin.* Bilirubin is a pigment excreted normally by the gallbladder and liver. An elevated bilirubin is indicative of obstruction of the gallbladder or of hepatic disease which affects the function of the liver. Normal values are: One min. 0.4 mg/100 ml. Direct: 0.4 mg/100 ml. Total: 0.7 mg/100 ml. Indirect is total minus direct.

*BUN (Blood urea nitrogen).* An elevated BUN may result in uremia reflecting the failure of the kidneys to excrete normal waste materials. For example, it occurs frequently in patients with cancer of the cervix and bladder where extensive growth of the cancer obstructs the ureters. Normal values are 8-25 mg/100 ml.

*Uric Acid.* In any malignancy with rapid destruction of cells, uric acid may be elevated. It is of particular interest in patients with lymphoma, Hodgkin's disease, lymphosarcoma, polycythemia vera, and leukemia treated by radiation therapy and/or chemotherapy. Normal values are 3.0-7.0 mg/ml.

*Total protein.* This test measures the amount of total circulating protein (albumin and globulin) in the patient's blood serum. It is elevated in multiple myeloma. Low total protein (low level of albumin) is associated with pleural effusion and ascites. Normal values are 6.0-8.0 gm/100 ml.

*LDH (Lactic acid dehydrogenase).* LDH is an intracellular enzyme which occurs in many body cells. An elevated LDH is indicative of increased cell destruction, possibly from metastatic spread of cancer. Normal values are 60-100  $\mu$ /ml.

*SGOT (Serum Glutamic-oxalacetic-transaminase).* This is an enzyme which is specifically manufactured in the liver. It is elevated when the liver does not function normally. Normal values are 10-40  $\mu$ /ml.

*CEA (Carcino-embryonic-antigen).* This term was first used in 1965 to describe a glyco-protein which is present in extracts of carcinoma cells. An elevated CEA may be indicative of cancer of the gastrointestinal tract and, occasionally of the breast, lungs, and female genital system. When the entire malignancy is removed, the CEA level may drop; it may rise when recurrence or metastasis develops. Normal values are 0-2.5 mg/ml. However, CEA titers less than 2.5 mg/ml are not proof of the absence of malignant disease. Normal values do not apply if the patient is a smoker.



**SECTION F**  
**MANIPULATIVE AND OPERATIVE PROCEDURES**



**SECTION F**  
**MANIPULATIVE AND OPERATIVE PROCEDURES**

**MANIPULATIVE PROCEDURES**

There are a variety of diagnostic procedures which involve the direct viewing, feeling, hearing, and smelling of the body. In many instances, special instruments have been devised to directly view the interior of the body. In this segment of instruction, we will discuss gross (as opposed to microscopic) direct examination procedures. Most of the instructional and practical exercise material will be related to endoscopic procedures.

*Endoscopic Examination*

An *endoscope* is an instrument for examining the interior of a canal or hollow viscus (any large interior organ). A variety of endoscopes have been developed for direct inspection of the interior of the stomach, larynx, colon, rectum, bladder, esophagus, and portions of the lung. Listed below are the more common endoscopic\* examinations:

BRONCHOSCOPY:	Examination of the bronchi (See page 128 and Examples F9, F10, F12)
COLONOSCOPY:	Examination of the colon and rectum by means of an elongated flexible fiberscope
COLPOSCOPY:	Examination of tissue of the cervix and vagina by use of a magnifying lens inserted into the vagina
CYSTOSCOPY:	Direct visual examination of the interior of the urinary bladder (See page 133, Example F3)
ESOPHAGOSCOPY:	Observation of the interior of the esophagus (See Examples F9, F11-F12)
GASTROSCOPY:	Inspection of the interior of the stomach (See Examples F4, F7, F8)
LARYNGOSCOPY:	Examination of the larynx (See Examples F2)
NASOPHARYNGOSCOPY:	Examination of the nasopharynx, pharynx, and the pharyngeal end of the auditory tube by lighted telescopic endoscope
OPHTHALMOSCOPY:	An examination in which an instrument containing a perforated mirror and lenses is used to examine the interior of the eye
OTOSCOPY:	Inspection of the internal ear
PANENDOSCOPY:	A cystoscopy that permits wide angle viewing of the urinary bladder (See Cystoscopy)
PROCTOSCOPY:	Inspection of the rectum (See Examples F1, F6)
SIGMOIDOSCOPY:	Inspection of the colon up to sigmoid flexure (See Example F5)
VAGINOSCOPY:	(See Colposcopy)

\*Colposcopy and otoscopy may not involve use of endoscopes. They are included here because they are diagnostic manipulative procedures.



*Proctoscopy, Sigmoidoscopy, and Colonoscopy.* Inspection of the intestinal tract is done by tubular endoscopes with appropriate illumination. The instrument for examination of the rectum is called a proctoscope. To examine the sigmoid colon, a device called a sigmoidoscope is used which can visualize up to 25 cm from the anal verge<sup>1</sup>. To examine the entire colon from the rectum to the cecum a device called a fiberoptic colonoscope is used. As its name implies, this instrument is flexible. The sigmoidoscope or proctoscope can be either rigid or flexible. If a malignancy is suspected, tissue can be removed during the examination for histologic study.

An illustration of a proctoscopy report is shown in Example F1. Abstract what you think is pertinent in Example F1 and compare with the suggested abstraction on page 127.

---

<sup>1</sup>anal verge--The external or distal boundary of the anal canal.

EXAMPLE F1

Rec. No. 000019 Name Ivan Block  
Age 65 Sex Male Race White Date 3/31/91  
Chief Complaint Bloody Stools Referred by Everett Hope, MD  
Previous Proctoscopy: Yes Date 3/20/84 Findings Negative  
Previous Rectal Surgery: None

HISTORY:

1. Blood per Rectum Occas for 6 mo.
  2. Abdominal Colic None
  3. Appetite Recent loss
  4. Abscess \_\_\_\_\_
  5. Itching \_\_\_\_\_
  6. Weight Loss 10 lbs.
  7. Protrusion Intermittent
  8. Change in bowel habits Diarrhea
  9. Draining fistula \_\_\_\_\_
  10. Rectal Pain \_\_\_\_\_
  11. Fever \_\_\_\_\_
  12. Constipation Alt. const./diarrhea
13. Diarrhea \_\_\_\_\_ Duration \_\_\_\_\_ Character of Stool --Ribbon-like  
Periodic for 6 mo. No. of Stools \_\_\_\_\_ Blood \_\_\_\_\_  
Mucus \_\_\_\_\_ Cramps \_\_\_\_\_
14. Laboratory: Frei \_\_\_\_\_ Serology \_\_\_\_\_ Ova & Parasites \_\_\_\_\_

PROCTOSCOPY:

Distance Scoped: 8 cm Interference \_\_\_\_\_  
Mucosa: Normal \_\_\_\_\_ Red \_\_\_\_\_ Edematous X Friable \_\_\_\_\_  
Ulcerated \_\_\_\_\_ Vascular Pattern \_\_\_\_\_ Mucus \_\_\_\_\_  
Pus \_\_\_\_\_ Blood X Granular \_\_\_\_\_ Glistening \_\_\_\_\_

DESCRIPTION OF OTHER PATHOLOGY AND REMARKS:

- (1) Digital - Hemorrhoids. Mass palpable posteriorly; feels fixed to sacrum; impinges on lumen
- (2) Proctoscopy - Obstruction posteriorly @ 8 cm. Multiple Bx's taken. Could not pass either regular size or stricture scope past lesion

Examined by: Sid Procter, MD

PROCTOSCOPY REPORT



The manner in which the findings in Example F1 can be summarized on the cancer registry abstract is as follows:

Example F1: 3/31/91. Procto.: Mass palpable posteriorly; feels fixed to sacrum. Multiple Bx taken. Obstruction @ 8 cm; could not examine above.

**Comments:**

- a. A proctoscopic examination will include both a digital (finger) examination and a proctoscopic inspection. Sometimes the findings from these two different procedures will not be described separately. This does not matter to the abstractor. When abstracting the findings, you can combine them to get the most complete and concise description.
- b. The medical definition of the term "lumen" is the cavity or channel within a tube or tubular organ. Endoscopes enter the body through the lumens of the colon-rectum, the esophagus, the trachea-bronchi and the urethra.
- c. Biopsies were taken; therefore, the medical record should contain pathology reports describing these findings.

The general procedures for abstracting the proctoscopy report are:

1. Record the date and type of procedure.
2. Combine the findings of the digital and proctoscopic examination into a short but complete statement of the pertinent findings.
3. If biopsies were taken, locate the pathology report and abstract the findings.

*Bronchoscopy.* Bronchoscopy is the visual examination of the bronchi of the lungs by the use of the bronchoscope which may be inserted into the oral or nasal cavities. The larynx, pharynx, and trachea may be visualized as the scope is passed to the bronchi (See F9, F10, F12). It may serve other purposes also. For example, it may be used to remove a foreign body from the bronchus, or for clearing a mucous plug which is causing atelectasis<sup>1</sup>.

*Laryngoscopy.*

Direct Visualization:

A laryngoscopy is the visual examination of the larynx and hypopharynx using a laryngoscope. Abstract what you think is pertinent in the laryngoscopy report (Example F2) and compare with the suggested abstraction on page 131.

Indirect Visualization:

Examination of the interior wall of the larynx by observation of the reflection of it in a laryngeal mirror

---

<sup>1</sup>atelectasis--Absence of air in the alveolar spaces resulting in incomplete expansion of the lungs at birth or collapse of the lungs of an adult.

EXAMPLE F2

LARYNGOSCOPY REPORT

Hosp. No. 000028 Name Larry Easop Service ENT

Sex Male Age 59 Race White Date of Operation 8/17/91

Clinical Diagnosis Carcinoma of the larynx

Procedure Direct laryngoscopy Anesthetic \_\_\_\_\_

Under general anesthesia and without intubation, the laryngoscope was inserted. The larynx was exposed. Immediately there was noted a fungating mass occupying the left supraglottic area up to the level of the aryepiglottic fold. The pyriform sinuses and the glottis itself were free of disease. A biopsy was taken. The cords were moving normally.

The mass, as was mentioned above, occupies the left supraglottic areas from the level of the false cord up to the aryepiglottic fold. It does not pass the midline. It was friable, but with no excessive bleeding.

The patient tolerated the procedure well and left the operating room in good condition.

Endoscopist Opie Endoes, MD

Assistant Andy Also, II, MD



The illustrated report can be abstracted as follows:

Example F2: 8/17/91. Laryngoscopy: Fungating mass occupying the left supraglottic area from the false cord up to the aryepiglottic fold. It does not pass the midline. Pyriform sinuses and the glottis are free of disease. The cords were moving normally. Bx taken.

**Comments:**

- a. The procedure "direct laryngoscopy" is sometimes abbreviated "D.L."
- b. Reporting "biopsy taken" alerts the abstractor to look for the pathology report.

The general procedures for abstracting the laryngoscopy report are:

1. Report date and type of procedure.
2. Record description of pertinent findings, such as location of the tumor and mobility of the cords.
3. If biopsies were taken, locate pathology report and abstract pertinent findings.

*Cystoscopy.* The cystoscopy is the examination of the interior of the urinary bladder by means of a cystoscope. It is inserted into the bladder by way of the urethra and, therefore, can be used to examine the urethra as well. The results of these examinations may be recorded on the report of cystoscopy as in the following example. Abstract what you think is pertinent in Example F3 and compare with the suggested abstraction on page 135.





EXAMPLE F3

REPORT OF CYSTOSCOPY

Name Sammy Kidd Service Medicine Hospital No. 000021  
Sex Male Age 56 Race White Date 1/14/91

Pre-operative Diagnosis: Carcinoma of the bladder

Surgeon K. U. Bladd, MD

Assistant Surgeon Urie Sac, MD

Operative Diagnosis: Carcinoma of the bladder

Operation: Cystoscopy; random biopsies of bladder; bilateral retrograde pyelography; TUR - primary bladder carcinoma

DESCRIPTION OF OPERATION: The patient was placed in the lithotomy position. Under satisfactory general anesthesia, the cystoscope was passed into the bladder and urine was sent for cytology. At this point, a careful evaluation of the bladder revealed a relatively extensive localized exophytic lesion in the right superior lateral portion of the bladder, just inside the bladder neck. This appeared to be sessile, and it was obviously tumor. There was some surrounding erythema. The rest of the bladder showed some inflammatory changes with erythema, but no overt lesions were noted.

It appeared that this was a relatively lower grade lesion than I had expected. A bilateral retrograde pyelogram was then performed which revealed a probable cyst in the upper pole of the right kidney with no other intrinsic filling defects or distortion. The left collecting system appeared to be quite normal with no ureteral defects.

Using cup biopsy forceps, random biopsies were taken from the trigone, the right and left lateral bladder wall, and the posterior bladder wall. These were submitted separately.

At this point, an extensive transurethral resection of the lesion in the right superior lateral portion of the bladder wall was performed using a resectoscope. The base was carefully fulgurated, as was the surrounding area, and all bleeding was carefully controlled. This tissue was submitted as a separate specimen for pathologic evaluation.

A careful bimanual exam revealed no evidence of induration within the bladder wall or other pelvic abnormality.

The patient tolerated the procedure very well and was taken to the Recovery Room in good condition.

K. U. Bladd, MD



Example F3 is abstracted as follows:

Example F3: 1/14/91. Cystoscopy: Localized sessile lesion in (R) superior lateral portion of bladder. No other overt lesions. Multiple Bx's taken. Dx: Carcinoma of bladder.

Pyelogram: Prob. cyst in upper pole of (R) kidney. (L) collecting system normal. No ureteral defects.

TURB done.

Bimanual examination: No evidence of induration within bladder wall or other pelvic abnormality.

**Comments:**

- a. Three examinations are described in this report (cystoscopy, retrograde pyelogram, and bimanual examination) as well as surgical treatment (TURB).
- b. Some reports will indicate the presence or absence of cancer as a "diagnosis." Other reports will contain a statement of the "impression." Do not attempt to distinguish between the two. Simply use whatever term appears on the report.

The general procedures for abstracting a cystoscopy report are as follows:

1. Record date and type of procedure.
2. Record pertinent findings.
3. Record statement of diagnosis, if given.
4. Record that Bx's and TURB were done, locate pathology reports, and record the pertinent findings.

*Gastroscopy.* The gastroscopy is the visual examination of the interior of the stomach. This report may also contain examination findings as the scope is passed through the esophagus as in Example F4. Abstract what you think is pertinent in this example and compare with the suggested abstraction on page 139.



EXAMPLE F4

GASTROINTESTINAL DIAGNOSTIC REPORT

Hosp. No. 000022                      Name George E. McJoin                      Service ENT  
Age 74                      Race White                      Sex Male                      Date 3/4/91  
Medication None

CLINICAL:                      Elderly male with epigastric distress, wt. loss 50 lb.

X-RAY:                      Filling defect fundus - stomach

ESOPHAGOGASTROSCOPY REPORT:

Esophagoscope was passed with ease to the GE junction. At that point the lumen narrowed and prevented entrance of the scope into the stomach. The mucosa in the distal esophagus is erythematous, and white patches measuring 2-3 mm were noted.

BIOPSY:                      Two mucosal biopsies taken

IMPRESSION:                      Obstruction of distal esophagus. Etiology undetermined.  
Prob. carcinoma of fundus of stomach.  
R/O benign tumor.

RECOMMENDATION:

Louis Stewells, MD



The information described in Example F4 is abstracted as follows:

Example F4: 3/4/91. Esophagogastroscopy: Mucosa in distal esophagus erythematous; obstruction of distal esophagus. Imp: Prob. Carcinoma of fundus of stomach. Two Bx's taken.

**Comments:**

- a. To conserve space, it is permissible to combine portions of description with impression.

It is not necessary to record full statement on report--"scope was passed with ease to gastroesophageal (GE) junction. At that point lumen narrowed and prevented entrance of scope into the stomach."

- b. Lumen means channel.
- c. The report describes the *mucosa* (mucous membrane or lining) of the esophagus.

The general instructions for abstracting this report are as follows:

1. Record date and procedure.
2. Record pertinent findings.
3. Record impressions of cancer, if given.
4. Record that biopsies were taken, locate the pathology report, and record the pertinent findings.

## PRACTICAL EXERCISE

On the following pages are eight endoscopic reports (Examples F5-F12). Abstract each report as it might appear on the cancer registry abstract, then compare with abstractions on pages 157-159.





EXAMPLE F5

SIGMOIDOSCOPY REPORT

Rec. No. 000023

Name Lil Massey

Age 70

Sex Female

Race White

Date 2/12/91

Chief Complaint Recent change in bowel habits - alternating constipation and diarrhea

Referred by Uriah Hurtt, MD

Previous Sigmoidoscopy: Date None Findings \_\_\_\_\_

Previous Rectal Surgery: None

HISTORY:

- |                                       |  |
|---------------------------------------|--|
| 1. Blood per rectum <u>None noted</u> | 7. Protrusion <u>None</u>                    |
| 2. Abdominal colic <u>None</u>        | 8. Change in bowel habits <u>Alternating</u> |
| 3. Appetite <u>Recent loss</u>        | 9. Draining fistula _____                    |
| 4. Abscess _____                      | 10. Rectal pain _____                        |
| 5. Itching _____                      | 11. Fever _____                              |
| 6. Weight Loss <u>5 lb.</u>           | 12. Constipation <u>See 8 above</u>          |
13. Diarrhea: X Duration \_\_\_\_\_ Constant \_\_\_\_\_ Periodic X No. of Stools \_\_\_\_\_  
Blood None noted Mucus \_\_\_\_\_ Cramps \_\_\_\_\_
14. Laboratory: Frei \_\_\_\_\_ Serology \_\_\_\_\_ Ova & Parasites \_\_\_\_\_

SIGMOIDOSCOPY:

Distance Scoped: 25 cm Interference: 0

Mucosa: Normal X Red \_\_\_\_\_ Edematous \_\_\_\_\_ Friable \_\_\_\_\_

Ulcerated \_\_\_\_\_ Vascular Pattern \_\_\_\_\_ Mucus \_\_\_\_\_

Pus \_\_\_\_\_ Blood \_\_\_\_\_ Granular \_\_\_\_\_ Glistening \_\_\_\_\_

DESCRIPTION OF OTHER PATHOLOGY AND REMARKS:

Rectal - Large, firm, fungating mass on ant, (L) and post. wall of rectum  
Anoscopy - Same. No ulcerations. Bx's taken.  
Sigmoidoscopy - Fungating, lobulated mass from anal verge to 10 cm on ant, (L) and post. rectal wall. No other lesions seen.

Examined by: Willa Prospect, MD



EXAMPLE F6

PROCTOSCOPY REPORT

Rec. No. 000024

Name Rollo Round

Age 56

Sex Male Race White

Date 2/8/91

Chief Complaint Urgency

Referred by Casey Good, MD

Previous Proctoscopy: Date None Findings \_\_\_\_\_

Previous Rectal Surgery: None

HISTORY:

- |   |  |
|---|--|
| 1. Blood per rectum <u>Occasionally</u> | 7. Protrusion _____  |
| 2. Abdominal colic _____                | 8. Change in bowel habits<br><u>Decreasing caliber of stools</u> |
| 3. Appetite <u>Recent loss</u>          | 9. Draining fistula _____  |
| 4. Abscess _____                        | 10. Rectal pain <u>Urgency</u>                                   |
| 5. Itching _____                        | 11. Fever _____  |
| 6. Weight loss <u>10 lb.</u>            | 12. Constipation _____   |

13. Diarrhea: \_\_\_\_\_ Duration \_\_\_\_\_ Constant \_\_\_\_\_ Periodic \_\_\_\_\_ No. of stools 3-4/day  
Blood \_\_\_\_\_ Mucus X Cramps \_\_\_\_\_
14. Laboratory: Frei \_\_\_\_\_ Serology \_\_\_\_\_ Ova & Parasites \_\_\_\_\_

PROCTOSCOPY:

Distance Scoped: \_\_\_\_\_ Interference X

Mucosa: Normal \_\_\_\_\_ Red \_\_\_\_\_ Edematous \_\_\_\_\_ Friable \_\_\_\_\_

Ulcerated \_\_\_\_\_ Vascular Pattern \_\_\_\_\_ Mucus \_\_\_\_\_

Pus \_\_\_\_\_ Blood \_\_\_\_\_ Granular \_\_\_\_\_ Glistening \_\_\_\_\_

DESCRIPTION OF OTHER PATHOLOGY AND REMARKS:

Procto exam unsatisfactory due to lack of prep. Digital rectal reveals 8-10 cm fungating posterolateral (L) lesion. Multiple biopsies taken through anoscope. Melanotic stool was noted to come from above the lesion.

IMPRESSION: Carcinoma of rectum, R/O more proximal lesion.

Examined by: Adam Oma, MD



EXAMPLE F7

GASTROSCOPIC REPORT

Hospital No. 000025                      Ward/Clinic E606                      Date 1/8/91

Name Eva Eton                      Age 62    Race White                      Sex Female

DIAGNOSIS R/O Carcinoma of stomach

Brief G.I. History Bloat, loss of appetite and epigastric discomfort

Pertinent Physical Findings Loss of weight - 10 lbs.

Gastric Analysis.    Total \_\_\_\_\_    Free \_\_\_\_\_    Histamine \_\_\_\_\_

Stool Examination \_\_\_\_\_    Blood Count \_\_\_\_\_

SUMMARY G.I. X-RAYS:    Two-35 mm pictures taken with esophagoscope camera

GASTROSCOPIC FINDINGS:

The fiberoptic gastroscope was passed into the stomach with ease. There is a fungating mass constricting the antrum. There are hemorrhagic and necrotic areas in the mass. The esophagoscope (flexible fiberoptic scope) was also placed in the stomach and a small Bx of the mass was obtained. A small shallow transverse laceration of the esophagus was incidentally noted.

IMPRESSION: Prob. adenocarcinoma of the stomach

C. A. Pendergast, M.D.



EXAMPLE F8

GASTROSCOPIC REPORT

Hospital No. 000026      Ward/Clinic Surgery      Date 2/26/91

Name Selden McGlutton      Age: 56      Race: White      Sex: Female

DIAGNOSIS: Obstruction due to old ulcer disease or malignancy

BRIEF G. I. HISTORY: Loss of appetite, bloating and occasional bouts of vomiting of retained food

PERTINENT PHYSICAL FINDINGS: Epigastric mass

GASTRIC ANALYSIS: Total \_\_\_\_\_ Free \_\_\_\_\_ Histamine \_\_\_\_\_

Stool Examination \_\_\_\_\_ Blood Count \_\_\_\_\_

SUMMARY G.I. X-RAYS:

GASTROSCOPIC FINDINGS:

Gastroscope was passed into the stomach without difficulty. The antrum was identified and observed constricted by an extrinsic mass lesion.

No intrinsic mucosal lesions were seen but the entire antrum could not be seen because of the degree of constriction.

There was no peristalsis seen to move into the area of constriction. Because of a large amount of retained secretions, adequate visualization of the remainder of the stomach was not attempted.

IMPRESSION: Malignant disease involving the antrum - constricting the antrum.

Adrian Maison, MD





EXAMPLE F9

BRONCHOSCOPY REPORT

Hospital No. 000027 Name Sophie Carina Service ENT

Sex Female Age 61 Race White Date of Operation 10/1/91

Clinical Diagnosis Esophageal Carcinoma

Procedure Esophagoscopy and Bronchoscopy Anesthetic 4% Xyloc

Larynx: Normal, V/C OK

Pharynx: Normal

Trachea: Extensive fungating encircling neoplastic-appearing tissue predom. on (L), invol. distal 1/4 of trach. down to and incl. trach. @ level of carina. Carina massively widened and fixed but no ulcerative tissue noted. Orifices of both MSB markedly narrowed due to wide fixed carina. Both proximal MSB fiery red and prob. involved in some neoplastic process in distal trachea, esp. on left. Adequate view of both bronchial trees not possible.

Right Bronchus:

Left Bronchus:

Esophagus: Esophagus normal down to 21 cm from the upper ant. alveolar ridge where circumferential necrotic hard mass with irregular eccentric lumen seen along with small tongue of edematous tissue post. and somewhat to (R). Scope would not pass through lesion, but Bx forceps were slipped by lesion 2.9 cm distal to edge of lesion.

1. Bx carina & (L) trach. wall
2. Trach. wash.
3. Bx esoph. lesion

Diagnosis: Impression Carcinoma of the esoph with involv. of trachea

Remarks:

Endoscopist Morris de Bronchi, MD

Assistant Wright Hand, MD



EXAMPLE F10

BRONCHOSCOPY REPORT

Hospital No. 000028 Name Essie Phagus Service ENT

Sex Female Age 49 Race White Date of Operation 5/5/91

Clinical Diagnosis Carcinoma of the lung

Procedure Bronchoscopy Anesthetic General

Larynx: Vocal cords move normally

Pharynx: WNL

Trachea: Normal  
Carina also normal

Right Bronchus: (R) main stem bronchus partially occluded by mucus & heaped up friable tissue. RUL bronchus completely occluded with granular tissue. Right bronchus intermedius almost completely occluded with mucus and tissue.

Left Bronchus: WNL except for slightly reddened mucosa in left main stem bronchus

Esophagus:

Diagnosis: Bronchogenic carcinoma: tumor involving RUL and right bronchus intermedius

Remarks: Fiberoptic bronchoscopy performed via transnasal approach. RUL bronchus - Bx taken x 3.

Endoscopist S. C. Opey, MD Assistant I. C. Tou, MD



EXAMPLE F11

BRONCHOSCOPY REPORT

Hospital No. 000029 Name Minnie Mumm Service ENT

Sex Female Age 48 Race White Date of Operation 6/10/91

Clinical Diagnosis Carcinoma of the esophagus

Procedure Esophagoscopy Anesthetic \_\_\_\_\_

Larynx: Normal

Pharynx: Normal

Trachea:

Right Bronchus: Not visualized

Left Bronchus: Not visualized

Esophagus: Carcinoma of the esophagus at 18 cm. Biopsy taken.

Diagnosis: Carcinoma of the esophagus

Remarks:

Endoscopist A. H. Access, MD

Assistant Rich Shaw, MD



EXAMPLE F12

BRONCHOSCOPY REPORT

Hospital No. 000038 Name Easop Bronchi Service ENT

Sex Male Age 61 Race Black Date of Operation 11/18/91

Clinical Diagnosis Carcinoma of the esophagus

Procedure Esophagoscopy and Bronchoscopy Anesthetic 4% Cocaine

Larynx: Normal

Pharynx: Normal

Trachea: Normal. Carina normal

Right Bronchus: Neg.

Left Bronchus: No invasion of left main bronchus.

Esophagus: At 27 cm a constricting friable area. Bx taken.

Diagnosis: Carcinoma of the esophagus

Remarks:

Endoscopist Rob. A. Little, MD

Assistant Shannon A. Lite, MD





## PRACTICAL EXERCISE ANSWERS

These endoscopic examinations may be abstracted as follows:

Example F5: 2/12/91. Sigmoidoscopy: Mass from anal verge to 10 cm on ant, (L) and post rectal wall. Bx's taken.

**Comment:** Length of mass is 10 cm; verge means "edge." The sigmoidoscope was passed to 25 cm.

Example F6: 2/8/91. Proctoscopy: Unsatisfactory. Digital rectal reveals 8-10 cm lesion. Carcinoma of rectum, R/O more proximal lesion. Multiple Bx's taken.

**Comment:** Reference made to "digital" to indicate a finger examination was done. Melanotic stool suggests bleeding from a source some place beyond that noted in the report.

Example F7: 1/8/91. Gastroscopy: Mass constricting antrum. Bx taken. Probably adenocarcinoma of the stomach.

**Comment:** The information on the hemorrhagic and necrotic areas is not necessary for cancer registry abstracting.

Example F8: 2/26/91. Gastroscopy: Antrum constricted by an extrinsic mass lesion. No intrinsic mucosal lesions seen. Imp: Malignant disease involving antrum.

**Comments:**

- a. Intrinsic means situated entirely within or pertaining exclusively to a part, in this case the lining of the stomach.
- b. Extrinsic means situated on the outside; coming from or originating outside; having relation to parts outside the organ in which found.

Example F9: 10/1/91. Bronchoscopy: Encircling neoplastic-appearing tissue involving distal 1/4 of trachea down to carina. Carina massively widened and fixed. Both proximal MSB probably involved.

10/1/91. Esophagoscopy: Circumferential mass in esophagus at 21 cm. Multiple Bx's, tracheal washings. Imp: Carcinoma of esophagus involving trachea.

**Comments:**

- a. The essential problem in abstracting this report is to properly select and combine the important points in the description. You need a statement describing something about both the esophagus and the trachea. Also, probable involvement of the bronchi should be mentioned. Then, you should try to describe the location of the tumor. The tumor in the trachea involves the distal 1/4 of trachea. The esophageal lesion is at 21 cm.
- b. V.C. means vocal cords; MSB means main stem bronchus. In the space titled "Procedure" the M.D. has written "Esophagoscopy and Bronchoscopy" to indicate that two procedures were done. You will also frequently encounter abbreviations such as (L) for left and ant. for anterior.
- c. Measurements are routinely made from incisors (upper anterior alveolar ridge). It is not necessary to abstract this information.
- d. "Tracheal washings" alerts the abstractor to look for a cytology report.

**Example F10: 5/5/91. Bronchoscopy:** Pharynx, V/C, trachea, carina and left bronchus--normal. RUL bronchus and (R) bronchus intermedius occluded. Bx's taken. Imp: Carcinoma involving RUL and (R) bronchus intermedius.

**Comments:**

- a. From the information on this report, you know that a pathology report should exist describing the three biopsies.
- b. Friable means easily pulverized or crumbled.
- c. RUL means right upper lobe; WNL means within normal limits.

**Example F11: 6/10/91. Esophagoscopy:** Larynx and pharynx normal. Carcinoma of esophagus at 18 cm. Bx taken.

**Comments:**

- a. Not much that you can abstract from this report, but it does confirm the diagnosis and establish the location of the lesion at 18 cm which is in the upper esophagus. You should check for the presence of a pathology report, since a biopsy was taken.
- b. You will note that the esophagoscopy report appears on a bronchoscopy report form. If both procedures are required, they may be done at the same time, as in Example F12.

**Example F12: 11/18/91. Esophagoscopy and Bronchoscopy:** Constricting, friable area of esophagus at 27 cm. Bx taken. Larynx, pharynx, trachea, carina and (R) bronchus--normal. Dx: Carcinoma of esophagus.

**Comment:** In this and previous reports, the diagnostic statement is based on a clinical impression. As part of most endoscopic examinations, one or more biopsies will be taken to confirm or negate this impression.



In all of the "oscopies" described so far, the scope has been inserted through a natural opening in the body. However, in the following four types of "oscopies", an actual incision is made and the instrument is inserted into the body space that is to be examined.

- CULDOSCOPY:** Visual examination of the female pelvic viscera by means of an endoscope introduced through the posterior vaginal wall into that part of the pelvic cavity known as the rectovaginal pouch or cul de sac
- LAPAROSCOPY:** Examination of intra-abdominal structures by means of an illuminated tubular instrument (laparoscope) inserted through a small incision in the abdominal wall
- MEDIASTINOSCOPY:** Examination of the mediastinum by means of a tubular instrument permitting direct inspection of the area between the lungs
- PERITONEOSCOPY:** Examination of the peritoneal cavity by an instrument inserted through the abdominal wall (See also laparoscopy)
- THORACOSCOPY:** Direct examination of the pleural cavity by means of an endoscope which is inserted into the cavity through an intercostal space

An example of a mediastinoscopy follows on the next page (Example F13). Abstract what you think is pertinent, then check with the suggested abstraction on page 165.



EXAMPLE F13

OPERATIVE REPORT

Name: Abner Hodges Service: Surgery Hospital No.: 000031

Sex: Male Age: 40 Race: White Ward: W505 Date: 10/21/91

Surgeon: Dick Dixon, MD Assistant: Jim Jackson, MD Anesthetist: R. Bop, MD

Name of Operation: Mediastinoscopy, sternal puncture biopsy

Pre-Operative Diagnosis: \_\_\_\_\_

Post-Operative Diagnosis: Probable Hodgkin's Disease or lymphoma

Operation Started: 8:30 am Operation Ended: 9:50 am

PROCEDURE IN DETAIL:

The patient was anesthetized without complication. A nasotracheal tube was placed. The patient was prepped from the nipples to the chin region. A small lateral incision was placed just above the jugular notch. Dissection was carried down to the trachea. The peritracheal fascia was found to be fibrotic and adherent around the trachea, and it was impossible to burrow the mediastinoscope into this region. An approximately 2 x 3 cm firm, somewhat hard grayish lymph node was discovered in the pretracheal region, and excisional biopsies were taken of this node and sent for culture for fungus, tuberculosis, and for pathologic report. Good hemostasis was obtained. The patient was then closed using #3 nylon for the skin sutures. It was decided because of the presumption of good diagnostic material in the lymph node that bronchoscopy should not be attempted at this time. It was also felt that bronchoscopy could add significantly to the morbidity of the procedure, and the procedure was discontinued at this time. Before the patient was aroused from anesthesia a sternal bone marrow tap was done with good aspiration and no complications. Post-operative diagnosis: Probable Hodgkin's disease or lymphoma. Estimated blood loss between 250 and 300 cc. Complications--None.

Dictated: 10/21/91

Date transcribed: 10/26/91





This operative report may be abstracted as follows:

**Example F13:** 10/21/91. Mediastinoscopy: Scope could not be passed into the mediastinum.  
A 2 x 3 cm firm paratracheal lymph node --  
Excisional Bx's taken.  
Sternal bone marrow aspiration taken.  
Dx: Prob. Hodgkin's disease or lymphoma.

**Comment:** Check reports of biopsies of lymph node and bone marrow aspiration.



## OPERATIVE PROCEDURES

### Exploratory Surgery

Sometimes, cancer of an internal organ may be suspected but the organ may be so located that direct access to it is possible only with surgery. Exploratory surgery may then be performed to determine whether or not a cancerous condition exists and the degree to which the cancer may have affected other organs and structures within the observed area. In most instances, biopsies will be performed and the material examined histologically.

The exploratory operation may be followed immediately by definitive surgery, or it may reveal cancer so extensive as to rule out definitive surgery. It may be that by-pass<sup>1</sup> surgery is indicated as a palliative measure. All surgery, whether it is definitive, exploratory, or by-pass surgery, is described in an operative report.

---

<sup>1</sup>by-pass--Surgical formation of a passage (anastomosis) between any two normally distinct spaces or organs. For example, a shunt to divert blood from one part of the body to the other is a by-pass. A colostomy to short circuit the GI tract, when there is an obstruction of the colon, is a by-pass.



EXAMPLE F14

OPERATIVE REPORT

Service Gen. Surg Ward      Name Hugh Gutzman Hosp. No. 000032

Sex Male Age 87 Race Black Date of Operation 9/27/91

Surgeon Polk N. See, MD Assistant A. Helpp, MD

Anesthesiologist Al Quiet, MD

Name of Operation Exploratory Laparotomy

Pre-Operative Diagnosis Bleeding Stomach Cancer

Post-Operative Diagnosis Inoperable Stomach Cancer

Operation started 11:52 am Operation ended 12:30 pm

OPERATIVE PROCEDURE: Exploratory laparotomy

PROCEDURE IN DETAIL:

With the patient supine and under endotracheal anesthesia, the entire abdomen and lower chest was prepped with pHisoHex and saline and draped with sterile sheets in the usual manner. Through an upper midline incision the peritoneal cavity was entered. Exploration revealed a huge mass posterior to the 7th rib which was penetrating the stomach, apparently causing the bleeding. This mass measured about 7 inches in diameter. It was fixed in the retroperitoneal space and to the posterior part of the stomach. It also ascended into the liver, and there were multiple liver metastases and multiple peritoneal metastases. A node from the greater omentum was biopsied; frozen section reported a highly anaplastic malignancy. The patient was inoperable. Through the gastrohepatic ligament the mass was further exposed and two sutures of 2-0 chromic were placed in the mass, and a small wedge biopsy was performed. The tumor was bleeding, and several sutures of 2-0 chromic atraumatic and a piece of Surgicel<sup>1</sup> was inserted; the bleeding controlled. The patient was poorly prepared pre-operatively, and his condition has not changed.

Date dictated 9/27/91

Date transcribed 10/1/91

<sup>1</sup>Surgicel--Hemostatic agent



The operative record used as an illustration should be summarized as follows:

**Example F14: 9/27/91. Expl. Lap.: Huge mass posterior to 7th rib penetrating stomach, 7 in. in diameter, fixed in retroperitoneal space and to posterior stomach, ascending into liver with multiple liver and peritoneal metastases. Node from the greater omentum was biopsied (frozen section reported as highly anaplastic and malignant). Wedge Bx of mass. Post-op Dx: Inoperable Carcinoma of stomach.**

**Comments:** The following points should be noted with respect to the above summary:

- a. Emphasis is placed on summarizing various locations of tumor to indicate the extent of the disease.
- b. Operative procedures are not summarized, but the name of the procedure is recorded, i.e., exploratory laparotomy.
- c. Size of lesion or mass is recorded, if given.
- d. Note that frozen section of biopsied node from greater omentum indicated a highly anaplastic malignancy.

Study the record for F15 and then abstract what you think is pertinent.





EXAMPLE F15

OPERATIVE REPORT

Service Surgery Ward W-405 Sex Male Age 74 Race Black Date 3/11/91

Surgeon Abel Cutter, MD Assistant Stan McWait, MD Anesthetist A. Snooz, RN

Name of Operation: Exploratory Laparotomy

Pre-Operative Diagnosis: Carcinoma of the Stomach

Post-Operative Diagnosis: Carcinoma of the Stomach

Operation Started 7:05 am

Operation ended 8:40 am

OPERATIVE FINDINGS

CLINICAL HISTORY:

This 74-year-old black male was admitted to the General Surgery Service for a thorough G.I. work-up carried out because of a history of 60 lb. weight loss during the past eight months. GI Series demonstrated a large space-occupying lesion in the fundus of the stomach.

Chest films, liver scan, and further diagnostic studies did not indicate metastatic spread. Therefore, it was elected to explore this patient; on 3/11/91, he was taken to the operating room.

PROCEDURE IN DETAIL:

Under adequate endotracheal anesthesia, the abdomen was prepped with pHisoHex and Betadine and draped for an upper midline incision. A small upper midline incision was made to explore the abdomen. The peritoneum was entered. Manual exploration demonstrated a large, hard, fixed mass on the posterior wall of the fundus of the stomach invading the spleen. There were numerous nodes along the lesser curvature of the stomach. There were some tumor studdings in the left lobe of the liver. A node was selected for biopsy, and a small wedge of this node was removed. The midline was then closed with interrupted figure-eight suture of 0-stainless steel wire; retention sutures were utilized to close the same. The skin was closed with 3-0-black silk and no blood was administered during the surgical procedure. The patient tolerated the procedure well.

Date dictated 3/11/91

Date transcribed 3/13/91

Patient Name Whatt U. Eton

Record Number 000033



**Example F15:** 3/11/91. Expl. Lap.: Large, fixed mass on posterior wall of fundus of stomach invading the spleen. Numerous nodes along lesser curvature of stomach. Some tumor studdings in left lobe of liver. Node was Bx'ed. Post-op dx: Carcinoma of the stomach.

**Comments:** The following points should be noted with respect to the operative record used in this illustration.

- a. A clinical history is presented. Sometimes this is not present. When it is, it can be very useful. For example, this clinical history indicates that the patient was admitted with symptoms possibly related to cancer--60 lb. weight loss in 8 months.
- b. The clinical history indicates that one or more reports of a GI series should be present in the medical record. They should report a lesion in the fundus of the stomach.
- c. Other diagnostic reports mentioned in the clinical history include chest films and liver scan which did not indicate metastatic spread.
- d. The location of the primary site on the posterior wall of the fundus of the stomach is described.
- e. According to the surgeon, the mass was invading the spleen and was metastatic to the liver. It appeared to involve nodes along the lesser curvature of the stomach. This indicates that the mass had extended beyond its primary site.



## PRACTICAL EXERCISE

The following pages contain two operative records (Examples F16 and F17). Would you summarize the pertinent findings of each of these records?

For Example F16, please answer the following questions:

1. Were "bilateral pulmonary metastases" observed at the time of surgery?
2. Do you need to report the observation of "ureter markedly dilated and had bluish appearance?"
3. Should any of the findings described on this record be reported?
4. Would you expect a post-operative pathology report to accompany this operative record?

(Answers to the questions are found on page 183.)



EXAMPLE F16

OPERATIVE REPORT

Service GU Ward Sex Female Age 61 Race Black Date 12/15/91

Surgeon A. Tieoff, MD Assistant A. Sist, MD Anesthesiologist Q. Tee, MD

Name of Operation Exploratory lap with ligation of R ureter

Pre-Operative Diagnosis Adenocarcinoma R kidney with hematuria

Post-Operative Diagnosis Adenocarcinoma R kidney with severe hemorrhage

Operation Started 11:15 am Operation ended 11:42 am

**CLINICAL HISTORY:** This 61-year-old black female was admitted to Urology with severe bladder hemorrhage. Physical examination revealed a right flank mass. On IVP the patient had poor to no function. At cystoscopy the patient had a large dilated orifice on the right side with blood gushing through. The patient required 5 units of blood to replace blood loss prior to this (her hematocrit was only 21%). Also pre-operative evaluation revealed the patient had what appeared to be bilateral pulmonary metastases from a hypernephroma and possible metastasis to the right hip. Because of the patient's blood requirements, it was felt that ligation of the ureter might help to tamponade the bleeding.

**OPERATIVE FINDINGS:** Removal of the tumor was impossible because of its size with probable fixation to the diaphragm and great vessels.

**PROCEDURE IN DETAIL:** The patient was placed in the supine position, the sand-bag was placed under the right flank, the skin was prepped with ether and betadine and sterile drapes were applied in the usual manner. A transverse incision was made extending from the lateral border of the rectus muscle to the anterior superior iliac spine with the combination of sharp and blunt dissection. The muscles were divided, split, and the retroperitoneal space opened at the anterior-superior iliac spine level. Bowel contents were retracted posteriorly.

The peritoneum was not opened and the ureter was identified as it crossed the pelvic brim. It was markedly dilated and had a bluish appearance. The ureter was ligated with zero-silk at 2 levels.

The patient tolerated the procedure well. A small drain was left in the area of dissection. The muscles were approximated with interrupted zero-chromic, the subcutaneous tissue with 2-0 plain, and the skin was closed with 3-0 silk.

Date dictated 12/15/91

Date transcribed 12/16/91

Patient Name Tessie Sicksack

Record Number 000034





EXAMPLE F17

OPERATIVE REPORT

Service Surgery Ward \_\_\_ Sex Female Age 62 Race Black Date 1/15/91

Surgeon Z. Alterman, MD Assistant R. Hand, MD Anesthesiologist Bo Peep, MD

Name of Operation Abd. Expl. - Distal gastrectomy - Gastroduodenostomy

Anesthesia General

Pre-Operative Diagnosis Carcinoma of the stomach

Post-Operative Diagnosis Carcinoma of the stomach with metastasis to liver

Operation Started 11:15 am Operation ended 1:55 pm

Patient Name Ann Trum Record Number 000035

CLINICAL HISTORY:

This 62-year-old black female had been worked up on Medicine for masses in the epigastrium. A liver scan revealed multiple filling defects and an upper GI series revealed an antral lesion which was obstructing the fundus of the stomach.

OPERATIVE FINDINGS:

Under a general anesthesia, with the patient in the supine position, the abdomen was prepped and draped in the usual fashion. An upper midline incision was made and the peritoneal cavity entered. Generalized abdominal exploration revealed multiple large nodules within the substance of both lobes of the liver and a large ulcerating lesion in the area of the antrum of the stomach. Multiple nodes along the lesser and greater curvature of the stomach and the subpyloric area were positive clinically for tumor. The stomach was not adherent to the pancreas or any other structures, therefore, a distal gastrectomy was undertaken. The greater and lesser curvatures of the stomach were freed up as was the duodenum, and Payr clamps were placed along the distal stomach just beyond the pylorus, and the distal stump was amputated.

Continued on next page

EXAMPLE F17 (continued)

PROCEDURE CONTINUED:

This was reflected up and the left gastric arteries were ligated. The stomach was then transected in the usual fashion and the greater curvature tapered using a 2-0 chromic and an inverting suture of 2-0 silk. The distal lumen was free of tumor and this was then anastomosed in 2-layer fashion to the proximal duodenum using an inner running suture of 3-0 chromic and an outer interrupted of 3-0 silk. Estimated blood loss during the procedure was approximately 300 cc's. The sponge counts at the conclusion of the procedure were correct.

The abdomen was closed with nylon retentions and midline sutures of zero-silk. The skin was closed with interrupted 4-0 silk. The patient tolerated the procedure well, however, a period of Cheyne-Stokes respiration followed the conclusion of the case and the endotracheal tube was allowed to remain in, and the patient was placed on a Byrd Respirator in the recovery room. Other than this, the case went smoothly and the patient did well.

Surgeon Z. Alterman, MD

Date 1/15/91

Date dictated 1/15/91

Date transcribed 1/18/91

Patient Name Ann Trum

Record Number 000035

These operative reports can be abstracted as follows:

Example F16: 12/15/91.      Expl. Laparotomy: Ligation of (R) ureter to control bleeding; removal of tumor impossible because of size and probable fixation to the diaphragm and the great vessels.      Dx: Carcinoma of (R) kidney.

#### ANSWERS TO QUESTIONS:

1. No. This condition was discovered as part of the pre-operative evaluation.
2. No. This observation is not directly related to the malignancy.
3. Yes. The operative record contains information regarding why the tumor was not removed. This is useful information and should be recorded. This operation was performed to correct another condition secondary to the malignant condition (the ureter was tied to cause blood to back up and clot, thus, preventing further bleeding). This report is also of interest because it describes the extent of disease.
4. No. There is no mention of removal of tissue.

Example F17: 1/15/91.      Abd. exploratory distal gastrectomy, gastro-duodenostomy:      Multiple nodules in both lobes of liver, large ulcerating lesion antrum of stomach, multiple nodes along lesser and greater curvatures of stomach, and subpyloric area clinically positive for tumor.      Dx: Carcinoma of stomach with metastases to liver.

#### PRACTICAL EXERCISE

An example of a two-stage operation for breast cancer is illustrated in Examples F18A and B. This patient had an excision of a breast tumor during the first procedure and was returned to surgery for a mastectomy two days later. The findings from the operative reports of both procedures should be recorded on the abstract. Abstract what you think is pertinent, then check with the suggested abstraction on page 189.



EXAMPLE F18A

OPERATIVE REPORT

Name Melanie Black

Hosp. No. 000036

Address \_\_\_\_\_

Clinic or Floor Surgery

Date 9/27/91

Race White

Age 27

Sex Female

Surgeon Rex Glover, MD

Assistant Henry Backas, MD

Time Operation Started 11:52 am

Ended 12:30 pm

Preoperative Diagnosis Right breast tumor

Operative Diagnosis Doubtful malig. of R breast tumor

Operation Performed Excision of R breast tumor

PROCEDURE IN DETAIL: The tumor of the right breast just to the right of the nipple was excised and sent to the laboratory for frozen section. The incision was closed. First report on frozen section was equivocal; will await results of paraffin section.

Sponge Count \_\_\_\_\_

Drains \_\_\_\_\_

Dictated by Rex Glover, MD

Surgeon Rex Glover, MD



EXAMPLE F18B

OPERATIVE REPORT

Name Melanie Black

Hosp. No. 000036

Address \_\_\_\_\_

Clinic or Floor Surgery

Date 9/29/91

Race White

Age 27

Sex Female

Surgeon Rex Glover, MD

Assistant Henry Backas, MD

Time Operation Started 11:52 am

Ended 3:37 pm

Preoperative Diagnosis Carcinoma R Breast

Operative Diagnosis No residual disease

Operation Performed Right radical mastectomy

PROCEDURE IN DETAIL:

A biopsy of the tumor of the right breast just to the right of the nipple had been performed 2 days previously. The tissue on permanent section was reported as grade 2 adenocarcinoma.

A Halsted type incision was so placed in the skin 2 inches distal to the biopsy scar, and a classical radical mastectomy was performed. The pectoralis major and minor were first divided at their attachments. The axilla was dissected free and the sternal and lateral attachments were divided as the last step. No glands of a suspicious nature were encountered during the dissection. The long thoracic and thoraco nerves were left intact. No glands were present in the supraclavicular area. The wound was closed without drainage. Considerable attention paid in the middle third of the wound because of the large amount of skin removed.

Sponge Count \_\_\_\_\_

Drains \_\_\_\_\_

Dictated by Rex Glover, MD

Surgeon Rex Glover, MD





**Example F18 can be abstracted as follows:**

**Example F18A: 9/27/91. Right breast tumor: Tumor located just to the right of the nipple. Dx: Equivocal malignancy (frozen section). Final Dx (permanent section): Grade 2 adenocarcinoma.**

**Example F18B: 9/29/91. (R) radical mastectomy: No suspicious glands in axilla or supraclavicular area. No residual disease.**

**Comments:**

- a. A classical radical mastectomy or Halsted radical mastectomy involves the removal of the breast, the pectoral muscles, axillary lymph nodes, and associated skin and subcutaneous tissue.
- b. Histopathologic findings of a grade 2 adenocarcinoma will appear on a pathology report. These forms will be described in Section G.
- c. The glands in the axilla and supraclavicular areas are another way of describing lymph nodes.



**SECTION G**  
**PATHOLOGICAL EXAMINATIONS**



## SECTION G

### PATHOLOGICAL EXAMINATIONS

The most accurate methods for diagnosing cancer are: 1) the microscopic examination of tissues removed from the site of a suspected cancer and 2) the microscopic examination of cells contained in fluid which bathes a suspected site. The purpose of the microscopic examination is to determine characteristics of the tissues and cells indicative of a malignancy. Histologic examination (study of tissue) will be discussed beginning on page 194. The histologic information is found on the Pathology Report, sometimes called the Histopathology Report. Cytologic examination (study of cells) will be discussed beginning on page 241. The cytologic information is usually found on a Cytology Report, sometimes called a Cytopathology report, but it may be submitted on a Pathology Report (See Example G15).

Both the operative reports and the pathologic reports should be reviewed by the cancer registry abstractor. The operative report may contain information on spread of disease to tissues which were not excised, for example, liver metastasis may be observed by the surgeon at the time of abdominal surgery, and a biopsy may not be taken. The surgeon may also describe the size of the tumor as well as apparent metastases to lymph nodes and other organs. It is important that this information be abstracted for a complete and accurate description of the extent of disease. If there is a discrepancy between the operative report and the pathology report with respect to involvement of excised tissues, the pathology report takes precedence over the operative report.

## HISTOLOGIC EXAMINATION

For most neoplasms histologic examination (study of tissue) provides the best evidence regarding the presence or absence of cancer. Sometimes there will be more than one pathology report in the record. Summarize each report giving the name and date of the procedure, the slide number(s), the source of the specimen, and the pertinent positive and/or negative findings. A histologic examination may be made from a biopsy specimen, a surgical specimen, or at autopsy. Each of these procedures will be described in this section of the manual together with practical exercises demonstrating how the information given in the reports might be abstracted. The study of cells (cytologic examination) will be covered separately beginning on page 241.

## A. *The Biopsy Report*

The term *biopsy* (Bx) refers to the removal and examination, gross and microscopic, of tissue or cells from the living body for the purpose of diagnosis. A variety of techniques exist for performing a biopsy of which the most common ones are:

*Aspiration biopsy*: Biopsy of material (fluid, cells, or tissue) obtained by suction through a needle attached to a syringe

*Bone marrow biopsy*: Examination of a piece of bone marrow by puncture or trephine (removing a circular disc of bone)

*Curettage*: Removal of growths or other material by scraping with a curette

*Excisional biopsy* (total): The removal of a growth in its entirety and having a therapeutic as well as diagnostic purpose

*Incisional biopsy*: Incomplete removal of a growth for the purpose of diagnostic study

*Needle biopsy*: Same as aspiration biopsy

*Percutaneous biopsy*: A needle biopsy with the needle going through the skin

*Punch biopsy*: Biopsy of material obtained from the body tissue by a punch technique

*Sponge (gel foam) biopsy*: Removal of material (cells, particles of tissue, and tissue juices) by rubbing a sponge over a lesion or over a mucous membrane for examination

*Surface biopsy*: Scraping of cells from surface epithelium, especially from the cervix, for microscopic examination

*Surgical biopsy*: Removal of tissue from the body by surgical excision for examination

*Total biopsy*: See excisional biopsy

**Note:** Any biopsy can be processed quickly by a frozen section technique or by routine fixation (permanent section) by H and E (Hematoxylin and Eosin) stain which usually takes 48 hours to prepare.

An example of a biopsy report appears on the next page (Example G1). Abstract what you think is pertinent, and then compare with the suggested abstraction on page 199.





EXAMPLE G1

DEPARTMENT OF PATHOLOGY

Name Sammy Kidd Hospital No. 000037

Sex Male Age 56 Race White Clinical Diagnosis Carcinoma of Bladder

Address: \_\_\_\_\_ Path. No. S91-1017

Clinic or Floor Surgery Date 3/31/91

Pathologic Diagnosis Papillary transitional cell carcinoma, GR III

Operation Multiple biopsies of bladder

Attending Physician O. P. Bixby, MD

GROSS: The specimen is submitted in formalin in two parts.

Part one is labeled "random bladder biopsy" and consists of two fragments of tissue each measuring approximately 1 x 1 mm.

Part two is labeled "right anterior bladder wall" and consists of multiple fragments of tissue measuring from 1 x 0.5 x 0.5 cm to 2 x 1 x 0.5 cm. This tissue is dark and appears to have a hyperplastic epithelium and underlying muscularity.

MICROSCOPIC: Sections of random bladder biopsies show mild to moderate epithelial atypia. Sections of urinary bladder labeled "right anterior bladder wall" show a papillary neoplasm with markedly atypical cells and high mitotic activity invading in solid nests into the lamina propria, but not the muscularis. Adjacent mucosa shows severe atypia.

DIAGNOSIS: Urinary bladder (biopsy) - Papillary transitional cell carcinoma, Grade III.  
Urinary bladder (random biopsies) - Mild to moderate epithelial atypia.

Ralph Abitt, MD  
Pathologist



**Example G1 can be abstracted as follows:**

**Example G1: 3/31/91.      Bx of bladder: (R) anterior bladder wall--Pap. trans. cell carcinoma, Gr III, invading into lamina propria, but not muscularis. Other Bx's: Moderate atypia.**

**Comment:      This is the pathology report for the biopsies obtained at cystoscopy in Example F3.**

B. *The Operative Pathology Report (Surgical Specimen)*

The operative pathology report of the surgical specimen contains a description of the gross and microscopic examination of the surgical specimen. This report is important for you, the cancer registrar, because it may tell you which structures and organs of the body are involved by the tumor. It verifies the primary site of the cancer and describes the extent to which it has spread.

Tumor size will usually be stated in the gross description of the surgical specimen. It is usually specified in centimeters. Always record any statement of tumor size given on the pathology report.

## Abstracting the Pathology Report

Let us now examine the following pathology reports (G2-G5). A number of important features of these reports are given below:

- a. The date of the report. This date should coincide with the date of the corresponding operative report, not the date the slides were read nor the date of dictation.
- b. A short clinical history of the patient. This information describes the reasons why the tissue was removed.
- c. In the space labeled "pre-operative diagnosis" or "clinical diagnosis" will be a brief description of the diagnosis as based on the physical examination and/or on a statement provided by a referring physician.
- d. The "gross description" of the report will contain a description of the material received for examination and will include the source of the specimen. The size of tissue fragments taken at biopsy and how they are received and the size of the surgical specimen are not important to the abstractor and should not be reported, but if the tumor size is given it should be recorded.
- e. The "microscopic description" of the report contains the pathologist's description of the specimen(s) examined. Of special significance is the total size of the tumor, and where it has extended or metastasized. Size will usually be reported in centimeters (cm), and often the length, breadth, and thickness of the tumor will be given. The abstractor need only report the largest dimension of the tumor. If there is a discrepancy between the microscopic and gross description of the excised tumor, the microscopic takes precedence.
- f. The "diagnosis" section will summarize the microscopic findings for each specimen examined. The diagnosis confirms or denies gross findings of malignancy, giving the histologic type of the cancer and, in some instances, giving the grade of the cancer (the degree to which the malignant cells have lost their normal configuration).
- g. Complete excision of the tumor may also be confirmed or denied by describing whether or not surgical margins are clear of tumor. This most often appears in the microscopic, but may be found in the final diagnosis.

**When summarizing the pathology report, record the following information:**

**The date and name of the report**

**Slide number**

**The source of the specimen**

**The primary site**

**Tumor size**

**The histologic diagnosis including the grade or degree of differentiation**

**The extent of disease within and beyond the primary site**

**Abstract what you think is pertinent in Examples G2-G5 and then compare with the suggested abstractions on pages 213-214.**

EXAMPLE G2

PATHOLOGY REPORT

Path. No. S91-210

Name Sally Sacqueski

Reg. No. 000038

Age 66

Sex Female

Race White

Location \_\_\_\_\_

Date 2/11/91

Address \_\_\_\_\_

Occupation \_\_\_\_\_

HISTORY OF CASE: Multiple TURB for Grade II TCC with microinvasion; multiple tumors

CLINICAL DIAGNOSIS: Carcinoma of bladder; R/O scalene node metastasis

POST-OPERATIVE DIAGNOSIS Carcinoma of bladder

Surgeon So Long, MD

Operation Bx of bladder & L scalene node

GROSS DESCRIPTION:

The specimen is received in two parts. They are labeled #1, "biopsy bladder tumor, " and #2, "scalene node, left."

Part #1 consists of multiple fragments of gray-brown tissue which appear slightly hemorrhagic. They are submitted in their entirety for processing.

Part #2 consists of multiple fragments of fatty yellow tissue which range in size from 0.2 to 1.0 cm in diameter. They are submitted in their entirety for processing.

MICROSCOPIC:

Section of bladder contains areas of transitional cell carcinoma. No area of invasion can be identified. A marked acute and chronic inflammatory reaction with eosinophils is noted together with some necrosis. Sections are examined at six levels.

Section of lymph node contains normal node with reactive germinal centers.

DIAGNOSIS:

1. Papillary transitional cell carcinoma, grade II, bladder, biopsy.
2. Acute and chronic inflammation, most consistent with recent biopsy procedure.
3. Scalene lymph node, left, no pathologic diagnosis.

Mike O'Seen, MD  
Pathologist





EXAMPLE G3

PATHOLOGICAL SPECIMEN REPORT

Path. No. S91-1700

Name Lilly McDermott

Reg. No. 000039

Age 47 Sex Female Race White Location \_\_\_\_\_ Service \_\_\_\_\_ Date 7/20/91

Address \_\_\_\_\_ Occupation \_\_\_\_\_

HISTORY OF CASE: 47-year-old white female with (L) UOQ breast mass

CLINICAL DIAGNOSIS: Carcinoma of breast

POST-OPERATIVE DIAGNOSIS: Same

Surgeon John Myeolmus, MD

Operation L radical mastectomy

SPECIMEN: 1. Left breast biopsy  
2. Apical axillary tissue  
3. Contents of left radical mastectomy

GROSS DESCRIPTION:

The specimen is received in three parts.

Part #1 is labeled "left breast biopsy" and is received fresh after frozen section preparation. It consists of a single very firm nodularity measuring 3 cm in circular diameter and 1.5 cm in thickness, surrounded by adherent fibrofatty tissue. On section a pale gray, slightly mottled appearance is revealed. Numerous sections are submitted for permanent processing.

Part #2 is labeled "apical left axillary tissue" and is received fresh. It consists of two amorphous fibrofatty tissue masses without grossly discernible lymph nodes therein. Both pieces are rendered into numerous sections and submitted in their entirety for histology.

Part #3 is labeled "contents of left radical mastectomy" and is received fresh. It consists of a large ellipse of skin overlying breast tissue, the ellipse measuring 20 cm in length and 14 cm in height. A freshly sutured incision extends 3 cm directly lateral from the areola, corresponding to the closure for removal of part #1. Abundant amounts of fibrofatty connective tissue surround the entire breast, and the deep aspect includes an 8 cm length of pectoralis minor and a generous mass of overlying pectoralis major muscle. Incision from the deepest aspect of the specimen beneath the tumor mass reveals tumor extension

Continued on next page

EXAMPLE G3 continued

grossly to within 0.5 cm of muscle. Sections are submitted according to the following code: DE - deep surgical resection margins; SU, LA, INF, ME -- full thickness radial samplings from the center of the tumor superiorly, laterally, inferiorly and medially, respectively; NI - nipple and subjacent tissue. Lymph nodes dissected free from axillary fibrofatty tissue from levels I, II, and III will be labeled accordingly.

**MICROSCOPIC:**

Sections of part #1 confirm frozen section diagnosis of infiltrating duct carcinoma. It is to be noted that the tumor cells show considerable pleomorphism, and mitotic figures are frequent (as many as 4 per high power field). Many foci of calcification are present within the tumor.

Part #2 consists of fibrofatty tissue and a single tiny lymph node free of disease.

Part #3 includes 18 lymph nodes, three from Level III, two from Level II and thirteen from Level I. All lymph nodes are free of disease with the exception of one Level I lymph node which contains several masses of metastatic carcinoma.

All sections taken radially from the superficial center of the resection site fail to include tumor, indicating the tumor to have originated deep within the breast parenchyma. Similarly, there is no malignancy in the nipple region, or in the lactiferous sinuses.

Sections of deep surgical margin demonstrate diffuse tumor infiltration of deep fatty tissues, however, there is no invasion of muscle. Total size of primary tumor is estimated to be 4 cm in greatest dimension.

**DIAGNOSIS:**

1. Infiltrating duct carcinoma, left breast.
2. Metastatic carcinoma, left axillary lymph node (1), Level I.
3. Lymph nodes, no pathologic diagnosis, left axilla, Level I (12), Level II (2), Level III (3).

Justin A. Glance, MD  
Pathologist

Name Lilly McDermott

Reg. No. 000039

EXAMPLE G4

DEPARTMENT OF PATHOLOGY

Path. No. S91-0100

Name Phineas Feltbad

Reg. No. 000040

Age 79 Sex Male

Race White Location \_\_\_\_\_

Service \_\_\_\_\_

Date 5/23/91

Address \_\_\_\_\_

Occupation Druggist

PREOPERATIVE DIAGNOSIS: Cancer of left floor of mouth

OPERATIVE FINDINGS: Cancer of left floor of mouth

POSTOPERATIVE DIAGNOSIS: Same

SURGICAL PATHOLOGY SECTION

GROSS:

The specimen is received in three parts, all fresh.

Part #1 which is labeled "? metastatic tumor in jugular vein lymph node" consists of an elliptical fragment of light whitish-tan tissue which measures approximately 0.3 x 0.2 x 0.2 cm. The specimen is examined by the frozen section technique, and the diagnosis is "ganglion." The remainder of part #1 of the specimen is submitted as frozen section control #1.

Part #2 is labeled "resection of floor of mouth continuous with tongue and mandible plus left radical neck dissection." As received in the frozen section room, the specimen consists of a grossly identifiable left radical neck dissection and also the entire left ascending ramus of the mandible, the posterior three-fourths of the left mandible proper, the left lateral portion of the tongue, and the submental and submaxillary salivary glands. The main lesion is identified on the left side of the floor of the mouth. There is a craterform lesion which measures approximately 1.2 x 0.5 cm in greatest dimensions. With the assistance of Dr. U. No Whoo, the specimen is properly oriented. Two areas of interest are defined. The first of these is the anterior tongue margin. The second of these is the medial tongue margin. Fragments from each of these areas are examined by the frozen section technique. The diagnosis on frozen section #2 (anterior tongue margin) is "no tumor seen" and on frozen section #3 (medial tongue margin) is "no tumor seen." Two additional areas of special interest are identified. The first of these is that portion of the left radical neck dissection which was nearest to the carotid artery. A fragment of tissue from this area is excised and submitted for sectioning labeled "CM." The second area of interest is that portion of the

Continued on next page

EXAMPLE G4 (continued)

---

left radical neck dissection which bordered upon the anterior aspect of the vertebral column. A fragment of tissue is excised from this area and submitted for sectioning labeled "VM." After having been photographed in several positions, the specimen is blocked further. A section is taken through the main tumor mass and submitted for sectioning labeled "T POST." Attention is directed to the left radical neck dissection proper. This part of the specimen is divided into the appropriate five levels. Each level is examined for lymph nodes which are dissected free and submitted in their entirety for sectioning. The remainder of the specimen is saved.

Part #3 of the specimen, labeled "anterior margin of inferior mandible" consists of an irregular fragment of fibrous connective and skeletal muscular tissues and measures approximately 1.0 x 0.5 x 0.2 cm. The specimen is submitted in its entirety for sectioning on three levels.

**MICROSCOPIC DESCRIPTION:**

Microscopic examination of frozen section control #1 confirms the original frozen section diagnosis of "ganglion."

Microscopic examination of frozen section control #2 confirms the original frozen section diagnosis of "no tumor seen."

Microscopic examination of frozen section control #3 confirms the original frozen section diagnosis of "no tumor seen."

Microscopic examination of part #2 of the specimen reveals foci of moderately well differentiated squamous cell carcinoma in the floor of the left side of the mouth. The residual tumor is surrounded by large amounts of dense fibrous connective tissue. Microscopic examination of the section labeled CM which represents the carotid margin reveals squamous cell carcinoma extending to within 0.1 cm of the surgical margin.

Microscopic examination of section labeled VM representing the vertebral margin fails to reveal evidence of tumor in this location. Microscopic examination of the tissue in level I reveals section of fibrotic and atrophic submaxillary salivary gland. There is also one lymph node in level I which is negative for metastatic tumor. Microscopic examination of the tissue in level II reveals sections of 11 lymph nodes none of which contains metastatic tumor. However, the extranodal fibrous connective tissue in level III contains numerous foci of squamous cell carcinoma. Microscopic examination of the tissue in level IV reveals sections of 6 lymph nodes, none of which contains metastatic tumor. Microscopic examination of the tissue in level V reveals 1 lymph node which is negative for metastatic tumor.

---

Name Phineas Feltbad

Reg. No. 000040

Continued on next page

EXAMPLE G4 (continued)

---

DIAGNOSIS:

1. Squamous cell carcinoma, left floor of mouth
2. Squamous cell carcinoma, in extranodal connective tissue of neck at level III
3. Nineteen cervical lymph nodes, no pathologic diagnosis

---

Largo Grossman, MD  
Pathologist

Name Phineas Feltbad

Reg. No. 000040



EXAMPLE G5

PATHOLOGICAL SPECIMEN REPORT

Path. No. S91-999

Name Marie du Malade

Reg. No. 000041

Age 47 Sex Female Race White Location \_\_\_\_\_ Service \_\_\_\_\_ Date 9/11/91

Address \_\_\_\_\_ Occupation Teacher

HISTORY OF CASE: 47-year-old while female with ten-year history of gastric ulcer

CLINICAL DIAGNOSIS: Carcinoma of stomach

Surgeon George Flatus, MD

Operation Vagotomy & subtotal gastrectomy

GROSS DESCRIPTION:

Received were three specimens: The first consisted of a portion of stomach measuring 13 x 7 x 2.5 cm. There was a portion of mesentery attached to the lesser curvature and there was a firm indurated area in the wall of the lesser curvature. The serosal surface was smooth and glistening and slightly hemorrhagic. On opening the specimen a 1 cm in diameter penetrating well-circumscribed ulcer was found in the wall of the lesser curvature. This ulcer penetrated to a depth of 1 cm. The ulcer was 3 cm from the proximal portion of the specimen and 4.5 cm from the distal portion. The edges of the ulcer were heaped up and firm, but there appeared to be no involvement of the surrounding mucosa. The rugae or folds radiate toward the center of the ulcer from the superior side, and the mucosa of the distal portion of the stomach was smooth.

The second specimen consisted of a portion of the left anterior vagus. Specimen consisted of a piece of pale gray-white, soft tissue measuring 0.8 cm in length. The entire specimen was submitted for examination.

The third specimen was labeled right posterior vagus and consisted of a piece of soft, gray-white tissue measuring 2 cm in length and 0.4 cm in diameter. Entire specimen was submitted for examination.

Continued on next page



EXAMPLE G5 (continued)

---

**MICROSCOPIC:**

Microscopically there is a ragged ulcer penetrating to within 5 mm of the serosal surface. The ulcer is surrounded by dense connective response and chronic inflammatory infiltrate. The edges are not heaped up, but several sections of the ulcer reveal malignant changes. The tumor is superficial and composed of poorly formed glands and sheets of malignant cells. The cells are pleomorphic with small amounts of eosinophilic cytoplasm. The nuclei are either pyknotic or large with prominent nucleoli and clumped chromatin. Mitoses are rare. The tumor proper does not extend below the mucosa, but a single nest of malignant cells is seen in a submucosal lymphatic space. The surgical margins are free of tumor.

Four perigastric lymph nodes show no evidence of metastatic spread.

There are two segments of large peripheral nerve.

**DIAGNOSIS:**

1. Superficial spreading carcinoma rising in the margin of a chronic gastric ulcer - the surgical margins appear free of tumor.
2. Perigastric lymph nodes (4) without demonstrable metastases.

---

Tish Ewing, MD  
Pathologist

Name Marie du Malade

Reg. No. 000041

The information which should be abstracted from pathology report G2 is:

2/11/91 Path. Rpt. #S91-210. Bx bladder tumor: Papillary transitional cell carcinoma, Grade II. No area of invasion identified. (L) scalene node: neg.

**Comments:**

- a. TURB means transurethral resection of the bladder.
- b. TCC means transitional cell carcinoma which is the most common cell type for bladder cancer.

The information which should be abstracted from pathology report G3 is:

7/20/91. Path. Rpt. #S91-1700. (L) Rad. mast.: 4 cm tumor infiltrates deep fatty tissue; no invasion of muscle, nipple, or lactiferous sinuses. Metas. carcinoma (L) axillary lymph node, level I. Dx: Infiltrating duct carcinoma, (L) breast.

The information which should be abstracted from pathology report G4 is:

5/23/91. Path. Rpt. #S91-0100.

Floor of mouth continuous with tongue and mandible plus left radical neck dissection: Lesion 1.2 x 0.5 cm on (L) side of floor of mouth: Extranodal fibrous connective tissue contains foci of sq. cell carcinoma. All lymph nodes neg. Surgical margins free. Dx: Mod. well diff. sq. cell carcinoma of (L) floor of mouth.

The information which should be abstracted from pathology report G5 is:

9/11/91. Path. Rpt. #S91-999.

Stomach: Tumor does not extend below mucosa, but a single nest of malignant cells is seen in submucosal lymphatic space. Surgical margins free. Perigastric lymph nodes free. Dx: Superficial spreading carcinoma arising in the margins of a chronic gastric ulcer.

**Comment:** Ask the pathologist if the "poorly formed glands" could make this an adenocarcinoma.

## PRACTICAL EXERCISE

In the following pages we have provided four additional pathology reports (Examples G6-G9). Please study and summarize each report and then check with the suggested abstractions on page 225.



EXAMPLE G6

PATHOLOGY REPORT

Name Ben Hurtin Path. No. S91-1017 Reg. No. 000042  
Age 74 Sex Male Race White Location \_\_\_\_\_ Service Surgery Date 3/17/91  
Address \_\_\_\_\_ Occupation Farmer

HISTORY OF CASE: Melanoma (R) arm; pos (R) axillary node

CLINICAL DIAGNOSIS: Melanoma Stage III

Surgeon Otto Fixum, MD

Operation R axillary node dissection

GROSS DESCRIPTION:

The specimen is received in two portions. Part 1 labeled "axillary node, right" consists of a single lymph node with attached fibroadipose tissue. The specimen is bisected and submitted *in toto*. Part 2 is received in a steel pan. It is labeled "contents, right axillary node dissection." A solitary silk suture identifies the highest axillary level which is separated and designated #3. A portion of pectoralis major muscle measuring 7.0 x 5.0 x 2.0 cm in thickness is attached to this portion. Level II contains a mass 6.5 x 3.5 cm which is firm and on cut surface contains a homogeneous flesh-like mass which is light gray in color and firm in consistency. Photographs are made. Several small nodes are identified in level I which consist primarily of adipose tissue.

MICROSCOPIC DESCRIPTION:

Sections of 18 lymph nodes revealed in 3 of them diffuse replacement of normal lymphoid tissue by epithelioid-in-appearance malignant cells. The mitotic activity is marked and nuclei disclose prominent pleomorphism. No melanin pigment is identified.

DIAGNOSIS:

Metastatic malignant melanoma, in 3 of 18 (Level I (one), level II (one), and level III (one)), right axillary lymph nodes.

Mac McSmall, MD  
Pathologist



EXAMPLE G7

PATHOLOGICAL SPECIMEN REPORT

Path. No. S91-8955

Name Horace Overback

Reg. No. 000043

Age 68 Sex Male Race White Location \_\_\_\_\_ Service \_\_\_\_\_ Date 3/3/91

Address \_\_\_\_\_ Occupation Cowboy

HISTORY OF CASE: Dysphagia; weight loss; respiratory distress

CLINICAL DIAGNOSIS: Carcinoma of hypopharynx

Surgeon Cole Handle, MD

Nature of Operation Multiple biopsies

GROSS DESCRIPTION:

Specimens: 1.	Left arytenoid	6.	Posterior cricoid
2.	Right arytenoid	7.	Left pyriform sinus, posterior wall
3.	Interarytenoid	8.	(?) Posterior wall of hypopharynx
4.	Right pyriform sinus	9.	Right pyriform sinus polyp
5.	Main tumor, cricoid area		

1. Received in formalin is a single minute fragment of light-tan tissue which measures 1.0 mm in its greatest dimension. The entire specimen is submitted in one piece for microscopic study.
2. Received in formalin is a single fragment of light-tan tissue which measures 2.0 x 2.0 mm. The entire specimen is submitted in one piece for microscopic study.
3. Received in formalin is a single minute fragment of light-tan tissue which measures 1.0 mm in its greatest dimension. The entire specimen is submitted in one piece for microscopic study.
4. Received in formalin are two minute fragments of brownish-tan tissue. The largest of these measures 2.0 mm in greatest dimension. Both fragments are submitted in entirety for microscopic study.
5. Received in formalin is a single minute fragment of light-tan tissue which measures 1.5 mm in greatest dimension. The entire specimen is submitted for microscopic study.

Continued on next page



EXAMPLE G7 (continued)

6. Received in formalin are two minute fragments of hemorrhagic light-tan tissue. The largest measures 1.5 mm in greatest dimension. The entire specimen is submitted in three pieces for microscopic study.
7. Received in formalin are two minute fragments of light-tan tissue which in aggregate measure 4.0 x 3.0 x 2.0 mm. The entire specimen is submitted in two pieces for microscopic study.
8. Received in formalin is a single minute fragment of light-tan tissue which measures 1.5 mm in greatest dimension. The entire specimen is submitted in one piece for microscopic study.
9. Received in formalin is a single minute fragment of light-tan tissue measuring 1.0 mm in greatest dimension. The entire specimen is submitted in one piece for microscopic study.

MICROSCOPIC DESCRIPTION:

- 1, 2, 3 - No tumor in sections examined
- 4-9 - Epidermoid carcinoma

Norman Finder, MD  
Pathologist

Name Horace Overback

Reg. No. 000043

EXAMPLE G8

DEPARTMENT OF PATHOLOGY

Date: 8/9/91 Location Service  
Reg. No. 000044 Name Ralph C. Sark Age 65 Race White Sex Male  
Occupation Student Dept. of Pathology Accession No. S91-7896  
Surgeon M. Sterling, MD Nature of Operation Bone marrow biopsy

HISTORY OF CASE: Malignant lymphoma

SPECIMEN: Bone marrow

GROSS DESCRIPTION: Received in a test tube and representing products of bone marrow biopsy

ASPIRATE SECTION:

Markedly hypercellular megakaryocytes  
Decreased stainable iron is normal  
Malignant Lymphoma (See comment)

SMEAR:

90% abnormal cells  
04% erythroid  
02% granulocytic  
04% small lymphocytes  
See comment

DIAGNOSIS:

Previously diagnosed malignant lymphoma  
90% abnormal cells

COMMENT:

The bone marrow is almost totally replaced by atypical lymphoid cells, with the development of a leukemic phase. Approximately 90% of cells in the peripheral blood are abnormal. The abnormal cell is a large cell with a high nuclear cytoplasm ratio, pale blue vacuolated cytoplasm, reticular nuclear chromatin with 1-2 nucleoli. Special stains reveal markedly positive PAS stain. Sudan black stain and peroxidase stain are negative.

Michael Cosm, MD  
Pathologist



EXAMPLE G9

DEPARTMENT OF PATHOLOGY

Name Ann Trum

Reg. No. 000045

Age 62 Sex Female Race Black Ward E510 Service Surgery Date 1/15/91

CLINICAL HISTORY: Fungating lesion of gastric antrum with liver metastases

CLINICAL DIAGNOSIS: Gastric carcinoma with metastasis to liver

Path. No. S91-0300

Specimen Antrum of Stomach

DESCRIPTION:

Received in formalin is a specimen stated to represent antrum of the stomach. The specimen measures 12 cm x 6 cm x 2.3 cm in greatest dimensions, respectively. The external surface has a small amount of attached mesentery and vessels. Noted in the mesentery are several firm, hard lymph nodes, the largest measuring 2.3 cm in greatest dimension. The cut surface appears gray-tan and somewhat necrotic. The serosal surface of the stomach appears congested, shows signs of surgical instrumentation, as the specimen has been previously opened. The interior of the specimen reveals a large fungating, ulcerating lesion in the distal two-thirds, almost filling the distal two-thirds. This lesion measures 9 cm x 4 cm. It is surrounded by what appears to be slightly hypertrophic yellow-tan mucosa in a rugaform pattern. Cut surface of the lesion reveals it to involve the muscular wall. Sections taken are as follows:

1. Sections through main tumor mass
2. Section through margin of resection closest to mass (proximal)
3. Section of margin of resection furthest from mass (distal)
4. Lymph nodes in 1/2 superior mesentery near pylorus
5. Lymph nodes in proximal 1/2 superior mesentery
6. Lymph nodes distal 1/2 inferior mesentery
7. Lymph nodes proximal 1/2 inferior mesentery

DIAGNOSIS:

1. Stomach: Poorly differentiated adenocarcinoma infiltrating through muscular wall and involving serosa.
2. Duodenum: No tumor in sections examined.
3. Stomach: Chronic gastritis with intestinalization of gastric mucosa.
4. Seven lymph nodes: four contain metastatic carcinoma.
5. Two lymph nodes: one contains metastatic carcinoma.
- 6,7. Tumor nodules involving fat.

Examined by Patrick Holly, MD  
Pathologist



## PRACTICAL EXERCISE ANSWERS

Example G6: 3/17/91. Path. Rpt. S91-1017: Right axillary node dissection. Metastatic malignant melanoma in 3/18 nodes, one node in each level Dx: metas. malignant melanoma

Example G7: 3/3/91. Path. Rpt. S91-8955: Bx's arytenoids, (R) and (L) pyriform sinus, cricoid, posterior wall of R hypopharynx, pyriform sinus polyp. Arytenoids neg; all other spec. epid. carcinoma. Dx: Epidermoid carcinoma--hypopharynx, (R) and (L) pyriform sinuses and polyp on (R) cricoid (main tumor)

**Comment:** Should negative findings be reported? We recommend that you report pertinent negative findings as well as positive findings to provide a complete picture of the extent of the disease.

Example G8: 8/9/91. Path. Rpt. S91-7896: Bone marrow biopsy: 90% abnormal cells; in leukemic phase. Malignant lymphoma

Example G9: 1/15/91. Path. Rpt. S91-0300: Antrum of stomach--9 cm lesion. Dx: Poorly differentiated adenocarcinoma infiltrating through muscular wall and involving serosa. Surgical margins free of tumor. 5/9 mesenteric lymph nodes contain metastatic carcinoma; tumor nodules involving fat.

### **Comments:**

- a. Be sure you coordinate the numbered descriptions with the specimen named above.
- b. The operative report for histopathologic Example G9 may be found in Example F17.

### C. The Autopsy (Necropsy; Postmortem) Report

The most important portion of the autopsy report as far as the abstractor is concerned is the section entitled "Final Diagnosis." It usually will describe the primary site, histologic type, and extension and metastases of the tumor based on a histopathologic examination of the tissues obtained after death. All of the major organs are examined unless, as sometimes happens, the autopsy is restricted to certain organs. All pertinent findings should be recorded.

Autopsy findings confirm the diagnosis of cancer made prior to death, if still present, and may determine the primary site of a tumor which may have been incorrectly diagnosed or unknown prior to death. The histologic findings described in the autopsy report relative to the primary site and cell type usually take precedence over those reported in prior pathology reports.

On occasion, the presence of cancer will be an incidental discovery at the time of autopsy. When this occurs, the patient's history and physical examination findings should be reviewed to rule out a clinical diagnosis of cancer prior to death. In instances where the diagnosis of cancer was first made at autopsy, the cases are abstracted and identified as "diagnosed at autopsy." In such cases the date of diagnosis is the date of death.

The autopsy report for patients who died in your hospital should be included in the medical record. The autopsy protocols for those who died after discharge may be available from other hospitals or coroners' offices. Your Committee on Cancer should decide whether or not you will attempt to obtain autopsy reports (and Death Certificates) for those patients who died elsewhere.

If the autopsy report is based on gross observation alone (no microscopic exam) this should be noted. However, as a part of most autopsies, a histologic examination of tissue removed from the body will be performed routinely.

Example G10 is a typical autopsy report. Abstract what you think is pertinent and then compare with the suggested abstraction on page 231.

EXAMPLE G10

AUTOPSY REPORT

IDENTIFICATION NO. \_\_\_\_\_ AUTOPSY NO. A91-21 HOSPITAL NO. 000046

NAME Doe, John SERVICE NO. \_\_\_\_\_ WARD NO. \_\_\_\_\_

AGE 70 SEX Male RACE White

Date and hour of death: 12/1/91- 7:25 am Autopsy performed: 12/1/91- 12:30 pm

Check one: Full autopsy  Head only  Trunk only

Prosecutor Dr. Smith Assistant \_\_\_\_\_

CLINICAL HISTORY

This 70-year-old Caucasian man was admitted to the hospital on November 14, 1991 because of a lesion of the large bowel with partial obstruction. He had a diagnosis of chronic lymphocytic leukemia many years ago treated with chemotherapy. Apparently he showed also bilateral pyelonephrosis and metastatic disease to iliac lymph nodes. The prostate was thought to be benign. His primary problem was in the upper urinary tract. X-ray examination of the colon showed diverticulosis. No definite nodes or masses. No gallstones. The esophagus was normal. The distal stomach showed mucosal thickening and deformity with a certain amount of fixation and rigidity probably due to prepyloric ulcer with edema and other inflammatory changes. The possibility of carcinoma of stomach with ulceration raised on x-ray examination of the upper G.I. tract. X-ray examination of urinary tract showed Stage II - III hydronephrotic changes in both kidneys. The bladder was poorly defined. The ureters were not seen. The findings were consistent with an obstructive process in the lower urinary tract.

Laboratory Data: November 16, 1991. SMA-12: Glucose 235, Cholesterol 130, Total Proteins 5.7, Albumin 6.3, Alkaline Phosphatase 120, all other parameters within normal range. WBC 3.7, RBC 4.80, Hgb. 15.4, Hct. 45.0, MCV 95, MCH 31.8, MCHC 33.9. Differential: Segs 72, Lymphs 25, Monos 2, Eosins 1, Platelets adequate, RBC essentially normochromic with slight anisocytosis. Amylase 127, Glucose 117 mg.% on November 20.

Continued on next page



EXAMPLE G10 (continued)

FINAL PATHOLOGICAL DIAGNOSES

1. Chronic lymphocytic leukemia, diagnosed in May 1982 and treated with one intravenous injection of nitrogen mustard.
2. At autopsy, chronic lymphocytic leukemic infiltrates in liver and bone marrow.
3. Signet ring cell carcinoma of stomach (linitis plastica) diagnosed in November, 1991.
4. At autopsy, metastatic signet ring cell carcinoma in esophagus, colon, liver, gallbladder, common bile duct, pancreas, mesentery, right lung, adrenal glands, spleen, mediastinal and abdominal lymph nodes, prostate gland and bone marrow.
5. Adenocarcinoma of the right bronchus locally invasive, (micro). No evidence of distant metastases.
6. Mild perivascular fibrosis, myocardium.
7. Arteriosclerosis: aorta, severe; coronary arteries, moderate.
8. Congestion and edema, lungs.
9. Anthracosis, lungs.
10. Chronic esophagitis.
11. Diverticulosis, colon
12. Fibrinous peritonitis.
13. Congestion of the viscera.
14. Adenomatous hamartoma, pancreas.
15. Submucosal fibrosis, ureters.
16. Mild bilateral hydronephrosis.
17. Arteriolar nephrosclerosis, bilateral.
18. Benign stromal and glandular hyperplasia, prostate gland.
19. Myelofibrosis secondary to metastatic signet ring cell carcinoma.
20. Surgical absence of appendix.
21. Healed surgical scar, skin of abdomen, right lower quadrant.

---

John E. Jones, M.D.  
Pathologist

Doe, John

Hosp. No. 000046

Autopsy #A91-21

Continued on next page

EXAMPLE G10 (continued)

CLINICOPATHOLOGICAL CORRELATION AND DIAGNOSIS

This 70-year-old white man was diagnosed in May 1982 at age 61 as having chronic lymphocytic leukemia. He received one intravenous injection of nitrogen mustard with good results.

In January 1983, the patient was admitted to the hospital for evaluation and his white blood count was 5200 with 55% lymph., 37% mature polymorphs, 4% monocytes and 2% eosinophils. He was asymptomatic, and his prognosis for the future was described as excellent. In November 1991, the patient was admitted to the hospital, about 18 days before his death. There the diagnosis of undifferentiated adenocarcinoma of the stomach with massive dissemination of the disease was made. The patient died on December 1, 1991.

Microscopic examination showed a signet ring cell carcinoma of stomach infiltrating the muscular coat with fibroblastic proliferation and thickening of the serosa. Metastatic signet ring cell carcinoma was found in many organs (see final pathologic diagnosis) and represented massive widespread metastatic disease.

Only microscopically were we able to diagnose adenocarcinoma of the right bronchus, locally invasive and infiltrating bronchial cartilage and adjacent nerves but without metastases.

Although, the patient was free of any symptoms of chronic lymphocytic leukemia, sections of the liver and bone marrow showed lymphocytic leukemic infiltrates. The enlargement of the spleen (770 gm.) and lymph nodes might be due to metastatic signet ring cell carcinoma as well as to leukemic involvement.

At autopsy this case revealed three histologically different tumors. Two of them were carcinomas: signet ring cell carcinoma of the stomach with widespread metastases and adenocarcinoma of the right bronchus with local infiltration. The third malignancy was chronic lymphocytic leukemic infiltrates without definite clinical manifestation. It is quite possible, that the signet ring cell carcinoma with metastases, diagnosed in late stage of such disease, covered other slightly marked features of leukemia or adenocarcinoma of the lung.

The myelofibrosis could be secondary to metastatic signet ring cell carcinoma or the results of the previous leukemic chemotherapy or connected with leukemic involvement of the bone marrow, or all of them caused such condition.

Doe, John

Hosp. No. 000046

Autopsy #A91-21



Example G10 can be abstracted as follows:

Example G10: 12/1/91. Autopsy Rpt. # A91-21.

1. Chronic lymphocytic leukemia infiltrating liver and bone marrow. Dx: 5/82
2. Signet ring cell carcinoma of stomach (linitis plastica) metas. to esophagus, colon, liver, gallbladder, common bile duct, pancreas, mesentery, right lung, adrenal glands, spleen, mediastinal and abdominal lymph nodes, prostate gland, and bone marrow. Dx: 11/91
3. Adenoca of (R) bronchus locally invasive. No evid. of distant metastasis. Dx: 12/91 (at autopsy)
4. Myelofibrosis secondary to metas. signet ring cell carcinoma.

**Comments:**

- a. The pathologic diagnosis confirms the original diagnosis of two separate primaries--chronic lymphocytic leukemia and carcinoma of the stomach.
- b. It reveals the presence of a third and previously unsuspected primary tumor--adenocarcinoma of the right bronchus.
- c. Record the description of each separate primary and the metastatic spread of each primary as described in the microscopic (pathological) section of the autopsy report.
- d. The clinicopathologic correlation contains information which may help you interpret other reports and statements found in the medical record.
- e. The cause of death is signet cell carcinoma of the stomach.
- f. Three separate abstracts will be prepared for this case.

A complete autopsy report of a different format is presented on the following pages. Prepare an abstract for Example G11.



EXAMPLE G11

DEPARTMENT OF PATHOLOGY - AUTOPSY REPORT

Coroner's Case [ ] Yes [x] No

Unit Hospital No. 000047

Necropsy No. N91-2000

Name Marty Gallstone Age 78 Race White Sex Male

Admitted: Date 3/3/91 Hour 1:00 pm Ward C400C Service Surgery

Died: Date 3/18/91 Hour 4:15 am Necropsied: Date 3/18/91 Hour 9:30 am

Prosecutor Harry O'Flexure, MD

Reviewer Robert McSplenic, MD

FINAL NOTE

This 78-y/o W M presented with jaundice, anorexia, and wt. loss. The clinical impression was carcinoma of the head of the pancreas. BE revealed an obstructed area at the ascending colon - probably due to carcinoma of colon. UGI revealed a hiatal hernia. Liver scan was abnormal, being compatible with a central lesion. His bilirubin was 22.1; D/I = 17.3/4.8. His course in the hospital was increasingly downhill with increasing jaundice and obstruction. He later became unresponsive and died on 3/18/91. At autopsy he was found to have an adenocarcinoma of the gallbladder extending into the liver and to the (R) hepatic flexure of the colon with resultant colonic obstruction. No other metastases were found. His lungs were adenomatous and atelectatic, and several areas of fibrosis were found in the heart.

PROVISIONAL GROSS NECROPSY FINDINGS:

- I      Carcinoma hepatic flexure (R) colon  
          (micro pending)
  - a)      Obstructive jaundice
  - b)      Extension into liver
  
- II      Cholelithiasis  
          Biliary cirrhosis
  
- III     Aspiration pneumonitis with acute bronchitis pulmonary edema
  
- IV      Benign nephrosclerosis  
          Chronic pyelonephritis

Continued on next page

EXAMPLE G11 (Continued)

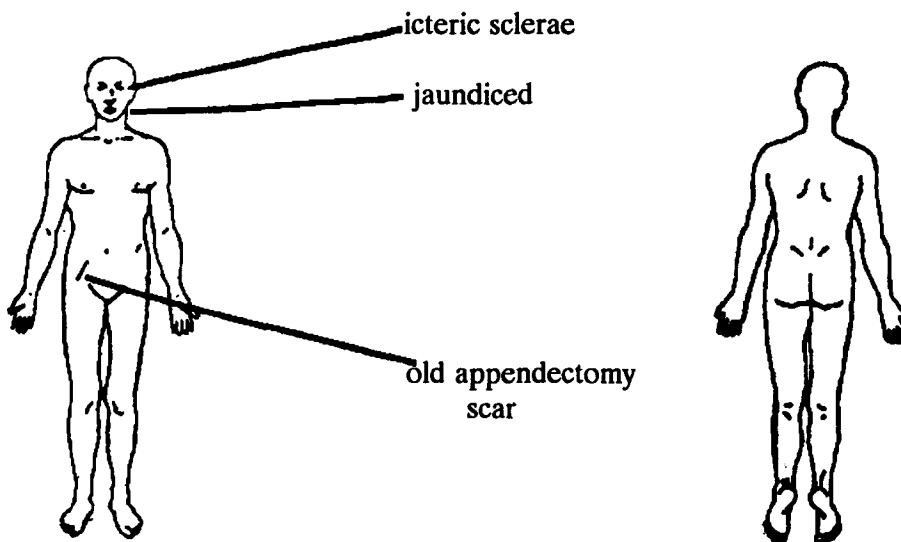
DEPARTMENT OF PATHOLOGY - AUTOPSY REPORT

EXTERNAL EXAMINATION

Height 180 cm      Weight 143 lb.      State of nutrition emaciated

Brain examined  
 Yes     No

Subcutaneous  
fat, abdominal 2 cm



- Indicates no significant abnormality
- Skin            jaundiced
- Hair
- Extremities
- Lymph nodes
- External genitalia
- Breasts
- Eyes
- Ears
- Nose
- Mouth
- Tongue
- Teeth

Continued on next page

EXAMPLE G11 (Continued)

DEPARTMENT OF PATHOLOGY - AUTOPSY REPORT

THORAX \_\_\_\_\_

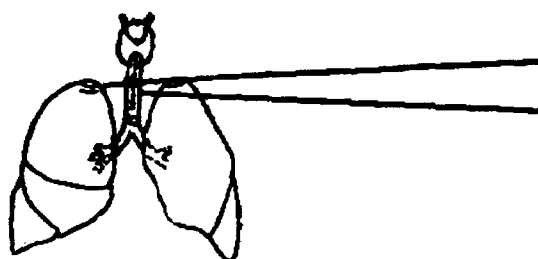
[x] Indicates no significant abnormality

[x] Thyroid \_\_\_\_\_ gm.

[x] Parathyroid \_\_\_\_\_ gm.

[x] Thymus \_\_\_\_\_ gm.

[ ] Trachea

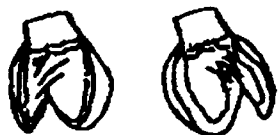

old apical scarring

The trachea is filled with dark brown foamy material similar to gastric contents as are both main stem bronchi and bronchioli.

[x] Hilar nodes

(R)		(L)
[x] Pleura		[x] Pleura
[ ] LUNG <u>750 gm.</u>	[ ]	[ ] LUNG <u>600 gm.</u>
[ ] Bronchi [x] Arteries	[ ]	[ ] Bronchi [x] Arteries



Both lungs are edematous excluding dark edema fluid.

[x] Pericardium

[x] HEART <u>300 gm.</u>
[x] (R) ventricle <u>0.7 cm</u>
[x] (L) ventricle <u>1.2 cm</u>
[x] Tricuspid v. <u>11 cm</u>
[x] Pulmonic v. <u>8.0 cm</u>

[x] Mitral v. <u>10 cm</u>
[x] Aortic v. <u>7.5 cm</u>
[x] Pulmonary artery
[x] Aorta [x] Vena cava

Continued on next page

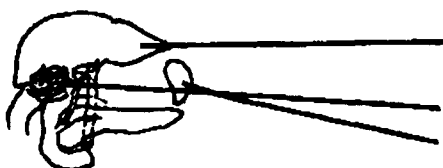


EXAMPLE G11 (Continued)

DEPARTMENT OF PATHOLOGY - AUTOPSY REPORT

ABDOMEN

- [x] Indicates no significant abnormality  
[x] Peritoneum [x] Mesentery [x] Omentum



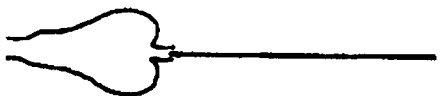The cut surface of the liver is bile stained nodular - 1-3 mm in diameter, very friable

4 large stones in gallbladder  
Spleen is autolyzed

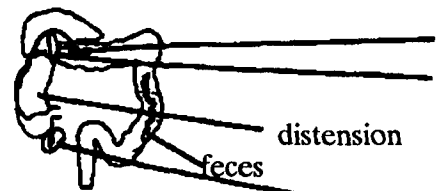
- [ ] LIVER 2500 gm.  
[ ] Gallbladder  
[ ] Common bile duct  
[ ] Portal vein  
[ ] SPLEEN 100 gm.  
[x] PANCREAS 100 gm.

The hepatic flexure of the (R) colon is matted into the liver--carcinoma in this flexure--yellow, tough fibrous on cut surface. The liver is sectioned and opened. Tumor appears to originate from gallbladder and extends to liver and down.

(The gallbladder is flesh colored and filled with 4 large mixed stones. The tumor appears to originate from gallbladder)



The stomach is filled with mucous colored material



Tumor nodules on internal surface of bowel.

Mass in hepatic flexure growing into liver; this mass involves the external portion of bowel and appears to originate from the gallbladder

- [x] Esophagus  
[x] Ilium

Continued on next page

EXAMPLE G11 (Continued)

DEPARTMENT OF PATHOLOGY - AUTOPSY REPORT

GENITOURINARY SYSTEM

[x] Indicates no significant abnormality

(R)

(L)

[x] ADRENAL gm. \_\_\_\_\_

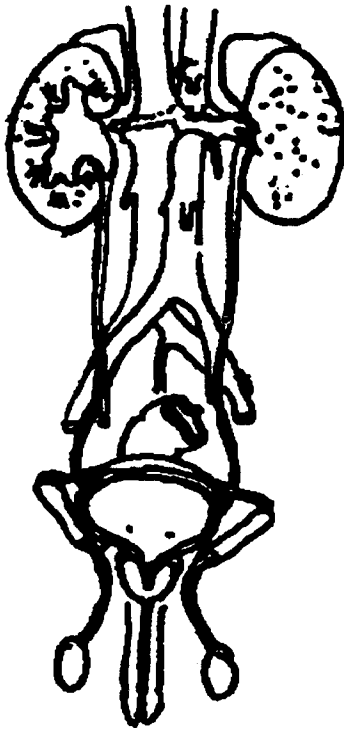
[x] ADRENAL gm. \_\_\_\_\_

[ ] KIDNEY 130 gm.

[ ] KIDNEY 150 gm.

(R) adrenal autolytic

[x] Pelvis [x] Ureter [x] Pelvis [x] Ureter



Both kidneys are studded with small yellow nodules 1 mm in diameter. The pelvises appear clear; ureters patent.

(R)  
[x] TESTIS \_\_\_\_\_ gm.  
[x] Epididymis  
[x] Bladder  
[x] Prostate  
[x] Urethra

(L)  
[x] TESTIS \_\_\_\_\_ gm.  
[x] Epididymis

Continued on next page

EXAMPLE G11 (Continued)

DEPARTMENT OF PATHOLOGY - AUTOPSY REPORT

MICROSCOPIC DESCRIPTION

Gallbladder - Adenocarcinoma extending to liver and hepatic flexure of (R) colon.

Kidney - Infiltration with PMN and plasma cells  
Hyalinization of arteriae  
Fibrosis of glomeruli

Spleen/pancreas - Microscopically unremarkable

Lung - Atelectasis with RBC congestion and edema

Heart - Occasional areas of fibrosis

FINAL DIAGNOSIS

- I Carcinoma of the gallbladder with extension into liver
  - a. Metastatic to hepatic flexure of colon with colonic obstruction
  - b. Obstructive jaundice
  - c. Passive congestion of liver with bile stasis
  
- II Cholelithiasis
  
- III Aspiration pneumonitis with pulmonary edema  
Acute tracheobronchitis
  
- IV Benign nephrosclerosis
  
- V Acute pyelonephritis

Example G11 can be abstracted as follows:

Example G11: 3/18/91. Autopsy Rpt. N91-2000: Adenocarcinoma of the gallbladder with extension into liver and hepatic flexure. Nodules on internal surface of bowel.

**Comments:** Did malignancy extend to hepatic flexure (microscopic description) or metastasize to hepatic flexure (final diagnosis)? Report as direct extension of tumor. "Direct extension of tumor" agrees with the microscopic description and is supported by the note on the diagram of the abdomen which says that the right colon was matted into the liver. (The distinction between direct extension and metastasis, non-contiguous disease, will be discussed in a later instructional manual.)



## CYTOLOGIC EXAMINATION

The study of cells, their origin, structure, function, and pathology is called cytology. Cells are continually shed (exfoliated) from tissues that line the cavities and hollow organs of the body. These exfoliated cells may float in the fluid and mucous material which bathes or passes through these cavities. These cells can be examined microscopically to determine their tissue of origin and whether or not they are malignant. The term *exfoliative cytology* refers to "microscopic examination of cells contained within body fluids."

The three body cavities, the pleura (enclosing the lungs), the peritoneum (enclosing the intestinal tract), and the pericardium (enclosing the heart), may be checked for fluid. The normal fluids within the body cavities are limited to an insignificant lubricating layer that cannot be aspirated. Therefore, fluid in any body cavity which can be aspirated indicates a pathological process, commonly malignant and metastatic. It is believed that the formation of ascites (fluid in the abdominal cavity), for example, is brought about by colonies of cancer cells which damage the capillaries and lymphatics resulting in leakage of cancer cells and plasma directly into the abdominal cavity.

The table below lists the sources of some of the specimens that are examined histologically and some that are examined cytologically. As a further guide, histology is the study of *tissues*, while cytology is the study of *cells*.

<u>Histologic Examination</u>	<u>Cytologic Examinations</u>	
Biopsy material	Sputum	Bronchial washing
Frozen section	Breast Secretion	Prostate secretion
Bone marrow biopsy/aspiration (tissue)	Gastric fluid	Spinal fluid
Operative specimen	Peritoneal fluid	Urinary sediment
Autopsy specimen	Pleural fluid	Cervical & vaginal smears
	Bone marrow aspiration (cells)	Tracheal washing
	Bronchial brushing	

## CYTOLOGY AND ITS PROCEDURES

Cytology is the study of the structure and function of cells; the examination of cells under a microscope as used in the diagnosis of cancer.

There are a variety of procedures employed to obtain material for cytologic examination from fine needle aspiration of superficial or internal lesions to exfoliated cells obtained by aspiration, washing, brushing, smears, or scraping of vaginal secretions, sputum, urine, abdominal fluid, prostate secretions, etc. The more common techniques include:

**Brushings**--the procedure of brushing the lining of an organ for the purpose of obtaining cells

**Punctures**--Inserting a hollow needle into a cavity or organ for the purpose of removal of some portion of the contents (fluid, bone marrow, tissue)

**Paracentesis**--Surgical puncture of a cavity for aspiration of fluid, such as the abdominal cavity

**Thoracentesis**--Surgical puncture for aspiration of fluid from the chest

**Scrapings**--the procedure of scraping the lining of a structure with an instrument for the purpose of obtaining cells

**Swabs**--Using a swab or similar device to obtain fluid and secretions which then can be used to make a smear

**Washings**--the removal of fluid from a hollow organ or structure for the purpose of collecting any cells in the fluid which may have exfoliated

A cytology report recorded as suspicious is not considered as diagnostic of cancer. Unless supported by a positive biopsy (as reported on a pathology report) or by a clinical impression of cancer, these cases should not be abstracted.

The Papanicolaou<sup>1</sup> classification of cells for the detection of malignancy ("Pap" smear) used in the past is as follows:

<u>Class</u>	<u>Interpretation</u>
I	No evidence of a malignant neoplasm, no atypical cells
II	Atypical cells present but no evidence of malignant neoplasm
III	Cells present causing suspicion of malignant neoplasm
IV	Fairly conclusive evidence of malignant neoplasm
V	Conclusive evidence of malignant neoplasm

Some medical records will contain more than one cytology report. If there are multiple reports on the same type and source of specimen, record the findings on the first positive report. If they are based on different types and sources of specimens, summarize all pertinent findings.

According to the National Cancer Institute Workshop on Terminology for Cervical and Vaginal Cytology, December 12-13, 1988, "While the Papanicolaou Classes have a significant historical association with the early development of cytology, it can no longer be relied upon to communicate clinically relevant information. In particular, the Papanicolaou Classes do not reflect current understanding of cervical neoplasia, do not provide for the diagnosis of non-cancerous entities, and, as a result of numerous idiosyncratic modifications over the years, no longer reflect uniform diagnostic interpretations. Accordingly, it is our conclusion that the Papanicolaou Class System is not acceptable in the practice of diagnostic cytology." Their organization of the new terminology and classifications is as follows:

- (a) a STATEMENT ON ADEQUACY OF THE SPECIMEN,
- (b) a GENERAL CATEGORIZATION of the diagnosis (*within normal limits or other*), and
- (c) the DESCRIPTIVE DIAGNOSIS

For Squamous Cell the following terminology is used:

- III.A.1 Atypical squamous cells of undetermined significance (specify recommended follow-up and/or further investigative procedures)
- III.A.2 Squamous intraepithelial lesions (Comment on presence or absence of cellular changes consistent with Human papillomavirus (HPV) infection)
  - III.A.2a Low grade squamous intraepithelial lesion *encompassing:*  
Cellular changes consistent with HPV infection  
Mild dysplasia / CIN 1

---

<sup>1</sup>George Nicolas Papanicolaou was a Greek physician, anatomist, and cytologist in the United States.



III.A.2b            **High grade squamous intraepithelial lesions *encompassing*:**  
                         **Moderate dysplasia / CIN 2**  
                         **Severe dysplasia / CIN 3**  
                         **Carcinoma *in situ* / CIN 3**

III.A.3             **Squamous carcinoma**

At first you may find it somewhat disconcerting to discover that more than one type of form may be used to report similar findings. However, as you study Examples G12-G15, you will find that they contain similar information. Example G12 contains check lists for recording most of the types of information. For example:

The source of the specimen is recorded by checking one of the blocks on the left of the report. This report is of special interest to the new cancer registrar because it lists the major sources of material used as specimens for a cytologic examination.

At the top left of the report, the clinical diagnosis may be summarized. This need not be recorded on the abstract. In many cases the laboratory study was ordered on the basis of a previously suspicious Pap smear.

The findings of the examination will be recorded by checking one of the blocks listed in the section describing the tissue status on the lower right.

**PRACTICAL EXERCISE**

Summarize the findings of these cytology reports (Examples G12-G15) and then compare with the suggested abstractions on page 253.

**EXAMPLE G12**

Name <b>Kay Soper</b>		Date <b>10/6/91</b>	CYTOPATHOLOGY REPORT	
Service		12179	[X] Inpatient  [ ] Clinic	
Patient No. <b>000048</b>				
Type and Source of Specimen <b>Tracheal Washings</b>				
Clinical Findings <b>Ca Esophagus</b>		Do Not Write Below This Line		
Previous Surgery		Screening for Malignancy Negative [ ] Atypical [ ] Unsatisfactory [ ]		
Cytologic Exams		Suspicious [ ] Positive [x]		
LMP	Parity	Comments: <b>The pattern suggests poorly differentiated squamous cell carcinoma</b>		
Radiation		Patient's Chart		
Hormones				
			Date <b>10/6/91</b>	



EXAMPLE G13

CYTOPATHOLOGY	PATIENT NO. 00049	DATE 10/6/91	CYTOPATHOLOGY REPORT #03166		NAME Hy Nix	
	CLINICAL FINDINGS Ca hypopharynx and larynx					
	<input type="checkbox"/> ROUTINE <input type="checkbox"/> STAT <input type="checkbox"/> TODAY <input type="checkbox"/> OTHER		DATE OR TIME	TIME ORDERED	ORDERED BY	
	194 <input checked="" type="checkbox"/> - CYTOLOGY - ROUTINE 195 <input type="checkbox"/> - CYTOLOGY AND CELL BLOCK 196 <input type="checkbox"/> - CYTOLOGY - SPECIAL	SLIDE NO.  03166	SOURCE OF SPECIMEN <input type="checkbox"/> VAGINA <input checked="" type="checkbox"/> BRONCHUS (washings) <input type="checkbox"/> SPUTUM <input type="checkbox"/> CERVIX  <input type="checkbox"/> GASTRIC <input type="checkbox"/> URINE <input type="checkbox"/> PLEURAL FL.  <input type="checkbox"/> PERITONEAL FL. <input type="checkbox"/> _____			
	COMMENTS  Very suspicious of epidermoid carcinoma  <p style="text-align: center;"><u>J. Marx, M.D.</u> PATHOLOGIST</p>		<input type="checkbox"/> CLASS I NO EVIDENCE OF MALIGNANCY <input type="checkbox"/> CLASS II ATYPICAL BENIGN EPITHELIAL CHANGES <input checked="" type="checkbox"/> CLASS III SUSPICIOUS FOR MALIGNANCY <input type="checkbox"/> CLASS IV STRONGLY SUGGESTIVE FOR MALIGNANCY <input type="checkbox"/> CLASS V POSITIVE EVIDENCE OF MALIGNANCY			
			ESTROGEN ACTIVITY <input type="checkbox"/> LOW <input type="checkbox"/> NORMAL <input type="checkbox"/> HIGH	TRICHOMONADS _____ YEAST _____	DODERLEIN B _____ POLYPS _____	
CYTOPATHOLOGY			DATE 10/6/91	TECH.		



EXAMPLE G14

Patient No. 000050		DATE 2/5/91	Name Kay Kline	Race: Black	<input checked="" type="checkbox"/> INPATIENT <input type="checkbox"/> CLINIC
DIAGNOSIS Post menopausal bleeding					SPECIMEN NO. 01000
PHYSICIAN					
SOURCE OF SPECIMEN		UNSATISFACTORY REASON			
<input checked="" type="checkbox"/> FEM. GEN. TRACT <input type="checkbox"/> ESOPHAGUS TYPE _____		CLINICAL STATUS (PERTINENT HISTORY, PHYSICAL FINDINGS, PREV. TREATMENT SURGERY, ETC.) Post menopausal bleeding, 62-year old			
<input type="checkbox"/> BRONCHOSCOPY <input type="checkbox"/> ORAL <input type="checkbox"/> SPUTUM <input type="checkbox"/> STOMACH <input type="checkbox"/> URINE <input type="checkbox"/> BREAST TYPE _____		<input type="checkbox"/> IRRADIATION <input type="checkbox"/> HORMONES			
<input type="checkbox"/> SPINAL FLUID <input type="checkbox"/> PLEURAL <input type="checkbox"/> PERITONEAL <input type="checkbox"/> OTHER _____		DO NOT WRITE BELOW THIS LINE			
EXAMINATION DESIRED <input checked="" type="checkbox"/> SCREENING FOR NEOPLASM <input type="checkbox"/> ENDOCRINE STATUS <input type="checkbox"/> OTHER (SPECIFY) _____		NEOPLASTIC STATUS <input type="checkbox"/> NORMOPLASIA <input type="checkbox"/> DYSPLASIA <input type="checkbox"/> MILD <input type="checkbox"/> MODERATE <input type="checkbox"/> SEVERE <input checked="" type="checkbox"/> NEOPLASIA Pap class V, Epid. Ca with <u>atypical glandular elements</u>			
		INFLAMMATORY STATUS <input type="checkbox"/> MILD <input type="checkbox"/> MODERATE <input type="checkbox"/> SEVERE _____ HORMONAL STATUS <input type="checkbox"/> NORMAL FOR AGE & PHYSIOLOGIC STATE, <input type="checkbox"/> ABNORMAL _____			
		RECOMMENDATION: <input type="checkbox"/> ROUTINE FOLLOW-UP, <input type="checkbox"/> REPEAT 1-3 MO. <input type="checkbox"/> TISSUE STUDY REC.			
		FEES: <input type="checkbox"/> REG. <input type="checkbox"/> ADD. <input type="checkbox"/> NONE			
		NAME Kay Kline		PATIENT'S CHART	
		CYTOPATHOLOGY LABORATORY 8900	DATE 2/5/91	SIGNATURE P. White	



EXAMPLE G15

CLINICAL RECORD - TISSUE EXAMINATION

Name: Sid Pathe

Hospital No. 000051

Age 56

Sex Male

Race White

Reg. No. 51 Ward 13East

Specimen submitted by \_\_\_\_\_

Date obtained \_\_\_\_\_

Specimen Bronchial washing (CYTOLOGY)

Brief Clinical History RLL and RML collapse

Pre-operative diagnosis Carcinoma

Operative findings Same

Post-operative Diagnosis \_\_\_\_\_

Signature and Title C. Hall

Name of Laboratory Cytopathology

Accession No(s). L-91-34

GROSS DESCRIPTION, HISTOLOGIC EXAMINATION AND DIAGNOSES:

The filter (1 ml. on millipore), cell block sections (3) and smears (3) prepared from the bronchial washing show leukocytes, histiocytes (many pigmented), erythrocytes, fibrin, bacteria and proteinaceous material. There are numerous cells present showing radiation effects. There are other cells which appear viable, with enlarged irregular nuclei, clumped chromatin, prominent irregular nucleoli and orangeophilic cytoplasm.

INTERPRETATION:

Bronchial washing: consistent with bronchogenic carcinoma.

Date 8/24/91

Maria Bronsky, MD  
Pathologist





**Examples G12-15 may be abstracted as follows:**

**Example G12: 10/6/91. Cytology Rpt. # 12179.**

**Tracheal washings: Pattern suggests poorly differentiated squamous cell carcinoma.**

**Example G13: 10/6/91. Cytology Rpt. # 03166.**

**Bronchial washing: Pap Class III, very suspicious of epidermoid carcinoma.**

**Example G14: 2/5/91. Cytology Rpt. # 01000.**

**Fem. Gen. Tract: Pap Class V, epidermoid carcinoma with atypical glandular elements.**

**Example G15: 8/24/91. Cytology Rpt. # L91-34.**

**Bronchial washing: Consistent with bronchogenic carcinoma.**

**Comment: Note this cytology report is submitted on a pathology report form which has quite a different format from the three previous cytology reports.**



## COMMON ABBREVIATIONS

### Abbreviation Index

<u>Abbreviation</u>	<u>Term(s)</u>		
A	Allergy	APP	Appendix
A	Annum	APPROX	Approximately
A	Anode	ARC	Aids related complex
A	Anterior	ARD(S)	Acute respiratory disease (syndrome)
A	Aortic	ART	Artery(ial)
A	Artery	AS	Aortic stenosis
A	Axial	AS	Arteriosclerosis
AB	Abort (miscarry)	ASCVD	Arteriosclerotic cardiovascular disease
AB	About	ASHD	Arteriosclerotic heart disease
AB	Antibody	ASP	Aspiration
AB	Asthmatic bronchitis	ASR	Aldosterone secretion rate
ABD, ABDOM	Abdomen	ASS	Anterior superior spine (of ilium)
ABN	Abnormal	A STEN	Aortic stenosis
ABP	Arterial blood pressure	ATP	Adenosine triphosphate
ABST	Abstract	ATR	Achilles tendon reflex
AC	Adrenal cortex	ATR	Atrophy
AC	Air contrast	AU	Angstrom unit
AC	Anterior chamber	AU	Aurum (gold, chemical symbol for)
ACH	Adrenal cortical hormone	AUT	Autopsy
ACID PHOS	Acid phosphatase	AV	Aortic valve
ACID P'TASE	Acid phosphatase	AV	Arteriovenous
ACTH	Adrenocorticotrophic hormone	AV	Atrioventricular
ADENOCA	Adenocarcinoma	AV	Average
ADH	Antidiuretic hormone (vasopressin)	A & W	Alive and well
ADJ	Adjacent	AX	Axilla(ry)
ADM	Admission	AX	Axis(ial)
ADM	Admit		
AFF	Afferent	B	Bacillus
AFF	Affirmative	B	Black
AFP	Alpha-fetoprotein	B	Blue
AG	Atrial gallop	B	Born
AG	Antigen	B	Brother
AG	Argentum (silver, chemical symbol for)	BA	Bachelor of Arts
AGL	Acute granulocytic leukemia	BA	Barium (chemical symbol for)
A/G RATIO	Albumin-globulin ratio	BA	Bronchial asthma
AGNO <sub>3</sub>	Silver nitrate	BAS	Basal
AIDS	Acquired immunodeficiency syndrome	BASOS	Basophil(s) (granular leukocyte)
AK(A)	Above knee (amputation)	BBB	Blood-brain barrier
AKA	Also known as	BBB	Bundle-branch block
ALB	Albumin	BBT	Basal body temperature
ALK PHOS	Alkaline phosphatase	BC	Birth control
ALL	Acute lymphocytic leukemia	BC	Bone conduction
AMA	Against medical advice	BC	Buccocervical
AMB	Ambulatory	BCC	Basal cell carcinoma
AML	Acute myelogenous leukemia	B-CELLS	Special lymphocytes formed in bone marrow (derived from bursa of Fabricius)
AMP	Amputation	BCG	Bacillus Calmette-Guerin
ANAP	Anaplastic	BD	Bile duct
ANAT	Anatomy	BE	Barium enema
ANES(TH)	Anesthesia, anesthetic	B/F	Black female
ANT	Anterior	BIL	Bilateral
ANTE	Before	BK(A)	Below knee (amputation)
A&P	Auscultation & percussion	BM	Bone marrow
AP	Abdominal perineal	BM	Bowel movement
AP	Anteroposterior	B/M	Black male
AP	Anterior pituitary	BMR	Basal metabolism rate
AP&LAT	Anteroposterior and lateral		

BP	Blood pressure	DIS, DISCH	Disease; Discharge
BPH	Benign prostatic hypertrophy/hyperplasia	DNA	Deoxyribonucleic acid
BRM	Biological response modifier	DO	Doctor of Osteopathy
BSC	Bone scan	DOA	Dead on arrival
BSO	Bilateral salpingo-oophorectomy	DOB	Date of birth
BT	Brain tumor	DOD	Date of death
BUN	Blood urea nitrogen	DOE	Dyspnea on exertion
BUS	Bartholin's, uethral & Skene's glands	DR	(Medical) doctor
BX	Biopsy	DS	Discharge
		DTR	Deep tendon reflex
		DX	Diagnosis
C	Centigrade		
Ca	Ca--Journal of the American Cancer Society		
C1-C7	Cervical vertebrae	ECF	Extended care facility
CA	Calcium	EKG, ECG	Electrocardiogram
CA	Carcinoma	EEG	Electroencephalogram
CAT	See CT SN	EENT	Eyes, ears, nose & throat
CBC	Complete blood count	EGD	Esophagogastroduodenoscopy
CBD	Common bile duct	EMG	Electromyogram
CC	Chief complaint	ENL	Enlarged
CC	Cubic centimeter	ENT	Ears, nose & throat
CCU	Coronary care unit	EPA	Erect (standing), posterior, anterior
CEA	Carcinoembryonic antigen	ER	Emergency room
CGL	Chronic granulocytic leukemia	ER(A)	Estrogen receptor (assay)
CHF	Congestive heart failure	ERCP	Endoscopic retrograde cholangiopancreatography
CHR	Chronic	EST	Electroshock therapy
CIG	Cigarettes	EUA	Exam under anesthesia
CIN	Cervical intraepithelial neoplasia	EXAM	Examination
CIS	Carcinoma-in situ	EXC	Excision
CLL	Chronic lymphocytic leukemia	EXP LAP	Exploratory laparotomy
CM	Centimeter	EXT	Extend, extension
CM	Costal margin	EXT	External; Extremity
CML	Chronic myeloid/myelocytic leukemia	F	Fahrenheit
CMV	Cytomegalovirus	FB	Fingerbreadth
CNS	Central nervous system	FBS	Fasting blood sugar
CO	Complaining of	F(M)H	Family (medical) history
CO <sub>2</sub>	Carbon dioxide	FLURO	Fluoroscopy
Co60	Cobalt 60	FOM	Floor of mouth
COR	Heart	FP	Flat plate
CS	Cesium	FU	Follow up
CSF	Cerebrospinal fluid	FUO	Fever unknown origin
CSF	Colony-stimulating factor	FX	Fracture
C-SPINE	Cervical spine	FX	Frozen section
CTR	Certified Tumor Registrar		
CT SC	Computerized (axial) tomography scan	GA	Gastric analysis
CVA	Cerebrovascular accident	GB	Gallbladder
CVA	Costovertebral angle	GE	Gastroenterostomy
C/W	Consistent with	GE	Gastroesophageal
CX	Cervix	GEN	Generalized
CXR	Chest x-ray	GI	Gastrointestinal
CYSTO	Cystoscopy	GM	Gram
CYTO	Cytology	GP	General practitioner
		GR	Grade, grain(s)
		GU	Genitourinary
		GYN	Gynecology
D <sub>1</sub> , D <sub>2</sub> , ETC	First dorsal vertebra, second, etc.		
D&C	Dilatation and curettage		
DC	Discharge		
DC	Discontinued	HB	Hemoglobin
DERM	Dermatology	HCG	Human chorionic gonadotropin
DD	Discharge diagnosis	HCT	Hematocrit
DIAM	Diameter	HCVD	Hypertensive cardiovascular disease
DIFF	Differentiated, differential	HD	Heart disease

HEENT	Head, eyes, ears, nose & throat	LE	Lower extremity; Lupus erythematosus
HGB	Hemoglobin	LFT	Liver function test
HIV	Human immunodeficiency virus	LG	Large
HN <sub>2</sub>	Nitrogen mustard	LIF	Left iliac fossa
H <sub>2</sub> O	Water	LINAC	Linear accelerator
H/O	History of	LIQ	Lower inner quadrant (breast)
HORM	Hormone	LKS(B)	Liver, kidney, spleen, (bladder)
HOSP	Hospital	LLE	Left lower extremity
H&P	History and physical	LLL	Left lower lobe (lung)
HPF	High power field	LLQ	Left lower quadrant (abdomen)
HPI	History of present illness	LMD	Local medical doctor
HPV	Human papilloma virus	LMP	Last menstrual period
HR(S)	Hour(s)	LN(S)	Lymph node(s)
HTLV-III	Human T-lymphotrophic virus type III	LOP	Lower outer quadrant (breast)
HVD	Hypertensive vascular disease	LP	Lumbar puncture
HX	History	LPF	Low power field
HYST	Hysterectomy	LPN	Licensed practical nurse
I	Iodine	LS	Lumbosacral
ICD-O-1	International Classification of Diseases for Oncology, 1st Ed., 1976	LSK, LKS	Liver, spleen, kidneys
ICD-O-2	International Classification of Diseases for Oncology, 2nd Ed., 1992	LSO	Left salpingo-oophorectomy
ICM	Intercostal margin	L-SPINE	Lumbar spine
ICS	Intercostal space	LT	Left
ICU	Intensive care unit	LUE	Left upper extremity
IG	Immunoglobulin	LUL	Left upper lobe (lung)
IM	Intramuscular	LUQ	Left upper quadrant (abdomen)
IMA	Internal mammary artery	L&W	Living and well
IMP	Impression	M	Monocytes, meter
INCL	Includes, including	MAL	Malignant
INF	Inferior	MALIG	Malignant
INF	Infraction	MAND	Mandible
INF	Infusion	MAST	Mastectomy
INFILT	Infiltrating	M-CSF	Macrophage Colony-Stimulating Factor
INJ	Injection	MC	Millicurie
INT MED	Internal medicine	MCH	Mean corpuscular hemoglobin
IP	Inpatient	MCHC	Mean corpuscular hemoglobin count
IPPB	Intermittent positive pressure breathing	MCL	Mid clavicular line
IT	Intrathecal	MCV	Mean corpuscular volume
IV	Intravenous	MD	Medical Doctor
IVC	Inferior vena cava	MD	Moderately differentiated
IVP	Intravenous pyelogram	MET, METS	Metastatic, metastases
JVD	Jugular venous distention	MEV	Million electron volts
K	Potassium	MH	Marital history
KG	Kilogram	MH	Mental health
KJ	Knee jerk	MG	Milligram
KK	Knee kick	MICRO	Microscopic
KUB	Kidneys, ureters, bladder	ML	Middle lobe
KV	Kilovolt	ML	Milliliter
L	Left	MM	Millimeter
L	Liter	MOD	Moderate
L	Lower	MOD DIFF	Moderately differentiated
L1-L5	Lumbar vertebrae	MRI	Magnetic resonance imaging
LAP	Laparotomy	MRM	Modified radical mastectomy
LAT	Lateral	MS	Mitral stenosis
LAV	Lymphadenopathy-associated virus	MS	Multiple sclerosis
LCM	Left costal margin	MSL	Mid sternal line
LDH	Lactic dehydrogenase	MX	Microscopic
		MX	Maxilla(ry), maximum
		NA	Not applicable
		NBS	Normal bowel sounds
		NEC	Not elsewhere classified

NED	No evidence of disease	POD	Postoperative day
NEG or -	Negative	POOR DIFF	Poorly differentiated
NERD	No evidence of recurrent disease	POS or +	Positive
NEURO	Neurology	POSS	Possible
NL	Normal	POST	Posterior
NOS	Not otherwise specified	POST	Postmortem examination
NR	Not recorded	POSTOP	Postoperative(ly)
NR	Not reportable	PPD	Purified protein derivative (Tuberculin skin test)
NSF	No significant findings	PPD	Packs per day
NTP	Normal temperature and pressure	PR(A)	Progesterone receptor (assay)
N&V	Nausea and vomiting	PREOP	Preoperative(ly)
NVD	Neck vein distention	PROB	Probable(ly)
		PT	Patient
OB	Obstetrics	PT	Physiotherapy
OBST	Obstructed (ing, ion)	PTA	Prior to admission
OD	Right eye (oculus dexter)	PUO	Pyrexia of undetermined origin
OH	Occupational history	PULM	Pulmonary
OP	Operation		
OP	Outpatient	Q	Quadrant
OPD	Outpatient clinic; department		
OPHTH	Ophthalmology	R	Roentgen
OR	Operating room	R	Respiration
ORTH	Orthopedics	R	Right
OS	Bone	RA	Radium
OS	Left eye (oculus sinister)	RAD	Radiation
OS	Mouth	RAD	Radiation Absorbed Dose
OS	Opening	RAD	Radical
OSTEO	Osteomyelitis	RAIU	Radioactive iodine (I 131) uptake
OT	Occupational therapy	RBC	Red blood cells
OTO	Otology	RCM	Right Costal Margin
OU	Each eye (oculus uterque)	RCS	Reticulum cell sarcoma
OV	Office visit	REG	Radioencephalogram
OZ	Ounce	RES	Reticuloendothelial system
		RESEC	Resection
P	Pulse	RESPIR	Respiratory
P&A	Percussion and auscultation	RH	Rhesus (monkey) factor in blood
PA	Posteroanterior	RIA	Radioimmunoassay
PA	Pulmonary artery	RIF	Right iliac fossa
PALP	Palpable, palpated, palpation	RIQ	Right inner quadrant (abdomen)
PAP	Papanicolaou smear	RLE	Right lower extremity
PAP	Papillary	RLL	Right lower lobe (lung)
PAR	Post anesthesia room	RLQ	Right lower quadrant
PARA	Number of pregnancies resulting in viable infants	RML	Right middle lobe (lung)
		RN	Registered nurse
PATH	Pathology	RNA	Ribonucleic acid
PCV	Packed cell volume	RO, R/O	Rule out
PD	Poorly differentiated	ROF	Review of outside films
PDR	Physicians' Desk Reference	ROM	Range of motion
PE	Physical examination	ROS	Review of outside slides
PED	Pediatrics	ROS	Review of systems
PEG	Pneumoencephalography	ROQ	Right outer quadrant (abdomen)
PERC	Percutaneous	RSO	Right salpingo-oophorectomy
PET	Positron emission tomography	R-S cells	Reed-Sternberg cells
PH	Past or personal history	RT	Radiation therapy
PI	Present illness	RT	Right
PID	Pelvic inflammatory disease	RUE	Right upper extremity
PLT	Platelets	RUL	Right upper lobe
PM	Post mortem (after death)	RUQ	Right upper quadrant
PMD	Personal (primary) medical doctor	R-V	Rectovaginal
PMH	Past medical history	RX	Treatment
PND	Postnasal drip		
PO, POSTOP	Postoperative(ly)	S1-S5	Sacral vertebra

SARC	Sarcoma	UMB	Navel (umbilicus)
SB	Small bowel	UNDIFF	Undifferentiated
SBE	Subacute bacterial endocarditis	UOQ	Upper outer quadrant (abdomen)
SCC	Squamous cell carcinoma	UR	Urine
SGOT	Serum glutamic oxaloacetic transaminase	URI	Upper respiratory infection
SGPT	Serum glutamic pyruvic transaminase	UROL	Urology
SH	Social history		
SH	Serum hepatitis	VAG	Vagina, Vaginal
SM	Small	VAG HYST	Vaginal hysterectomy
SMA	Sequential multiple analysis (Biochem profile)	VAIN	Vaginal intraepithelial neoplasia
SML	Small	VASC	Vascular
SML BWL	Small bowel	VD	Venereal disease
SNF	Skilled nursing facility	VIN	Vulvar intraepithelial neoplasia
SO	Salpingo-oophorectomy	VS	Vital signs
SOB	Shortness of breath		
SOL	Solution	W/	With
S/P	Status post	WBC	White blood cells
SPEC	Specimen	W/D	Well developed
SP GR	Specific gravity	WD, WELL DIFF	Well differentiated
S-Q, SQ	Subcutaneous	W/F	White female
SQ, SQUAM	Squamous	W/M	White male
SQ CELL CA	Squamous cell carcinoma	WNL	Within normal limits
SR	Sedimentation rate	W/O	Without
S-SPINE	Sacral spine	WT	Weight
STAPH	Staphylococcus	W/U	Work-up
STAT	Immediately (statim)		
STREP	Streptococcus	XR	X-ray
STSG	Split thickness skin graft		
SUB-Q, SUBQ	Subcutaneous	Y/O	Year old
SURG	Surgery, surgical	YR	Year
SVC	Superior vena cava		
SX	Symptoms		
T	Temperature		
T	Thoracic		
TA	Toxin-antitoxin		
T1-T12	Thoracic vertebra		
T&A	Tonsillectomy and adenoidectomy		
TAH	Total abdominal hysterectomy		
TAH-BSO	Total abdominal hysterectomy-bilateral salpingo-oophorectomy		
TB, TBC	Tuberculosis		
TCC	Transitional cell carcinoma		
TD	Tumor dose		
TNM	Tumor, Nodes, Metastasis		
TP	Total protein		
TPR	Temperature, pulse and respiration		
TS	Tumor size		
TSH	Thyroid stimulating hormone		
T-SPINE	Thoracic spine		
TUR	Transurethral resection		
TURB	Transurethral resection - Bladder		
TURP	Transurethral resection - Prostate		
TVH	Total vaginal hysterectomy		
TX	Treatment		
U	Unit		
UCHD	Usual childhood diseases		
UE	Upper extremity		
UGI	Upper gastrointestinal		
UIQ	Upper inner quadrant (breast)		





## Definition Index

Abdomen	ABD, ABDOM	Arteriosclerotic cardiovascular disease	ASCVD
Abdominal perineal	AP	Arteriosclerotic heart disease	ASHD
Abnormal	ABN	Arteriovenous	AV
Abort (miscarry)	AB	Artery	A
About	AB	Artery(ial)	ART
Above knee (amputation)	AK(A)	Aspiration	ASP
Abstract	ABST	Asthmatic bronchitis	AB
Achilles tendon reflex	ATR	Atrial gallop	AG
Acid phosphatase	ACID P <sup>T</sup> TASE	Atrioventricular	AV
Acid phosphatase	ACID PHOS	Atrophy	ATR
Acquired immunodeficiency syndrome	AIDS	Aurum (gold, chemical symbol for)	AU
Acute granulocytic leukemia	AGL	Auscultation & percussion	A&P
Acute lymphocytic leukemia	ALL	Autopsy	AUT
Acute myelogenous leukemia	AML	Average	AV
Acute respiratory disease (syndrome)	ARD(S)	Axial	A
Adenocarcinoma	ADENOCA	Axilla(ry)	AX
Adenosine triphosphate	ATP	Axis(ial)	AX
Adjacent	ADJ		
Admission	ADM	Bachelor of Arts	BA
Admit	ADM	Bacillus	B
Adrenal cortex	AC	Bacillus Calmette-Guerin	BCG
Adrenal cortical hormone	ACH	Barium (chemical symbol for)	BA
Adrenocorticotrophic hormone	ACTH	Barium enema	BE
Afferent	AFF	Bartholin's, Urethral & Skene's glands	BUS
Affirmative	AFF	Basal	BAS
Against medical advice	AMA	Basal body temperature	BBT
Aids related complex	ARC	Basal cell carcinoma	BCC
Air contrast	AC	Basal metabolism rate	BMR
Albumin	ALB	Basophil(s) (granular leukocyte)	BASOS
Albumin-globulin ratio	A/G RATIO	Before	ANTE
Aldosterone secretion rate	ASR	Below knee (amputation)	BK(A)
Alive and well	A & W	Benign prostatic hypertrophy/hyperplasia	BPH
Alkaline phosphatase	ALK PHOS	Bilateral	BIL
Allergy	A	Bilateral salpingo-oophorectomy	BSO
Alpha-fetoprotein	AFP	Bile duct	BD
Also known as	AKA	Biological response modifier	BRM
Ambulatory	AMB	Biopsy	BX
Amputation	AMP	Birth control	BC
Anaplastic	ANAP	Black	B
Anatomy	ANAT	Black female	B/F
Anesthesia, anesthetic	ANES(TH)	Black male	B/M
Angstrom unit	AU	Blood-brain barrier	BBB
Annum	A	Blood pressure	BP
Anode	A	Blood urea nitrogen	BUN
Anterior	ANT	Blue	B
Anterior chamber	AC	Bone	OS
Anterior pituitary	AP	Bone conduction	BC
Anterior superior spine (of ilium)	ASS	Bone marrow	BM
Anteriorposterior	AP	Bone scan	BSC
Anteroposterior and lateral	AP&LAT	Born	B
Antibody	AB	Bowel movement	BM
Antidiuretic hormone (vasopressin)	ADH	Brain tumor	BT
Antigen	AG	Bronchial asthma	BA
Aortic stenosis	AS	Brother	B
Aortic stenosis	A STEN	Buccocervical	BC
Aortic	A	Bundle-branch block	BBB
Aortic valve	AV		
Appendix	APP	Ca--Journal of the American Cancer Society	CA
Approximately	APPROX	Calcium	CA
Argentum (silver, chemical symbol for)	AG	Carbon dioxide	CO <sub>2</sub>
Arterial blood pressure	ABP	Carcinoembryonic antigen	CEA
Arteriosclerosis	AS	Carcinoma	CA

Carcinoma-in situ	CIS	Enlarged	ENL
Centigrade	C	Erect (standing), posterior, anterior	EPA
Centimeter	CM	Esophagogastroduodenoscopy	EGD
Central nervous system	CNS	Estrogen receptor (assay)	ER(A)
Cerebrospinal fluid	CSF	Examination	EXAM
Cerebrovascular accident	CVA	Examination under anesthesia	EUA
Certified Tumor Registrar	CTR	Excision	EXC
Cervical spine	C-SPINE	Exploratory laparotomy	EXP LAP
Cervical intraepithelial neoplasia	CIN	Extend, extension	EXT
Cervical vertebrae	C1-C7	Extended care facility	ECF
Cervix	CX	External	EXT
Cesium	CS	Extremity	EXT
Chemotherapy	CHEMO	Eyes, ears, nose & throat	EENT
Chest x-ray	CXR		
Chief complaint	CC	Fahrenheit	F
Chronic myeloid/myelocytic leukemia	CML	Family (medical) history	F(M)H
Chronic	CHR	Fasting blood sugar	FBS
Chronic granulocytic leukemia	CGL	Fever unknown origin	FUO
Chronic lymphocytic leukemia	CLL	Fingerbreadth	FB
Cigarettes	CIG	First dorsal vertebra, second dorsal vertebra, etc.	D <sub>1</sub> , D <sub>2</sub> , etc.
Cobalt 60	Co60		
Colony-stimulating factor	CSF	Flat plate	FP
Common bile duct	CBD	Floor of mouth	FOM
Complaining of	C/O	Fluoroscopy	FLURO
Complete blood count	CBC	Follow up	FU
Computerized (axial) tomography scan	CT SC	Fracture	FX
Congestive heart failure	CHF	Frozen section	FS
Consistent with	C/W		
Coronary care unit	CCU	Gallbladder	GB
Costal margin	CM	Gastric analysis	GA
Costovertebral angle	CVA	Gastroenterostomy	GE
Cubic centimeter	CC	Gastroesophageal	GE
Cystoscopy	CYSTO	Gastrointestinal	GI
Cytology	CYTO	Generalized	GEN
Cytomegalovirus	CMV	General practitioner	GP
Genitourinary	GU	Genitourinary	GU
Date of birth	DOB	Grade, grain(s)	GR
Date of death	DOD	Gram	GM
Dead on arrival	DOA	Gynecology	GYN
Deep tendon reflex	DTR		
Deoxyribonucleic acid	DNA	Head, eyes, ears, nose & throat	HEENT
Dermatology	DERM	Heart	COR
Diagnosis	DX	Heart disease	HD
Diameter	DIAM	Hematocrit	HCT
Differentiated, differential	DIFF	Hemoglobin	HB, HGB
Dilatation and curettage	D&C	High power field	HPF
Discharge	DIS, DISCH	History	HX
Discharge	DC, DS	History and physical	H&P
Discharge diagnosis	DD	History of	H/O
Discontinued	DC	History of present illness	HPI
Disease	DIS	Hormone	HOR
Doctor of Osteopathy	DO	Hospital	HOSPM
Dyspnea on exertion	DOE	Hour(s)	HR(S)
		Human chorionic gonadotropin	HCG)
		Human papilloma virus	HPV
Each eye (oculus uterque)	OU	Human immunodeficiency virus	HIV
Ears, nose & throat	ENT	Human T-lymphotrophic virus type III	HTL
Electrocardiogram	ECG, EKG	Hypertensive cardiovascular disease	HCVV-III
Electroencephalogram	EEG	Hypertensive vascular disease	HVDD
Electromyogram	EMG	Hysterectomy	HYST
Electroshock therapy	EST		
Emergency room	ER		
Endoscopic retrograde cholangiopancreatography	ERCP	Immediately (statim)	STAT
		Immunoglobulin	IG

Impression	IMP	Lumbar spine	L-SPINE
Includes, including	INCL	Lumbar vertebrae	L1-L5
Inferior	INF	Lumbosacral	LS
Inferior vena cava	IVC	Lupus erythematosus	LE
Infiltrating	INFILT	Lymph node(s)	LN(S)
Infraction	INF	Lymphadenopathy associated virus	LAV
Infusion	INF		
Injection	INJ		
Inpatient	IP	Macrophage Colony-Stimulating Factor	M-CSF
Intensive care unit	ICU	Magnetic resonance imaging	MRI
Intercostal margin	ICM	Malignant	MAL, MALIG
Intercostal space	ICS	Mandible	MAND
Intermittent positive pressure breathing	IPPB	Marital history	MH
Internal mammary artery	IMA	Mastectomy	MAST
Internal medicine	INT MED	Maxilla(ry), maximum	MX
International Classification of Diseases for Oncology, 1st Ed., 1976	ICD-O-1	Mean corpuscular hemoglobin	MCH
International Classification of Diseases for Oncology, 2nd Ed., 1992	ICD-O-2	Mean corpuscular volume	MCV
Intramuscular	IM	Mean corpuscular hemoglobin count	MCHC
Intrathecal	IT	Medical Doctor	MD
Intravenous	IV	Mental health	MH
Intravenous pyelogram	IVP	Metastatic, metastases	MET, METS
Iodine	I	Microscopic	MX
		Microscopic	MICRO
		Mid clavicular line	MCL
		Mid sternal line	MSL
Jugular venous distention	JVD	Middle lobe	ML
		Millicurie	MC
Kidneys, ureters, bladder	KUB	Milligram	MG
Kilogram	KG	Milliliter	ML
Kilovolt	KV	Millimeter	MM
Knee kick	KK	Million electron volts	MEV
Knee jerk	KJ	Mitral stenosis	MS
		Moderate	MOD
Lactic dehydrogenase	LDH	Moderately differentiated	MD
Laparotomy	LAP	Moderately differentiated	MOD DIFF
Large	LG	Modified radical mastectomy	MRM
Last menstrual period	LMP	Monocytes, meter	M
Lateral	LAT	Mouth	OS
Left	L, LT	Multiple sclerosis	MS
Left costal margin	LCM		
Left eye (oculus sinister)	OS	Nausea and vomiting	N&V
Left ilial fossa	LIF	Navel (umbilicus)	UMB
Left lower extremity	LLE	Neck vein distention	NVD
Left lower lobe (lung)	LLL	Negative	NEG or -
Left lower quadrant (abdomen)	LLQ	Neurology	NEURO
Left upper extremity	LUE	Nitrogen mustard	HN <sub>2</sub>
Left upper lobe (lung)	LUL	No evidence of disease	NED
Left upper quadrant (abdomen)	LUQ	No evidence of recurrent disease	NERD
Left salpingo-oophorectomy	LSO	No significant findings	NSF
Licensed practical nurse	LPN	Normal	NL
Linear accelerator	LINAC	Normal bowel sounds	NBS
Liter	L	Normal breath sounds	NBS
Liver function test	LFT	Normal temperature and pressure	NTP
Liver kidney, spleen (bladder)	LKS(B)	Not applicable	NA
Liver, spleen, kidneys	LSK, LKS	Not elsewhere classified	NEC
Living and well	L&W	Not otherwise specified	NOS
Local medical doctor	LMD	Not reportable	NR
Low power field	LPF	Not recorded	NR
Lower	L	Number of pregnancies resulting in viable infants	PARA
Lower extremity	LE		
Lower inner quadrant (breast)	LIQ	Lumbar puncture	ObstetricsOB
Lower outer quadrant (breast)	LOQ		Obstructed (ing, OBST
Lumbar puncture	LP		
ion) ion)			
Occupational history	OH		

Occupational therapy	OT	Radioactive iodine (I 131) uptake	RAIU
Office visit	OV	Radioencephalogram	REG
Opening	OS	Radioimmunoassay	RIA
Operating room	OR	Radium	RA
Operation	OP	Range of motion	ROM
Ophthalmology	OPHTH	Rectovaginal	R-V
Orthopedics	ORTH	Red blood cells	RBC
Osteomyelitis	OSTEO	Reed-Sternberg cells	R-S CELLS
Otology	OTO	Registered nurse	RN
Ounce	OZ	Resection	RESEC
Outpatient	OP	Respiration	R
Outpatient clinic	OPD	Respiratory	RESPIR
Outpatient department	OPD	Reticuloendothelial system	RES
		Reticulum cell sarcoma	RCS
Packed cell volume	PCV	Review of systems	ROS
Packs per day	PPD	Review of outside slides	ROS
Palpable, palpated, palpation	PALP	Review of outside films	ROF
Papanicolaou smear	PAP	Rhesus (monkey) factor in blood	RH
Papillary	PAP	Ribonucleic acid	RNA
Past medical history	PMH	Right	RT
Past or personal history	PH	Right costal margin	RCM
Pathology	PATH	Right eye (oculus dexter)	OD
Patient	PT	Right iliac fossa	RIF
Pediatrics	PED	Right inner quadrant (abdomen)	RIQ
Pelvic inflammatory disease	PID	Right lower extremity	RLE
Percussion and auscultation	P&A	Right lower lobe (lung)	RLL
Percutaneous	PERC	Right lower quadrant	RLQ
Personal (primary) medical doctor	PMD	Right middle lobe (lung)	RML
Physical examination	PE	Right outer quadrant (abdomen)	ROQ
Physicians' Desk Reference	PDR	Right salpingo-oophorectomy	RSO
Physiotherapy	PT	Right upper extremity	RUE
Platelets	PLT	Right upper lobe	RUL
Pneumoencephalography	PEG	Roentgen	R
Poorly differentiated	PD	Rule out	RO, R/O
Positive	POS or +		
Positron emission tomography	PET		
Possible	POSS		
Post anesthesia room	PAR	Sacral spine	S-Spine
Post mortem (after death)	PM	Sacral vertebrae	S1-S5
Posterior	POST	Salpingo-oophorectomy	SO
Posteroanterior	PA	Sarcoma	SARC
Postmortem examination	POST	Sedimentation rate	SR
Postnasal drip	PND	Sequential multiple analysis	SMA
Postoperative day	POD	(Biochem profile)	
Postoperative(ly)	PO, POSTOP	Serum glutamic oxaloacetic transaminase	SGOT
Potassium	K	Serum glutamic pyruvic transaminase	SGPT
Preoperative(ly)	PREOP	Serum hepatitis	SH
Present illness	PI	Shortness of breath	SOB
Prior to admission	PTA	Silver nitrate	AGNO <sub>3</sub>
Probable(ly)	PROB	Skilled nursing facility	SNF
Progesterone receptor (assay)	PR(A)	Small	SM, SML
Pulmonary	PULM	Small bowel	SML BWL
Pulmonary artery	PA	Small bowel	SB
Pulse	P	Social history	SH
Purified protein derivative (Tuberculin skin test)	PPD	Solution	SOL
Pyrexia of undetermined origin	PUO	Special lymphocytes formed in bone marrow (derived from bursa of Fabricius)	B-CELLS
Quadrant	Q	Specific gravity	SP GR
		Specimen	SPEC
Radiation	RAD	Split thickness skin graft	STSG
Radiation absorbed dose	RAD	Squamous	SQ, SQUAM
Radiation therapy	RT	Squamous cell carcinoma	SCC
Radical	RAD	Squamous cell carcinoma	SQ CELL CA

Staphylococcus	STAPH	Within normal limits	WNL
Status post	S/P	Without	W/O
Streptococcus	STREP	Work-up	W/U
Subacute bacterial endocarditis	SBE		
Subcutaneous	S-Q, SQ	X-ray	XR
Subcutaneous	SUB-Q, SUBQ		
Superior vena cava	SVC	Year	YR
Surgery, surgical	SURG	Year old	Y/O
Symptoms	SX		
Temperature	T		
Temperature, pulse and respiration	TPR		
Thoracic	T		
Thoracic spine	T-SPINE		
Thoracic vertebra	T1-T12		
Thyroid stimulating hormone	TSH		
Tonsillectomy and adenoidectomy	T&A		
Total protein	TP		
Total abdominal hysterectomy	TAH		
Total abdominal hysterectomy- bilateral salpingo-oophorectomy	TAH-BSO		
Total vaginal hysterectomy	TVH		
Toxin-antitoxin	TA		
Transitional cell carcinoma	TCC		
Transurethral resection	TUR		
Transurethral resection - Bladder	TURB		
Transurethral resection - Prostate	TURP		
Treatment	RX, TX		
Tuberculosis	TB, TBC		
Tumor size	TS		
Tumor dose	TD		
Tumor, Nodes, Metastasis	TNM		
Undifferentiated	UNDIFF		
Unit	U		
Upper extremity	UE		
Upper gastrointestinal	UGI		
Upper inner quadrant (breast)	UIQ		
Upper outer quadrant (abdomen)	UOQ		
Upper respiratory infection	URI		
Urine	UR		
Urology	UROL		
Usual childhood diseases	UCHD		
Vagina, Vaginal	VAG		
Vaginal hysterectomy	VAG HYST		
Vaginal intraepithelial neoplasia	VAIN		
Vascular	VASC		
Venereal disease	VD		
Vital signs	VS		
Vulvar intraepithelial neoplasia	VIN		
Water	H <sub>2</sub> O		
Weight	WT		
Well developed	W/D		
Well differentiated	WD, WELL DIFF		
White blood cells	WBC		
White female	W/F		
White male	W/M		
With	W/		



## COMMON SYMBOLS

### Symbol Index

<u>Symbol</u>	<u>Term(s)</u>
1°	Primary
2°	Secondary
@	At
/	Comparison (e.g. 6/12 LN for six of 12 lymph nodes)
=	Equals
#	Number (if before a numeral), pounds (if after a numeral)
X	Times
♀	Female
♂	Male
↑	Increased
↓	Decreased
-	Negative
+	Positive
μCi	Microcurie
μg	Microgram
<	Less than
>	Greater than
≤	Less than or equal to
≥	Greater than or equal to
○	With
○	Without





## ACRONYMS FOR ORGANIZATIONS CONCERNED WITH CANCER

### Acronym

### Organization

#### FEDERAL GOVERNMENT

- NCI National Cancer Institute: One of the National Institutes of Health in the U. S. Department of Health and Human Services, it was established as a center for cancer research. The NCI has also assumed a leading role in Acquired Immunodeficiency Syndrome (AIDS) research since the disease was first recognized in 1981.
- SEER Surveillance, Epidemiology, and End Results: SEER collects incidence and follow-up data in ten areas in the United States for the purpose of identifying and monitoring trends in cancer incidence and survival.

#### NATIONAL ORGANIZATIONS

- AACR American Association of Cancer Research: An organization dedicated to cancer research with probably the largest research meeting in the country. It also publishes information on all basic cancer research.
- ACCC Association of Community Cancer Centers: An organization of comprehensive hospitals and cancer centers with an interest in community activities. Members are concerned about the how and why of cancer program development, the impact of prospective payment, capitation, and competition, and the establishment and maintenance of high standards of quality patient care.
- ACOA American College of Oncology Administrators: A professional health care organization for oncology administrators, managers, and consultants of cancer programs and services. It is a chapter of the American Academy of Medical Administrators.
- ACOS American College of Surgeons: A professional medical association to improve the quality of care for surgical patients by elevating the standards of surgical education and practice.
- ACS American Cancer Society: A private cancer research organization, which supports, through grants, investigator-initiated projects in established medical and other scientific institutions across the country.
- AHIMA American Health Information Management Association: A group of credentialed professionals, Registered Record Administrator (RRA) and Accredited Record Technician (ART), who collect and analyze a wide range of health information.

- AJCC American Joint Committee on Cancer: Organized in 1959 for the purpose of clinical staging, the AJCC decided to use the TNM system of the UICC to develop its own system of clinical and pathologic staging. Cooperation between 1982-87 has resulted in uniform and identical definitions and stage groupings of cancer for all sites between UICC and AJCC.
- AMA American Medical Association: A professional organization of practicing physicians. It also provides coordination and direction for allied health education to establish and maintain appropriate standards of patient care through its accreditation of allied medical education programs.
- ASCO American Society of Clinical Oncology: A society of oncologists, primarily medical, for the dissemination and exchange of cancer information.
- ASSO American Society of Surgical Oncology: A society of surgical oncologists for dissemination and exchange of cancer information.
- CCOP Community Clinical Oncology Program: A cooperative agreement supported program which provides support to community-based oncologists to participate in clinical trials sponsored by the clinical cooperative groups and/or cancer centers.
- COC Commission on Cancer of the American College of Surgeons: Representing 28 national professional organizations, the Commission seeks multidisciplinary cooperation in cancer management. It establishes standards for approval of cancer programs, stimulates cancer programs in institutions and communities, develops nationwide patient care evaluation studies of specific organ sites and types of malignancy as well as symposia and postgraduate courses on cancer for physicians.
- JCAHCO Joint Commission on Accreditation of Health Care Organizations (Formerly Joint Commission on Accreditation of Hospitals): Provides standards for accreditation of health care organizations and conducts surveys to determine an organization's degree of compliance and provides acceptable ways to bring the organization into compliance.
- NTRA National Tumor Registrars Association: A professional organization to promote the level of knowledge and performance of tumor registrars through educational standards and continuing education as well as to improve and standardize the compiling of tumor registry information.
- NAACCR North American Association of Central Cancer Registries: A professional society whose members are, for the most part, from population-based registries interested in the development and application of cancer registration and morbidity survey techniques to studies of defined population groups and to the conduct of cancer control programs.

## WORLDWIDE ORGANIZATIONS

- IACR**      International Association of Cancer Registries: A voluntary non-governmental organization established in 1970 to represent the scientific and professional interests of cancer registries interested in the development and application of cancer registration and morbidity survey techniques to studies of well-defined populations.
- IARC**      International Agency for Research on Cancer: Established in 1965 within the framework of the World Health Organization (WHO), IARC is dedicated to research on cancer, particularly epidemiology of cancer and study of potential carcinogens in the human environment.
- UICC**      International Union Against Cancer (Union Internationale Contre le Cancer): An organization established to monitor cancer throughout the world. It disseminates current knowledge of cancer, its prevention, early detection, diagnosis, treatment, rehabilitation, and continuing care as well as knowledge in basic and clinical cancer research. It was first in the development of the TNM Clinical Staging Classification in the early 1950's, one of its many accomplishments.
- WHO**      World Health Organization: A United Nations organization established to monitor world health. It divides the world into seven regions with a headquarters in each region.

## PUBLICATIONS AND ON-LINE DATA BASES

- ACTUR**      The Automated Central Tumor Registry System: A Department of Defense automated central tumor registry system established by the Defense Enrollment Eligibility Reporting System (DEERS) for Army, Navy, and Air Force hospitals (on-line data base).
- ICD-O**      The International Classification of Diseases for Oncology: The ICD-O, First Edition (1976), (published by WHO) permits coding of all neoplasms by topography, histology (morphology), and behavior. It also provides a separate grading and differentiation code. The ICD-O, Second Edition (1990), went into general use in the United States in 1992 (publication).
- MEDLINE**      An on-line version of Index Medicus published by the National Library of Medicine (NLM). It contains information (abstracts) about the documents, but not the documents themselves (on-line data base).
- MEDLARS**      The MEDLARS system (NLM) is a basic guide to searching the various biomedical data bases. It contains more than 20 separate data bases, such as, MEDLINE to search for articles in recent journals, CANCERLIT to search for cancer literature, and CHEMLINE to search for chemical compounds (on-line data base).

GRATEFUL MED A system for simplifying the process of searching for and retrieving biomedical information on the MEDLARS system (on-line data base).

PDQ The Physicians Data Query: An on-line data base which makes state-of-the-art treatment information, directory information, and protocol information available to the medical community. This data base is maintained by the International Cancer Research Data Base Branch, International Cancer Information Center, NCI (on-line data base).

### THE AUTOMATED CAUSE CODING SYSTEM

#### TRACER

Target Recognition of Automatically Coded Entity References--an automated coding program used at the Office of Population, Censuses and Surveys for coding death certificates

#### MICAR

Mortality medical Indexing, Classification, And Retrieval--a computer program that takes diagnoses and translates words into code numbers of ICD-9 (CM)

#### ACME

Automated Classification of Medical Entities--the computer program used by the National Center for Health Statistics (NCHS) to select the underlying cause of death after the individual diagnoses have been coded

#### TRANSAX

TRANSlate the AXis of Classification of the manually assigned codes into a form amenable to person-based analyses of multiple causes of death. This resolves multiple anomalies when coding death certificates in the United States.

## ACRONYMS FOR STUDY GROUPS

The following study groups are funded privately and by the Clinical Trials Cooperative Group Program of the National Cancer Institute for the purpose of providing the opportunity for cancer research by extramural investigators. The Cooperative Groups have been instrumental in the development of new standards of cancer patient management and in the development of sophisticated clinical investigation techniques:

BCCA	British Columbia Cancer Agency
BTCG	Brain Tumor Cooperative Group
BTSG	Brain Tumor Study Group
CALGA	Cancer and Leukemia Group A
CALGB	Cancer and Leukemia Group B
CCSG	Children's Cancer Study Group
CCDEP	Central Clinical Drug Evaluation Program
COG	Central Oncology Group
ECOG	Eastern Cooperative Oncology Group
GITSG	Gastrointestinal Study Group
GOG	Gynecologic Oncology Group
HNCP	Head and Neck Contracts Program
HTSG	Hepatic Tumor Study Group
AML1	Acute Myelocytic Leukemia Intergroup
INTERG	Intergroup (Other)
IRS	Intergroup Rhabdomyosarcoma Study
LCSG	Lung Cancer Study Group
MAOP	Mid-Atlantic Oncology Program
MARCOG	Mid-Atlantic Regional Co-Op Oncology Group
NABMTG	North American Bone Marrow Treatment Group
NBCG	National Bladder Cancer Group
NCCTG	North Central Cancer Treatment Group
NCOG	Northern California Oncology Group
NORCA	Nutrition Oncology Research Cooperative Association
NPCTG	National Prostatic Cancer Treatment Group
NSABP	National Surgery Adjuvant Project for Breast and Bowel Cancers
POA	Piedmont Oncology Association
POG	Pediatric Oncology Group
PVACCG	Pacific VA Cancer Chemotherapy Group
PVSG	Polycythemia Vera Study Group
RTOG	Radiation Therapy Oncology Group
SECSG	Southeastern Cancer Study Group
SWOG	Southwest Oncology Group
TPNG	Total Parenteral Nutrition Group
UORG	Uro-Oncology Research Group
VALG	V.A. Lung Group
VASOG	V.A. Surgical Oncology Group
VACG	V.A. Chemotherapy Group
WCCG	Western Cancer Chemotherapy Group
WCG	Weski Cancer Group
WTSG	Wilms' Tumor Study Group



## SELECTED BIBLIOGRAPHY

- Cancer Registry Manual. Chicago, Commission on Cancer, American College of Surgeons, 1974.
- Chabner, D. The Language of Medicine. Philadelphia, Saunders, 1976.
- Data Acquisition Manual. Chicago, Commission on Cancer, American College of Surgeons, 1990.
- International Classification of Diseases for Oncology, First Edition, 1976. World Health Organization
- Percy, CL; Van Holten, V.; Muir, CM, eds. International Classification of Diseases for Oncology, Second Edition, World Health Organization, 1990.
- Shambaugh, EM; Ries, LG; Young, JL; Kruse, MA; Platz, CE; Ryan, RF; and Weiss, MA. SEER Extent of Disease--1988: Codes and Coding Instructions. NIH Publication No. 92-2313.
- Shambaugh, EM; Ries, LG; et al. The SEER Program Code Manual. NIH Publication No. 92-1999.





## INDEX

- Abstract, 3, 9, 11, 15-17, 21, 22, 231
- Abstracting a medical record, 5, 3, 13, 15-17, 21, 22, 25, 201, 226, 231, 239, 245
  - Biographical information, 7, 17, 20
  - Diagnostic procedures, 16, 22, 25, 29, 33, 37, 41, 45, 49, 53, 57, 61, 69, 71, 75, 76, 85, 87, 96, 99, 100, 109, 113, 117, 125, 128, 129, 132, 136, 140, 158-160, 162, 166, 169, 172, 184, 190, 195, 199, 202, 213-215, 243, 246, 253
  - How to Abstract, 15, 17, 19
  - Medical history, 1, 7, 11, 20, 21
  - Patient identification, 1, 7, 17
  - Pertinent findings, 9
  - Selection of tumors for, 15
  - What to abstract, 15, 22
  - When to abstract, 16
- Adenopathy, 258
- Admission sheet, 10
- Agranular leukocytes, 96, 97
- Allergy, 255, 264
- Anal verge, 125
- Anemia, 99
- Anesthesia record, 10
- Anesthesia, 255, 257, 260, 264, 267
- Angiogram (cerebral, cardiac), 40
- Angiography, 40
- Aplastic anemia, 99
- Arteriography, 40
- Aspiration biopsy, 109, 111, 113, 165, 195
  - Example E20,
  - Example F13
- Atelectasis (definition), 129
- Auscultation, 255, 260, 264, 267
- Autopsy report, 9, 10, 16, 226, 227, 229, 231, 233-237, 239
  - Abstracting, 231
  - Clinicopathologic correlation, 229, 231
  - Example G10, 227-229, 231
  - Example G11, 233-237, 239
- Autopsy, 10, 194, 226, 228, 229, 231
  
- Barium enema (see Lower GI series), 41, 255, 264
- Barium swallow (See Upper GI series), 40
- Basal cell carcinoma, 255
- Basophils, 97-101, 105
- Bibliography, 279
- Bilirubin, 8, 118, 233
- Biographical information, 7, 17, 19
  - Age, 17, 19
  - Birthdate, 19
  - Marital status, 20
  - Medical history, 20
  - Name, 17
  - Occupational history, 20
  - Place of birth, 19

Biographical information (Cont'd)  
 Race, 19  
 Sex, 19  
 Social history, 7, 20

Biopsy techniques, 109, 134, 164, 170, 174, 195  
 Example F18A, 185, 190  
 Example G1, 195, 197, 199  
 Example G2, 203

Biopsy, 257, 264

Blood counts (normal values),  
 CBC (Complete Blood Count), 98, 100, 103  
 Development of white blood cells, 97  
 Differential, 98, 101, 227  
 RBC (Red Blood Count), 98, 100, 101, 103, 105, 227  
 WBC (White Blood Count), 98, 100, 101, 105, 227

Blood serum studies, 115, 119  
 Serum acid phosphatase, 115-117  
 Serum alkaline phosphatase, 8, 116, 227  
 Serum calcium, 8, 115

Blood urea nitrogen (BUN), 8, 118

Body section radiography, 39

Bone marrow biopsy,  
 Example E18, 103  
 Example G8, 221

Bone marrow,  
 Aspirate, 111, 113, 117, 164, 166, 221  
 Biopsy, 109, 195, 221, 225, 242  
 Studies, 109

Bone scan, 76, 83, 85  
 Example E14, 83, 85  
 Figure 1, 77

Brain scan, 79, 85  
 Example E12, 79, 85, 160  
 Figure 1, 77

Bronchial washings (See Cytologic examinations and reports), 251, 253

Bronchitis, 255, 264

Bronchogram, 40

Bronchography, 40

Bronchoscopy, 123, 129, 150, 152, 154, 159, 160  
 Example F10, 151, 160  
 Example F11, 153, 160  
 Example F12, 155, 160  
 Example F9, 149, 159

Brushings (Cytology procedures), 242

BUN (Blood urea nitrogen), 8, 91, 118

Cancer registry abstract (see Abstract), 3, 9-11, 128, 140, 158, 193

Carcino-embryonic-antigen (CEA), 119

Carcinogens, 7, 20

Carcinoma, 255, 257, 262, 264, 265, 267, 268

Cardiac angiogram, 40

CAT scan (see Computerized axial tomography), 39

CEA (Carcino-embryonic antigen), 119

Cerebral angiogram, 40  
 Chemistry (See also Laboratory reports), 8  
 Chemotherapy report(s), 9, 10  
 Chest x-ray, 31, 59, 61, 67, 69  
     Example E1, 29, 31, 33  
     Example E10, 67, 69  
     Example E7, 57, 59, 61  
 Cholecystogram, 41  
 Cholecystography, 41  
 Clinical examinations,  
     Diagnostic nuclear medicine, 29  
     Hematologic, 29  
     Other imaging, 29  
     Physical, 29  
     Radiographic, 40  
     Radioisotope scintillation scanning, 76  
     Radiologic, 29, 40  
 Clinical examinations: physical, radiologic, diagnostic nuclear 27-33, 35-46, 48, 50-60, 62-69, 71, 73-84, 86-91, 94-106, 108, 110-119  
 Clinical history, 91, 174  
 Colonoscope, fiberoptic, 125  
 Colonoscopy, 123, 125  
 Committee on Cancer, 20, 226  
 Composition of a medical record, 3, 5, 7  
 Computerized (axial) tomography, 39, 71, 73  
     Example E11, 71, 73, 75  
 Consent to operation and treatment, 10  
 Consultation report(s), 8, 10, 57, 59, 67, 83, 91  
 Contrast media, 40, 41, 71, 73  
 CT Scan (See Computerized Tomography), 71, 73, 75  
 Culdoscopy, 162  
 Culture, 8, 164  
 Curettage, 195  
 CVA, 257, 265  
 Cystocopy,  
     Example F3, 123, 133-134, 136, 199  
 Cystogram, 40  
 Cystoscopy, 123, 133  
 Cystourethrogram, 41  
 Cytologic examination (study of cells) and reports,  
     Bone marrow aspiration, 109  
 Cytologic examinations (study of cells) and reports, 9, 109, 193, 194, 241, 242, 245, 246  
     Ascitic fluid, 119, 241  
     Bone marrow aspiration, 95, 109, 111, 113, 164, 166, 195, 221, 225, 229, 242  
     Bronchial washings, 251, 253  
     Cervical cells, 243  
     Cytology procedures in general, 242  
     Exfoliative cytology, 242  
     Papanicolaou classification, 243  
     Papanicolaou smear, 243  
     Paracentesis, 242  
     Prostatic secretions, 242

Cytologic Examinations (Cont'd)  
     Spinal fluid, 249  
     Tracheal washings, 159, 246, 253  
     Vaginal cells, 242  
 Cytology report(s), 10

Death certificate(s), 9, 10, 226  
 Definitive surgery (See surgery), 168, 169  
 Diagnosis, 23, 25, 26, 226-229, 231, 233-237, 239, 257, 265, 274  
     Autopsy, 226-229, 231, 233-237, 239  
     Clinical, 20, 156, 197, 201, 203, 205, 211, 217, 219, 223, 226, 245  
     Date of, 17,-20, 21, 226  
     Final, 9, 226, 239  
     Findings, 9, 25, 26, 29, 37  
     Impression, 8, 22, 25, 29, 140, 160  
     Post-Operative, 164, 203, 205  
     Pre-operative, 134, 164, 201, 251  
     Previous, 20  
     Provisional (see Diagnosis, Impression), 8  
 Diagnostic nuclear medicine examinations and reports, 10, 76, 77, 79  
     Diagnostic imaging/scans, 8, 76, 77, 79  
     Example E12, 79, 85, 160  
     Example E13, 81, 85  
     Example E14, 83, 85  
     Figure 1, 77  
     Radioisotope exposure record, 10  
     Radioisotope, 10  
     Radiologic, 8  
 Diagnostic procedures, 7, 22, 23, 25, 26, 41, 123  
     Abstracting, 22  
     General description, 23-26  
     Indirect procedures, 29, 31, 33, 35, 37, 39-41, 43, 45, 47, 49, 51, 53, 55-57, 59, 61, 63, 65, 67, 69, 71, 73, 75-77, 79, 81, 83, 85, 87, 89, 91, 95, 96-101, 103, 105, 107, 109, 111, 113, 115-119  
 Diagnostic procedures, General description, 23  
 Diagnostic x-ray (see Radiologic examinations and reports), 10  
 Differential, 98-101, 105, 227  
 Digital examination, 128, 144, 158  
 Discharge summary, 10, 11  
 Doctor's order sheets, 10  
 Doctor's progress notes, 10  
 Dyspnea, 257, 265

Echogram (Ultrasonogram), 45  
 Echogram, 45  
 Electrocardiogram (EKG) report, 8, 10  
 Electroencephalogram (EEG) report, 10  
 Emergency room report, 10  
 Endoscopic examination, 8, 123, 125, 129, 130, 134, 138, 142, 144, 146, 148, 150, 152, 154, 156, 158, 160  
     Abstracting, 125, 128, 129, 132, 136, 140, 158-160, 164, 166  
     Example F1, 125, 128  
     Example F10, 151, 160

Endoscopic examination (Cont'd)  
     Example F11, 153  
     Example F12, 155  
     Example F5, 141  
     Example F6, 143  
     Example F7, 145  
     Example F8, 147  
     Example F9, 149  
 Endoscopy report, 10  
 Eosinophils, 97-101, 105, 203, 229  
     Polymorphonuclear (PME), 100  
 Erythrocytes, 95, 96, 98, 99, 105, 251  
 Esophagogastroscopy, 138, 140  
     Example, 138  
 Esophagoscopy, 123, 154, 156, 159, 160  
     Examples, 123, 160  
 Esophagram, 43, 45, 59, 61  
     Example, 43  
 Excisional biopsy, 195  
 Exfoliative cytology, 241  
 Exploratory laparotomy, 169, 170, 172, 174  
     Example F14, 169  
 Exploratory Surgery, 8, 168  
 Extent of disease, 15, 26, 69, 71, 184, 193, 202  
 Extrinsic (definition), 81, 148, 159  
  
 Family medical history, 7  
 Fine needle aspiration, 242  
 Fingerstick method for obtaining blood, 95  
 Fistulogram, 41  
 Fluoroscopy, 41, 43  
     Example, 41  
 Follow-up reports, 9, 17, 18, 107  
 Forms contained in medical records, 10  
 Friable, 126, 130, 142, 144, 152, 156, 160, 236  
     Definition of, 160  
 Frozen section, 170, 172, 186, 190, 195, 205-208  
  
 Gallium scan, 76  
 Gastrectomy, 169, 182, 184, 211  
     Example, 169, 184  
 Gastroduodenostomy, 169, 170  
     Example F17, 169-170, 181-183, 225  
 Gastrointestinal, 257, 262, 265, 268  
 Gastroscopy, 123, 136, 138, 140, 142, 144, 146, 148  
     Example F3, 133, 135  
     Example F7, 145, 158  
     Example F8, 147, 159  
 Geocoding, 19  
 -gram (definition), 29  
 Granulocytes, 96, 97, 100, 105, 111

-graph (definition), 29  
Graphic report(s), 10  
-graphy (definition), 29  
Gross description, 200, 201, 203, 205, 211, 217, 219, 221, 251

Hct (Hematocrit), 100, 107, 227  
Hematocrit (HCT), 96, 98, 100, 101, 105, 180  
Hematologic examinations and reports, 10, 95-97  
    Example E15, 89, 93  
    Example E16, 91, 93  
    Example E17, 99-101, 107  
Hematologic, 8, 27, 29, 95, 107, 109  
Hemoglobin, 96, 98-101, 105  
History and physical examination, 10, 226  
Hodgkin's disease, 118, 164, 166  
    Example, 166  
Hormonal/steroid studies, 117  
How to abstract medical records, 18-20  
How to abstract, 3, 13, 15, 17, 20-22, 25  
Hypaque (contrast media), 40

Ileogram, 41  
Imaging, 8, 10, 27, 29, 39, 41, 71, 76, 87, 89  
    Magnetic, 87, 89  
    Spectroscopic, 87  
Immunotherapy report(s), 10  
Incisional biopsy, 195  
Informed consent to treatment, 10  
Infrared (definition), 53  
Infusion nephrotomography, 41  
Intake-Output chart, 10  
Intraoperative imaging, 41  
Intravenous urography, 40  
Intrinsic (definition), 159  
Iodine, 40, 76  
Isotope (definition), 10, 71, 76, 79, 81, 85  
IVP (intravenous pyelography), 40, 91, 180  
IVU, 40

Kidney, 258, 266  
KUB (Kidneys, Ureter, Bladder), 29

Laboratory report(s), 8, 10, 25  
Lactic acid dehydrogenase (LDH), 119  
Laminogram, 39  
Laminography, 39  
Laparoscopy, 162  
    Laparotomy, 169, 170, 172, 174, 184  
    Example F14, 169  
    Example F15, 173  
    Example F16, 179  
    Example F17, 181-183

Laryngogram, 65, 69  
     Example E9, 65, 69  
 Laryngoscopy, 123, 129  
     Example F2, 129  
 LDH (see Lactic acid dehydrogenase), 8, 119, 258, 266  
 LDH, 8, 119  
 Leukemia, 15, 99, 101, 107, 109, 111, 113, 118, 227-229, 231, 255, 257, 264, 265, 277  
     Example, 109  
     Lymphocytic, 255, 257, 264, 265, 277  
 Leukocytes, 95-100, 105, 251, 255, 264  
 Leukocytosis, 99  
 Leukopenia, 99  
 Liver scan, 71, 81, 85, 174, 176, 182, 233  
     Example E13, 81, 85  
 Lower GI series, 41  
 Lumen (definition), 43, 63, 73, 126, 128, 138, 140, 150, 183  
 Lymphadenopathy, 258  
 Lymphangiogram, 40  
 Lymphoblast, 97, 99, 101, 107, 111  
 Lymphocytes, 97, 98, 100, 101, 103, 105, 111, 221  
 Lymphocytic leukemia, 255, 257, 264, 265  
 Lymphoma, 15, 107, 109, 118, 164, 166, 221, 225  
     Example, 166, 225  
 Lymphoscintigraphy, 76

Magnetic resonance imaging (MRI), 87, 89  
 Mammography, 49  
     Example E5, 51, 53  
 Manipulative and operative procedures, 121-123, 125-131, 133, 134, 136, 137, 139, 141, 143, 145, 147, 149, 151, 153, 155, 157, 159-164, 166, 168-171, 173, 175, 177-179, 181-185, 187, 189  
 Marrow acid phosphatase, 117  
 Mastectomy, 184, 188, 190, 205  
 Mediastinoscopy, 162, 164, 166  
     Example F13, 163  
 Medical history, 7, 11, 20, 25  
     Admission date, 21  
     Chief complaint, 25  
     Composition of, 7  
     Date of diagnosis, 20, 21  
     Date of discharge, 21  
     Family medical history, 7  
     Other previous neoplasms, 21  
     Personal medical history, 7, 11  
     Previous diagnosis, 20  
     Previous neoplasm, 20  
     Previous treatment, 20  
     Review of symptoms (R.O.S.), 7  
 Medical records, 3, 5-13, 19, 25, 26, 91, 243  
     Abstracting, 10, 22  
     Composition of, 5-13  
     Forms contained in, 10  
     Organization, 10



Medication record, 9, 10  
 Metamyelocyte, 97, 101  
 Metastatic series, 33, 35, 37  
 Microscopic examination, 25, 95, 191-198, 200-204, 206-209, 229, 241  
 Monoblast, 97  
 Monocytes, 97-101, 103, 105, 229  
 MRI (magnetic resonance imaging), 87, 89, 91  
     Example E15, 89  
 Mucosa (definition), 126, 138, 140, 142, 144, 148, 152, 159, 197, 211, 212, 214, 223, 227, 228  
 Multiple primary tumors, 15  
 Myeloblast, 97, 101  
 Myelocytes, 98, 101, 105  
 Myelography, 41

Nasopharyngoscopy, 123  
 Needle biopsy, 195  
 Neoplasm, 274  
 Nephrotomography, 41  
 Neutrophils, 97-101, 103, 105  
     Banded, 97, 98  
     Juvenile, 97, 98  
     Polymorphonuclear (PMM), 100  
     Segmented, 98, 103  
     NMR chemical-shift imaging, 87  
 Normal alkaline and acid phosphatase values, 116  
     Bessey-Lowry method, 116  
     Bodansky method, 116  
     Gutman method, 116  
     King-Armstrong method, 116  
     Shinowara method, 116  
 Normal blood values, 97, 98  
 Normal marrow acid phosphatase values, 117, 118  
 Nuclear medicine (see Diagnostic nuclear medicine), 10  
 Nuclear medicine report,  
     Diagnostic imaging/scans, 10  
     Radio-isotope exposure record, 10  
 Nuclear medicine, 10, 76, 79, 81, 83  
 Nurses' notes, 9, 10

Objectives and content of instructional package, 3, 6  
 Oncology, 258, 266, 273, 274, 277  
 Operative pathology report, 178, 200  
 Operative procedures and reports, 10  
 Ophthalmoscopy, 123  
 Organization of a medical record, 3, 5, 7, 11  
 Other previous neoplasms, 21  
 Otoscopy, 123, 124  
 Outpatient clinic record, 10

Palpate, 260, 267  
 Palpation, 29  
 Panendoscopy, 123

**Papanicolaou classification, 243**  
**Papanicolaou smear, 243**  
**Paracentesis, 242**  
**Pathologic examinations and reports, 10**  
     Abstracting, 160  
     Example G6, 217, 225  
     Example G7, 219-220, 225  
     Example G8, 109, 221, 225  
     Example G9, 223, 225  
**Patient follow-up,**  
     Employer, 18  
     Nearest relative or friend, 18  
     Physician (family doctor, referring physician, hospital staff), 18  
**Patient identification, 7, 17**  
     Name, 17  
**Patient numbers,**  
     Hospital, 17  
     Registry, 18  
**Patients identification,**  
     Address, 18  
     Social security number, 18  
     Spouse, 18  
**Pelvic examination, 134**  
**Pelvic inflammatory disease, 260, 267**  
**Percutaneous biopsy, 195**  
**Peripheral blood, 95, 221**  
**Peritoneoscopy, 162**  
**PET, 71**  
**Phosphatase, 8, 115-117, 227**  
     Acid, 116, 117  
     Alkaline, 115, 116, 227  
     Marrow, 117  
**Photoscanner, 76**  
**Physical examination, 8-10, 25, 29, 180, 201, 226**  
**Physical therapy report, 10**  
**Plain films, 29**  
**Planograms, 39**  
**Plasma, 95, 105, 241**  
**Platelets, 95, 97-100, 103, 105, 107, 227**  
**PME, 97, 100, 103**  
**PMN, 100, 103**  
**Pneumocolon, 41**  
**Polycythemia vera, 99, 103, 107, 118**  
**Positron emission tomography (PET), 71**  
**Pre-operative diagnosis, 134, 170, 251**  
**Previous diagnosis, 20**  
**Previous treatment, 20**  
**Primary site, 9, 15, 18, 69, 169, 176, 200, 202, 226**  
**Proctoscopy report,**  
     Example F1, 125, 128  
     Proctoscopy, 123, 125, 126, 128, 144, 158

Progress notes, 9, 10  
     Doctor's orders and notes, 9, 10  
     Nurses' notes, 9, 10  
 Prolymphocyte, 97  
 Promonocyte, 97, 100, 103  
 Promyelocyte, 97, 101  
 Protein, 8, 96, 119, 227, 251  
     Total, 96, 119, 227, 251  
 Protocol study report, 10  
 Provisional diagnosis, 8  
 Punch biopsy, 195  
 Punctures (Cytology procedures), 242  
 Pyelogram, 40, 134, 136  
  
 Radiation therapy summary, 10  
 Radioisotope, 76, 79, 81  
 Radiologic examinations and reports, 8, 10, 33, 35, 37  
     Abstracting, 33  
     Body section, 31  
     Chest x-ray, 29, 31  
     Example E1, 31  
     X-ray series, 29  
 RBC, 98-101, 103, 105, 227  
 Recovery room report, 10  
 Red blood cells, 96  
 Referral information, 7, 10  
 Renal flow study, 41  
 Renografin (contrast media), 40  
 Request to blood bank report, 10  
 Reticulocytes, 98, 100, 105  
 Reticulum cell sarcoma, 260, 267  
 Retrograde ileogram, 41  
 Retrograde pyelography, 40, 134  
 Retrograde urography, 40  
 Roentgen (definition), 29, 51  
  
 Salpingography, 41  
 Sarcoma, 260, 262, 267  
 Scans, 8, 10, 71, 76, 79  
 Scintillation scanning, 76, 79  
 Scintiscan, 76  
 Scrapings, 242  
 Sequence number, 15  
 Serology report, 10  
 Serum acid phosphatase, 115-117  
 Serum alkaline phosphatase, 115, 116  
 Serum calcium, 115  
 SGOT, 8, 119  
 Sialography, 41  
 Sigmoidoscopy, 123, 125, 142, 158  
 Simultaneous multiple analysis (SMA), 8  
 Sonogram, 45

Special examinations, 8  
 SPECT, 71  
 Spectroscopic imaging, 87  
 Spinal fluid, 249  
 Sponge (Gel-Foam) biopsy, 183, 186, 188, 195  
 Sputum, 242, 247, 249  
 Stem cell, 97  
 Steroid studies, 117  
 Study of cells, 193, 194, 241  
 Study of tissue, 193, 194, 241  
 Surface biopsy, 195  
 Surgery, 8-10, 71, 117, 126, 142, 144, 148, 164, 168, 169, 174, 178, 182, 184, 186, 188, 193, 197, 200, 217, 223, 233, 246, 249  
     By-pass, 168  
     Definitive, 168  
     Exploratory, 8, 71, 168, 169  
 Surgical biopsy, 109, 195  
 Swabs, 242  
  
 Technetium, 76, 81, 83  
 Tentative diagnosis, 25  
 Therapy, 9, 10, 16, 118, 227, 229  
 Thermography, 53, 55  
 Thoracentesis, 242  
 Thoracoscopy, 162  
 Thrombocytes, 95, 97, 105  
 Thrombocytopenia, 99  
 Tissue examination, 9, 251  
 Tomograms, 39, 73  
 Tomography, 39, 41, 71  
     Emission computerized, 71  
 Total biopsy, 195  
 Total protein, 8, 119, 227  
 Treatment (therapy), 9-11, 16, 17, 20, 21, 107, 117, 136, 249  
     Chemotherapy, 9, 10  
     Immunotherapy, 9, 10  
     Medication, 9  
     Physical therapy, 9  
     Radiation therapy, 9  
     Surgery, 9, 117  
 Trepine (definition), 109, 195  
 Tuberculosis, 262, 268  
 Tumor board summary, 10  
 Tumors, 15, 25, 26, 45, 71, 76, 117, 203, 229  
     Multiple primary sites, 15  
     Premalignant, 15, 26  
     Primary site, 15, 18, 69, 169, 176, 200, 202, 226  
     Size of tumors, 169, 200, 202  
     Unrelated primary site, 15

- Ultrasonogram, 45
- Ultrasonography, 45
- Upper GI series, 40, 63, 182
  - Example E8, 61, 63, 69
- Uric acid, 8, 118
- Urogram (pyelogram), 40
- Urogram, 40
- Urography, 40
  - Cystogram, 40
  - IVP (intravenous pyelography), 40
  - Urogram (pyelogram), 40
  
- Vaginoscopy, 123
- Venipuncture, 95
- Venography, 40
- Visualization, 41, 129, 148
  
- Washings, 159, 242, 246, 253
- WBC, 98-101, 103, 105, 107, 227
- What cases to abstract, 15
- When to abstract, 16
- White blood cells, 96, 97
  
- X-ray series (see also Radiologic examinations and reports), 29, 33, 39
  - Metastatic series, 37
- X-ray,
  - Example E1, 29, 31, 33
- Xeroradiography, 49

## Index of Examples

- Example E1 29, 31, 33
  - Example E2 33, 35, 37
  - Example E3 41, 43, 45
  - Example E4 45, 47, 49
  - Example E5 49, 51, 53
  - Example E6 53, 55, 57
  - Example E7 57, 59, 61
  - Example E8 61, 63, 69
  - Example E9 65, 69
  - Example E10 67, 69
  - Example E11 71, 73, 75
  - Example E12 76, 79, 85
  - Example E13 76, 81, 85
  - Example E14 76, 83, 85
  - Example E15 89, 93
  - Example E16 91, 93
  - Example E17 99, 101, 107
  - Example E18 99-100, 103, 107
  - Example E19 99-100, 105, 107
  - Example E20 109, 111, 113
- 
- Example F1 123, 125, 127
  - Example F2 129, 131
  - Example F3 123, 133, 135, 199
  - Example F4 123, 137, 139
  - Example F5 123, 141, 157
  - Example F6 123, 143, 157
  - Example F7 123, 145, 157
  - Example F8 123, 147, 158
  - Example F9 123, 149, 158
  - Example F10 123, 151, 159
  - Example F11 123, 153, 159
  - Example F12 123, 155, 159
  - Example F13 161, 163, 165
  - Example F14 168-169, 171
  - Example F15 168, 171, 173, 175
  - Example F16 168, 177, 179, 183
  - Example F17 168, 177, 181-183, 225
  - Example F18A 185, 189
  - Example F18B 187, 189
- 
- Example G1 195, 197, 199
  - Example G2 202-203, 213
  - Example G3 202, 205-206, 213
  - Example G4 202, 207-209, 214
  - Example G5 202, 211-212, 214
  - Example G6 215, 217, 225
  - Example G7 215, 219-220, 225
  - Example G8 109, 215, 221, 225
  - Example G9 215, 223, 225

## Index of Examples (Cont'd)

**Example G10** 226-229, 231  
**Example G11** 231, 233-239  
**Example G12** 245, 253  
**Example G13** 247, 253  
**Example G14** 249, 253  
**Example G15** 193, 251, 253